

We are IntechOpen, the world's leading publisher of Open Access books Built by scientists, for scientists

6,900

Open access books available

186,000

International authors and editors

200M

Downloads

Our authors are among the

154

Countries delivered to

TOP 1%

most cited scientists

12.2%

Contributors from top 500 universities



WEB OF SCIENCE™

Selection of our books indexed in the Book Citation Index
in Web of Science™ Core Collection (BKCI)

Interested in publishing with us?
Contact book.department@intechopen.com

Numbers displayed above are based on latest data collected.
For more information visit www.intechopen.com



Surgical Treatment of Ovarian Cancer

Lucas Minig, M. Guadalupe Patrono,
Rafael Alvarez Gallego,
Javier Valero de Bernabé and Ivan Diaz-Padilla

Additional information is available at the end of the chapter

<http://dx.doi.org/10.5772/53972>

1. Introduction

Despite great efforts in developing novel screening, diagnosis and therapeutic strategies, the incidence and mortality of ovarian cancer have not significantly changed in the last 30 years. [1] It remains the leading cause of death from gynecologic malignancy with a lifetime probability of developing the disease of 1 in 59.[1] Worldwide, approximately 200.000 women are annually diagnosed with ovarian cancer,[2] and almost 70% of them will be diagnosed at advanced stage disease.[3] With current treatment modalities, the 5-year survival rate ranges from 80–95% for those with organ-confined or early stage disease (International Federation of Gynecology and Obstetrics (FIGO) stage I-II); to 30 – 40% for those women with advanced disease, FIGO stage III-IV. Thus, ovarian cancer is a challenging and complex malignancy.[4]

Surgical management of ovarian cancer remains as the cornerstone treatment of this disease. [5] An adequate full surgical staging in women with early stage disease has demonstrated to improve oncologic outcome.[6] On the other hand, complete surgical cytoreduction is the only modifiable prognosis factor for patients with advanced disease. This chapter will describe the rationale and surgical steps for an adequate surgical staging for women with early stage ovarian cancer, and for obtaining the maximal surgical cytoreduction in women affected by advanced stage and relapsed disease.

2. Surgical treatment of early stage epithelial ovarian cancer

Approximately 25% of newly diagnosed ovarian cancer will be early stage disease. Prognosis is good with survival rates ranging from 80 % to 95 % when recommended treatment is

followed.[5] These patients are initially managed by comprehensive surgical staging, which is relevant not only for identifying women with truly early stage disease, but also to select patients who will be candidates for adjuvant chemotherapy.

3. Rationale for surgical staging

Adequate surgical staging procedures include: exploration of abdomen/pelvis, peritoneal washings, bilateral salpingo-oophorectomy, hysterectomy, peritoneal biopsies of Cul-de-sac, pelvic walls, paracolic gutters, diaphragm, suspicious areas, omentectomy, appendectomy, as well as pelvic and para-aortic node dissection up to the renal veins. (TABLE 1)[7],[8] These procedures are needed to find hidden disease in nearly 18% of women[8], which has implications in the prognosis and subsequent patient treatment.[9] Surgeon expertise is crucial given that it was correlated with under-staged ovarian cancer. Several studies demonstrated that over 30% of patients operated by general gynecologists or general surgeons were upstaged by gynecologist oncologists by finding disease on pelvic-aortic lymph nodes, diaphragm biopsies and omentum.[6, 10] Moreover, as it has been demonstrated, inadequate initial surgical staging leads to a higher risk of developing recurrent disease despite receiving adjuvant chemotherapy.[6] Thus, if the operative risk is not too high, all patients should be routinely re-staged before starting chemotherapy.

• Peritoneal cytology/ascites drainage
• Careful and systematic abdominal exploration – inspect and palpate all peritoneal surface
• Infracolicomentectomy
• Total abdominal hysterectomy and bilateral salpingo-oophorectomy
• Pelvic and aortic lymphadenectomy
• Random and directed peritoneal biopsies – posterior cul-de-sac, bladder reflection, both pelvic sidewalls and both paracolic spaces
• Biopsy or scrapings from the undersurface of both diaphragms
• Appendectomy (for mucinous histology)

Table 1. Surgical staging procedures for early stage ovarian cancer

4. Surgical staging procedures

Midline vertical incision is the recommended surgical approach for initial management of suspected early stage ovarian cancer. The incision is firstly made from the pubis to the umbilicus and then progressed to xifoid appendix, if surgical staging is indicated following the frozen section diagnosis. The abdominal-pelvic cavity is opened and visualized. If free fluid is present, a minimum sample of 100 cc[3] should be obtained for cytological examination.

Peritoneal washing from paracolic gutters, pelvis and abdominal cavity should be done in the absence of ascites. It is estimated that over 30% of patients with stage I disease have tumoral cells on cytological examination.[11] Careful inspection and palpation is preformed to detect extra-ovarian implants in a systematic way: starting by right paracolic space, advancing the hand to the right kidney, suprahepatic space, the right diaphragm, right hepatic lobe, gallbladder, Morrison's pouch, left hemi-diaphragm, left hepatic lobe, spleen, stomach, transverse colon, left kidney and left paracolic space. The lesser sac is entered on the left side of the gastrocolic ligament. Both surfaces of the mesentery should be examined and retroperitoneal vascular areas should be palpated as well. The result of this comprehensive procedure should be properly described.

The ovaries need to be examined for capsule rupture or external excrescences. The affected ovary must then be removed for frozen section. Although the influence on the prognosis of the intraoperative rupture of malignant ovarian tumors is controversial,[12] adnexal masses should be removed intact. If malignancy is confirmed in the frozen section, full surgical staging, as previously described, must be performed by the extension of the incision up to xifoid appendix. Contralateral oophorectomy and total hysterectomy is completed due to the possibility of synchronous cancer.

Even though controversial, random peritoneal biopsies are indicated in early-stage disease. A retrospective study demonstrated that less than 4% of patients with ovarian cancer were upstaged due to positive peritoneal biopsies. No patient, however, had a change in treatment recommendations based on these biopsies.[13] Infracolic omentectomy should be performed from the hepatic to splenic flexure. During dissection, the lesser sac is developed dissecting the posterior and anterior layer of the transverse mesocolon, while preserving the middle colic artery. The omentum is removed and the pedicles are sequentially sutured – ligated. Appendectomy is only reserved for mucinous histology.

5. Retropetitoneal lymph node dissection

The incidence of lymph-node involvement in patients with disease confined to the ovary is 5% in only pelvic nodes, 9% in aortic nodes and 6% in both pelvic and aortic nodes.[14] Systematic lymphadenectomy as part of surgical staging of apparent early stage ovarian cancer is associated with a statistically significant increase in median operative time, median blood loss, and the proportion of patients undergoing blood transfusions.[15] Systematic lymphadenectomy, however, significantly improves progression-free survival (PFS) rates, without a statistically significant impact on overall survival (OS). [14, 15] Lymphatic drainage of the ovaries is known to follow the gonadal blood supply that reaches the renal vein, on the left side, and the inferior vena cava, on the right side. Pelvic lymphadenectomy should include removal of nodes from paravesical and pararectal spaces, including bilateral common iliac nodes. Aortic nodes should be removed from aortic bifurcation to the renal veins.[14]

6. Minimally invasive surgery for surgical staging ovarian cancer

Over the last years, laparoscopy has gained an important role for the management of suspected adnexal masses. High-volume centers have reported their experience in performing a comprehensive surgical staging by using minimally invasive surgery.[16],[17] Nezhat et al. [16] reported a case series of 36 patients with early stage invasive ovarian carcinoma managed by laparoscopy. They showed 100% OS rate with a mean duration of follow-up of 55.9 months. Chi et al. [17] conducted a case control study by staging 20 patients with early ovarian cancer with laparoscopy compared with 30 patients staged with laparotomy. There were no differences in the omental specimen size or number of lymph nodes removed. Blood loss and hospital stay were lower for the laparoscopy group, with longer operating time. There were no conversions to laparotomy or other intraoperative complications in the laparoscopy group.

Despite laparoscopic staging of early ovarian cancer seems to be a safe and feasible procedure performed by expert surgeons, the possibility of cyst rupture or port-site metastases remain controversial. The immediate effect of tumor rupture is that a patient with a potentially curable disease will require additional adjuvant chemotherapy. Preoperative evaluation is essential, as well as the surgical experience and the quality of laparoscopic instruments.[18] Even though there are no specific recommendations, adnexal masses up to 5-6 cm could be reasonably managed by laparoscopy.

The etiology of port-site metastases is uncertain. Several hypotheses include tumor cell entrapment, direct spread from the trocar in which instruments are exchanged, and the “chimney effect,” which suggests that tumor cells travel along the sheath of the trocars with the leaking gas. Port-site metastases have been reported in 1% to 2% of patients with ovarian cancer. However, <5% of port metastases are clinically detected and these sites are likely to respond to chemotherapy.[9]

Robotic surgery has emerged as an innovative minimally invasive approach in the field of gynecology. The da Vinci Surgical System (Intuitive Surgical, Inc, Sunnyvale, California, USA) offers several advantages over conventional laparoscopy including three-dimensional view, greater dexterity, and tremor filtration. Most of the data regarding the application of robotic technology for ovarian cancer staging are included in the literature used in the assessment for its implementation in other gynecologic malignancies, such as cervical and endometrial cancer.[19] Data are still scarce but promising.

7. Treatment of advanced stage disease: Surgical cytoreduction

Advanced-stage disease means that the disease is extended to pelvic/ aortic lymph nodes, peritoneum, intra-abdominal organs or disease outside the abdominal cavity.[20] In 1975, a landmark study quantified residual disease and demonstrated for the first time an inverse relationship between residual tumor and oncologic outcome.[21] The goal of surgery is to resect as much tumor as possible obtaining, ideally, a complete resection. The standard

worldwide recommendation consists of primary maximal surgical cytoreduction followed by 6 cycles of intravenous carboplatin plus paclitaxel. [5,7] An alternative strategy is reserved for selected patients and it includes surgical cytoreduction in between chemotherapy courses, usually after three or four cycles. This strategy is called neoadjuvant chemotherapy followed by interval debulking surgery. (fig 1) The appropriate selection of patients for each modality of treatment will be described below.

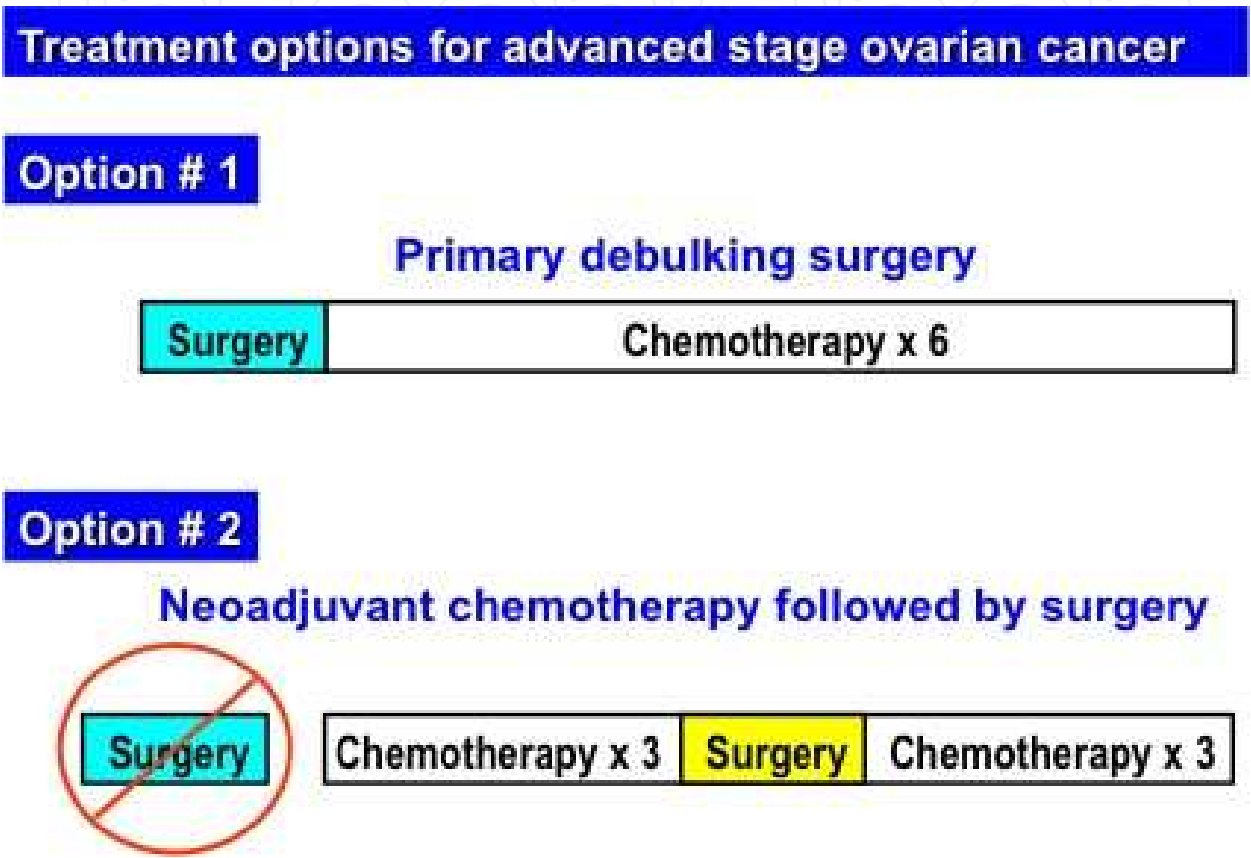


Figure 1. Treatment options for advanced stage ovarian cancer

8. Prognostic factors

Prognostic factors in women with advanced stage EOC was described in literature based on retrospective data.[22] Recently, Du Buois et al., [23] did a combined exploratory analysis of three prospective randomized phase III multicenter trials, which enrolled 3388 patients with advanced EOC between 1995 and 2002. Univariate and multivariate analysis revealed non-modifiable significant prognostic factors for OS and PFS such as: age, performance status (ECOG 2 versus 0-1), FIGO stage (IIIC-IV versus IIB-IIIB), subtype histology (Mucinous versus serous), histology grade (grade 2-3 versus 1), presence of large volume ascites (> 500 mL). The only significant modifiable prognosis factor was postoperative residual tumor (0

versus >1 mm). (Table 2) This study highlighted the importance of an adequate surgical management of women affected by ovarian cancer as the key-point for improving oncologic outcomes given that the quality of surgical cytoreduction was the only modifiable prognosis factor for survival.

Non-modifiable

- Patient performance status
- FIGO stage
- Hystology subtype
- Hystology grade
- Large volume of ascites

Modifiable

- Post-surgical residual tumor

Table 2. Prognosis factors of overall survival and progression free survival in patients with advanced stage epithelial ovarian cancer

9. Rationale for primary surgical cytoreduction

1. **Improvement of oncologic outcomes:** a large body of retrospective and non-randomized prospective studies consistently show an inverse correlation between survival and the amount of postoperative residual disease [22]. Results of two meta-analysis[22],[24] evaluated women affected by advanced stage EOC that were treated with primary surgical cytoreduction and platinum-based neoadjuvant chemotherapy and demonstrated a mean weighted median survival of 29 and 24 months respectively.
2. **Surgical reduction of tumor burden prior to chemotherapy:** it has been postulated that the proportion of tumor cells destroyed with each cycle of chemotherapy is constant. Thus, in cases of tumor cells not resistant to chemotherapy, fewer cycles would be necessary to eradicate them if the absolute number were less.[25] In addition, tumor size is correlated with an increased spontaneous mutation rate of malignant cells.[26] Animal models have also demonstrated that drug exposure allows the resistant cells to outgrow the sensitive tumor cells population.[27] Primary surgical cytoreduction, thus, reduces the number of cancer cells decreasing the chance of inducing drug resistance.
3. **Improved drug diffusion:** large bulky tumors may have hypoperfused areas where concentration of chemotherapy agents can be suboptimal, increasing the possibility of drug resistance.[28]
4. **Increased tumor cells growth rate:** During initial tumor growth, cancer cell division is almost exponential. But then, cell growth reaches a plateau. Thus, the great majority of cells in large tumoral masses are not dividing, being in G₀ phase of the cell cycle, which

are essentially resistant to chemotherapy.[29] Primary surgical cytoreduction may stimulate G₀ residual tumor cells to re-enter in the normal cell cycle, increasing the chemotherapy efficacy.[29]

10. Residual tumor disease: Definition and relevance

Residual tumor disease is commonly described as the diameter, in millimeters, of the biggest nodule left after surgical debulking. Griffiths *et al.*, first described the importance of residual disease after surgery in women with ovarian cancer.[21] They demonstrated an inverse relationship between residual disease and patient survival. In 1994, the Gynecology Oncology Group (GOG) published a sub-analysis of two retrospective series (GOG protocol 52 & 97) of patients affected by advanced stage EOC who underwent primary cytoreduction followed by chemotherapy. The study showed significant differences in OS in women with microscopic disease or less than 2 cm in comparison with of residual disease of more than 2 cm diameter. The maximum diameter of residual disease was firstly found to be an independent predictor of OS after controlling other variables. Thus, surgery with residual disease of less than 2 cm was defined as “optimal” cytoreduction; while more than 2 cm was called “suboptimal”. [30]

In 2002, a meta-analysis of 6885 patients with stage III or IV ovarian cancer was reported. [22]The study analyzed 81 cohorts of patients treated in the platinum era to evaluate the effect of maximal cytoreductive surgery and other prognostic factors on survival. The investigators demonstrated that each 10% increase in the proportion of patients undergoing maximal cytoreduction was associated with a concomitant 5.5% increase in median cohort survival time. The mean weighted median survival time was 29 months. Thus, for all clinical trials that followed, the GOG established ≤ 1 cm residual disease as the criterion for optimal cytoreduction.

Winter III *et al.* [31] reported the GOG collective experience analyzing the data of seven trials (GOG 11, 114, 132, 152, 158, 162 and 172) that studied the efficacy of chemotherapy in 1895 stage III and 360 stage IV ovarian cancer patients. All patients underwent primary debulking surgery followed by 6 courses of cisplatin and paclitaxel. Residual disease after surgery was an independent prognostic factor. The median OS reported was 79.1, 42.4 and 35 months in patients with microscopic, 1-10 mm and > 10 mm of residual disease, respectively. The authors suggested a modification of the term “optimal residual disease” from < 1 cm to microscopic.

These results were confirmed when 3 large phase III randomized trials conducted by the AGO (AGO-OVAR 3, 5 and 7) of patients with stage IIB-IV ovarian cancer receiving platinum/taxanes chemotherapy following primary cytoreduction surgery were analyzed. [23] Patients with microscopic residual disease had significantly longer median OS than those with any residual disease, 99.1 months versus less than 36 months, respectively. Thus the current goal of the surgery in ovarian cancer is to obtain a complete cytoreduction. (Fig 2)

The goal of the surgery in ovarian cancer is to obtain a complete cytoreduction

Figure 2. Goal of the surgery in ovarian cancer

Chang and Bristow in 2012, reported a single institution series and cooperative group trials since 2003 of patients who underwent primary debulking surgery followed by adjuvant chemotherapy. Over 14000 patients in 15 studies were analyzed.[32] A marked inverse correlation between the maximal diameter of residual tumor and OS was noted. The weighted median OS for 3593 patients with no gross residual disease was 77.8 months compared to 39.0 months for the 4780 patients with 0.1–1 cm residual disease and 31.1 months for the 3518 patients with residual tumor >1 cm in maximal diameter. The magnitude of the incremental improvement in OS strongly suggests that complete resection should be the surgical objective whenever feasible.

11. Feasibility of complete primary cytoreduction

In the presence of a preoperative suspected adnexal mass with ascites and peritoneal carcinomatosis are present, the feasibility of complete cytoreduction should be determined by exclusion of multiple liver or pulmonary metastases by imaging studies such as computed tomography (CT). In the absence of extra-peritoneal lesions and surgical contraindications, patients should undergo primary debulking surgery. The feasibility of optimal cytoreduction depends on the disease distribution, the patient's overall medical condition and the surgeon's expertise. However, obtaining an optimal cytoreduction ≤ 1 cm of residual disease is not an easy task. In highly specialized centers, the rate with optimal primary cytoreduction is over 75 %. (Fig 3) But this rate falls down to 25% when low-volume ovarian cancer surgeries centers are included in the analysis. (Fig 4) Nevertheless, as it was previously mentioned, according with collecting data of the latter,[23],[31] primary debulking surgery is beneficial if complete cytoreduction is achieved. According with the literature, this is achievable in only 30% of patients when a gynecologist oncologist performs the surgery, a higher rate when compared with general gynecologists or general surgeons.[33]-[38]

12. Neoadjuvant chemotherapy followed by interval debulking surgery

Despite upfront primary debulking surgery (PDS) for newly diagnosed patients with advanced stage ovarian cancer is considered the standard of care,[5] limitations to this strategy have been postulated.[39],[40] For instance, patients with incomplete primary cytoreduction seem to have no meaningful impact on OS.[23],[31] Furthermore, only experienced surgeons

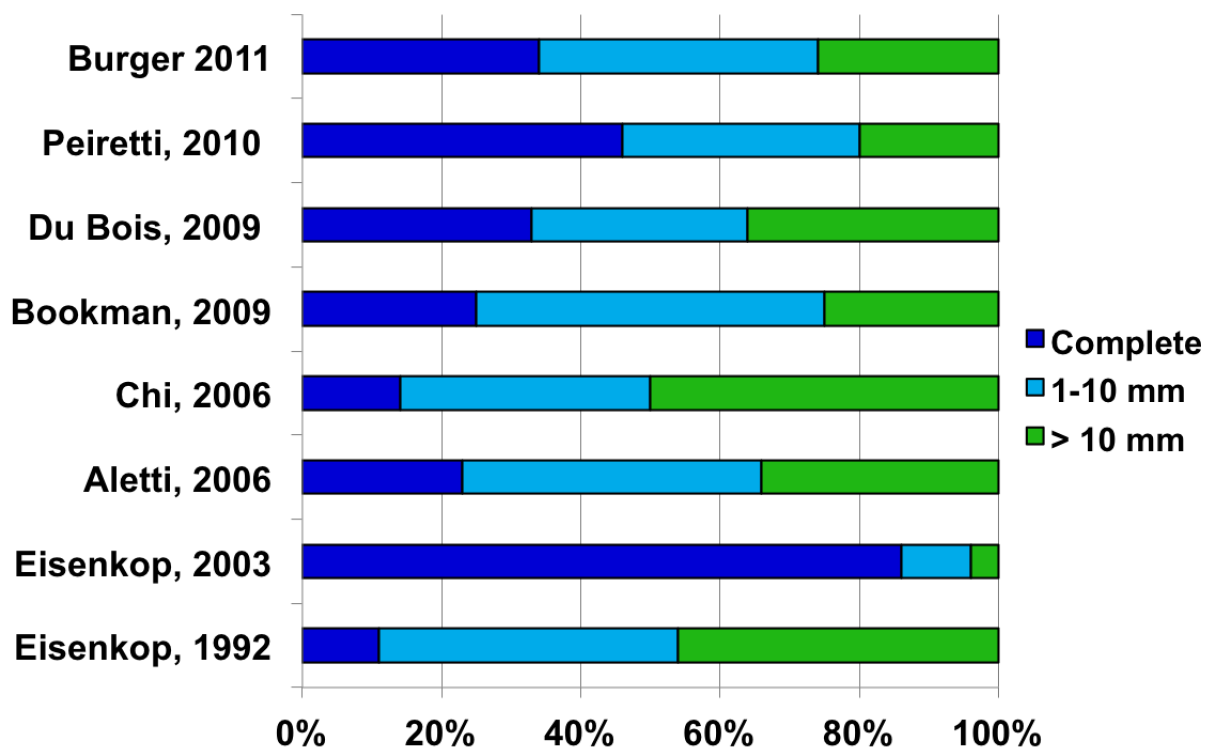


Figure 3. Stratified residual tumor on expert series/international traits

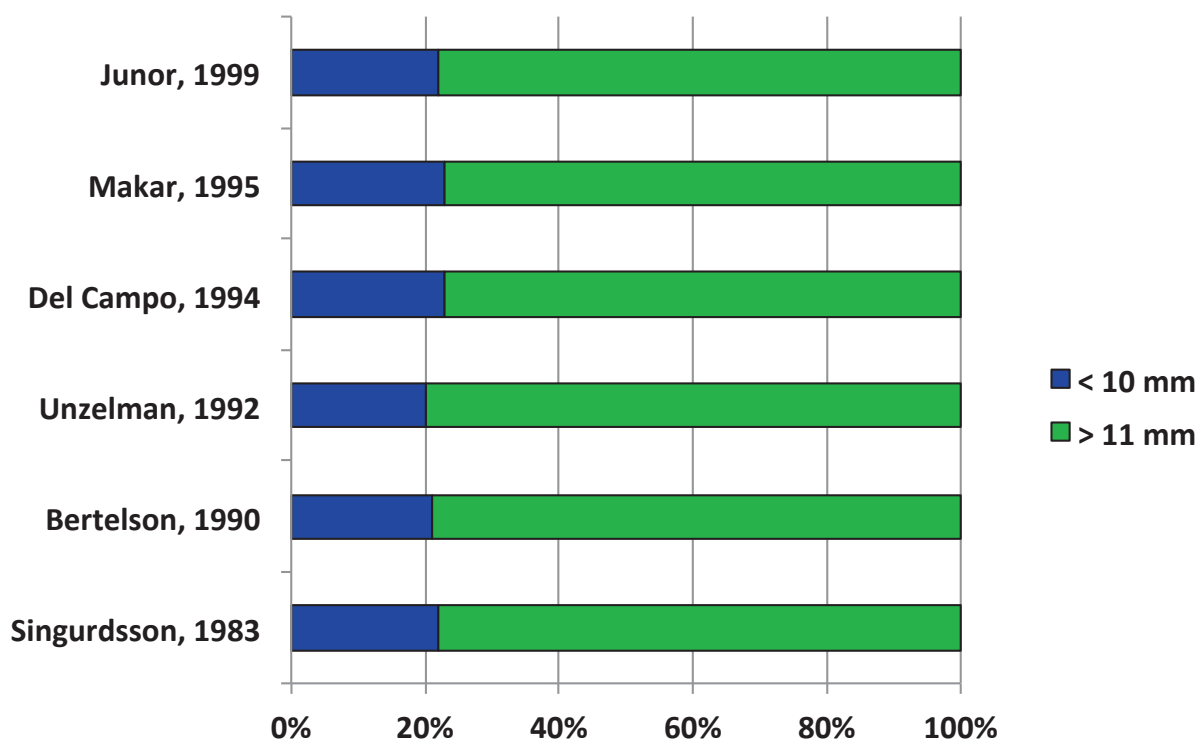


Figure 4. Stratified residual tumor on less experienced centers

with extended formal training in cytoreductive techniques obtain an acceptable complete primary cytoreduction rate.[41]-[43]

Consequently, an alternative approach such as neoadjuvant chemotherapy (NACT) has been proposed by several authors.[39],[40] This strategy of treatment consists in the administration of at least 3 courses of platinum-taxanes chemotherapy followed by an interval debulking surgery (IDS) and further adjuvant treatment in patients responsive to chemotherapy. [44] (Figure 1) The goal of this modality is to reduce the extension of the disease and, by performing a less radical surgical procedure, to improve the complete cytoreduction rate reducing the surgical time and complication rate, while improving the PFS and OS rate.

Objective indications for neoadjuvant chemotherapy are patients with poor performance status and with significant medical co-morbidities making them unsuitable for an aggressive debulking surgery. These indications include, however, the smallest proportion of patients who underwent neoadjuvant chemotherapy in the series published in the literature. [39],[40],[45],[46] The majority of women receive either NACT or PDS based on tumor extension and on estimated tumor resectability.[47] The latter is a subjective and highly surgeon-dependent indication. [24] Although several criteria have been tested for predicting the surgical resectability of ovarian tumors, its accuracy and clinical applicability is still controversial. [48] Some of these criteria include ascites volume, serum CA 125 values[48] and computer tomography scan parameters.[49] For example, terms like “dense adhesion between bowel and omentum”, “large diaphragm disease”, and “large tumor nodules adherent to abdominal structures” have been postulated by some authors as criteria of unresectability.[50] These terms show how subjective is the definition of a patient as debulkable or not. These criteria are mostly based on CT scan findings but, sometimes, a direct laparoscopic assessment of is recommended.[51] (Fig. 5)

On the other hand it is a common belief to associate NACT with less complex surgical procedures, shorter surgical time, and lower incidence of complications after IDS.[44],[46] However, this strategy does not exclude the necessity of performing complex surgical procedures at the time of IDS in order to obtain an optimal cytoreduction. Thus, referring these patients to a specialized gynecologist is mandatory as well.

Recently, the results of a randomized, controlled, prospective trial conducted by the European Organization for Research and Treatment of Cancer (EORTC) were published.[52] Six hundred and seventy patients with stage IIIC and IV ovarian cancer were randomly assigned to primary cytoreductive surgery group or neoadjuvant chemotherapy group. There were no significant differences in OS (29 months for primary cytoreductive surgery group versus 30 months for neoadjuvant chemotherapy group) between the two groups. Complete cytoreduction with no gross residual disease was possible in 20% of patients who underwent primary cytoreduction and 52% of those who had neoadjuvant chemotherapy. On multivariate analysis, the strongest independent predictor factor of prolonged survival was the absence of residual tumor after surgery ($p < 0.001$). The authors concluded that neoadjuvant chemotherapy followed by interval debulking surgery has similar efficacy compared with primary debulking surgery followed by chemotherapy for patients with stage IIIC or

IV ovarian cancer and complete resection of all gross lesions remains the objective of the cytoreductive surgery whether performed as primary or after neoadjuvant chemotherapy. However, optimal cytoreduction (<1 cm residual disease) was achieved in only 41.6% of patients in the PDS arm, a substantially lower rate than the published by expert series.[31],[42],[43] The PFS and OS for patients randomized to the PDS arm were substantially lower than those reported in previous studies, including prospective trials of the Gynecologic Oncology Group (GOG) as well.[30],[31],[43]

A recent report from the Memorial Sloan-Kettering Cancer Center contradicts the findings of the EORTC study and suggests that the strategy of neoadjuvant chemotherapy requires further investigation. A total of 316 stage IIIC–IV ovarian cancer patients were treated at the institution during the same period in which the EORTC-NCIC trial were evaluated, using identical inclusion criteria.[53] The optimal cytoreduction rate was 71% and the median OS time was 50 months. This study suggested that primary cytoreductive surgery should be considered as the preferred initial management strategy for patients with this disease.

It seems, therefore, that neoadjuvant chemotherapy should not be performed routinely in patients with advanced ovarian cancer and be done in selected patients who are at risk of morbidity associated with primary surgery and less likely to have a complete cytoreduction. (Fig. 5)

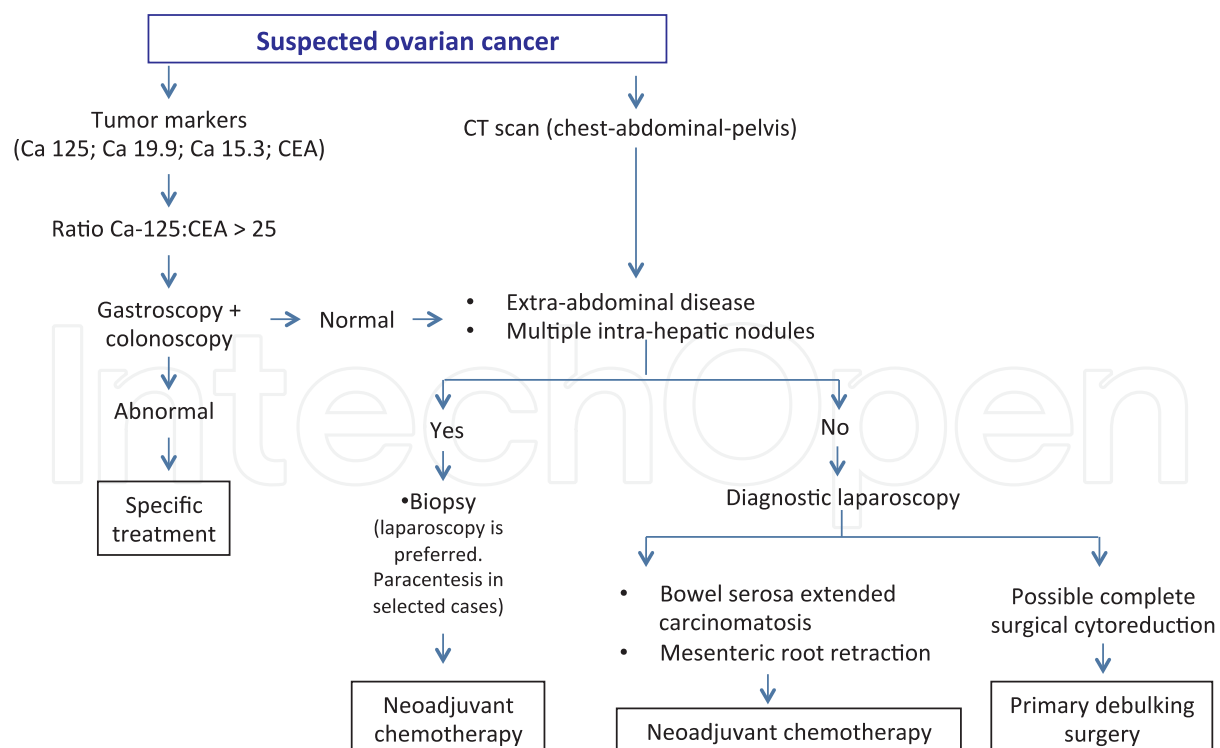


Figure 5. Initial approach of suspected advanced ovarian cancer

13. Surgical cytoreduction technique

Women should be placed on supine position with legs spread apart. Vertical midline incision is recommended in order to access to the entire abdominal cavity. Ascites is evacuated and sent for cytological evaluation. As described above, a careful inspection and palpation of the entire peritoneal cavity and retroperitoneum is carried out in order to assess the extent of the primary and metastatic disease. The localization and diameter of the primary tumor and its extension into surrounding organs is described as the diameter of the larger metastases. Sometimes, there are regions that cannot be accessed before larger tumor masses are removed. This careful inspection and palpation is essential in order to establish the feasibility and extension of surgical cytoreduction. Complete cytoreduction may be difficult in cases of bulky suprarenal nodes, extensive disease in the liver parenchyma, along the root of the small bowel mesentery and in the bowel serosa, close to the origin of the superior mesenteric artery, or in the porta hepatis. If complete surgical cytoreduction is not feasible, neo-adjuvant chemotherapy is preferred. (Figure 5)

Radical omentectomy use to be the first surgical step because it is the first tumor encountered upon entering the peritoneal cavity. The infracolic omentum is separated from the transverse colon and resected. If the omental metastases involve the gastrocolic omentum, it is resected as well. The next step is to remove the primary tumor in the pelvis with the other adnexa and the uterus in the usual fashion if no extension to other pelvic organs is present. However, advanced ovarian cancer often involves the uterus, rectosigmoid, cecum, ileum and bladder. Metastases of the pelvic peritoneum sometimes completely obliterate the anterior and posterior cul-de-sac. In this case, the retroperitoneal approach is the most reasonable way for removing *in block* the entire tumor. This procedure is accompanied by performing a rectosigmoid resection with an end-to end mechanical anastomosis.[54] Tumor spread to the hilum of the spleen may be carefully inspected as well. Splenectomy may be sometimes indicated to achieve maximal tumor debulking. Any peritoneal implants should be removed, particularly if there are large, isolated masses and their removal will render the patient optimally cytoreduced. Diaphragm peritoneum should be visualized and resected if the disease is present. Sometimes, it can involve muscle resection that can be sutured with non-reabsorbed monofilament continuous suture. Pelvic and /or aortic lymph node involvement is seen in approximately 60% of patient with advanced stage disease. Despite controversial, pelvic and aortic lymphadenectomy should be completed starting from aortic bifurcation up to the renal veins. The incidence of complications and morbidity of this approach should be also taken into consideration for patient selection. The most common complications include: infections, cardiac morbidity, pulmonary thromboembolism, coagulopathy, gastrointestinal, renal failure, re-laparotomy and death.

14. Surgical treatment of relapsed ovarian cancer: Secondary cytoreduction

Once recurrence is confirmed, the next step is to determine the best treatment approach for each individual case. Recurrent epithelial ovarian carcinoma is, however, a therapeutic di-

lemma for physicians. To date, there is no consensus for optimal treatment strategies. Three essential options are proposed: surgical resection followed by chemotherapy, chemotherapy only or enrollment into clinical trials. This dilemma will be fundamentally responded by the localization of the disease, by the disease free interval (DFI) between the end of standard front-line chemotherapy (platinum/taxanes-based) and the date of documented disease recurrence. This period will divide patients in three groups: *platinum sensible* with a DFI more than 6 months; *platinum resistant*: patients with a DFI less than 6 months; and the group of *platinum refractory*: patients who will never respond to front line therapy or who will experience progression of disease. The latter represents 20-30% of the patients with FIGO stage III-IV who underwent surgical cytoreduction followed by carboplatin /paclitaxel.[55],[56] DFI has been established as the most important predictor factor for response to treatment of the relapsed disease.[55],[57],[58]

15. Secondary cytoreduction

Surgical resection for ovarian cancer recurrence means secondary cytoreduction. Although primary cytoreductive surgery is well accepted as the cornerstone of initial management, the use of cytoreductive surgery in the setting of recurrent disease is defined less clearly. Benefits of secondary cytoreduction are encountered in several studies.[59] No randomized studies exist regarding the benefits of surgical resection over chemotherapy in patients with recurrent disease. The available data is controversial and biased by the decision whether or not to expose patients to a surgical treatment. In general, studies included patients with more favorable characteristics such as younger age, fewer medical comorbidity, scarce number of lesions, better performance status, absence of ascites at recurrence, early stage at diagnosis, DFI more than 12 months, and optimal primary cytoreduction.[60]-[64] All of the previous characteristics are favorable prognostic factors and constitute the standard indications for secondary surgical resection.[60] A recent meta-analysis studied 2,019 patients enrolled in 40 retrospective and prospective trials who underwent secondary cytoreduction due to recurrent ovarian cancer. The mean weighted median OS time after recurrence was 30.3 months. Complete cytoreduction was identified as an independent factor for the improving OS after secondary cytoreduction. In addition, the multivariate analysis showed that the survival time is increased 3.0 months each 10 % increase in the proportion of patients undergoing complete cytoreductive surgery.[65]

The objective of secondary cytoreduction should be to achieve complete debulking. In patients who are able to tolerate a major surgical procedure, secondary cytoreduction should be offered to those with a single site disease regardless of DFI, as well as to all patients with a DFI of greater than 30 months regardless the amount of disease sites. Patients with carcinomatosis and a DFI of less than 12 months should not be considered for secondary cytoreduction. The decisions must be, however, individualized based on each patient's goals, performance status, operative risk, and available therapeutic options.[66] (Table 3)

Disease-Free Interval	Single site of recurrence	Multiple site of recurrence – but no carcinomatosis	Carcinomatosis
6 – 12 months	Offer SC	Consider SC	No SC
12 – 30 months	Offer SC	Offer SC	Consider SC
> 30 months	Offer SC	Offer SC	Offer SC

Table 3. Recommendations for secondary cytoreduction (SC)

16. Specialized gynecologists

Surgical evaluation of a pelvic mass is one of the most common indications for gynecologic surgery and, therefore, it is unlikely that all patients with adnexal masses will be referred to a gynecologic oncologist. To assist in the referral process, the Society of Gynecologic Oncology established a guideline for patient referral with suspected ovarian cancer.[67]

It has been demonstrated that patients operated on by gynecologic oncologists are more likely to undergo an adequate staging procedure in early stage disease[34],[36],[37],[68] and a better percentage of optimal primary cytoreduction in advanced stage disease can be achieved in comparison to general gynecologists or general surgeons.[33]-[38] Moreover, many studies from several countries around the world have shown over 10 months increased OS when ovarian cancer patients were initially operated by a gynecological oncologist rather than general gynecologist [33],[34],[69]-[71] or general surgeons.[68],[72] Thus, optimal primary cytoreductive surgery performed by a surgeon with extended formal training in cytoreductive techniques followed by an appropriate chemotherapy combination is among the most powerful clinician-driven determinants of survival for women with ovarian cancer.[24]

17. Multidisciplinary team and centralization of treatment

Ovarian cancer is a challenging, complex and multidisciplinary disease. It is not only important how well trained physicians are, but also how many physicians of different specialties are involved in the management of this malignancy. The holistic conception of patient care and the intrinsic complexity of ovarian cancer require the involvement of different specialties to optimize the quality of care. The concept of multidisciplinary team approach in ovarian cancer is not restricted to the operating room settings. Multidisciplinary approach is crucial from the diagnosis to the demise of disease.

Results of different studies consistently show that patients with ovarian cancer treated at referral teaching high-volume hospitals receive better quality of care as accomplished by better surgical staging, better optimal cytoreduction[35],[39],[69],[73]-[75] and better chemotherapy administration rate and schemes.[69],[75]-[78] Treating patients at referral hospitals was independently associated with 10%-20% increased probability of survival at 5

years after first treatment.[69],[72],[73],[75],[79] In absolute numbers, this translates in an extension of survival of more than 10 months.[79]

Despite the consensus and the advantages explained above, population-based studies indicate that access to specialist care in gynecologic oncology for women with suspected ovarian cancer has been less than universal.[35],[36],[70] Reports from countries such as USA,[80] and UK[35],[81] have consistently shown that the majority of patients were treated in low-volume hospitals by low-volume surgeons. For example, the accessibility of patients with ovarian cancer to a specialized center was reported in 18% of patients in The Netherlands[74], 35% in Canada[72] and 40% in Maryland, USA.[82]

In summary, the configuration of health-care delivery systems to facilitate quick and consistent centralized referral will be necessary to ensure widespread access for women with suspected ovarian cancer to such health-care providers. Only through such efforts will contemporary patterns of surgical practice conform to the definition of high-quality cancer care.[83]

Author details

Lucas Minig^{1*}, M. Guadalupe Patrono¹, Rafael Alvarez Gallego²,
Javier Valero de Bernabé¹ and Ivan Diaz-Padilla²

*Address all correspondence to: lucasminig@yahoo.com

1 Gynecologic Oncology Division, Department of Obstetrics and Gynecology. HM Universitario Sanchinarro, Centro Integral Oncológico Clara Campal, Madrid, Spain

2 Medical Oncology Division, Gynecologic Oncology Program, Medical Oncology Division, HM Universitario Sanchinarro, Centro Integral Oncológico Clara Campal, Madrid, Spain

References

- [1] Jema A, Siegel R, Ward E, Hao Y, Xu J, Murray T, Thun M. Cancer Statistics, 2008. *CA Cancer J Clin* 2008;58:71-96.
- [2] Siegel R, Desantis C, Virgo K, Stein K, Mariotto A, Smith T, Cooper D, Gansler T, Lerro C, Fedewa S, Lin C, Leach C, Cannady RS, Cho H, Scoppa S, Hachey M, Kirch R, Jemal A, Ward E. Cancer treatment and survivorship statistics, 2012. *CA Cancer J Clin*. 2012 Jul;62(4):220-41.
- [3] Pecorelli S, Creasman WT, Petterson F, Benedet JL, Shepard JH. FIGO annual report on the results of treatment in gynaecological cancer. *J Epidemiol Biostat*. 1998;3:75-102.

- [4] Bookman MA, Brady MF, McGuire WP, Harper PG, Alberts DS, Friedlander M, Colombo N, Fowler JM, Argenta PA, De Geest K, Mutch DG, Burger RA, Swart AM, Trimble EL, Accario-Winslow C, Roth LM. Evaluation of new platinum-based treatment regimens in advanced-stage ovarian cancer: a Phase III Trial of the Gynecologic Cancer Intergroup. *J Clin Oncol*. 2009 Mar 20;27(9):1419-25.
- [5] GCIG-Consensus. Stuart GC, Kitchener H, Bacon M, duBois A, Friedlander M, Ledermann J, Marth C, Thigpen T, Trimble E; participants of 4th Ovarian Cancer Consensus Conference (OCCC); Gynecologic Cancer Intergroup. 2010 Gynecologic Cancer InterGroup (GCIG) consensus statement on clinical trials in ovarian cancer: report from the Fourth Ovarian Cancer Consensus Conference. *Int J Gynecol Cancer*. 2011 May;21(4):750-5
- [6] Le T, Adolph A, Krepart GV, Lotocki R, Heywood MS. The benefits of comprehensive surgical staging in the management of early-stage epithelial ovarian carcinoma. *Gynecol Oncol*. 2002 May;85(2):351-5.
- [7] NIH consensus conference. Ovarian cancer. Screening, treatment, and follow-up. NIH Consensus Development Panel on Ovarian Cancer. *JAMA*. 1995 Feb 8;273(6):491-7
- [8] Buchsbaum HJ, Brady MF, Delgado G, Miller A, Hoskins WJ, Manetta A, Sutton G. Surgical staging of carcinoma of the ovaries. *Surg Gynecol Obstet*. 1989;169(3):226-32.
- [9] Salani R, Bristow RE. Surgical management of epithelial ovarian cancer. *Clin Obstet Gynecol*. 2012;55(1):75-95.
- [10] Bagley CM Jr, Young RC, Schein PS, Chabner BA, DeVita VT. Ovarian carcinoma metastatic to the diaphragm--frequently undiagnosed at laparotomy. A preliminary report. *Am J Obstet Gynecol*. 1973 Jun 1;116(3):397-400.
- [11] Zuna RE, Behrens A. Peritoneal washing cytology in gynecologic cancers: long-term follow-up of 355 patients. *J Natl Cancer Inst*. 1996 17;88(14):980-7.
- [12] Sigurdsson K, Alm P, Gullberg B. Prognostic factors in malignant epithelial ovarian tumors. *Gynecol Oncol*. 1983;15(3):370-80.
- [13] Powless CA, Bakkum-Gamez JN, Aletti GD, Cliby WA. Random peritoneal biopsies have limited value in staging of apparent early stage epithelial ovarian cancer after thorough exploration. *Gynecol Oncol*. 2009;115(1):86-9.
- [14] Angioli R, Plotti F, Palaia I, Calcagno M, Montera R, Cafà EV, Sereni MI, Panici PB. Update on lymphadenectomy in early and advanced ovarian cancer. *Curr Opin Obstet Gynecol*. 2008;20(1):34-9.
- [15] Panici PB, Maggioni A, Hacker N, Landoni F, Ackermann S, Campagnutta E, Tamusino K, Winter R, Pellegrino A, Greggi S, Angioli R, Mancini N, Scambia G, Dell'Anna T, Fossati R, Floriani I, Rossi RS, Grassi R, Favalli G, Raspagliesi F, Giannarelli D, Martella L, Mangioni C. Systematic aortic and pelvic lymphadenectomy versus resec-

tion of bulky nodes only in optimally debulked advanced ovarian cancer: a randomized clinical trial. *J Natl Cancer Inst.* 2005 Apr 20;97(8):560-6.

- [16] Nezhat FR, Ezzati M, Chuang L, Shamshirsaz AA, Rahaman J, Gretz H. Laparoscopic management of early ovarian and fallopian tube cancers: surgical and survival outcome. *Am J Obstet Gynecol.* 2009;200(1):83.e1-6.
- [17] Chi DS, Abu-Rustum NR, Sonoda Y, Ivy J, Rhee E, Moore K, Levine DA, Barakat RR. The safety and efficacy of laparoscopic surgical staging of apparent stage I ovarian and fallopian tube cancers. *Am J Obstet Gynecol.* 2005 May;192(5):1614-9.
- [18] Tozzi R, Schneider A. Laparoscopic treatment of early ovarian cancer. *Curr Opin Obstet Gynecol.* 2005;17(4):354-8.
- [19] Magrina JF, Zanagnolo V, Noble BN, Kho RM, Magtibay P. Robotic approach for ovarian cancer: perioperative and survival results and comparison with laparoscopy and laparotomy. *Gynecol Oncol.* 2011 Apr;121(1):100-5.
- [20] FIGO. The new FIGO staging system for cancers of the vulva, cervix, endometrium and sarcomas. *Gynecologic Oncology* 115 (2009) 325–328
- [21] Griffiths CT. Surgical resection of tumor bulk in the primary treatment of ovarian carcinoma. *Natl Cancer Inst Mongr* 1975;421:1014.
- [22] Bristow RE, Tomacruz RS, Armstrong DK, Trimble EL, Montz FJ. Survival effect of maximal cytoreductive surgery for advanced ovarian carcinoma during the platinum era: a meta-analysis. *J Clin Oncol.* 2002 Mar 1;20(5):1248-59.
- [23] du Bois A, Reuss A, Pujade-Lauraine E, Harter P, Ray-Coquard I, Pfisterer J. Role of surgical outcome as prognostic factor in advanced epithelial ovarian cancer: a combined exploratory analysis of 3 prospectively randomized phase 3 multicenter trials: by the Arbeitsgemeinschaft Gynaekologische Onkologie Studiengruppe Ovarialkarzinom (AGO-OVAR) and the Groupe d'Investigateurs Nationaux Pour les Etudes des Cancers de l'Ovaire (GINECO). *Cancer.* 2009 Mar 15;115(6):1234-44.
- [24] Bristow RE, Chi DS. Platinum-based neoadjuvant chemotherapy and interval surgical cytoreduction for advanced ovarian cancer: a meta-analysis. *Gynecol Oncol.* 2006 Dec;103(3):1070-6.
- [25] Skipper HE. Adjuvant chemotherapy. *Cancer.* 1978 Mar;41(3):936-40.
- [26] Goldie JH, Coldman AJ. A mathematic model for relating the drug sensitivity of tumors to their spontaneous mutation rate. *Cancer Treat Rep.* 1979 Nov-Dec;63(11-12):1727-33.
- [27] Curt GA, Clendeninn NJ, Chabner BA. Drug resistance in cancer. *Cancer Treat Rep.* 1984 Jan;68(1):87-99.
- [28] Skipper HE. Thoughts on cancer chemotherapy and combination modality therapy. *JAMA.* 1974;18;230(7):1033-5.

- [29] Gunduz N, Fisher B, Saffer EA. Effect of surgical removal on the growth and kinetics of residual tumor. *Cancer Res.* 1979 Oct;39(10):3861-5.
- [30] Hoskins WJ, McGuire WP, Brady MF, et al.: The effect of diameter of largest residual disease on survival after primary cytoreductive surgery in patients with suboptimal residual epithelial ovarian carcinoma. *Am J Obstet Gynecol* 1994, 170:974–980.
- [31] Winter WE 3rd, Maxwell GL, Tian C, Carlson JW, Ozols RF, Rose PG, Markman M, Armstrong DK, Muggia F, McGuire WP; Gynecologic Oncology Group Study. Prognostic factors for stage III epithelial ovarian cancer: a Gynecologic Oncology Group Study. *J Clin Oncol.* 2007 Aug 20;25(24):3621-7.
- [32] Chang SJ, Bristow RE. Evolution of surgical treatment paradigms for advanced-stage ovarian cancer: redefining 'optimal' residual disease. *Gynecol Oncol.* 2012 May; 125(2):483-92.
- [33] Junor EJ, Hole DJ, McNulty L, Mason M, Young J. Specialist gynaecologists and survival outcome in ovarian cancer: a Scottish national study of 1866 patients. *Br J Obstet Gynaecol* 1999;106:1130– 6.
- [34] Engelen MJA, Kos HE, Willemse PHB, et al. Surgery by consultant gynecologic oncologists improves survival in patients with ovarian carcinoma. *Cancer* 2006; 106: 589–98.
- [35] Olaitan A, Weeks J, Mocroft A, Smith J, Howe K, Murdoch J. The surgical management of women with ovarian cancer in the south west of England. *Br J Cancer.* 2001;85:1824-30.
- [36] Grossi M, Quinn MA, Thursfield VJ, Francis PA, Rome RM, Planner RS, Giles GG. Ovarian cancer: patterns of care in Victoria during 1993-1995. *Med J Aust.* 2002 Jul 1;177(1):11-6.
- [37] Kumpulainen S, Kuoppala T, Leminen A, Penttinen J, Puistola U, Pukkala E, et al. Surgical treatment of ovarian cancer in different hospital categories—A prospective nation-wide study in Finland. *Eur J Cancer* 2006;43:388–95.
- [38] Vernooij F, Heintz P, Witteveen E, van der Graaf Y. The outcomes of ovarian cancer treatment are better when provided by gynecologic oncologists and in specialized hospitals: a systematic review. *Gynecol Oncol.* 2007;105:801-12.
- [39] Vergote I, DeWever I, Tjalma W, Van Gramberen M, Decloedt J, van Dam P. Neoadjuvant chemotherapy or primary debulking surgery in advanced ovarian carcinoma: a retrospective analysis of 285 patients. *Gynecol Oncol* 1998;71:431–6.
- [40] Schwartz PE, Rutherford TJ, Chambers JT, Kohorn EI, Thiel PR. Neoadjuvant chemotherapy for advanced ovarian cancer: long-term survival. *Gynecol Oncol* 1999;72:93–9.

- [41] Eisenkop SM, Spirtos NM, Friedman RL, et al. Relative influences of tumor volume before surgery and the cytoreductive outcome on survival for patients with advanced ovarian cancer: a prospective study. *Gynecol Oncol* 2003;90:390–6.
- [42] Aletti GD, Gostout BS, Podratz KC, Cliby WA. Ovarian cancer surgical resectability: relative impact of disease, patient status, and surgeon. *Gynecol Oncol* 2006;100:33–7.
- [43] Chi DS, Eisenhauer EL, Lang J, Huh J, Haddad L, Abu-Rustum NR, et al. What is the optimal goal of primary cytoreductive surgery for bulky stage IIIC epithelial ovarian carcinoma (EOC)? *Gynecol Oncol* 2006;103:559–64.
- [44] Pecorelli S, Odicino F, Favalli G. Interval debulking surgery in advanced epithelial ovarian cancer. *Best Prac Res, Clin Obstet Gynaecol* 2002;16:573–83.
- [45] Hegazy MA, Hegazi RA, Elshafei MA, Setit AE, Elshamy MR, Eltatoongy M, Halim AA. Neoadjuvant chemotherapy versus primary surgery in advanced ovarian carcinoma. *World J Surg Oncol*. 2005 Aug 31;3:57.
- [46] Hou JY, Kelly MG, Yu H, McAlpine JN, Azodi M, Rutherford TJ, Schwartz PE. Neoadjuvant chemotherapy lessens surgical morbidity in advanced ovarian cancer and leads to improved survival in stage IV disease. *Gynecol Oncol*. 2007;105:211–7.
- [47] Chi DS, Schwartz PE. Cytoreduction vs. neoadjuvant chemotherapy for ovarian cancer. *Gynecol Oncol*. 2008;111:391–9.
- [48] Eltabbakh GH, Mount SL, Beatty B, Simmons-Arnold L, Cooper K, Morgan A. Factors associated with cytoreducibility among women with ovarian carcinoma. *Gynecol Oncol* 2004;95:377–83.
- [49] Nelson BE, Rosenfield AT, Schwartz PE. Preoperative abdominopelvic computed tomographic prediction of optimal cytoreduction in epithelial ovarian carcinoma. *J Clin Oncol* 1993;11(1):166–72.
- [50] Bristow RE, Santillan A, Diaz-Montes TP, Gardner GJ, Giuntoli RL, Meisner BC, et al. Centralization of care for patients with advanced-stage ovarian cancer: a costeffectiveness analysis. *Cancer* 2007;109:1513–22.
- [51] Fagotti A, Ferrandina G, Fanfani F, Ercoli A, Lorusso D, Rossi M, Scambia G. A laparoscopy-based score to predict surgical outcome in patients with advanced ovarian carcinoma: a pilot study. *Ann Surg Oncol*. 2006 Aug;13(8):1156–61
- [52] Vergote I, Tropé CG, Amant F, Kristensen GB, Ehlen T, Johnson N, et al. European Organization for Research and Treatment of Cancer — Gynaecological Cancer Group; NCIC Clinical Trials Group. Neoadjuvant chemotherapy or primary surgery in stage IIIC or IV ovarian cancer. *N Engl J Med* 2010;363:943–53.
- [53] Chi DS, Musa F, Dao F, Zivanovic O, Sonoda Y, Leitao MM. An analysis of patients with bulky advanced stage ovarian, tubal, and peritoneal carcinoma treated with primary debulking surgery (PDS) during an identical time period as the randomized

- EORTC-NCIC trial of PDS vs neoadjuvant chemotherapy (NACT). *Gynecol Oncol* 2012;124:10-4.
- [54] Hudson CN, Chir M. Surgical treatment of ovarian cancer. *Gynecol Oncol* 1973;1:370-8.
- [55] Markman M, Reichman B, Hakes T, Jones W, Lewis JL Jr, Rubin S, et al. Responses to second-line cisplatin-based intraperitoneal therapy in ovarian cancer: influence of a prior response to intravenous cisplatin. *J Clin Oncol*. 1991;9:1801-5.
- [56] McGuire WP, Markman M. Primary ovarian cancer: current standards of care. *BJC* 2003; 89 Suppl. 3: S3-8
- [57] Gore ME, Fryatt I, Wiltshaw E, Dawson T. Treatment of relapsed carcinoma of the ovary with cisplatin or carboplatin following initial treatment with these compounds. *Gynecol Oncol*. 1990;36:207-11.
- [58] Hoskins PJ, O'Reilly SE, Swenerton KD. The 'failure free interval' defines the likelihood of resistance to carboplatin in patients with advanced epithelial ovarian cancer previously treated with cisplatin: relevance to therapy and new drug testing. *Int J Gynecol Cancer* 1991; 1: 205-8.
- [59] Munkarah AR, Coleman RL. Critical evaluation of secondary cytoreduction in recurrent ovarian cancer. *Gynecol Oncol*. 2004;95:273-280.
- [60] Chi DS, McCaughty K, Diaz JP, Huh J, Schwabenbauer S, Hummer AJ, Venkatraman ES, Aghajanian C, Sonoda Y, Abu-Rustum NR, Barakat RR. Guidelines and selection criteria for secondary cytoreductive surgery in patients with recurrent, platinum-sensitive epithelial ovarian carcinoma. *Cancer*. 2006 May 1;106(9):1933-9.
- [61] Eisenkop SM, Friedman RL, Spirtos NM. The role of secondary cytoreductive surgery in the treatment of patients with recurrent epithelial ovarian carcinoma. *Cancer*. 2000;88:144-53.
- [62] Harter P, du Bois A, Hahmann M, Burges A, Loibl S, Gropp M, et al. Surgery in recurrent ovarian cancer: the Arbeitsgemeinschaft Gynaekologische Onkologie (AGO) DESKTOP OVAR trial. *Ann Surg Oncol*. 2006;13:1702-10.
- [63] Scarabelli C, Gallo A, Carbone A. Secondary cytoreductive surgery for patients with recurrent epithelial ovarian carcinoma. *Gynecol Oncol*. 2001;83:504-12.
- [64] Zang RY, Zhang ZY, Li ZT, Chen J, Tang MQ, Liu Q, et al. Effect of cytoreductive surgery on survival of patients with recurrent epithelial ovarian cancer. *J Surg Oncol*. 2000;75:24-30.
- [65] Bristow RE, Puri I, Chi DS. Cytoreductive surgery for recurrent ovarian cancer: a meta-analysis. *Gynecol Oncol*. 2009;112(1):265-74.
- [66] Leitao MM Jr, Chi DS. Surgical management of recurrent ovarian cancer. *Semin Oncol*. 2009 Apr;36(2):106-11.

- [67] SGO. Guidelines for referral to a gynecologic oncologist: rationale and benefits. The Society of Gynecologic Oncologists. *Gynecol Oncol*. 2000 Sep;78(3 Pt 2):S1-13.
- [68] Earle CC, Schrag D, Neville BA, Yabroff KR, Topor M, Fahey A, et al. Effect of surgeon specialty on processes of care and outcomes for ovarian cancer patients. *J Natl Cancer Inst* 2006;98(3): 172–80.
- [69] Paulsen T, Kjaerheim K, Kaern J, Tretli S, Trope C. Improved short-term survival for advanced ovarian, tubal, and peritoneal cancer patients operated at teaching hospitals. *Int J Gynecol Cancer* 2006;16(Suppl 1):11–7.
- [70] Carney ME, Lancaster JM, Ford C, Tsodikov A, Wiggins CL. A population-based study of patterns of care for ovarian cancer: who is seen by a gynecologic oncologist and who is not? *Gynecol Oncol* 2002; 84: 36–42.
- [71] Eisenkop SM, Spirtos NM, Montag TW, Nalick RH, Wang HJ. The impact of subspecialty training on the management of advanced ovarian cancer. *Gynecol Oncol* 1992;47:203– 9.
- [72] Elit L, Bondy SJ, Paszat L, Przybysz R, Levine M. Outcomes in surgery for ovarian cancer. *Gynecol Oncol* 2002;87(3):260–7.
- [73] Vernooij F, Heintz A, Coebergh J, Massuger L, Witteveen P, van der Graaf Y. Specialized and high-volume care leads to better outcomes of ovarian cancer treatment in the Netherlands. *Gynecol Oncol* 2009;112:455–461.
- [74] Vernooij F, Heintz APM, Witteveen E, et al. Specialized care and survival of ovarian cancer patients in The Netherlands: nationwide cohort study. *J Natl Cancer Inst* 2008;100:399–406.
- [75] Tingulstad S, Skjeldestad FE, Hagen B. The effect of centralization of primary surgery on survival in ovarian cancer patients. *Obstet Gynecol*. 2003;102:499-505.
- [76] Cress RD, O'Malley CD, Leiserowitz GS, Campleman SL. Patterns of chemotherapy use for women with ovarian cancer: a population-based study. *J Clin Oncol*. 2003;21:1530-5.
- [77] Schrag D, Earle C, Xu F, Panageas KS, Yabroff KR, Bristow RE, et al. Associations between hospital and surgeon procedure volumes and patient outcomes after ovarian cancer resection. *J Natl Cancer Inst* 2006;98 (3):163–71.
- [78] Harlan LC, Clegg LX, Trimble EL. Trends in surgery and chemotherapy for women diagnosed with ovarian cancer in the United States. *J Clin Oncol* 2003;21(18):3488–94.
- [79] Wolfe CD, Tilling K, Raju KS. Management and survival of ovarian cancer patients in south east England. *Eur J Cancer* 1997;33(11):1835–40.
- [80] Goff BA, Matthews BJ, Wynn M, Muntz HG, Lishner DM, Baldwin LM. Ovarian cancer: patterns of surgical care across the United States. *Gynecol Oncol*. 2006 Nov; 103(2):383-90.

- [81] Jolly K, Parry J, Rouse A, Stevens A. Volumes of cancer surgery for breast, colorectal and ovarian cancer 1992– 97: is there evidence of increasing sub-specialization by surgeons? *Br J Cancer* 2001;84:1308– 13.
- [82] Diaz-Montes TP, Zahurak ML, Giuntoli II RL, Gardner GJ, Gordon TA, Armstrong DK, et al. Surgical care of elderly women with ovarian cancer: a population-based perspective. *Gynecol Oncol* 2005;99(2):352–7.
- [83] Bristow RE, Berek JS. Surgery for ovarian cancer: how to improve survival. *Lancet*. 2006;367:1558-60.