

# We are IntechOpen, the world's leading publisher of Open Access books Built by scientists, for scientists

6,900

Open access books available

186,000

International authors and editors

200M

Downloads

Our authors are among the

154

Countries delivered to

TOP 1%

most cited scientists

12.2%

Contributors from top 500 universities



WEB OF SCIENCE™

Selection of our books indexed in the Book Citation Index  
in Web of Science™ Core Collection (BKCI)

Interested in publishing with us?  
Contact [book.department@intechopen.com](mailto:book.department@intechopen.com)

Numbers displayed above are based on latest data collected.  
For more information visit [www.intechopen.com](http://www.intechopen.com)



---

# **Temporomandibular Joint Arthroscopy *versus* Arthrotomy**

---

Edvitar Leibur, Oksana Jagur and Ülle Voog-Oras

Additional information is available at the end of the chapter

<http://dx.doi.org/10.5772/55011>

---

## **1. Introduction**

Although some patients with temporomandibular joint (TMJ) disorders are successfully treated by nonsurgical means or by arthrocentesis or arthroscopic surgery, there is still a group of patients who do not respond to these procedures and for whom an arthrotomy and disc surgery (discoplasty) are necessary. Arthroscopy is an important diagnostic and therapeutic modality in the treatment of TMJ disorders being an alternative to arthrotomy ( „open“ TMJ surgery) and can be very effective in eliminating symptoms as pain, mandibular dysfunction, hypomobility, acute and chronic „closed lock“ due to osteoarthritis and arthrosis with adhesive capsulitis, where nonsurgical treatment has been unsuccessful. Bony ankylosis and fibrosis are best managed by open arthrotomy procedures. It has been found that a total of 22 of the 137 arthroscopies were diagnostic only, which resulted in immediate arthrotomy, including arthroplasty, meniscectomy [1]. Arthroscopy is a technique for direct visual inspection of internal joint structures, including biopsy and other surgical procedures performed under visual control. In 1918 Takagi first described arthroscopy of the knee joint examinations using cystoscope [2]. Onishi in 1970 was the first to report arthroscopy of the human temporomandibular joint and the first results were published by him [3,4]. The progress in research and applications of TMJ arthroscopy in joint disease have led to the acceptance of small operative procedures as a safe, minimally invasive means of effectively treating a number of intra-articular and degenerative TMJ problems [5-7]. Arthroscopic surgery has been an effective treatment for TMJ disorders refractory to nonsurgical treatments [8-10]. TMJ arthroscopy has been variously reported as successful in up to 80% of cases where outcome of arthroscopic surgery to the TMJ correlates with the stage of internal derangement [11-13]. Studies have been variable in their scientific methods and some long-term outcomes studies have been completed where both quality of life and functional outcome have been assessed [14-16]. For enabling direct comparison of the clinical results following arthroscopic

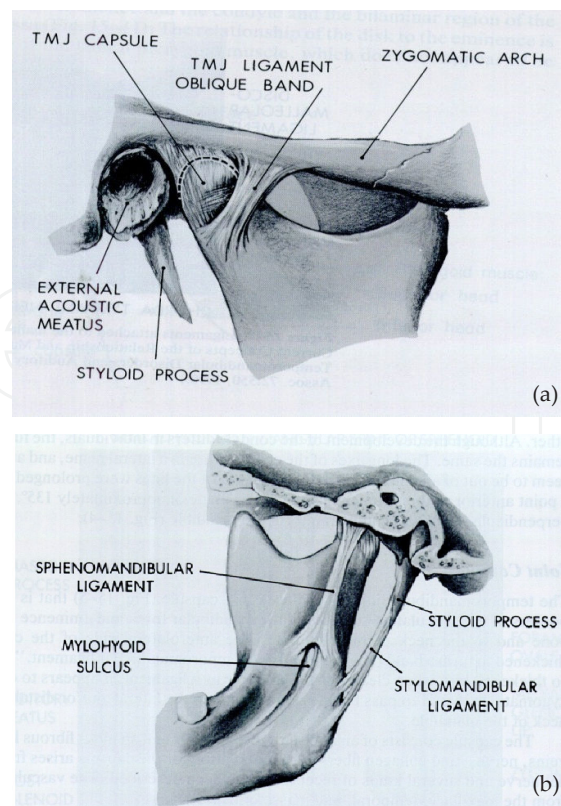
surgery and open surgery a retrospective study comparing two centers' results using the Jaw Pain and Function Questionnaire [17] has been performed and these treatment results of open surgery were comparable with arthroscopic treatment results [15].

## 2. Anatomy of the temporomandibular joint

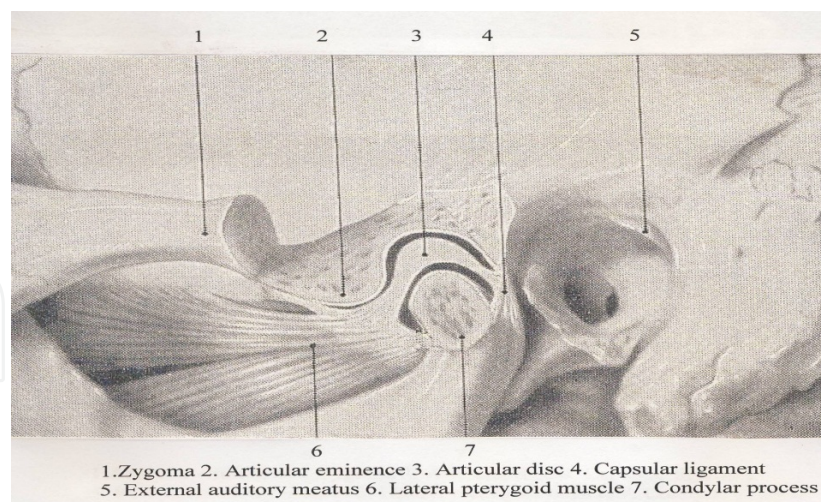
The temporomandibular joint is the articulation between the mandible and the cranium. The mandibular head (condyle), glenoid (mandibular) fossa, and articular eminence form the TMJ. These joints serve as one anatomic control for both mandibular movement and the occlusion, surrounded by a capsule which consists of fibrous material, and a synovial lining. The capsule is quite thin anteromedially and medially ~ 0,7 mm and thick laterally and posteriorly ~1,8 mm. The inner layer of the capsule or synovial membrane is highly vascularized layer of endothelial origin cells, producing synovial fluid. The capsule stretches from the edge of the mandibular fossa to the neck of the mandible, proximal to the pterygoid fovea, and envelops the articular eminence. Excessive displacement of the mandible is restricted by the joint capsule and ligaments. Nearist to the joint is temporomandibular joint ligament, which consists of a fibrous thickening in the lateral joint capsule. This ligament extends from the inferior surface of the posterior aspect of the zygomatic arch to the lateral part of the neck of the condyle. It functions by preventing lateral dislocation and it also prevents medial dislocation (Figure 1a). The two other ligaments are described in conventional anatomical descriptions of the joint, although it is doubtful whether either has a functional role. The sphenomandibular ligament running from the lingula shielding the opening of the inferior alveolar canal to the spine of the sphenoid. This ligament represents the residual perichondrium of Meckel's cartilage. The second ligament is the stylomandibular ligament running from the spine of the sphenoid to the angle of the mandible and represent the free border of the deep cervical fascia (Figure 1b).

The articular surface of the mandible is the upper and anterior surface of the condyle, lined by dense, avascular, fibrous connective tissue. A layer of hyaline cartilage covers the articulating cortical bone. The adult human condyle is about 15 to 20 mm from side to side and 8 to 10 mm from front to back. The articular surface is convex when viewed from the side and less when viewed from the front. Glenoid fossa is the concavity within the temporal bone. The anterior wall is formed by the articular eminence of the temporal bone and its posterior wall by the tympanic plate, which also forms the anterior wall of the external auditory meatus. An articular disc is interposed between the temporal bone and the mandible, dividing the articular space into upper and lower compartments (Figure 2).

The interposed fibrocartilaginous disc has a bow-tie-shaped biconcave morphology. The anterior and posterior ridges of the disc are termed anterior and posterior bands and are longer in the mediolateral than in the anteroposterior dimension. The smaller anterior band attaches to the articular eminence, condylar head, and joint capsule. The posterior band blends with highly vascularized, loose connective tissue, the bilaminar zone, and the capsule, the bilaminar zone residing in the retrodiscal space in the mandibular fossa and attaching to the condyle and temporal bone. Medially and laterally, the disc is firmly attached to the capsule and the



**Figure 1.** a. The temporomandibular ligament by M. M. Ash (In:Wheeler's dental anatomy, physiology and occlusion, W.B. Saunders Company, Philadelphia 1993). b. The sphenomandibular and stylomandibular ligaments by M. M. Ash (In: Wheeler's dental anatomy, physiology and occlusion, W.B. Saunders Company, Philadelphia 1993).

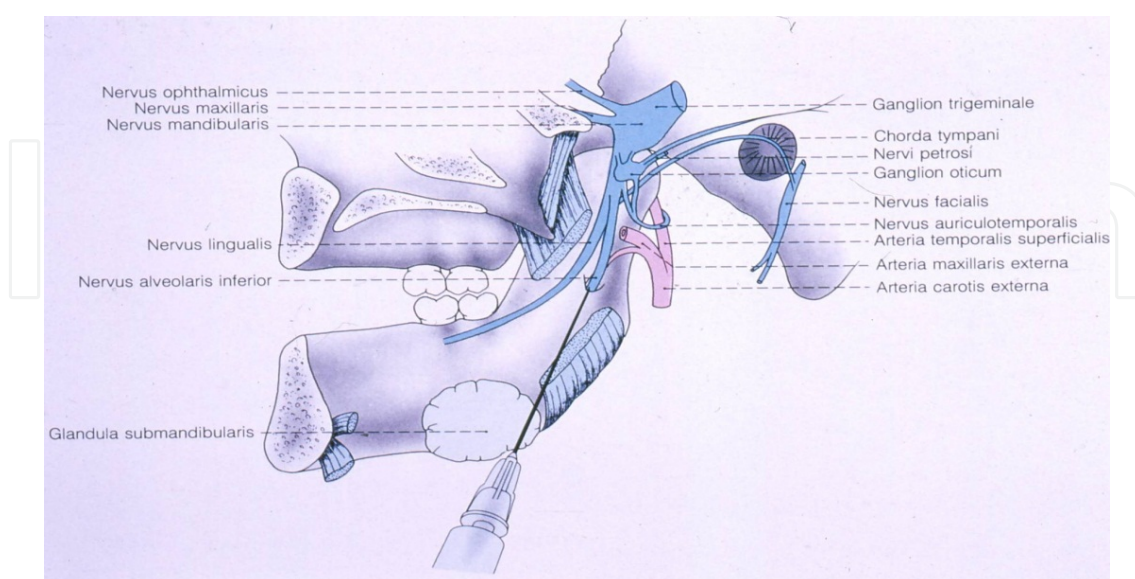


**Figure 2.** A sagittal section through the left temporomandibular joint.

condylar neck. Anteromedially, it is attached to the superior part of the pterygoid muscle. In a physiologic joint, the disc is positioned between the mandibular head inferiorly and the articular eminence anteriorly and superiorly when the jaw is closed. The posterior band of the disc lies within 10° of the 12 o'clock position. The medial and lateral corners of the disc align

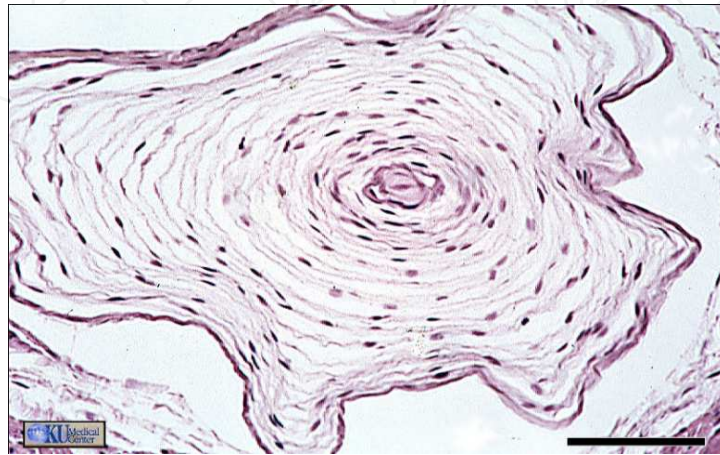


with the condylar borders and do not bulge laterally or medially. When the jaw is opened, the disc slides into a position between the mandibular head and articular eminence. The loose tissue of the bilaminar zone allows the remarkable range of motion of the disc. The attachments of the disc prevent luxation during opening. A triangular lateral ligament acts as a strong lateral stabilizer and inhibits the posterior translation of the mandibular head. The muscles of mastication are responsible for the complex movement of the jaw. The temporal, medial pterygoid, and masseter muscles facilitate jaw closure. Mouth opening is effected by coordinated action of the lateral pterygoid, mylohyoid, digastric, and suprahyoid muscles. The lateral pterygoid muscle and part of the fibers of the masseter and medial pterygoid muscles effect the anterior translation of the mandible. The superior belly of the lateral pterygoid muscle originates from the greater sphenoid wing and inserts on the disc. Subsequently, the superior belly plays a key role in upholding the physiologic position of the disc as it pulls the disc forward when the jaw is opened, in a combined translation and rotation. The inferior head of the lateral pterygoid muscle stretches from the lateral lamina of the pterygoid process to the pterygoid fovea. The medial pterygoid muscle originates from the pterygoid fossa and inserts near the medial aspect of the mandibular angle [18]. The blood supply to the TMJ, outer and inner ear is provided mainly by branches from an internal maxillary artery as follows: temporal superficial artery, superior auricular artery, anterior tympanic artery and pterygoid artery. Innervation is provided by the auriculotemporal nerve (sensory branch of the mandibular nerve), deep temporal nerve, masseteric nerve. Sensory cervical sympathetic ramifications are going to disc and capsule. The auriculotemporal nerve runs medial to the joint, then runs laterally, crossing the condylar neck, where it divides into branches to innervate the capsule, disc attachments, the tympanic membrane, the anterior surface of the cochlea, the upper part of the auricle, the tragus of the ear, the skin lining, the external auditory meatus, the temporal region (Figure 3) [19].



**Figure 3.** Branches of trigeminal nerve. Innervation and blood supply of temporomandibular joint (by R. Schmelzle, 1989).

Nerve receptors as Ruffin receptors, Golgi tendon organs, Vater-Pacini corpuscles free nerve endings are in the capsule and substance P nerve fibres are also available in both the auriculotemporal and masseteric nerves, and have been demonstrated in the capsule, disc attachments but they are not present in the disc. The Vater-Pacini corpuscles are large “onion-like” encapsulated pressure receptors. The surrounding concentric lamellae respond to distortion and generate an action potential in the unmyelinated fiber in the core (Figure 4).



**Figure 4.** The Vater-Pacini corpuscle. (<http://www.kumc.edu/instruction/medicine/anatomy/histoweb/nervous.htm>)

### 3. Classification of TMJ disorders

#### 1. Inflammatory arthritis:

- acute, chronic
- infectious: nonspecific, specific (gonococcal, syphilitic, tuberculous, Lyme disease associated arthritis)

#### 2. Osteoarthritis/arthrosis (most often disorder)

#### 3. Injuries:

- macrotrauma as luxations, concussion, fracture
- multiple instances of microtrauma

#### 4. Ankylosis (fibrous, fibro-osseous, osseous)

#### 5. Systemic conditions affecting the TMJ: rheumatoid arthritis, juvenile arthritis, psoriatic arthritis, Sjögren syndrome, ankylosing spondylitis (namely seropositive), scleroderma, mixed connective tissue disease, gout, pseudogout, calcium pyrophosphate deposition disease (CPDD)

6. Tumours (benign and malignant)
7. Congenital disturbances: I & II branchial arch malformations, condylar hypo-, hyperplasia, idiopathic condylar resorption.

## 4. Aetiology and pathogenesis of temporomandibular joint disorders

### 4.1. Aetiology

Main aetiological factors of TMJ disorders are as follows: systemic diseases (rheumatoid arthritis, psoriasis, pseudogout, ankylosing spondylitis etc.), secondary inflammatory component from the neighbouring regions (otitis, maxillary sinusitis, tonsillitis), trauma (chronical), prevalence of dental arch defects *e.g.* missing of molar teeth [20], malocclusion, endocrinological disturbances, odontogenic infections (third molars). Osteoarthritis is an inflammatory process, being most frequent TMJ disorder [6]. In systemic diseases (rheumatoid arthritis, psoriasis etc.) involvement of TMJ occurs [21]. Osteoarthritis refers to an inflammatory condition affecting the bony structures of the joint that results in destructive changes of hard tissues, and the presence of fibrillations, adhesions. The condition referred to as osteoarthrosis represents a subacute or chronic process that has inflammatory components (inflammatory mediators and markers), identified in the synovial fluid and tissues [22].

Presence of specific bacterial species in the synovial fluid have been found [23]. Serum antibodies against *Chlamydia spp.* in patients with monoarthritis of the TMJ have been occurred. An association may exist between the presence of *Chlamydia trachomatis* and TMJ disease [24].

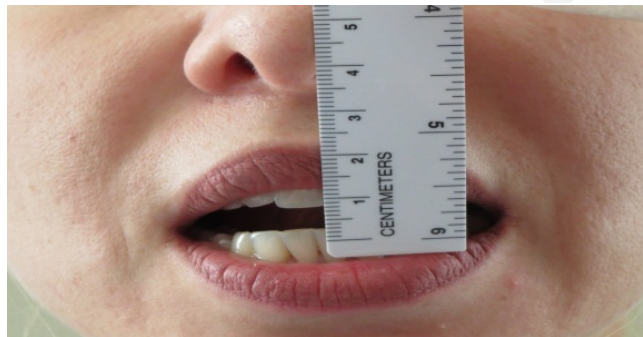### 4.2. Pathogenesis

Knowledge about the pathogenesis on a molecular level of disorders of the TMJ has been improved in recent years giving a possibility to use these data for the evidence based treatment. Inflammation mainly affects the posterior disc attachment [6,10]. Several inflammatory mediators play an important role in the pathogenesis of TMJ diseases as tumor necrosis factor  $\alpha$  (TNF $\alpha$ ), interleukin-1 $\beta$  (IL-1 $\beta$ ), prostaglandin E<sub>2</sub> (PGE<sub>2</sub>), leukotrien B<sub>4</sub> (LkB<sub>4</sub>), matrix metalloproteinases (MMP<sub>s</sub>), serotonin- 5-hydroxytryptamine (5-HT) [22,25]. MMP-s are responsible for the metabolism of extracellular matrix, being an early marker to determine TMJ arthritis. High level of MMP-3 has been determined in the synovial fluid in TMJ osteoarthritis patients [26]. Serotonin, mediator of pain and inflammation, is produced in the enterocromafin cells of the gastrointestinal mucosa and absorbed by platelets. It is produced also in the synovial membrane and is present in the synovial fluid and in blood in case of rheumatoid arthritis and is involved in the mediation of TMJ pain in systemic inflammatory joint diseases [27,28]. It plays a role also in bone metabolism [29]. Tissue response in case of inflammation is as follows: vasodilatation, extravasation, releasing of mediators, activation of nociceptors, release of neuropeptides as substance P (SP), neuropeptide Y (NPY), which stimulate releasing of histamin and serotonin from afferent nerve endings and hyperalgesia in TMJ occurs.

## 5. Diagnostics of the temporomandibular joint disorders

### 5.1. Clinical data

The most frequent complaint is pain, joint sounds and a decrease in the maximal interincisal opening (MIO), which normal values are between 35 -50 mm. Mouth opening is recorded by asking the patient to open maximally, and the distance between maxillary and mandibular incisors tip is measured (Figure 5). Locking and deviation of mandible is recorded as present or absent.



**Figure 5.** Female patient 22 yrs. with difficulty in opening the mouth, maximal interincisal opening (MIO) is only 6 mm.

The following symptoms as pain (at rest, during maximum mouth opening and upon chewing), tenderness to digital palpation of the joint, sounds (clicking, crepitation), restricted mandibular mobility *e.g.* difficulty in opening the mouth, intermittent lock, closed lock, stiffness in the morning are observed. Visual analog scales (VAS) are very useful instruments to estimate the intensity of the pain or the level of suffering that patient has been experiencing. The stages of disease are usually classified according to Wilkes [30], (Table 1) by reviewing the case histories, clinical data, radiological records (computerized tomography images incl. cone beam computer tomography), magnetic resonance images, orthopantomography and/or plain radiographs by Schüller, Parma.

Symptom related factors obtained by questionnaire, the scores pre- and posttreatment MIO and VAS for pain are to be documented and compared. Joint pain is assessed with 100mm visual analogue scale with end points marked „no pain“ and „worst pain ever experienced“. The absence of pain is scored as 0. If pain is present the patient is asked to select marked field from 1mm to 100 mm. It is known that inflammation often is accompanied by pain. Evaluation and estimation of the impact of pain is a complicated matter, since pain has many different ways to interfere with everyday life. The impact of pain on the health status and quality of life in patients with chronic inflammatory joint diseases has been recognized, but there is a lack of knowledge about the specific impact of TMJ pain on daily activities in patients with clinical involvement of the TMJ. A scale for measuring the activity of daily living (ADL) [31] of patients with TMJ disorders for assessment of the restriction of activities is a useful tool [14,16,32].



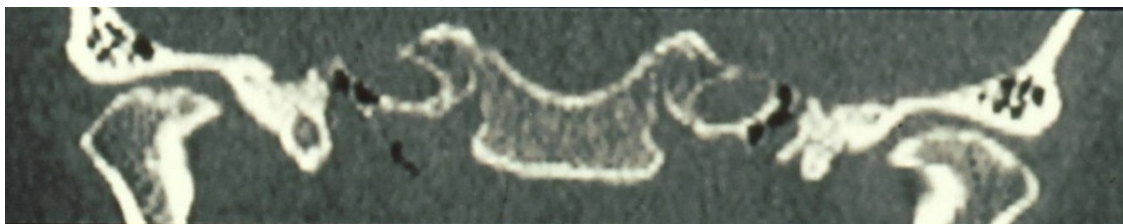<b>I.Early stage</b>	
A. Clinical:	No significant mechanical symptoms other than opening reciprocal clicking; no pain or limitation of motion
B. Radiologic:	Slight forward displacement, good anatomic contour of the disc, negative tomograms, no bone structure changes
C. Pathoanatomy:	Excellent anatomic form; slight anterior displacement, passive in-coordination demonstrable
<b>II. Early intermediate stage</b>	
A. Clinical:	One or more episodes of pain; beginning major mechanical problems consisting of mid-to-late opening loud clicking; transient catching and locking
B. Radiologic:	Slight forward displacement; beginning disc deformity, slight thickening of posterior edge; negative tomograms, no bone structure changes
C. Pathoanatomy:	Anterior disk displacement; early disk deformity; good central articulating area
<b>III. Intermediate stage</b>	
A. Clinical:	Multiple episodes of pain; major mechanical symptoms consisting of locking (intermittent or fully closed): restriction of motion, function difficulties
B. Radiologic:	Anterior disc displacement with significant deformity or prolapse of disc (increased thickening of posterior edge), negative tomograms, no bone structure changes
C. Pathoanatomy:	Marked anatomic disc deformity with anterior displacement; no hard tissue changes
<b>IV. Late intermediate stage</b>	
A. Clinical:	Slight increase in severity over intermediate stage
B. Radiologic:	Increase in severity over intermediate stage; positive tomograms showing early-to-moderate degenerative changes - flattening of eminence, deformation of condylar head, erosions, sclerosis
C. Pathoanatomy:	Increase in severity over intermediate stage; hard tissue degenerative remodelling of both bearing surfaces (osteophytes), multiple adhesions in anterior and posterior recesses; no perforation of disc or attachments
<b>V. Late stage</b>	
A. Clinical:	Characterized by crepitus, variable and episodic pain, chronic restriction of motion and difficulty with function
B. Radiologic:	Disc or attachment perforation, filling defects, gross anatomic deformity of disk and hard tissues, positive tomograms with essentially degenerative arthritic changes
C. Pathoanatomy:	Degenerative changes of disc and hard tissues, perforation of posterior attachment, multiple adhesions, osteophytes, flattening of condyle and eminence, subcortical cyst formation

**Table 1.** Classification for internal derangement of the TMJ by Wilkes (1989).

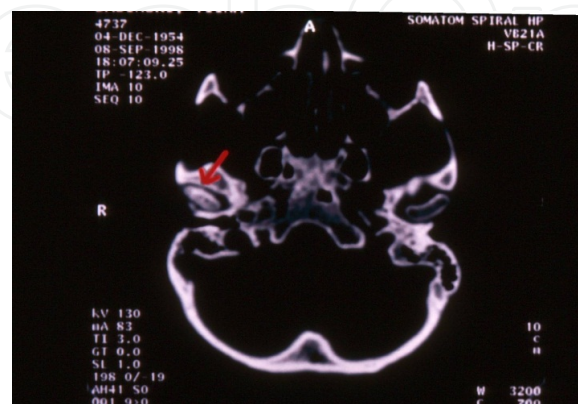
**5.2. Radiographic investigations**

Radiographic changes of the TMJ are evaluated by orthopantomography (OPTG), computed tomography (CT), magnet resonance imaging (MRI) [8,21,22,33] as well as ultrasonography [34]. OPTG is mainly used to demonstrate the structural bone changes in the TMJ and it has the advantage of being easily available but gives limited information about the above mentioned joint. By evaluating the OPTGs the following radiographic signs of bone structural changes can

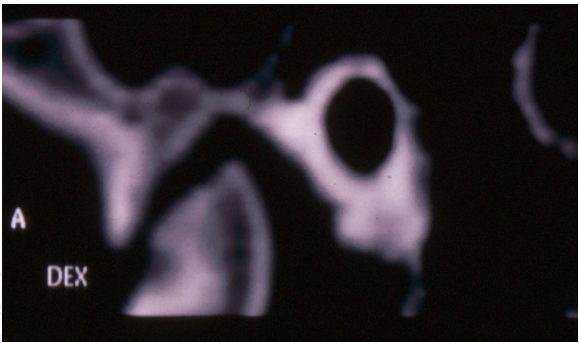
be achieved such as presence of erosions, flattening and osteophytes of the condyle as well as of the temporal bone [35]. Erosion in condyles in the radiographs is scored as follows: score 1 - very slight erosion; score 2 - erosion on top of the condyle; score 3 - half of condyle is eroded; score 4 - condyle totally eroded [36]. The first report of TMJ CT was published by Suarez et al. [37] and this method is superior to plain transcranial or transmaxillary imaging for detecting bone changes. CT allows detailed three-dimensional examination of the TMJ and it is capable to detect even small bone changes not demonstrable by conventional tomographic procedures [38, 39]. The CT sections are evaluated for presence of radiographic signs of bone changes within three regions (lateral, central and medial) of the mandibular and temporal part (eminence) of the TMJ. The recording of the signs is made in the axial, coronal and sagittal views [22, 40]. The changes are defined as follows: erosion - a local area with decreased density of the cortical joint surface including or not including adjacent subcortical bone (Figure 6), sclerosis - a local area with increased density of the cortical bony joint surface that may extend into the subcortical bone (Figure 7), subchondral pseudocyst - a well defined, local area of bone rarefaction underneath, an intact cortical outlining of the joint surface, flattening – a flat bony contour deviating from the convex form (Figure 8). The grade of the total changes of the TMJ can be evaluated according to the scoring system [41]. Not treated properly and immediately a juvenile trauma to the TMJ area can lead to ankylosis (Figure 9). 3-D reconstruction of the mandible gives a possibility to find the fracture of the condyle not diagnosed in time (Figure 10).



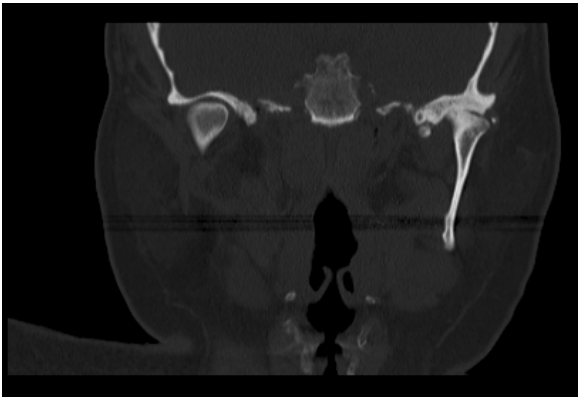**Figure 6.** Osteoarthritis of the TMJ, signs of erosions on the surfaces of the condyles in a coronal view of the CT.



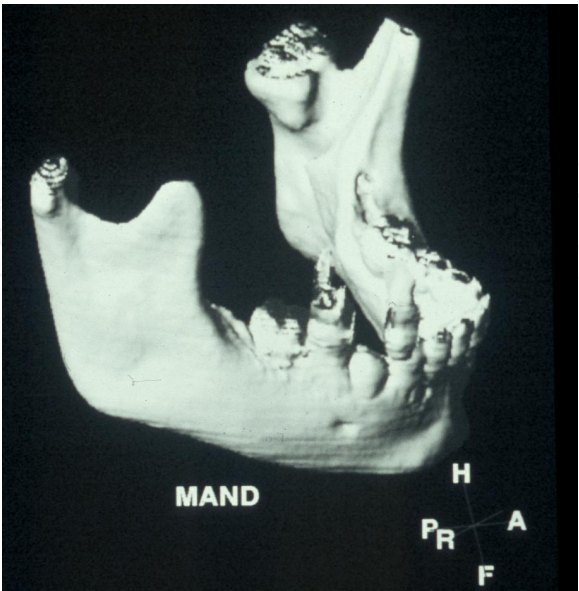
**Figure 7.** Axial view of the CT from the head, sign of sclerosis in the medial and central parts of the right condyle of the mandible (red arrow).



**Figure 8.** Sagittal view of the CT from the temporomandibular joint, sign of flattening of the left mandibular condyle.

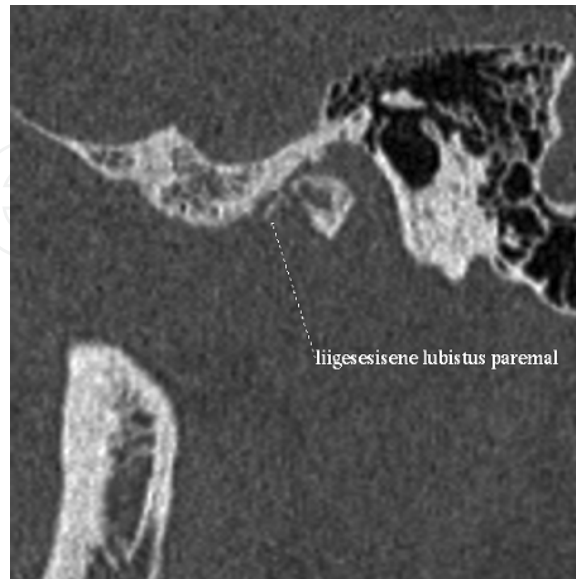

**Figure 9.** Coronal view of the the CT, osseous ankylosis of the left TMJ.

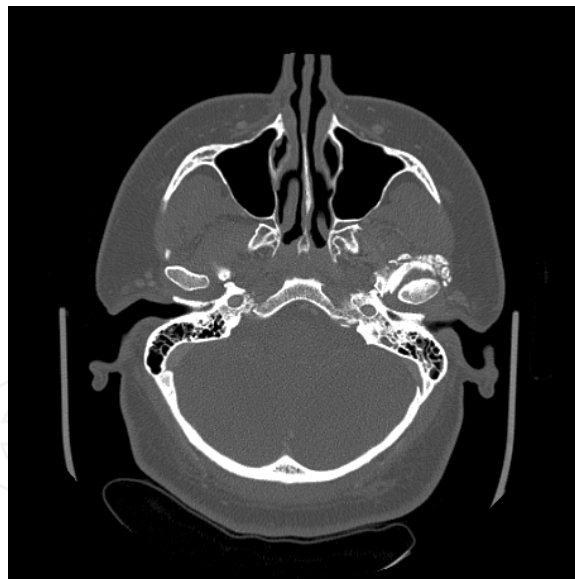


**Figure 10.** Male patient 9 yrs, trauma has been ~5 years ago, fracture of the left condyle is evident, displaced medially.

Foreign bodies in case of calcium pyrophosphate deposition disease (CPPD) crystals and synovial chondromatosis granules may be diagnosed radiographically (Figure 11, 12).



**Figure 11.** Sagittal view of the CT, left TMJ in an open mouth position, the calcifications in the joint space are found.

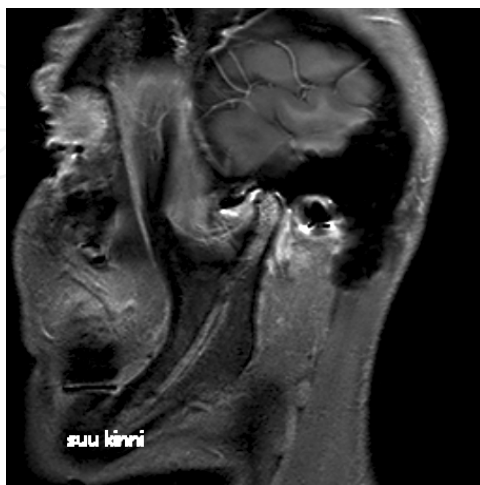


**Figure 12.** Axial view of the CT, granules of synovial chondromatosis are in the left TMJ.

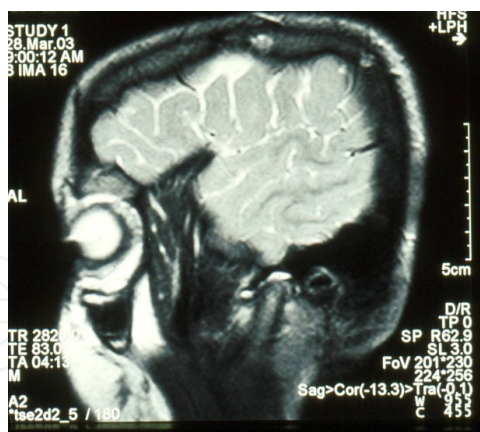
MRI has diagnostic value for internal derangements of the TMJ and rapidly surpassing CT as the imaging method of choice (Figure 13, 14). Sections in the oblique sagittal plane (*i.e.* perpendicular to the horizontal long axis of the mandibular condyle) and oblique coronal plane (*i.e.* parallel with the long axis of the condyle), and bilateral temporomandibular base surface coils are used for obtaining the image [39]. Disc displacement without reduction is



found by using MRI in at least one of the joints in 75% of the subjects and in 54% of all the joints imaged.



**Figure 13.** Sagittal view of the MRI in the closed mouth position in a patient with internal derangement of the left TMJ. Anterior disc displacement, hypoplastic condyle, destruction of the disc. Changes of bone structures, effusion in the anterior recess.



**Figure 14.** Sagittal view of the MRI in a patient with internal derangement of the left TMJ. Anterior disc displacement, destruction of the disc. Changes in the bone structures, effusion in the anterior recess.

The biting device (MEDRAD; Pittsburg) which enables dynamic imaging can be used as bite blocks during the open jaw phase of the imaging procedure [42]. Ultrasonography has been a helpful diagnostic approach for patients with TMJ disorders, having a possibility to diagnose with considerable reliability when compared with MRI and being a sensitive tool for assessing joint function [43].

## 6. Temporomandibular joint arthroscopy

### 6.1. Indications for TMJ arthroscopy

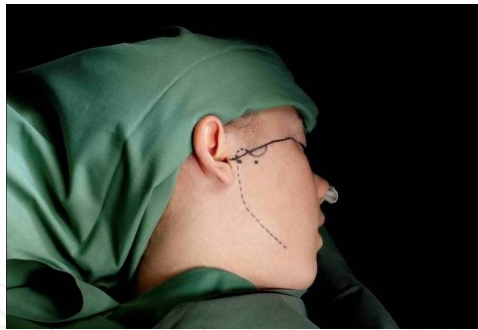The treatment decision must be based on a patient examination evaluation that integrates the imaging and clinical findings, including the history and the other diagnostic data.

Indications for arthroscopy are radiological bone changes in TMJ characteristic to osteoarthritis with disc displacement or deformity and non effectiveness of conservative treatment with NSAIDs, intraoral splints or arthrocentesis. Arthroscopic surgery has been used to treat anteriorly displaced, nonreducing discs. Various techniques have been used as: lysis of adhesions and joint lavage, anterior disc release, lateral capsular release, scarification of the retrodiscal region with a laser. Arthroscopic electrothermal capsulorrhaphy is performed using a standard double puncture operative arthroscopy with a Hol: YAG laser [44]. In practice, the decision to operate and the choice of the method seems to be a matter of the individual surgeon's training, experience, and attitude toward the surgical management of TMJ disorders. Involvement of the TMJ in patients with rheumatoid arthritis or other connective tissue diseases is rather common and arthroscopy with simultaneous biopsy is indicated in these situations. Posttraumatic complaints may also be an indication for arthroscopy. Arthroscopy is contraindicated in case of acute arthritis. In these situations as large medial osteophytes on the condyle, large central cartilaginous perforations, fibrous, fibro-osseous, osseous ankylosis are better to handle *via* open reduction. Arthrocentesis is considered as an intervening treatment modality between nonsurgical treatment and arthroscopic surgery. All cases for arthroscopy are usually classified as advanced Wilkes [30] stages IV and V, in rare cases stage III (Table 1).

### 6.2. Prearthroscopic procedures

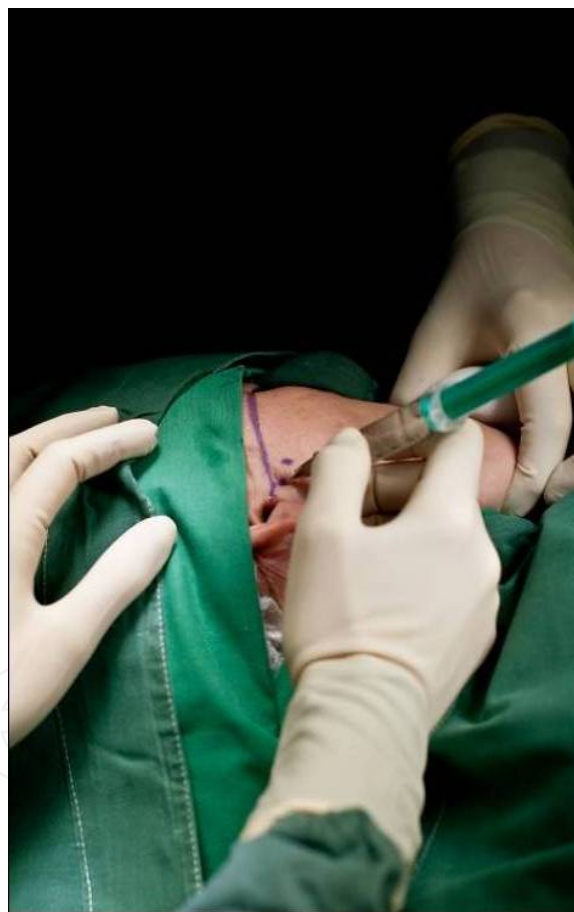Temporomandibular arthroscopy is usually done on an outpatient basis in the hospital. If diagnostic arthroscopy is followed by arthrotomy, the patient is admitted for postoperative care. Arthroscopy is performed under general anaesthesia with nasotracheal intubation which makes possible to manipulate the mandible during the operation. Both the surgeon and the assistant surgeon should have direct visibility of the monitor. First the zygomatic arch and the condyle are palpated. The condyle is then forced in anterior position by the assistant and the preauricular concavity is formed in the skin, marking a point for the injection. Although various arthroscopic approaches to the TMJ have been described, the one most commonly used is the posterolateral approach to the upper joint space. After the condylar head of the TMJ has been determined, a marking line and puncture points are made on the skin surface (Figure 15).

The puncture site is located by manipulating the mandible antero-inferiorly. For distension of the superior compartement and in order to avoid iatrogenic damage to the cartilaginous surfaces during introduction of the trocar, 0,5 – 1,0 % lidocain solution 2,0 mL with 1: 200 000 epinephrine is inserted to distend the superior compartment dilatation of capsule, in order to get hemostasis and postoperative analgesia. The solution is injected with a 27-gauge needle, which is aimed in a medial and slightly antero-superior direction until the contact with the



**Figure 15.** A marking line and the puncture points on the skin surface for TMJ arthroscopy.


glenoid fossa is achieved. The posterior recess of the superior joint space is reached when there is a backflow into the syringe of the solution injected into the joint space (Figure 16).



**Figure 16.** Distension of the superior compartment with 2% lidocaine solution.

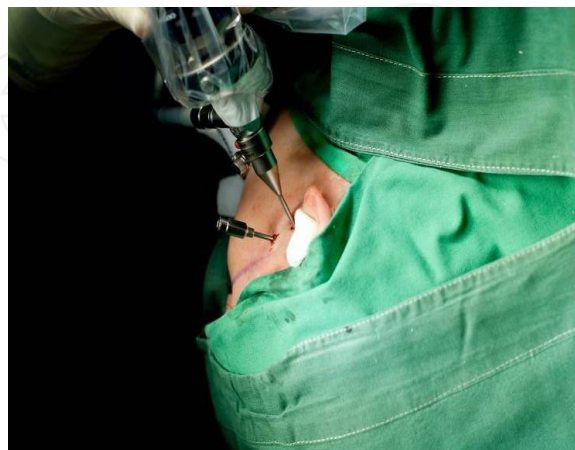### 6.3. Technique for arthroscopy

Usually arthroscope KARL STORZ GmbH & Co.KG is used. Overall view of the set is given in the Figure 17.



**Figure 17.** Overall view of the instruments set of arthroscope KARL STORZ GmbH & Co.KG with forward oblique - telescope 30° (HOPKINS®).

Through the small skin incision 0,75 – 1,0 cm from the center of the *tragus* at the injection site the lateral capsule is punctured with a sharp trocar in an arthroscopic sheath inserted in the same direction as the previous injection needle. The sharp trocar is exchanged for a blunt one and the arthroscopic sheath is advanced further into the upper joint space. Puncture with arthroscope sheath (trocar) with a blunt obturator inserted into upper posterior recess is performed angling it medially upward ~ 2,5 cm. Another skin incision is made ~ 0,75 cm from the first skin incision in anterolateral direction for outflow cannula to be inserted into the upper joint anterior recess. Following insertion of the trocar (diameter 1,8 mm, length 4 cm) into the joint space, blunt obturator is removed and forward-oblique telescope 30° (HOPKINS®), diameter 1,9 mm, length 6,5 cm, fiber optic light transmission incorporated is inserted (Figure 18). The inferior joint space is seldom entered because of the limited area makes it difficult to insert the trocar.



**Figure 18.** Forward-oblique telescope 30° (HOPKINS®) fiber optic light transmission incorporated and outflow cannula are inserted into the upper joint space.



Initial recognition of anatomical structures as the superior surface of the disc, articular fossa, and internal aspects of the posterior and medial capsule is performed. The fluid level in the arthroscope sheath should move with the jaw, confirming that the sheath is correctly positioned in the joint upper space. The upper joint compartment is examined from the posterior pouch *via* the intermediate zone to the anterior pouch. Disc may give the impression of being obstructed against the arthrotic surface of the temporal cartilage. The anterior part of the disc surface looks usually smooth and collagen fibres could clearly seen. The condylar cartilage is normally smooth, but in case of pathology *e.g.* in osteoarthritis where irregularities of the surface as erosions, osteophytes can be seen. Severe arthrotic changes of both fossa cartilage and disc may also be observed. Adhesions between the disc and glenoid fossa are quite common. In rare cases the arthrotic or inflammatory changes are found in the anterior recess. Upper compartment is swept clear under constant irrigation with isotonic saline solution. This manipulation allows translation of the disc along the eminence, allowing the condyle to complete its natural path. After the diagnostic arthroscopy has been completed, either forceps, palpation hook or blunt probe are used to cut fibres, mainly fibers of the pterygoid muscle anterior to the disc, in order to reduce pull in the anterior direction and facilitate repositioning of the disc. Cutting of adhesions facilitates repositioning of the disc. During arthroscopy a sweeping procedure between the disc and fossa releases the adhesions and fibrillations increasing the mobility in the joint. Release of the adhesions and fibrillations of the superior surface of the disc and shaving the surface of articular fossa in the upper joint compartment are performed with the aid of a blunt obturator or hook and with grasping forceps, scissors or double-edged knife. Removal of the superficial layer of cortical bone induces capillary bleeding stimulating formation of fibrocartilage on bone. Quite often a displaced disc may be found during arthroscopy. Surgical procedure is completed by irrigating the joint space to remove small tissue fragments. The outflowing fluid is collected and may be retained for diagnostic purposes. Arthroscopic lysis and lavage includes also a lateral release of the upper joint compartment performed with the aid of the blunt obturator or hook. Thus the locked disc could be mobilized sufficiently.

#### **6.4. Analysis of arthroscopic findings**

Clinical, radiographic and arthroscopic findings in patients who underwent arthroscopy are given in Table 2 [10].

Arthroscopic findings are as follows: irregularities of joint surfaces, foldings and synovitis – hyperaemia of the inner wall, localising also in the posterior part of the disc, intra-articular fibrous adhesions, intracapsular adhesions, fibrillations of superior surface of the disc and arthrotic lesions of temporal cartilage, pseudowalls, foreign bodies - chondromatosis (Figure 19, 20, 21, 22a, 22b, 23).

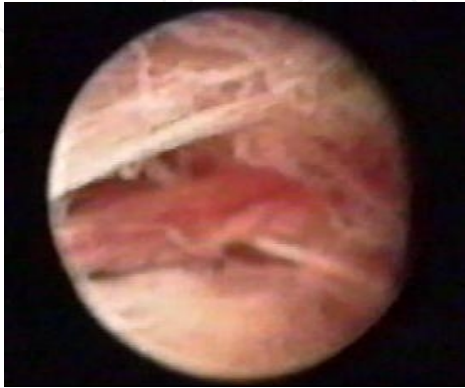
Signs and symptoms	Sum	% abn	Radiographic findings	Sum	% abn	Arthroscopic findings	Sum	% abn
Pain	25	86	Flattening	10	34	Adhesions	29	100
Hypomobility	23	79	Bone cyst / Subchondral pseudocysts	9	31	Chondromatosis	5	17
Closed lock	5	17	Erosions	20	69	Fibrillations	22	76
Intermittent lock	5	17	Reduced space	10	34	Synovitis	9	31
Deviation	4	14	Sclerosis	8	27	Eburneation of fossa	15	52
			Hypomobility of condyle	4	14	Displaced disc	23	23
			Osteophyts	5	17			

Sum = total number of patients with findings; % abn = percentage of individuals with abnormal findings.

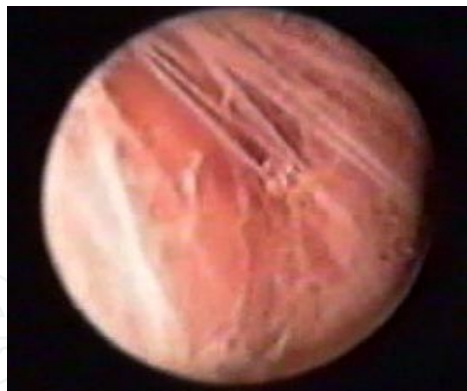**Table 2.** Clinical, radiographic and arthroscopic findings in patients who underwent arthroscopy (N=29).



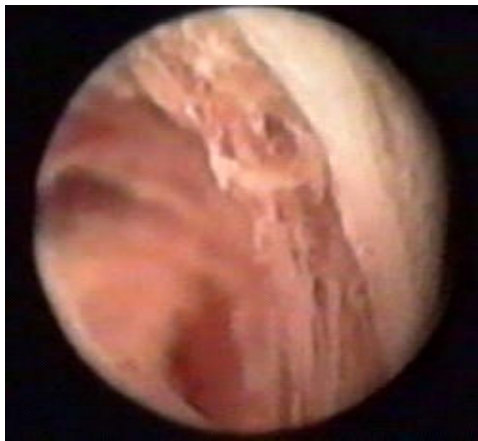
**Figure 19.** Posterior recess of the superior compartment of the right TMJ. Fibrillations and pronounced adhesions with appearance irregularities of condylar surface, hyperaemia in the posterior capsular wall. Synovial chondromatosis granule is in the 6 o'clock position. A greater amount of floating debris is noted.



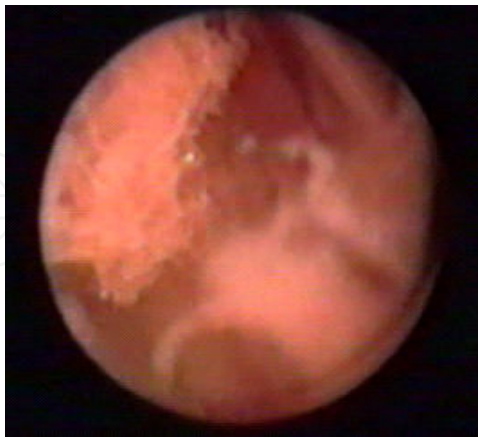
**Figure 20.** Posterior recess of the superior compartment of the left TMJ. Eburneation of glenoid fossa, adhesions and fibrillations with „crab meat“ appearance, mild granulations, irregularities of condylar surface, hyperaemia of the posterior attachment can be determined. Some debris is visible in the superior aspect of the field.



**Figure 21.** Posterior recess of the superior compartment of the right TMJ. The irregular surface of the remodeled retrodiscal tissues, fibrous adhesions, fibrillations and smooth fibres seen clearly. Synovial inflammation is obvious, localizing in the posterior part of the disc. Some loose bodies (chondromatosis granules) are detectable.

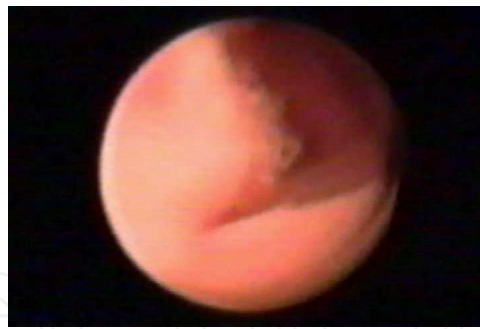

(a)



(b)

**Figure 22.** a. Posterior recess of the superior compartment of the left TMJ. Debris on the posterior glenoid fossa wall can be seen. Fibrillations, adhesions and increased vascularization in the posterior capsular wall. b. Posterior recess of the superior compartment of the left TMJ. Hyperaemia in the posterior capsular wall. A greater amount of floating debris and some granules (foreign bodies) are noted.



**Figure 23.** Appearance of the superior compartment of the TMJ after arthroscopic debridement. The apparent intimate relationship of the glenoid fossa with the valley of the retrodiscal tissue and its junction with the disc in an essentially normal TMJ. The joint space is free of debris.

The patients are to be followed up after 6 months and approximately 5 years after the operation. Intravenous antibiotics at the beginning of the procedure is recommended. Concepts of irrigation are to maintain the capsule distended through the procedure. Continuous irrigation constantly cleanses a joint debris and blood, increases mobility, relieving symptoms. It is also important to use of adjunctive therapy postoperatively to obtain maximum success with arthroscopic surgery *e.g.* physical therapy especially in case of haemorrhage, as it may prolong healing time *e.g.* ultrasound with hydrocortisone ointment. A pressure dressing during the first couple of hours after the operation is recommended.

### 6.5. Summary of arthroscopic findings

Arthroscopic findings included surface adhesions, stickiness of the superior surface of the disc to the anterior fossa portion and articular eminence, superior compartment adhesions, antero-medially displaced disc without reduction and morphologic changes in the disc. A number of arthroscopic findings as fibrous adherences mainly between the disc and fossa, fibrillations with „crab meat“ appearance, mild granulations, irregularities of condylar surface, foreign bodies, increased vascularisation are to be found. Synovitis in the upper joint space of the TMJ has been observed during arthroscopy and this inflamed synovium may cause pain. The alterations in the constituents of the synovial fluid affect lubrication of the joint causing stickiness and decreased mobility. Synovial chondromatosis has been found in the joint space [10, 45,46]. Synovial chondromatosis of the TMJ in both the superior and inferior joint compartments have found due to osteoarthritis during long period ~ 10 years [47].

### 6.6. Complications

Intra- and postoperative complications for arthroscopy are rare. Bleeding may be from branches of the temporal vein during puncture. Extravasation of irrigation fluid into surrounding tissues may be occur sometimes due to leakage of the irrigating fluid into the surrounding tissues caused by accidental perforation of the TMJ capsule. This situation is easily controlled if the surgeon always check the out-flow from out-flow cannula. From postoperative complications a few cases with otologic complications and nerve damage have been reported

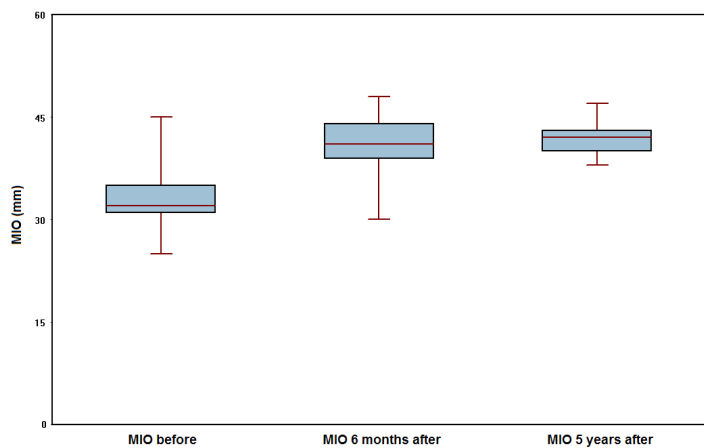


[5,48]. Injuria of superficial branches of facial nerve resulting to paraesthesia in the preauricular region was observed in two cases. These symptoms disappeared during one month [10].

7. Analysis of clinical data and results

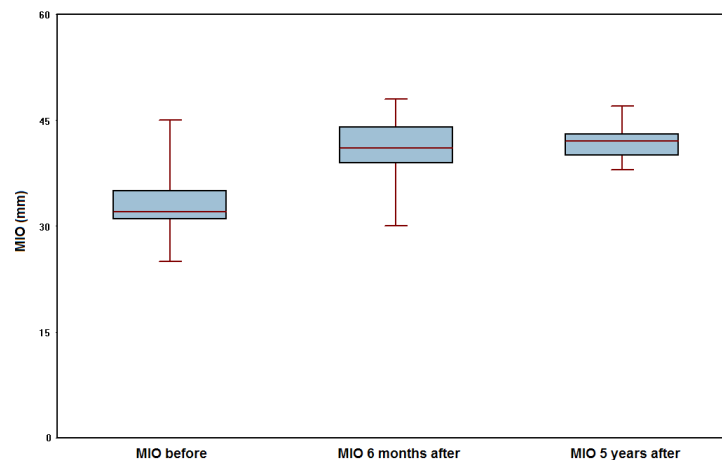
It has been shown that during arthroscopy several inflammatory and pain mediators causing destructive changes, foreign bodies as grains of chondromatosis are washed out eliciting joint noises [9,49]. For the patients with episodic signs and symptoms a noninvasive conservative approach is indicated (Wilkie's stages I-III). Procedures currently used for the TMJ derangements as osteoarthritis/arthrosis (Wilkie's stages IV and V) are: arthrocentesis, arthroscopy, arthrotomy or TMJ replacement. From arthroscopic findings fibrillation seemed to be the most common ~76% [50]. Arthroscopic lysis and lavage has been an effective treatment for TMJ disorders refractory to nonsurgical treatments [8,12,51]. An evaluation following temporomandibular joint arthroscopic surgery with lysis and lavage after 2 to 10,8 years treatment showed that arthroscopic surgery of the temporomandibular joint is successful in the long term for patients with painful motion [11,52]. Assessment of symptoms reported by the patient as well as of objective signs noted on clinical examination confirms resolution of pain on movement and increased vertical opening.

A significant and maintained improvement in MIO and VAS is also observed over the 5 years period of time (Figure 24, 25) [10].



**Figure 24.** Graphical representation of VAS values (median) before treatment and after 6 months and 5 years treatment in patients (n = 29).

TMJ arthroscopy is especially useful when the disc has not yet been deformed. Superior joint compartment adhesions and disc immobility can be treated during arthroscopic procedure, leading to resolution of symptoms and return of joint function [10]. The adhesions may cause retention of the disc in its anteriorly displaced position, which may explain the failure to



**Figure 25.** Graphical representation of MIO values (median) before treatment and after 6 months and 5 years after treatment in patients ( $n = 29$ ).

respond to conservative treatment. An adherence of the disc to the fossa may be caused by an alteration of the normal lubrication of the joint as a result of intermittent joint overloading, with secondary activation of oxidative species and degradation of hyaluronic acid. Anchored Disc Phenomen could be one of the first clinical symptoms observed in the chain events that would end in a more severe internal derangement [52, 53].

Long-term results of TMJ arthroscopy have been analysed demonstrating a high accuracy for adhesions, fibrillations and degenerative changes of the bone structures. The adhesions may cause retention of the disc in its anteriorly displaced position, which may explain the failing response to conservative treatment. It has been shown that during this procedure several inflammatory and pain mediators causing destructive changes and granules of chondromatosis are washed out eliciting joint noises [10, 22, 40]. It is important to select the procedure with the highest probability of success and least morbidity. For the patients with episodic signs and symptoms a noninvasive, conservative approach is indicated (Wilkies stages I-III). Procedures currently used for the TMJ derangements as osteoarthritis/arthrosis (Wilkies stages IV and V) are: arthrocentesis [12], arthroscopy, arthrotomy or TMJ replacement [5,54]. Pain and hypomobility seems to be a part of a wide spectrum of symptoms appearing in the context of chronic dysfunction of the TMJ. Some authors have reported that the major symptom has been closed lock phenomenon [12,55]. From arthroscopic findings [55] fibrillation seemed to be the most common -76%. In other study [10] closed lock was found in 17,2 % and fibrillations in 75,8 % of cases. Arthroscopic lysis and lavage has been an effective treatment for TMJ disorders refractory to nonsurgical treatments [8,12,51]. Several authors [52] performed long-term evaluation following temporomandibular joint arthroscopic surgery with lysis and lavage after 2 to 10,8 years treatment. On the bases of assessment of symptoms reported by the patients as well as objective signs noted on clinical examination confirmed resolution of pain on movement and increased vertical opening. In a later study also lysis and lavage improved translation of the joint, decreased or eliminated pain.

The chief presenting complaint for most patients (86,2%) was pain preoperatively. A significant maintained decrease in VAS score was achieved after 6 months and also 5 years follow-up. A significant and maintained improvement in MIO was also observed over the same period of time [10]. The results are comparable to those reported in the other papers [34,52]. It is important to take into account that the sympathetic and sensory nerve fibres within the temporomandibular joint are located in the anterior recess and the retrodiscal tissue of the upper compartment. Anterior disc release may reduce the number of these nerve fibres in arthroscopic procedures, thus influencing pain dynamics. The advantages of arthroscopy compared with open joint surgery using the Jaw Pain and Function Questionnaire are that arthroscopic surgery is less invasive and associated with lower morbidity [15]. No statistical differences were also observed between arthroscopic lysis and lavage and operative arthroscopy in relation to postoperative pain or MIO at any stage of the follow-up period [9]. Arthroscopic lysis and lavage has been found effective in 84% of patients in case of osteoarthritis of TMJ [55]. Multiple adhesions also develop skeletal changes, with a shortened ramus. If the condition develops rapidly enough, open bite and rethognathia may occur [40,56,57]. During arthroscopic surgery nodules of TMJ synovial chondromatosis are able to pass through the cannula by lavage with saline solution [49].

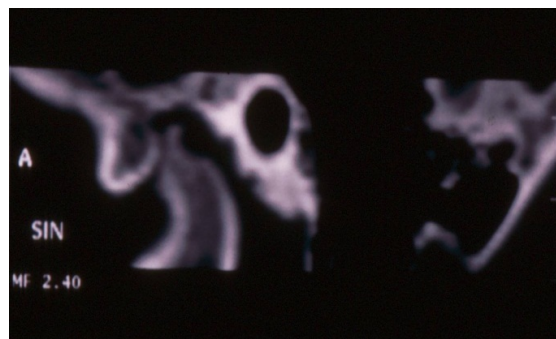
An adherence of the disc to the fossa may be caused by an alteration of the normal lubrication of the joint as a result of intermittent joint overloading, with secondary activation of oxidative species and degradation of hyaluronic acid. Anchored Disc Phenomen could be one of the first clinical symptoms observed in the chain events that would end in a more severe internal derangement [52,53].

Based on the present findings, it follows that a displaced disc, by itself, is of only limited significance. This is not surprising because the majority of individuals with derangement of the TMJ are asymptomatic [7,57]. The intriguing question that remains is why lavage and lysis of adhesions or high-pressure irrigation of the upper joint space should be therapeutic. The answer is, that during this procedure several inflammatory mediators available in the synovial fluid as prostaglandins [58], cytokines [22,59], serotonin as pain mediator [28] etc. are washed out. In episodes of closed lock, the limitation in condylar movement probably originates from changes in the upper compartment that restrict the sliding motion of the disc; This course of events may explain the efficacy of lysis and lavage of only this joint space, as this manipulation allows translation of the disc along the eminence, allowing the condyle to complete its natural path. The data in the literature have stated that the most frequent disc displacements were anterior and anteromedial [52].

In episodes of closed lock, the limitation in condylar movement probably originates from the changes in the upper compartment that restrict the sliding motion of the disc. The data in the literature have stated that the most frequent disc displacements were anterior and anteromedial [39,60]. Using MRI pre- and postoperatively revealed that disc position remained anteriorly without reduction, disc mobility increased after arthroscopic surgery [8]. Improvement in joint symptoms and function is not attributed so much as to the restoration of disc position as to possible release of the lateral capsular fibrosis during arthroscopy [52,61].

## 8. Arthrotomy

Arthrotomy can play an important role in the management of the TMJ disorders. There are conditions that require primary surgical management as developmental disturbances (condylar hypo-, hyperplasia of the mandible, tumours, ankylosis etc.). Secondary surgical management is indicated in case of arthritis, disc displacements, trauma, synovial chondromatosis. Not treated properly and immediately a juvenile trauma to the TMJ area can lead to ankylosis. Arthrotomy has been recognised as the only treatment method of fibrous or osseous ankylosis. There is still a group of patients whom an arthrotomy and disc surgery are necessary *e.g.* to treat painful clicking in patients with anteriorly displaced, nonreducing discs and limited mouth opening, irreparable disc perforation or if it is misshaped, shortened, rigid. Large medial osteophytes on the condyle are very difficult to shave arthroscopically, and in these situations they are better to handle *via* arthrotomy (Figure 26).

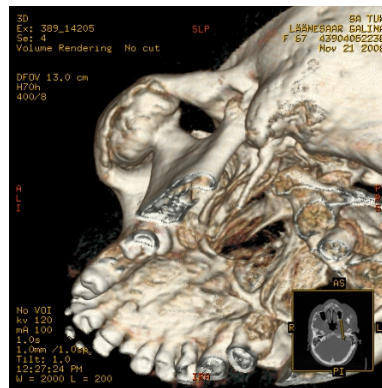


**Figure 26.** An osteophyte in the medial part of the right mandibular condyle in a sagittal view of the CT. Cortical destruction of the glenoid fossa surface.

Large central cartilaginous perforations may need an arthrotomy and possibly discectomy, although there are data about healing of disk perforations as the bilaminar zone undergoes metaplastic changes forming pseudodisc [61]. The importance of disc position and shape is emphasized by many authors [8, 51]. As a result, open joint procedures are developed to reposition the displaced disc [7, 9]. A surgical procedure for TMJ disc-repositioning surgery using bioresorbable fixation screws for stabilisation of the disc to the condyle is reported [62], but the efficacy of the method described should be confirmed by the long-term studies. Arthrotomy includes not only a discoplasty but also high condylar shave and eminectomy. For discectomy the medial disc attachment is cut with curved scissors, facilitating approach to the lower joint space. Direct comparison of the clinical results are achieved in patients following arthroscopic surgery with a group of patients who underwent open surgery. The postoperative follow-up period ranged 5 to 6 years and 9 months. These results following open and arthroscopic surgery measured with the Jaw Pain and Function Questionnaire a self rating



scale, originally published by Clark et al. [17] and differentiated by Wilkes' stages. No significant difference was noted when comparing the group 5 years postoperatively [15]. Some patients with a presentation of TMJ pathology however, have a history of previous mandibular trauma. Following trauma a joint ankylosis may occur. Ankylosis is more likely in younger patients and it can be also classified as true and false. False ankylosis results from pathologic conditions not directly related to the joint (Figure 27).

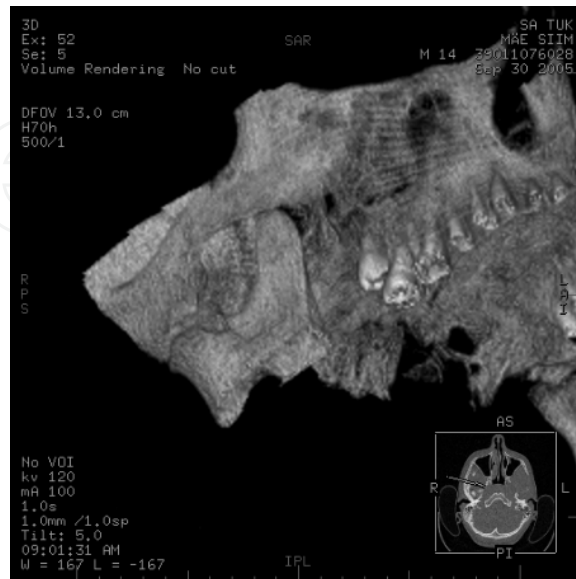


**Figure 27.** CT 3D reconstruction of the false ankylosis resulting from the osteochondroma of the left coronoid process.

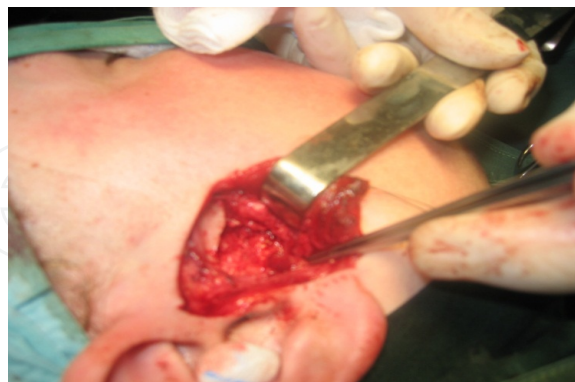There are several things to be considered the traumatically induced ankylosis. TMJ is commonly traumatized indirectly by blows to the mandible. It is known, that at least 35% of mandibular fractures involve the condyle [63]. It is found, that in 64% of the ankylosis cases, the patients had fractures of the mandible locating in the anterior area of the mandible and they were not diagnosed in time or not treated properly [65]. Synovial chondromatosis (SC) of the TMJ is a rare benign condition characterized by the formation of metaplastic cartilage in the synovium resulting in osteocartilagenous loose bodies within the joint [65]. We have analysed arthroscopic findings and synovial chondromatosis was observed in 17% of cases of treated patients due to TMJ osteoarthritis [10]. Differential diagnosis is necessary to perform with calcium pyrophosphate dihydrate crystal deposition disease of the TMJ.

### 8.1. Method of arthrotomy

Under general anaesthesia and naso-tracheal intubation (with fibre endoscope if necessary), a preauricular incision is performed. Preauricular approach is the most commonly used to expose the TMJ. Once the incision is carried through the skin and subcutaneous tissues, the tissue layer, containing partly the parotid gland, facial nerve branches, auriculotemporal nerve, superficial temporal artery and vein is bluntly reflected forward with the elevator in order to expose the joint capsule. Then a vertical incision is made to begin to expose the joint space (Figure 28, 29). After performing arthroplasty the wound can be closed in the usual fashion.



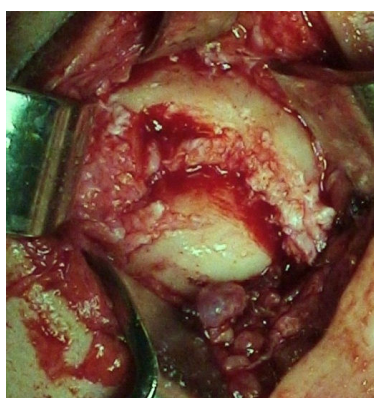
**Figure 28.** D image of the CT showing fibroosseous ankylosis of the right TMJ on a 15 yrs. boy. Trauma took place at the age of 4 years.



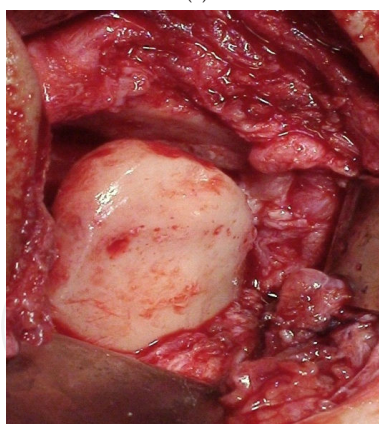
**Figure 29.** Arthrotomy of the same 15 yrs boy is performed. The right ankylotic TMJ is exposed.

We have used [66] the suture anchor in interpositional arthroplasty in case of the temporomandibular joint ankylosis traumatic origin. Ankylotic left TMJ was exposed and a gap arthroplasty was performed using different types of burs. An ipsilateral myofascial temporal pedicled flap was prepared, rotated inferiorly and interposed between the head of the condyle

and the mandibular fossa.. The mini anchor in the lateral pole of the condyle was inserted and anchored suture of the myofascial flap was performed and the capsule was sutured.(Figure 30a, 30b, 31a, 31b, 32).

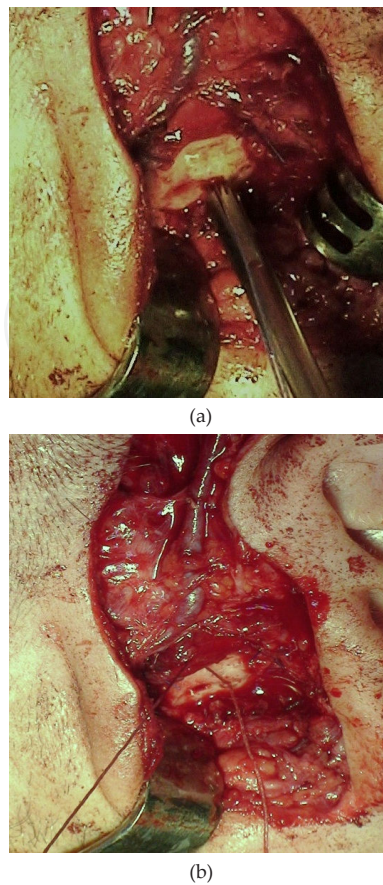


(a)

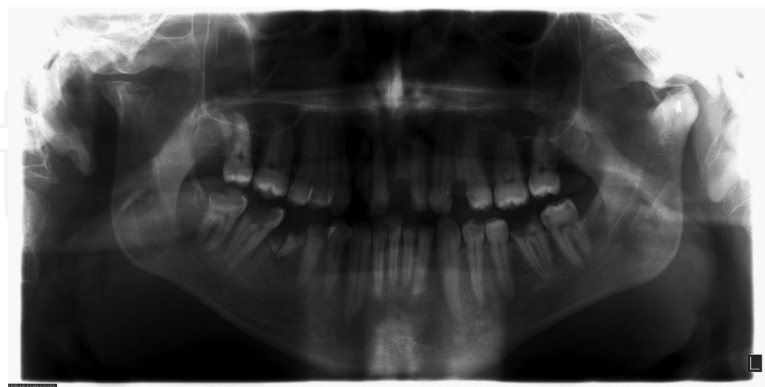

(b)

**Figure 30.** a. Ankylosed left TMJ is exposed for osteotomy. b. The osseous components of the TMJ after arthroplasty and the joint space is formed.



**Figure 31.** a. Insertion of the mini anchore in the lateral pole of the condyle. b. The condyle and the anchored suturing of the myofascial flap.

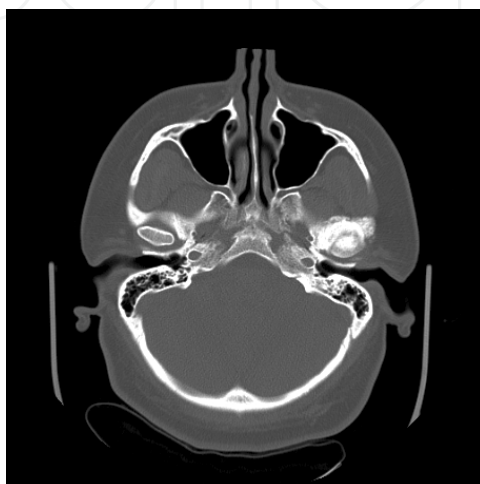

**Figure 32.** Post-operative ortopantomograph showing an acceptable anatomy of the left mandibular condyle and articular fossa and a formed space between them. The mini anchor is visualized in the condyle.

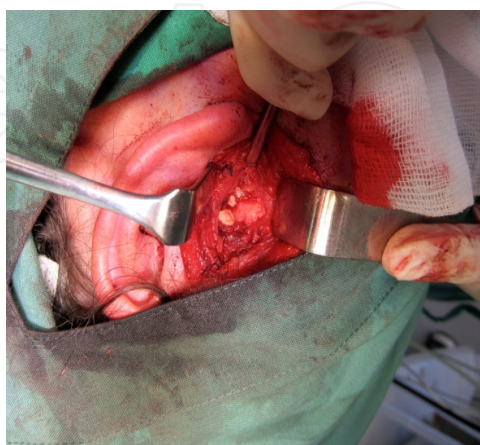
The standard treatment in case of synovial chondromatosis is arthrotomy of the affected joint and removal of the loose bodies. In our case granular masses with different size situated in the upper compartment of the TMJ (Figure 33, 34, 35a). Histological findings showed chondro-



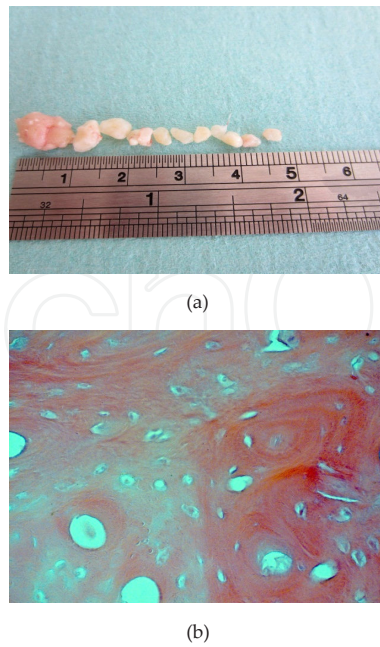
metaplasia of the synovial membrane (Figure 35b) [67]. Arthroscopy is proved to be useful for management of synovial chondromatosis of the TMJ in case of granules smaller than 3 mm which are commonly removed with joint lavage [10]. OPTG and CT scans reveal usually calcifying lesions in the TMJ region.



**Figure 33.** Axial view of the CT scan of the patient (female, 44 yrs.), showing granular masses surrounding the left condylar head.



**Figure 34.** Intra-operative finding of the same patient (female, 44 yrs.) with irregular cartilaginous loose granules in the posterior recess of the upper compartment of the TMJ.



**Figure 35.** a. The different size of granules are pearly white, of varying shape and ranging in the size from 3,0 to 10,0 mm.b. Histologically clustered hyaline chondrocytes with synovial lining are visible. Staining with haematoxylin-eosin, magnification 40X.

## 9. Summary

Early diagnosis is the key to successful treatment, because it permits the use of nonsurgical means or minimally invasive procedures (arthrocentesis, arthroscopy). In late stage disease is indicated arthrotomy, to attain an improved quality of life with less pain and improved function. Clinical success of arthroscopy is based on several factors. Lysis and lavage remove intraarticular inflammatory and pain mediators. The release of fibrillations and adhesences as well as improvement in discal mobility allows to distribute the functional stresses on the articular tissues and adverse loading on the joints is decreased. The long-term outcome of TMJ arthroscopic surgery with lysis and lavage is considered to be acceptable and effective. Fibrillations and fibrous adhesions are the most usual pathological signs of arthroscopic findings in patients with internal derangement of the TMJ. Arthroscopic releasing of these restrictive bands improves the joint mobility and contributes to reducing pain level. The results of arthroscopy offered favourable long-term stable results with regard to increasing MIO and reducing pain and dysfunction. The improvement in joint mobility and disc mobility will lead to adaptive changes in the hard tissues. This may imply that the arthroscopic procedure with mechanics may stop the process of further TMJ degeneration. The advantages of arthroscopy compared with open joint surgery are that arthroscopic surgery is less invasive, procedure needs less time and associated with lower morbidity. Arthrotomy is indicated in cases with anteriorly displaced, nonreducing discs who continue to have pain and limited mouth opening despite the treatment by either arthrocentesis or arthroscopic surgery that has not responded

to arthrocentesis or arthroscopy. In conclusion procedures such as arthrocentesis, arthroscopic surgery and arthrotomy can be used with reasonably good results in properly selected cases.

## Acknowledgements

The publication of this chapter is supported by Ernst Jaakson Memorial Scholarship.

## Author details

Edvitar Leibur<sup>1,2</sup>, Oksana Jagur<sup>1</sup> and Ülle Voog-Oras<sup>1</sup>

1 Department of Stomatology, Tartu University, Tartu University Hospital, Estonia

2 Department of Internal Medicine, Tartu University, Tartu University Hospital, Estonia

## References

- [1] Sanders B, Buonocristiani R. Diagnostic and Surgical Arthroscopy of the Temporomandibular Joint: Clinical Experience with 137 Procedures over a 2-year period. *Journal of Craniomandibular Disorders: Facial & Oral Pain* 1987;12(3) 202-213.
- [2] Tag H. Arthroscope. *Journal of Japanese Orthopedic Association* 1939;14, 359-362.
- [3] Onishi M. Arthroscopy of the temporomandibular joint (author's transl.). *Journal of Japanese Stomatological Association* 1975;(42) 207-213.
- [4] Onishi M. Clinical application arthroscopy in the temporomandibular joint diseases. *Bulletin Tokyo Medical Dental University* 1980;(27) 141-148.
- [5] McCain JP, Sanders B, Koslin MG, Quinn JH, Peters PB, Indresano AT. Temporomandibular joint arthroscopy : a 6-year multicenter retrospective study of 4,831 joints. *Journal of Oral and Maxillofacial Surgery* 2002;50(9) 926-930.
- [6] Holmlund AB, Axelsson S. Temporomandibular arthropathy: correlation between clinical signs and symptoms and arthroscopic findings. *International Journal of Oral & Maxillofacial Surgery* 1996;25(3) 266-271.
- [7] Holmlund AB, Axelsson S, Gynther GW. A comparison of discectomy and arthroscopic lysis and lavage for the treatment of chronic closed lock of the temporomandibular joint: a randomized outcome study. *Journal of Oral and Maxillofacial Surgery* 2001;59(9) 972-977.
- [8] Ohnuki T, Fukuda M, Iino M, Takahashi T. Magnetic resonance evaluation of the disk before and after arthroscopic surgery for temporomandibular disorders. *Oral*

Surgery Oral Medicine Oral Pathology Oral Radiology Endodontics 2003;96(2) 141-148.

- [9] González-Garcia R, Rodriguez-Campo FJ, Monje F, Sastre-Perez J, Gil-Diez Usandizaga JL. Operative versus simple arthroscopic surgery for chronic closed lock of the temporomandibular joint: a clinical study of 344 arthroscopic procedures. *International Journal of Oral&Maxillofacial Surgery* 2008;17(9) 790-796.
- [10] Leibur E, Jagur O, Mürsepp P, Veede L, Voog-Oras Ü. Long-term evaluation of arthroscopic surgery with lysis and lavage of temporomandibular disorders. *Journal of Cranio-Maxillo-Facial Surgery* 2010;38(8) 615-620.
- [11] Murakami K, Segami N, Okamoto I, Takahashi K, Tsuboi, Y. Outcome of arthroscopic surgery for internal derangement of the temporomandibular joint: long – term results covering 10 years. *Journal of Cranio-Maxillo-Facial Surgery* 2000;28(3) 264 – 271.
- [12] Sanroman JF. Closed lock (MRI fixed disc): a comparison of arthrocentesis and arthroscopy. *International Journal of Oral & Maxillofacial Surgery* 2004;33(4) 344-348.
- [13] Mancha de la Plata M, Muñoz-Guerra M, Escorial Hernandez V, Martos Diaz P, Gil-Diez Usandizaga JL, Rodriguez-Campo FJ. Unsuccessful temporomandibular joint arthroscopy: is a second arthroscopy an acceptable alternative? *Journal of Oral and Maxillofacial Surgery* 2008;66(10) 2086-2092.
- [14] Voog Ü, Alstergren P, Leibur E, Kallikorm R, Kopp S. Impact of temporomandibular joint pain on activities of daily living in patients with rheumatoid arthritis. *Acta Odontologica Scandinavica* 2003;61(5) 278-282.
- [15] Undt G, Murakami KI, Rasse M, Ewers R. Open versus arthroscopic surgery for internal derangement of the temporomandibular joint: A retrospective study comparing two centers results using Jaw Pain and Function Questionnaire. *Journal of Cranio-Maxillo-Facial Surgery* 2006;34(4) 234-241.
- [16] Jagur O, Kull M, Leibur E, Kallikorm R, Looits D, Lember M, Voog-Oras Ü. The associations of TMJ pain and bone characteristics on the activities of daily living. *Open Journal of Stomatology* 2012 (accepted for publication).
- [17] Clark GT, Seligman D, Solberg WK, Pullinger AG. Guidelines for the examination and diagnosis of temporomandibular disorders. *Journal of Craniomandibular Disorders* 1989;3(1) 7-14.
- [18] Sommer OJ, Aigner F, Rudisch A, Gruber H, Fritsch H, Millesi W, Stiskal M. Cross-sectional and Functional Images of the Temporomandibular Joint: Radiology, Pathology, and Basic Biomechanics of the Jaw Radiographics. *Radiology* 2003;23(6) 428-432.
- [19] Schmelzle R. Lokalanästhesie. In: *Zahnärztliche Chirurgie*. 2. Auflage Urban & Schwarzenberg. München-Wien-Baltimore 1989; p.19.



- [20] Tallents RH, MacherDJ, Kyrkanides S, Katzberg RW, Moss M.E. Prevalence of missing posterior teeth and intraarticular temporomandibular disorders. *Journal of Prosthetic Dentistry* 2002;87(1) 45-49.
- [21] Voog Ü, Alstergren P, Eliasson S, Leibur E, Kallikorm R, Kopp S. Progression of radiographic changes in the temporomandibular joints of patients with rheumatoid arthritis in relation to inflammatory markers and mediators in the blood. *Acta Odontologica Scandinavica* 2004;62(1) 7-13.
- [22] Voog Ü, Alstergren P, Eliasson S, Leibur E, Kallikorm R, Kopp S. Inflammatory mediators and radiographic changes in temporomandibular joints in patients with rheumatoid arthritis. *Acta Odontologica Scandinavica* 2003;61(1) 57-64.
- [23] Kim SJ, Park YH, Hong SP, Cho BO, Park JW, Kim SG. The presence of bacteria in the synovial fluid of the temporomandibular joint and clinical significance: preliminary study. *Journal of Oral and Maxillofacial Surgery* 2003;61(10) 1156-1161.
- [24] Paegle DI, Holmlund AB, öStlund MR, Grillner L. The occurrence of Antibodies against Chlamydia species in patients with monoarthritis and chronic closed lock of the temporomandibular joint. *Journal of Oral and Maxillofacial Surgery* 2004;62(4) 435-439.
- [25] Alstergren P, Kopp S, Theodorson E. Synovial fluid sampling from the temporomandibular joint: sample quality criteria and levels of interleukin-1 beta and serotonin. *Acta Odontologica Scandinavica* 1999;57(1) 278-282.
- [26] Kamada A, Kakudo K, Arika T, Okazaki J, Kano M, Sakaki T. Assay of synovial MMP3 in temporomandibular joint diseases. *Journal of Cranio-Maxillo- Facial Surgery* 2000;28(3) 247-248.
- [27] Alstergren P, Kopp S. Pain and synovial fluid concentration in arthritic temporomandibular joints. *Pain* 2007;2(1-2) 137-143.
- [28] Voog Ü, Alstergren P, Leibur E, Kallikorm R, Kopp S. Immediate effect of the serotonin antagonist granisetron on temporomandibular joint pain in patients with systemic inflammatory disorders. *Life Sciences* 2000;68(5) 591-602.
- [29] Warden SJ, Haney EM. Skeletal effects of serotonin (5-hydroxytryptamine) transporter inhibition: evidence from in vitro and animal-based studies. *Journal of Musculoskeletal Neuronal Interaction* 2008;8(2) 121-132.
- [30] Wilkes CH. Internal derangements of the temporomandibular joint. Pathological variations. *Archives of Otolaryngology, Head Neck Surgery* 1989;115(4) 469-477.
- [31] List T, Helkimo M. A scale for measuring the activities of daily living (ADL) of patients with craniomandibular disorders. *Swedish Dental Journal* 1995;19(1) 33-40.

- [32] Kaselo E, Jagomägi T, Voog U. Malocclusion and the need for orthodontic treatment in patients with temporomandibular dysfunction. *Stomatologija. Baltic Dental and Maxillofacial Journal* 2007;9(3) 79-85.
- [33] Whyte AM, McNamara D, Rosenberg I, Whyte AW. Magnetic resonance imaging in the evaluation of temporomandibular joint disc displacement. *International Journal of Oral & Maxillofacial Surgery* 2006;35(8) 696-703.
- [34] Landes CA, Goral WA, Sader R, Mack MG. 3-D sonography for diagnosis of disc dislocation of the temporomandibular joint compared with MRI. *Ultrasound Medical Biology* 2007;32(5) 633-639.
- [35] Rohlin M, Åkerman S, Kopp S. Tomography as an aid to detect macroscopic changes of the temporomandibular joint. *Acta Odontologica Scandinavica* 1986;44(3) 131-140.
- [36] Helenius L, Hallikainen D, Meurman J, Koskimies S, Tervahartiala P, Kivisaari L, Hietanen J, Suuronen R, Lindqvist C, Leirisalo-Repo M. HLA-DRB1\* alleles and temporomandibular joint erosion in patients with rheumatic disease. *Scandinavian Journal of Rheumatology* 2004;33(1) 24-29.
- [37] Suarez FR, Bhussry BR, Neff PA, Huang HK, Vaughn D. A preliminary study of computerized tomographs of the temporomandibular joint. *The Compendium on continuing education in general dentistry* 1980;1(3) 217-222.
- [38] Raustia M, Pyhtinen J, Virtanen KK. Examination of the temporomandibular joint by direct sagittal computed tomography. *Clinical Radiology* 1985;36(3) 291-296.
- [39] Larheim TA, Westesson P, Sano T. Temporomandibular Joint Disk Displacement: Comparison in Asymptomatic Volunteers and Patients. *Radiology* 2001;218(2) 428-32.
- [40] Emshoff R, Brandlmaier I, Bertram S, Rudish A. Relative odds of temporomandibular joint pain as a function of magnetic resonance imaging findings of internal derangement, osteoarthritis, effusion, and bone marrow edema. *Oral Surgery Oral Medicine Oral Pathology Oral Radiology Endodontics* 2003;95(4) 437-445.
- [41] Rohlin M, Petersson A. Rheumatoid arthritis of the temporomandibular joint: radiologic evaluation based on standard reference films. *Oral Surgery, Oral Medicine, and Oral Pathology* 1989;67(5) 594-599.
- [42] Gaggle A, Schults G, Santler G, Kärcher H, Simbrunner J. Clinical and magnetic resonance findings in the temporomandibular joints of patients before and after orthognathic surgery. *The British Journal of Oral & Maxillofacial Surgery* 1999;37(1) 41-45.
- [43] Landes C, Walendzik H, Klein C. Sonography of the temporomandibular joint from 60 examinations and comparison with MRI and axiography. *Journal of Cranio-Maxillo-Facial Surgery* 2000;28(6) 352-361.

- [44] Torres DE, McCain JP. Arthroscopic elctrothermal capsulorrhaphy for the treatment of recurrent temporomandibular joint dislocation. *International Journal of Oral & Maxillofacial Surgery* 2012;41(6) 681-689.
- [45] Mercuri LG. Synovial chondromatosis of the temporomandibular joint with medial cranial fossa extension. *International Journal of Oral & Maxillofacial Surgery* 2008;37(7) 684-685.
- [46] González-Pérez LM, Concregado-Córdoba J, Salinas-Martin MV. Temporomandibular joint synovial chondromatosis with a traumatic etiology. *International Journal of Oral & Maxillofacial Surgery* 2011;40(3) 330-334.
- [47] Sato J, Segami N, Suzuki T, Yoshitake Y, Nishikawa K. The expression of fibroblast growth factor receptor 1 in chondrocytes in synovial chondromatosis of the temporomandibular joint. Report of two cases. *International Journal of Oral & Maxillofacial Surgery* 2002;31(7) 532-536.
- [48] Appelbaum EL, Berg LF, Kumar A, Mafee MF. Otologic complications Following temporomandibular joint arthroscopy. *Annals of Otology, Rhinology, Laryngology* 1988;97(6) 675-679.
- [49] Shibuya T, Kino K, Yoshida S, Amagasa T. Arthroscopic removal of nodules of synovial chondromatosis of the temporomandibular joint. *Cranio* 2002;20(4) 304-306.
- [50] Dimitroulis G. A review of 56 cases of chronic closed lock treated with temporomandibular joint arthroscopy. *Journal of Oral and Maxillofacial Surgery* 2002;60(5) 519-524.
- [51] Politi M, Sembronio S, Robiony M, Costa F, Toro C, Undt G. High condylectomy and disc repositioning compared to arthroscopic lysis, lavage and capsular stretch for the treatment of chronic closed lock of the temporomandibular joint. *Oral Surgery Oral Medicine Oral Pathology Oral Radiology Endodontics* 2007;103(1) 27 - 33.
- [52] Sorel B, Piecuch JF. Long-term evaluation following temporomandibular joint arthroscopy with lysis and lavage. *International Journal of Oral & Maxillofacial Surgery* 2000;29(4) 532-536.
- [53] Krug J, Jirousek Z, Suchmova H, Germakova E. Influence of discoplasty and discectomy of the temporomandibular joint on elimination of pain and restricted mouth opening. *Acta Medica (Hradec Kralove)* 2004;47(1) 47-53.
- [54] Smolka W, Iizuka T. Arthroscopic lysis and lavage in different stages of internal derangement of the temporomandibular joint: correlation of preoperative staging to arthroscopic findings and treatment outcome. *Journal of Oral and Maxillofacial Surgery* 2005;63(4) 471-478.
- [55] Dimitroulis G. The prevalence of osteoarthritis in cases of advanced internal derangement of the Temporomandibular Joint: a clinical, surgical and histological study. *International Journal of Oral & Maxillofacial Surgery* 2005;34(2) 345-349.

- [56] Emshoff R. Clinical factors affecting the outcome of arthrocentesis and hydraulic distension of the temporomandibular joint. *Oral Surgery Oral Medicine Oral Pathology Oral Radiology Endodontics* 2005;100(4) 409-414.
- [57] Hamada Y, Kondoh T, Holmlund AB, Iino M, Kobayashi K, Seto K. Influence of arthroscopically observed fibrous adhesions before and after joint irrigation on clinical outcome in patients with chronic closed lock of the temporomandibular joint. *International Journal of Oral & Maxillofacial Surgery* 2005; 34(7) 727-732.
- [58] Murakami KI, Shibata T, Kubota E, Maeda H. Intra-articular levels of prostaglandin E<sub>2</sub>, hyaluronic acid, and chondroitin -4 and -6 sulfates in the temporomandibular joint synovial fluid of patients with internal derangement. *Journal of Oral and Maxillofacial Surgery* 1998;56(2) 199-203.
- [59] Kardel R, Ulfgren AK, Reinholt FP, Holmlund A. Inflammatory cell and cytokine patterns in patients with painful clicking and osteoarthritis in the temporomandibular joint. *International Journal of Oral & Maxillofacial Surgery* 2003;32(5) 390-396.
- [60] Güven O. Management of chronic recurrent temporomandibular joint dislocations: A retrospective study. *Journal of Craniomaxillofacial Surgery* 2009;37(1) 24-29.
- [61] Moses JJ, Lo H. The treatment of internal derangement of the temporomandibular joint – an arthroscopic approach. *Oral Surgery Oral Diagnosis* 1992;3, 5-11.
- [62] Sembronio S, Robiony M, Politi M. Disc-repositioning surgery of the temporomandibular joint using bioresorbable screws. *International Journal of Oral & Maxillofacial Surgery* 2006;35(10) 1149-1152.
- [63] Bradley P. Injuries of the condylar region and coronal process. In Rowe NL, Williams JL (eds.): *Maxillofacial Injuries*, Vol.1. London, England, Churchill Livingstone, 1985, pp. 337-339
- [64] He D, Ellis E. 3rd., Zhang Y. Etiology of temporomandibular joint ankylosis secondary to condylar fractures: the role of concomitant mandibular fractures. *Journal of Oral and Maxillofacial Surgery* 2008;66(1).74-78
- [65] Ardekian L, Faquin W, Troulis M, Kaban LB, August M. Synovial chondromatosis of the temporomandibular joint: report and analysis of eleven cases. *Journal of Oral and Maxillofacial Surgery* 2005;63,(5) 941-947.
- [66] Nestal-Zibo H, Leibur E, Voog-Oras Ü, Tamme T. Use of the suture anchor in interpositional arthroplasty of temporomandibular joint ankylosis. *Oral and Maxillofacial Surgery* 2012;16(1) 157-162.
- [67] Jagur O, Leibur E, Erm T. Synovial chondromatosis of the temporomandibular joint. A case report. *Stomatologija. Baltic Dental and Maxillofacial Journal* 2012;12(Suppl. 8):29.



