

We are IntechOpen, the world's leading publisher of Open Access books Built by scientists, for scientists

6,900

Open access books available

186,000

International authors and editors

200M

Downloads

Our authors are among the

154

Countries delivered to

TOP 1%

most cited scientists

12.2%

Contributors from top 500 universities



WEB OF SCIENCE™

Selection of our books indexed in the Book Citation Index
in Web of Science™ Core Collection (BKCI)

Interested in publishing with us?
Contact book.department@intechopen.com

Numbers displayed above are based on latest data collected.
For more information visit www.intechopen.com



Ankle Arthroscopy

Jami Ilyas

Additional information is available at the end of the chapter

<http://dx.doi.org/10.5772/54013>

1. Introduction

Arthroscopy is a valuable skill for the foot and ankle surgeon and is used not only to evaluate and treat intra-articular abnormalities but also for endoscopic and tendoscopic procedures. Burman [1] was the first to attempt arthroscopy of the ankle joint in 1931 and surmised that it was not a suitable joint for arthroscopy because of its narrow intra-articular space. With the development of smaller-diameter arthroscopes and improvements in joint distraction techniques, there was a renewed interest in ankle arthroscopy. Watanabe [2] was the first to present a series of 28 ankle arthroscopies in 1972.

Arthroscopic surgery of the ankle allows the direct visualization of all intra-articular structures of the ankle without an arthrotomy or malleolar osteotomy. Technological advances and a thorough understanding of anatomy have resulted in an improved ability to perform diagnostic and operative arthroscopy of the ankle. The decreased morbidity and faster recovery times make it an appealing technique compared with open arthrotomy.

2. Indications and contraindications of ankle arthroscopy

For the purpose of simplification, relative indications for ankle arthroscopy can be divided into 3 distinct surgical categories based on the desired final outcome for the procedure:

1. Arthroscopic ankle survey
2. Arthroscopic reparative ankle surgery
3. Arthroscopic ablative ankle surgery

2.1. Arthroscopic ankle survey

Arthroscopic survey should be considered when preoperative assessment of the ankle joint does not yield a confirmative diagnosis via clinical, physical, or diagnostic testing. Arthroscopic survey in the ankle joint may also be desired as a precursor to anticipated reparative arthroscopic procedures as well.

Indications for an ankle arthroscopic survey include lavage for septic joint with survey, syndesmotomic analysis, preemptive assessment of joint before an intended open repair, assessment of poorly placed internal or external fixation hardware & arthroscopic biopsy. With respect to arthroscopic survey, the scope of the procedure is relatively narrow, as one would expect with any operative survey. Surveys may be performed after an examination under anaesthesia with mortise and Broden's views of the ankle under image intensification before a formal repair of the lateral ligament & retinacular structures or "Brostrom" (modified/true) repair for ankle joint instability.

An arthroscopic survey may also be beneficial as a diagnostic tool when infection is suspected. The success of this approach may be directly related to the physiologic lavage and reduction of a pathologic microorganism count more so than the topical introduction of antibiotic-rich saline. Often, an unsuspected chondral fracture or soft-tissue lesion not detected on radiographic, clinical, or laboratory evaluation or on bone scanning or magnetic resonance (MRI) imaging can become obvious on arthroscopic examination [3].

2.2. Arthroscopic reparative ankle surgery

Reparative arthroscopy may be indicated when preoperative assessment examinations are relatively conclusive for an underlying pathology via clinical, physical, or diagnostic findings. Simply put, this is a surgical "search and remove/repair" approach to ankle arthroscopy. Reparative indications include synovectomy, ligament repair, osteochondral defect repair, capsular thermo-cautery, intra-articular fracture reduction, arthrofibrosis, impingement syndromes (either soft tissue or osseous), and os trigonum resection.

2.3. Arthroscopic ablative ankle surgery

Another parameter in the surgical decision-making process as to whether an open repair versus an arthroscopic procedure is better indicated can be made on realization of the constraints of an arthroscopic approach to the ankle joint. Studies have shown that patients with bony or soft tissue impingements tend to do better with smaller focal impingements and a lack of significant osteoarthritis. This consideration is an important one if solely for the purpose of open treatment consent and appropriate instrumentation being available at time of surgery. Arthroscopy can also be used in ankle-stabilization procedures [7] and arthrodesis [11, 12] as well as for irrigation and debridement of septic arthritis [13].

Relative contraindications for arthroscopy of the ankle include moderate degenerative joint disease with a restricted range of motion, a markedly reduced joint space, severe edema, reflex sympathetic dystrophy, and a tenuous vascular status. More absolute contraindications include localized soft-tissue infection and severe degenerative joint disease [9].

| Soft tissue Lesions | Bony Indications |
|-------------------------------------|---|
| • Synovitis | • Osteochondral lesions |
| • Anterior soft tissue impingement | • Loose bodies |
| • Posterior soft tissue impingement | • Osteophytes |
| • Syndesmotic impingement | • Traumatic and degenerative osteoarthritis |
| • Lateral ankle instability | • Ankle fusion |
| | • Acute ankle fractures |

Table 1. Indications for Ankle Arthroscopy

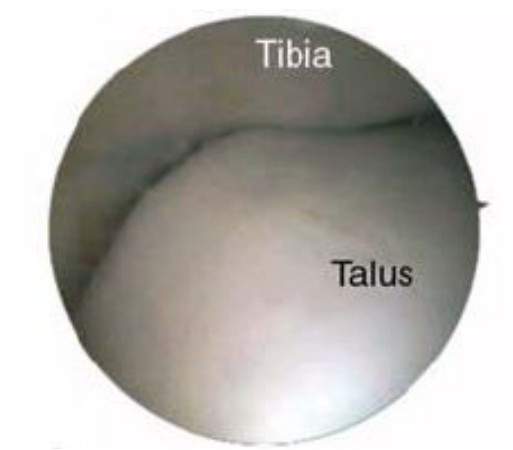

Figure 1. Normal ankle joint,

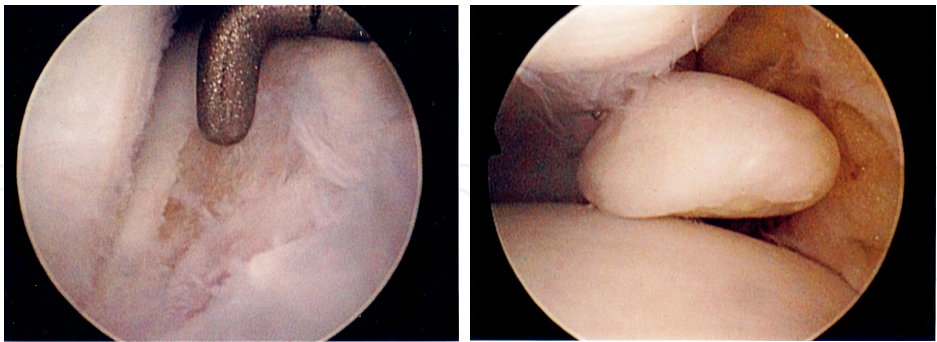


Figure 2. a) Osteoarthritis and **b)** Loose body

3. Synovitis

The synovial lining of the ankle joint may become inflamed and hypertrophied secondary to various inflammatory arthritis, infection, and degenerative or neuropathic changes. Trauma

and overuse can cause generalized inflammation of the joint synovium, resulting in pain and swelling.

Diagnosis may be made clinically on the basis of diffuse ankle pain and swelling with painful range of motion. Septic arthritis, gout, and other systemic arthritis must first be ruled out with aspiration. Localized synovitis of the medial or lateral talo-malleolar joint can develop after trauma (Figure 3). Localized tenderness with minimal swelling and full range of motion is usually seen on physical examination. The diagnostic workup is usually negative, although there may be some signal alteration on MR imaging.

Initial treatment should consist of limited weight bearing, anti-inflammatory medication, and physical therapy. Intra-articular injections of corticosteroids may be used. Failure of conservative treatment of at least 3 months duration is the indication for arthroscopic partial synovectomy and lysis of adhesions, which can provide dramatic relief of pain. Treatment of infected ankle joints by arthroscopic irrigation and debridement has been described [28]. The less invasive nature of the procedure is appealing. However, there are no prospective studies comparing open and arthroscopic debridement of infected ankle joints, and the latter should therefore be considered an investigational technique.

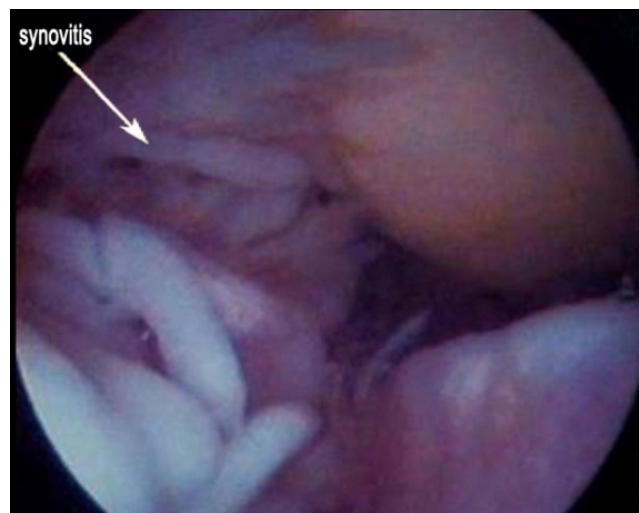


Figure 3. Synovitis and arthrofibrosis in ankle joint

4. Soft tissue impingement

4.1. Anterior soft tissue Impingement

The cause of chronic lateral ankle pain is often elusive, particularly in patients whose ankles are stable on physical examination and stress radiography. Anterior soft-tissue impingement, or anterolateral impingement of the ankle, is believed to be caused by one or more inversion injuries to the ankle joint [4]. The pain is usually anterolateral and persists despite adequate rest, healing, and rehabilitation.

Physical examination must distinguish pain in the lateral gutter of the ankle joint from pain in the area of the sinus tarsi. If there is tenderness in both areas, an anesthetic agent should be injected into the sinus tarsi; if this relieves the symptoms, the diagnosis of anterolateral impingement should not be made. The two may coexist, or subtalar dysfunction may be the underlying problem. The differential diagnosis includes ankle and subtalar instability, osteochondral lesions of the talus, calcific ossicle beneath the malleolus, peroneal subluxation or tear, tarsal coalition, and degenerative joint disease [4].

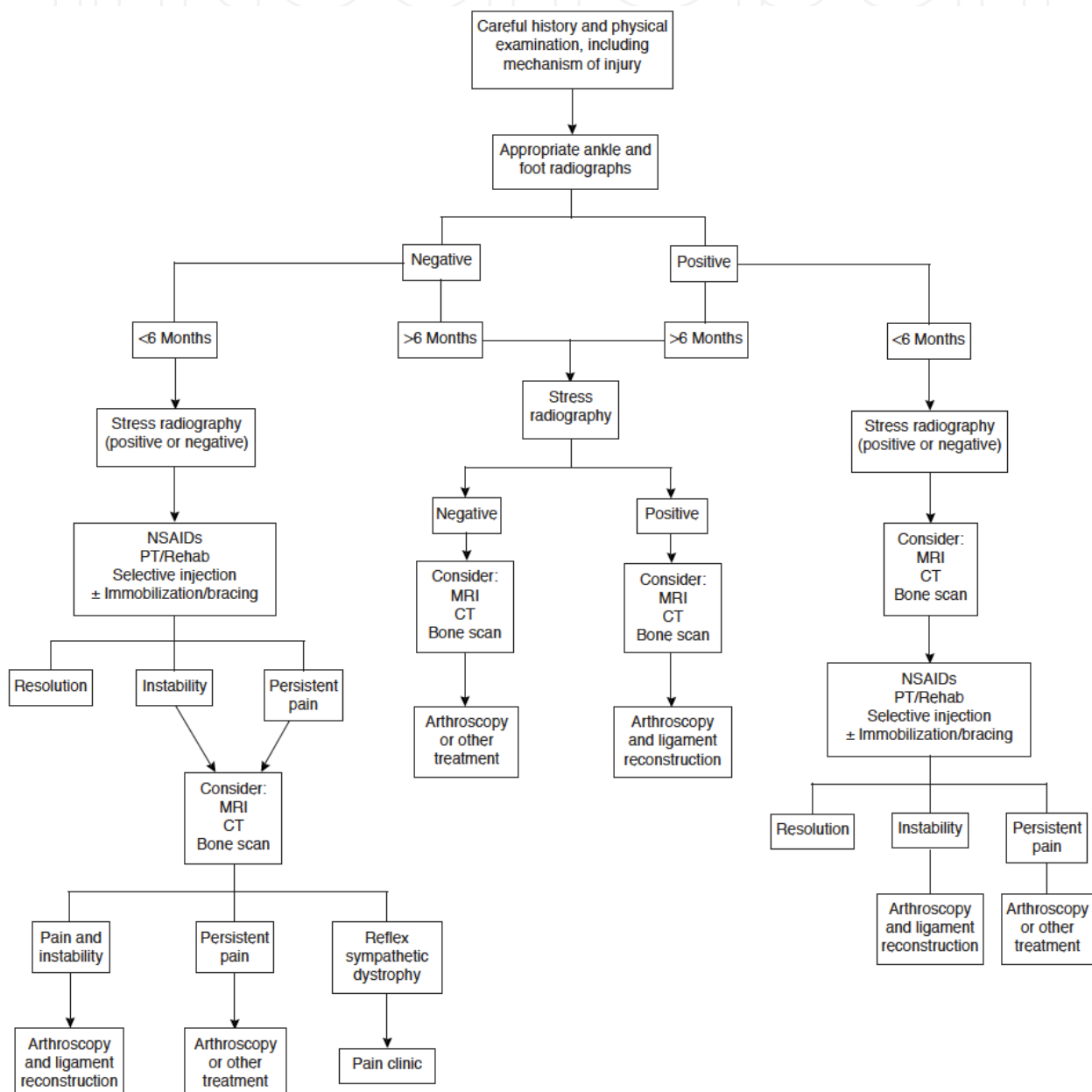


Figure 4. Algorithm for management of chronic ankle pain (Reference: Stetson & Ferkel, Ankle Arthroscopy: Indications & Results. J Am Acad Orthop Surg 1996 [30])

Anterolateral impingement most commonly occurs in the superior portion of the anterior talofibular ligament, but it can also be localized to the distal portion of the anteroinferior tibiofibular ligament (AITFL). Ferkel et al have stated that anterolateral synovial tissue and redundant ligamentous tissue may cause joint irritation and pain and may be secondary to an isolated tear of the anterior talofibular ligament and/or syndesmosis. Adjacent talar or fibular chondromalacia and inflammatory synovitis may be seen in association with these lesions. In some cases, soft-tissue impingement may also be seen along the entire anterolateral gutter and into the syndesmosis. Plain-radiographic studies can appear normal in patients with anterolateral impingement of the ankle. MR imaging can be more useful; it has revealed thickening of the synovium in the anterolateral gutter in almost 40% of patients. However, MR imaging may also give false-negative results. Smaller coils and different planes of imaging are needed to demonstrate impingement abnormalities more clearly. Meyer et al [29] demonstrated the value of high-resolution CT in the diagnosis of chronically painful ankle sprains. They found avulsed intra-articular or juxta-articular fragments of traumatic origin that were not readily apparent on standard radiographs of 13 patients.

A complete course of at least 4 to 6 months of conservative treatment for anterolateral impingement should be completed before arthroscopic debridement is considered. Careful arthroscopic debridement of the inflamed synovium and inflamed capsular or ligamentous tissue may be accomplished with either basket forceps or a power shaver. The cutting blade of the shaver must always be directly viewed, and the mouth of the shaver should never be turned dorsally and anteriorly, where neurovascular structures lie. Care must be taken to preserve the functional remnants of the anterior talofibular ligament. The rehabilitation program should be delayed for 2 to 3 weeks after surgery to avoid inflammation of the joint.

Histologically, moderate synovial hyperplasia with sub-synovial capsular proliferation is seen, which is indicative of chronic synovitis. Hyaline cartilage degenerative changes and fibrosis are also noted in many patients. Good to excellent results have been found in 75% to 90% of patients in whom conservative treatment was a failure [4, 5]. An algorithm has been developed to assist in appropriate treatment for a patient with chronic ankle pain.

4.2. Posterior soft-tissue impingement

Posterolateral impingement may occur in combination with anterolateral impingement. Radiography and MR imaging are often unrevealing. Generalized synovitis, fibrosis, and capsulitis are noted in the posterolateral corner of the ankle joint near the posteroinferior tibiofibular ligament (PITFL). Posterior impingement may occur with hypertrophy or tearing of the PITFL, transverse tibiofibular ligament, tibial slip, or pathologic labrum of the posterior ankle joint. There is a higher incidence of impingement type problems when both the PITFL and the transverse tibiofibular ligament are injured.

The tibial slip, which runs from the posterior talofibular ligament to the transverse ligament, may be a source of posterior soft-tissue impingement. This ligament can undergo hypertrophy and fibrosis after ankle trauma. A torn labrum can cause pathologic posterior impingement in much the same way that the superior labrum of the shoulder can cause impingement.

| Pathology | Example |
|--------------------|---|
| Trigonal process | <ul style="list-style-type: none">• Fracture (acute or chronic)• Synchondrosis injury• True compression |
| FHL dysfunction | <ul style="list-style-type: none">• Tenosynovitis |
| Tibiotalar | <ul style="list-style-type: none">• Posterior capsuloligamentous injury• Osteochondritis• Fracture |
| Subtalar pathology | <ul style="list-style-type: none">• Osteochondritis• Arthritis |
| Other | <ul style="list-style-type: none">• Calcified inflammatory tissue• Prominent calcaneus posterior process |
| Combined | <ul style="list-style-type: none">• FHL tenosynovitis and synchondrosis injury |

Table 2. Etiological Classification of PAIS

Arthroscopic evaluation of all posterolateral lesions is facilitated by use of a distraction device. Views from both the anterior and posterolateral portals should also be obtained. Posterior impingement syndrome can effectively treated by means of a two-portal hindfoot approach with the patient in the prone position. This approach offers excellent access to the posterior ankle compartment, the subtalar joint, and extra-articular structures.

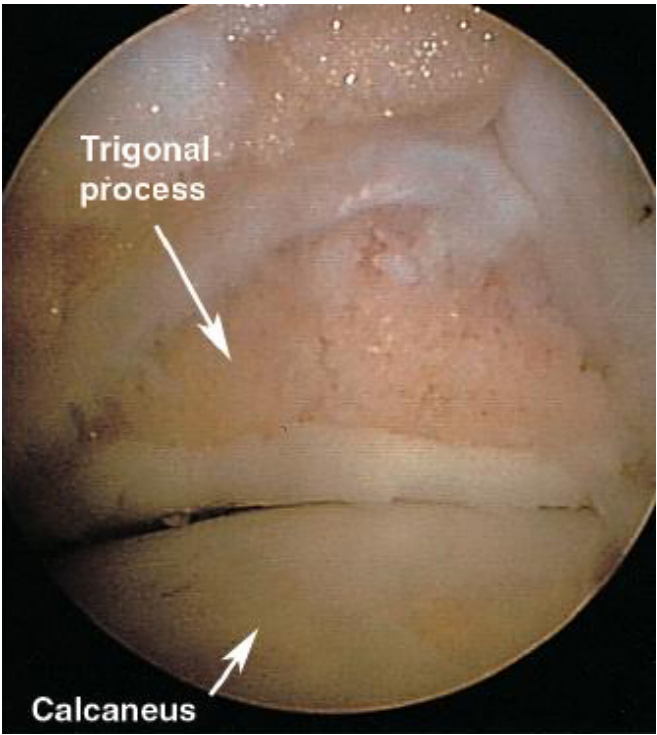


Figure 5. Posterior ankle endoscopy. Posterior ankle view after trigonal process resection.

5. Syndesmotic injury

Close [22] and Inman [23] have shown that normal movement of the ankle depends on a precise relationship determined by the syndesmosis. The talus normally articulates with the ankle mortise throughout the range of movement and the intermalleolar distance increases by approximately 1.5 mm as the ankle goes from plantar flexion to dorsiflexion. If the syndesmosis is disrupted, there may be widening of the tibiofibular joint and lateral shift of the talus. Ogilvie-Harris [11] reported that division of each ligament resulted in progressive weakening of the joint between the tibia and fibula, and Ramsey and Hamilton [24] reported that when the talus moved laterally by 1 mm the contact area of the tibiotalar articulation was decreased by 42%. Furthermore, Burns et al showed that a complete disruption of the syndesmosis combined with a tear of the deltoid ligament caused a decrease of 40% in the tibiotalar contact area and an increase of 36% in the tibiotalar contact pressure. Thus, as large changes may occur after minor ligamentous disruptions, correct diagnosis is essential for the treatment of the injured ankle (Figure 6).

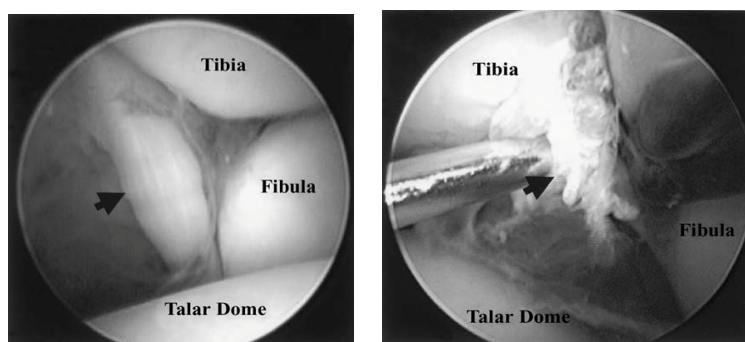


Figure 6. The AITFL. The left figure shows a normal (arrow) and the right a disrupted (arrow) ligament. It is torn in the mid-substance. The arthroscope was inserted through the anteromedial portal

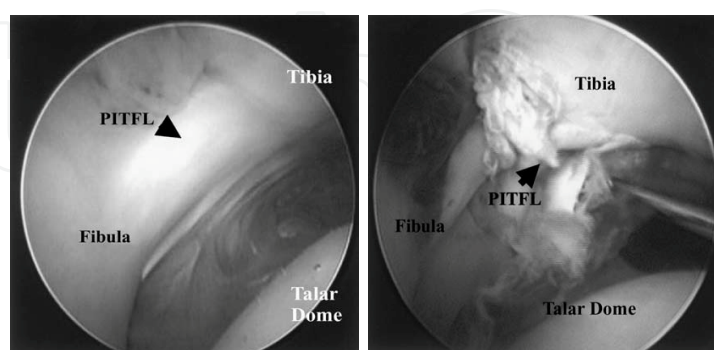


Figure 7. The PITFL. The left figure shows a normal (arrow) and the right a disrupted (arrow) ligament. It is torn from its tibial attachment. The arthroscope was inserted through the anterolateral portal

Syndesmotic injury, however, may be difficult to diagnose by radiological examination when the tears are incomplete or if there is no opening of the distal tibiofibular joint. Litera-

ture shows no definitive diagnostic criteria for MRI to establish incomplete syndesmotic injury, though it is very sensitive (96%) for complete tears.

The anterior tibiofibular ligament is best viewed from the anteromedial and the posterior tibiofibular ligament from the anterolateral portal. A stress test of the distal tibiofibular joint can be performed by moving the ankle from internal rotation to external rotation under arthroscopy. It has been reported that the maximum opening of the distal tibiofibular joint is approximately 1.5 mm in the normal ankle therefore, an opening of 2 mm is considered as instability (Figure 8). The diagnostic criteria for a torn ligament is abnormal course or discontinuity of the ligament, a decrease in its tension, an avulsion at its attachment to the fibula and tibia, and a positive arthroscopic stress test. By direct visualisation of the ligament and probing, arthroscopy of the ankle is an indispensable tool for the accurate diagnosis of a tear of the tibiofibular syndesmosis.

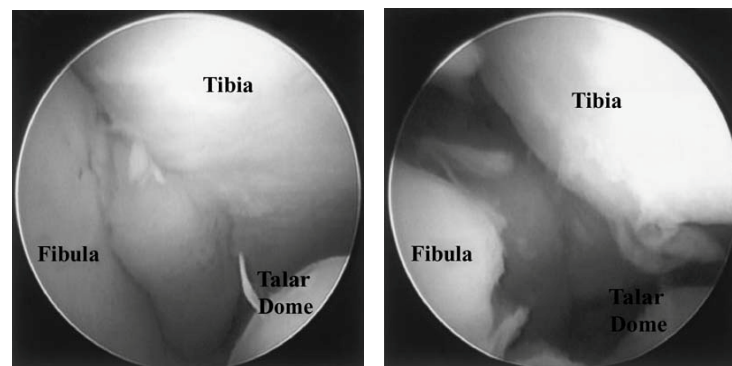


Figure 8. Stress test showing anterior tibiofibular space a) in internal and b) external rotation. The anterior tibiofibular space is widened >2 mm from internal to external rotation.

6. Lateral ankle instability

Joint instability usually coexists with intra-articular symptoms in patients with chronic ankle instability (CAI). Mechanical joint instability results from relaxed or deficient ligaments (ATFL and CFL), and functional instability is caused by weakened proprioception and other neuromuscular abnormalities. The intra-articular symptoms may be due to primary or secondary intra-articular lesions. The basic Broström procedure, which reconstructs lateral ankle stability by overlapping suture of the ATFL, is commonly used for the treatment of CAI. The modified Broström procedure, however, is used to reconstruct joint stability:

1. Tightening of the ATFL and/or CFL
2. Ligament augmentation by use of the extensor retinaculum
3. Use of a piece of periosteum to overlay the remnant of the ligament if the ligament intensity was still inadequate, despite above measures.

These measures improve the ankle stability by maximizing the ligament intensity and tension. Although the modified Broström procedure can improve ankle stability, it does not resolve the intraarticular lesions associated with CAI. The presence of accompanying intra-articular lesions might, therefore, result in a poor outcome [25]. DiGiovanni et al [27] suggested that opening inspection and management of the intra-articular lesions, in addition to the ligament reconstruction, improved the surgical outcome. However, open inspection increases surgical trauma and has been reported to only allow exploration of 20% of intra-articular lesions, as compared with those found by arthroscopy [26]. The modified Broström procedure combined with ankle arthroscopy produced significantly better surgical outcomes in patients with CAI accompanied by intra-articular symptoms.

7. Osteochondral lesion

Conservative treatment is usually advocated for grade A and grade B lesions (Ferkel- Cheng Arthroscopic Grading System: Table 3). This should include 6 to 12 weeks of casting, with the length determined by the size of the lesion. There is no good evidence that non-weight bearing in a cast is any better than weight bearing; therefore, it is not advocated. If the patient is still symptomatic after a conservative program, surgical treatment is suggested.

| Grade | Arthroscopic Appearance |
|-------|--|
| A | Smooth and intact, but soft or ballottable |
| B | Rough surface |
| C | Fibrillations or fissures |
| D | Flap present or bone exposed |
| E | Loose, non-displaced fragment |
| F | Displaced fragment |

Table 3. Ferkel-Cheng Arthroscopic Grading System for Osteochondral Lesions of the Talus

Surgery is advocated for all symptomatic stage III and IV lesions, except in children whose growth plates have not closed at the distal tibial and fibular epiphyses. In these cases, initial conservative treatment with casting is recommended before surgical intervention.

Arthroscopic treatment is based on the location and extent of osteochondral injury and on whether the lesion is acute or chronic (Figure 9). For acute lesions, CT or MR imaging may be utilized to further visualize the appearance and radiologic stage. If an acute lesion is displaced, arthroscopy should be done immediately. If the lesion is primarily chondral, excision is recommended, with subsequent debridement and drilling of the base to promote formation of a fibrocartilaginous surface. Generally, drilling techniques are recommended for lesions greater than 1 cm, whereas abrasion may be adequate for smaller lesions. If the

chondral fragment has enough underlying bone, the piece should be reattached with absorbable pins, Kirschner wires, or Herbert screws by means of arthroscopy.

Chronic osteochondral lesions should be carefully assessed for size, location, and stability. If the lesion is not loose, transmalleolar or transtalar drilling can be accomplished. If the lesion is loose and the articular cartilage is healthy, fixation can be accomplished with absorbable pins, Kirschner wires, or screws. Most commonly, chronic lesions are loose, nonviable, and occasionally displaced and must be excised. After excision, curettage and abrasion or drilling is done.

For medial osteochondral lesions, a small-joint drill guide is inserted through the anteromedial portal, and a small puncture is made over the medial malleolus. A 0.062-mm Kirschner wire is then used to perform transmalleolar drilling into the medial aspect of the talar dome at approximately 3- to 5-mm intervals to a depth of approximately 10 mm. After drilling or abrasion, the tourniquet is released, so that the bleeding talar bed can be viewed. Postoperatively, a bulky compression dressing is applied, with a posterior splint holding the ankle in neutral position. Early range-of-motion exercises are begun at approximately 1 week, but weight bearing is delayed 4 to 8 weeks, depending on the size of the lesion

Ferkel et al. showed in his study with an average follow-up of 40 months, and found that good to excellent results were achieved in 84%. Results are worse when preexisting arthritis is present. When the results of open treatment are compared with those of arthroscopic treatment, the outcomes yielded with the latter are equally good or better.

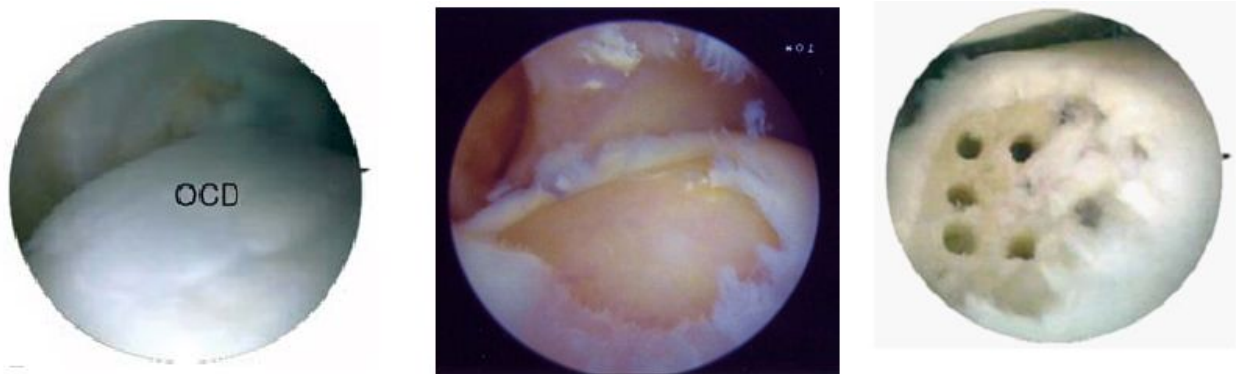


Figure 9. Osteoarthritis (OCD): Talus before and after drilling

8. Ankle fusion

The principles of arthroscopic ankle arthrodesis are similar to those of open arthrodesis. This includes debridement of all hyaline cartilage and underlying avascular subchondral bone from the talus, tibial plafond, and medial and lateral gutters; reduction in an appropriate position for fusion; and rigid internal fixation. During debridement, care should be taken

to maintain the normal bone contour of the talar dome and the tibial plafond (i.e., talar convexity and tibial concavity).

It is critical not to remove too much bone and not to square off the tibiotalar surfaces, which could lead to a varus/valgus deformity and delayed union. The use of hand-held ring-and-cup curettes, shavers, and burrs is essential. In addition, the debridement process involves removal of the usually large anterior “lip osteophyte” so that it will not block reduction of the talar dome convexity into the concavity of the tibial plafond. Occasionally, the anterior capsule adheres to the osteophyte, and great caution must be exercised in peeling the capsule off the anterior distal tibia, so as not to injure the neurovascular structures. Fixation is usually accomplished with insertion of percutaneous transarticular 6.5- or 7.0-mm cannulated screws through the medial and lateral malleoli or two screws through the medial malleolus. Occasionally, three screws are required to secure fixation, especially if there is osteoporotic bone. External compression frames can also be used. Rarely is an anterior or posterior screw needed (Figure 10).

The disadvantages of arthroscopic arthrodesis include a difficult learning curve for the surgeon, the expense of arthroscopic equipment, and the inability to correct significant varus, valgus, and rotational problems. Another potential disadvantage of the arthroscopic technique is that it makes posterior displacement of the talus difficult.

There is a decreased time to union. This is probably because periosteal stripping was not necessary and therefore the local circulation is intact. Following arthroscopic fusion, the mean time for union may be as short as approximately 8 weeks. Some studies have found that the procedure can be done as an outpatient/overnight stay. Compared with open fusion, arthroscopic ankle arthrodesis appears to offer similar or better overall results in selected patients. The technique is particularly appealing in elderly patients and in patients with rheumatoid arthritis who are unable to tolerate prolonged non-weight-bearing postoperatively.

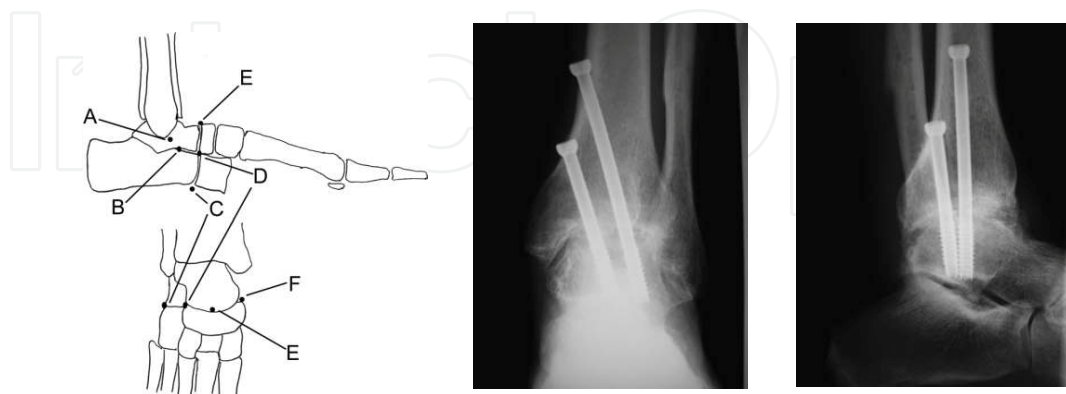


Figure 10. Arthroscopic triple arthrodesis: Subtalar arthrodesis is performed through the (A) middle and (B) anterolateral portals. Calcaneocuboid arthrodesis is performed through the (C) lateral and (D) dorsolateral portals. Talonavicular arthrodesis is performed through the dorsolateral, (E) dorsomedial, and (F) medial portals. Plain radiographs 12 weeks post operative.

9. Technique for ankle arthroscopy

An understanding of the surface and intra-articular anatomy of the ankle region is essential to the successful performance of arthroscopy of the ankle. The superficial anatomy serves as a guide to the successful placement of arthroscopic portals in the ankle [13]. The neurovascular and tendinous structures are most at risk. Before portal placement, a skin marker is used to mark important anatomic landmarks, including the joint line, the dorsalis pedis artery, the greater saphenous vein, the tibialis anterior tendon, and the peroneus tertius tendon. The superficial peroneal nerve and its branches should be identified, if possible, because of their proximity to the anterolateral portal. These branches frequently can be seen, as they are pulled taut beneath the skin when the fourth toe is grasped and the forefoot is pulled into plantar flexion and adduction.

10. Setup and instrumentation

Arthroscopy of the ankle may be performed with general, regional, or local anaesthesia. The position of the patient may also vary, depending on the surgeon's preference. Supine placement of the patient is preferred, with the hip flexed 45 to 50 degrees on a non-sterile thigh holder. This supports the thigh proximal to the popliteal fossa. Adequate padding is added to avoid injury to the sciatic nerve [13]. An alternative method includes flexion of the knee over the end of the operating table with the patient supine. This permits some distraction by gravity and by an assistant. However, access to posterior portals is somewhat difficult with this technique [14].

Positioning the patient in the lateral decubitus position, with the body supported by a beanbag & kidney rest and tilted posteriorly, has also been described [15]. This technique does not require the use of a thigh or ankle holder. For anterior portals, the ipsilateral hip is rotated externally; for posterolateral a portal, the hip is rotated internally [16]. Guhl [17] described the technique of placing the supine patient's ipsilateral hip & knee on a padded support. The foot and ankle are secured to an ankle holder, & a mechanical ankle distractor is used. A tourniquet may be used.

11. Ankle distraction

The decision to perform invasive or non-invasive distraction generally is made at the time of surgery and depends on both the laxity of the ankle joint and the location of the pathologic tissue that is to be addressed. With invasive distraction, a tibial pin and a talar or calcaneal pin are placed from the medial or lateral side with a mechanical distractor device. Non-invasive distractors include a clove-hitch-type device wrapped over the anterior aspect of the mid-foot & the posterior aspect of the heel (Figure. 11).

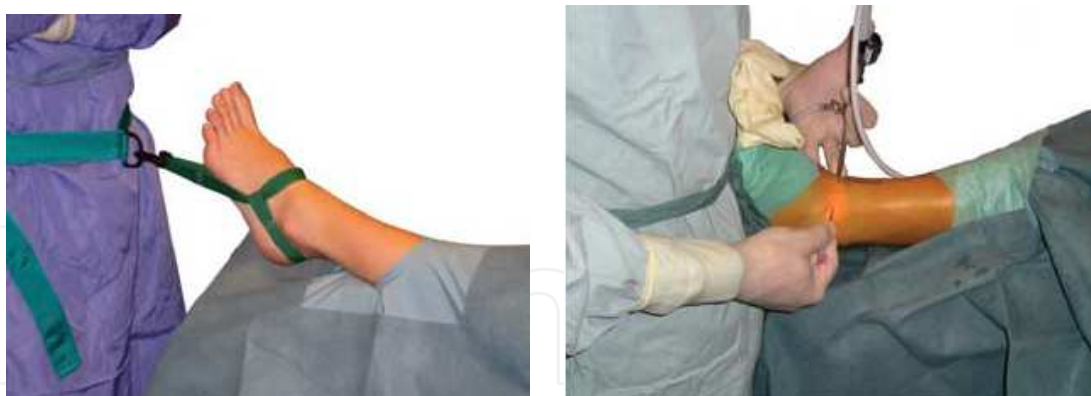

Figure 11. A resterilizable distraction device, which permits the surgeon to move the ankle quickly from the dorsiflexed position to the distracted position and vice versa.

12. Portal placement

Before portal placement, the ankle joint should be distended with 10 to 15 ml of lactated Ringer's solution injected into the ankle joint medial to the tibialis anterior tendon with the use of an 18- to 20-gauge needle. This injection also helps to establish the exact location of the anteromedial portal. Care should be taken to avoid directing the needle either too far anteriorly or too far posteriorly in the ankle joint. To prevent injury to neurovascular structures, the incisions for the portals should be made vertically and through the skin only. The deeper layers should be penetrated with a mosquito clamp followed by a blunt obturator, not with a sharp knife or a trocar. The anterolateral, anteromedial, and posterolateral portals are most commonly used. In a recent anatomic study [19] they were found to be the safest areas for portal placement, allowing no penetration of neurovascular structures.

12.1. Anteromedial portal

This is made just medial to the tendon of the tibialis anterior at, and just proximal to, the joint line (Figure 12, A). This portal is made first because it is easy to establish and is located in a region devoid of any major neurovascular structures. With the use of a blunt trocar, the arthroscope is carefully introduced into the joint. The portal is, on average, 9 mm lateral to the greater saphenous vein and 7.4 mm lateral to the greater saphenous nerve [3].

12.2. Anterolateral portal

The anterolateral portal is used for placement of the inflow cannula and is established under direct visualization with the use of a 25-gauge 1.5-inch needle. It is usually made just lateral to the tendon of the peroneus tertius at, or just proximal to, the level of the joint line. However, its location is also determined on the basis of the type and location of the pathologic tissue. This portal can sometimes be determined more easily by transilluminating the skin with the arthroscope to assist in the avoidance of neurovascular structures and tendons. The

branches of the superficial peroneal nerve are most at risk. The mean distance of the anterolateral portal from the intermediate branch of the superficial peroneal nerve is 6.2 mm (range, 0 to 24 mm) [19].

12.3. Anterocentral portal

This may be created between the tendons of the extensor digitorum communis, at the level of the joint or proximal to the joint line. Care must be taken to avoid injury to the dorsalis pedis artery and the deep branch of the peroneal nerve, which lies between the extensor hallucis longus tendon and the medial border of the extensor digitorum communis tendon. Use of this portal is discouraged because of the inherent risk of neurovascular injury. Feiwell and Frey [19] found that the average distance (in either direction) of the portal from the artery, vein, and nerve is 3.3 mm (range, 0 to 10 mm).

12.4. Posterolateral portal

This is established just lateral to the Achilles tendon, approximately 1.0 to 1.5 cm proximal to the distal tip of the fibula (Figure 12, B). The portal can be made under direct visualization by placing the arthroscope from the anteromedial portal through the *notch of Harty*, looking posteriorly. An 18-gauge spinal needle is inserted just lateral to the Achilles tendon at a 45-degree angle toward the medial malleolus. The posterior aspect of the capsule is usually punctured just medial to the transverse tibio-fibular ligament.

An alternative for placement of the posterolateral portal is to place a switching stick (a smooth metal rod) from the anteromedial portal. The switching stick is inserted through the capsule, and the cannula is placed over the rod through the posterolateral portal. This can be done only with marked distraction of the joint. If the joint is not distracted sufficiently, this portal may be established too far proximally. The lesser saphenous vein and the sural nerve are at risk in establishing this portal. These two structures run parallel to each other along the posterolateral aspect of the ankle joint, an average of 3.5 mm apart. The sural nerve is consistently posterior to the lesser saphenous vein. On average, the posterolateral portal is 6 mm (range, 0 to 12 mm) posterior to the sural nerve and 9.5 mm (range, 2 to 18 mm) posterior to the lesser saphenous vein [19].

12.5. Postero-central portal

This portal is made just below the joint line through the middle of the Achilles tendon. This portal is not recommended because of its limitations and potential associated morbidity.

12.6. Posteromedial portal

This is generally contraindicated because of the proximity of the posterior tibial artery and nerve. The flexor hallucis and flexor digitorum longus tendons are also at risk, along with branches of the calcaneal nerve.

12.7. Transmalleolar portal

This portal may be necessary to drill osteochondral lesions of the talus. These portals are made by creating small incisions over the medial or lateral malleolus. A small-joint drill guide is helpful in directing the tip of the Kirschner wire to the lesion. Transtalar portals can be used by drilling from the sinus tarsi or the medial talus.

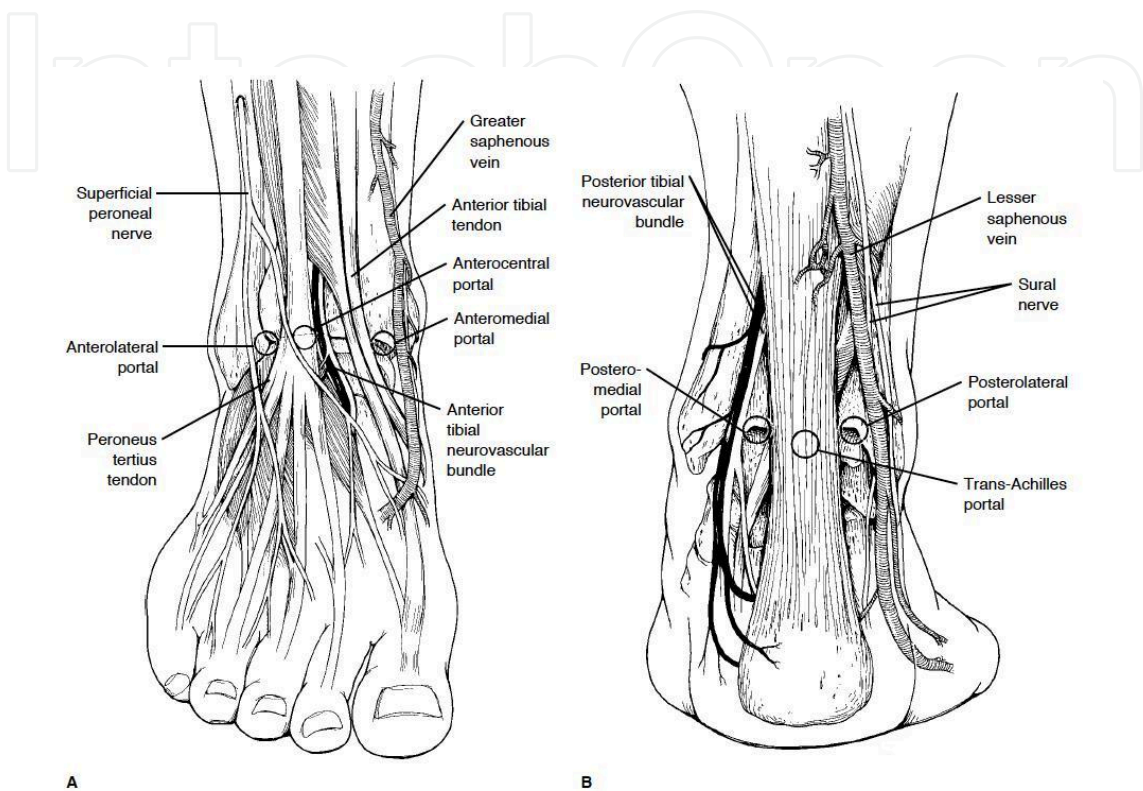


Figure 12. **A**, Location of the anteromedial, anterolateral, and anteroportal portals. The central portal should be avoided. **B**, The posterolateral portal is established just lateral to the Achilles tendon.

13. Arthroscopic examination

A 21-point arthroscopic examination enables the surgeon to perform a thorough, systematic evaluation of all areas of the ankle (Table 4) [20]. The use of this system allows reproducible documentation of the arthroscopic findings and accurate diagnosis of any intra-articular pathologic changes. In addition, it guarantees that all areas of the ankle joint are carefully inspected and provides a complete videotape record that can be reviewed in the future for both patient care and clinical studies of the patient population undergoing ankle arthroscopy.

The arthroscopic examination is always done initially through the anteromedial portal and subsequently through the anterolateral and posterolateral portals (Figure 13). Occasionally, one can slip out of the posterior capsule just enough to look down the sheath of the flexor

hallucis longus tendon as it runs in its groove on the posterior talus. Extreme caution is necessary to avoid injury to this structure.

| Anterior | Central | Posterior |
|--|--|-------------------------------------|
| Deltoid ligament | Medial tibia and talus | Posteromedial gutter |
| Medial gutter | Central tibia and talus | Posteromedial talus |
| Medial talus | Lateral tibiofibular or talofibular articulation | Posterocentral talus |
| Central talus & overhang | Posterior inferior TFL | Posterolateral talus |
| Lateral talus | Transverse ligament | Posterior talo-fibular articulation |
| Trifurcation of the tibia/ talus/ fibula | Reflection of the flexor hallucis longus | Posterolateral gutter |
| Lateral gutter | | Posterior gutter |
| Anterior gutter | | |

Table 4. 21-Point Arthroscopic Examination of the Ankle

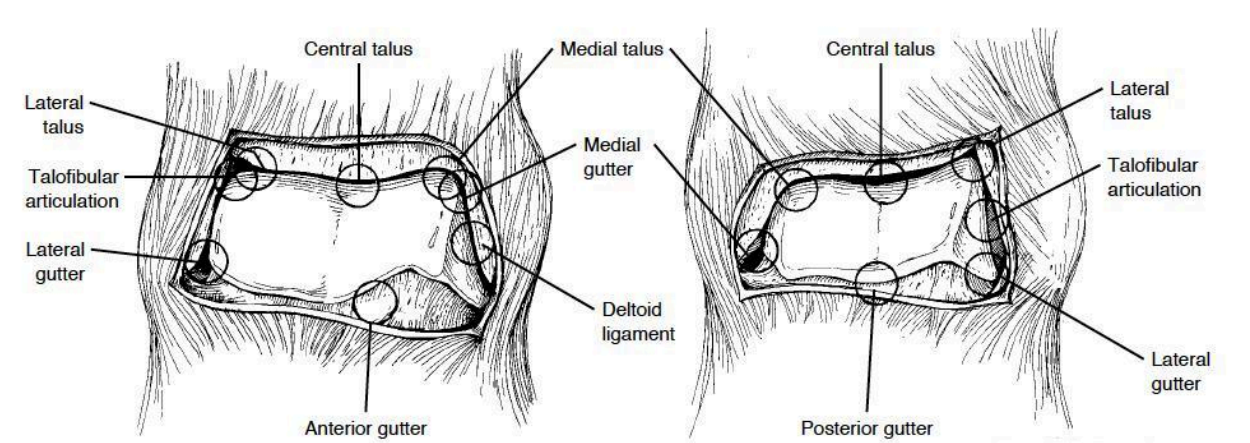


Figure 13. Left, The eight-point anterior examination of the ankle through the arthroscope. Right, The seven-point posterior examination

14. Complications

There are many potential complications with ankle arthroscopy (Table 4). Most can be avoided if the surgeon becomes thoroughly familiar with the surface anatomy of the region. Careful preoperative planning and the use of appropriate distraction and instrumentation techniques also help in avoiding complications.

In a series of 612 cases, Ferkel et al [21] found an overall complication rate of 9%. Neurologic complications were the most common (49%). In the 27 instances of neurologic injury, the su-

perforial branch of the peroneal nerve was involved in 15 (56%); the sural nerve in 6 (22%); the greater saphenous nerve in 5 (18%); and the deep peroneal nerve in 1 (4%). In the same study, Ferkel et al also reported neurologic and arterial damage with the use of the antero-central or posteromedial portal, as well as with the use of distraction pins. The invasive distractor was used in 317 of 612 cases. Distraction pins were associated with some transient pin-tract pain, which resolved in all cases. No ligament injuries occurred in the ankle, but two stress fractures in the tibia occurred early in the series, when the pins were placed too far anteriorly or posteriorly in the tibia. One stress fracture occurred when the pin was placed in the fibula.

Ferkel et al also found superficial wound infection in six patients, which appeared to be related to the closeness of portal placement, the type of cannula used, early mobilization, and the use of tapes to close the portals. Deep wound infection occurred in two patients and was correlated with a lack of preoperative antibiotic therapy. Other complications included instrument failure, ligament injury, and incisional pain (two cases of each). Increased experience of the surgeon was associated with a lower complication rate. Compartment syndrome has not been reported in association with ankle arthroscopy. Some fluid extravasation occurs in all cases. The thinness of the skin and the lack of subcutaneous tissues around the ankle joint make postoperative swelling common. This usually responds well to elevation, compression, and application of ice. Thrombophlebitis and reflex sympathetic dystrophy can occur postoperatively, as they can after all operative procedures.

Overall, complications can be avoided by careful preoperative planning, meticulous surgical technique, the use of suitable small-joint instrumentation, and appropriate postoperative care (Table 5). It is mandatory to have a thorough understanding of the intra and extra-articular anatomy of the ankle and foot. In addition, practicing on plastic bone models and cadaver specimens can be particularly helpful in developing experience with small joint instrumentation and surgical procedures.

| | |
|------------------------------|--|
| • Missed diagnosis | • Haemarthrosis |
| • Tourniquet complications | • Postoperative effusion |
| • Neurovascular injury | • Reflex sympathetic dystrophy |
| • Tendon injury | • Fluid-management complications |
| • Ligament injury | • Distraction-related complications (E.g., skin necrosis, pin problems) |
| • Wound complications | |
| • Infection | • Intra-operative fracture |
| • Articular cartilage damage | • Postoperative stress fracture |
| • Compartment ischemia | • Instrument breakage |
| • Compartment syndrome | |

Table 5. Potential Complications of Ankle Arthroscopy.

15. Conclusion

Orthopaedic surgeons are always searching for ways to improve on current methods so as to provide maximal benefit for each intervention while minimizing its impact. Such benefits have been anticipated with ankle arthroscopy and in some instances have been realized. Compared with open arthrotomy, arthroscopy has the potential to shorten recovery times and limit surgical morbidity.

When used for the appropriate indications, ankle arthroscopy appears to give a high percentage of good results. Further refinement of techniques is necessary, and long-term comparative studies are needed to fully evaluate the efficacy of certain treatment protocols. Ankle arthroscopy should not replace a careful history and physical examination, an appropriate diagnostic workup, and a regimen of conservative therapy. The scope of arthroscopy and endoscopy of the foot and ankle is expanding. With sound knowledge regarding the indications, merits, and potential risks of new techniques, they will be powerful tools in foot and ankle surgery.

Author details

Jami Ilyas

Department of Orthopaedics, Royal Perth Hospital, Perth. Western Australia, Australia

References

- [1] Burman MS. Arthroscopy of direct visualization of joints. An experimental cadaver study. *J Bone Joint Surg* 1931;13:669- 695.
- [2] Watanabe M. Selfoc-Arthroscope (Watanabe no. 24 arthroscope). Monograph. Tokyo: Teishin Hospital, 1972.
- [3] Feder KS, Schonholtz GJ: Ankle arthroscopy: Review and long-term results. *Foot Ankle* 1992; 13:382-385.
- [4] Ferkel RD, Karzel RP, Del Pizzo W, et al: Arthroscopic treatment of anterolateral impingement of the ankle. *Am J Sports Med* 1991; 19:440-446.
- [5] Liu SH, Raskin A, Osti L, et al: Arthroscopic treatment of anterolateral ankle impingement. *Arthroscopy* 1994; 10:215-218.
- [6] Scranton PE Jr, McDermott JE: Anterior tibiotalar spurs: A comparison of open versus arthroscopic debridement. *Foot Ankle* 1992; 13:125-129.
- [7] Ogilvie-Harris DJ, Mahomed N, Demazire A: Anterior impingement of the ankle treated by arthroscopic removal of bony spurs. *JBJS Br* 1993; 75:437-440.

- [8] Ferkel RD, Scranton PE Jr: Arthroscopy of the ankle and foot. *J Bone Joint Surg Am* 1993; 75:1233-1242.
- [9] Loomer R, Fisher C, Lloyd-Smith R, et al: Osteochondral lesions of the talus. *Am J Sports Med* 1993; 21:13-19.
- [10] Myerson MS, Quill G: Ankle arthrodesis: A comparison of an arthroscopic and an open method of treatment. *Clin Orthop* 1991; 268:84-95.
- [11] Ogilvie-Harris DJ, Lieberman I, Fitsialos D: Arthroscopically assisted arthrodesis for osteoarthrotic ankles. *J Bone Joint Surg Am* 1993; 75:1167-1174.
- [12] Parisien JS, Shaffer B: Arthroscopic management of pyarthrosis. *Clin Orthop* 1992; 275:243-247.
- [13] Ferkel RD: Arthroscopy of the ankle and foot, in Mann RA, Coughlin MJ (eds): *Surgery of the Foot and Ankle*, 6th ed. St Louis: Mosby, 1993, vol 2, pp 1277-1310.
- [14] Andrews JR, Previte WJ, Carson WG: Arthroscopy of the ankle: Technique and normal anatomy. *Foot Ankle* 1985; 6:29-33.
- [15] Parisien JS, Vangsness T: Operative arthroscopy of the ankle: Three years' experience. *Clin Orthop* 1985; 199:46-53.
- [16] Parisien JS: Arthroscopic treatment of osteochondral lesions of the talus. *Am J Sports Med* 1986; 14:211-217.
- [17] Guhl JF: *Foot and Ankle Arthroscopy*, 2nd ed. Thorofare, NJ: Charles B. Slack, 1993.
- [18] Yates CK, Grana WA: A simple distraction technique for ankle arthroscopy. *Arthroscopy* 1988; 4:103-105.
- [19] Feiwell LA, Frey C: Anatomic study of arthroscopic portal sites of the ankle. *Foot Ankle* 1993; 14:142-147.
- [20] Ferkel RD: *Arthroscopic Surgery: The Foot and Ankle*. Philadelphia: Lippincott- Raven (in press).
- [21] Ferkel RD, Guhl JF, Heath DD: Neurological complications of ankle arthroscopy: A review of 612 cases. Presented at the 13th Annual Meeting of the Arthroscopy Association of North America, Orlando, Fla, April 29, 1994.
- [22] Close JR. Some applications of the functional anatomy of the ankle joint. *J Bone Joint Surg [Am]* 1987; 69-A: 596-604.
- [23] Inman VT. *The joint of the ankle*. Baltimore: Williams and Wilkins, 1976.
- [24] Ramsey PL, Hamilton W. Changes in tibiotalar area of contact caused by lateral talar shift. *J Bone Joint Surg [Am]* 1976; 58-A: 356-7.
- [25] Choi WJ, Lee JW, Han SH, et al. Chronic lateral ankle instability: The effect of intra-articular lesions on clinical outcome. *Am J Sports Med* 2008; 36: 2167-2172.

- [26] Ferkel RD, Chams RN. Chronic lateral instability: Arthroscopic findings and long-term results. *Foot Ankle Int* 2007; 28: 24-31
- [27] DiGiovanni BF, Fraga CJ, Cohen BE, et al. Associated injuries found in chronic lateral instability. *Foot Ankle Int* 2000; 21: 809-815.
- [28] Parisien JS, Shaffer B: Arthroscopic management of pyarthrosis. *Clin Orthop* 992; 275: 243-247.
- [29] Meyer JM, Hoffmeyer P, Savoy X: High resolution computed tomography in the Chronically painful ankle sprain. *Foot Ankle* 1988; 8:291-296.
- [30] Stetson & Ferkel, *Ankle Arthroscopy: Indications & Results*. *J Am Acad Ortho Surg* 1996;4:24-34

