

We are IntechOpen, the world's leading publisher of Open Access books Built by scientists, for scientists

6,900

Open access books available

186,000

International authors and editors

200M

Downloads

Our authors are among the

154

Countries delivered to

TOP 1%

most cited scientists

12.2%

Contributors from top 500 universities



WEB OF SCIENCE™

Selection of our books indexed in the Book Citation Index
in Web of Science™ Core Collection (BKCI)

Interested in publishing with us?
Contact book.department@intechopen.com

Numbers displayed above are based on latest data collected.
For more information visit www.intechopen.com



Immunopathophysiology of Large Vessel Involvement in Giant Cell Arteritis – Implications on Disease Phenotype and Response to Treatment

Panagiota Boura, Konstantinos Tselios,
Ioannis Gkougkourelas and
Alexandros Sarantopoulos

Additional information is available at the end of the chapter

<http://dx.doi.org/10.5772/55222>

1. Introduction

Giant cell arteritis (GCA) or temporal arteritis or Horton's disease is classified amongst the primary large-vessel vasculitides, according to the 2012 revision of the Chapel-Hill classification criteria. The disease develops almost exclusively in patients older than 50 years (prevalence of 1 in 500 individuals in this age spectrum) and represents the most common vasculitis in Western countries. [1] Incidence rates are progressively increased and estimated to range between 10-30 new cases per 100000 persons beyond the age of 50, while the highest frequency is reported in Scandinavian and North American populations. [2]

The disease affects, mainly, the large- and medium-sized extracranial branches of the carotid artery and, classical clinical features, such as headache, jaw claudication, scalp tenderness and visual impairment, are closely related to this marked cranial tropism of GCA. [3]

On a histopathological basis, GCA involves all layers of the arterial wall, including the adventitia. Inflammatory lesions consist of activated T cells, dendritic cells (DCs) and macrophages. These lesions are believed to be the histopathologic hallmark of GCA and are characterized by a predominance of mononuclear infiltrates or granulomas, usually with multinucleated giant cells. [4]

Besides the inflammation of the carotid branches, involvement of the great arteries, such as the aorta and its main tributaries, was initially recognized in the late 1930s and reported sporadically thereafter in necropsy or histopathologic studies of surgically resected tissues. [5,

6] The prevalence of aortic inflammation, in unselected patients with GCA, has not been fully estimated, although in a systematic necropsy study of 13 patients, large artery involvement was demonstrated in over 90% of them. [7] In more recent studies, an increased prevalence of aortic aneurysm (compared to the general population), was observed in GCA patients. [8]

Retrospective surveys, over extended time periods (20-50 years), confirmed that aortic aneurysm occurs in 9.5-22.5% of these patients and, particularly, in the first 5 years of follow up. [9, 10] These findings indicate that large vessel involvement in GCA may be more frequent than anticipated. Based on these data, a recent prospective study from Prieto-Gonzalez et al, using non-invasive techniques (CT angiography), concluded that large vessel vasculitis occurs in two thirds of patients with GCA, while aortic dilatation is already present in 15% of them at the time of diagnosis. [11]

Large vessel involvement represents a significant cause of death in GCA and it may be asymptomatic and lead to aortic dissection and/or rupture. [12] These findings underline the importance of elucidating the pathophysiologic basis of the disease, in which the immune system seems to play a central role.

In this chapter, a thorough review of the current evidence for disease immunopathophysiology, in regard to disease phenotype and response to treatment, is presented.

2. The pathophysiologic basis of GCA

In accordance with the pathophysiology of many immune-mediated diseases, GCA is believed to represent the final result of the complex interactions between three distinct factors, namely the host (by means of the individual genetic background), the environment (pathogens, physicochemical exposures etc.) and the unique immune system response. However, the exact etiology of the disease remains unknown.

3. Genetic predisposition

Several studies have demonstrated that GCA is a complex disease, where multiple genes confer susceptibility. In most surveys, the allele HLA-DRB1*04 has been shown to be related to disease and its severity. [13] More recent studies have implied the role of genetic variants in the evolution of the immune and inflammatory pathways in GCA and its clinical expression. Polymorphisms include the rs20541 (R130Q) polymorphism of the IL-13 gene [14], the rs2779251 in the NOS2 gene, the rs1885657 and the rs2010963 in the VEGF gene [15] and, also, the TLR-4 (+896A/G) gene. [16]

4. Environmental factors

Several experimental studies, using DNA analysis, have shown a possible relation of GCA with certain infectious agents, such as the human papilloma virus (HPV) [17], *Chlamydia spp*, herpes viruses and PARVO B19 among others. [18] Older epidemiological studies have also demonstrated that increased incidence of GCA was observed in close relation to two independent epidemics of *Mycoplasma pneumoniae* infection. [19] However, not all studies confirmed these associations and GCA initiation is not definitely considered to be triggered by infectious agents. [20]

5. The immune system in GCA

Although evidence regarding the genetic background of GCA and the possible influence of external factors, such as viruses and bacteria, have not elucidated disease pathogenesis, it is now well understood that the immune system plays a central role in the disease process. GCA is a complex systematic disorder and it is believed to represent the result of the breakdown of immunologic tolerance, resulting from interactions between the immune system and poorly defined components of the arterial wall.

A single triggering factor, initiating the inflammatory process, has not been yet identified. The initial insult may lead to a foreign-body giant cell attack on calcified internal elastic membrane in arteries and calcified atrophic parts of the medium layer of the aorta. [21] The prerequisite for a calcified artery explains why GCA almost exclusively occurs in older people.

Recent studies have raised the possibility that, in GCA, both the innate and the adaptive arms of the immune system are activated and may lead to vessel wall injury through, at least two, distinct pathophysiological mechanisms. [22]

6. Innate immunity abnormalities in GCA

Immune responses are initiated by the recognition of foreign molecular structures, such as invading pathogens, by the antigen presenting cells (APCs) of the innate immune system. Tissue macrophages and dendritic cells (DCs) represent the main classes of professional APCs and are characterized by the membrane expression of germ-line receptors (pattern recognition receptors, PRRs). These receptors are able to recognize specific molecular patterns of exogenous and/or endogenous foreign proteins, known as pathogen associated molecular patterns (PAMPs) and damage associated molecular patterns (DAMPs).

Upon recognition of a certain PAMP or DAMP, dendritic cells become differentiated and activated and produce cytokines, which are able to recruit neutrophils and macrophages,

activate the adaptive immune system and trigger the complement cascade. The physiological goal of early innate immune response is to control and demarcate infection and prevent microbe spreading and further tissue damage.

Recently, DCs were shown to initiate the immune response in GCA. [23] These cells lay dormant, in a ring-like structure around the adventitia-media border. It is suggested that, in normal arteries, DCs are sentinels that form a part of the first line immune defense of the vessel wall. [24]

The population of the immune cells in the adventitia of the large-vessel wall is mainly consisted of immature myeloid DCs, with a characteristically high threshold of activation. [25] In contrast to mature APCs that induce adaptive immunity, immature DCs do not express co-stimulatory molecules on their surface, such as CD80 and CD86. This condition is primarily responsible for maintaining an anergic state for T cells. In normal arteries, immature APCs are tolerogenic, thus supporting T-cell unresponsiveness. [21] They have been found to be positive for the S-100 protein and express the chemokine receptor CCR6. [26] As guardians of the immunoprivileged arterial wall, DCs are committed to protect the structural integrity of these vital and non-regenerative tissue structures.

However, in susceptible individuals, such as those bearing the HLA-DR4 allele or in older persons (immune-aging), an unknown instigator or a persistent stimulus activates DCs and initiates an innate immune response. In this context, certain antigens (derived from pathogens or locally formatted by tissue calcification) are considered to infiltrate the vessel wall adventitia, through vasa vasorum, and activate immature DCs.

Physiologically, dendritic cells subsequently migrate to the local lymph nodes and clear the antigens, without triggering inflammation. [26] In GCA, however, for yet ill-defined reasons, the activated DCs remain *in situ* and mature in the vessel wall. [27] Existing evidence supports that the maturation of DCs is a very early step in the initiation of the vasculitic process and occurs long before the chronic phase of wall inflammation. In biopsy studies from patients with polymyalgia rheumatica (PMR), mature DCs, already expressing co-stimulatory molecules, were found in their temporal arteries, despite the absence of any clinically apparent sign of inflammation. [25] These observations are closely correlated with the fact that a great proportion of PMR patients will eventually develop giant cell arteritis.

The principal role of DCs in GCA pathogenesis lies, not only in initiating the inflammatory process, but, also, in perpetuating immune reactions. Dendritic cells, found in vasculitic lesions, are able to produce high amounts of IL-12 and IL-18 and up-regulate the release of IFN- γ from T cells. [22] In addition, dendritic cells, in inflamed arteries, can release the homing chemokines CCL19 and CCL21, which bind to the receptor CCR7. The expression of CCR7 results in the local arrest of activated DCs, which are no longer able to leave the tissue. Instead, they are trapped in the arterial wall and enforce an aberrant T-cell response. [28] Furthermore,

it has been shown that DCs' depletion abrogates vasculitis, thus confirming the critical role of activated DCs in sustaining wall inflammation. [29]

The activation of vascular DCs is mediated via the ligation of their TLRs. It has been shown that certain infectious agents are able to ligate to specific Toll-like receptors, such as TLR-4 (LPS) or TLR-5 (flagellin). The ligation of a PAMP (or DAMP), such as LPS or flagellin, to the extracellular portion of the TLR provokes the activation of the intracellular TRAM motif and the consequent activation of an intracellular phosphorylation cascade (second message). The final result is the activation of the NfKB , which enters the nucleus and induces certain genes. This mechanism leads to the translation of pro-inflammatory molecules with autocrine or paracrine actions, expression of co-stimulatory receptors on cell surface and production of antimicrobial substances. [26]

Additional research, in regard to the role of TLRs in GCA pathogenesis, led to some very interesting results. It is well known that GCA shows an impressive, yet unexplained, predilection for specific sites of the vasculature, such as the 2nd to 5th aortic branches. [1] Histopathologic studies demonstrated that DCs express different type of TLRs in different arteries. [30]

The distribution of TLRs in the vessel wall is highly determined by the embryological origin of the tissue. The aortic arch and its branches derive from the ectoderma, whereas the descending aorta derives from mesodermal cells. The heterogeneity of the immune response in GCA is believed to be strongly influenced by the specific type of TLRs, whose expression varies in the different blood vessels. Indeed, in an experimental study, Pryshchep et al showed that the distribution of TLRs, in various sites of the vascular tree, determine the extent and profile of the inflammatory reactions. [30] DCs, with differential surface expression of TLRs, display a marked heterogeneity in their immune-regulatory functions, providing a possible clue toward the tissue tropism of GCA. Furthermore, the immunological identity of blood vessels, as defined by the expression of a vessel-specific profile of TLRs, has been considered to determine the nature of the inflammatory reaction in various types of vasculitides. [21]

In this context, it has been shown that TLR-4, abundantly expressed on adventitial DCs, recognize LPS from bacterial pathogens. Upon recognition, $\text{IFN-}\gamma$ is produced in large amounts and leads the subsequent mononuclear infiltration in all layers of the arterial wall. This all-layer inflammation characterizes panarteritis, with granuloma formation, which is typically found in biopsies of the temporal artery in GCA. [31]

On the contrary, when TLR-5 recognizes flagellin, the elicited inflammatory response is characterized by the sole infiltration of the adventitia (periarteritis). In this case, disruption of the elastic lamina and subsequent luminal occlusion is typically lacking. [31] Clinical observations have suggested that periarteritis rarely accompanies systematic inflammatory processes, such as aneurysm formation. Subtle alterations in inflammatory reactions guided by DCs with TLR-4 and/or TLR-5 overexpression may explain the differences in the clinical phenotype of giant cell arteritis.

Nevertheless, independently of the mode of the initial stimulation, DCs become activated and subsequently produce cytokines with redundant and pleiotropic actions. In inflamed temporal arteries, DCs secrete pro-inflammatory cytokines, mainly IL-2, IL-6 and IFN- γ , which, in turn, mediate the recruitment of inflammatory cells, inhibition of cell migration, enhancement of T cell proliferation and stimulation of T and B cells. [32] The net result is further amplification of the immune response, through positive feedback loops.

7. Adaptive immunity abnormalities in GCA

The differentiation and activation of DCs (following stimulation via their TLRs) induces the subsequent recruitment of T cells into the vessel wall. Indeed, several studies on activation patterns and inflammatory mediators in GCA, have confirmed that the progression of the immune response is totally dependent on CD4⁺ T cells. [33] These cells are able to orchestrate the stimulation of macrophages that lead to vessel response to injury, resulting in luminal stenosis or wall destruction and aneurysm formation.

Upon antigen recognition, CD4⁺ T cells are activated and differentiated into effector and memory T cells, while the antigen-specific subpopulation is 10 to 100-fold expanded. Under physiological conditions, only a few antigen-specific memory T cells are capable to persist indefinitely and provide life-long protection against pathogens. In parallel, these memory cells comprise the main barrier against the elimination of T-cell mediated autoimmune responses.

In GCA, several efforts to recognize a single antigen that may initiate the pathogenic specific immune response have not been fruitful. [20] In accordance, attempts to isolate the T cell clone, which is responsible for the vascular pathology in the disease, have suggested more heterogeneity than expected. Studies focusing on T cell receptor V genes in the arterial wall and the peripheral blood of GCA patients have arrived at the conclusion that the T cell repertoire is significantly biased. [34, 35] Sequence analysis of the CD4⁺ T cells isolated from the inflamed temporal arteries has strongly supported local T cell activation and expansion of only a few selected T cell specificities. Notably, T cells isolated from the right and left temporal arteries of the same patient utilized identical T cell receptors. [36]

More recent studies confirmed that multiple T cell lineages contribute to the disease process. Histopathologic analyses from temporal arteries, both prior to therapy and on therapy, convincingly proved that two cell lineages, Th1 and Th17, infiltrate the vessel wall prior to therapy. [37] The concurrent presence of the two T cell lineages coincided closely with the stimulation of two distinct immune axes, an IL-12-IFN- γ axis and an IL-1-IL-23 axis. It seems that different APC signals are able to recruit either the IFN- γ -dependent or the IL-17-dependent arm of the adaptive immunity, thus raising the possibility that more than one instigator is involved in GCA. [21]

8. Th1 cells in GCA

Th1 cells represent the dominant cell population in the intramural lesions and the periphery of patients with untreated GCA. [37] These cells produce IFN- γ , as their signature cytokine, which, physiologically, has a critical role against viral and intracellular bacterial infections. Once called macrophage activating factor, IFN- γ target macrophages and provide a substantial pro-inflammatory environment.

IFN- γ committed T cells are considered to account for >20% of circulating CD4⁺ T cells, an almost 100% increase compared to age-matched healthy controls. [38] Corticosteroid therapy cannot affect the expansion of this subpopulation, indicating continuous signaling from the respective DCs. The underlying mechanism of this resistance involves the triggering of APCs that continue to release IL-12. Actually, both in the blood and the temporal arteries of GCA patients, IL-12 production continued unabated during the chronic phase of the disease in treated patients. [38]

At the tissue level, cytokine profiling in GCA temporal arteries has demonstrated robust expression of IFN- γ and an association with a defined disease phenotype. [32] In particular, high tissue IFN- γ levels are typical for patients with ischaemic complications, implicating its crucial participation in the process leading to luminal occlusion. Pathophysiological studies have correlated increased IFN- γ levels with the production of vascular endothelial growth factor (VEGF) and platelet derived growth factor (PDGF), which are molecules implicated in the intimal response that leads to lumen stenosis. [39, 40] VEGF may, in turn, promote IFN- γ production, thus leading to a vicious cycle of inflammation and structural stenosis. [39]

It is currently unknown which aspects of the granulomatous inflammation depend upon IFN- γ . The ability of this cytokine to activate monocytes and macrophages certainly has a role in promoting the differentiation of lesional histiocytes. However, the profound differences in the clinical presentation of treated and untreated GCA patients suggest that IFN- γ is less relevant to the systemic manifestations of the disease and, instead, the major mediator of vessel wall destruction. [21]

9. Th17 cells in GCA

Th17 cells play an important role in antimicrobial immunity where they regulate the recruitment of neutrophils and facilitate protection against extracellular bacteria and fungi. Far beyond their role in host defense, Th17 cells have been implicated in the pathogenesis of several autoimmune and inflammatory disorders, such as rheumatoid arthritis, multiple sclerosis and inflammatory bowel disease. [41]

In untreated GCA patients, the frequency of Th17 cells is 10-fold elevated in the peripheral blood and they accumulate in the vascular infiltrates. [37] In healthy individuals, Th17 cells are infrequent and account for less than 0.3% of the circulating CD4⁺ T cells. In newly diag-

nosed GCA patients, an average of 2.2% of circulating CD4⁺ T cells were found to be IL-17 producers, while in some patients these cells were >5%.

In contrast to the Th1 lineage, Th17 cells displayed a totally different sensitivity to corticosteroid therapy. Prednisone therapies led to a fast and, almost, complete reduction of both circulating and lesional Th17 cells, as, in treated patients, only 0.4% of the circulating CD4⁺ T cells were capable of producing IL-17. [38] Taking into account that the systemic manifestations of GCA, such as fever and PMR, are the most responsive to steroid therapy and coincide with the normalization of Th17 cells, it can be speculated that these features are pathophysiologically related to the Th17 response. In addition, corticosteroid therapy was shown to suppress the entire IL-1 – IL-6 – IL-17 axis. [38]

The specific circumstances under which the Th17 response is amplified are not well understood, but studies, in untreated patients, showed that circulating monocytes (primed by IFN- γ) produce significant amounts of Th17-polarizing cytokines, such as IL-6 and IL-23. Of note, IL-6 may represent a reliable biomarker for assessing disease activity over time.

Latest studies showed that Th17 cells possess a substantial plasticity and they are able to transform into Th1 cells and release IFN- γ . [22] It is possible that, at least partially, Th17 represent the precursor cells that will progress to Th1 cells in a chronic disease process. On the other hand, one could expect that the successful suppression of Th17 cells (after steroid therapy) would eventually lead to the reduction of the Th1 cells, but this was not confirmed in experimental studies. Furthermore, there is evidence that there may be a small proportion of CD4⁺ T cells that are able to secrete both IL-17 and IFN- γ . The presence of these double producers was confirmed in atherosclerosis, although in GCA, these cells behave like the Th17 cells, in terms of steroid responsiveness. [22, 42] These findings suggest that these cells are not important in promoting the chronic phase of the disease.

10. The final common pathway: Mechanisms of arterial wall destruction in GCA

After the expansion of the Th1 and Th17 cells, the production of their related cytokines is capable to drive the inflammatory reaction in the vessel wall. IFN- γ induces macrophages towards their effector functions, mainly, the formation of multinucleated giant cells and granulomatous inflammation. [29] Granuloma formation may lead to lumen stenosis and, thus to the ischemic complications of GCA. It is interesting that PMR patients share some clinical features with GCA, although they do not develop ischemic complications. [3] This is possibly related to the lack of IFN- γ from resected arteries of PMR patients. [22] Unsuppressed actions of IFN- γ on macrophages could explain why patients, under corticosteroid treatment, may still develop devastating occlusive vasculitis.

The pro-inflammatory environment, shaped by IL-1, IL-6, IL-17, IL-23 and IFN- γ , promotes the infiltration of the arterial wall adventitia by activated monocytes and neutrophils, via the vasa vasorum. The endothelial cells of these small capillaries in the vessel wall upregulate the

expression of certain adhesion molecules, which attract and restrain inflammatory cells. Within the vessel wall, altered macrophage function enhances IFN- γ production (through IL-12 release) and the subsequent recruitment of additional macrophages and lymphocytes, thus creating a vicious cycle. Intimal macrophages also express nitric oxide (NO) synthetase, which augments the capillary permeability and peroxynitrite, which has been associated with endothelial dysfunction. [29]

Additionally, reactive oxygen species (ROS) are secreted by macrophages into the surrounding tissues and degrade the proteins of the extracellular matrix. Oxygen-derived free radicals and their metabolites promote tissue injury through multiple mechanisms, the most important being oxidation of membrane lipids, resulting in structural disintegration and cell death. Reactive oxygen intermediates are not only directly cytotoxic; they can also alter cellular function by disrupting intracellular signaling cascades. The net result is the degradation of the media and the weakening of the arterial wall.

Additionally, metalloproteases (MMPs) that are released by macrophages and vascular smooth muscle cells are associated with matrix degeneration, intimal hyperplasia and luminal narrowing. In particular, matrix metalloproteases MMP-2 and MMP-9, which possess gelatinase activity, have both been detected in the infiltrates of the arterial wall in patients with GCA. [43] Due to their ability to destroy elastin, MMP-2 and MMP-9 have been suggested to play a primary role in the internal elastic lamina degradation, a characteristic pathologic finding in GCA. These metalloproteases are able to differentially regulate vascular smooth muscle cell migration and cell-mediated collagen organization. [44]

In parallel, the inflammatory milieu provokes the apoptosis of smooth muscle cells, which are primarily responsible for the compliance of the arterial wall. Aneurysms can eventually be formed in these hemodynamically non-compliant sites of the vasculature. [29]

Although the pathophysiologic mechanism underlying aneurysm formation in GCA is well understood, the pathophysiologic basis of lumen stenosis is not equally clear. It has been shown that IFN- γ may produce endothelial hyperplasia and subsequent narrowing of the vascular lumen. [22] Interestingly, it was demonstrated that the extent of platelet-derived growth factor (PDGF) production, in the vascular lesions, correlates with the degree of luminal occlusion and the severity of the ischaemic manifestations. [40] In accordance, VEGF derived from activated macrophages deregulate the endothelial functions. Eventually, anatomical alterations will ensue, leading to the remodeling of inflamed arteries. The physiologic basis of these findings may rely on the increased needs of the hyperplastic arterial wall in means of oxygen and nutrients. Neoangiogenesis, provoked by these factors, may supply the needed nutrients in the hyperplastic wall but, also, effectively supports the destructive inflammatory reaction. [45] Nonetheless, thrombotic occlusions are rare complications of giant cell arteritis.

The outline of GCA immunopathogenesis is displayed in Figure 1.

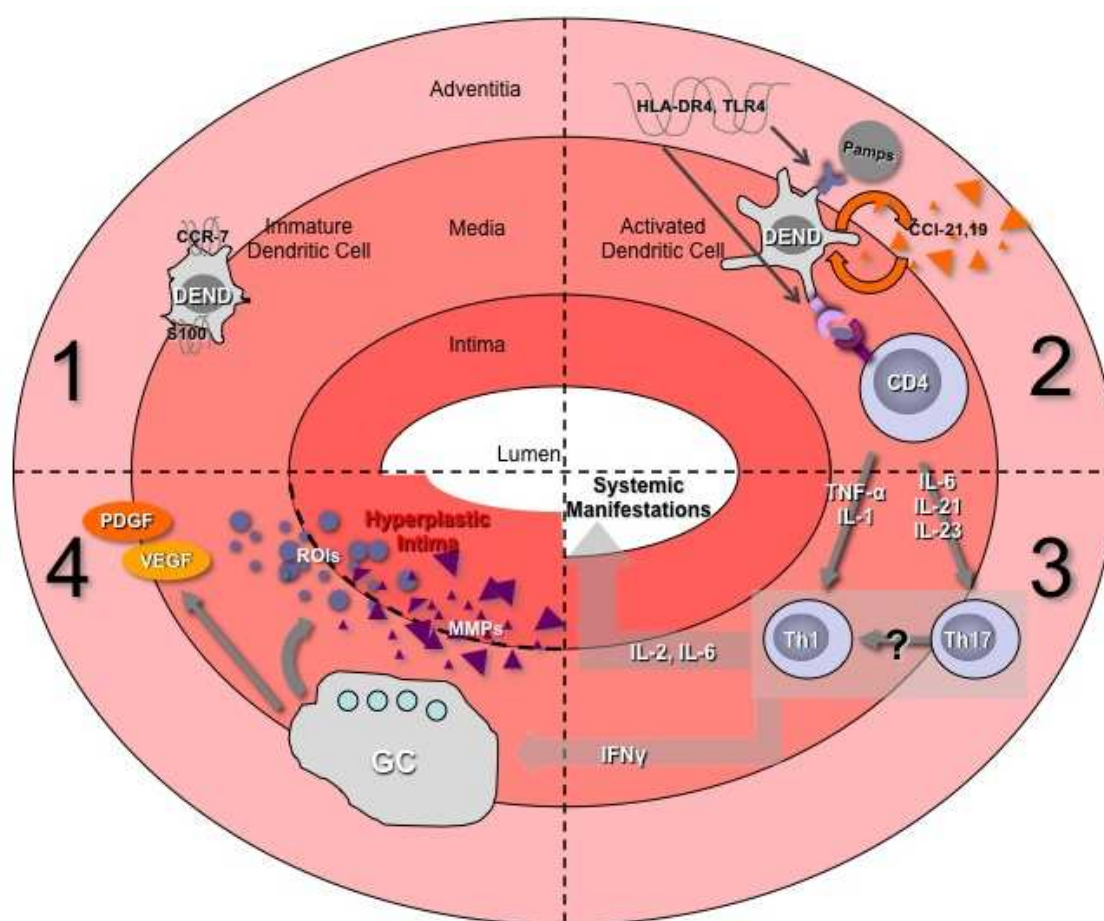


Figure 1. The immunopathophysiologic basis of giant cell arteritis. 1. In normal arteries, immature DCs, in the adventitia-media border, are the immune sentinels of the vessel wall. 2. In GCA, their maturation and activation (by an unknown instigator) leads to the recruitment of CD4+ T cells into the vessel wall. 3. CD4+ T cells are able to differentiate into either the Th17 arm of the immune response, which is responsible for the systemic manifestations of the disease, or the Th1 arm. 4. Th1 cells along with IFN- γ are able to drive the activation of macrophages, the formation of granuloma and the destruction of the structural integrity of the vessel wall via the secretion of MMPs and ROS.

11. Newer concepts in GCA pathogenesis: Immune and vascular aging

According to the 1990 ACR criteria for the diagnosis of GCA, age above 50 is considered a major criterion for disease diagnosis. [46] Susceptibility of elder persons for GCA is considered to be the result of two separate degenerative processes.

Firstly, immunesenescence is characterized by the shrinkage of the naïve T-cell pool, loss of immune-regulation and impairment of innate immunity. [47] More specifically, alterations in innate immunity functions, such as impairment of DC trafficking and prolonged maintenance of TLR expression raise the possibility of uncontrolled inflammatory reactions in immunoprivileged sites. Furthermore, the immune aging process results in an increase in basal cytokine production by macrophages, dendritic cells, endothelial cells and fibroblasts.

Secondly, biochemical modifications in vessel wall extracellular structures, such as the disorganization of the elastic fibers, render the vessel wall extremely compliant. Vascular smooth muscle cells decrease in number and function. The media becomes thinner and deposition of calcium is not unusual. Beyond the alterations observed in biomechanical parameters, the “old” artery seems to provide a distinct micro-environment that potentially increases the risk for the formation of a novel spectrum of neoantigens and the persistence of inflammatory reactions. [48]

12. Clinical phenotype and response to treatment are dependent on pathophysiology

Aneurysm formation in GCA is reported in 3% of the patients with 3 months disease duration and 18-27 % of patients with 6 months duration. [49, 50] Cumulatively, the relative risk for aneurysm formation is estimated to be 17.3. [51]

Disease diagnosis is straightforward in typical cases with headache, temporal tenderness, non palpable temporal arteries, jaw claudication and systemic symptoms (fever, malaise, weight loss) in an individual beyond 50 years of age. Unfortunately, a considerable proportion of patients presents with minor or no symptoms from the cranial arteries, which is presumably the hallmark of GCA.

Temporal artery biopsy represents the diagnostic gold standard, as its sensitivity is reported to exceed 85%. It should be mentioned that negative biopsy does not exclude GCA, as the lesions are skipped and long tissue specimens (>20mm) are required. Common causes of false negative results are the incomplete technique (sampling error) and the lack of sensitive pathologic criteria. Thus, in highly suspected cases, a second, contralateral, biopsy is recommended. Recent studies suggest ultrasonography-guided biopsy to precisely locate the patchy lesions of vessel wall inflammation. [52]

Another advanced technique to detect vascular inflammatory sites is FDG-PET (fluorodeoxyglucose positron emission tomography) imaging, which is currently incorporated in diagnostic algorithms. [53]

Immune system abnormalities play a critical role in GCA pathogenesis and are able to drive, not only clinical phenotype, but, also, response to treatment. DCs have been shown to initiate the immune response, as the number of myeloid DCs significantly increases in the adventitia of affected arteries and they appear to be activated via ligation of their TLR-4 (LPS) or TLR-5 (flagellin). [31] Stimulation of DCs via these TLRs induces the subsequent recruitment of T cells into the vessel wall, where they undergo local proliferation and activation. T cells produce pro-inflammatory cytokines to regulate the functions of macrophages, vascular smooth muscle cells and endothelial cells, while they were proved to belong to either Th1 or Th17 lineage. [22]

Th17 cells secrete IL-17 and provide the early immune response in GCA, where these cells are reported to be 10-fold elevated in initial phases. Furthermore, in untreated patients, circulating monocytes (primed by IFN- γ) produce significant amounts of Th17-polarizing cytokines, such

as IL-6 and IL-23. Th17 response is considerably sensitive to steroids and is related to the inflammatory phenotype of GCA, like fever and PMR. [37] The most common clinical manifestations of the disease include constitutional symptoms (anorexia, weight loss), fever (in some cases fever of unknown origin), headache (usually localized in the temporal region), and polymyalgia rheumatica. This cluster of symptoms is attributed to the initial Th17 response and has been shown to respond adequately to steroids. [38]

Th1 cells represent the dominant cellular population at the tissue level and the periphery of patients with untreated GCA. These cells produce IFN- γ , target macrophages and provide a substantial pro-inflammatory environment. Additionally, IFN- γ is strongly related to elevated levels of metalloproteases (MMP-2, MMP-9), which lead to vessel wall destruction and aneurysm formation. Th1 response is believed to be steroid resistant (in usual doses), as IFN- γ committed T cells and soluble IFN- γ are not affected even after months of steroid therapy. [38] The late clinical manifestations in the disease course, such as jaw claudication, tongue claudication, scalp necrosis and visual impairment, represent ischemic complications resulting from this Th1-IFN- γ driven process.

On the other hand, thoracic and abdominal aortic aneurysms comprise the most dreaded complications of GCA. These manifestations are mediated through an intense Th1 response that leads to IFN- γ secretion, macrophage activation and release of metalloproteases into the aortic wall. This leads eventually to internal elastic lamina rupture, intimal hyperplasia and lumen stenosis or aneurysm formation. [21] This sequela has been shown to be steroid-resistant even if used in high doses.

Glucocorticoids, while the mainstay of therapy in GCA, do not exert the expected efficacy in Th1-driven aneurysmal disease. [38] Based on these data, glucocorticoids should be instituted promptly once the diagnosis of GCA is suspected. The optimal dose for remission induction in GCA remains uncertain. An initial daily dose of 40 to 60 mg of prednisone or its equivalent is reported to be adequate in almost all cases. [54] In severe, life threatening cases or, when the visual loss is considered imminent, intravenous methylprednisolone is recommended, while tapering can begin once the disease has been adequately controlled, with a rate of 3-4 mg/week. Most patients require medium doses of steroids for at least two years, since relapse risk is high.

Adjuvant therapy is usually needed to avoid chronic side effects, but no agent (methotrexate, IVIGs or other cytotoxic agents) has so far proven satisfactory efficacy. [55-57] Recent advances in GCA pathophysiology may lead to alternative treatments, like those which interrupt Th17 differentiation, such as tocilizumab. [58]

In conclusion, large vessel involvement in GCA is characterized by a biphasic pathophysiologic process. Initial Th17 response will lead to the steroid-sensitive systemic inflammatory features of the disease, while, in late phases, Th1 response is responsible for the steroid-resistant aneurysmal disease. Given the fact that these complications may be life-threatening, it is reasonable to be thoroughly evaluated and managed promptly, either by surgical or by pharmaceutical means or both.

Author details

Panagiota Boura*, Konstantinos Tselios, Ioannis Gkougkourelas and
Alexandros Sarantopoulos

Clinical Immunology Unit, 2nd Department of Internal Medicine, Hippokration General Hospital, Aristotle University of Thessaloniki, Thessaloniki, Greece

References

- [1] Salvarani C, Cantini F, Hunder GG. Polymyalgia rheumatica and giant cell arteritis. *Lancet* 2008; 372: 234-45
- [2] Gonzalez-Gay MA, Martinez-Dubois C, Agudo M, Pompei O, Blanco R, Llorca J. Giant cell arteritis: epidemiology, diagnosis, and management. *Curr Rheumatol Rep* 2010; 12(6): 436-42
- [3] Salvarani C, Pipitone N, Versari A, Hunder GG. Clinical features of polymyalgia rheumatica and giant cell arteritis. *Nat Rev Rheumatol* 2012 Jul 24 doi: 10.1038/nrrheum.201.97 (Epub ahead of print)
- [4] Stacy RC, Rizzo JF, Cestari DM. Subtleties in the histopathology of giant cell arteritis. *Semin Ophthalmol* 2011; 26: 342-8
- [5] Hunder GG. The early history of giant cell arteritis and polymyalgia rheumatica: first descriptions to 1970. *Mayo Clin Proc* 2006; 81: 1071-83
- [6] Homme JL, Aubry MC, Edwards WD et al. Surgical pathology of the ascending aorta: a clinicopathologic study of 513 cases. *Am J Surg Pathol* 2006; 30: 1159-68
- [7] Ostberg G. Morphological changes in the large arteries in polymyalgia rheumatica. *Acta Med Scand Suppl* 1972; 533: 135-59
- [8] Evans JM, O'Fallon WM, Hunder GG. Increased incidence of aortic aneurysm and dissection in giant cell (temporal) arteritis. A population-based study. *Ann Intern Med* 1995; 122: 502-7
- [9] Nuenninghoff DM, Hunder GG, Christianson TJ et al. Incidence and predictors of large-artery complication (aortic aneurysm, aortic dissection and/or large artery stenosis) in patients with giant cell arteritis: a population-based study over 50 years. *Arthritis Rheum* 2003; 48: 3522-31
- [10] Garcia-Martinez A, Hernandez-Rodriguez J, Arguis P et al. Development of aortic aneurysm/dilatation during the follow-up of patients with giant cell arteritis: a cross-sectional screening of fifty-four prospectively followed patients. *Arthritis Rheum* 2008; 59: 422-30

- [11] Pietro-Gonzalez S, Arguis P, Garcia-Martinez A, Espigol-Frigole G, Tavera-Bahilo I, Butjosa M et al. Large vessel involvement in biopsy-proven giant cell arteritis: prospective study in 40 newly diagnosed patients using CT angiography. *Ann Rheum Dis* 2012; 71: 1170-6
- [12] Nuenninghoff DM, Hunder GG, Christianson TJ et al. Mortality of large-artery complication (aortic aneurysm, aortic dissection and/or large artery stenosis) in patients with giant cell arteritis: a population-based study over 50 years. *Arthritis Rheum* 2003; 48: 3532-7
- [13] Gonzalez-Gay MA, Amoli MM, Garcia-Porrúa C, Ollier WE. Genetic markers of disease susceptibility and severity in giant cell arteritis and polymyalgia rheumatica. *Semin Arthritis Rheum* 2003; 33: 38-48
- [14] Alvarez-Rodriguez L, Lopez-Hoyos M, Carrasco-Marin E, Mata C, Calvo-Alen J, Aurrecoechea E et al. Analysis of the rs20541 (R130Q) polymorphism in the IL-13 gene in patients with elderly-associated chronic inflammatory diseases. *Rheumatol Clin* 2012 Jun 27 (Epub ahead of print)
- [15] Enjuanes A, Benavente Y, Hernandez-Rodriguez J, Queralt C, Yaque J, Jares P et al. Association of NOS2 and potential effect of VEGF, IL-6, CCL2 and IL-1 α polymorphisms and haplotypes on susceptibility to GCA. A simultaneous study of 130 potentially functional SNPs in 14 candidate genes. *Rheumatology* 2012; 51: 841-51
- [16] Palomino-Morales R, Torres O, Vazquez-Rodriguez TR, Morado IC, Castaneda S, Callejas-Rubio JL et al. Association between toll-like receptor 4 gene polymorphism and biopsy-proven giant cell arteritis. *J Rheumatol* 2009; 36: 1501-6
- [17] Mohammadi A, Pfeifer JD, Lewis JS Jr. Association between human papilloma virus DNA and temporal arteritis. *BMC Musculoskelet Disord* 2012; 13: 132
- [18] Cooper RJ, D'Arcy S, Kirby M, Al-Buhtori M, Rahman MJ, Proctor L et al. Infection and temporal arteritis: a PCR-based study to detect pathogens in temporal artery biopsy specimens. *J Med Virol* 2008; 80: 501-5
- [19] Elling P, Olsson AT, Elling H. Synchronous variations in the incidence of temporal arteritis and polymyalgia rheumatica in Danish countries. Association with epidemics of *Mycoplasma pneumoniae* infection. *Ugeskr Laeger* 1997; 159: 4123-8
- [20] Duhaut P, Bosshard S, Ducroix JP. Is giant cell arteritis an infectious disease? Biological and epidemiological evidence. *Presse Med* 2004; 33: 1403-8
- [21] Mohan SV, Liao J, Kim JW, Goronzy JJ, Weyand CM. Giant cell arteritis: immune and vascular aging as disease risk factors. *Arthritis Res Ther* 2011; 13: 231
- [22] Weyand CM, Younge BR, Goronzy JJ. IFN- γ and IL-17: The two faces of T cell pathology in giant cell arteritis. *Curr Opin Rheumatol* 2011; 23: 43-9

- [23] Yilmaz A, Arditi M. Giant cell arteritis: DCs take two T's to tango. *Circ Res* 2009; 104: 425-7
- [24] Ma-Krupa W, Dewan M, Jeon MS, Kurtin PJ, Younge BR, Goronzy JJ et al. Trapping of misdirected dendritic cells in the granulomatous lesions of giant cell arteritis. *Am J Pathol* 2002; 161: 1815-23
- [25] Ma-Krupa W, Jeon MS, Spoerl S, Tedder TF, Goronzy JJ, Weyand CM. Activation of the arterial wall dendritic cells and breakdown of self-tolerance in giant cell arteritis. *J Exp Med* 2004; 199: 173-83
- [26] Caux C, Ait-Yahia S, Chemin K, De Bouteiller O, Dieu-Nosjean MC, Homey B et al. Dendritic cell biology and regulation of dendritic cell trafficking by chemokines. *Springer Semin Immunopathol* 2000; 22: 345-69
- [27] Han JW, Shimada K, Ma-Krupa W, Johnson TL, Nerem RM, Goronzy JJ et al. Vessel-wall embedded dendritic cells induce T-cell autoreactivity and initiate vascular inflammation. *Circ Res* 2008; 102: 546-53
- [28] Weyand CM, Ma-Krupa W, Pryschep O, Groschel S, Bernardino R, Goronzy JJ. Vascular dendritic cells in giant cell arteritis. *Ann N Y Acad Sci* 2005; 1062: 195-208
- [29] Chang K, Rizzo F. Recent advances in the immunopathology of giant cell arteritis. *Int Ophthalmol Clin* 2009; 49: 99-109
- [30] Pryschep O, Ma-Krupa W, Younge BR, Goronzy JJ, Weyand CM. Vessel specific Toll-like receptor profiles in human medium and large arteries. *Circulation* 2008; 118: 1276-84
- [31] Deng J, Ma-Krupa W, Gewirtz AT, Younge BR, Goronzy JJ, Weyand CM. TLR4 and TLR5 induce distinct types of vasculitis. *Circ Res* 2009; 104(4): 488-95
- [32] Weyand CM, Tetzlaff N, Bjornsson J, Brack A, Younge BR, Goronzy JJ. Disease patterns and tissue cytokine profiles in giant cell arteritis. *Arthritis Rheum* 1997; 40: 19-26
- [33] Brack A, Geisler A, Martinez-Taboada VM, Younge BR, Goronzy JJ, Weyand CM. Giant cell vasculitis is a T cell-dependent disease. *Mol Med* 1997; 3: 530-43
- [34] Grunewald J, Andersson R, Rydberg L, Gigliotti D, Schaufelberger C, Hansson GK et al. CD4+ and CD8+ T cell expansions using selected TCR V and J gene segments at the onset of giant cell arteritis. *Arthritis Rheum* 1994; 37: 1221-7
- [35] Schaufelberger C, Andersson R, Nordborg E, Hansson GK, Nordborg C, Wahlstrom J. An uneven expression of T cell receptor V genes in the arterial wall and peripheral blood in giant cell arteritis. *Inflammation* 2008; 31: 372-83
- [36] Weyand CM, Schonberger J, Oppitz U, Hunder NN, Hicok KC, Goronzy JJ. Distinct vascular lesions in giant cell arteritis share identical T cell clonotypes. *J Exp Med* 1994; 179: 951-60

- [37] Deng J, Younge BR, Olshen RA, Goronzy JJ, Weyand CM. Th17 and Th1 T-cell responses in giant cell arteritis. *N Engl J Med* 2009; 361: 1114-6
- [38] Deng J, Younge BR, Olshen RA, Goronzy JJ, Weyand CM. Th17- and Th1-cell responses in giant cell arteritis. *Circulation* 2010; 121: 906-15
- [39] Basu A, Hoerning A, Datta D, Edelbauer M, Stack MP, Calzadilla K et al. Cutting edge: Vascular endothelial growth factor-mediated signalling in human CD45RO+CD4+ T cells promotes Akt and ERK activation and costimulates IFN-gamma production. *J Immunol* 2010; 184: 545-9
- [40] Kaiser M, Weyand CM, Bjornsson J, Goronzy JJ. Platelet-derived growth factor, intimal hyperplasia and ischemic complications in giant cell arteritis. *Arthritis Rheum* 1998; 41: 623-33
- [41] Mesquita D, Cruvinel WM, Camara NOS, Kallas EG, Andrade LEC. Autoimmune diseases in the Th17 era. *Braz J Med Biol Res* 2009; 42: 47-86
- [42] Eid RE, Rao DA, Zhou J, Lo SF, Ranjbaran H, Gallo A et al. Interleukin-17 and interferon-gamma are produced concomitantly by human coronary artery-infiltrating T cells and act synergistically on vascular smooth muscle cells. *Circulation* 2009; 119: 1424-32
- [43] Rodriguez-Pla A, Bosch-Gil JA, Rosello-Urgell J, Huguet-Redecilla P, Stone JH, Vilar-dell-Tarres M. Metalloproteinase-2 and -9 in giant cell arteritis: involvement in vascular remodelling. *Circulation* 2005; 112: 264-9
- [44] Johnson C, Galis ZS. Matrix metalloproteinase -2 and -9 differentially regulate smooth muscle cell migration and cell-mediated collagen organization. *Arterioscler Thromb Vasc Biol* 2004; 24: 54-60
- [45] Kaiser M, Younge BR, Bjornsson J, Goronzy JJ, Weyand CM. Formation of new vasa vasorum in vasculitis. Production of angiogenic cytokines by multinucleated giant cells. *Am J Pathol* 1999; 155: 765-74
- [46] Hunder GG, Bloch DA, Michel BA, Stevens MB, Arend WB, Calabrese LH et al. The American College of Rheumatology 1990 criteria for the classification of giant cell arteritis. *Arthritis Rheum* 1990; 33: 1122-8
- [47] Campisi J, d'Adda di Fagagna F. Cellular senescence: when bad things happen to good cells. *Nat Rev Mol Cell Biol* 2007; 8: 729-40
- [48] Wang M, Monticone RE, Lakatta EG. Arterial aging: a journey into subclinical arterial disease. *Curr Opin Nephrol Hypertens* 2010; 19: 201-7
- [49] Bossert M, Prati C, Balblanc JC, Lohse A, Wendling D. Aortic involvement in giant cell arteritis: Current data. *Joint Bone Spine* 2011; 78(3): 246-51

- [50] Ghinoi A, Pipitone N, Nicolini A, Boiardi L, Silingardi M, Germano G et al. Large-vessel involvement in recent-onset giant cell arteritis: a case-control colour-Doppler sonography study. *Rheumatology* 2012; 51(4): 730-4
- [51] Evans JK, Bowles CA, Bjornsson J, Mullany CJ, Hunder GG. Thoracic aortic aneurysm and rupture in giant cell arteritis. A descriptive study of 41 cases. *Arthritis Rheum* 1994; 37(10): 1539-47
- [52] Noel B. An easy and safe procedure for temporal artery biopsy. *J Cutan Med* 2006; 10(3): 147-50
- [53] Lehmann P, Buchtala S, Achajew N, Haerle P, Ehrenstein B, Lighvani H et al. 18F-FDG PET as a diagnostic procedure in large vessel vasculitis-a controlled, blinded re-examination of routine PET scans. *Clin Rheumatol* 2011; 30(1): 37-42
- [54] Chan M, Lugmani R. Pharmacotherapy of vasculitis. *Expert Opin Pharmacother* 2009; 10(8): 1273-89
- [55] Hoffman GS, Cid MC. A multicenter, randomized, double-blind, placebo-controlled trial of adjuvant methotrexate treatment for giant cell arteritis. *Arthritis Rheum* 2002; 46(5): 1309-18
- [56] Jover A. Combined treatment of giant-cell arteritis with methotrexate and prednisone. A randomized, double-blind, placebo-controlled trial. *Ann Intern Med* 2001; 134(2): 106-14
- [57] Langford CA. Drug insight: anti-tumor necrosis factor therapies for the vasculitic diseases. *Nat Clin Pract Rheumatol*. 2008; 4(7): 364-70
- [58] Seitz M, Reichenbach S, Bonel HM, Adler S, Wermelinger F, Villiger PM. Rapid induction of remission in large vessel vasculitis by IL-6 blockade. A case series. *Swiss Med Wkly* 2011; 141: w13156

