

We are IntechOpen, the world's leading publisher of Open Access books Built by scientists, for scientists

6,900

Open access books available

186,000

International authors and editors

200M

Downloads

Our authors are among the

154

Countries delivered to

TOP 1%

most cited scientists

12.2%

Contributors from top 500 universities



WEB OF SCIENCE™

Selection of our books indexed in the Book Citation Index
in Web of Science™ Core Collection (BKCI)

Interested in publishing with us?
Contact book.department@intechopen.com

Numbers displayed above are based on latest data collected.
For more information visit www.intechopen.com



Surgical Approaches to the Hip Joint and the It's Clinical Implications in Adult Hip Arthroplasty

Hiran Amarasekera

Additional information is available at the end of the chapter

<http://dx.doi.org/10.5772/55212>

1. Introduction

The Hip joint can be approached in many ways and therefore many different exposures have been described. The choice of which approach to use depend on the type of surgery, what part of the hip needs to be exposed, age of the patient and surgeon's preference and expertise.

When approaching the hip it is also important to consider whether the surgery is done for trauma or elective surgery, whether the patient is an adult or a child whether it is conservative hip surgery or replacement surgery and what part needs to be accessed for the specific surgery such as the acetabulum, femoral head or whether both need equal access as in total hip arthroplasty.

The main aim of this chapter is to discuss the available surgical approaches in the adult hip when elective reconstructive surgery is done such as total hip resurfacing and revision hip arthroplasty.

The advantages and dis-advantages and the clinical relevance of these approaches to each surgery and basic surgical steps are discussed including the traditional approach and the modification of these approaches.

For completion of the chapter most approaches and classifications are mentioned but the emphasis is mainly on the common approaches used in hip arthroplasty. A good approach to the hip should have good access to both femoral head and acetabulum, should have minimal dissection of soft tissues, leading to reduced operative time and blood loss, less post operative pain and early mobilisation, least risk of damage to neurovascular bundles muscles and tendons with minimal risk of infection thrombosis and dislocation. However in practice there is no one ideal approach hence many approaches have been described and used among orthopaedic surgeons over the years.

2. Classification of different surgical approaches

Surgical approaches to the hip joint can be classified in many ways. One simple classification is based on the direction of approach. (Fig 1) The common approaches used based on this classification are the anterior, antero-lateral and posterior. Some of the different ways of classifying surgical approaches to the hip is given below. [1]

a. Based on the direction

1. Anterior type
2. Lateral and antero lateral type
3. Posterior type
4. Medial type
5. Combined e.g. anterior and posterior

b. Based on incision and invasiveness

1. Standard incision e.g. Posterior
2. Mini incision posterior (MIS)

c. Based on type of surgery

1. Open surgical e.g. anterior
2. Arthroscopic

It is also important to know that certain new approaches described are essentially a modification of an existing approach. E.g. Trochanteric flip approach is a modification of an anterior type approach. [2]

3. Surgical approaches to the hip joint

Before performing any surgical approach it is important to understand the anatomical principles that lie behind the surgical dissection.

Like in all orthopaedic surgeries positioning the patient, draping and preparing the area, identification of landmarks and making the incision along skin creases, are important to remember. It is also important to note that all incisions should be made along the identified line of incision but the initial incision is best made within the middle half of the incision line so that if needed this can be extended in either direction. Previous concept of "Big surgeons make big incisions" does not hold true in modern day practice as the demand is for mini incisions and key hole surgery as they give a better cosmetic outcome.

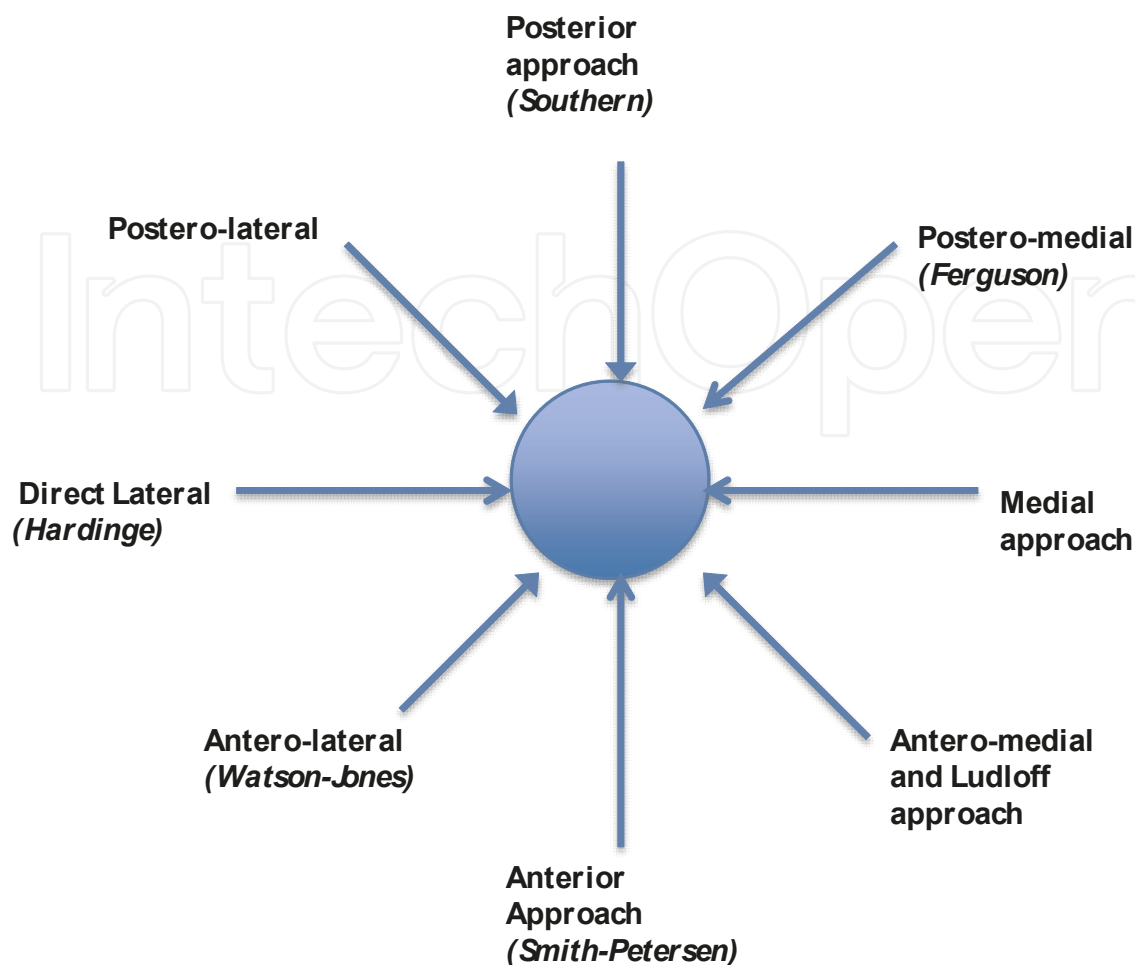


Figure 1. All directions the hip can be approached.

Another principle in operative orthopaedic surgery is the attempt to go directly to the operative area whether it is a bone or a joint. This minimises the lateral dissection thus avoiding damage to soft tissues such as nerves and vessels.

The concept of “*internervous plane*” is important to understand before any surgical approach is done. This means that all deep dissections should be done by dissecting and separating the muscles between two nervous planes so that all muscles supplied by one nerve and its branches are retracted towards one side to avoid damage and denervating the muscles. (Fig 2)

It is not always possible to dissect along the internervous plane. Sometimes dissection planes are developed by splitting the muscles. (Fig 3) The principles of muscle splitting incision are

1. Always muscles are split longitudinally along the line of the fibres.
2. Splitting is done away from the neuromuscular junction to avoid denervation.
3. Bulk of the muscle is retracted along with the nerve-so that most of the muscle will retain the nerve supply.

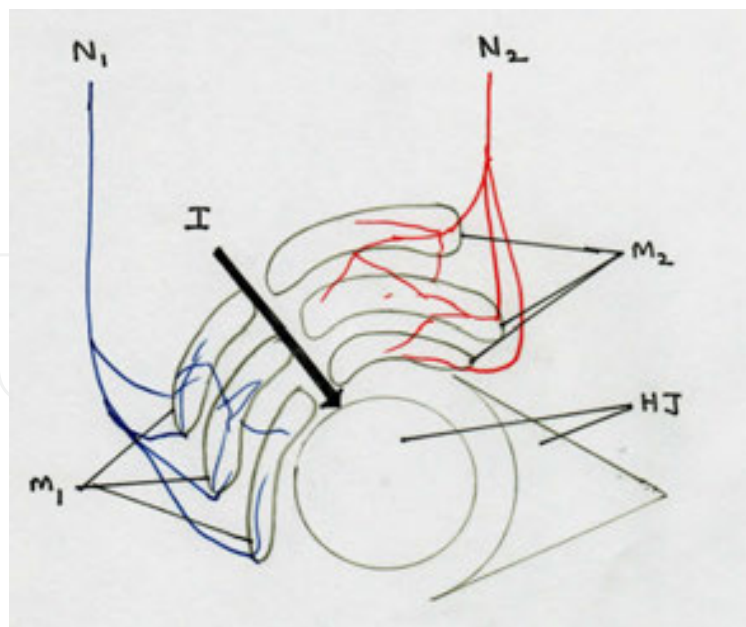


Figure 2. Concept internervous plane, (HJ, Hip Joint; N1 Nerve supplying the muscle group M1; N2 nerve supplying the muscle group M2; I internervous plane)

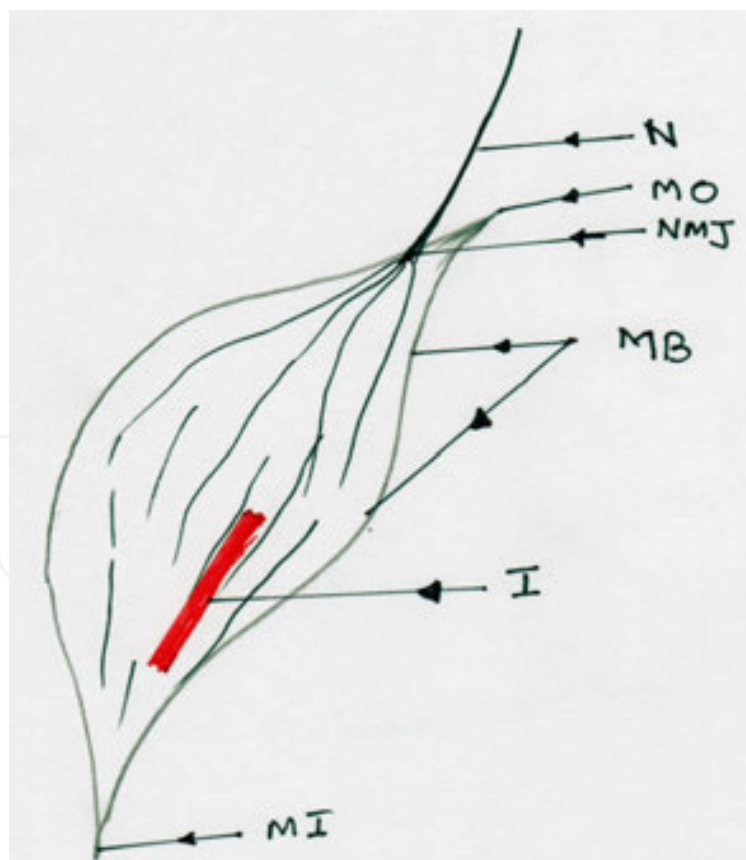


Figure 3. Muscle splitting incisions (I) are made along the line of the fibres, away from the Neuro-muscular junction (NMJ) MO: Muscle Origin, MB: muscle Belly, MI: Muscle Insertion, N: Nerve

In the next few paragraphs the following approaches are described in relation to the clinical implications.

1. Anterior approaches

- a. Anterior type approach is Smith Peterson approach
- b. Mini incision anterior approach

2. Lateral approaches

- a. Direct Lateral /Hardinge
- b. Antero-Lateral /Watson Jones

3. Posterior approach

- a. Southern Approach [3]

4. Medial approaches

- a. Antero medial
- b. Postero-medial (Ferguson Approach)
- c. Ludloff's approach

5. Modern

- a. Arthroscopic
- b. Minimally invasive

6. Modified and combined approaches

- a. Trochanteric Flip Ganz [2]
- b. Antero –lateral minimally invasive [4]
- c. Mini incision posterior approach [5]
- d. Modified antero-lateral [6]
- e. Combined approaches [7]

Out of these approaches it is important understand that the medial approaches are rarely used in hip arthroplasty due to poor access to acetabulum and femoral head.

Even though a detailed description of each surgical approach is beyond the scope of this chapter all the salient features of above approaches are discussed with regard to their key steps, key advantages, key limitations, specific complications, common surgical procedures done through the approach, modifications of the traditional approach and other key issues.

The approaches described in depth below are the surgical approaches used commonly in hip arthroplasty.

4. The anterior approach (*Smith-Petersen*)

a. Key steps

This approach initially described by Smith-Peterson [8] is one of the approaches but not a very popular approach used by arthroplasty surgeons as the femoral exposure is limited. It is mainly used for arthrotomies to drain the hip in presence of infection. The key steps and the details are given below.

Position: Supine with a pillow under the pelvis on the operating side

Incision: Longitudinal incision lies between anterior iliac crest towards upper thigh curving over anterior superior iliac spine.

Soft tissue dissection: This is between sartorius and the tensor fasciae lata and rectus femoris and gluteus medius.

Internervous plane: Lies between the sartorius (Femoral nerve) and the tensor fasciae latae (Superior gluteal nerve)

Arthrotomy: Adduct and externally rotate the leg and incise the capsule longitudinally or with W or T shape incision.

Dislocation: by external rotation

Closure: In layers capsule rarely closed. Fascial planes are closed and skin

b. Key advantages

The advantages of this approach include preservation of the vascularity, stability following the procedure with less chance of dislocation. Limited morbidity, high stability and with good access to the acetabulum are key advantages of this approach. [9] The approach limits muscle cutting and separation, reduce chance of dislocations, and makes it easier to take intra-operative radiographs as the patient is supine in position. Key muscle groups the extensors and the abductors are kept intact the along with the medial circumflex femoral artery and it's branches. [10], [11]

c. Key Limitations

The key limitation of this approach is the limited access making it technically demanding to place components in arthroplasty. Even though the approach to the acetabulum is good approach to proximal femur is limited through this approach. Some encourage to use a fracture table to get a better approach to the femur [12] while others use the standard operating table. [13]

Even though many total hip arthroplasties and even resurfacing hip replacements are done using this approach [10] due to limited access and technical demanding nature [14] this may not be a popular approach among arthroplasty surgeons.

d. Specific complications, [15]

Damage to lateral cutaneous nerve and the anterior cutaneous nerve should be kept in mind. [16]

e. Common surgical procedures

Even though hip arthroplasty is not commonly done some surgeons still prefer to do total hip arthroplasty [17] and hip resurfacing [10] through an anterior approach.

f. Modifications to the approach

The modification of this approach includes two incision direct anterior approach and minimally invasive direct anterior approaches. [18], [19] Low blood loss, early recovery, early mobilisation reduced operating time are the advantages of the minimally invasive anterior approach. [20]

5. Antero-lateral approach (Watson-Jones)

Described initially by Watson-Jones [21] approaches the hip between tensor fascia lata and the gluteus medius muscle planes.

a. Key Steps:

Position: The patient can be positioned supine or laterally on the table

In the supine position a sand bag may be placed under the pelvis on the operating side.

Incision: Longitudinal incision is made while flexing the hip slightly extending over the centre of the greater trochanter running posteriorly along the shaft of the femur.

Soft tissue dissection: This is done by identifying the plane between the tensor fasciae latae and the gluteus medius taking care not to damage the inferior branch of the superior gluteal nerve as it supplies the former muscle.

Vastus lateralis is identified and the muscle is detached from the origin and the capsule identified.

Internervous plane: Since the superior gluteal nerve supply both gluteus medius and tensor fasciae latae it is difficult to define a true internervous plane for this approach. However as long as the plane between these muscles are not dissected superiorly up to the origin the nerve will remain intact.

Arthrotomy: The capsule is divided longitudinally over the anterior superior femoral neck.

Dislocation: This is done by applying external rotation, traction and adduction to dislocate the hip.

Closure: The wound is closed in layers starting with the capsule. If a trochanteric osteotomy is performed it has to be re attached.

b. Key advantages

The key advantages of the approach include stability, less chance of posterior dislocation, less risk to sciatic nerve damage unless during dislocation where traction can stretch the nerve. Precautions should also be taken not to damage the superior gluteal nerve.

c. Key limitations

One of the key limitations is that possibility of abductors getting weak during dissection or by denervation of the nerve supply. [22]

d. Specific complications

Damage to superior gluteal nerve and lateral circumflex femoral artery (LCFA) should be kept in mind.

Damage to the femoral nerve and vessels are a relatively rare complication.

e. Modifications

Mueller modified the approach to avoid trochanteric osteotomy.

Another recent modification for this approach is the minimally invasive approach.[4] Antero lateral minimally invasive approach (ALM) has been described as a good alternative [23] to traditional approaches as it reduces hospital stay, surgical time, blood loss, morbidity, and encourages early mobilisations, and recovery. Even though some report high complication rates [24] with this approach over all this is an approach with many advantages in the modern day practice. However this is a technically demanding procedure that needs expertise.

Trochanteric flip approach developed by Ganz et al is can be considered as a modification or combined type approach where steps of posterior approach is used but the hip is dislocated anteriorly by performing a trochanteric flip osteotomy.[2]

f. Advantages

The key advantage of this approach is the protection of medial circumflex femoral artery thus preserving the main blood supply to the hip. Therefore this becomes an important approach to use in conservative hip surgery and the surface replacement of the hip joint as this can protect the femoral head and neck from developing avascular necrosis (AVN). [25] The key step of this approach is the trochanteric flip osteotomy where a bony flip of around 1.5cm made over the greater trochanter and reflected anteriorly along with vastus lateralis, gluteus medius and minimus and the hip is dislocated anteriorly thus avoiding and dissection of short external rotators.

g. Key limitations

The key limitations include the patient need to be non-weight bearing for six weeks or until the trochanteric osteotomy is healed. Non-union and separation of the osteotomy are other potential complications. [6] (Fig 4)

6. Direct lateral approach

Direct lateral approach also called as the trans-gluteal approach initially described by Kocher in 1903 [26] popularised by Hardinge in the modern age [27] gives good exposure to the hip

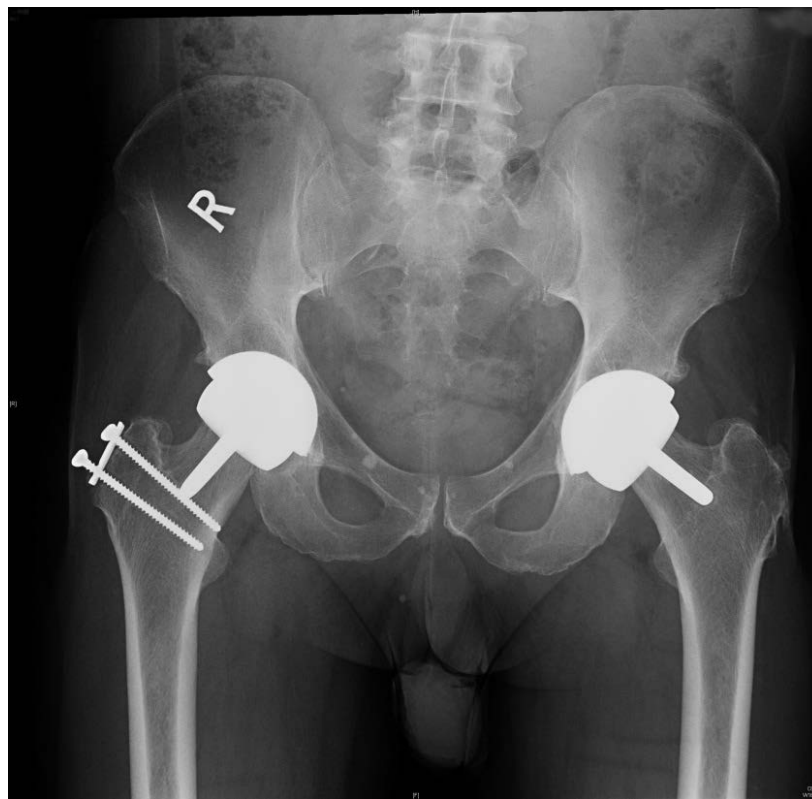


Figure 4. Post-operative X ray of patient showing Hip resurfacing done through Posterior approach (Left Hip) and Trochanteric flip approach (Right hip), note the re-attachment of the osteotomy with screws and loosening of the lower screw.

joint preserving most of gluteus medius minimus and vastus lateralis, and the vascularity. It exposes the femur well with good access to the joint.

a. Key steps

Position: This can either be done on lateral or supine position

Incision: from mid point of greater trochanter longitudinally along the femoral shaft extending around 8-10 cm with proximal extension up to anterior superior iliac spine. [27]

Incision: Usually it is made about 7-10 cm below the tip of the greater trochanter along the anterior border of the femur.

Soft tissue dissection: Gluteal fascia and ilio tibial band divided and plane between tensor fascia late and gluteus maximus is identified. Gluteus medius incised and approach via gluteus medius and vastus muscles.

Internervous plane: As the gluteus medius tendon and muscle fibres and the vastus lateralis muscles are split there is no true internervous plane. However it is important are split protect the superior gluteal nerve by making the incision distal to the point which it enters the muscle.

Dislocation: Leg can be externally rotated and abducted for dislocation [27].

Closure: Ilio tibial ligament initially re attached followed by gluteus medius suturing.

b. Key advantages

This approach gives good access to the hip and yet preserves vascularity and minimise risk of damage to sciatic nerve as compared to the posterior approach.

c. Key limitations

Damage to gluteal muscle mainly medius can increase recovery time,

d. Specific complications

Complications are relatively rare with low dislocation rates. Heterotopic ossification may be a problem in selected cases. [28]

e. Common surgical procedures

Total hip replacements, hip resurfacing, [29] trauma, and many procedures can be done via this.

f. Modifications

Modifications include the trans gluteal approach. [30] This has been compared with Watson Jones approach and appear to be a good alternative to the traditional approach. [31] According to some authors the surgical exposure can be improved by modifying the way muscle fibres are split, fascia is cut retractors are placed and closing the wound. [32]

Lateral trans trochanteric approach was initially described in 1881 by Ollier and popularised by Sir John Charnley provide a good exposure hip joint is mainly used in revision arthroplasties. [33]

7. Posterior approach

Also called, as the Southern approach is one of the commonest approaches used by the orthopaedic surgeons at present.

a. Key Steps

Position: Mostly done in lateral position

Incision: standard incision is 10-15 cm long curve-linear extending from posterior superior iliac spine to greater trochanter and extending down in a variable distance along the shaft of the femur. The modern incisions are shorter than the standard. As this can be extended if needed it is sensible to initially make a smaller incision and extend if needed.

Soft tissue dissection: Initially fascia lata and vastus lateralis is cut. The gluteus maximus fibres are split. Then the hip is internally rotated and short external rotators are cut after holding them with stay sutures.

Obturator internus and piriformis is detached and reflected backwards to protect the sciatic nerve.

Internervous plane: As we split through the fibres of gluteus maximus rather than between muscle planes it is difficult to find a true internervous plane. However as the nerve enters the muscle medial to the split the muscle denervation is unlikely.

Arthrotomy: Capsule is incised with a T shaped incision

Closure: Capsular closure is described but the practicality is an issue mainly following hip arthroplasty procedures.

It is important re-attached the external rotators and obturator internus and piriformis.

b. Key advantages

This is a good approach that provides excellent exposure to both acetabulum and the femoral head and neck equally making it easier to surgical procedures well.

c. Key Limitations

Due to the possibility that blood supply may get damaged resulting in AVN has limited it's used in conservative hip surgery such as open hip debridement, open surgery for hip impingement and use of this in paediatric population is not recommended.

d. Specific Complications

The posterior approach has specific complications these are

1. Damage to sciatic nerve, which could be either stretching which recover usually, or permanent damage, which will result in a foot drop.
2. Damage to inferior gluteal vessels, branches of profunda femoris vessels and rarely femoral vessels.
3. Invariably branches of medial circumflex femoral artery are cut during this approach, which can theoretically give rise to AVN of femoral head and neck. This does not matter in total hip replacement as the head and neck is removed but in conservative procedures including hip resurfacing arthroplasty. Many authors have challenged however the clinical implications of this blood flow drop. [34]- [37] Some argue the blood supply drop is transient which may recover during post-operative period. [38]

e. Common surgical procedures

This is in an approach commonly used to do Primary and revision total hip replacements, hip resurfacings, and other procedures such as open reduction of hip dislocations and fixation of acetabular fractures.

f. Modifications

Minimally invasive (MIS) posterior approach is a modification. This approach when compared with standard lateral approach has similar outcomes during early post-operative period such as surgical duration, blood loss and hospital stay but long term results such as Harris Hip score is higher in the MIS. [39] Similar results have been achieved when compared with postero-lateral approaches. [40] When compared with the standard posterior approach it was found

to be less blood loss, less post-operative pain and early recovery. [41] Gibson approach [42] is another modification and can be considered a poster-lateral type of approach.

8. Postero-lateral approach

Initially described by Langenback in 1874 [43] is another approach that can be used in hip arthroplasty surgery. Compared with trans trochanteric approach it is believed that this has less blood loss and shorter hospital stay. [44]

6. Medial approaches are mainly used developmental dysplasia of the hip, in young patients and children as it protects most soft tissues and blood supply to the hip joint.

The medial approaches can be further sub classified to antero-medial, postero-medial (Ferguson) and Ludloff's approach

- a. Antero-medial approach,
- b. Postero-medial approach
- c. Ludloff's approach

These approaches are mainly used in children to treat DDH and open reduction of CDH and other conservative procedures. [45], [46]

The minimally invasive approaches to the hip joint used in hip arthroplasty.

Due to ion crease blood loss, slow recovery increase intra operative time, and delay in discharge more and more orthopaedic surgeons have been keen to develop minimally invasive approaches. These are usually modifications of existing approaches so that a surgeon preferring a certain standard approach can try the minimally approaches. The commonest minimally invasive approaches are minimally invasive antero lateral, minimally invasive direct lateral [24] minimally invasive posterior, minimally invasive anterior

The principles include shorter skin incision either single or multiple, minimal soft tissue dissection, without compromising the access or the quality of the surgery.

Optimal incision is around 8-9 cm either used as single or two separate incisions. [47] [48]

The results suggests better immediate outcomes and similar long term out comes in total hip arthroplasty for antero lateral MIS [23], postero-lateral MIS [49]

The reasons for developing Modified and modern approaches to the hip joint was mainly driven by the concept of minimal invasive surgeries being developed through out the surgical fields as they are supposed to be less invasive with low intra-operative complications such as low blood loss, less tissue dissection and less operative time, with early recovery, early mobilisation and early discharge from hospital. With development of smaller implants better instrumentation, better pre-operative planning, use of navigation, and better intra-operative imaging it has been possible to develop and use minimally invasive approaches to major

surgeries like total hip arthroplasty or revision hip surgery. However at present there is debate over the long term outcomes quality of surgery including implant positioning and learning curve for minimally invasive approaches over standard surgical approach. The answers to these questions will come from the research done comparing minimally invasive approaches versus the standard surgical approaches.

9. Conclusion

In conclusion it is important note that there are multiple surgical approaches to the hip joint and some better suited for arthroplasty and some for more conservative hip surgery. A checklist of factors one should consider before an approach is selected is,

1. What type of surgery? Is it conservative or hip arthroplasty?
2. If is arthroplasty, is it Total hip replacement, Hip resurfacing or a Revision hip replacement?
3. Age of patient? Adult young adult or a child
4. What part of the hip do you need the best exposure to? Acetabular socket, Femoral head and neck or both
5. Surgeon's preference and competence in doing the approach.
6. Whether the surgery is elective or trauma/emergency.

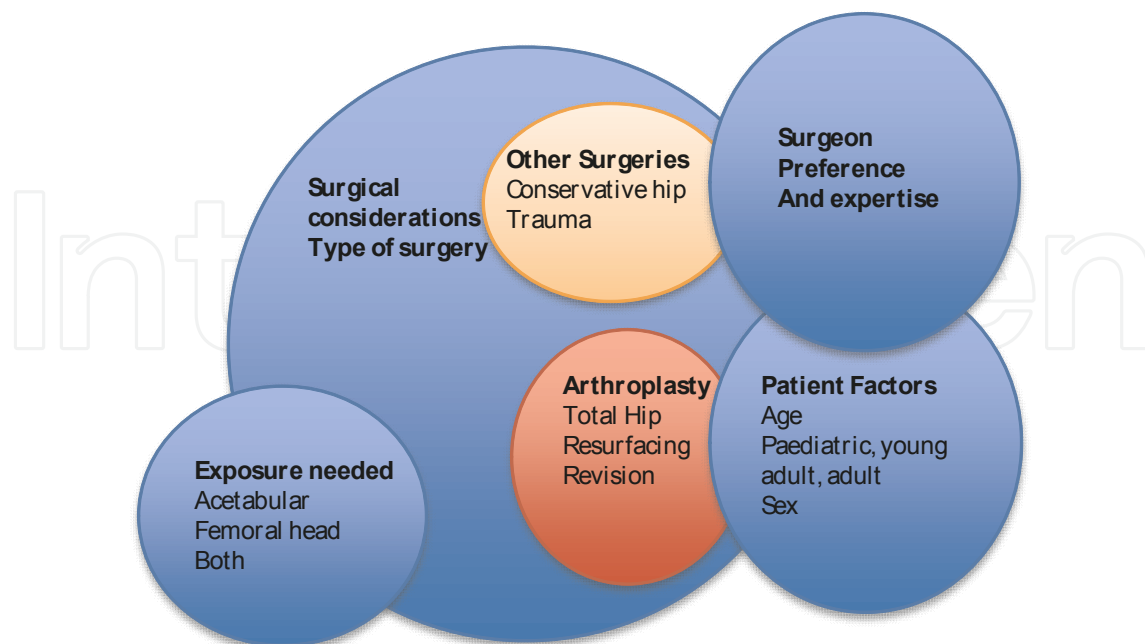


Figure 5. Show different factors that has to be taken to consideration when selecting

The relationship between the outcome of surgery and the surgical approach is still less understood, even though many comparison studies have been done. [50] [51] The final decision on what surgical approach to use is a clinical decision that has to be made by the operating surgeon.

Author details

Hiran Amarasekera

Orthopaedic Research Fellow/ PhD Student, Warwick Medical School, University of Warwick, And University Hospital of Coventry and Warwickshire, UK

References

- [1] Gerdesmeyer, L, Gollwitzer, H, Bader, R, & Rudert, M. Surgical approaches in hip resurfacing]. *Orthopade* (2008).
- [2] Ganz, R, Gill, T. J, Gautier, E, Ganz, K, Krugel, N, & Berlemann, U. Surgical dislocation of the adult hip: A TECHNIQUE WITH FULL ACCESS TO THE FEMORAL HEAD AND ACETABULUM WITHOUT THE RISK OF AVASCULAR NECROSIS. *J Bone Joint Surg Br* (2001). B-, 8, 1119-24.
- [3] Hunter, S. C. Southern hip exposure. *Orthopedics* (1986).
- [4] Jerosch, J, Theising, C, & Fadel, M. E. Antero-lateral minimal invasive (ALMI) approach for total hip arthroplasty technique and early results. *Arch Orthop Trauma Surg* (2006).
- [5] McMinn, D. J, Daniel, J, Pynsent, P. B, & Pradhan, C. Mini-incision resurfacing arthroplasty of hip through the posterior approach. *Clin Orthop Relat Res* (2005). 441, 91-8.
- [6] Khan, R. M, Cooper, G, & Hull, J. B. Hip resurfacing through a modified anterolateral approach, as compared with the Ganz trochanteric flip osteotomy: a two year follow-up study. *Hip Int* (2009).
- [7] Lusskin, R, Goldman, A, & Absatz, M. Combined anterior and posterior approach to the hip joint in reconstructive and complex arthroplasty. *J Arthroplasty* (1988).
- [8] Smith-petersen, M. N. Approach to and exposure of the hip joint for mold arthroplasty. *J Bone Joint Surg Am* (1949). A-, 1, 40-6.
- [9] Light, T. R, & Keggi, K. J. Anterior approach to hip arthroplasty. *Clin Orthop Relat Res* (1980).

- [10] Kreuzer, S, Leffers, K, & Kumar, S. Direct anterior approach for hip resurfacing: surgical technique and complications. *Clin Orthop Relat Res* (2011).
- [11] Judet, J, & Judet, H. Anterior approach in total hip arthroplasty]. *Presse Med* (1985).
- [12] Horne, P. H, & Olson, S. A. Direct anterior approach for total hip arthroplasty using the fracture table. *Curr Rev Musculoskelet Med* (2011).
- [13] Lovell, T. P. Single-incision direct anterior approach for total hip arthroplasty using a standard operating table. *J Arthroplasty* (2008). Suppl:64-8., 23-7.
- [14] Goytia, R. N, Jones, L. C, & Hungerford, M. W. Learning curve for the anterior approach total hip arthroplasty. *J Surg Orthop Adv* (2012).
- [15] Barton, C, & Kim, P. R. Complications of the direct anterior approach for total hip arthroplasty. *Orthop Clin North Am* (2009).
- [16] Bhargava, T, Goytia, R. N, Jones, L. C, & Hungerford, M. W. Lateral femoral cutaneous nerve impairment after direct anterior approach for total hip arthroplasty. *Orthopedics* (2010).
- [17] Bender, B, Nogler, M, & Hozack, W. J. Direct anterior approach for total hip arthroplasty. *Orthop Clin North Am* (2009).
- [18] Oinuma, K, Eingartner, C, Saito, Y, & Shiratsuchi, H. Total hip arthroplasty by a minimally invasive, direct anterior approach. *Oper Orthop Traumatol* (2007).
- [19] Rachbauer, F. Minimally invasive total hip arthroplasty. Anterior approach]. *Orthopade* (2006).
- [20] Hallert, O, Li, Y, Brismar, H, & Lindgren, U. The direct anterior approach: initial experience of a minimally invasive technique for total hip arthroplasty. *J Orthop Surg Res* (2012).
- [21] Watson-Jones. Fractures of the neck of femur. *British Journal of surgery* (1936). 23, 787-808.
- [22] Pawlowski, Z, Bohatyrewicz, A, Czajkowski, A. A, Kominiak, P, & Gusta, A. Early abductor muscle strength after total hip replacement performed by antero-lateral approach]. *Chir Narzadow Ruchu Ortop Pol* (2002).
- [23] Walde, T. A, Blattgerste, D, Sehmisch, S, Kuttler, W, Walde, H. J, & Koster, G. Early results and patient satisfaction after total hip arthroplasty using a minimally invasive anterolateral approach. *Hip Int* (2009).
- [24] Spaans, A. J. van den Hout JA, Bolder SB. High complication rate in the early experience of minimally invasive total hip arthroplasty by the direct anterior approach. *Acta Orthop* (2012).
- [25] Amarasekera Surface Replacement of the Hip Joint. In: K.Fokter S, ed. *Recent Advances in Hip and Knee Arthroplasty*, 1 ed. Croatia: Intech, (2012). , 2012, 181-90.

- [26] Kocher, T. In: *Text book of operative surgery*. London: Adams and Charles Blac, (1903).
- [27] Hardinge, K. The direct lateral approach to the hip. *J Bone Joint Surg Br* (1982).
- [28] Foster, D. E, & Hunter, J. R. The direct lateral approach to the hip for arthroplasty. Advantages and complications. *Orthopedics* (1987).
- [29] Gerdesmeyer, L, Gollwitzer, H, Diehl, P, Buttgereit, B, & Rudert, M. The minimally invasive anterolateral approach combined with hip onlay resurfacing. *Oper Orthop Traumatol* (2009).
- [30] Bauer, R, Kerschbaumer, F, Poisel, S, & Oberthaler, W. The transgluteal approach to the hip joint. *Arch Orthop Trauma Surg* (1979).
- [31] Eyb, R. Clinical results following the transgluteal and anterolateral (Watson-Jones) approach to hip prosthesis implantation]. *Z Orthop Ihre Grenzgeb* (1985).
- [32] Warren, P. J, Jennings, G. J, & Fletcher, M. D. Improvement in surgical exposure of the hip using the direct lateral approach. *Ann R Coll Surg Engl* (2002).
- [33] Mulliken, B. D, Rorabeck, C. H, Bourne, R. B, & Nayak, N. The surgical approach to total hip arthroplasty: complications and utility of a modified direct lateral approach. *Iowa Orthop J* (1995). 15, 48-61.
- [34] Amarasekera, H. W, Costa, M. L, Foguet, P, Krikler, S. J, Prakash, U, & Griffin, D. R. The blood flow to the femoral head/neck junction during resurfacing arthroplasty: A COMPARISON OF TWO APPROACHES USING LASER DOPPLER FLOWMETRY. *J Bone Joint Surg Br* (2008).
- [35] Amarasekera, H. W, Costa, M. L, Parsons, N, Achten, J, Griffin, D. R, Manktelow, S, & Williams, N. R. SPECT/CT bone imaging after hip resurfacing arthroplasty: is it feasible to use CT attenuation correction in the presence of metal implants? *Nucl Med Commun* (2011).
- [36] Campbell, P, Mirra, J, & Amstutz, H. C. Viability of femoral heads treated with resurfacing arthroplasty. *J Arthroplasty* (2000).
- [37] Amarasekera, H, Costa, M, Prakash, U, Krikler, S, Foguet, P, & Griffin, D. FEMORAL BLOOD FLOW DURING HIP RESURFACING: A COMPARISON OF TWO APPROACHES USING LASER DOPPLER FLOW MEASUREMENT. *Journal of Bone & Joint Surgery, British* 2012B-SUPP III:148.
- [38] Amarasekera, H, Roberts, P, Costa, M, Parsons, N, Achten, J, Griffin, D, & Williams, N. Scintigraphic assessment of bone status at one year following hip resurfacing: comparison of two surgical approaches using SPECT-CT scan. *Bone and Joint Research* (2012).
- [39] Schleicher, I, Haas, H, Adams, T. S, Szalay, G, Klein, H, & Kordelle, J. Minimal-invasive posterior approach for total hip arthroplasty versus standard lateral approach. *Acta Orthop Belg* (2011).

- [40] Fink, B, & Mittelstaedt, A. Minimally invasive posterior approach for total hip arthroplasty]. *Orthopade* (2012).
- [41] Fink, B, Mittelstaedt, A, Schulz, M. S, Sebens, P, & Singer, J. Comparison of a minimally invasive posterior approach and the standard posterior approach for total hip arthroplasty A prospective and comparative study. *J Orthop Surg Res* (2010).
- [42] Gibson, A. Posterior exposure of the hip joint. *J Bone Joint Surg Br* (1950). B-, 2, 183-6.
- [43] Pellegrini VJaECM. Surgical approaches to the hip. In: Evarts C, ed. *Surgery of the Musculoskeletal system*. NewYork: Churchill Livingstone, (1990).
- [44] Aglietti, P, & Salvati, E. The postero-lateral approach for total hip prosthesis. *Ital J Orthop Traumatol* (1981).
- [45] Di Mascio LCarey-Smith R, Tucker K. Open reduction of developmental hip dysplasia using a medial approach: a review of 24 hips. *Acta Orthop Belg* (2008).
- [46] Broughton, N. S, Graham, H. K, Nattrass, G. R, Torode, I. P, Marshall, P. D, Sullivan, O, & Ludloff, M. s medial approach for open reduction of congenital dislocation of the hip. *J Bone Joint Surg Br* (1997).
- [47] Noble, P. C, Pfluger, G, Junk-jantsch, S, Thompson, M. T, Alexander, J. W, & Mathis, K. B. The optimal skin incision for minimally invasive total hip arthroplasty performed via the anterolateral approach. *J Arthroplasty* (2012).
- [48] Wetzel, R, & Dorsch, M. Minimally invasive approach to implantation of a hip endoprosthesis]. *Orthopade* (2006).
- [49] Varela Egocheaga JRSuarez-Suarez MA, Fernandez-Villan M, Gonzalez-Sastre V, Varela-Gomez JR, Murcia-Mazon A. [Minimally invasive posterior approach in total hip arthroplasty. Prospective randomised trial]. *An Sist Sanit Navar* (2010).
- [50] Barber, T. C, Roger, D. J, Goodman, S. B, & Schurman, D. J. Early outcome of total hip arthroplasty using the direct lateral vs the posterior surgical approach. *Orthopedics* (1996).
- [51] Jolles, B. M, & Bogoch, E. R. Posterior versus lateral surgical approach for total hip arthroplasty in adults with osteoarthritis. *Cochrane Database Syst Rev* (2006). CD003828.

