

# We are IntechOpen, the world's leading publisher of Open Access books Built by scientists, for scientists

6,900

Open access books available

186,000

International authors and editors

200M

Downloads

Our authors are among the

154

Countries delivered to

TOP 1%

most cited scientists

12.2%

Contributors from top 500 universities



WEB OF SCIENCE™

Selection of our books indexed in the Book Citation Index  
in Web of Science™ Core Collection (BKCI)

Interested in publishing with us?  
Contact [book.department@intechopen.com](mailto:book.department@intechopen.com)

Numbers displayed above are based on latest data collected.  
For more information visit [www.intechopen.com](http://www.intechopen.com)



# Cataract Surgery in Patients with a History of Retinoblastoma and Melanoma

A.C. Scheffler and T.G. Murray

*Bascom Palmer Eye Institute, Department of Ophthalmology,  
University of Miami Miller School of Medicine  
USA*

## 1. Introduction

Both pediatric and adult malignant intraocular ocular tumors are often treated with external beam radiation or brachytherapy. Because the lens is the most radiosensitive ocular structure, cataracts are a common occurrence after such treatments. Some studies report up to an 87% occurrence of cataracts within 3 years in retinoblastoma patients treated with external beam radiation (Blach et al., 1996; Fontanesi et al., 1996). In the Collaborative Ocular Melanoma Study, the largest multicenter prospective randomized trial ever performed for uveal melanoma patients, 83% of patients had developed cataracts by 5 years post-treatment (Collaborative Ocular Melanoma Study Group, 2007). Because many patients treated for intraocular tumors survive for extended periods and have the capacity for excellent vision, cataract surgery is an important part of the treatment algorithm for these patients. However, this group of patients poses a unique set of surgical challenges not present in standard cataract patients. In this chapter, we will review the incidence, surgical techniques, visual and anatomic outcomes, and complications for this unique group of patients.

## 2. Cataracts in retinoblastoma patients

### 2.1 Epidemiology

#### 2.1.1 Incidence

Cataract is a well-known complication after radiation to the eye after all forms of radiation. Many studies have indicated that after external beam radiation therapy, cataracts can develop after doses as low as 2 Gy (Dymlacht, 2006; Gordon, 1995). For over 100 years, external beam radiation has been used to treat retinoblastoma because in certain cases, it can achieve tumor control and enable retention of vision when other treatment modalities have failed (Chodick et al., 2009). Although other treatment modalities such as chemotherapy and laser are more commonly used for retinoblastoma patients at the present time, external beam radiation is still used as salvage therapy in advanced cases. Furthermore, many patients who received external beam radiation in the past are still under the care of ophthalmic oncologists and are currently in need of or will need cataract surgery in the future. Chodick et al. examined the records of a series of 753 patients who were diagnosed with retinoblastoma from 1914 to 1984. Only one patient who had not had radiotherapy had

cataract surgery while 51 cataract surgeries were performed in patients who had had radiation. Overall, Kaplan-Meier analysis demonstrated that after 40 years of follow-up, 77% of eyes with 2 or 3 radiotherapy treatments underwent cataract surgery. The estimated survival time to cataract surgery in eyes that did not undergo radiation was 71.7 years compared to 50.8 years and 31.6 years for eyes treated with one and 2 or 3 radiotherapy treatments, respectively. Of note, many patients in this study underwent older forms of treatment with more radiation scatter such as orthovoltage radiation and cobalt plaques. Nonetheless, the incidence of cataracts requiring cataract surgery in retinoblastoma survivors was high and underscored the necessity for ongoing ophthalmic follow-up in these patients.

### **2.1.2 Risk factors**

In the study by Chodick et al., the clinical risk factors that contributed to cataract development requiring cataract surgery were: increased number of external beam radiation treatments, diagnosis of retinoblastoma after the first year of life (versus earlier), and radiation dose. No other studies published up until this point have had extended follow-up or enough power to assess the risk factors for cataract development adequately.

## **2.2 Visual and anatomic results**

### **2.2.1 Visual results**

There have been several studies examining the visual outcomes in retinoblastoma survivors who have undergone cataract surgery (Table 1).

The data from Table 1 suggests that visual outcomes in these patients can be surprisingly excellent. In particular, the studies by Miller et al. (2005), Payne et al. (2008), and Hoehn et al. (2010) reported good visual results and no major complications. Patients in this population have many other reasons to have poor visual outcomes including tumor involvement of the macula, radiation retinopathy, progressive retinal scarring from laser or cryotherapy treatments, and amblyopia.

### **2.3 Surgical approach and complications**

Controversies in pediatric cataract management include the surgical approach, management of the posterior capsule and anterior vitreous, and IOL implantation. Table 1 demonstrates that there has been a wide range of approaches to these controversies in retinoblastoma patients. Our group, Miller et al. (2005) reported good visual and anatomic results in 16 patients after ECCE/PPV/PCIOL. Payne et al. (2008) also reported good results with an ECCE approach with a capsulotomy, anterior vitrectomy, and IOL placed only in some patients. In contrast, Hoehn et al. (2010) reported outstanding results with only a lens aspiration and IOL with no posterior capsulotomy, deferring this procedure to a later EUA when needed.

The major concern for patients undergoing any intraocular procedure who have a history of retinoblastoma is tumor recurrence or the development of metastatic disease as a result of the surgery. Recurrences have been reported in series by Brooks et al. (1990), Honovar et al. (2005), Moshfeghi et al. (2005), and Osman et al. (2011). All of these series included patients who had short quiescent intervals from the time of attainment of local control of the retinoblastoma and cataract surgery, sometimes as short as 3 months. It seems that a longer quiescent interval is the only identifiable risk factor for this devastating complication. In patients with a short quiescent interval whose fundus cannot be visualized due to a dense

cataract, we strongly recommend enucleation rather than performing cataract surgery with its associated risk of tumor recurrence which may or may not be able to be adequately treated.

Author, Year	No. of eyes	Median Quiescent interval (Range)	Procedure (No. of eyes)	Median follow up, mos (range)	No. of RB recurrences	Visual outcome (No. of eyes)
Monge et al., 1986	2	30 mos (72 mos)	Asp ± PPV	(24-78)	0	6/18 (2)
Brooks et al., 1990	42	29 mos (17-144)	Asp or PPL	72 (6-178)	3	20/20-20/50 (19) 20/80-CF (12)
Portellos & Buckley, 1998	11	55 mos (16-88)	ECCE + caps+Ant Vtx + PCIOL	Mean 20 (6-39)	0	20/20-20/30 (6) 20/50-20/250 (5)
Madreperla et al., 2000	3	34 mos (9-40 mos)	Asp	(60-189)	0	20/60 (2); HM (1)
Bhattacharjee et al., 2003	1	84 mos	ECCE+Caps+PCIOL	144	0	20/30
Shanmugam et al., 2004	5	Minimum 24 mos	Phaco+caps+Ant Vtx+PCIOL	NA	0	>6/9 (4) at 6 wks
Sinha et al., 2004	9	Minimum 12 mos	Asp	(24-42)	0	"No improvement"
Miller et al., 2005	16	Minimum 18 mos	ECCE+PPV+PCIOL	Mean 66 (30-94)	0	20/20-20/40 (11) 20/200-20/400 (5)
Honovar et al., 2005	34	16 mos (3-54 mos)	ICCE; ECCE; PPL	72 (12-360)	5	>20/200 (12)
Moshfeghi et al., 2005	4	89 mos (12-172 mos)	NA	Mean 184 (60-339)	1	20/30; CF; HM; Enuc
Payne et al., 2008	12	35 mos (17-240)	ECCE ± caps ± Ant Vtx ± PCIOL	72 (13-148)	0	20/20-20/60 (6) 20/70-20/200 (2) CF (2) HM (2)
Hoehn et al., 2010	19	NA	Asp + IOL	Mean 58 (19-105)	0	20/20-20/60 (3) 20/70-20/200 (4) 20/400 (4) CF (5) HM (1) F+F (1) Enuc (1)
Osman et al., 2011	21	21.5 ms (3-164 mos)	ECCE or Asp ± caps ± Ant Vtx ± IOL	Mean 90 ± 69	3	20/20 (4) 20/20-20/200 (9) <20/200 (2) NLP (3) NA (3)

Table 1. Reports of cataract surgery in patients with a history of retinoblastoma. Modified and adapted from Payne et al. (2009). NA, Data not reported; Ant Vtx, anterior vitrectomy; ECCE, extracapsular cataract extraction; ICCE, intracapsular cataract extraction; IOL, posterior chamber intraocular lens; Phaco, phacoemulsification; PPL, pars plana lensectomy; NLP, no light perception; HM, hand motion; CF, count fingers.

### 3. Cataracts in uveal melanoma patients

#### 3.1 Epidemiology

##### 3.1.1 Incidence

There have been several studies examining the incidence and risk factors for the development of cataracts after Iodine 125 brachytherapy, the most commonly employed treatment for uveal melanoma in the United States (Table 1). Taking these studies as a group, approximately 40% of all patients have been reported to develop cataracts with most studies having a follow-up period of 5 years. Among these studies, however, the Collaborative Ocular Melanoma Study trial was the only prospective, multicenter trial and the rate of cataract development in this study was much higher, 83% by 5 years.

Author, Year	No. of patients at risk/No. of cataracts	Rate of cataract development	Follow-up time Median (Range)	Time to cataract development Median (Range)	Risk factors for cataract development
Garretson et al., 1987	26/3	NA	Mean 45 mos ( $\geq 2$ yrs)	NA	NA
Bosworth et al., 1988	58/13	NA	Mean 48.7 (23-112)	NA	NA
Lean et al., 1990	56/20	NA	Mean 39 mos (20-57)	NA	NA
Mameghan et al., 1992	53/4	NA	NA	NA	NA
Quivey et al., 1993	239/33	25-50% by 5 yrs	NA, (2-10 yrs)	9-81 mos	NA
Shields et al., 2002	270/NA	2% at 2 yrs, 6% at 5 yrs	NA	NA	NA
Bechrakis et al., 2002	152/5	28%	33 mos	NA	NA
Fontanesi et al., 1993	144/43	NA	46 mos (25-90)	3-53 mos	Tumor location
Puusari et al., 2004	96/65	2% by 2 yrs	NA	Median 18 mos	Dose to lens, age, diabetes
Puusari et al., 2004	89/57	69% by 3 yrs	3.5 yrs (0.3-10.4)	<1-8 yrs	NA
Lumbroso-Le Rouic et al., 2004	NA	21% by 2 yrs, 50% by 5 yrs	NA	NA	Gender, age, diameter
Stack et al., 2005	92/9	11%	31 mos (4-86)	NA	NA
COMS, 2007	538/362	83% by 5 yrs	NA (data not provided in this format)	2.5 yrs (6 mos-5 yrs)	Age, Baseline tumor size, Dose to lens
Meta-analysis	1543/614	40%	-	-	-

Table 2. Rates of Cataract Development after Cataract from Iodine 125 Brachytherapy for Uveal Melanoma. Updated and Adapted from Collaborative Ocular Melanoma Study Group (2007). NA, Data not reported.

### 3.1.2 Risk factors

The number of studies reporting risk factors for cataract development after Iodine 125 brachytherapy is limited. Overall, a review of the literature indicates that cataractogenesis is likely a function of tumor size, tumor location, radiation dose, and patient age. There appears to be no obvious advantage to any particular form of radiation (i.e. Cobalt 60, Ruthenium 106, proton beam therapy) (Collaborative Ocular Melanoma Study, 2007).

## 3.2 Visual and anatomic results

### 3.2.1 Visual results

Several studies have reported on visual acuity results after cataract surgery. In the Collaborative Ocular Melanoma Study, in patients with medium-sized tumors undergoing cataract surgery, the median best corrected visual acuity at baseline was 20/25 (Collaborative Ocular Melanoma Study Group, 2007). In the group that underwent cataract surgery, the median visual acuity before surgery was 20/125 (range 20/25 < 20/1600) and median visual acuity at the study visit immediately after cataract surgery was 20/50 (range 20/20-20/1600). In the study, 32 of the 48 eyes (66%) had improved vision of greater than or equal to 2 lines, 13 eyes (27%) remained stable, and 3 (6%) had decreased vision of greater than or equal to 2 lines at final follow-up. Figure 1 demonstrates the change in visual acuity in the 3 months after cataract surgery in patients in the Collaborative Ocular Melanoma Study.

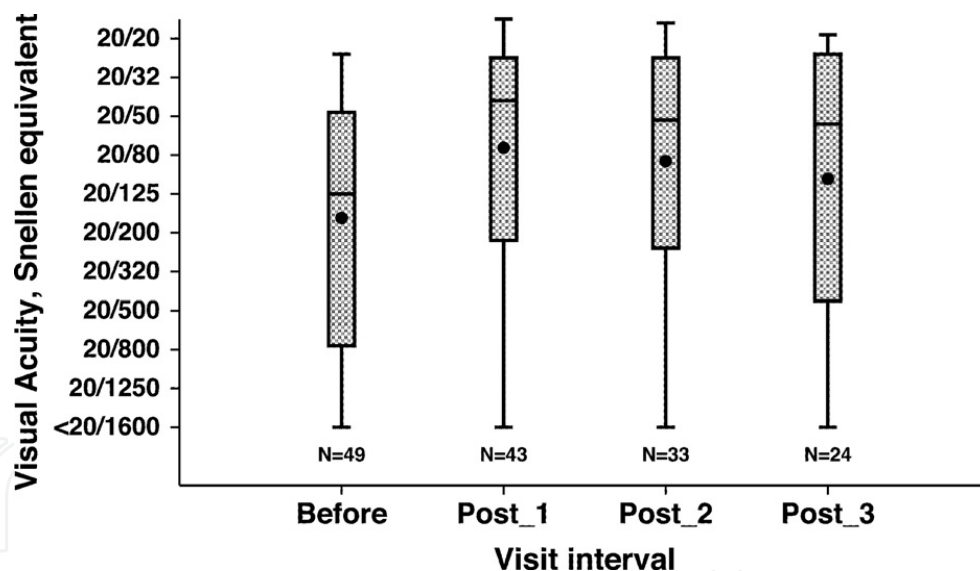


Fig. 1. Patients' visual acuity before and in the 3 visits after cataract surgery in the Collaborative Ocular Melanoma Study. The dot represents the mean of the box and the range of the box extends from the 25<sup>th</sup> percentile to the 75<sup>th</sup> percentile. The whiskers extend up to 1.5 times with interquartile range from each end of the box. Reproduced with permission from Collaborative Ocular Melanoma Study (2007).

Our group investigated visual acuity outcomes in patients undergoing cataract surgery with injection of intravitreal triamcinolone injection (Cebulla et al., 2008). In this study, 51 eyes of 49 patients with a history of choroidal nevi or uveal melanoma underwent cataract surgery with injection of intravitreal triamcinolone (IVTA) during surgery. There were 30 patients



who had had a history of melanoma treated with Iodine-125 brachytherapy in the cohort. Among the melanoma patients, the visual acuity at 6 months after surgery was worse in 2 patients (11%), stable in 2 patients (11%), and better in 14 patients (78%). At the final follow-up, vision was worse in 3 patients (10%), stable in 7 patients (24%), and better in 19 patients (66%). The mean number of Snellen lines gained after surgery was  $3.9 \pm 3.8$  (SD) at 6 months and  $3.1 \pm 3.8$  at last follow up (both  $p < 0.001$ ). This data compares favorably to the data outlined above and from Gragoudas et al. (1992), the largest study published to date in patients undergoing proton beam radiotherapy (Figures 2A-2G).

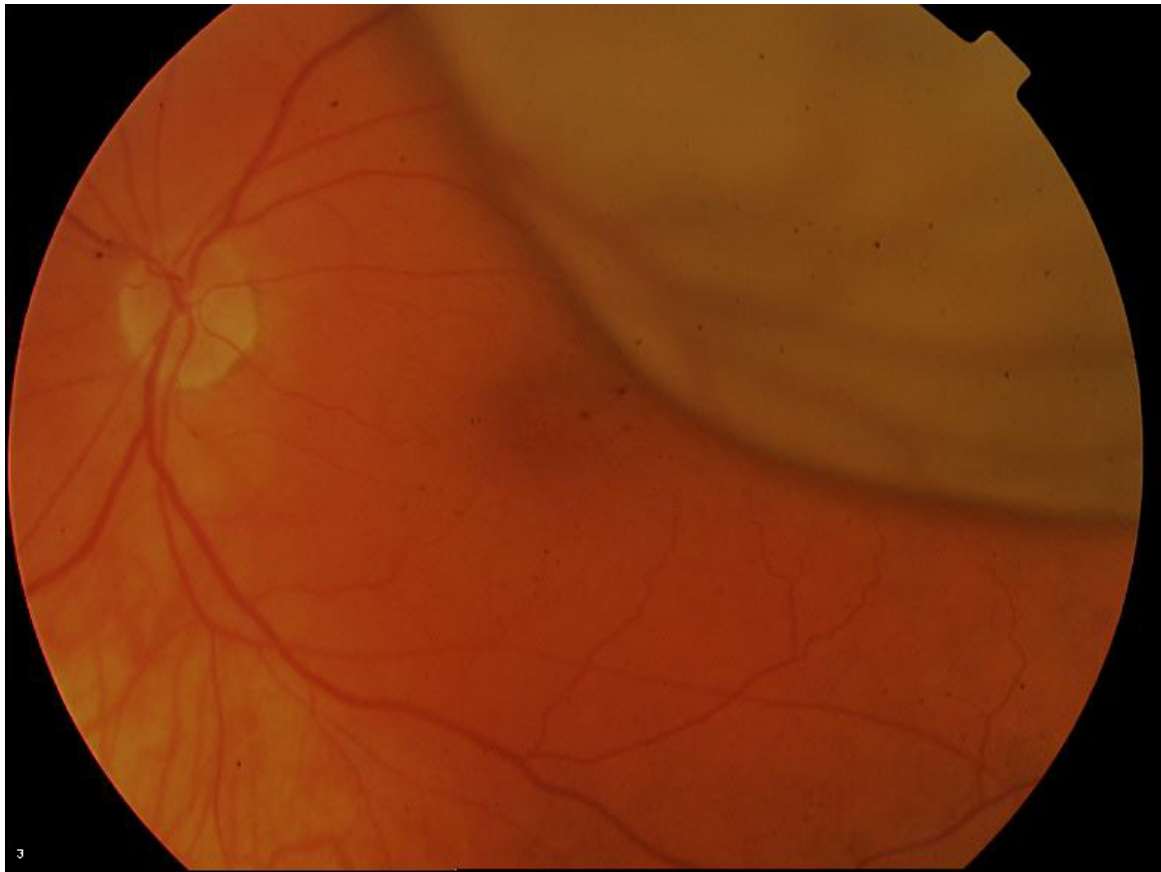


Fig. 2A. Patient with uveal melanoma at the time of diagnosis. Visual acuity was 20/40.

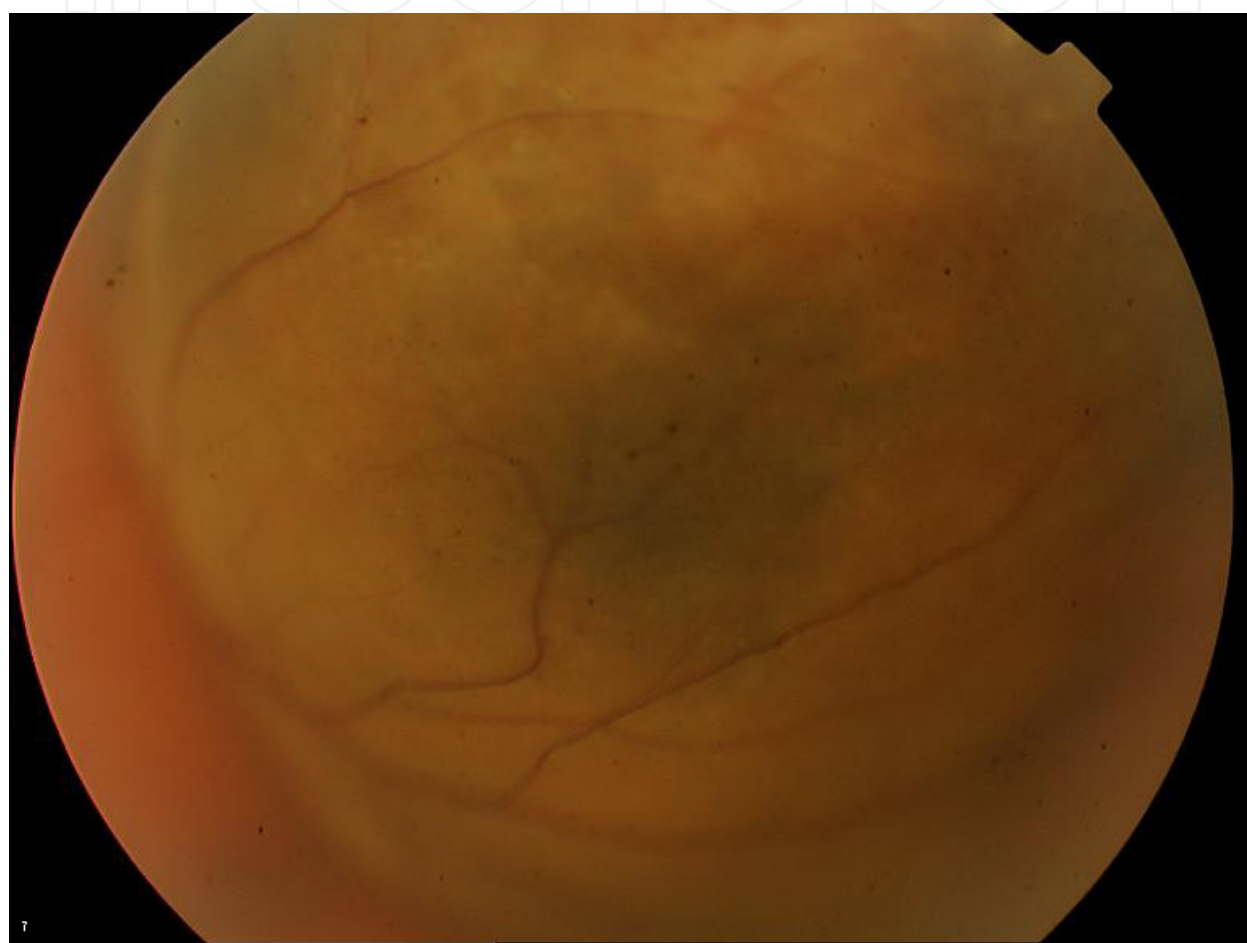


Fig. 2B. Photo of tumor apex of patient in Figure 2A at diagnosis.



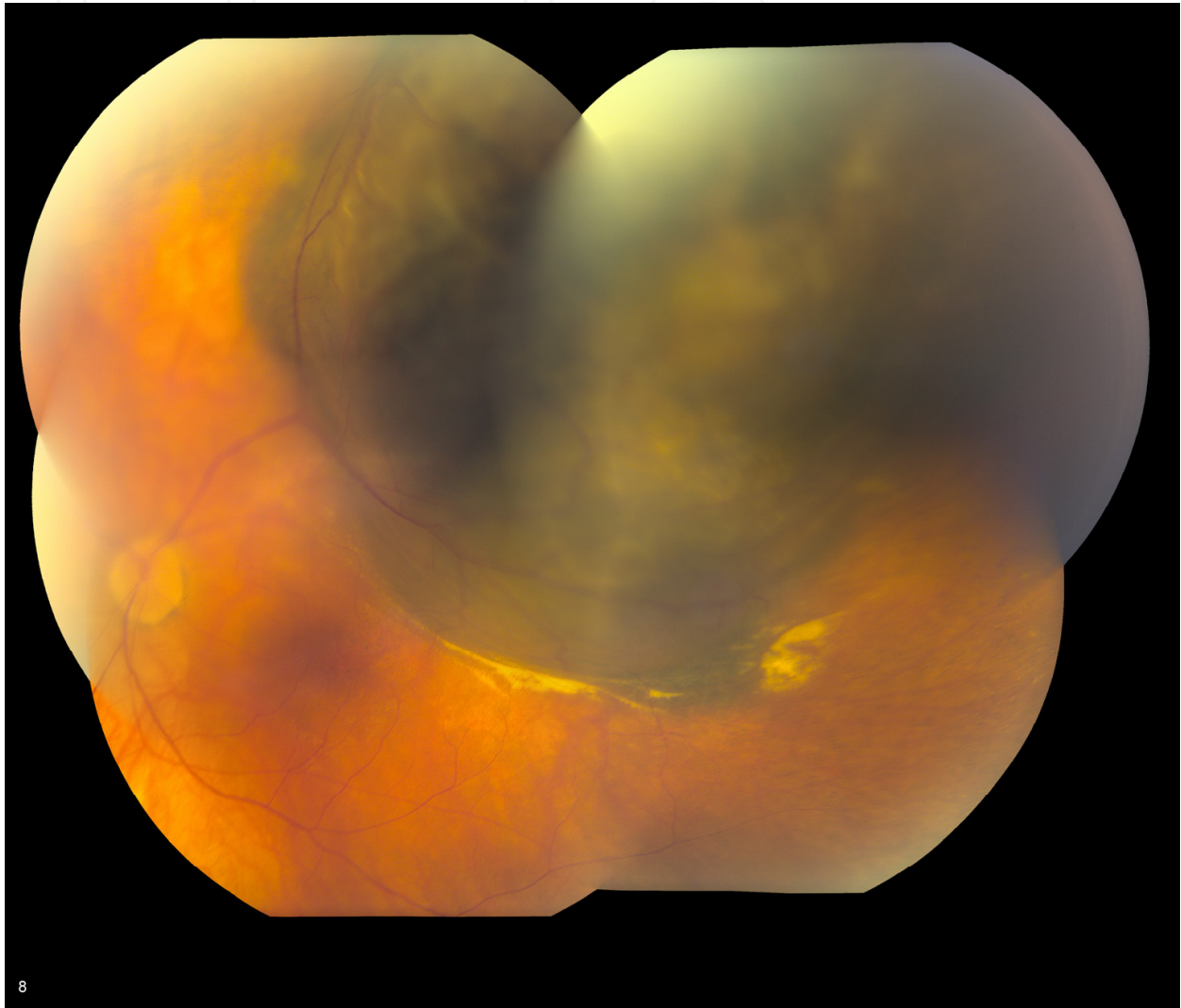


Fig. 2C. Patient in Figure 2A, 21 months after diagnosis. Note the yellow hue of the photograph and inability to visual the macula and optic nerve well to assess radiation retinopathy. The vision was 20/80. The patient subsequently underwent cataract surgery with intravitreal triamcinolone acetonide.

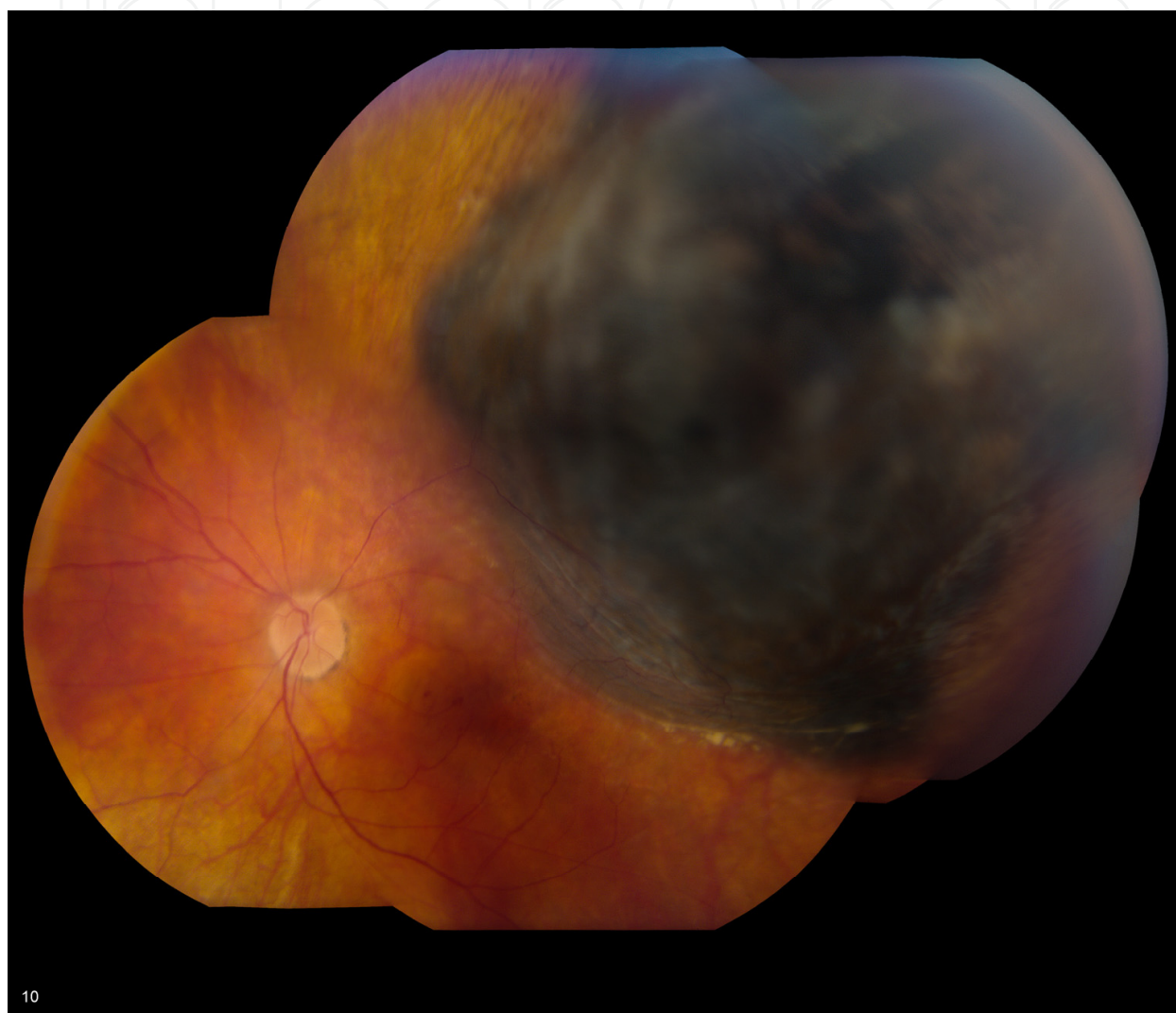


Fig. 2D. Patient in Figure 2C after cataract surgery. Note the increased ability to visualize the macula and optic nerve. The patient's best corrected vision improved to 20/60.

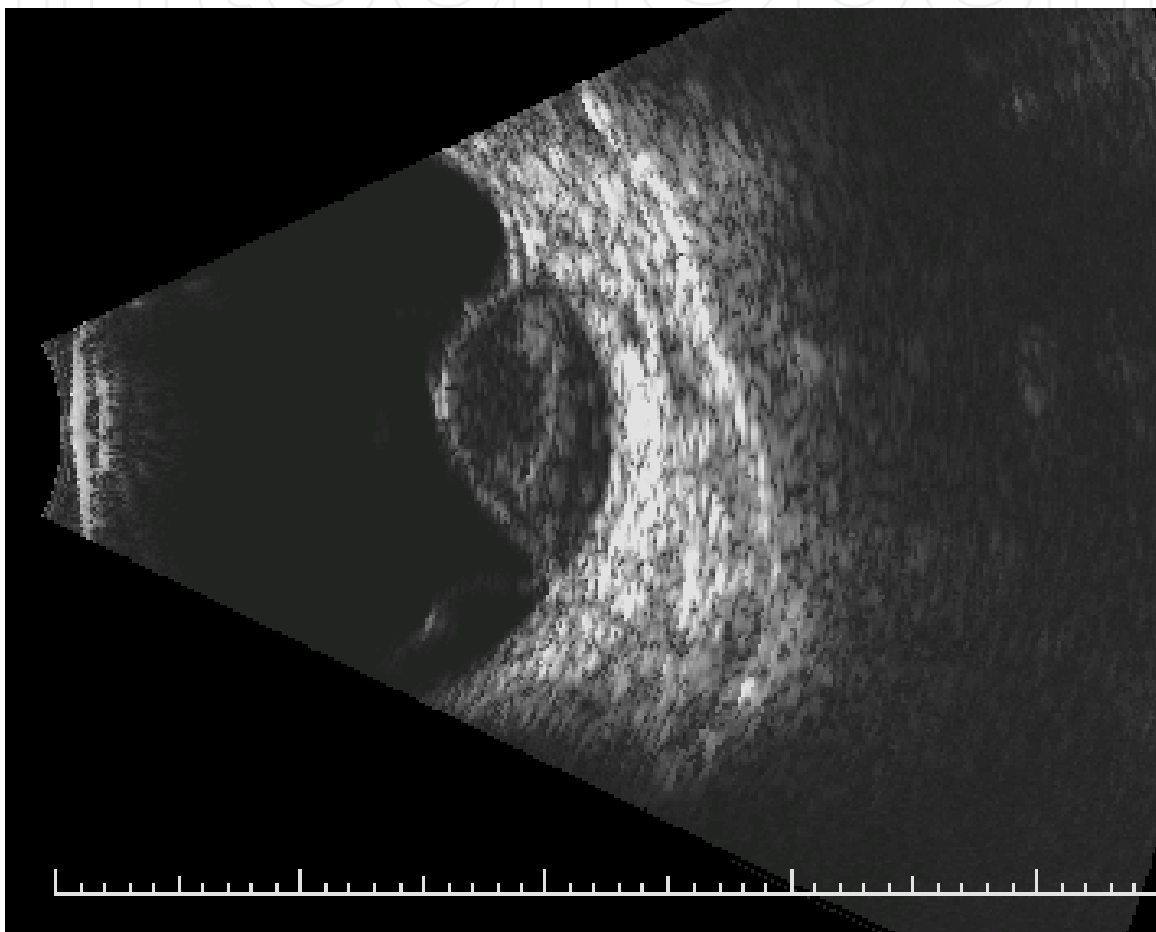


Fig. 2E. B-scan ultrasound of the tumor in Figure 2A at diagnosis with an apical height of 7.5 mm.

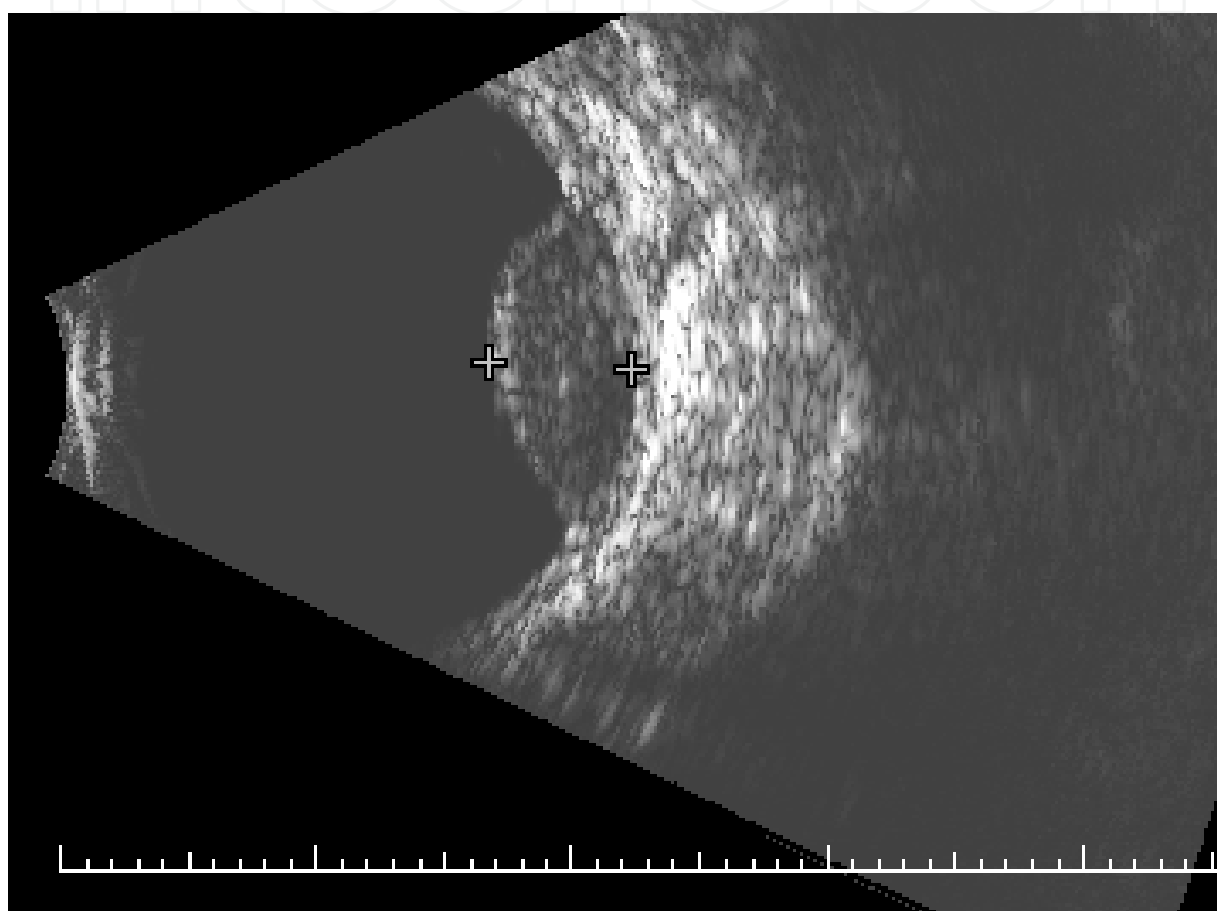


Fig. 2F. B-scan ultrasound of the tumor in Figure 2E after plaque surgery just before cataract surgery with an apical height of 5.8 mm.

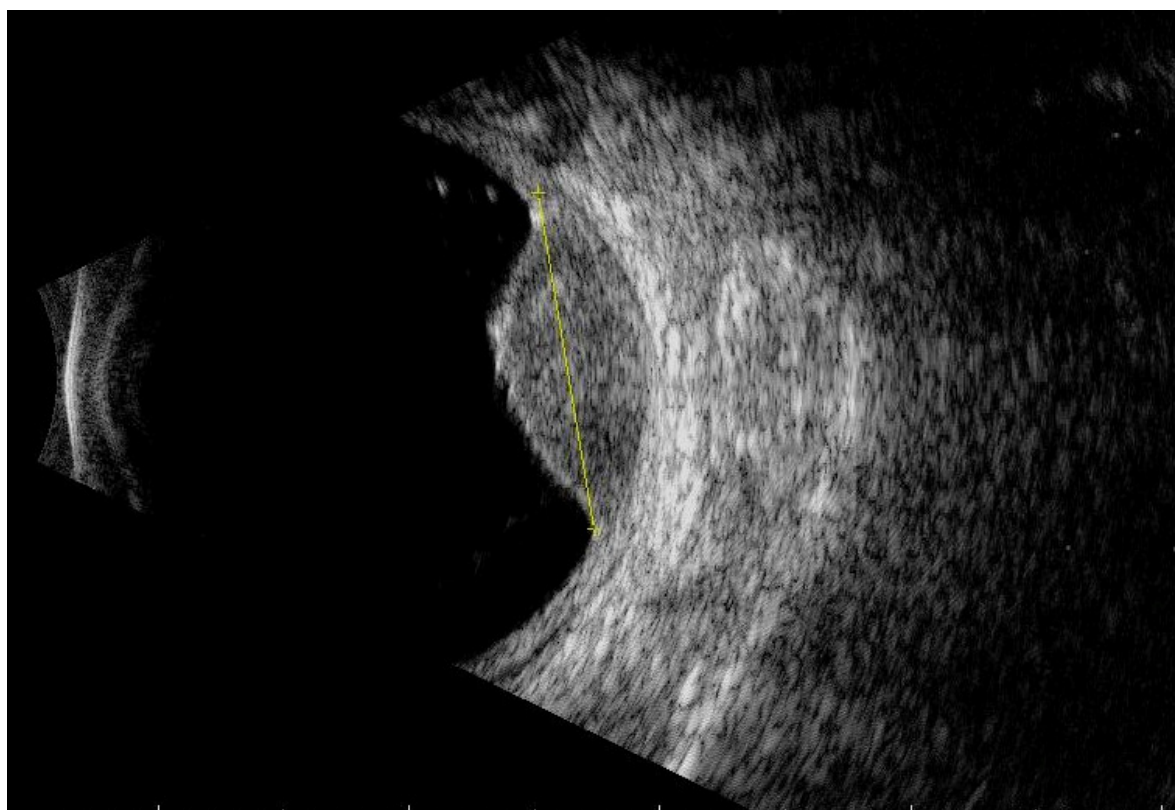


Fig. 2G. B-scan ultrasound of the tumor in Figure 2E eight months after cataract surgery. The tumor's apical height has decreased further to 5.6 mm.

### 3.2.2 Anatomic outcomes

The study by our group published in 2008 is the only study to our knowledge which has addressed the issue of anatomic changes induced in the treated melanoma as a result of cataract surgery (Cebulla et al., 2008). In this study, cataract surgery was combined with intravitreal triamcinolone (IVTA) at the time of surgery. Triamcinolone was chosen because it has been demonstrated to inhibit angiogenesis and to have direct antineoplastic activity (DiSorbo et al., 1986; Ebrahim et al., 2006). Furthermore, triamcinolone acetonide has been used to decrease radiation retinopathy and optic neuropathy in eyes with uveal melanoma treated with plaque therapy (Shields et al., 2006). In the study, echographic measurements of patients' tumors were followed in melanoma patients after cataract surgery-IVTA. This analysis demonstrated that 12 (46%) of 26 melanomas diminished in size over a median follow-up period of 11.8 months (range, 1-26 months). Regression analysis demonstrated a shallow but statistically significant ( $p=0.039$ ) negative slope in tumor height after cataract surgery-IVTA. Tumor growth did not occur in any patients. It was difficult to determine if this effect was due to a continuing effect from previous brachytherapy, although the median interval between plaque therapy and cataract surgery was 34 months (range 7-114 months), and the majority of the decrease in tumor height typically occurs within the first 2.5 years of tumor treatment. Ultimately, in long-term follow-up, the rate of tumor recurrence in this population may be lower than the published rates of 2.0% to 19.4% (Gragoudas et al., 1992; Wachtlin et al., 2000) due to the additional antitumoral effect from the IVTA approach. Further prospective studies are needed to address this question.



### 3.3 Complications

The complications reported in large studies of patients undergoing cataract surgery after plaque therapy for uveal melanoma are listed in Table 3.

Author	Complication	Incidence
Cebulla et al., 2008	Tumor recurrence	0 (0%)
	Posterior capsular opacity	8 (27%)
	Cystoid macular edema	1 (3%)
COMS et al., 2007	Cystoid macular edema	13 (27%)
	Neovascular glaucoma	6 (12%)
	Retinal detachment	1 (2%)
Wachtlin et al., 2000	Enucleation required for tumor recurrence, scleral necrosis, or pain	7 (10%)
	Dislocated IOL	1 (1.4%)
	Posterior capsular opacity	8 (11%)
	Vitreous hemorrhage	4 (6%)
	Retinal detachment	2 (3%)
Gragoudas et al., 1992	Tumor recurrence	2 (3%)
	Retinal detachment	2 (3%)
	Vitreous hemorrhage	1 (1%)
	Chronic wound leak	1 (1%)
	Neovascular glaucoma	3 (4%)
	Enucleation for retinal detachment, neovascular glaucoma, pain, tumor recurrence	5 (6%)

Table 3. Complications observed after cataract surgery in patients with a history of uveal melanoma after plaque brachytherapy or proton beam radiotherapy.

Complication profiles seem to have improved over the past 20 years, likely due to the modernization of phacoemulsification techniques such as small incisions, and of the more judicious use of cataract surgery, reserving the procedure only for patients with preoperative visual potential and no pre-existing neovascular glaucoma secondary to radiation vasculopathy.

### 4. Conclusion

In summary, cataract surgery has been safely performed in patients with a history of both retinoblastoma and melanoma. Controversy still exists regarding the best technique in patients with a history of retinoblastoma, but we have had success with no tumor recurrences in a series of patients with long-term follow-up using a ECCE/PPV/IOL approach. Tumor recurrence is a known risk of this surgery, and patients should demonstrate a quiescent interval of at least 18 months before surgery. Visual results are largely dependent on side effects from the primary tumor. In uveal melanoma patients, cataracts are common after plaque therapy and occur on average 2.5 years after initial treatment. Most patients regain vision and vision is typically limited by radiation retinopathy, cystoid macular edema, and neovascular glaucoma. Surgical adjuncts such as IVTA may help in decreasing the inflammatory nature of these tumors and contribute to tumor regression. Further prospective studies are needed.



## 5. References

- Blach, L. et al. (1996). External beam radiation therapy and retinoblastoma: long term results in the comparison of two techniques. *International Journal of Radiation Oncology, Biology, and Physics*, Vol. 35, pp. 45-51.
- Bechrakis, N. et al. (2002). Iodine 125 plaque brachytherapy versus transcleral tumor resection in the treatment of large uveal melanomas. *Ophthalmology*, Vol. 109, pp. 1855-1861.
- Bhatterjee, H. et al. Cataract surgery and intraocular lens implantation in a retinoblastoma case treated by external-beam radiation therapy. *Journal of Cataract and Refractive Surgery*, Vol. 29, 1837-1841.
- Brooks, H. et al. (1990). Removal of radiation-induced cataracts in patients treated for retinoblastoma. *Archives of Ophthalmology*, Vol. 108, pp. 1701-1708.
- Bosworth, J. et al. (1988). Choroidal melanoma: I-125 plaque therapy. *Radiology*, Vol. 169, 169, pp. 249-251.
- Cebulla, C. et al. Tumor volume reduction with intravitreal triamcinolone. *Journal of cataract and Refractive Surgery*, Vol. 34, pp. 1669-1673.
- Chodick, G. et al. (2009). Risk of cataract extraction among adult retinoblastoma survivors. *Archives of Ophthalmology*, Vol. 127, pp. 1500-1504.
- Collaborative Ocular Melanoma Study Group (2007). Incidence of cataract and outcomes after cataract surgery in the first 5 years after Iodine 125 brachytherapy in the collaborative ocular melanoma study. COMS Report No. 27. *Ophthalmology*, Vol. 114, pp. 1363-1371.
- DiSorbo, D. et al. (1986). Effect of triamcinolone acetonide on the growth of NEL-M1 human melanoma cells cultured in the presence and absence of growth stimulatory agents. *Cancer Research*, Vol. 46, 1986, pp. 3964-3968.
- Dynlacht, J. et al. (2006). Effect of estrogen on radiation-induced cataractogenesis. *Radiation Research*, Vol. 165, pp. 9-15.
- Ebrahem, Q et al. (2006). Triamcinolone acetonide inhibits IL-6 and VEGF-induced angiogenesis downstream of the IL-t and VEGF receptors. *Investigative Ophthalmology and Visual Sciences*, Vol. 46, 4935-4941.
- Fontanesi, J. et al. (1993). Treatment of choroidal melanoma with I-125 plaque. *International Journal of Radiation Oncology, Biology, and Physics*. Vol. 26, pp. 619-623.
- Fontanesi, J. et al. (1996). Treatment outcome and dose-response relationship in infants younger than 1 year treated for retinoblastoma with primary irradiation. *Medical and Pediatric Oncology*, Vol.26, pp. 297-304.
- Garretson, B. et al. (1987). Choroidal melanoma treatment with iodine 125 brachytherapy. *Archives of Ophthalmology*, Vol. 105, pp. 1394-1397.
- Gordon, K. (1995). Late effects of radiation on the eye and ocular adnexa. *International Journal of Radiation Oncology, Biology, and Physics*, Vol. 31, pp. 1123-1139.
- Gragoudas, E. et al. (1992). Cataract extraction after proton beam irradiation for malignant melanoma of the eye. *Archives of Ophthalmology*, Vol. 110, pp. 475-479.
- Hoehn, M. et al. (2010). Outcomes after cataract extraction in young children with radiation-induced cataracts and retinoblastoma. *Journal of AAPOS*, Vol. 14, pp. 232-234.

- Honovar, S. et al. (2001) Intraocular surgery after treatment of retinoblastoma. *Archives of Ophthalmology*, Vol. 119, pp. 1613-1621.
- Lean, E. et al. (1990). Episcleral radioactive plaque therapy: initial clinical experience in 56 patients. *American Journal of Clinical Oncology*, Vol, 13, pp. 185-190.
- Lumbroso-Le Rouic, L. (2004). I125 plaque brachytherapy for anterior uveal melanomas. *Eye*. Vol. 18, pp. 911-916.
- Madreperla, S. et al. (2000). Repair of late retinal detachment after successful treatment of retinoblastoma. *Retina*, Vol. 20, pp. 28-32.
- Mameghan, H. et al. (1992). Iodine-125 irradiation of choroidal melanoma: clinical experience from the Prince of Wales and Sydney Eye Hospitals. *Australas Radiology*, Vol. 36, pp. 249-252.
- Miller, D. et al. (2005). Pars plana lensectomy and intraocular lens implantation in pediatric radiation-induced cataracts in retinoblastoma. *Ophthalmology*, Vol. 112, pp. 1620-1624.
- Monge, O. et al. (1986). Sightsaving therapy in retinoblastoma: Experience with external megavoltage radiotherapy. *Acta Ophthalmologica*, Vol. 64, pp. 414-420.
- Moshfeghi, D. et al. (2005). Intraocular surgery after treatment of germline retinoblastoma. *Archives of Ophthalmology*, Vol. 123, pp. 1008-1012.
- Osman, I. et al. (2011) Modern cataract surgery for radiation-induced cataracts in retinoblastoma. *British Journal of Ophthalmology*. Vol. 95, pp. 227-230.
- Payne, J. et al. (2009). Outcomes of cataract surgery following radiation treatment for retinoblastoma. *Journal of AAPOS*, Vol. 13, pp. 454-458.
- Portellos M. & Buckley, E. (1998) Cataract surgery and intraocular lens implantation in patients with retinoblastoma. *Archives of Ophthalmology*, Vol. 116, 449-452.
- Puusari, I. et al. (2004). Effect of radiation dose on ocular complications after iodine brachytherapy for large uveal melanoma: empirical data and simulating information of collimating plaques. *Investigative Ophthalmology and Visual Sciences*, Vol. 45, pp. 3425-3434.
- Puusari, I. et al. (2004). Ocular complications after iodine brachytherapy for large uveal melanoma. *Ophthalmology*, Vol. 111, pp. 1768-1777.
- Quivey, J. et al. (1993). High intensity 125-iodine (I125) plaque treatment of uveal melanoma. *International Journal of Radiation Oncology, Biology, and Physics*, Vol. 26, pp. 613-618.
- Shanmugan, M. (2004). Cataract surgery and intraocular lens implantation in retinoblastoma. *Journal of Cataract and Refractive Surgery*, Vol. 30, 1825-1826.
- Shields, C. et al. (2002). Combined plaque radiotherapy and transpupillary thermotherapy for choroidal melanoma: tumor control and treatment complications in 270 consecutive patients. *Archives of Ophthalmology*, Vol. 120, pp. 933-940.
- Shields, C. et al. (2006). Intravitreal triamcinolone acetonide for acute radiation papillopathy. *Retina*, Vol. 26, pp. 537-544.
- Sinha, R. et al. (2004). Management of radiotherapy-induced cataracts in eyes with retinoblastoma. *Journal of Cararact and Refractive Surgery*, Vol. 30, pp. 1145-1146.
- Stack, R. et al. (2005) New Zealand experience of I125 brachytherapy for choroidal melanoma. *Clinical and Experimental Ophthalmology*, Vol. 33, pp. 490-494.

Wachtlin, J. et al. (2000) Phacoemulsification following treatment of choroidal melanoma.  
*Graefes Archives of Clinical and Experimental Ophthalmology*, Vol. 34, pp. 942-948.

IntechOpen

IntechOpen