

We are IntechOpen, the world's leading publisher of Open Access books Built by scientists, for scientists

6,900

Open access books available

186,000

International authors and editors

200M

Downloads

Our authors are among the

154

Countries delivered to

TOP 1%

most cited scientists

12.2%

Contributors from top 500 universities



WEB OF SCIENCE™

Selection of our books indexed in the Book Citation Index
in Web of Science™ Core Collection (BKCI)

Interested in publishing with us?
Contact book.department@intechopen.com

Numbers displayed above are based on latest data collected.
For more information visit www.intechopen.com



Complications of Autogenous Arteriovenous Fistulas

Lucian Florin Dorobanțu, Ovidiu Știru,
Cristian Bulescu, Șerban Bubenek and
Vlad Anton Iliescu

Additional information is available at the end of the chapter

<http://dx.doi.org/10.5772/53018>

1. Introduction

Autogenous arteriovenous fistulas (AVF) are the preferred vascular access for patients with end-stage kidney disease. They are cheap and easy to construct, have excellent patency rates and require minimal maintenance by the patient and the health care staff. However, they can develop various complications, which have different rates of incidence, morbidity and mortality. Most of them threaten the functionality of the fistula and some of them even pose an immediate vital risk. We believe it is important that all health care professionals who deal with patients on whom an AVF is performed should have thorough knowledge of the types, physiopathology, risks and treatment of these complications.

Our team has performed 832 surgical constructions of autogenous AFV in the last 5 years. The number of complications that required surgical revision was 61 (7.3%). This is comparable to a 9% rate of complications reported in a study of 628 patients, by Fokou et al. in Cameroon [1]. The patients in this population have numerous comorbidities besides the end-stage kidney disease; among them, diabetes mellitus, hypertension and chronic viral hepatitis. These 4 are factors who augment the complication rate after any surgical intervention. However, the number of events requiring surgical exploration following AFV construction is relatively low, probably because of increasing experience and technical skills of vascular surgeons.

The complications can be divided in 2 categories:

1. Acute complications
2. Chronic complications

2. Acute complications

These are complications that occur in the first hours or days after the construction of an AVF and always require evaluation by a vascular surgeon.

Thrombosis of the fistula occurs when there is inadequate flow through the fistula, which leads to stasis and thrombosis. Thrombosis of the fistula occurs mostly in patients with inadequate venous run-off, i.e. history of subclavian vein catheters, multiple venous punctions with local fibrosis [2]. We do not use preoperative Duplex exam to assess the vein [3]. Local inspection at the time of surgery should be performed, and if the vein is small, fibrotic or with a visible thrombus inside, another vein should be used. We also assess the vein by flushing it with a heparinated saline solution via a catheter; if there is resistance in advancing the catheter, injecting the solution or no backflow through the catheter, a proximal stenosis of the vein should be suspected, which leaves no alternative but using a different vein. Building an anastomosis that is too tight, restricting the blood flow, coupled with systemic hypotension can also be incriminated in acute thrombosis. We advise our patients to maintain their blood pressures in the 130-150 mmHg interval during the fistula's maturation period. Hypotension sometimes occurs during the first hemodialysis (HD) session performed after the operation, using an indwelling HD catheter. This is the reason why a newly constructed fistula should be assessed by the medical staff at the beginning and end of all HD sessions.

Introducing a catheter on the subclavian vein of an arm with a functional AVF can lead to thrombosis, either immediate or after the first HD session.

Other causes of thrombosis are extrinsic compression of the operated arm, e.g. wearing clothes with tight sleeves or sleeping on the respective arm.

In the acute setting (during the first 12-24 hours), thrombosis can be solved by surgical thrombectomy. If, on palpation, the vein is tender, pulsatile in the initial segment but with no thrill, the vein can be opened longitudinally and a Fogarty catheter passed both distally (towards the subclavian vein) and proximally (towards the anastomosis). Flushing the vein with a heparinated saline solution is mandatory. A thrill should be obtained after removing the cross clamp. There is an increased risk of pulmonary embolism associated with this procedure, making its use subject to a very careful evaluation of the patient and close monitoring. In the past 5 years, only 3 patients were operated on for acute thrombosis of the fistula (0.3%) by our team – compared to an incidence of 2% in other studies [1]. All three cases preserved the AVF after thrombectomy.

Bleeding is the most common acute complication. Spontaneous bleedings are not uncommon in uremic patients, in whom the primary mechanisms of hemostasis are compromised, including thrombocytopenia, platelet dysfunction and von Willebrand factor's changes. Chronic anemia, which is common in uremic patients, also negatively influences the rheologic component of the platelet – vascular wall interaction. All of these factors concur to the fact that, in the postoperative setting, a bleeding is unlikely to spontaneously stop.

Bleeding sources have several causes. There are smaller sources, with no significant hemodynamic impact, but with a continuous flow, generally overestimated by the patient and his family. These smaller sources are dermal, subdermal or from the subcutaneous tissue. If the patient undergoes a session of hemodialysis (HD) or heparination of the hemodialysis catheter shortly after the AVF has been constructed, bleeding is usually the norm. In our practice, we have observed that a delay of 36 hours between the operation and the HD session makes bleeding complications exceptional. We routinely recommend to all patients abstention from HD during this time period.

The wound is inspected, and if only a dermal bleeding point is found, with no hematoma, then the source is sutured under local anesthesia. This maneuver can be performed in the emergency room. Local digital compression or applying a hemostatic sponge generally does not stop the bleeding. Compressive dressings are to be avoided, as they can stop the blood flow through the fistula.

There are also larger sources, with a higher flow and a life-threatening potential. They are usually found at the site of the anastomosis or a slipped vessel ligature and are accompanied by a hematoma.

In the past 5 years, 4 of our 832 patients (0.5%) presented for bleeding requiring surgical exploration. In all the cases, the bleeding source was a slipped ligature on the distal end of the vein used for the AVF, with accompanying hematoma. The incision was reopened, the hematoma removed and bleeding source sutured. The wound was then flushed with an antiseptic solution and closed.

Although uremic patients are prone to bleeding due to their pathophysiological changes to the mechanisms of hemostasis, in our experience, the small number of bleedings and the fact that a "mechanical" cause is found, we believe that there is no benefit in running a series of extensive tests on these patients (thrombelastogram, von Willebrand's factor determination, clotting time etc). There is no doubt that each and every one of these patients' coagulation pathways are malfunctioning and are unlikely to spontaneously stop a bleeding. However, we feel that good surgical technique avoid bleeding in all patients.

Hematoma formation, with or without associated active bleeding, can demand surgical exploration of the wound. There are several situations that can be encountered. A hematoma with no active bleeding through the sutures may not impart on the fistula's functionality. If the hematoma is small and the AVF's thrill is present, there is no surgical indication and the patient is routinely monitored. If the hematoma is larger, and the thrill is modified or absent, the hematoma must be evacuated, followed by closing the bleeding source and AVF repermeation. Sometimes, removing the hematoma can bring back the thrill; if this does not occur, thrombectomy of the AVF or even construction of a new AVF should be performed.

Hematoma associated with bleeding with dark red blood is accompanied by an alteration of the thrill, rendering it sharp, dull, short and systolic only. Surgical exploration and hematoma removal usually turn the thrill back to normal. The bleeding source is probably a slipped ligature from the distal end of the vein used for the fistula. The volume of blood flowing from the wound can appear quite high; in this situation, the patient or untrained medical

personnel can interpret this as anastomosis disruption and can apply a tourniquet on the arm, which completely closes the flow through the fistula, making it unsalvageable. As previously stated, we have operated on 4 patients with active bleeding and hematoma. The bleeding source was found to be a slipped ligature on the distal end of the vein. In 2 patients, a tourniquet had been placed on the arm prior to presentation, so the fistula could not be salvaged, but only the bleeding stopped. In the other 2 cases, the fistula was preserved and later matured and was used for HD.

Hematoma accompanied by bright red blood oozing through the sutures has an arterial source – at the anastomotic level or a collateral arterial branch. The flow through the fistula is severely compromised due to the compression, leading to venous and possibly arterial thrombosis. After suturing the source, arterial and venous thrombectomy with a Foley catheter are performed; making sure not to injure the arterial or venous wall with the balloon catheter.

3. Chronic complications

These are complications that occur days or months after the construction of an AVF.

Thrombosis is caused by inadequate flow through the fistula, which leads to stasis. Causes of inadequate flow are discussed earlier. Other causes include intimal hyperplasia of the anastomosis, thrombosis of a venous pseudoaneurysm with consecutive thrombosis of the whole vein and extrinsic compression of the vein during its' maturation period (for example, during sleep) [4] [5]. If the patients presents promptly, an attempt to salvage the fistula can be made via a surgical thrombectomy with a Fogarty catheter [6] [7]; if the vein has aneurysmal changes, it is probably not amenable to surgical treatment. If the fistula is unsalvageable, a new one must be constructed under the protection of a temporary hemodialysis catheter.

Anastomotic pseudoaneurysm is a rare complication with severe consequences, which requires emergency surgery. In our group, 7 patients (0.8%) developed this complication. A pseudotumoral, pulsatile mass appears at the level of the incision used to create the fistula; this mass is tender, increasing in size and may be painful. The overlying skin has inflammatory and necrotic modifications. A septic process is quite always involved, which disrupts the anastomosis. The origin of the infection can be intraoperative or a clinically silent infection in a patient wearing a HD catheter. The main risk is of overlying skin necrosis with massive bleeding. Surgical exploration is mandatory. Usually, a partially thrombosed false aneurysm is found, with partial anastomosis disruption. A fragment of the pseudoaneurysm's wall is sent for a bacteriological exam and a full course of antibiotics is given after the operation.

Further action depends on the artery used for the fistula and the patient's general condition. If the radial artery is used, it is ligated; we have seen this scenario in only 3 cases and there were no ischemic complications after interruption of the radial artery. In the case of the brachial artery, which has a higher ischemic potential, the main goal is pseudoaneurysm removal and rebuilding the arterial continuity. This can be performed via a termino-terminal arterial anastomosis (as one of our patients has received) or by a venous graft interposition, using either an arterialized venous segment, or with a greater saphenous vein segment, if

there are signs that the arterialized vein is infected. In cases with severe septic potential and aggravated general condition, the brachial artery can be ligated. Three of our patients received this treatment, fortunately without secondary ischemic events.

Venous aneurysm occurs in uncorrected hypertensive patients, months or years after fistula construction, irrespective of the fact that the fistula has or has not been used for HD (figure 1). The incidence of this complication was 3.6% (30 patients) in our group and 4.2% in the group from Cameroon [1].

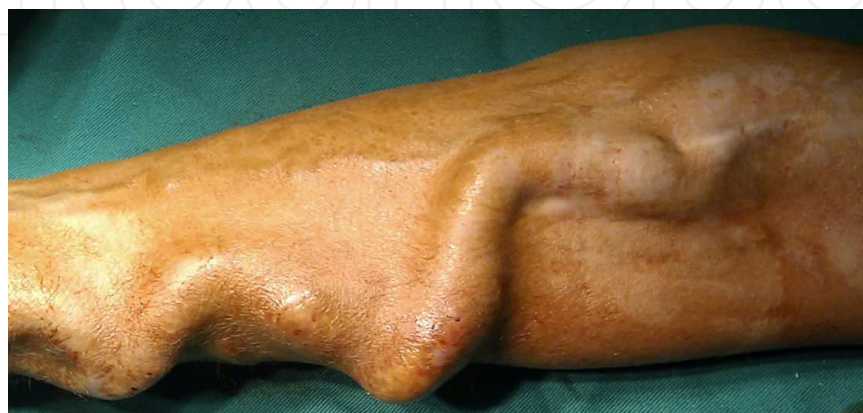

Figure 1. Aneurysm of the cephalic vein in a patient with a radio-cephalic fistula

A Doppler examination of the aneurysm shows turbulent blood flow and parietal thrombus (figure 2). The natural evolution of this complication is with total thrombotic occlusion or spontaneous rupture. Other associated processes are thrombophlebitis, infection, skin necrosis with imminent perforation and hyperdynamic syndrome[8]; these all require surgical treatment. Also, a quickly evolving aneurysm requires surgical intervention. Otherwise, the undilated segments of the fistula can be used for hemodialysis access[9].



Figure 2. Aneurysm of the cephalic vein with parietal thrombus

The fistula is ligated and a new one is constructed using a different vein. The aneurysm can be removed or left in place. Further control of blood pressure values ensures that the new fistula does not develop the same complication.

Among the 30 patients venous aneurysms in our group, we operated on 21. The fistula was ligated and a new one created with an available vein. These new fistulas developed no aneurysm once the blood pressure values were kept in the normal range.

Venous pseudoaneurysm develops due to a common mistake made in hemodialysis services, which is repeated punctures at the same site. In time, the arterialized vein can grow to impressive sizes, develop a false aneurysm with partial or complete thrombosis. After repeated punctures, the overlying skin undergoes fibrotic changes, followed by necrosis, with a high risk of disruption and massive bleeding. This potential course of events makes surgery mandatory as soon as possible. The most common intervention is fistula ligation, followed by creating a new fistula with a different vein. In selected patients, who have no aneurysmal thrombi on Doppler exam or on palpation, a reductional plasty of the aneurysm can be performed. The entire aneurysm is exposed through a longitudinal incision, followed by proximal and distal cross clamping and wedge resection of the anterior wall of the aneurysm. The vein is rebuilt with a 7-0 Prolene continuous suture. The proximal segment of the vein can be used for HD after 36 hours and the dissected segment, after 3 weeks.

Eight of our 832 patients (0.9%) presented for venous pseudoaneurysm and were operated on immediately. We performed fistula ligation in 5 cases, followed by creation of a new fistula after 3 weeks, during which time the patient underwent HD sessions via a temporary catheter. In the other 3 cases, after assessing the pseudoaneurysms with palpation and Doppler exam, we found them suitable for remodeling and a reductional plasty was performed in the described manner.

Skin necrosis also develops at the site of repeated punctures. It occurs after superficialization of a basilic or brachial vein, if the wound had been closed with a thin layer of skin overlying the fistula (figure 3). This heals poorly between HD sessions, as it has an inadequate blood supply, and becomes even thinner and necrotic; the venous wall is also thin and very fragile. Bleeding is the risk with this complication, and can be massive, life-threatening due to the high flow through the fistula (figure 4).

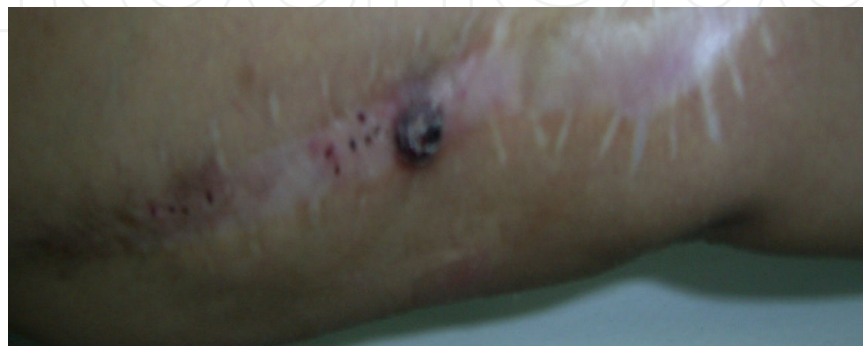

Figure 3. Skin necrosis at the level of a superficialized basilic vein

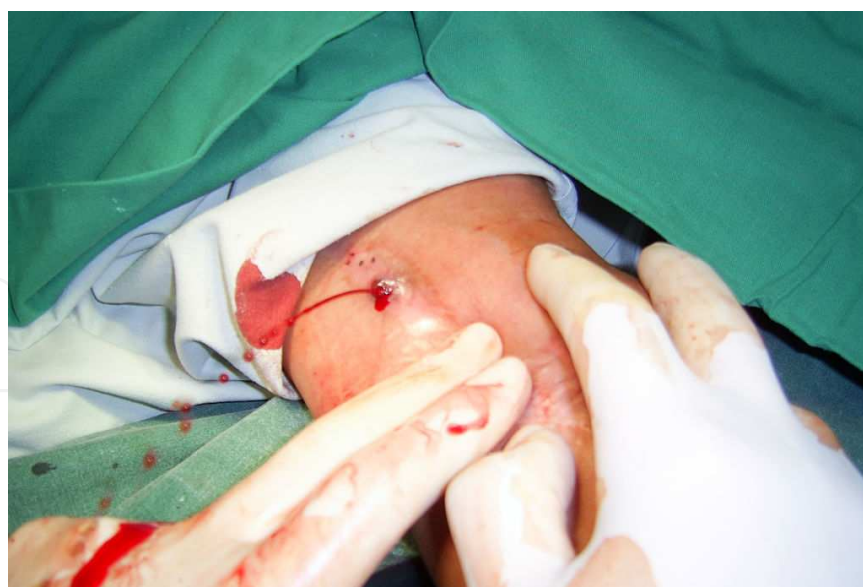

Figure 4. Bleeding from the necrotic skin area

Surgical treatment involves the bleeding point skin suture, then making a circular incision around the necrotic segment and carefully dissecting it away from the vein, without entering the vein.

Then the hemostasis can be easily performed with a 5-0 Prolene suture and the necrotic skin removed. The skin is then approximated with interrupted Prolene sutures. If bleeding occurs, the assistant compresses the fistula at the anastomotic level and proximally, on the arm, until hemostasis has been performed with interrupted 5-0 Prolene sutures. We routinely give an antibiotic regimen to our operated patients, usually 2 grams of Oxacillin per day, for 5 days.

We have seen this complication in 3 of our 832 patients (0.3%). Two of them bled from the necrotic area before presenting to the hospital. They were all operated on and made an uneventful recovery.

Hand ischemia is the most serious complication of vascular access surgery. The patients have all the clinical manifestations of chronic limb ischemia: muscular atrophy of the thenar and hypothenar eminences with functional impotence of the fingers, cold extremities, pain at rest, which becomes excruciating during HD sessions [10]. Gangrenous changes of the fingers are sometimes present (figure 5).

The patient is usually diabetic and has atherosclerotic lesions distal to the anastomosis. Blood flow is diverted through the vessel with a lower resistance, which is the vein – the “steal syndrome” [11]. Under normal conditions, when the radial artery is used for the fistula, the hand is still supplied with blood via the ulnar artery and the vascular arcades of the hand. However, there are cases when the arcades have clinically silent lesions (i.e. negative Allen test), which become significant if the distal radial artery is interrupted while constructing the AVF. This is why we attempt to maintain the distal radial artery open after creating the fistula. Hand ischemia can also occur if the brachial artery is used and is usually more serious.

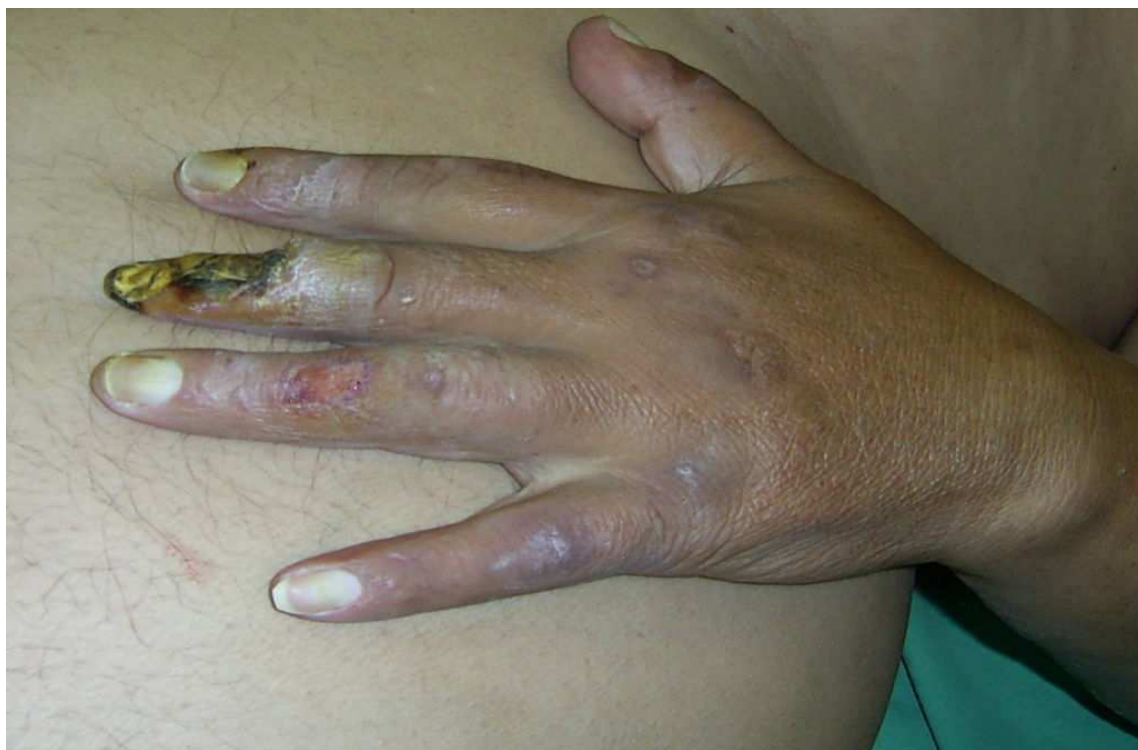

Figure 5. Ischemic hand and necrosis of the fingers in a patient with a brachio-cephalic fistula

All attempts should be made to salvage the limb firstly, and the fistula, secondly. The most direct and simple technique is outflow ligation. The vein is exposed close to the anastomosis and doubly ligated with a number 5 Nylon tape. The thrill should disappear and distal perfusion is immediately improved, with quick remission of symptoms. The major drawback is that the AVF is lost for further access.

Other AVF preserving techniques aim to decrease the flow through the fistula. These are banding of the vein, prosthetic graft interposition (ePTFE nr.5) and venous by-pass using the accessory radial vein. These techniques will be discussed in the hyperdynamic syndrome paragraph.

The DRIL procedure (Distal Revascularization Interval-Ligation) has been described by Schanzer in 1988 [12]. The artery is ligated distal to the anastomosis. An arterio-arterial by-pass is performed between the proximal artery (usually, the brachial artery) and the distal arterial territory (usually, the radial artery). Immediate technical success rates are excellent, with an overall reduction in ischemic events; however, if graft failure occurs, the entire distal extremity is at risk of gangrene and may require amputation [13][14].

In patients with a brachio-cephalic fistula and pseudoischemic symptoms accompanied by venous engorgement, we have found a patent accessory radial artery, which originates high in the arm, from the cephalic vein. This vein had a retrograde flow which impeded the venous outflow of the cubital region and the forearm. Ligation of this vein led to the disappearance of the venous engorgement and the ischemic symptoms.

Hand ischemia can also have technical reasons, if the anastomosis causes reduction in diameter or even occlusion of the distal brachial artery. In this setting, the fistula is also sacrificed, this time by ligation followed by arterial reconstruction at the site of the anastomosis.

This complication occurred in 7 of our 832 patients (0.7%). We were forced to ligate the fistula in 6 cases and perform vein banding in one other case. There have also been cases of ischemia associated with hyperdynamic syndrome; these cases will be discussed below.

Hyperdynamic syndrome is a consequence of greatly increased blood flow through the fistula, with consecutive volume overload of the right heart and cardiac failure. It is a relatively rare complication and can occur irrespective of the age of the fistula. It is associated with brachial artery use, which has a larger diameter and thus a higher flow (1-1.1 L/min) when compared to the radial artery (0.65 L/min) [15] [16] [17]. After the maturation period, Doppler examinations show flows of 8-10 L/min through the fistula. Local examination shows venous dilatations and the patients are restless and show dyspnea, orthopnea and sinus tachycardia [18]. Almost all of them are hypertensive, with uncorrected BP values in spite of treatment. The aim of the surgical treatment is to decrease the flow through the fistula.

Fistula closure promptly makes this syndrome disappear. However, this means that the heart has to rapidly adapt to new hemodynamic conditions (with severely decreased venous return). Transient bradycardia, hypotension and syncope can occur. With this patients subgroup, we always ligate the fistula under close monitoring (EKG, blood pressure and SpO₂).

As previously stated, there are also techniques which aim to preserve the AVF. Banding the vein decreases the vein's diameter and thus increases the resistance flow and decreases the flow. The vein is dissected and encircled with a tape which is progressively tightened until the thrill becomes less intense, the heart rate drops below 100 beats/minute and the dyspnea gets clinically better. It is sometimes difficult to establish a precise amount of banding that prevents the steal syndrome but still allows fistula patency. In the setting of reduced flow that results from fistula banding, thrombosis can occur with further transient flow decrease, for example in hypotensive states [15][19]. Also, in our experience, banding offers only a momentary decrease of symptoms. For this reason, we prefer to use alternate techniques and have used this technique in only 3 patients in the last 5 years.

Prosthetic graft interposition uses a nr.5 ePTFE graft, which obviously has a much smaller diameter than the arterialized vein and thus a higher resistance. A 4-5 cm segment of the vein is dissected; 3-5 cm are removed and the graft is interposed via 2 end-to-end anastomoses. Approximating the end of the vein and the graft can be difficult, due to the difference in size. Alternatively, the vein can be left in place and the graft sutured via 2 end-to-side anastomoses, followed by ligating the fistula between the 2 anastomoses. This eliminates the size-mismatch. The surgeon must resist the urge of using a larger graft, as this does not reduce the flow in a significant manner.

To decrease flow, we have also created a venous by-pass using the accessory radial vein. This is usually found in the forearm, where it merges with the median cephalic vein, creating the cephalic vein. But there are cases when it has a high origin, in the arm, lateral to the

cephalic vein. Even after arterialization of the cephalic vein, this branch maintains a small diameter and can be used to divert the blood flow from the larger cephalic vein (figure 6).

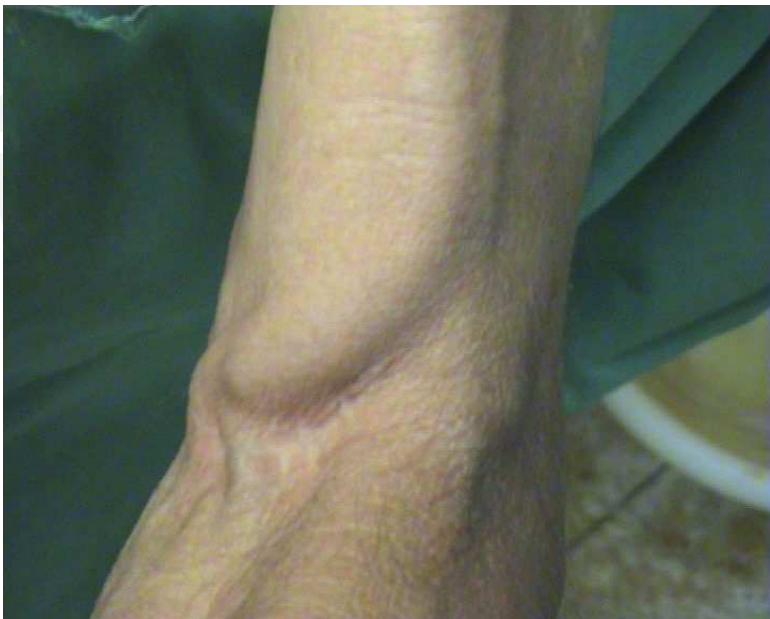

Figure 6. Accessory radial vein with a high origin in a patient with a brachio-cephalic fistula

During surgery, it is dissected from its' origin in the cephalic vein for a distance of 5 cm, then anastomosed end-to-side to the cephalic vein after the arterio-venous anastomosis. The cephalic vein is then interrupted between the newly created anastomosis and the origin of the accessory radial vein (figure 7). The patients receive one week of antibiotics after the intervention.

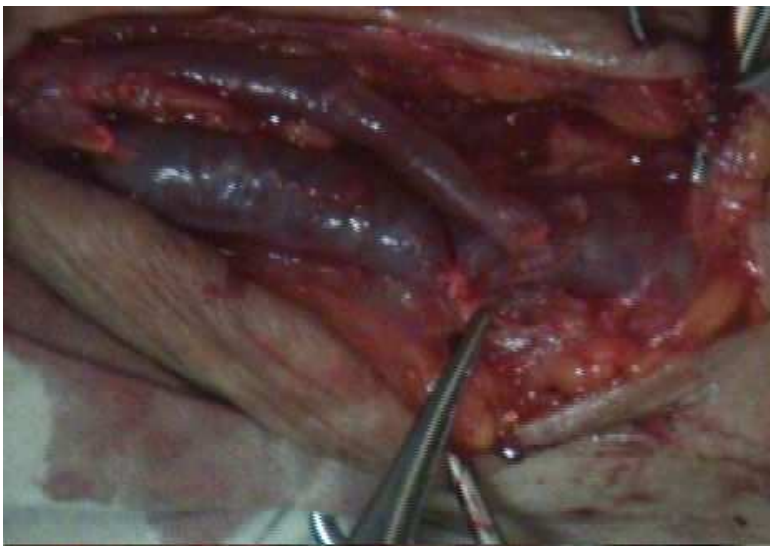


Figure 7. The anastomosis is complete and the cephalic vein is ligated distal to the anastomosis

In 4 of our patients (0.4%) we performed a by-pass with a PTFE graft; 3 other cases (0.3%) received a venous by-pass. The results of by-pass (either using a prosthetic graft or the accessory radial vein) are very good at short and mid-term follow-up. Heart rate is maintained at less than 100 beats/minute with great clinical improvement. Doppler echography shows diminished flows, of 4-5 L/min. The fistula remains functional with no residual steal syndrome. In conclusion, the surgical treatment that we favor for hyperdynamic syndrome is venous by-pass with the accessory radial vein, whenever available; if not, graft interposition is the next option.

Hand edema is a relatively frequent, but usually transient complication in vascular access surgery. It is more frequent when the superficial veins have been used up and a brachio-brachial fistula is constructed. Venous hypertension occurs shortly after AVF creation, but it diminishes after collaterals develop and outflow improves. Outflow obstruction due to stenosis of a central vein provoked by a long-term indwelling catheter or by neointimal hyperplasia from the turbulent flow of the AVF also cause venous hypertension. Sometimes, venous tributaries become dilated, incompetent and perfuse retrograde toward the forearm and the hand, thus increasing the capillary pressure. If the hypertension does not subside, it is accompanied by the classic symptoms of a venous stasis syndrome: edema, pigmentation and ulceration. The whole upper extremity can become involved in the edema, which sometimes includes the chest wall and the breast. A rich collateral venous circulation also develops. There are rare cases when the edema is so important that it produces ischemic phenomena. Treatment consists of repair of the fistula outflow or ligation of the fistula; improvement is immediate and dramatic, with edema reduction and healing of ulcerations within 1-2 weeks.

We have seen no cases of edema requiring surgical correction during the past 5 years.

Lymphorhea is a relatively rare complication (<1% of operated patients)[7]. Patients with a thick layer of subcutaneous tissue, which has been extensively dissected, complicated with postoperative upper arm edema sometimes develop it. We have never seen it in conjunction with radio-cephalic fistula. In our experience, it is more frequent with the brachio-brachial fistula. The wound closes and heals following several (sometimes daily) sessions of HD, and frequent changing of dressings. If a septic process develops, surgical debridement and antibiotherapy become necessary.

Infection is a rare complication with severe repercussions [20]. In the past 5 years, only one of our patients developed it (0.1%). If intraoperative contamination occurs, after a short period of time the wound becomes inflamed, painful, with purulent discharge, accompanied by fever. Vascular access creation is forbidden in a patient which carries a HD catheter but presents with fever and leucocytosis; in this case, the anastomosis becomes infected due to bacteremia and is extremely susceptible to disruption. These patients should be postponed until a new catheter is implanted in a different site and the old catheter removed and its tip sent for bacteriological examination, followed by proper antibiotherapy. The most common infectious agents encountered are *S. aureus* and *S. epidermidis*. Reinterventions for bleeding or fistula thrombosis also increase the risk of infection. The higher the number of reexploration, the higher is the chance of acquiring an infection. For this reason, we believe that the

maximum number of reinterventions is 2 in 24 hours. If the fistula is not functional after these 2 reinterventions, we wait until the incision heals before trying to create a new fistula using the same incision. Late anastomotic pseudoaneurysm formation is also a septic complication, which can develop even if the incision is healed.

If the wound shows a purulent discharge, the patient must be evaluated by a vascular surgeon. There are 2 therapeutic options. The conservative one is drainage of the collection, followed by washing with an antiseptic solution. A more aggressive option is closure of the fistula, also followed by antiseptisation of the wound. For a radio-cephalic fistula, the radial artery can be ligated without any ischemic consequences. For a fistula using the brachial artery, the fistula must be closed and arterial reconstruction performed. In the setting of acute bleeding, with fragile arterial wall, arterial ligation is mandatory; ischemic phenomena may occur, but this is not the rule.

In all cases, antibiotherapy is indicated.

Author details

Lucian Florin Dorobanțu¹, Ovidiu Știru¹, Cristian Bulescu¹, Șerban Bubenek² and Vlad Anton Iliescu¹

*Address all correspondence to: ludorobantu@yahoo.com

1 Department of Cardiovascular Surgery, "Prof. Dr. C.C. Iliescu" Emergency Cardiovascular Diseases Institute, Bucharest, Romania; "Carol Davila" University of Medicine and Pharmacy, Bucharest, Romania

2 Department of Anesthesiology and Intensive Care, "Prof. Dr. C.C. Iliescu" Emergency Cardiovascular Diseases Institute, Bucharest, Romania; "Carol Davila" University of Medicine and Pharmacy, Bucharest, Romania

References

- [1] Fokou M, Teyang A, Ashuntantang G, Kaze F, Eyenga VC, Chichom Mefire A, Angwafo F. Complications of arteriovenous fistula for hemodialysis: an 8-year study. *Ann Vasc Surg* 2012 Jul;26(5):680-4.
- [2] Fitzgerald JT, Schanzer A, Chin AI, McVicar JP, Perez RV, Troppmann C. Outcomes of upper arm arteriovenous fistulas for maintenance hemodialysis access. *Arch Surg*. 2004 Feb;139(2):201-8.
- [3] Dorobantu, L.F.; Stiru, O.; Iliescu, V.A.; Bubenek, S.; Novelli E. (2010). The brachio-brachial arteriovenous fistula: mid-term results. *J Vasc Access* No.11 (2010), pp.23-25.

- [4] Arroyo MR, Sideman MJ, Spergel L, Jennings WC. Primary and staged transposition arteriovenous fistulas. *J Vasc Surg*. 2008 Jun;47(6):1279-83.
- [5] Jennings WC, Sideman MJ, Taubman KE, Broughan TA. Brachial vein transposition arteriovenous fistulas for hemodialysis access. *J Vasc Surg* 2009 Nov;50(5):1121-5.
- [6] Tordoir JH, Bode AS, Peppelenbosch N, van der Sande FM, de Haan MW. Surgical or endovascular repair of thrombosed dialysis vascular access: is there any evidence? *J Vasc Surg* 2009 Oct;50(4):953-6.
- [7] Iyem H. Early follow-up results of arteriovenous fistulae created for hemodialysis. *Vasc Health Risk Manag* 2011;7:321-5.
- [8] Sohawon S, Nazeri A, Dernier Y, Noordally SO. Painful true aneurysm in a brachio-basilic arterio-venous fistula. *ANZ J Surg*. 2012 Jan-Feb;82(1-2):87-8.
- [9] Ahmed GM, Mansour MO, Elfatih M, Khalid KE, Ahmed Mel I. Outcomes of arterio-venous fistula for hemodialysis in Sudanese patients: single-center experience. *Saudi J Kidney Dis Transpl* 2012 Jan;23(1):152-7.
- [10] Zamani P, Kaufman J, Kinlay S. Ischemic steal syndrome following arm arteriove-nous fistula for hemodialysis. *Vasc Med*. 2009 Nov;14(4):371-6.
- [11] Barnes RW. Hemodynamics for the vascular surgeon. *Arch Surg* 1980;115:216–223.
- [12] Schanzer H, Skladany M, Haimov M. Treatment of angioaccess-induced ischemia by revascularization. *J Vasc Surg* 1992;16(6):861–866.
- [13] Anaya-Ayala JE, Pettigrew CD, Ismail N, Diez-De Sollano AL, Syed FA, Ahmed FG, Davies MG, Peden EK. Management of dialysis access-associated "steal" syndrome with DRIL procedure: challenges and clinical outcomes. *J Vasc Access* 2012 Jan 13:0.
- [14] Gupta N, Yuo TH, Konig G 4th, Dillavou E, Leers SA, Chaer RA, Cho JS, Makaroun MS. Treatment strategies of arterial steal after arteriovenous access. *J Vasc Surg*. 2011 Jul;54(1):162-7.
- [15] Schanzer, H.; Schanzer, A. (2004). Vascular access for dialysis, \. In Ascher, E. (ed.), Haimovici's Vascular Surgery, 5th ed., p.1015-1030, Blackwell Science, Malden, Mas-sachusetts, USA
- [16] Stiru, O.; Iliescu V.A. & Dorobantu, L.F. (2006). Tehnici de fistule arteriovenoase na-tive la nivelul membrului superior, Editura Universitara "Carol Davila", Bucharest, Romania
- [17] Moini M, Rasouli MR, Salehirad S, Nazarinia M. Interrupting connection of superfi-cial and deep veins of the upper extremity at the elbow for creation of hemodialysis arteriovenous fistulas. *Saudi J Kidney Dis Transpl* 2010 Sep;21(5):859-62.
- [18] Beigi AA, Sadeghi AM, Khosravi AR, Karami M, Masoudpour H. Effects of the arte-rio-venous fistula on pulmonary artery pressure and cardiac output in patients with chronic renal failure. *J Vasc Access* 2009 Jul-Sep;10(3):160-6.

- [19] West JC, Bertsch DJ, et al. Arterial insufficiency in hemodialysis access procedures: correction by “banding” technique. *Transplant Proc* 1991;23:1838–1840.
- [20] Schild AF, Perez E, Gillaspie E, Seaver C, Livingstone J, Thibonnier A. Arteriovenous fistulae vs. arteriovenous grafts: a retrospective review of 1,700 consecutive vascular access cases. *J Vasc Access* 2008 Oct-Dec;9(4):231-5.