

# We are IntechOpen, the world's leading publisher of Open Access books Built by scientists, for scientists

6,900

Open access books available

185,000

International authors and editors

200M

Downloads

Our authors are among the

154

Countries delivered to

TOP 1%

most cited scientists

12.2%

Contributors from top 500 universities



WEB OF SCIENCE™

Selection of our books indexed in the Book Citation Index  
in Web of Science™ Core Collection (BKCI)

Interested in publishing with us?  
Contact [book.department@intechopen.com](mailto:book.department@intechopen.com)

Numbers displayed above are based on latest data collected.  
For more information visit [www.intechopen.com](http://www.intechopen.com)



---

# Segmental Oriented Liver Surgery

---

O. Al-Jiffry Bilal and Khayat H. Samah

Additional information is available at the end of the chapter

<http://dx.doi.org/10.5772/51775>

---

## 1. Introduction

Understanding the vascular and biliary anatomy of the liver is mandatory for a successful anatomical liver resection. It is also extremely important in complex liver operations, although it might not be in cases of simple wedge resection for benign disease. As the presence of HCC is usually in the background of liver cirrhosis, the importance of anatomical resection to be able to clear the tumour and have sufficient amount of liver to avoid post-operative liver failure. In this chapter we will try to illustrate the importance of anatomical liver resection and give an idea of the latest liver anatomy with a demonstration on how to identify and resect each part of the liver.

## 2. Why anatomical liver resection

As many general surgeons might like to do wedge non anatomical liver resections because it is less complicated and gets the tumour out. There are several reasons to perform anatomical resection:

1. In Hepato-Cellular carcinoma (HCC) which is the most common reason to perform liver resections, where it is the first line of treatment nowadays [1,2]. As the HCC are able to invade the portal veins and disseminate through its inter segmental branches [3] (cough reflux), segmentectomy is preferable. Intrahepatic metastasis [4,5] and invasion to the portal and hepatic venous system will affect the post operative prognosis. To improve the post surgical outcome the segmental liver resection is indicated. It involves the removal of the whole segment containing the tumor with its vasculature which might be affected by the tumor invasion [1,4 - 6]. Satellite micro metastasis will also be removed as their feeding vessel for that segment [3].

Anatomic liver resection is superior to non anatomic from the oncologic and anatomic aspects [7]. Anatomically based hepatectomy is the best means of achieving a negative margin[8].The recurrence rate within 2 years associated with aggressive tumor biology such as high tumor grade, satellite lesions and microvascular invasion [7], is higher in non anatomical resection.

In small HCC <4cm anatomic resection achieves better disease-free survival than limited resection without increasing the postoperative risk [9-10].

The overall survival and the disease-free survival rates were significantly better in the anatomic resection compared to the non anatomic resection group [1,11-12],as well as the recurrence disease free survival [10].

A meta-regression analysis was done and published in June 2012 that was conducted on 9036 patients from 1990-2011 and demonstrated that the 5 years disease free survival and the 5 year survival was significantly better in the anatomic resection group than the non anatomic resection group with no effect on the post operative mortality and morbidity[13].

2. Less bleeding with almost no need for transfusion in the intra-operative period as there is no transaction of the vessels. Also there is few vessels present in the inter segmental planes. Relatively the inter segmental area is a non-vascular plane, so segmental identification, control of the feeding vessels and the vascular pedicle will decrease the blood loss. This is one of the direct causes of decreased post operative morbidities and mortalities [3,14 - 16].
3. Segmental resection will preserve as much of the liver parenchyma [3] and will enable sufficient liver volume especially in cirrhotic patients [16] and in patients with multiple liver lesions [17] or in patients who will need another resection in the future. Also it will decrease the post operative liver insufficiency from small liver remnant in cirrhotic patients [3,14,15,16].
4. In colorectal metastasis segmental resection is superior to non anatomical resection as it results in better tumour clearance and free margins. Multiple studies demonstrated that it did affect the disease free survival, and the control of micro-metastasis through segmental portal branches. Segmentectomy offered disease-free and overall survival rates similar to those after major resection. [3,14]

For metastasis it has been found that with wedge resection the recurrence rate and positive margins were higher compared to the segmental resection. This resulted in inadequate tumour resection especially in deep lesions where the incidence of inadvertently cutting into the tumour is higher. Also the bleeding rate is high due to the difficult control of the venous branches that will obscure the resection plane.

Wedge resections are usually inadequate and potentially dangerous, especially for large tumours, and are often associated with greater blood loss and a greater incidence of positive histological margins.[8,11]. Liver failure due to parynchymal necrosis or small liver remnant are observed in non anatomical (wedge) liver resection. It also results in higher incidence of biliary fistula and infection because of the remnant devitalized liver tissue [18].

Non-anatomical liver resection (Wedge) can be done in certain circumstances; in resections where the tumour is small (<3cm) and located peripherally at the edge of a cirrhotic liver or when the tumour is situated at the border of several segments and its resection requires the removal of large volume which is not possible due to the liver status.

Also, in cases of benign liver resection where no safety margin is required and the surgeon would like to preserve as much liver volume as possible, so the lesion can be enucleated. However, care should be taken not to injure nearby vessels or bile ducts.

### 3. Segmental liver anatomy

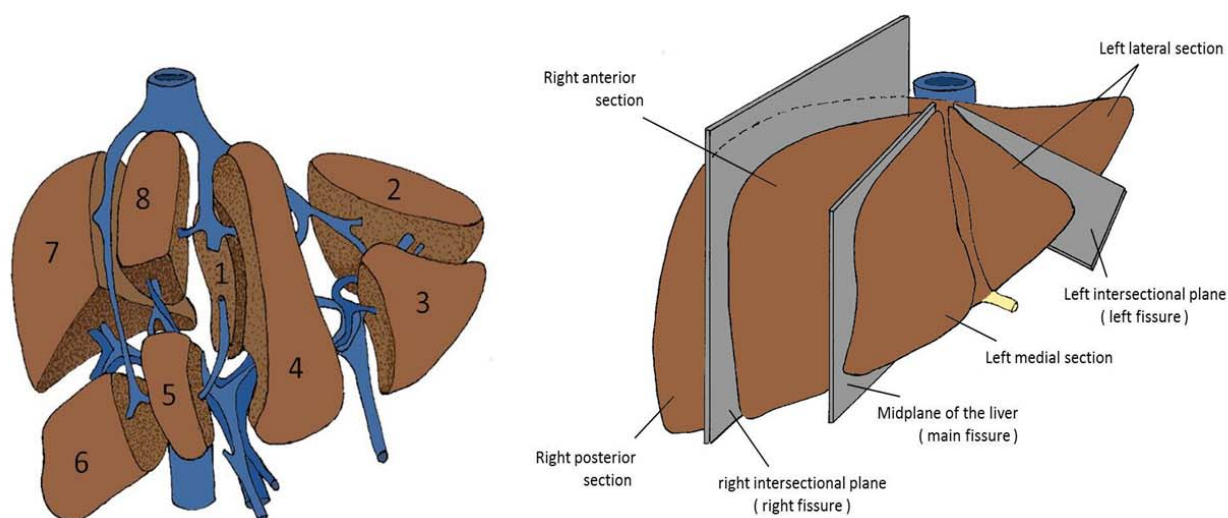
#### 3.1. The history

The understanding of liver segments was first established in 1953 by Healy [19] and was further reinforced by Couinaud in 1957 [20]. When trying to understand their description it might be somewhat confusing, however we will try to make it as simple as possible.

They both used the new division by Cantlie who disapproved the old terminology of the right and left liver which was divided by the falciform ligament and used his description of the right and left liver divided by the midline which is oblique and extended from the gallbladder bed to the right side of the inferior vena cava. Healy then divided the liver using the arteriobiliary segmentation. This led to the division of the right liver into the two segments, the right anterior and the right posterior segments (called now sections). The left side was divided by the falciform into the left medial and left lateral segments (called now sections). However, Couinaud used the hepatic veins and divided the right liver into right anterior and right posterior sectors. The left side was divided by the left hepatic vein into the left medial and left lateral sectors, and the middle hepatic vein was running in the midplane of the liver (Cantlie line). Then recently the terminology of segments that was described by Healy was changed to sections leading the way to the word section and sector that you see in all papers involving the liver anatomy. They both divided these sectors or sections to segments according to the portal vein anatomy and we reached to our 8 segments that we know today. **Figure.1**

When looking at these two descriptions you will find that both agreed on the anatomy of the right liver because there was no difference between the right anterior (segment 5&8) and the right posterior (segments 6&7) section or sector. However, on the left side there was a difference, because of the anatomical variations and we believe this is what led to this misunderstanding. The left medial section (segment 4) is not the same as the left medial sector (segment 3&4), and the left lateral section (segment 2&3) is not the same as the left lateral sector (segment 2). They also both agreed on the separation of segment 1 (caudate Lobe) as it has its own blood supply and drains directly to the inferior vena cava.

Another thing when looking to the terminology is the word "Lobe". Some authors use the term left lobectomy to describe the resection of segments 2&3, which is the functional left lateral section. Also the right lobe as segments 4 to 8 where it is an extended right trisectionectomy.



**Figure 1.** Liver sections, plane and segments

This description was based on the anatomical land mark of the liver using the falciform ligament and not the functioning liver segments as described above.

### 3.2. The new terminology

The use of many different terminologies and difficulty in understanding the description described above, were the European societies adopted Couinaud's description and the American societies used the Healy's description. So the scientific committee of the International Hepato-Pancreato-Biliary Association with experts around the world came up with the Brisbane 2000 Terminology of Liver Anatomy and resection which we have been using and will use for our description in this chapter [21].

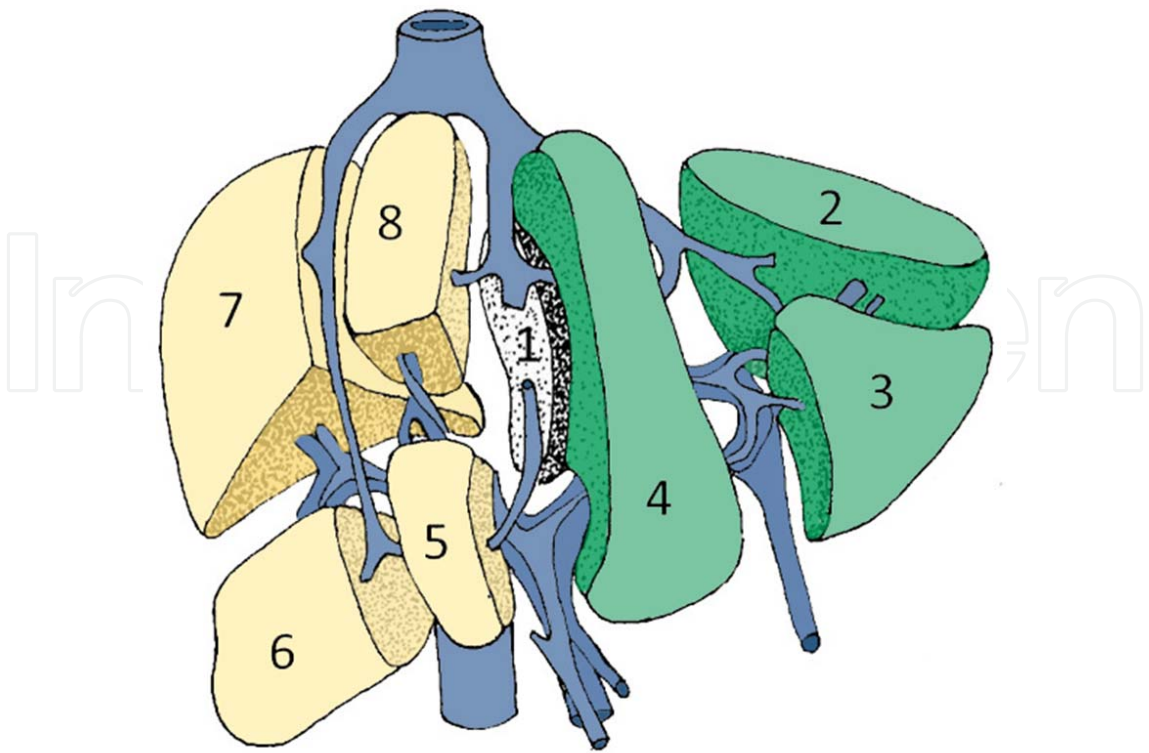
To understand this terminology, first the liver is divided into two parts, the main liver and the caudate lobe (called the dorsal sector by Cauinaud). Then the main liver is divided into the right and left liver.

This part is called the first order division, where the liver is divided into the right liver or right hemiliver, and the left liver or the left hemiliver. Notice the word lobe has been removed completely for the confusion we mentioned above, so the resection of the right side is called right hepatectomy or right hemihepatectomy (segments 5 to 8). The left side is called; left hepatectomy or left hemihepatectomy (segments 2 to 4). **Figure.2**

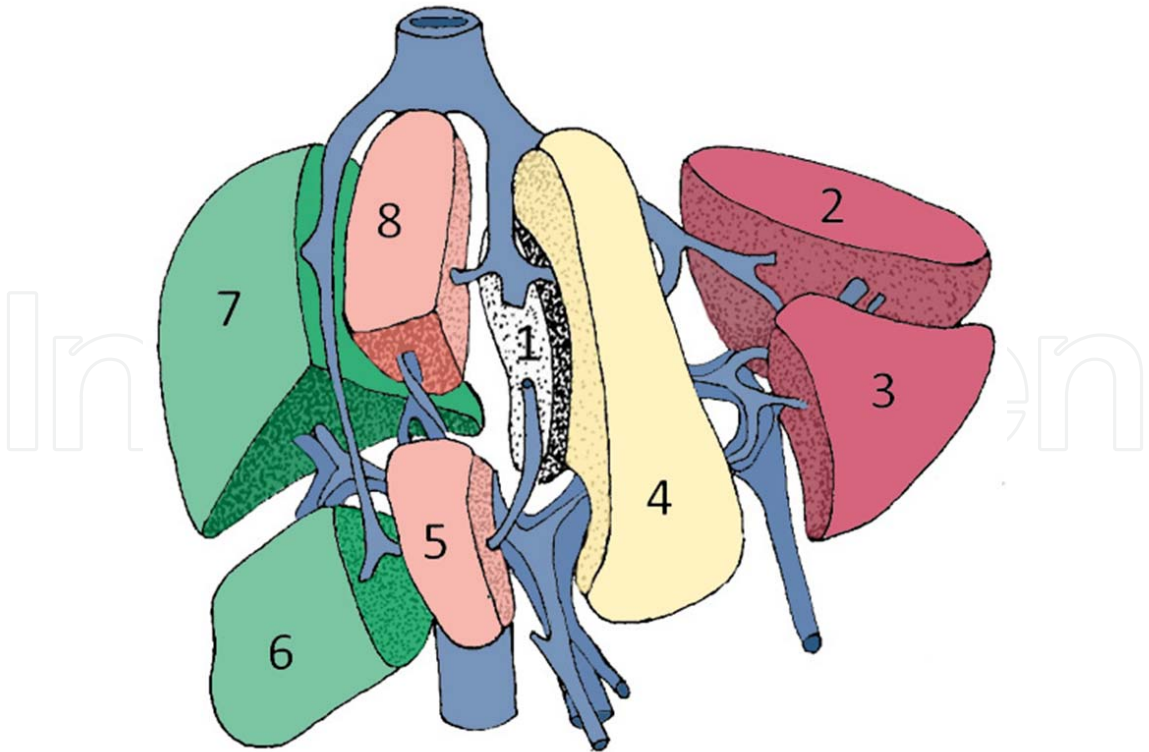
The second order division, where the right liver is divided into two parts. The right anterior section giving the right anterior sectionectomy (segment 5&8), the right posterior section leading to the resection of the right posterior sectionectomy (segments 6&7). On the left side there will be the left medial section giving the left medial sectionectomy (segment 4), and the left lateral section leading to the resection of the left lateral sectionectomy (segment 2&3).

### **Figure.3**



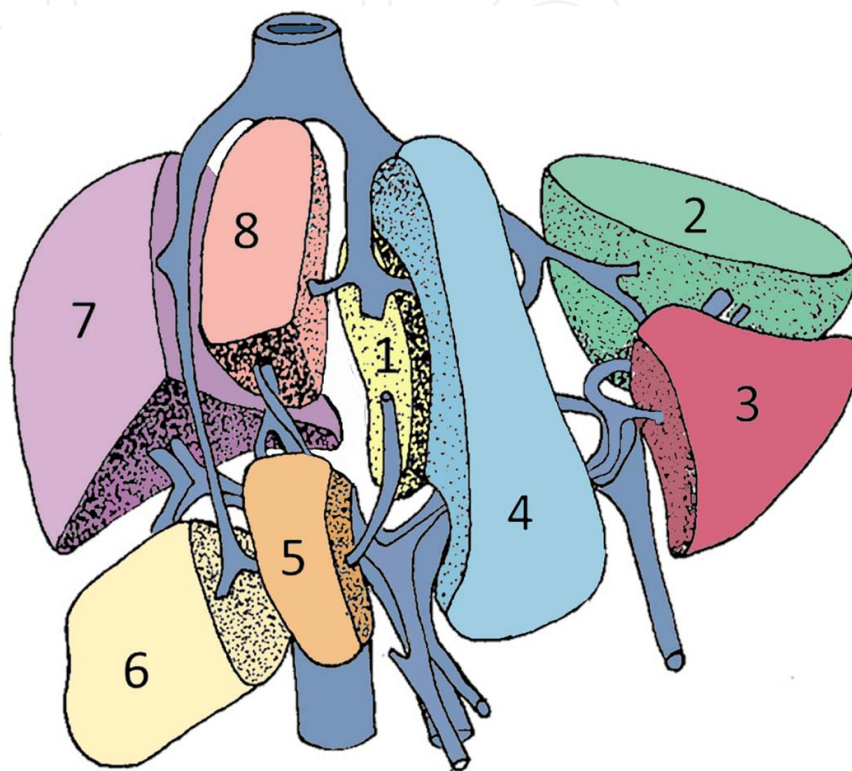


**Figure 2.** Right (yellow) and left liver (green)



**Figure 3.** Sections Green: right posterior, orange: right anterior Yellow: left medial, red: left lateral

The third order division, is the division of each of these sections into segments as we mentioned above. The resection of any of these segments is called a segmentectomy and if two or more segments were resected that are not related as described in the second order division it is called bisegmentectomy or trisegmentectomy. This should not be confused with the trisectionectomy of the right or left side where we resect three sections and not segments. **Figure.4**



**Figure 4.** Segments, each with a different color

An addition was added also if the word sector were to be used instead of section. This is the same on the right side and on the left we had a left medial sector with a left medial sectorectomy (segment 3&4), and the left lateral sector giving rise to the resection of the left lateral sectorectomy (segment 2). So the term section or sector has to be used very cautiously on the left side to describe exactly what you mean.

### 3.3. Clinical applications

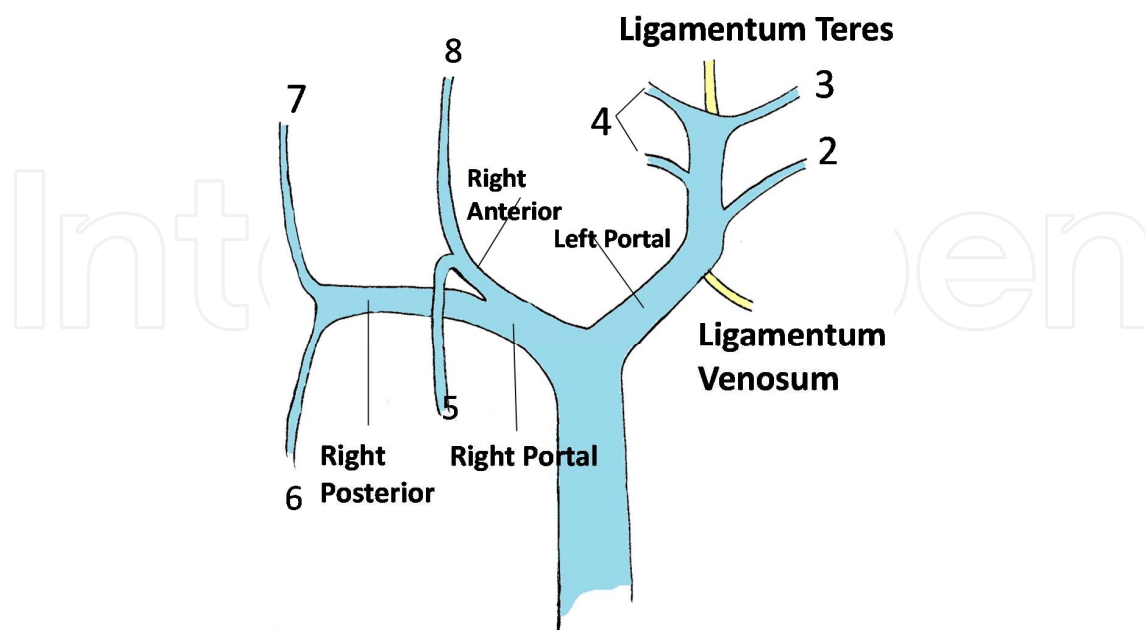
1. As each liver segment can be resected separately, liver resection can be segment based
2. Segment 4, is divided into 4A and 4B. This was made because of multiple indications where segment 4A is resected without the resection of segment 4B like in cases of gallbladder cancer. Also the resection of segment 4A is counted as the most difficult liver resection as it lies between the middle and the left hepatic vein.
3. This terminology has gained wide acceptance and has removed most of the confusion that used to exist in the past.

### 3.4. Intrahepatic glissonian triads

The extra hepatic portal triad is consisted of the portal vein, the hepatic artery and the common hepatic duct. These structures are enclosed in a connective tissue and peritoneum up to the hepatic hilum. The term Glissonian sheath is reserved for the part that extendeds into the intrahepatic portion of the liver beyond the hilum. This sheath surrounds the portal triad structure before they enter into each section, giving rise to the resection of each segment (liver unit) separately without affecting the other segments [22]. This gives rise to the aberrance of the central segments 4, 5 and 8 ramifications like a bush and fan shaped. Consequently, a single segment resection will require several Glissonian sheath at various depth and is much more difficult. Were the priphral segments 6, 7, 2 and 3 have long branches that travels a distance reaching to these segments giving the appearance of tree like making their resection less complicated and usually requiring a single Glissonian sheath ligation [23].

### 3.5. Portal vein and liver resection

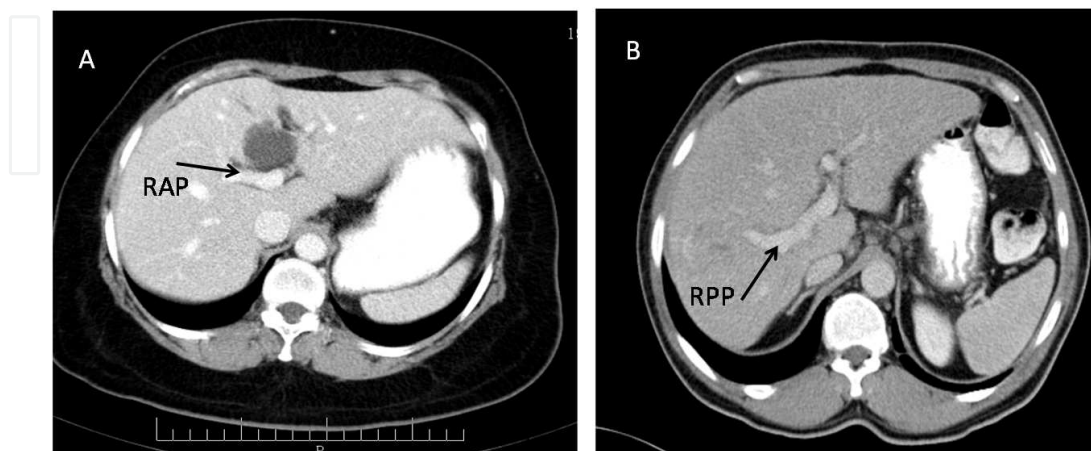
On the right side the portal vein is similar to the arteriobiliary segmentation. On the left side they differ from each other. The left portal vein consists of a transverse and an umbilical portion. The transverse portion only sends small branches to segment 4 and one or two branches to segment 1. All the larger branches arise beyond the attachment of the ligamentum venosum (umbilical portion of the left portal vein). **Figure.5.** This part of the vein gives right branches to segment 4 and on the left side it gives one branch to segment 2 and more than one to segment 3. The portal vein terminates where it joins the ligamentum teres at the edge of the liver. This unique structure explains the duael function of the left portal vein during in-utero and then in-adult life.



**Figure 5.** Portal vein with its divisions



On the right side the portal vein is usually very short and gives rise to the right anterior and right posterior branches. Each of these branches gives rise to two main segmental divisions. The right anterior gives both segment 5 and 8, where the right posterior gives segment 6 and 7. **Figure.6.**



**Figure 6.** A) right anterior portal branch (RAP) B) right posterior portal branch (RPP)

Usually there are very little variations in the portal vein. The commonest one is where the right anterior branch joins the left portal vein. This is very important to recognise especially when doing a left hepatectomy causes injury could happen to the right anterior section leading to the loss of segments 5 and 8. Another common anomaly is the absence of the main right portal vein giving rise to a trifurcation at the hilum of the portal vein to the left main, right anterior and the right posterior branches. This is important when doing a right hepatectomy to transect each branch separately not to injure the left portal vein [24-25].

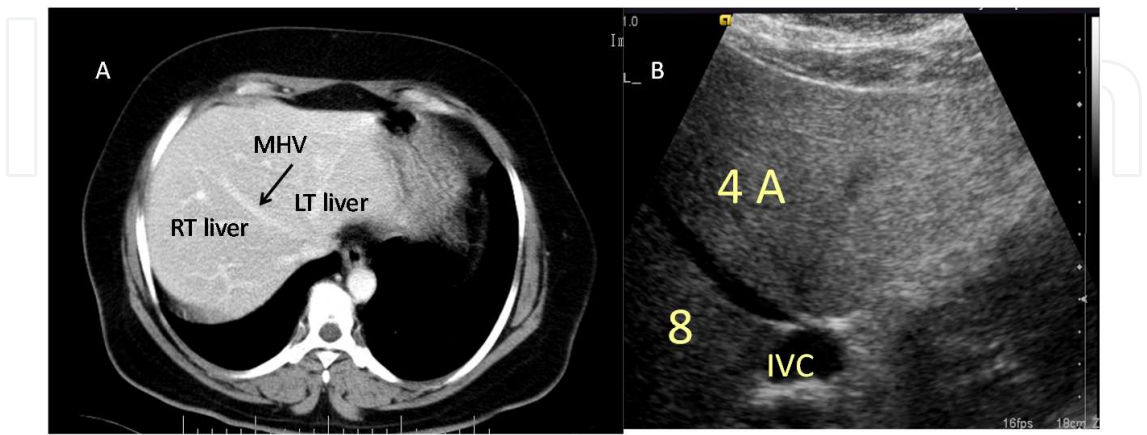
## 4. Clinical identification of the liver segments

For the clinical description of this part we will try to simulate what happens in clinical practice by dividing it to pre-operative radiology and intra-operative by intra-operative ultrasound.

### 4.1. Pre-operative

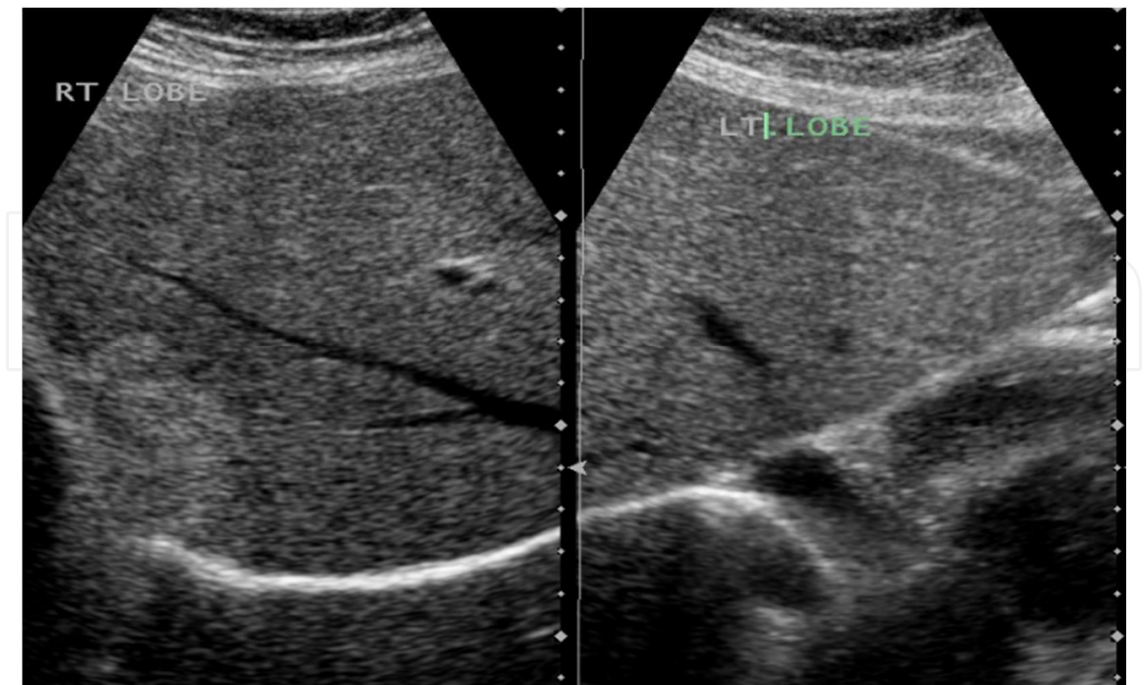
To try and make this part as simple as possible for the reader we will try to identify land marks that you should look for in the ultrasound, CT or MRI. The ultrasound is the usual screening tool used to see the whole liver and identify cystic from solid lesions. Then most centres will request a Triphasic CT scan of the liver in the hope to identify the nature of the lesion and the location. A physician should not comment on any lesion seen until full examination of all three phases (arterial, venous and delayed) are examined and the lesion is seen on all three phases to give the best chance of reaching the right diagnosis.

As we described the anatomy of the liver by the first order division and its landmark the middle hepatic vein, it is the same here. The middle hepatic vein can be seen on any of the above mentioned x-ray investigation. This will lead to the division of the liver to the right and left liver and identifying the lesion in which liver it lies. **Figure.7.**



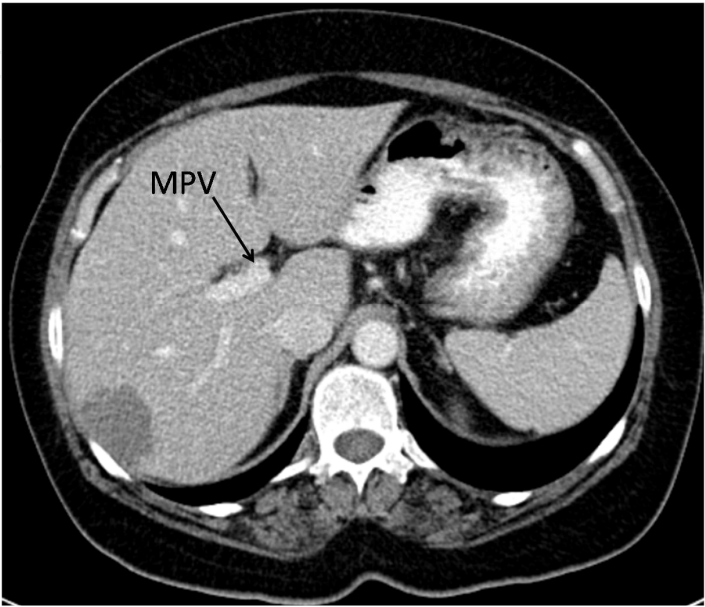
**Figure 7.** Middle hepatic vein (MHV) A) CT B) Ultrasound

The next step is to identify the falciform ligament and the right hepatic vein. This will divide the left liver to the medial and lateral sections and the right liver to the anterior and posterior sections alternatively. By this any lesion will be clearly seen in each section of the hemi-liver. **Figure.8.**



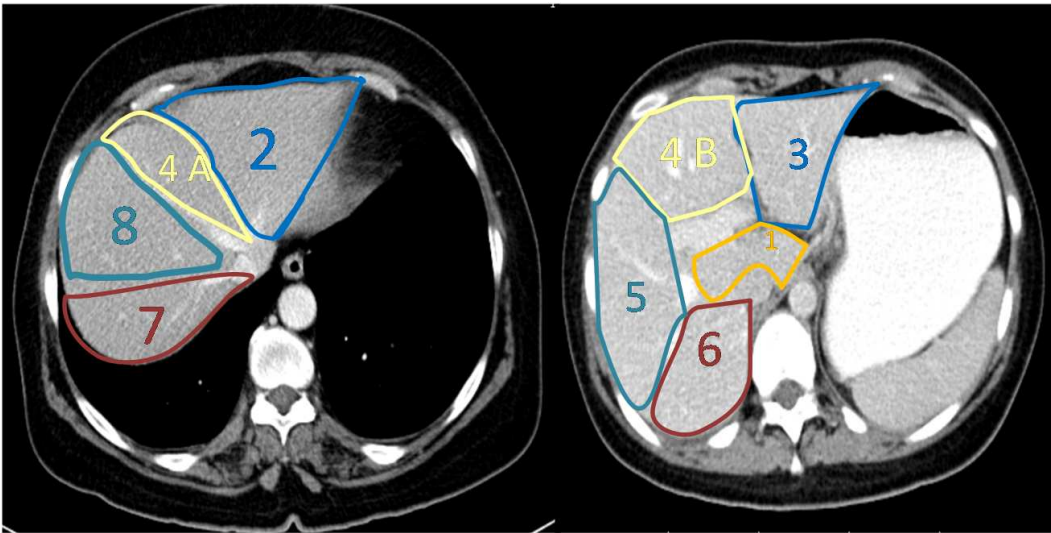
**Figure 8.** A) right hepatic vein (RHV) – with a lesion in seg 7 B) falciform (FL)

The last step is to identify the main portal vein and follow it till you reach to the bifurcation of the right and left branches which corresponds to the line that divides the liver into the upper and lower segments. This will give rise to the division of each section to its corresponded segments as described before in the anatomy part **Figure.9**.



**Figure 9.** Main portal vein (MPV), with a lesion seen in the right posterior lower segment (segment6)

If this simple technique is adopted a full idea of the lesions identity and location could be achieved with a high degree of certainty making the surgical planning much more feasible. **Figure.10.**



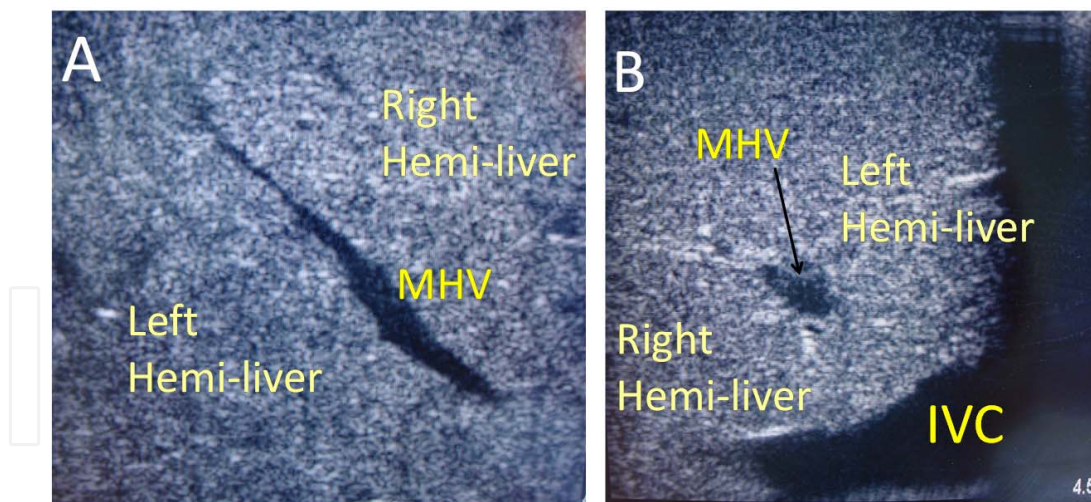
**Figure 10.** All segments identified on CT pre-operative



## 4.2. Intra-operative

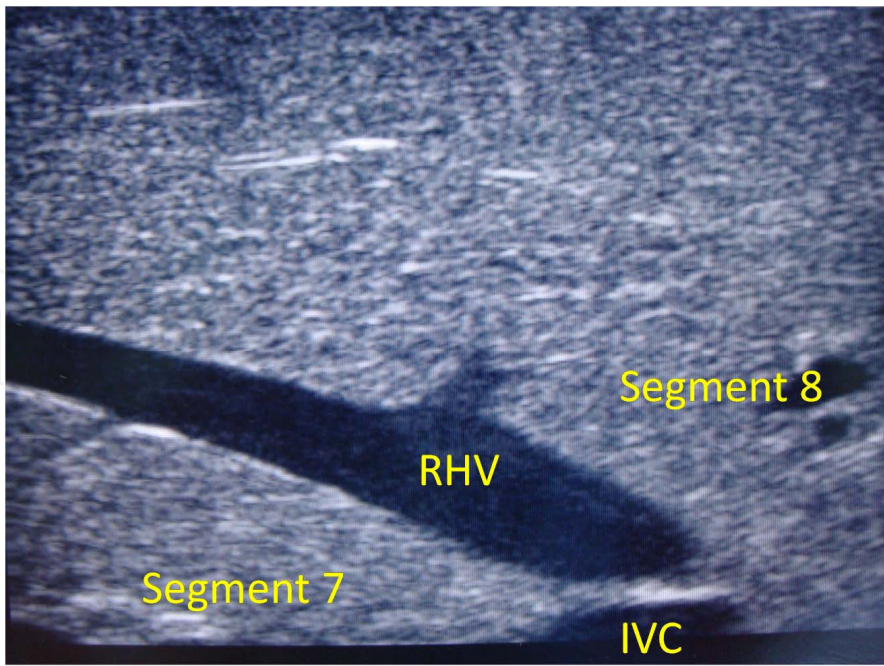
This is usually carried out by the intra-operative ultrasound [26-30], which we believe no liver resection should be done without mastering its use especially in malignant liver lesions. There are six simple steps that should be followed to get the best results of the ultrasound. 1) General inspection the whole liver as CT is not the ideal tool to identify superficial liver lesions. 2) A systemic recognition of all three hepatic veins and the main portal veins with its branches to identify all the liver segments. 3) Localize the tumour and determine which segments are involved. 4) Determine which segments needs to be resected to achieve good margins and balance it with the state of the liver trying at all times to go thru the anatomical lines to get an anatomical liver resection when possible to achieve the advantages mentioned before. 5) Mark the liver resection line on the liver surface. 6) Redetermine the distance from the tumour and the resection lines to be certain not to be close or even worse go thru the lesion.

To identify the segments the same method that was done pre-operative on CT is adopted by the localisation of the middle hepatic vein and drawing a line on it to get the right and left livers. **Figure.11.**



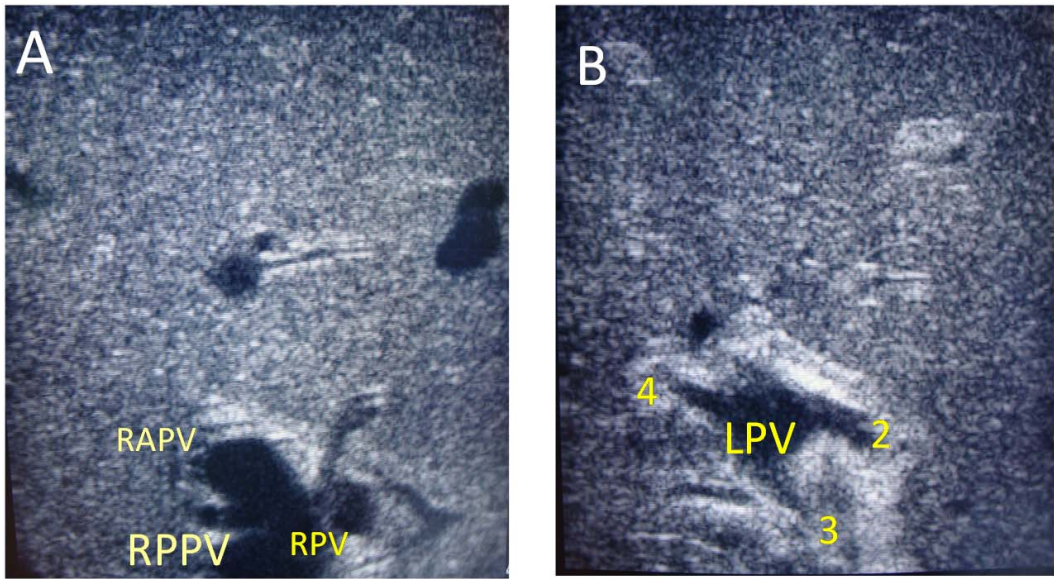
**Figure 11.** Intra operative ultrasound middle hepatic vein. A) longitudinal B) sagittal

The falciform ligament which divides the left liver to the medial and lateral sections can be seen on the surface. The left hepatic vein that divides segment 2 and 3 can be identified. On the right side the right hepatic vein is seen and a line is made to divide the right liver to the anterior and posterior sections. **Figure.12.**



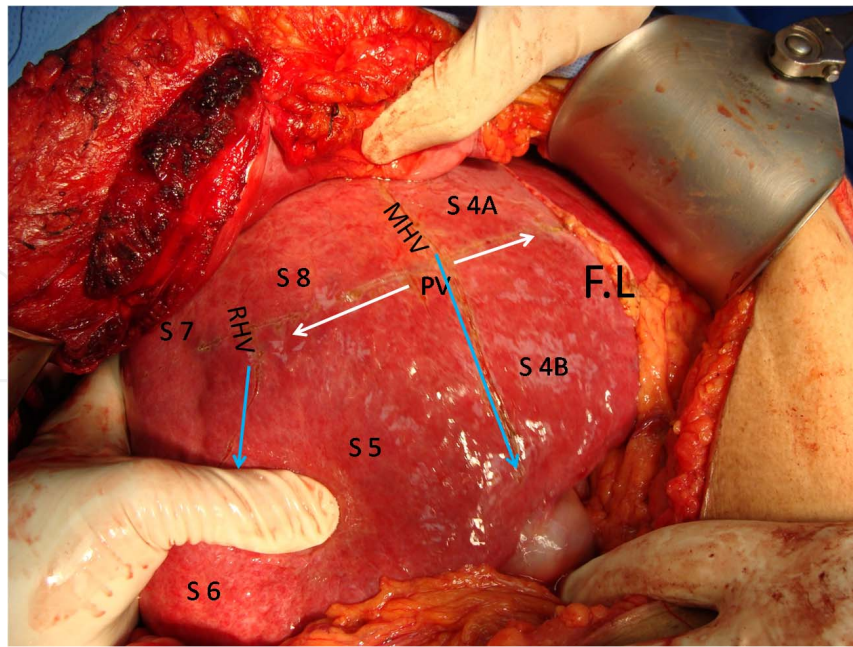
**Figure 12.** Intra operative ultrasound right hepatic vein.

The portal vein is then identified and followed to get all its branches and a line is made horizontally to get the upper and lower segments of the liver. **Figure.13.** After connecting all these lines the liver segments will be seen on the surface with the exception of segment 1 which is separate as we indicated before and can be seen over the IVC as the caudate lobe [31]. **Figure.14**



**Figure 13.** A) Right Portal veins (RPV) and its bifurcation to right anterior (RAPV) and right posterior (RPPV). B) Left portal vein (LPV) with its segmental branches





**Figure 14.** Liver segments on the liver intra operatively Portal vein (PV) in weight, middle hepatic vein (MHV), falciform ligament (FL), right hepatic vein (RHV)

## 5. Liver resection

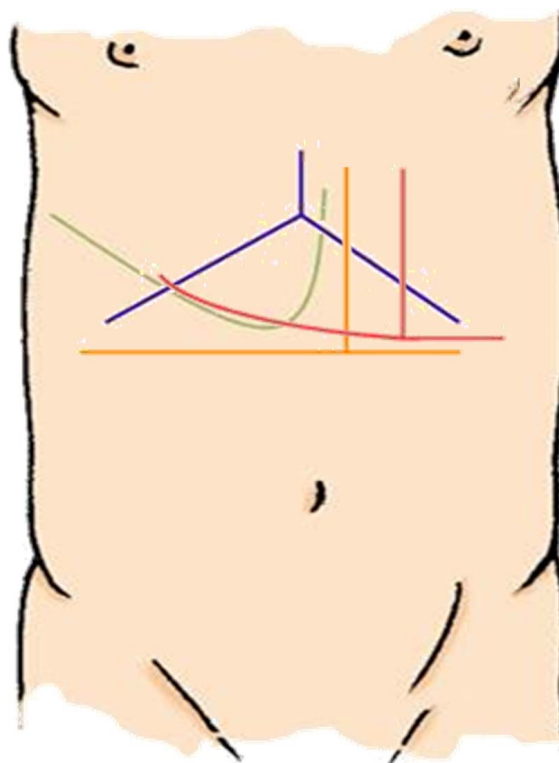
A full pre-operative evaluation is necessary before embarking on a liver resection especially that most of the patients with HCC are also cirrhotic. There are multiple models to evaluate these patients and the most widely used one is the Child-Pugh score. This model stratifies patients into stage A, B, and C. Also the size of the tumour and the patient's physiological function are very important. Therefore most recent staging systems for HCC has included three important factors to evaluate the patient before any liver resection, the tumour, the liver status and the patient factor. Although chronic liver disease is not an absolute contraindication to liver resection, the morbidity and mortality increases prohibitively with increasing hepatic dysfunction. Childs class C or late B patients are generally excluded from major resections whereas Childs A or early B patients may be candidates [8,31].

As we mentioned above radiological studies are important in determining the presence of portal hypertension, ascitis, tumour localization, feasibility of the resection, tumour extension, distance from the pedicles and segments necessary to be resected as well as extra-hepatic metastasis [8].

### 5.1. Position and skin incision

The patient is usually in supine position, with the arms extended 90° when possible [8]. To minimize risk of air embolism from disrupted hepatic veins[8] and to minimize blood loss from the resected raw liver surface[3]. The resection is performed with the patient in the

Trendelenburg position and as recommended by all liver surgeon with a low central venous pressure of 0-5 mmHg(15°).**Figure.15.**



**Figure 15.** Skin incisions for liver surgery

Preparation of the operative field includes the area from the lower abdomen up to and including the chest, extending from axillary line to axillary line [8]. The majority of liver resections are performed with either a right subcostal incision with upper midline extension (inverted hockey stick) or a chevron (Mercedes) incision [8]. Intra-operative ultrasound is done as described above and the necessary ligaments are released according to the segments of the liver that needs to be resected. Usually the falciform ligament is released to allow free mobilization of the liver and a better access for the ultrasound.

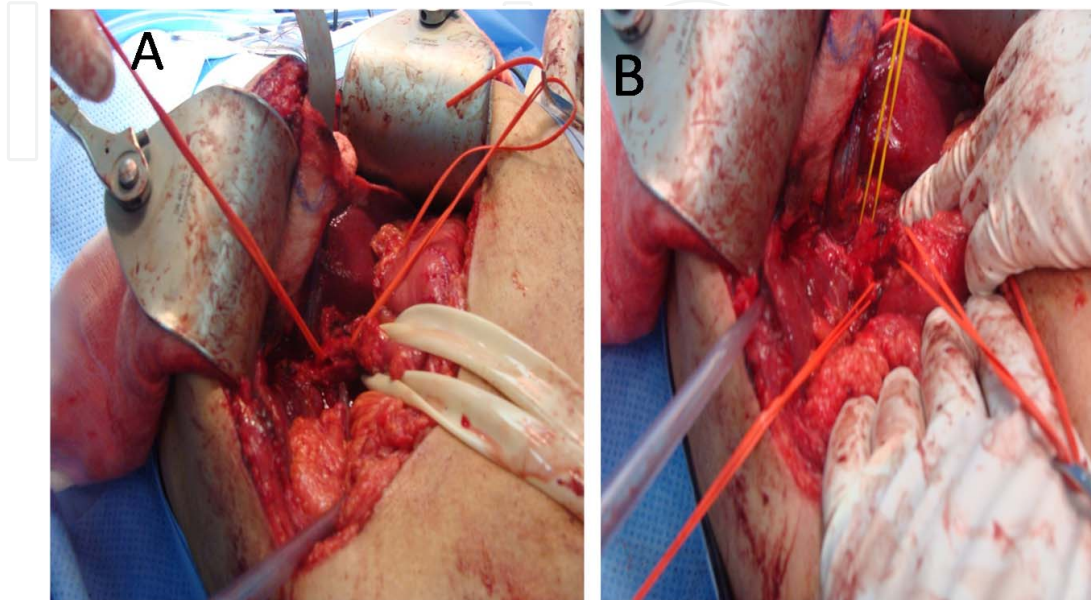
## 5.2. Approaches to liver resection

A liver surgeon should be familiar with all the techniques of liver resection because each has advantages and disadvantages making different resections more feasible.

### 5.2.1 Anterior approach

This technique is started by dissection of the portal triad and the hilar plate, where the right and left portal veins are identified. Figure.16. This makes the ligation of each portal branch more feasible. Then the vascular line of demarcation is seen and with the aid of intra-operative ultrasound to identify the rest of the vascular structures and the tumour. The liver is then

mobilized according to the part being resected. Parenchymal transection is then carried out followed by ligation of the hepatic veins. This type is usually applied in patients with less liver fibrosis and a right or left liver resection is needed.



**Figure 16.** Anterior Approach. A) the tape is around the main and right hepatic artery. B) The yellow tape is around the left portal vein

### 5.2.2 Posterior approach

The liver is mobilized according to the part being resected. This will give access to the right or left hepatic vein which is usually circled and controlled. Then two ways can be done, where some surgeons transect the vein followed by Pringle and transect the liver parenchyma by the fast technique in about 10-15 min. This is usually fast and has less bleeding and can be done in patients with right, left and both left lateral and right posterior (peripheral sections) liver resections specially if the patient has liver fibrosis because of the time and bleeding. However, this technique requires the excellent use of ultrasound to avoid injury to the main vascular structures, and prevent a long Pringle time for the unresected part of the liver.

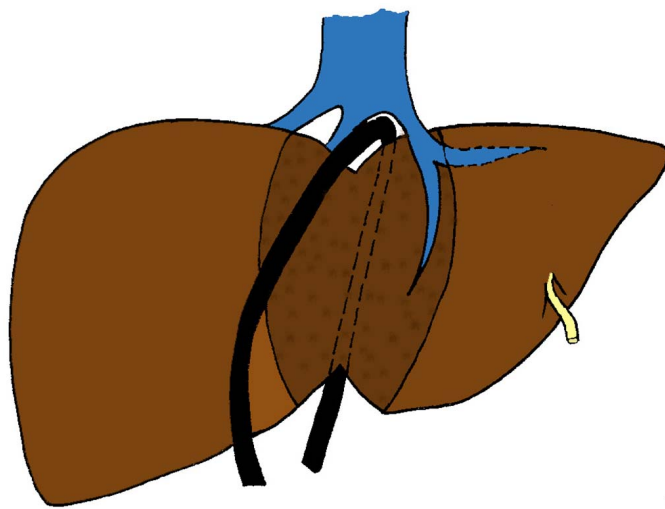
The other way is to start with the liver transection. This will not require the routine use of Pringle, however it can be associated with more blood loss, and longer transection time to control the bleeding. This is usually done in non cirrhotic patients specially in living related liver transplant.

By using also the posterior approach the portal pedicle will be transected at the end in the liver. This will decrease the injury or the narrowing of the unresected pedicle.

### 5.2.3 Hanging technique

This approach was adopted recently and was mainly applied in the right liver donors for living related liver transplant. This technique usually relies on the principle of keeping the liver well vascularised till the last minute to keep the liver viable.

The approach is done by using the avascular plane on the anterior part of the inferior vena cava and the window between the right and middle hepatic vein. This makes the passage of a tape from the inferior part of the liver to the superior part over the inferior vena cava. **Figure. 17.** The live is then transacted over the tape slowly while maintaining good haemostasis. Then the right hepatic vein and the right pedicle are transacted.



**Figure 17.** Hanging technique

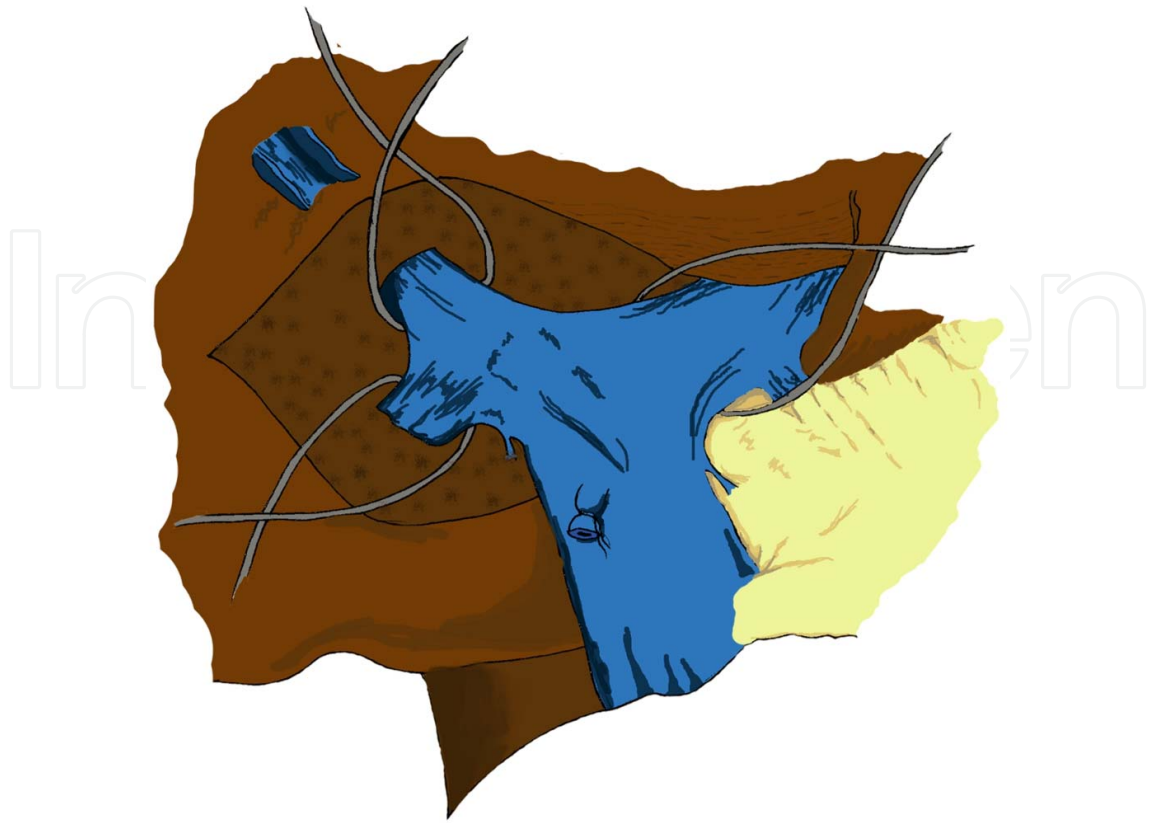
This method is used mainly in right liver resection, and the tape can be moved in any plane wanted with the aid of the ultrasound. It also has a non touch like technique, where the liver is not mobilized till the vascular inflow and outflow are transacted. However, it requires time and very experienced surgeon not to injure the inferior vena cava during insertion of the tape. It's also time consuming and not applied in cirrhotic liver because bleeding will be more.

### 5.2.4. Hilar plate dissection

This technique is started by hilar plate dissection and reaching to each sectional branch or even to each segmental branch. Control of the inflow is done first followed by mobilization of the part intended to be resected. The liver resection is then carried out and the outflow is then transacted. **Figure.18**

This method is best for central liver resection, however the hilar dissection requires experience and cannot be carried out in cirrhotic livers as bleeding will be difficult to control. Intra-operative ultrasound is very important to locate the portal branches and the outflow veins to decrease its injury, also the tumor localization is important not to cut through it.





**Figure 18.** Hilar dissection. Tapes around the sectional portal branches on the right and the main left portal vein on the left

#### 5.2.5. *Intra-hepatic ligation*

Peripheral and non anatomical liver resections are usually done by this approach. Intra-operative ultrasound is done to see the tumour and its blood supply. Mobilization followed by parenchymal transaction, where the inflow and outflow vessels are transacted in the liver.

#### 5.2.6. *Radio-frequency assisted liver resection*

The first description of RFA-assisted liver resection was published by Habib's group [32]. This technique showed a major improvement of liver surgery with low/no morbidity and mortality observed [33]. It also showed decrease in the anesthetic time, operative time, hospital stay, and blood loss. Liver resection became a comparatively safer procedure [34].

Liver resection utilizing radiofrequency-induced resection plane coagulation as a safe alternative to the established resection techniques. The residual zone of coagulation necrosis remains basically unchanged during a follow up of three years, with a safety margins of 0.5-3.5 cm and Histopathological proof [35].

The RadioFrequency Assisted liver resection has 5 steps [32, 36]:

**Step 1:** First or inner line is made on the liver capsule with argon diathermy to mark the periphery of the tumor. This is done by bimanual palpation and intraoperative ultrasound.



**Step 2:** Second or outer line, again using argon diathermy, is made on the liver capsule 2 cm outside (away from) the inner line to mark the site where the probe is positioned to achieve coagulative necrosis.

**Step 3:** Coagulative necrosis is produced along a line that follows the second or outer line. The cooled-tip RF probe and a 500-kHz RF Generator, which produces 100 W of power and allows measurements of the generator output, tissue impedance, and electrode tip temperature. The probe contains a 3-cm exposed electrode, a thermocouple on the tip to monitor temperature and impedance. Two coaxial cannulae through which chilled saline is circulated during RF energy application to prevent tissue boiling and cavitation immediately adjacent to the needle.

**Step 4:** Further probe applications are deployed to obtain a zone of necrosis according to the depth of the liver parenchyma to be resected. Application of the RF energy should begin with the area deepest and farthest from the upper surface of the liver. Once the deepest 3 cm of tissue is coagulated, the probe is withdrawn by 3 cm to coagulate the next cylinder of tissue, and so on until the upper surface of the liver is reached. Each application requires about 60 seconds of RF energy.

Before each probe removal, the saline infusion is stopped to increase the temperature close to the electrode. This results in coagulation of the needle tract during withdrawal and reduces the possibility of bleeding from the probe tract and the liver capsule.

**Step 5:** The liver parenchyma is divided using the scalpel. The plane of division should be situated midway between the first and second line so as to leave a 1-cm resection margin away from the tumor and leave in situ 1 cm of burned coagulated surface.

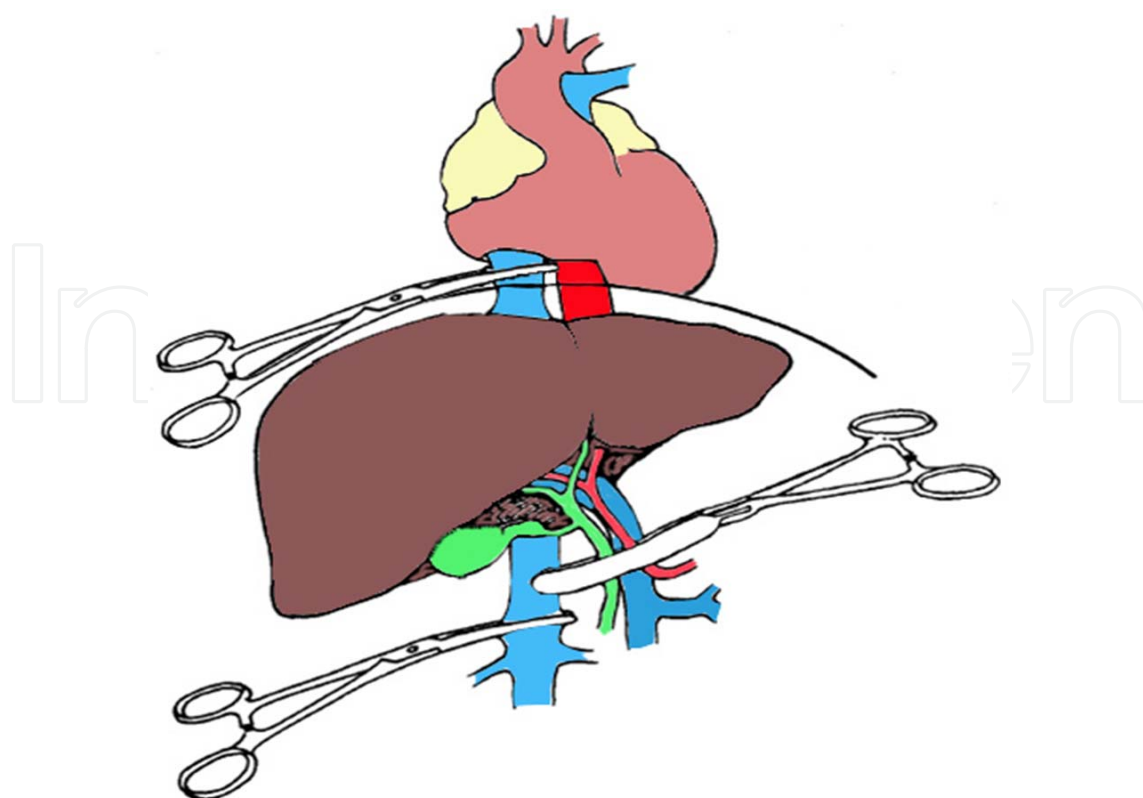
#### *5.2.7. Total hepatic vascular exclusion*

This method combines total inflow and outflow vascular occlusion of the liver, isolating it completely from the systemic circulation. It is achieved after complete liver mobilization, application of inflow occlusion by Pringle manoeuvre, and then placing a clamp across the infra-hepatic IVC above the renal veins and the right adrenal vein followed by a supra-hepatic IVC clamp above the opening of the major hepatic veins. After the parenchymal transection and hemostasis, the clamps are removed in the reverse order[37]. **Figure 19.**

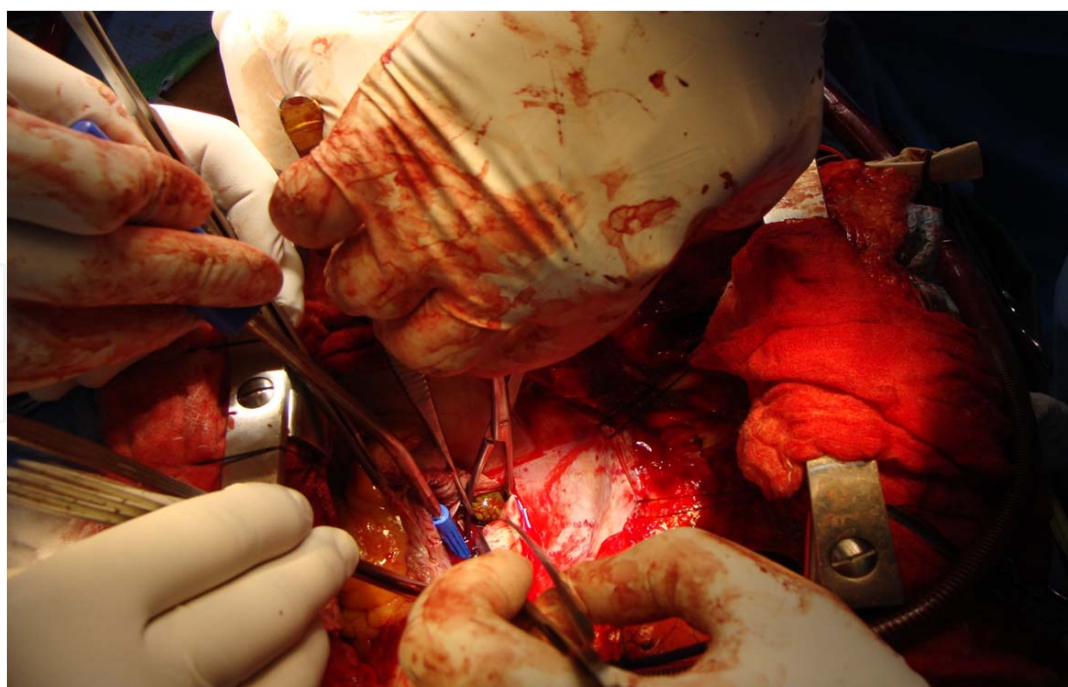
This results in a significant haemodynamic instability, with a substantial reduction in cardiac output, though blood pressure is usually maintained [38]. Around 10% of patients cannot tolerate it haemodynamically[39].

The ischaemic limit is 60-90 mins for patients with normal liver function [40]. In patients with cirrhosis, the maximal ischaemic time is halved and, in addition, the liver function before surgery must be at the better end of the spectrum[41]

However this technique is not done nowadays with the advanced surgical techniques except in rare conditions like tumour thrombus reaching the IVC or the atrium **Figure 20.** It also prevents intra-operative thrombus migration, and allows major hepatic veins or IVC reconstruction [37].



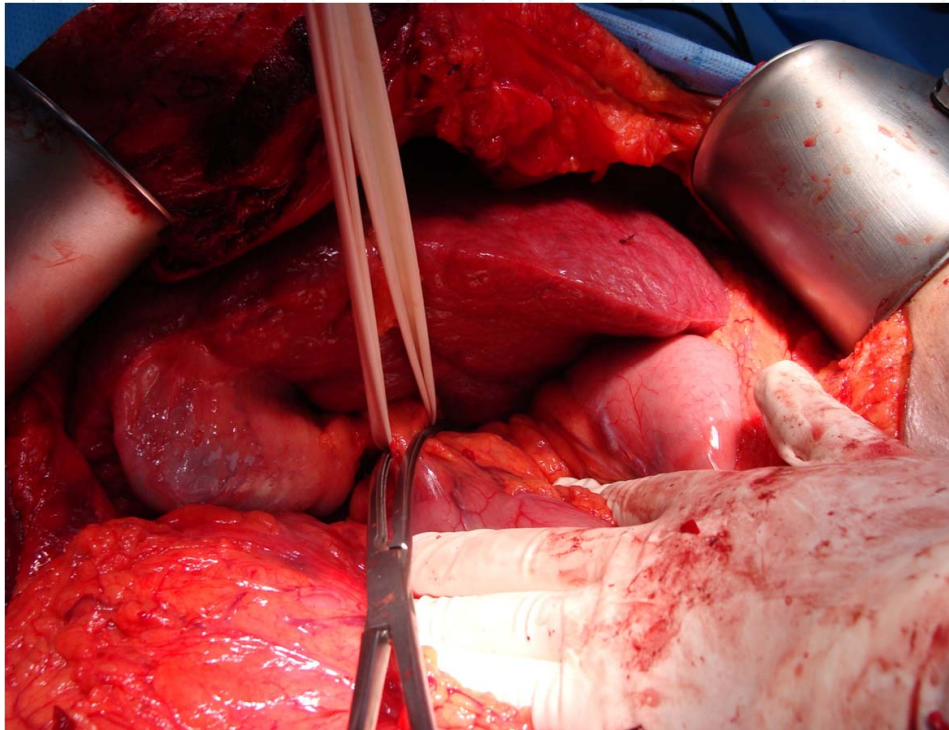
**Figure 19.** Total hepatic vascular occlusion



**Figure 20.** A case of HCC with atrial thrombus with total vascular occlusion. The thrombus is being removed from the right atrium.

However, with the development of liver surgery there has been use of some part of vascular occlusion done selectively or in combinations:

1. In-flow control:
2. Pringle manoeuvre; This is done by occluding the total inflow to the liver. This is usually in cases of central liver resection or major resections where a large volume of blood is suspected to be lost. **Figure 21**



**Figure 21.** Pringles manoeuvre

1. Hemi-Hepatic control; This is done as described before in the right or left hemi-hepatectomy by controlling the right or left pedicle at the glissonian sheath. **Figure 16**
2. Sectional control; This is done by isolating and controlling the sectional branches as described in the (Hilar Plate Dissection) as described above to be able to isolate each section without affecting other parts of the liver. **Figure 17**
3. Out-Flow Control:
4. Total hepatic control; this is achieved by either clamping of the IVC above and below or clamping the hepatic veins without affecting the flow of the IVC as nowadays done in piggy-back liver transplant.
5. Isolated hepatic vein control; this is done as described in the posterior approach where full mobilization of the liver is done and the right or left hepatic vein is isolated and clamped with-out affecting the IVC or the other hepatic veins



These all can be done separately or combined to achieve a bloodless liver resection and maintain patient stability.

### 5.3. Parynchymal transaction

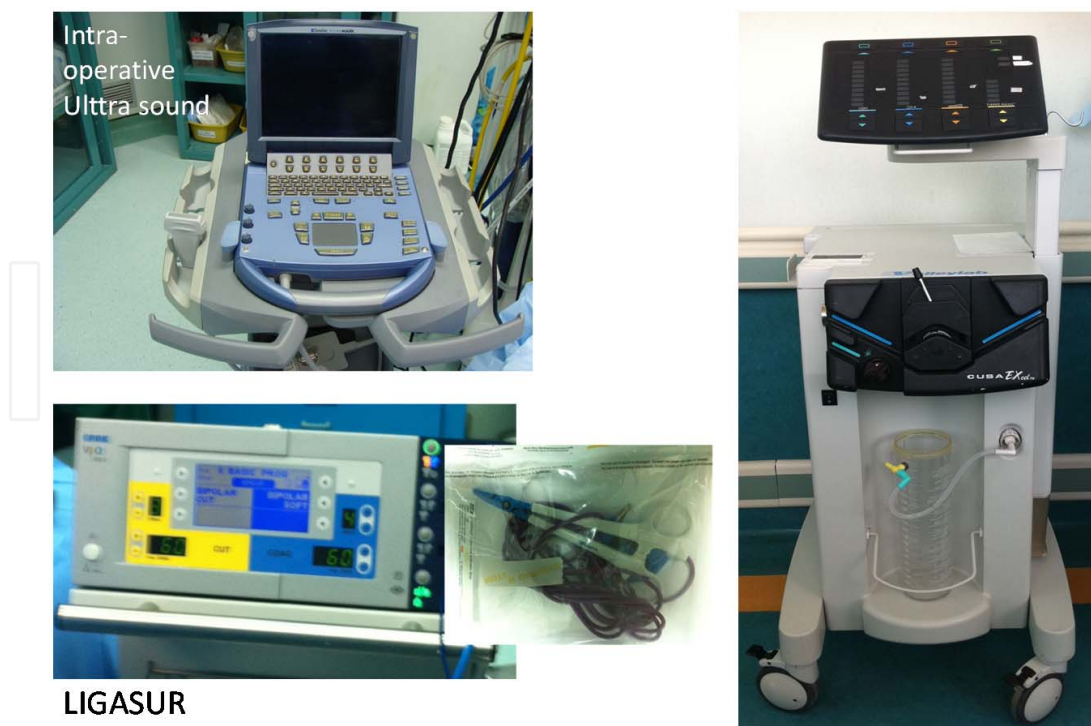Meyer-May described the use of Kocher-like clamps to crush liver parenchyma in 1939 [12,42] and haemostatic clamps such as Kelly clamps [43] are still used to crush small areas of the parenchyma, leaving the vessels intact.

Lortat-Jacob used the handle of a scalpel[9] and Lin described the use of finger fracture to remove parenchyma under inflow occlusion to isolate vessels and bile ducts for ligation[44,45].

Ultrasonic dissection has been developed using the CUSA (Cavitron Ultrasonic Surgical Aspirator)[42], this allows for delineation of the hepatic veins, particularly at the junction with the inferior vena cava, and prevents positive margin [45]. It has been shown to be very effective for division of the parenchyma with low blood losse [46,47].

Water-jet dissection [48-49] reduced blood loss, blood transfusion, and transaction time compared with CUSA, but there is increased risk of venous air embolism [45].

Harmonic Scalpel allows sealing of small vessels during the transaction of liver parenchyma. It can be used alone or in combination with clamp crushing or CUSA. It also have been adopted for laparoscopic resections [50,51] with limitation in the dissection around the main trunk of the hepatic veins [52]. **Figure.22**



**Figure 22.** Instruments used for liver resection

Ligasure designed to seal small vessels by a combination of Ultrasonic dissection of liver parenchyma using compression pressure and bipolar radiofrequency (RF) energy [45], it was found to be more useful in laparoscopic resection than open.

Tissue Link dissecting sealer, where saline runs to the tip of the electrode to couple RF energy to the liver surface and achieve coagulation [45].

All these instruments have been used and according to many authors each has been claimed to be better than the other. Our believe is that a surgeon should be familiar with all techniques and instruments as each hospital has its own and when instrument malfunction occurs he will have the ability to adopt and rise up to the situation.

## 5.4. Specific liver resections

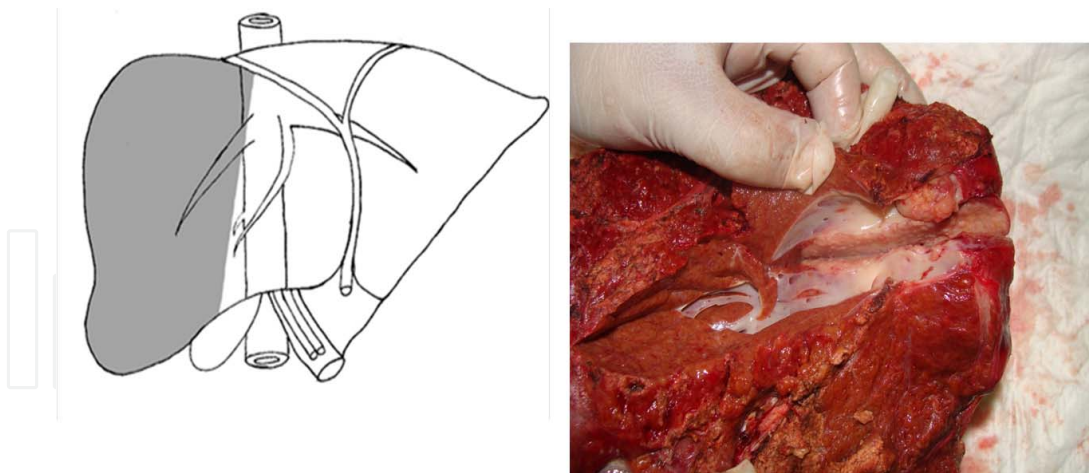
### 5.4.1. *Right hepatectomy*

Resection of the right hemiliver (segments 5, 6, 7 & 8) is one of the most common types of liver resection. It involves removing all hepatic parenchyma to the right of the middle hepatic vein [8]. This can be done by the Anterior, Posterior or the hanging techniques described above. However, it is important to see which approach will be better for each patient taking into consideration the tumour and the status of the liver.

This starts with mobilization of the right liver by division of the falciform, coronary and right triangular ligaments. Then vascular inflow and outflow control should take place. Three general approaches have been described for achieving vascular inflow control: 1) extrahepatic dissection within the porta hepatis, with division of the right hepatic artery and right portal vein prior to division of the parenchyma (anterior approach) 2) intrahepatic control of the main right pedicle within the substance of the liver prior to parenchymal transection (Intra-Hepatic ligation); and 3) intrahepatic control of the pedicle after parenchymal transaction (hanging technique or posterior approach) [8].

Then the right hepatic artery, right portal vein and the right hepatic duct are lighted and divided extrahepatic. The right liver is then dissected from the inferior vena cava either before or after according to which approach is being adopted. The short hepatic veins that drain from the right hemi liver to the inferior vena cava should be ligated and divided as well as the Hepato-caval ligament. The right hepatic vein is then dissected extrahepatic and ligated. After this step a clear line of demarcation will appear as the right hemi liver will become darker and ischemic. Liver parenchyma transaction will be done on the right border of the middle hepatic vein. Some vascular anomalies can cause the demarcation line of a right hepatectomy to be along the left border of the middle hepatic vein so care must be taken to preserve segment 4 branches or it will become congested. Blood loss control can be achieved by pringle's maneuver, using of low central pressure or extrahepatic clamping of the middle and left hepatic veins. **Figure.23**



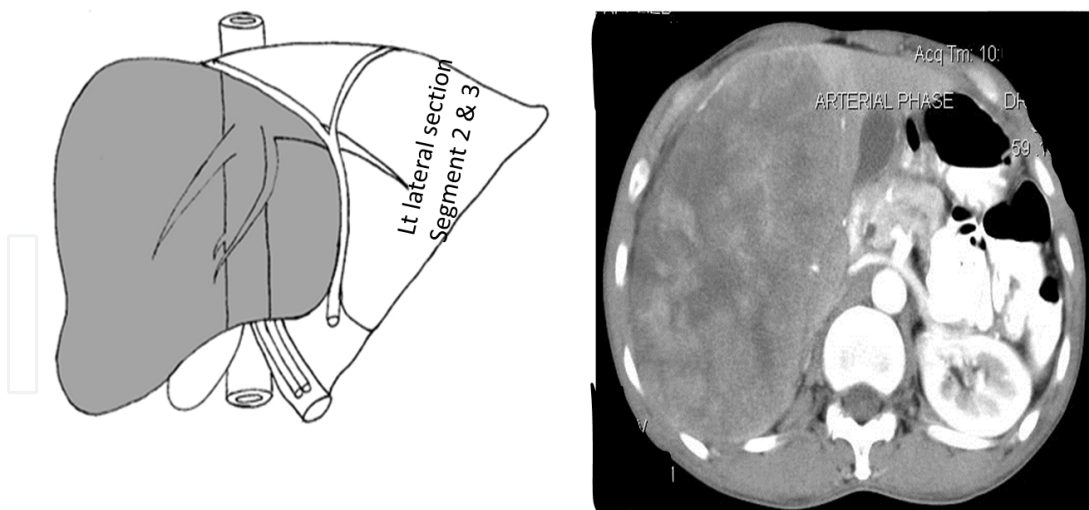


**Figure 23.** Right Hepatectomy; a right liver specimen with tumor invasion in the right hepatic vein

#### 5.4.2. *Extended right hepatectomy (Right trisectionectomy)*

Right hepatectomy + extrahepatic ligation and division of the branches of the hepatic artery, portal vein and bile ducts to segment 4 with the division of the right and middle hepatic veins leaving the left hepatic vein and portal triad supplying the left lateral section intact [18].

The left triangular ligament may be preserved to prevent liver rotation and venous outflow occlusion post resection [42]. **Figure.24**

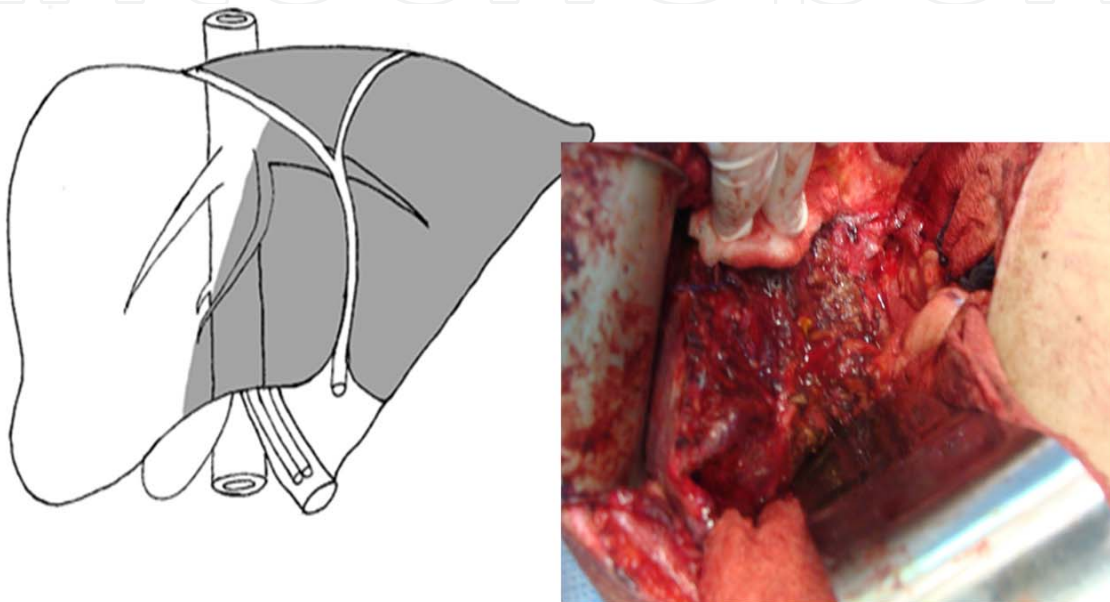


**Figure 24.** Right extended tri-sectionectomy; a CT scan of a liver tumor that was resected as shown in the drawing

#### 5.4.3. *Left hepatectomy*

This can be done in the same manner as the right liver resection, however it will require the identification of the left portal triad. Starting with mobilization of the left liver by division of

the falciform and the left triangular ligaments. Extrahepatic division of the extrahepatic branches of the left hepatic artery, left portal vein and left hepatic duct. Isolation of the trunk of the middle and left hepatic vein. Parenchymal transection done along the plane demarcated by the ischemic left liver along a plane on the left side of the middle hepatic vein. The same should be considered as the line of demarcation can be on the right of the middle hepatic vein. The left hepatic vein is ligated intrahepatically. Blood Loss can be reduced by using Pringle's maneuver plus either low central venous pressure or selective hepatic vascular occlusion by clamping the right hepatic vein. **Figure 25**



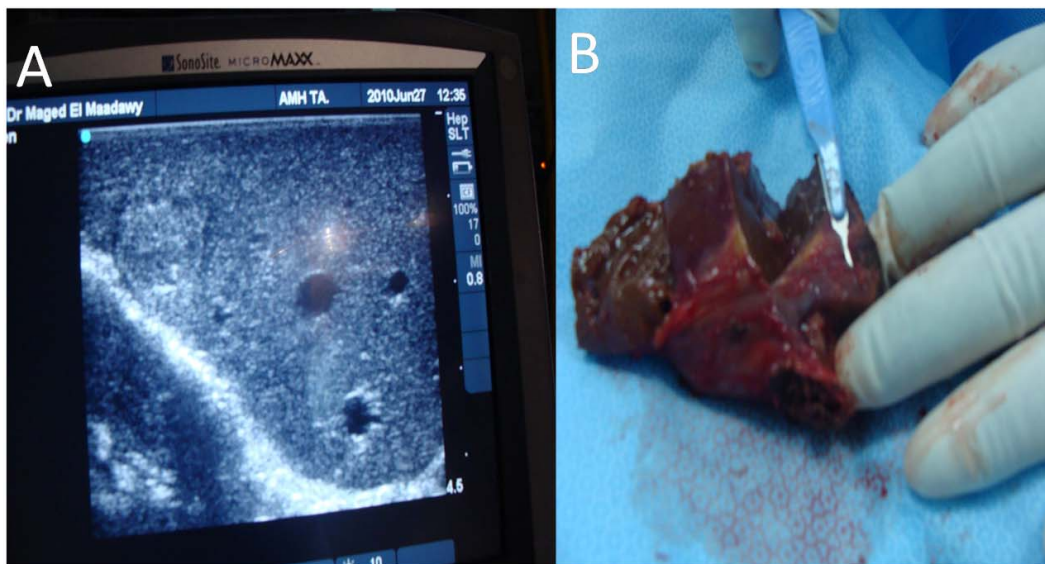
**Figure 25.** A case of Left Liver resection; the middle hepatic vein seen in the remnant liver with a schematic demonstration

#### 5.4.4. Extended left hepatectomy (Left trisectionectomy)

Similar to left hepatectomy in addition of the right anterior section. Care should be done to preserve the hepatic arterial, portal venous and bile duct branches to the right posterior section and the right hepatic vein. If the right inferior hepatic vein is large it should be preserved so the venous drainage to segment 6 will not be affected [18].

#### 5.4.5. Left lateral sectionectomy

Isolated segment II or III resection is uncommonly performed because of the ease of combined segment II and III (left lateral section) and the small volume of each segment. In the presence of cirrhosis or when multiple segmental resections are performed, isolated resection may be necessary. The left hepatic vein is identified extrahepatically and the left lateral sectional portal triad is ligated at the umbilical vein and the falciform ligament. **Figure.26.** Then the hepatic transection is carried out with very minimal blood loss.



**Figure 26.** A) left lateral section as seen on intra-operative ultrasound. B) the specimen with tumour to check for margins

#### 5.4.6. Right posterior sectionectomy (Segment VI and VII)

This can be achieved by most techniques described above depending on the tumour size and the status of the Liver. Full mobilization of the right liver with division of the posterior draining veins. The right portal pedicle is exposed, and the anterior and posterior branches are identified (Hilar plate approach). The posterior pedicle is clamped, and the line of demarcation is evident. The pedicle may be divided, and parenchymal dissection may be performed in standard fashion. The line of transection is horizontal and posterior to the right hepatic vein. However, the right vein may be sacrificed during this procedure since the anterior section will be adequately drained by the middle hepatic vein[8]. If the liver is cirrhotic we would advise the use of an extrahepatic approach like the posterior approach to minimize the blood loss and injury to the right anterior portal triad.

#### 5.4.7. Right anterior sectionectomy (Segment V and VIII)

This is extremely rare and very difficult because of its location between both the right and middle hepatic veins with the importance of not injuring any of them. This is why if it is done it is combined with segment IV (Central liver resection) to remove the middle hepatic vein and have a safe distance from the right hepatic vein. The approach is similar to the right posterior sectionectomy were the right anterior portal triad is seen and ligated to stop the inflow and get the line of demarcation.

#### 5.4.8. Isolated segment II or III resection

For removal of either segment II or III, the inflow pedicle is ligated, but the main left hepatic vein is preserved because it provides the only venous drainage to the remaining segment. The

inflow pedicles to segments II and III branches directly from the umbilical portion of the left main portal vein. To isolate these pedicles, the left lateral section is shifted cephalad using traction on the divided falciform ligament. If present, the parenchymal bridge between segment III and IV is divided with electrocautery. Dissection of the umbilical fissure to the left of the portal vein is performed. Ligation of either segment II or III pedicles demarcates the boundary between them. The left hepatic vein may be clamped to reduce blood loss, but clamping is generally unnecessary if the central venous pressure is low. Liver transection then proceeds in an oblique antero-cranial plane with attention to preserve the left hepatic vein [3].

#### 5.4.9. *Isolated segment VII*

To expose this segment dissection of the right triangular ligament is necessary. The vascular pedicle of segment VII originates from the right lateral glissonian pedicle and enters the parenchyma in a common trunk at segment VI, this will run deep and divide to two branches anterior to segment VI and posterior to segment VII.

After mobilizing the infundibulum of the gall bladder and dividing the lateral peritoneum of the hepato-duodenal ligament the lateral pedicle can be easily freed as well as the artery. Once this is identified with the bile duct, the right branch of the portal vein is freed. The bile ducts will never be dissected outside the parenchyma but only transparenchymally at the end of the resection to prevent damage to the adjacent hepatic ducts. Clamping of the arterial branch will lead to blanching of the entire right anterior section. The fissure of the right hepatic vein will indicate the upper resection margin. The vein could be left in place or removed in case of neoplasm infiltration, also isolated resection of segment VII with ligation of the right hepatic vein can be safely performed, venous outflow of segment VI should be insured by preserving the accessory hepatic veins and the right inferior hepatic vein (present in 25%) to prevent the transitory venous congestion of segment VI with hemorrhage from the resection margins after isolated removal of segment VII. After clamping of the lateral glissonian pedicle the trunk of the right hepatic vein will be clamped and divided. Parenchymal dissection will follow the appearing ischemic demarcation line and the dissection plane will start from the top downward between segment VII and VIII. The pedicle will be exposed with the dissection once it has been divided the arterial and portal branches at the hilum can be unclamped, segment VI returns to its normal color and the inferior demarcation line will become evident.

#### 5.4.10. *Isolated segment VI*

Similar to segment VII, after mobilization of the right liver, ligation of the inferior or accessory suprahepatic vein if present and clamping of the arterial and portal branches which will produce the ischemic demarcation line.

The parenchyma is divided starting from the lower margin of the liver proceeding along an oblique plane from the right to the left and from the front to back. Deep in the parenchyma the lateral pedicle is ligated. The glissonian pedicle is then unclamped at the hilum and segment VII will return to the normal colour, the upper dissection margin will follow the ischemic line between the two segments VI and VII.



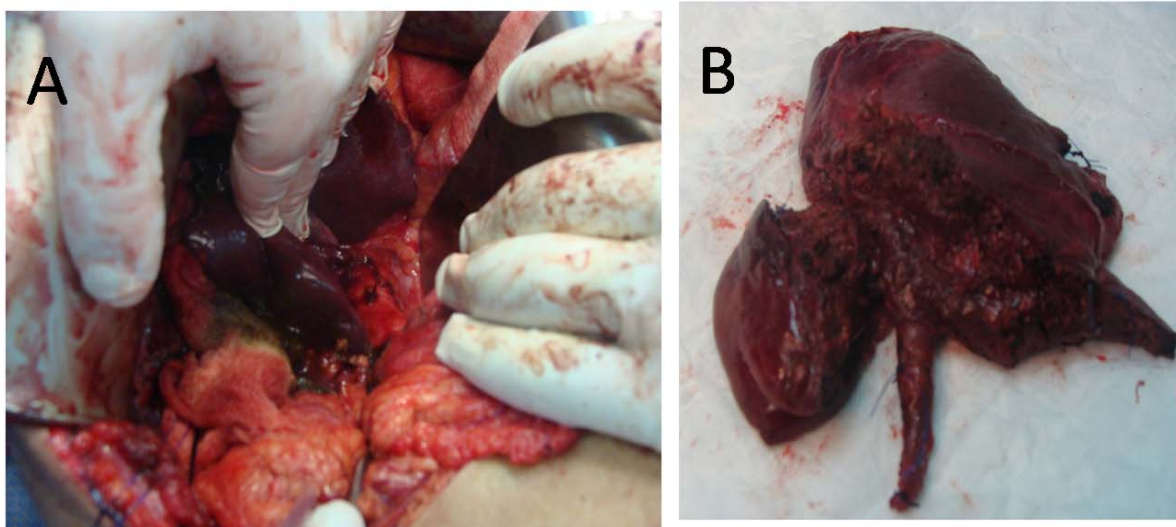
#### 5.4.11. Isolated segment IV

Segment IV is divided into two subsegments, IVA and IVB, based on the inflow pedicles. Isolated resection of IVB is usually done in an intra-hepatic ligation method and most often with segment V in cases of gallbladder carcinoma. Where outflow control for segment IV resection is usually not obtained until the liver is divided. After dissection of the hepatoduodenal ligament the left branches of the hepatic artery are identified and then the middle branch is ligated and divided. Dissection will be carried out along the gall bladder-inferior vena cava plane. Glissonian capsule divided above the hilar plate. The portal branch is usually seen with the hilar plate and dissection with control by Bull-dog clamps to see the line of demarcation. At this point segment IV will only be attached to the Middle Hepatic vein which will be transfixed.

#### 5.4.12. Isolated segment I "Caudate lobe"

This is the least popular liver resection as all the other segments can be done in an intra-hepatic ligation method or in a non-anatomical approach. However, the Caudate liver resection has its own unique location above the inferior vena cava and its own blood supply giving it the excellent challenge for any liver surgeon. There are 5 approaches:

1. **Bilateral approach:** For isolated caudate lobectomy, the caudate lobe is approached from both right and left side after complete mobilization of the liver with control of the suprahepatic and intrahepatic inferior vena cava as well as the right hepatic vein and the common trunk of the middle and left hepatic veins. Then the caudate lobe is detached from the inferior vena cava along the anterior surface of the retro-hepatic IVC and the short hepatic veins are identified and divided. The hepatogastric ligament is detached from the undersurface of the liver and the fibrous hepatocaval ligament need to be divided to free the Spiegelian lobe from the IVC and the diaphragm. All short hepatic veins are ligated and divided. So the caudate lobe is free from the inferior vena cava. The branches of the to the para caval portion of the caudate lobe from the right portal vein, right hepatic artery and duct, branches to the Spiegelian lobe from the left portal vein, left hepatic artery and duct are ligated and divided. By careful dissection the liver is detached from the surroundings and the right, middle and left hepatic veins. In this step; 2 important landmarks for this dissection : A) the angle between the right hepatic vein and the inferior vena cava i.e the top of the caudate lobe. B) the meeting point between the caudate process and the right liver. An imaginary line joining these two points is considered as the caudate boundary for the liver transection. Meticulous care should be applied not to injure the major vessels or induce bleeding which will be difficult to control.
2. **Left sided approach:** Similar to the bilateral approach with the exception that the dissection is mainly from the left side of the liver. In small tumours <3cm, if an isolated partial caudate lobectomy or left hepatectomy combined with complete caudate lobectomy is carried out. **Figure 27**
3. **Right sided approach:** Similar to the bilateral approach with the exception that the dissection is mainly from the right side of the liver. In thin patients with right hepatectomy combined with caudate lobectomy.

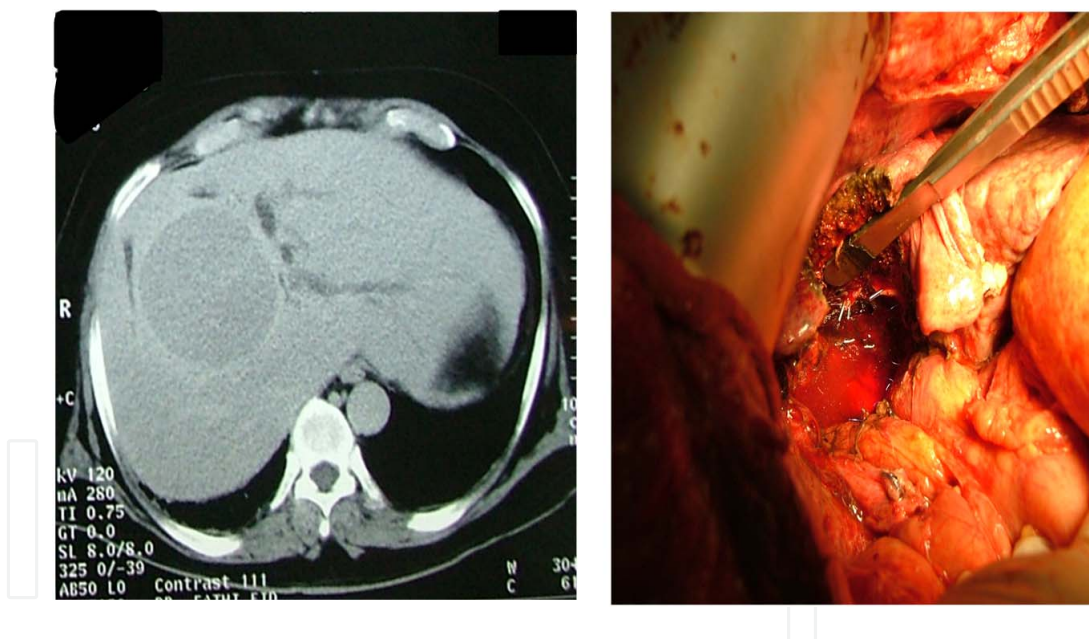


**Figure 27.** Caudate liver resection, A) the lobe is removed from the IVC and lifted up (left approach). B) The specimen of the caudate with the left liver and the CBD for cholangiocarcinoma

4. **Anterior approach:** This approach provides a better operative field by opening the mid plane of the liver widely so the major hepatic veins and the Hilar plate will be exposed to direct vision thus will facilitate tumour resection from the main vessels. For tumours >4cm especially when the tumour is located in the paracaval portion or in close contact with the major hepatic veins. With the same technique of the bilateral approach. After freeing the caudate lobe from the retro-hepatic inferior vena cava, pringle's maneuver is then applied. The liver is transected through the mid plane starting from the point between the root of the right and middle hepatic veins to the fossa of the gall bladder. This is better done using the hanging technique. When the transection reaches the Hilar plate at the hilum, the portal triad of the caudate lobe is isolated and divided. The caudate lobes then separated from the major hepatic veins in one block with the tumour. After removal of the specimen all bleeding points and bile leak should be controlled individually.
5. **Retrograde caudate lobectomy:** Used if the tumour is closely adherent to or infiltrating the inferior vena cava, or if the tumour is too large in size to be turned from one side to the other. Mobilization of the liver by the division of all the ligaments, control of the hepatoduodenal ligament, suprahepatic and intrahepatic inferior vena cava for possible occlusion if necessary. The liver is transected along the mid plane 1cm from the tumour, the hepatic veins are exposed under direct vision and carefully dissected from the specimen, ligation and division of the caudate portal triad from the right/left hepatic arteries and veins. In combined Left/right hepatectomy with caudate lobectomy the hepatic pedicle can be transected accordingly. The specimen will be attached only to the inferior vena cava. The last step here will be the division of the short hepatic veins, and if the tumour is attached to the IVC part of it could be resected with the tumour and then it'll be repaired or reconstructed.

#### 5.4.13. Central liver resection

Segments IV, V, and VIII (also known as mesohepatectomy) is rarely performed. This resection involves ligation of inflow vessels from both the right and left portal pedicles. The resection is performed by combining the techniques of segment IV resection and right anterior sectionectomy. Dissection begins at the hilum and the umbilical fissure with the goal of inflow control. The right anterior sectional pedicle is isolated, as are the segment IV pedicles. The division of the liver parenchyma begins to the right of the umbilical fissure (or within it if the tumor is nearby). **Figure.28.** Care should be given to avoid ligating the left main portal umbilical branch. Dissection is continued upward to the main trunk of middle hepatic vein. The right anterior sectional pedicle is ligated to demarcate the boundary of the liver resection on the right side. Liver transection proceeds in the plane of the right hepatic vein until it meets the left resection plane. At this point, one should be cautious with handling the freely dangling central lobe. Excessive traction may tear the thin-walled middle hepatic vein, resulting in massive hemorrhage. Gently hold the lobe and divide the base of the middle hepatic vein. This procedure removes the gallbladder, central lobe, and middle hepatic vein en bloc, leaving the caudate, right posterior section, and left lateral section intact. The raw liver surface may be covered with a flap of omentum.



**Figure 28.** Central liver lesion as seen on CT scan and the same patient intra-operatively after resection

#### 5.5. Control of bleeding

To minimize blood loss from the resected raw liver surface the patient is placed 15 degrees in the Trendelenburg position [3]. Low venous pressure is maintained by minimizing fluid infusion and restricting intraoperative blood transfusion unless more than 25% of the blood volume is lost [53,54]. Systolic blood pressure is kept above 90 mm Hg, and intraoperative urine output is maintained at about 25 mL/hour [3].

Dissection and control of the hepatic veins performed prior to parenchymal transection.[8].

Venous outflow draining is divided after dividing the inflow vessels[8], unless the posterior approach is adopted with a Pringles manoeuvre to prevent liver congestion.

Control of the suprahepatic and intrahepatic inferior vena cava [18], pringle's maneuver[3,18], and mobilization with parenchymal transection performed with a low central venous pressure < 5 mm Hg [3,11] can decrease the bleeding amount significantly.

## Author details

O. Al-Jiffry Bilal<sup>1,2</sup> and Khayat H. Samah<sup>2</sup>

1 Surgery, Taif University, Taif, Saudi Arabia

2 Surgery, AlHada Military Hospital, Taif, Saudi Arabia

## References

- [1] Prognostic impact of anatomical resection for hepatocellular carcinoma Kiyoshi Hasegawa, Norihiro Kokudo, Hiroshi Imamura, Yutaka Matsuyama, Masami Minagawa, Keiji Sano, Yasuhiko Sugawara, Tadatoshi Takayama, Masatoshi Makuuchi. *Ann surg.* (2005). , 242, 252-259.
- [2] Eltawil et al Differentiating the impact of anatomic and non-anatomic liver resection on early recurrence in patients with Hepatocellular Carcinoma. *World journal of surgical oncology* (2010).
- [3] Segment-Oriented approach to liver resection K.H. Liao, L.H. Blumgart, R.P. dematteo. *Surg clin N Am* (2004). , 84(2004), 543-561.
- [4] Ultrasonically guided subsegmentectomy Makuuchi M, Hasegawa H, Yamaxaki S. *Surg Gynecol Obstet.* (1986). , 161, 346-359.
- [5] Segmental liver resection using ultrasound-guided selective portal vein occlusion- Casting D, Garden J, Bismuth H. *Ann Surg.* (1989). , 210, 20-23.
- [6] Segment-Oriented hepatic resection in the management of Malignant neoplasms Billigslley KG Jarnagin WR, Fong Y, Blumgart LH. *of the liver. J Am Coll Surg* (1998). Nov; , 187(5), 471-81.
- [7] Anatomic versus limited nonanatomic Resection for solitary hepatocellular carcinoma Tanaka K, Shimada H, Matsumoto K, Nagano Y, Endo I, Togo S *Surgery* (2008).



- [8] Techniques of Hepatic Resection Howard m. Karpoff, William r. Jarnagin, José melen-  
dez, Yuman fong, Leslie h. Blumgart. Hepatobiliary Cancer.
- [9] Ueno, S, et al. (2008). Efficacy of anatomic resection vs nonanatomic resection for  
small nodular hepatocellular carcinoma based on gross classification. J Hepatobiliary  
Pancreat Surg , 15(5), 493-500.
- [10] Extent of liver resection influences the outcome in patients with cirrhosis and small  
hepatocellular carcinoma Regimbeau JM, Kianmanesh R, Farges O, Dondero F, Sau-  
vanet A, Belghiti J. Surgery (2002). Mar;, 131(3), 311-7.
- [11] Dematteo, R. P, Palese, C, Jarnagin, W. R, et al. Anatomic segmental hepatic resection  
is superior to wedge resection as an oncologic operation for colorectal liver metasta-  
ses. J Gastrointest Surg (2000). , 4, 178-84.
- [12] Imamura, H, Matsuyama, Y, Miyagawa, Y, et al. Prognostic significance of anatomi-  
cal resection and des-\_-carboxy prothrombin in patients with hepatocellular carcino-  
ma. Br J Surg. (1999). , 86, 1032-1038.
- [13] Cucchetti, A, et al. Acomprehensive meta-analysis on outcome of anatomic resection  
versus nonanatomic resection for hepatocellular carcinoma. Annal of Surgical oncol-  
ogy 27 June (2012).
- [14] Segmental liver resection for Colorectal metastasis, Daniel V. Kosov, Georgi L. Kaba-  
kov. Gastrointestin Liver Dis.December (2009). , 18(4)
- [15] Anatomic segmental resection compared to major hepatectomy in the treatment of  
liver neoplasms Thomas S. Helling, Benoit Blondeau. HPB,(2005). , 7, 222-225.
- [16] Postoperative liver dysfunction and future remnant liver: where is the limit? Results  
of a prospective study Ferrero A, Vigano L, Polastri R, et al. World J Surg (2007). , 31,  
1643-1651.
- [17] Expanding criteria for resectability of colorectal liver metastases Pawlik TM, Schulick  
RD, Choti MA. Oncologist (2008). , 13, 51-64.
- [18] Applied anatomy in liver resection and liver transplant W.Y. Lau  
978-7-11712-875-9R-12876
- [19] Healey JE Jr Schriy PC. Anatomy of the biliary ducts within the human liver: analysis  
of the prevailing pattern of branching and the major variations of the biliary ducts.  
Arch Surg (1953). , 66, 599-616.
- [20] Couinaud, C. Lefoie. Etudes Anatomiques et Chirugicales. Paris: Masson & Cie,  
(1957).
- [21] The brisbane (2000). Terminology of Liver Anatomy and Resection Terminology com-  
mittee of the IHPBA, HPB 2000; , 333-9.

- [22] The importance of Glisson's capsule and its sheaths in the intrahepatic approach to resection of the liver Launois B, Jamieson G. *Surg Gynecol Obstet* (1992). , 174, 7-10.
- [23] Kida, H, Uchimura, H, & Okamoto, K. Intrahepatic architecture of bile and portal vein. *J Biliary tract and pancreas* (1987). , 8, 1-7.
- [24] Jamieson, G, & Launois, B. Liver resection and liver transplantation: the anatomy of the liver and associated structures. In :*The anatomy of general surgical operations*. Ed. Jamieson GG, Ilsevier Edinburgh, (2006). Chapter , 2, 8-23.
- [25] Strsberg, S. M. liver terminology and Anatomy. In *Hepatobiliary Carcinoma*. Editor: W.Y. Lau World scintific Singapore (2007). chapter 2, , 25-50.
- [26] The impact of intraoperative ultrasonography on surgery for liver neoplasms Kane R, Hughes L, Qcua E. *J Ultrasound Med* (1994).
- [27] Laparoscopic staging and intraoperative ultrasonography for liver tumor management Ravikumar T. *Surg Oncol Clin North Am* (1996).
- [28] Liver resection by ultrasonic dissection and intraoperative ultrasonography Hanna SS, Nam R, Leonhardt C. *HPB Surg* (1996). , 9, 121-8.
- [29] Intraoperative ultrasonography and other techniques for segmental resections Takayama T, Makuuchi M. *Surg Oncol Clin North Am* (1996). , 5, 261-9.
- [30] The use of operative ultrasound as an aid to liver resection in patients with hepatocellular-carcinoma Makuuchi M, Hasegawa H, Yamazaki S, Takayasu K, Moriyama N. *World J Surg* (1987). , 11, 615-21.
- [31] Operative risks of major hepatic resections Capussotti L, Polastri R. *Hepatogastroenterology* (1998). , 45, 184-90.
- [32] Weber, J. C, Navarra, G, Jiao, L. R, Nicholls, J. P, Jensen, S. L, & Habib, N. A. New technique for liver resection using heat coagulative necrosis. *Ann Surg* (2002).
- [33] Navarra, G, Lorenzini, C, Curro, G, Basaglia, E, & Habib, N. H. Early results after radiofrequency-assisted liver resection. *Tumori* (2004).
- [34] Tepel, J, Klomp, H. J, Habib, N, Fandrich, F, & Kremer, B. Modification of the liver resection technique with radiofrequency coagulation. *Chirurg* (2004).
- [35] Radiomorphology of the Habib Sealer-Induced Resection Plane during Long-Time Followup: A Longitudinal Single Centere Experience after 64 Radiofrequency-Assisted Liver Resections Robert Kleinert, Roger Wahba, Christoph Bangard, Klaus Prenzel, Arnulf H. H°olscher, 1, 2 and Dirk Stippel.
- [36] Radiofrequency ablation-assisted liver resection: review of the literature and our experience Peng Yao & David L. Morris. *HPB*, (2006).

- [37] Methods of vascular control technique during liver resection: a comprehensive review, Wan-Yee Lau, Eric C. H. Lai and Stephanie H. Y. Lau. *Hepatobiliary Pancreat Dis Int*, October 15, (2010). (5)
- [38] Delva, E, Barberousse, J. P, Nordlinger, B, Ollivier, J. M, Vacher, B, Guilmet, C, et al. Hemodynamic and biochemical monitoring during major liver resection with use of hepatic vascular exclusion. *Surgery* (1984).
- [39] Belghiti, J, Noun, R, Zante, E, Ballet, T, & Sauvanet, A. Portal triad clamping or hepatic vascular exclusion for major liver resection. A controlled study. *Ann Surg* (1996). , 224, 155-61.
- [40] Huguet, C, Gavelli, A, Chieco, P. A, Bona, S, Harb, J, Joseph, J. M, et al. Liver ischemia for hepatic resection: where is the limit? *Surgery* (1992). , 111, 251-9.
- [41] Emond, J, Wachs, M. E, Renz, J. F, Kelley, S, Harris, H, Roberts, J. P, et al. Total vascular exclusion for major hepatectomy in patients with abnormal liver parenchyma. *Arch Surg* (1995). discussion 830-1., 130, 824-30.
- [42] A review of techniques for liver resection. AG Heriot, ND Karanjia. *Ann R Coll Surg Engl* 2002; 84: 371-380.
- [43] One hundred consecutive hepatic resections Blood loss, transfusion, and operative technique. Cunningham JD, Fong Y, Shriver C, Melendez J, Marx WL, Blumgart LH. *Arch Surg* (1994). , 129, 1050-6.
- [44] A simplified technique for hepatic resection. Lin T. *Ann Surg* 1974; 180: 225-9.
- [45] Current techniques of liver transaction RONNIE T.P. POON. *HPB*, (2007).
- [46] Cavitron ultrasonic surgical aspirator (CUSA) in liver resection Fasulo F, Giori A, Fissi S, Bozzetti F, Doci R, Gennari L. *Int Surg* (1992). , 77, 64-6.
- [47] Resection of colorectal liver metastases Scheele J, Stang R, Altendorf-Hofmann A, Paul M. *World J Surg* (1995). , 19, 59-71.
- [48] New water-jet dissector: initial experience in hepatic surgery Baer HUMaddern GJ, Blumgart LH. [published erratum appears in *Br J Surg* 1994; 81: 1103]. *Br J Surg* (1991). , 78, 502-3.
- [49] A comparison of different techniques for liver resection: blunt dissection, ultrasonic aspirator and jet-cutter. Rau HG, Schardey FM, Buttler E, Reuter C, Cohnert TU, Schildberg FW. *Eur J Surg Oncol* 1995; 21: 183-7.
- [50] Experience with ultrasound scissors and blades (UltraCision) in open and laparoscopic liver resection Schmidbauer S, Hallfeldt KK, Sitzmann G, Kantelhardt T, Trupka A *Ann Surg* (2002).
- [51] Cherqui, D, Husson, E, Hammoud, R, Malassagne, B, Stephan, F, Bensaid, S, et al. Laparoscopic liver resections: a feasibility study in 30 patients. *Ann Surg* (2000).

- [52] Hepatic resection using the harmonic scalpel Sugo H, Mikami Y, Matsumoto F, Tsumura H, Watanabe Y, Kojima K, et al. Surg Today (2000).
- [53] Perioperative outcomes of major hepatic resections under low central venous pressure anesthesia: blood transfusion and the risk of postoperative renal dysfunction. Melendez JA, Arslan V, Fischer ME, Wuest D, Jarnagin W, Fong Y, et al. J Am Coll Surg (1998). , 187, 620-5.
- [54] Recent advances in hepatic resection DeMatteo RP, Fong YM, Jarnagin WR, Blumgart LH. Semin Surg Oncol (2000). , 19, 200-7.