

We are IntechOpen, the world's leading publisher of Open Access books Built by scientists, for scientists

6,900

Open access books available

186,000

International authors and editors

200M

Downloads

Our authors are among the

154

Countries delivered to

TOP 1%

most cited scientists

12.2%

Contributors from top 500 universities



WEB OF SCIENCE™

Selection of our books indexed in the Book Citation Index
in Web of Science™ Core Collection (BKCI)

Interested in publishing with us?
Contact book.department@intechopen.com

Numbers displayed above are based on latest data collected.
For more information visit www.intechopen.com



Epidermolysis Bullosa Simplex

Ken Natsuga

Additional information is available at the end of the chapter

<http://dx.doi.org/10.5772/54609>

1. Introduction

Epidermolysis bullosa (EB) is a heterogeneous group of congenital disorders characterized by skin blister formation. EB is subdivided into three main subtypes (EB simplex (EBS), junctional EB (JEB) and dystrophic EB (DEB)) and one minor subtype (Kindler syndrome (KS)), according to the level of skin split [1].

The EBS subtype can be defined as EBS with blisters within epidermal basal keratinocytes or above, and it is distinguished from other subtypes whose levels of blister formation are deeper (JEB and DEB) or variable (KS). Mutations in several genes have been identified as being responsible for EBS phenotypes. The clinical manifestations of EBS vary greatly depending on the causative genes. Some EBS subtypes are mild and tend to improve with age, whereas others are severe and often associated with early demise and/or other organ involvement. This chapter introduces the clinical and histological characteristics and classifications of EBS. Subsequently, each protein that is defective in EBS is discussed, as are animal models of the disease.

2. Overview of epidermolysis bullosa simplex

Mutations in genes encoding keratinocyte components involved in the organization of the cytoskeleton or cell-cell junctions are responsible for EBS. EBS can be subclassified into basal and suprabasal according to the level of skin split [1, 2] (**Table 1**).

Basal EBS is caused by defects in skin basement membrane (BMZ) proteins. **Figure 1** diagrams the skin BMZ. Among the BMZ components, keratin 5/14 and plectin are the main targets in EBS [3, 4]. A few EBS cases have been reported to have mutations in *ITGB4* and *COL17*, which encode $\beta 4$ integrin and type XVII collagen, respectively [5, 6]. Recently, BPAG1-e was added to the list of basal EBS target proteins [7, 8].

	Subtype	Target gene (protein)
EBS	Suprabasal EBS	<i>PKP1</i> (plakophilin-1)
		<i>DSP</i> (desmoplakin)
		<i>JUP</i> (plakoglobin)
	Basal EBS	<i>KRT5</i> (keratin 5)
		<i>KRT14</i> (keratin 14)
		<i>PLEC</i> (plectin)
		<i>COL17</i> (type XVII collagen)
		<i>ITGB4</i> ($\beta 4$ integrin)

Table 1. Classification of EBS [1, 2]

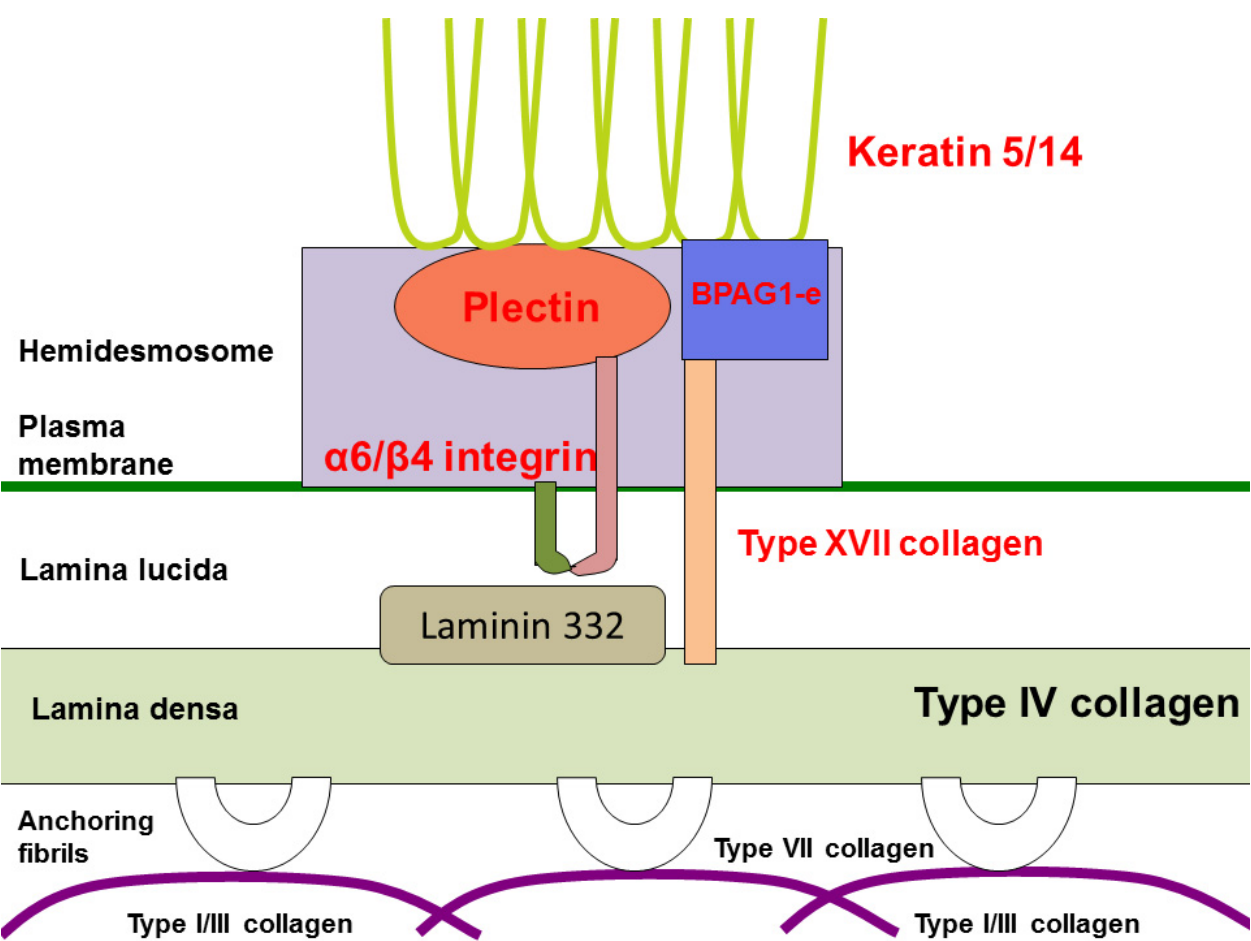


Figure 1. Schematic of the skin basement membrane zone. Components in red characters are target proteins of basal EBS.

In contrast, suprabasal EBS is associated with abnormalities in desmosomal proteins (**Figure 2**). So far, plakophilin-1, plakoglobin and desmoplakin are known to be the target proteins of suprabasal EBS [2, 9-11].

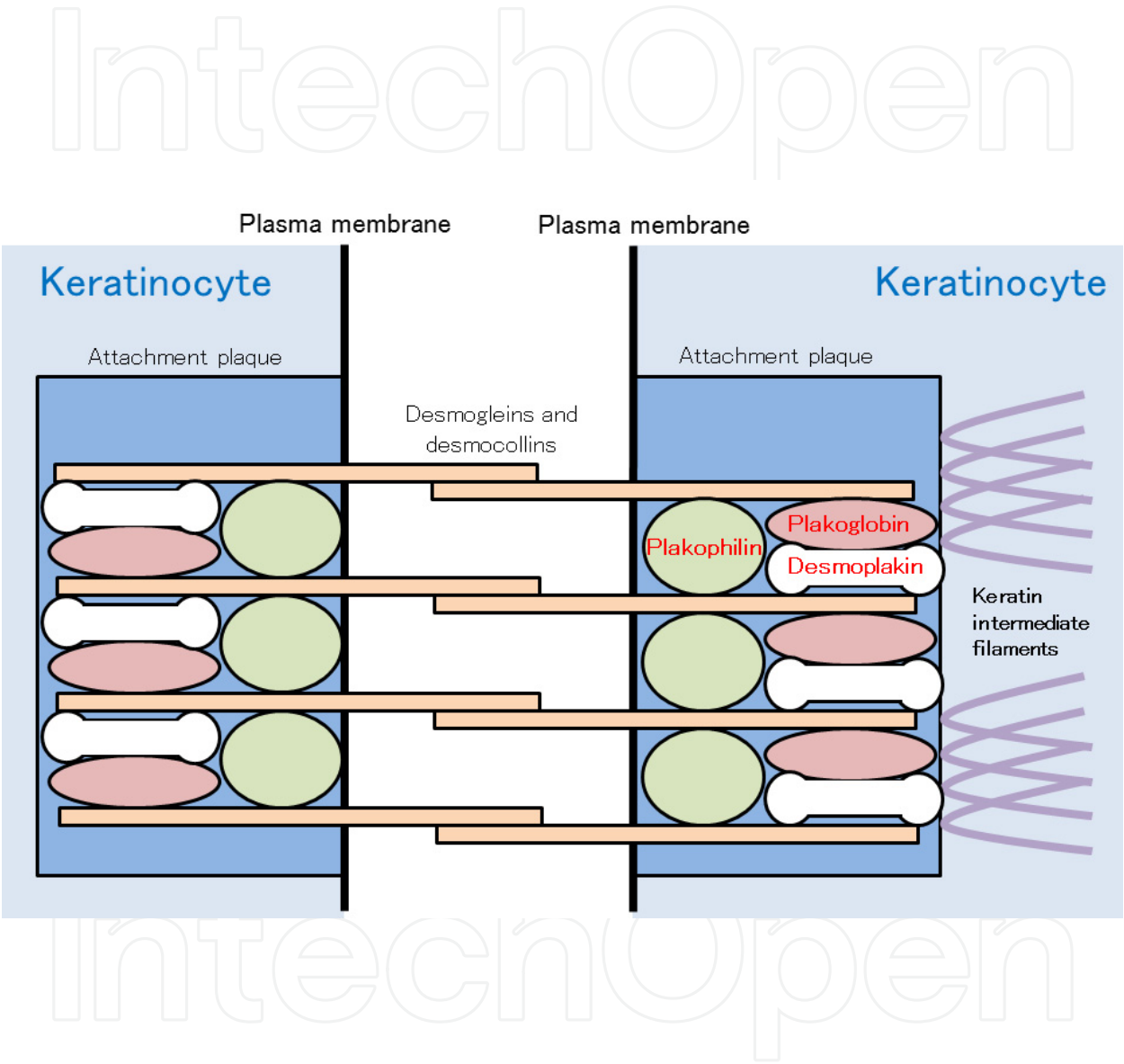


Figure 2. Schematic of desmosomes. Components in red characters are target proteins of suprabasal EBS.

Animal models have been used to clarify the function of some proteins and to develop new therapies for human diseases. Animal models of EB were reviewed recently [12, 13]. However, some new animal models have emerged since then [14, 15], and other transgenic mice with abnormalities in desmosomal proteins should be added to the list of EB animal models because of the introduction of the concept of “suprabasal EBS” [1]. **Table 2** summarizes animal models of EBS.

Causative Gene	Species	Type	Survival	Reference
<i>KRT5</i>	Mouse	KO	Neonatal death	[16]
<i>KRT5</i>	Cow	Naturally occurring (a heterozygous missense mutation)	Not mentioned	[17]
<i>KRT14</i>	Mouse	Tg (expressing truncated protein)	Neonatal death	[18]
<i>KRT14</i>	Mouse	KO	Neonatal death	[19]
<i>KRT14</i>	Mouse	KI	Neonatal death	[20]
<i>KRT14</i>	Mouse	KI (an inducible model)	Not mentioned	[20]
<i>PLEC</i>	Mouse	KO	Neonatal death	[21]
<i>PLEC</i>	Mouse	Conditional KO	Neonatal death	[22]
<i>PLEC</i>	Mouse	KI (expressing EBS-Ogna mutation)	Normal	[14]
<i>DST</i>	Mouse	KO	Not mentioned	[23]
<i>DSP</i>	Mouse	KO	Embryonic death	[24]
<i>DSP</i>	Mouse	Conditional KO	Not mentioned	[25]
<i>PKP1</i>	Dog	Naturally occurring (a homozygous splice donor site mutation)	Neonatal death (6 of 9 affected dogs)	[15]
<i>JUP</i>	Mouse	KO	Embryonic death	[26]
<i>ITGB4</i>	Mouse	KO	Neonatal death	[27]
<i>ITGB4</i>	Mouse	KO	Neonatal death	[28]
<i>ITGB4</i>	Mouse	Partial ablation (expressing ectodomain of $\beta 4$ integrin)	Neonatal death	[29]
<i>ITGB4</i>	Mouse	Conditional KO	Not mentioned	[30]
<i>COL17A1</i>	Mouse	KO	Prolonged survival in 20% of mice	[31]

KO: knockout; Tg: transgenic; KI: knock-in

Table 2. Animal models of EBS [12-15]

3. Target proteins in basal EBS

3.1. Keratin 5/14

Recent brilliant reviews have addressed keratins and EBS [3, 32]. Here we focus on the history, mutation analysis, animal models and future therapeutics of keratin-associated EBS from the physician's point of view.

Keratin is one of the most abundant components of the epithelial cytoskeleton [33]. Typically, type I and type II keratins form heteropolymers that function in cells [34]. Keratin 5 (K5) and keratin 14 (K14) are specifically expressed in epidermal basal cells [34, 35] (**Figure 1**). In the 1980's, disorganization of those keratins was recognized in the basal keratinocytes of EBS patients [36, 37]. From those findings, it had been hypothesized that EBS patients have mutations in *KRT5* or *KRT14*, which encodes K5 or K14, respectively. In the early 1990's, transgenic mice overexpressing mutated K14 were reported to have severe skin fragility [18]. Soon after this discovery, two groups of researchers identified EBS cases with heterozygosity for *KRT14* missense mutations [38, 39], which were followed by the identification of the first EBS family with a heterozygous *KRT5* mutation [40]. Since then, several hundreds of EBS patients have been described as having *KRT5* or *KRT14* mutations and have been summarized in the Human Intermediate Filament Database (<http://www.interfil.org/>) [41].

There are several subtypes of keratin-associated EBS, as described in **Table 3** [1]. Classical and common EBS subtypes, in which traits are autosomal-dominantly inherited, are Dowling-Meara type EBS (EBS-DM), non Dowling-Meara type (EBS-gen-non-DM) and localized type (EBS-loc), from the severest to the mildest. Ultrastructurally, basal keratinocytes of EBS-DM are characterized by keratin aggregates [42]. Hot spots of the mutations in *KRT5* or *KRT14* are located within the helix-boundary motifs of each keratin [41]. A missense mutation in one allele of those regions (which leads to an amino acid alteration) typically exerts a dominant-negative effect on keratin organization. The severity of the clinical manifestations among EBS-DM, EBS-gen-non-DM and EBS-loc is generally determined by the site of the mutations and the difference between the original and the mutated amino acids [32]. However, it is not always easy to predict the phenotype from the underlying mutations and, in some cases, two different amino acid substitutions at the same codon result in different clinical manifestations [43, 44]. As a single amino-acid alteration does not necessarily cause a pathological change, *in vitro* and *in silico* systems to validate mutational effects have been proposed where keratin organization is visualized in cells transfected with mutated or wild-type keratins [44, 45].

The pathogenesis of EBS development through keratin mutations has also been demonstrated in animal models (**Table 2**). Following the discovery of transgenic mice overexpressing mutated K14 described above [18], *Krt5*-null and *Krt14*-null mice were reported to have a skin fragility phenotype [16, 19], although the condition of those mice was different from that of most EBS patients, where altered amino acids yield dominant-negative effects. Instead, those *Krt5*-null and *Krt14*-null mice show the phenotype of

autosomal recessive EBS (EBS-AR) whose K5 or K14 is null [32]. To reproduce dominant-negative effects of mutated keratins in human EBS (EBS-DM, EBS-gen-non-DM and EBS-loc), inducible knock-in EBS model mice were generated, in which a *Krt14* missense mutation equivalent to human EBS mutation was introduced [20]. This inducible EBS model recapitulates the skin fragility seen in human patients with autosomal dominant EBS. Furthermore, there is one naturally occurring bovine with a heterozygous *KRT5* mutation [17]. This Friesian-Jersey crossbred bull exhibits the EBS phenotype.

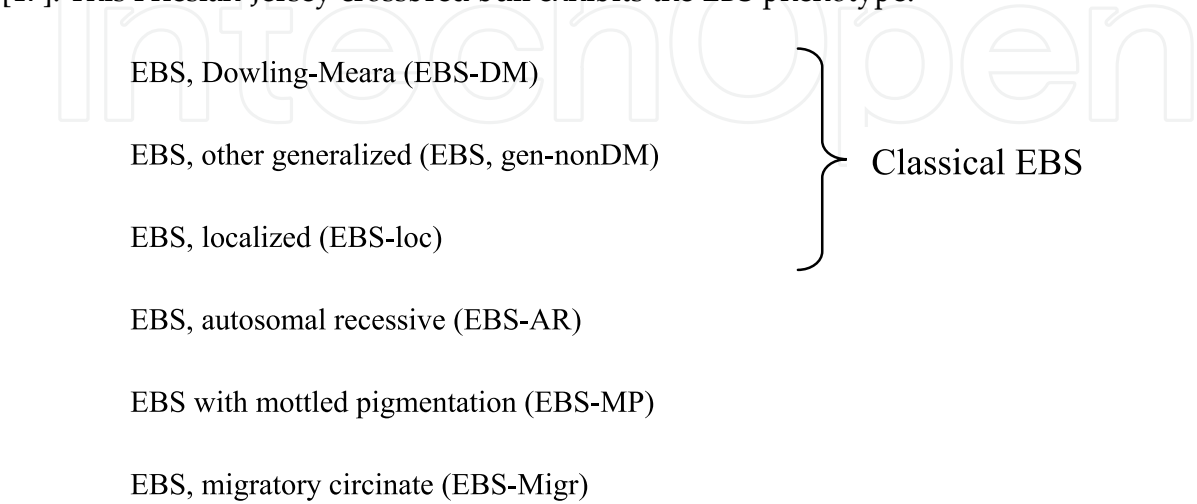


Table 3. Keratin-associated EBS

Therapeutic interventions for EBS have been confined to palliative modalities. However, recent innovations in RNA interference have led to therapeutic strategies for dominant-negative disorders including keratin-associated EBS, where aberrant mutated keratin is knocked down while normal keratin synthesis on another allele is left intact [46]. This RNAi strategy is promising and will be further validated in clinical trials.

3.2. Plectin

A comprehensive review paper has addressed EBS and plectin [4], although there have been several advances in this field since then [14, 47-49].

Plectin is a cross-linking protein between the cytoskeleton and membranous proteins including hemidesmosomal components (**Figure 1**). Plectin has been known to have many transcript isoforms that differ from each other in N-terminal sequences at the protein level [50]. Among the many transcript isoforms, plectin 1a is the one that is mainly expressed in epidermal keratinocytes [51]. In addition to 5' transcript complexity, plectin has a rodless splicing variant [52]. There are several EBS subtypes that are caused by plectin deficiencies (**Table 4**).

In the mid-1990's, mutations in the gene encoding plectin (*PLEC*) were discovered in patients with EBS with muscular dystrophy (EBS-MD) [53, 54]. Since then, many *PLEC* mutations, mostly located in the region encoding the rod domain of plectin, have been reported in EBS-MD patients [4, 47, 55].

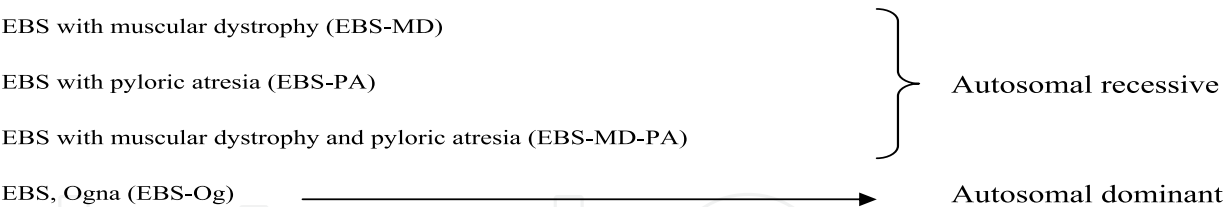


Table 4. Plectin-associated EBS

In 2005, two groups independently reported a new EBS subtype with *PLEC* mutations: EBS with pyloric atresia (EBS-PA) [56, 57]. EB with pyloric atresia (PA) had been known in patients with *ITGA6* or *ITGB4* mutations [58, 59]. However, skin specimens from those patients with integrin mutations show skin-split at the level of the lamina lucida, leading to the diagnosis of junctional EB (JEB). In contrast, EBS-PA cases with *PLEC* mutations were characterized by skin-split within epidermal basal cells [56].

The reason *PLEC* mutations lead to two distinct subtypes of EBS was clarified only recently. The development of monoclonal antibodies against several portions of plectin allowed us to understand the plectin expression patterns that distinguish between EBS-MD and EBS-PA [47]. EBS-MD skin typically shows the expression of rodless plectin without that of full-length plectin, whereas neither rodless nor full-length plectin is present in EBS-PA skin [47].

The next big question was whether EBS-MD and EBS-PA can occur simultaneously in a single patient or those two distinct EBS subtypes are mutually exclusive. Recently, one case was reported to have the phenotype of both EBS-MD and EBS-PA (EBS-MD-PA) [48]. The patient had truncation mutations at the last exon of *PLEC*, which resulted in the expression of diminished and shortened full-length and rodless plectin without the intermediate filament binding domain [48].

Apart from autosomal recessive EBS subtypes associated with *PLEC* mutations (EBS-MD, EBS-MD and EBS-MD-PA), there is one distinct autosomal dominant EBS with a *PLEC* mutation: EBS, Ogna (EBS-Og). EBS-Og is caused by a heterogeneous mutation of p. Arg2000Trp and is characterized by mild blister formation without MD or PA phenotype [4, 60]. To date, 5 unrelated families of EBS-Og have been reported to have the same mutation [49, 60].

Animal models of plectin-deficient EBS have been generated (**Table 2**). *Plec*-null mice show severe blistering phenotype and neonatal death [21], although gastrointestinal tracts were not investigated to confirm PA or PA-like lesions. Myofibril integrity is impaired in the skeletal and heart muscle of those mice [21]. Epidermis-specific ablation of plectin also elicits a severe blistering phenotype and early lethality in mice [22]. Furthermore, mice knocked-in with the murine equivalent mutation of EBS-Og show skin fragility due to epidermal-specific proteolysis of mutated plectin [14].

3.3. BPAG1-e

Dystonin, encoded by *DST*, has various isoforms in neural, muscle and epithelial tissue. BPAG1-e, also called BP230, is a major skin isoform of dystonin and a component of hemidesmosomes (**Figure 1**). BPAG1-e is known to be an autoantigen in bullous pemphigoid as well as type XVII collagen (C17) [61-63]. Since *COL17*, which encodes C17, was identified as a causative gene for non-Herlitz JEB [64], *DST*, which encodes BPAG1-e, had also been hypothesized for decades to be a target gene in other EB subtypes. However, it was only recently that mutations in *DST* were identified in autosomal recessive EBS patients [7, 8]. Those two patients typically had a mild acral blistering phenotype and had truncation mutations in the coiled-coil rod domain of BPAG1-e. Electron microscopy observation revealed loss of the inner plaque of hemidesmosomes in both cases [7, 8]. *Dst*-null mice show neural degeneration and mild skin fragility upon mechanical stress [23] (**Table 2**).

3.4. Miscellaneous

Mutations in *COL17* have been known to be responsible for non-Herlitz JEB (nH-JEB), in which the lamina lucida is the location of the skin-split as described above [64] (**Figure 1**). However, one case was reported to show a phenotype of EBS with *COL17* mutations [5]. The mutations found in that case caused a loss of intracellular C17 [5]. Furthermore, *Col17*-null mice were reported to show a reduced number of hypoplastic hemidesmosomal inner and outer attachment plaques with poor keratin filament attachment [31]. These findings suggest that *COL17* mutations can cause not only nH-JEB but also EBS, depending on the mutational sites.

$\alpha 6/\beta 4$ integrins are hemidesmosomal components that are encoded by *ITGA6/ITGB4*, respectively. (**Figure 1**). Those genes are also target genes in JEB (with or without PA), just as *COL17* is a target gene in nH-JEB. There is one autosomal recessive EBS case where the intracellular portion of $\beta 4$ integrin was deleted [6].

4. Target proteins in suprabasal EBS

4.1. Desmoplakin

Desmoplakin is a plakin family protein located in desmosome [55] (**Figure 2**). Two isoforms (desmoplakins I and II) are generated through alternative splicing [65]. Desmoplakin I is mainly expressed in the heart, whereas desmoplakin II is abundant in the skin [66]. In the early 1990's, desmoplakin was determined as a major autoantigen in paraneoplastic pemphigus [67, 68]. Mutations in the gene encoding desmoplakin, *DSP*, have been reported in several genodermatoses, mostly with cardiac manifestations [11, 69]. In 2005, a very severe EB case, referred to as lethal acantholytic epidermolysis bullosa (LAEB), was reported to have a homozygous deletion mutation in *DSP* [70]. The patient showed severe skin blistering and early demise. There have been only three reports on LAEB with *DSP* mutations [70-72]. Skin specimens in all the cases revealed acantholytic features in histopathology. From the correlation of clinical manifestations and mutational sites, it seems

that complete or almost complete loss of desmoplakin might lead to LAEB [72]. However, at least one full-length desmoplakin (either isoform I or II) may be enough to prevent the development of LAEB [72].

There are two desmoplakin-associated EBS model animals (**Table 2**). The fact that *Dsp* knockout mice show embryonic lethality confirms that desmoplakin is essential in the early development of tissue architecture through embryogenesis [24]. Epidermis-specific ablation of *Dsp* elicits severe skin defects in newborn mice [25].

4.2. Plakophilin-1

Plakophilin-deficient EBS is listed in the newest classification of EB [1]. This entity has also been called ectodermal dysplasia-skin fragility syndrome (ED-SF). An excellent review on this EBS subtype was published recently [10]. The first case of ED-SF and the mutations in the gene encoding plakophilin-1, *PKP1*, were reported in 1997 [73]. Since then, many cases of ED-SF with *PKP1* mutations have been published. The clinical manifestations of ED-SF include skin fragility, perioral cracking, alopecia and palmoplantar keratoderma [10].

The desmosomal expression of plakophilin-1 (**Figure 2**) accounts for skin fragility and histological features of skin specimens characterized by widening of spaces between keratinocytes. However, the phenotype of ectodermal dysplasia may not be explained solely by desmosomal proteins. Recently, plakophilin-1 has been identified as a regulator of protein synthesis and proliferation through a pathway associated with eIF4A1 [74]. It is speculated that the role of plakophilin-1 in translation and proliferation is involved in abnormalities in skin appendages of ED-SF patients [74].

Mice models in which plakophilin-1 is defective have not been reported. However, there is a naturally occurring canine model with *PKP1* mutations that recapitulates human ED-SF [15] (**Table 2**). This family of Chesapeake Bay retriever dogs typically shows skin fragility and some ectodermal dysplasiac manifestations such as hair loss.

4.3. Plakoglobin

JUP, which encodes plakoglobin, was not listed as a causative gene of EB in the report of the Third International Consensus Meeting on Diagnosis and Classification of EB [1]. It was only recently that a homozygous nonsense mutation of this gene, leading to complete loss of plakoglobin, was revealed to be responsible for one subtype of suprabasal EBS [2]. Lethal congenital EB (LCEB), named by the authors, has manifestations similar to those of LAEB, which is caused by *DSP* mutations [2]. This similarity is accounted for by the expression pattern of plakoglobin and desmoplakin in desmosomes (**Figure 2**). This new entity is expected to be included in future classifications of EB [11].

Jup-null mice were reported much earlier than their human equivalents [26] (**Table 2**). Those mice show embryonic death with severe defects in the skin and heart [26].

5. Summary

Many genes are involved in the manifestations of EBS, as described in this chapter. The most common subtype is keratin-associated EBS caused by dominant-negative effects of aberrant mutated protein. RNAi strategies will be used in future clinical trials, although it is not easy to apply such therapies for all patients, because each patient has a different mutation. Tailor-made strategies will be required to correct each EBS mutation.

Other EBS subtypes are generally complicated with organ malfunction. The task of clinicians is to predict the prognosis of each EBS cases based on the causative genes. It is imperative to clarify what organs, other than the skin, will suffer dysfunction in each EBS case.

Author details

Ken Natsuga
Hokkaido University, Japan

6. References

- [1] Fine JD, Eady RA, Bauer EA, Bauer JW, Bruckner-Tuderman L, Heagerty A, Hintner H, Hovnanian A, Jonkman MF, Leigh I, McGrath JA, Mellerio JE, Murrell DF, Shimizu H, Uitto J, Vahlquist A, Woodley D, Zambruno G. The classification of inherited epidermolysis bullosa (EB): Report of the Third International Consensus Meeting on Diagnosis and Classification of EB. *J Am Acad Dermatol*. 2008;58(6):931-950.
- [2] Pigors M, Kiritsi D, Krumpelmann S, Wagner N, He Y, Podda M, Kohlhase J, Hausser I, Bruckner-Tuderman L, Has C. Lack of plakoglobin leads to lethal congenital epidermolysis bullosa: a novel clinico-genetic entity. *Hum Mol Genet*. 2011;20(9):1811-1819.
- [3] Coulombe PA, Kerns ML, Fuchs E. Epidermolysis bullosa simplex: a paradigm for disorders of tissue fragility. *J Clin Invest*. 2009;119(7):1784-1793.
- [4] Rezniczek GA, Walko G, Wiche G. Plectin gene defects lead to various forms of epidermolysis bullosa simplex. *Dermatol Clin*. 2010;28(1):33-41.
- [5] Huber M, Floeth M, Borradori L, Schacke H, Rugg EL, Lane EB, Frenk E, Hohl D, Bruckner-Tuderman L. Deletion of the cytoplasmatic domain of BP180/collagen XVII causes a phenotype with predominant features of epidermolysis bullosa simplex. *J Invest Dermatol*. 2002;118(1):185-192.
- [6] Jonkman MF, Pas HH, Nijenhuis M, Kloosterhuis G, Steege G. Deletion of a cytoplasmic domain of integrin beta4 causes epidermolysis bullosa simplex. *J Invest Dermatol*. 2002;119(6):1275-1281.
- [7] Groves RW, Liu L, Dopping-Hepenstal PJ, Markus HS, Lovell PA, Ozoemena L, Lai-Cheong JE, Gawler J, Owaribe K, Hashimoto T, Mellerio JE, Mee JB, McGrath JA. A homozygous nonsense mutation within the dystonin gene coding for the coiled-coil

- domain of the epithelial isoform of BPAG1 underlies a new subtype of autosomal recessive epidermolysis bullosa simplex. *J Invest Dermatol.* 2010;130(6):1551-1557.
- [8] Liu L, Dopping-Hepenstal PJ, Lovell PA, Michael M, Horn H, Fong K, Lai-Cheong JE, Mellerio JE, Parsons M, McGrath JA. Autosomal recessive epidermolysis bullosa simplex due to loss of BPAG1-e expression. *J Invest Dermatol.* 2012;132(3 Pt 1):742-744.
 - [9] McGrath JA, Bolling MC, Jonkman MF. Lethal acantholytic epidermolysis bullosa. *Dermatol Clin.* 2010;28(1):131-135.
 - [10] McGrath JA, Mellerio JE. Ectodermal dysplasia-skin fragility syndrome. *Dermatol Clin.* 2010;28(1):125-129.
 - [11] Petrof G, Mellerio JE, McGrath JA. Desmosomal genodermatoses. *Br J Dermatol.* 2012;166(1):36-45.
 - [12] Bruckner-Tuderman L, McGrath JA, Robinson EC, Uitto J. Animal models of epidermolysis bullosa: update 2010. *J Invest Dermatol.* 2010;130(6):1485-1488.
 - [13] Natsuga K, Shinkuma S, Nishie W, Shimizu H. Animal models of epidermolysis bullosa. *Dermatol Clin.* 2010;28(1):137-142.
 - [14] Walko G, Vukasinovic N, Gross K, Fischer I, Sibitz S, Fuchs P, Reipert S, Jungwirth U, Berger W, Salzer U, Carugo O, Castanon MJ, Wiche G. Targeted proteolysis of plectin isoform 1a accounts for hemidesmosome dysfunction in mice mimicking the dominant skin blistering disease EBS-Ogna. *PLoS Genet.* 2011;7(12):e1002396.
 - [15] Olivry T, Linder KE, Wang P, Bizikova P, Bernstein JA, Dunston SM, Paps JS, Casal ML. Deficient plakophilin-1 expression due to a mutation in PKP1 causes ectodermal dysplasia-skin fragility syndrome in Chesapeake Bay retriever dogs. *PLoS One.* 2012;7(2):e32072.
 - [16] Peters B, Kirfel J, Bussow H, Vidal M, Magin TM. Complete cytolysis and neonatal lethality in keratin 5 knockout mice reveal its fundamental role in skin integrity and in epidermolysis bullosa simplex. *Mol Biol Cell.* 2001;12(6):1775-1789.
 - [17] Ford CA, Stanfield AM, Spelman RJ, Smits B, Ankersmidt-Udy AE, Cottier K, Holloway H, Walden A, Al-Wahb M, Bohm E, Snell RG, Sutherland GT. A mutation in bovine keratin 5 causing epidermolysis bullosa simplex, transmitted by a mosaic sire. *J Invest Dermatol.* 2005;124(6):1170-1176.
 - [18] Vassar R, Coulombe PA, Degenstein L, Albers K, Fuchs E. Mutant keratin expression in transgenic mice causes marked abnormalities resembling a human genetic skin disease. *Cell.* 1991;64(2):365-380.
 - [19] Lloyd C, Yu QC, Cheng J, Turksen K, Degenstein L, Hutton E, Fuchs E. The basal keratin network of stratified squamous epithelia: defining K15 function in the absence of K14. *J Cell Biol.* 1995;129(5):1329-1344.
 - [20] Cao T, Longley MA, Wang XJ, Roop DR. An inducible mouse model for epidermolysis bullosa simplex: implications for gene therapy. *J Cell Biol.* 2001;152(3):651-656.
 - [21] Andra K, Lassmann H, Bittner R, Shorny S, Fassler R, Propst F, Wiche G. Targeted inactivation of plectin reveals essential function in maintaining the integrity of skin, muscle, and heart cytoarchitecture. *Genes Dev.* 1997;11(23):3143-3156.

- [22] Ackerl R, Walko G, Fuchs P, Fischer I, Schmuth M, Wiche G. Conditional targeting of plectin in prenatal and adult mouse stratified epithelia causes keratinocyte fragility and lesional epidermal barrier defects. *J Cell Sci.* 2007;120(Pt 14):2435-2443.
- [23] Guo L, Degenstein L, Dowling J, Yu QC, Wollmann R, Perman B, Fuchs E. Gene targeting of BPAG1: abnormalities in mechanical strength and cell migration in stratified epithelia and neurologic degeneration. *Cell.* 1995;81(2):233-243.
- [24] Gallicano GI, Kouklis P, Bauer C, Yin M, Vasioukhin V, Degenstein L, Fuchs E. Desmoplakin is required early in development for assembly of desmosomes and cytoskeletal linkage. *J Cell Biol.* 1998;143(7):2009-2022.
- [25] Vasioukhin V, Bowers E, Bauer C, Degenstein L, Fuchs E. Desmoplakin is essential in epidermal sheet formation. *Nat Cell Biol.* 2001;3(12):1076-1085.
- [26] Bierkamp C, McLaughlin KJ, Schwarz H, Huber O, Kemler R. Embryonic heart and skin defects in mice lacking plakoglobin. *Dev Biol.* 1996;180(2):780-785.
- [27] Dowling J, Yu QC, Fuchs E. Beta4 integrin is required for hemidesmosome formation, cell adhesion and cell survival. *J Cell Biol.* 1996;134(2):559-572.
- [28] van der Neut R, Krimpenfort P, Calafat J, Niessen CM, Sonnenberg A. Epithelial detachment due to absence of hemidesmosomes in integrin beta 4 null mice. *Nat Genet.* 1996;13(3):366-369.
- [29] Murgia C, Blaikie P, Kim N, Dans M, Petrie HT, Giancotti FG. Cell cycle and adhesion defects in mice carrying a targeted deletion of the integrin beta4 cytoplasmic domain. *Embo J.* 1998;17(14):3940-3951.
- [30] Raymond K, Kreft M, Janssen H, Calafat J, Sonnenberg A. Keratinocytes display normal proliferation, survival and differentiation in conditional beta4-integrin knockout mice. *J Cell Sci.* 2005;118(Pt 5):1045-1060.
- [31] Nishie W, Sawamura D, Goto M, Ito K, Shibaki A, McMillan JR, Sakai K, Nakamura H, Olsz E, Yancey KB, Akiyama M, Shimizu H. Humanization of autoantigen. *Nat Med.* 2007;13(3):378-383.
- [32] Coulombe PA, Lee CH. Defining keratin protein function in skin epithelia: epidermolysis bullosa simplex and its aftermath. *J Invest Dermatol.* 2012;132(3 Pt 2):763-775.
- [33] Schweizer J, Bowden PE, Coulombe PA, Langbein L, Lane EB, Magin TM, Maltais L, Omary MB, Parry DAD, Rogers MA, Wright MW. New consensus nomenclature for mammalian keratins. *J Cell Biol.* 2006;174(2):169-174.
- [34] Moll R, Franke WW, Schiller DL, Geiger B, Krepler R. The catalog of human cytokeratins: patterns of expression in normal epithelia, tumors and cultured cells. *Cell.* 1982;31(1):11-24.
- [35] Nelson WG, Sun TT. The 50- and 58-kdalton keratin classes as molecular markers for stratified squamous epithelia: cell culture studies. *J Cell Biol.* 1983;97(1):244-251.
- [36] Kitajima Y, Inoue S, Yaoita H. Abnormal organization of keratin intermediate filaments in cultured keratinocytes of epidermolysis bullosa simplex. *Arch Dermatol Res.* 1989;281(1):5-10.

- [37] Anton-Lamprecht I, Schnyder UW. Epidermolysis bullosa herpetiformis Dowling-Meara. Report of a case and pathomorphogenesis. *Dermatologica*. 1982;164(4):221-235.
- [38] Bonifas JM, Rothman AL, Epstein EH, Jr. Epidermolysis bullosa simplex: evidence in two families for keratin gene abnormalities. *Science*. 1991;254(5035):1202-1205.
- [39] Coulombe PA, Hutton ME, Letai A, Hebert A, Paller AS, Fuchs E. Point mutations in human keratin 14 genes of epidermolysis bullosa simplex patients: genetic and functional analyses. *Cell*. 1991;66(6):1301-1311.
- [40] Lane EB, Rugg EL, Navsaria H, Leigh IM, Heagerty AH, Ishida-Yamamoto A, Eady RA. A mutation in the conserved helix termination peptide of keratin 5 in hereditary skin blistering. *Nature*. 1992;356(6366):244-246.
- [41] Szeverenyi I, Cassidy AJ, Chung CW, Lee BT, Common JE, Ogg SC, Chen H, Sim SY, Goh WL, Ng KW, Simpson JA, Chee LL, Eng GH, Li B, Lunny DP, Chuon D, Venkatesh A, Khoo KH, McLean WH, Lim YP, Lane EB. The Human Intermediate Filament Database: comprehensive information on a gene family involved in many human diseases. *Hum Mutat*. 2008;29(3):351-360.
- [42] Ishida-Yamamoto A, McGrath JA, Chapman SJ, Leigh IM, Lane EB, Eady RA. Epidermolysis bullosa simplex (Dowling-Meara type) is a genetic disease characterized by an abnormal keratin-filament network involving keratins K5 and K14. *J Invest Dermatol*. 1991;97(6):959-968.
- [43] Cummins RE, Klingberg S, Wesley J, Rogers M, Zhao Y, Murrell DF. Keratin 14 point mutations at codon 119 of helix 1A resulting in different epidermolysis bullosa simplex phenotypes. *J Invest Dermatol*. 2001;117(5):1103-1107.
- [44] Natsuga K, Nishie W, Smith BJ, Shinkuma S, Smith TA, Parry DA, Oiso N, Kawada A, Yoneda K, Akiyama M, Shimizu H. Consequences of two different amino-acid substitutions at the same codon in KRT14 indicate definitive roles of structural distortion in epidermolysis bullosa simplex pathogenesis. *J Invest Dermatol*. 2011;131(9):1869-1876.
- [45] Sorensen CB, Andresen BS, Jensen UB, Jensen TG, Jensen PK, Gregersen N, Bolund L. Functional testing of keratin 14 mutant proteins associated with the three major subtypes of epidermolysis bullosa simplex. *Exp Dermatol*. 2003;12(4):472-479.
- [46] Atkinson SD, McGilligan VE, Liao H, Szeverenyi I, Smith FJ, Moore CB, McLean WH. Development of allele-specific therapeutic siRNA for keratin 5 mutations in epidermolysis bullosa simplex. *J Invest Dermatol*. 2011;131(10):2079-2086.
- [47] Natsuga K, Nishie W, Akiyama M, Nakamura H, Shinkuma S, McMillan JR, Nagasaki A, Has C, Ouchi T, Ishiko A, Hirako Y, Owaribe K, Sawamura D, Bruckner-Tuderman L, Shimizu H. Plectin expression patterns determine two distinct subtypes of epidermolysis bullosa simplex. *Hum Mutat*. 2010;31(3):308-316.
- [48] Natsuga K, Nishie W, Shinkuma S, Arita K, Nakamura H, Ohyama M, Osaka H, Kambara T, Hirako Y, Shimizu H. Plectin deficiency leads to both muscular dystrophy and pyloric atresia in epidermolysis bullosa simplex. *Hum Mutat*. 2010;31(10):E1687-1698.

- [49] Kiritsi D, Pigors M, Tantcheva-Poor I, Wessel C, Arin MJ, Kohlhase J, Bruckner-Tuderman L, Has C. Epidermolysis Bullosa Simplex Ogna Revisited. *J Invest Dermatol.* 2012.
- [50] Fuchs P, Zorer M, Rezniczek GA, Spazierer D, Oehler S, Castanon MJ, Hauptmann R, Wiche G. Unusual 5' transcript complexity of plectin isoforms: novel tissue-specific exons modulate actin binding activity. *Hum Mol Genet.* 1999;8(13):2461-2472.
- [51] Andra K, Kornacker I, Jorgl A, Zorer M, Spazierer D, Fuchs P, Fischer I, Wiche G. Plectin-isoform-specific rescue of hemidesmosomal defects in plectin (-/-) keratinocytes. *J Invest Dermatol.* 2003;120(2):189-197.
- [52] Elliott CE, Becker B, Oehler S, Castanon MJ, Hauptmann R, Wiche G. Plectin transcript diversity: identification and tissue distribution of variants with distinct first coding exons and rodless isoforms. *Genomics.* 1997;42(1):115-125.
- [53] McLean WH, Pulkkinen L, Smith FJ, Rugg EL, Lane EB, Bullrich F, Burgeson RE, Amano S, Hudson DL, Owaribe K, McGrath JA, McMillan JR, Eady RA, Leigh IM, Christiano AM, Uitto J. Loss of plectin causes epidermolysis bullosa with muscular dystrophy: cDNA cloning and genomic organization. *Genes Dev.* 1996;10(14):1724-1735.
- [54] Smith FJ, Eady RA, Leigh IM, McMillan JR, Rugg EL, Kelsell DP, Bryant SP, Spurr NK, Geddes JF, Kirtschig G, Milana G, de Bono AG, Owaribe K, Wiche G, Pulkkinen L, Uitto J, McLean WH, Lane EB. Plectin deficiency results in muscular dystrophy with epidermolysis bullosa. *Nat Genet.* 1996;13(4):450-457.
- [55] Sonnenberg A, Liem RK. Plakins in development and disease. *Exp Cell Res.* 2007;313(10):2189-2203.
- [56] Nakamura H, Sawamura D, Goto M, Nakamura H, McMillan JR, Park S, Kono S, Hasegawa S, Paku S, Nakamura T, Ogiso Y, Shimizu H. Epidermolysis bullosa simplex associated with pyloric atresia is a novel clinical subtype caused by mutations in the plectin gene (PLEC1). *J Mol Diagn.* 2005;7(1):28-35.
- [57] Pfendner E, Uitto J. Plectin gene mutations can cause epidermolysis bullosa with pyloric atresia. *J Invest Dermatol.* 2005;124(1):111-115.
- [58] Vidal F, Aberdam D, Miquel C, Christiano AM, Pulkkinen L, Uitto J, Ortonne JP, Meneguzzi G. Integrin beta 4 mutations associated with junctional epidermolysis bullosa with pyloric atresia. *Nat Genet.* 1995;10(2):229-234.
- [59] Ruzzi L, Gagnoux-Palacios L, Pinola M, Belli S, Meneguzzi G, D'Alessio M, Zambruno G. A homozygous mutation in the integrin alpha6 gene in junctional epidermolysis bullosa with pyloric atresia. *J Clin Invest.* 1997;99(12):2826-2831.
- [60] Koss-Harnes D, Hoyheim B, Anton-Lamprecht I, Gjesti A, Jorgensen RS, Jahnsen FL, Olaisen B, Wiche G, Gedde-Dahl T, Jr. A site-specific plectin mutation causes dominant epidermolysis bullosa simplex Ogna: two identical de novo mutations. *J Invest Dermatol.* 2002;118(1):87-93.

- [61] Labib RS, Anhalt GJ, Patel HP, Mutasim DF, Diaz LA. Molecular heterogeneity of the bullous pemphigoid antigens as detected by immunoblotting. *J Immunol.* 1986;136(4):1231-1235.
- [62] Sawamura D, Li K, Chu ML, Uitto J. Human bullous pemphigoid antigen (BPAG1). Amino acid sequences deduced from cloned cDNAs predict biologically important peptide segments and protein domains. *J Biol Chem.* 1991;266(27):17784-17790.
- [63] Giudice GJ, Emery DJ, Diaz LA. Cloning and primary structural analysis of the bullous pemphigoid autoantigen BP180. *J Invest Dermatol.* 1992;99(3):243-250.
- [64] McGrath JA, Gatalica B, Christiano AM, Li K, Owaribe K, McMillan JR, Eady RA, Uitto J. Mutations in the 180-kD bullous pemphigoid antigen (BPAG2), a hemidesmosomal transmembrane collagen (COL17A1), in generalized atrophic benign epidermolysis bullosa. *Nat Genet.* 1995;11(1):83-86.
- [65] Green KJ, Goldman RD, Chisholm RL. Isolation of cDNAs encoding desmosomal plaque proteins: evidence that bovine desmoplakins I and II are derived from two mRNAs and a single gene. *Proc Natl Acad Sci U S A.* 1988;85(8):2613-2617.
- [66] Uzumcu A, Norgett EE, Dindar A, Uyguner O, Nisli K, Kayserili H, Sahin SE, Dupont E, Severs NJ, Leigh IM, Yuksel-Apak M, Kelsell DP, Wollnik B. Loss of desmoplakin isoform I causes early onset cardiomyopathy and heart failure in a Naxos-like syndrome. *J Med Genet.* 2006;43(2):e5.
- [67] Anhalt GJ, Kim SC, Stanley JR, Korman NJ, Jabs DA, Kory M, Izumi H, Rattie H, 3rd, Mutasim D, Ariss-Abdo L, et al. Paraneoplastic pemphigus. An autoimmune mucocutaneous disease associated with neoplasia. *N Engl J Med.* 1990;323(25):1729-1735.
- [68] Oursler JR, Labib RS, Ariss-Abdo L, Burke T, O'Keefe EJ, Anhalt GJ. Human autoantibodies against desmoplakins in paraneoplastic pemphigus. *J Clin Invest.* 1992;89(6):1775-1782.
- [69] Bolling MC, Jonkman MF. Skin and heart: une liaison dangereuse. *Exp Dermatol.* 2009;18(8):658-668.
- [70] Jonkman MF, Pasmooij AM, Pasmans SG, van den Berg MP, Ter Horst HJ, Timmer A, Pas HH. Loss of desmoplakin tail causes lethal acantholytic epidermolysis bullosa. *Am J Hum Genet.* 2005;77(4):653-660.
- [71] Bolling MC, Veenstra MJ, Jonkman MF, Diercks GF, Curry CJ, Fisher J, Pas HH, Bruckner AL. Lethal acantholytic epidermolysis bullosa due to a novel homozygous deletion in DSP: expanding the phenotype and implications for desmoplakin function in skin and heart. *Br J Dermatol.* 2010;162(6):1388-1394.
- [72] Hobbs RP, Han SY, van der Zwaag PA, Bolling MC, Jongbloed JD, Jonkman MF, Getsios S, Paller AS, Green KJ. Insights from a desmoplakin mutation identified in lethal acantholytic epidermolysis bullosa. *J Invest Dermatol.* 2010;130(11):2680-2683.
- [73] McGrath JA, McMillan JR, Shemanko CS, Runswick SK, Leigh IM, Lane EB, Garrod DR, Eady RA. Mutations in the plakophilin 1 gene result in ectodermal dysplasia/skin fragility syndrome. *Nat Genet.* 1997;17(2):240-244.

- [74] Wolf A, Krause-Gruszczynska M, Birkenmeier O, Ostareck-Lederer A, Huttelmaier S, Hatzfeld M. Plakophilin 1 stimulates translation by promoting eIF4A1 activity. *J Cell Biol.* 2010;188(4):463-471.

IntechOpen

IntechOpen