

# We are IntechOpen, the world's leading publisher of Open Access books Built by scientists, for scientists

6,900

Open access books available

186,000

International authors and editors

200M

Downloads

Our authors are among the

154

Countries delivered to

TOP 1%

most cited scientists

12.2%

Contributors from top 500 universities



WEB OF SCIENCE™

Selection of our books indexed in the Book Citation Index  
in Web of Science™ Core Collection (BKCI)

Interested in publishing with us?  
Contact [book.department@intechopen.com](mailto:book.department@intechopen.com)

Numbers displayed above are based on latest data collected.  
For more information visit [www.intechopen.com](http://www.intechopen.com)



---

# Surgical Treatment of Neurocysticercosis-Related Epilepsy

---

Alejandro L. Escalaya and Jorge G. Burneo

Additional information is available at the end of the chapter

<http://dx.doi.org/10.5772/54275>

---

## 1. Introduction

Seizures are the most frequent clinical manifestation associated with neurocysticercosis (NCC) [1]. But, not all patients with NCC and seizures will develop epilepsy [2]. Nearly 85% of patients with a single NCC in transitional or degenerative phase have a good seizure outcome following resolution of the lesion, and antiepileptic drugs (AEDs) withdrawal [3]. Patients with residual calcifications and those with both recurrent seizures and multiple cysts before treatment with albendazole have the highest rate of relapse after complete disappearance of the cysts and withdrawal of AEDs [4]. Cerebral calcifications are a common finding in persons with seizures or epilepsy in endemic populations [5], and perilesional edema is associated with episodic seizure activity in patients with calcified NCC [6]. However, a high rate of negative correlations between the electroclinical localization and the topography of intracranial calcification has been reported [7], and an irritative zone in the temporal lobe is more relevant in determining the severity and frequency of seizures, than the number and location of calcifications [8].

Drug-resistant epilepsy (DRE) is now defined as “failure of two adequate trials, appropriately chosen and tolerated AEDs schedules (whether as monotherapy or in combination) to achieve sustained seizure freedom” [9]. NCC is an uncommon cause of DRE, even in endemic regions [10]. Perilesional gliosis (best visualized on magnetization transfer spin-echo magnetic resonance imaging), may cause seizures that could be difficult to control with antiepileptic drugs (AEDs) in patients with a solitary cysticercal cyst in the brain [11, 12].

Epilepsy surgery is highly effective in selected patients with DRE, has durable benefits, and improves quality of life [13]. The standard presurgical evaluation should encompass careful history and physical examination, interictal electroencephalography (EEG) including sleep, prolonged video EEG monitoring, magnetic resonance imaging (MRI) with specific

sequences, and neuropsychological assessment. In some cases, invasive monitoring with intracranially-placed electrodes is needed for the purpose of seizure localization. Epilepsy surgery as a treatment of DRE due to NCC has been uncommonly reported.

## 2. Epilepsy surgery and NCC

Rassi Neto et al. [14], in 1998, reported three cases of patients with DRE associated to calcified neurocysticercotic lesions in the temporal lobe. Two of them had MRI imaging, and one of the studies showed perilesional edema. In all cases, the epileptiform focus was demonstrated by EEG. The patients were submitted to removal of the lesion with use of perioperative electrocorticogram, also rendering possible removal of the irritative perilesional focus. In all the cases, the histologic examination showed NCC. However, the authors did not report complete histological description. Out-patient follow-up was approximately 30 months. Two patients were seizure-free and one patient presented an improvement of 95% in seizure frequency.

Chung et al. [15], in 1998, reported a 47-year-old man with intractable temporal lobe epilepsy. Computed tomography (CT) and MRI imaging showed a calcification in the region of the left medial temporal lobe, and atrophy of the hippocampal head portion. Interictal EEG and prolonged video-EEG monitoring were compatible with left temporal lobe epilepsy. The patient underwent standard left temporal lobectomy. Histologic examination revealed degenerated cysticercus and scolex, with the surrounded hippocampus showing a fascia dentata with neuronal loss and gliosis. He was seizure-free for two years after the first postoperative day.

Ooi et al. [16], in 2011, presented a 23-year-old male with recurrent focal seizures despite continued treatment with AED. CT and MRI imaging showed a calcified lesion with surrounding edema in the right frontal lobe that waxed and waned over time. After extensive presurgical evaluation, including mapping of the seizure focus to the right frontal lobe, the lesion was excised. The histological description was available. The capsule, around a degenerated cysticercus, contained marked mononuclear infiltrates that extended to adjacent brain, which showed marked astrocytosis, microgliosis, and inflammatory perivascular infiltrates. The patient was seizure-free for a period of 2 years while on AEDs until he presented again with seizures associated with perilesional edema around the one cyst in the left frontal lobe that had evolved into a calcified granuloma.

Based on these cases published in the literature, it appears important to presurgically identify the presence of perilesional gliosis (around the cysticercotic lesion), as this appeared to be an important predictor of seizure freedom following surgery. This would indicate the important role of gliosis in the generation of seizures, which are particularly difficult to treat in this group of patients. The technique of magnetization transfer spin-echo magnetic resonance imaging is useful for this purpose, as well as the use of electrocorticography when possible, which would allow delineating the epileptogenic tissue.

### 3. Epilepsy surgery in NCC and coexistence of other lesions

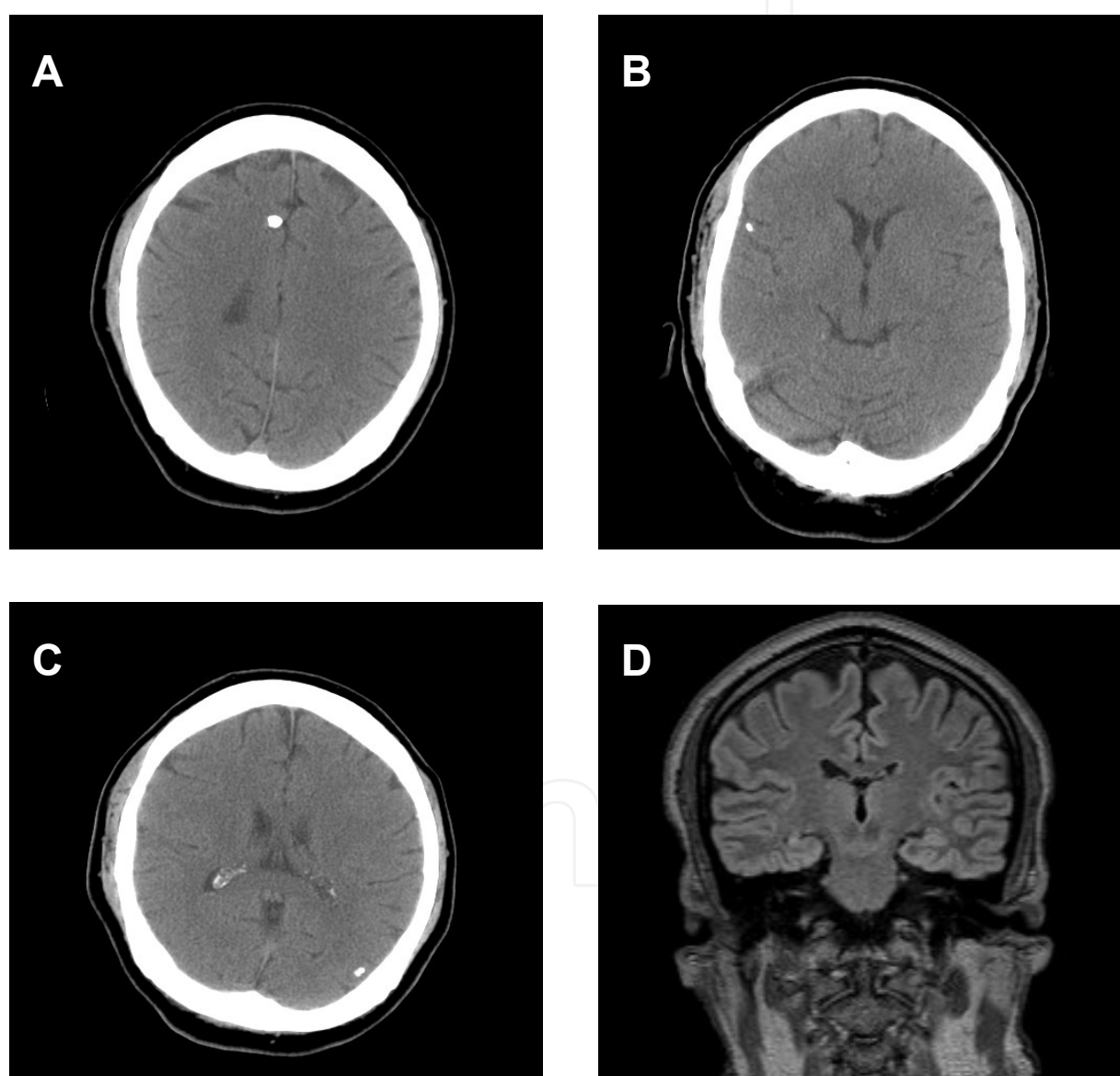
The association of NCC with hippocampal sclerosis (HS) has been reported in developing countries [17, 18]. In a cross-sectional study of 512 patients with DRE, 54.8% of them had HS, and 37% of them presented with HS plus NCC [19]. The mechanism of this association is not clarified. First, NCC might work as an initial precipitating injury leading to HS [20]. Second, the occurrence of NCC lesions in association with HS, or *vice versa*, may be merely coincidental [21]. Finally, both diseases might share common predisposing factors [10].

Leite et al. [21], in Brazil, determined the clinical and pathologic findings of 30 patients with HS and compared them with 32 patients with HS and calcified cysticercotic lesions (CCL) from an epilepsy surgery program. Preoperative data localized the focus to the anterior temporal region and patients were referred for a standardized en-bloc resection including 2 to 3 cm of the hippocampus. In three patients, a CCL ipsilateral to the atrophic hippocampus was located within the margins of resection and removed. The mean follow-up was 29.7 months. The percentage of patients with very good seizure control was similar in both groups. 81.2% patients in the HS + CCL group and 76.6% in the HS group had seizure-free outcome ( $p = 0.90$ ). No differences were found between the 2 groups in regards to age at seizure onset, hippocampal cell densities, or fascia dentata neo-Timm's staining patterns. Accordingly, their findings indicate that there is no need for removal of CCL in order to achieve good postsurgical seizure control in this set of patients.

Chandra et al. [22], in India, presented a series of 28 DRE cases resulting from post-infectious etiologies requiring surgery. All patients underwent a complete epilepsy presurgical evaluation. The criteria used to define infection-related DRE included absence of other potential etiologies preceding the infection as a cause of epilepsy. This was determined by reviewing the clinical history and MRI/CT scans performed at the time of onset of initial infection (the authors did not report if this initial MRI scan was with a special epilepsy protocol). The mean duration of epilepsy prior to surgery was  $8.2 \pm 2.1$  years. Patients were followed after surgery for an average of 14.2 months. The pathologies included NCC in six cases. Four of the five cases with NCC in the temporal lobe, had HS. Histology of one of these cases showed evidence of early HS (not detected earlier on MRI, but with significant spike activity in electrocorticography). Free-seizure outcome was seen in all six cases.

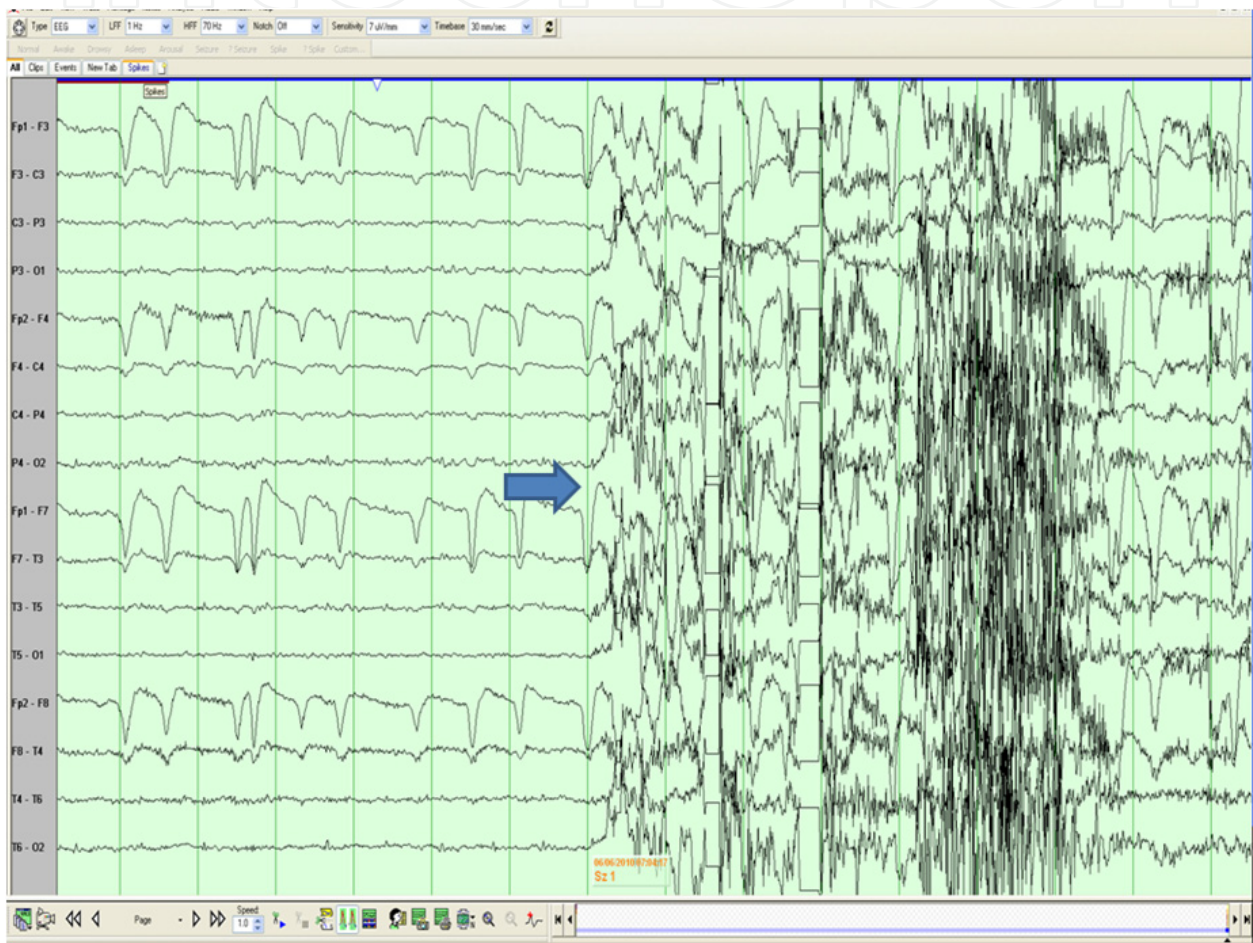
In our center, one patient with DRE NCC-related epilepsy was assessed for possible epilepsy surgery. He was a 39 year-old man who had a previous history of a single, non-febrile, generalized tonic-clonic seizure at age of 5. At age of 13, he began to experience recurrent seizures consisting of fear, followed by loss of awareness associated with unusual movement of the hands. He then would scream, run and have forceful eye deviation to the left. Postictal confusion and aggressiveness were reported. The episodes were lasting from two to five minutes and they would occur one to two times a month. Once a year, those events would be followed by a secondarily generalized tonic-clonic seizure. He had an unclear history of central nervous system infection at the age of two years and some developmental delay. He had been treated with three different AEDs before he was referred

to our epilepsy program. He was a Mexican Mennonite, who immigrated to Canada at the age of 6 years, with frequent travels to his country of origin. The CT scan and the MRI study revealed right HS as well as 3 extratemporal calcified cysticerci (Figure 1). Initial presurgical evaluation indicated possible frontal epilepsy (Figure 2), but subsequent placement of intracranial electrodes identified that seizures arose from the right mesial temporal lobe (Figure 3). He underwent a right temporal lobectomy and has been seizure free for over 2 years.

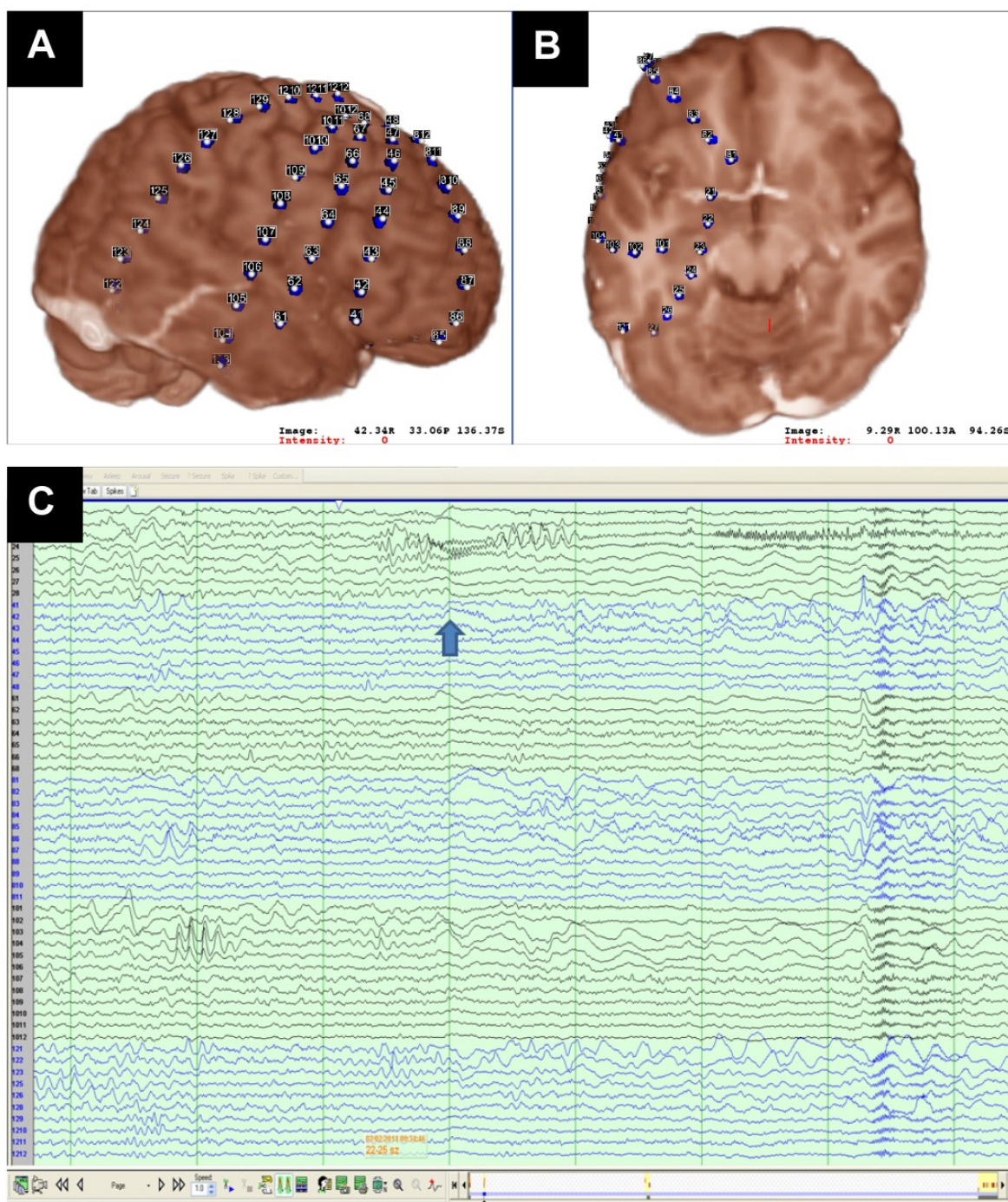


**Figure 1.** Preoperative imaging studies in one patient with drug resistant epilepsy. (A, B and C) Serial CT scan of the patient showing 3 extratemporal calcified cysticerci. (D) MRI fluid-attenuated inversion recovery (FLAIR) reveals a focal high signal intensity lesion in the right mesial temporal region and minimal atrophy of the hippocampus support hippocampal sclerosis.





**Figure 2.** Initial presurgical evaluation in one patient with drug resistant epilepsy with right hippocampal sclerosis and three extratemporal calcified cysticerci. Video electroencephalography monitoring was obscured by movement and muscle artifact (arrow), but the semiology of the seizures captured on video, were concerning for a possible extratemporal lobe focus, despite the initial symptom of fear.



**Figure 3.** Presurgical evaluation in one patient with drug resistant epilepsy with right hippocampal sclerosis and three extratemporal calcified cysticerci. (A and B) Localization of the intracranial electrodes. (C) Invasive recordings show an ictal onset from the mesial right temporal lobe.

#### 4. Conclusions

Epilepsy surgery in NCC is rare but effective. Patient with DRE and NCC should be referred for consideration of epilepsy surgery. The presurgical evaluation is essential and extensive investigations at experienced centers may also be required. NCC itself is not necessarily the



epileptogenic lesion in this set of patients. The association of NCC and HS is rather frequent, further studies are necessary to clarify the mechanisms of this association.

## Author details

Alejandro L Escalaya and Jorge G Burneo\*

*Epilepsy Program, Western University, London, Ontario, Canada*

## 5. References

- [1] Carabin H, Ndimubanzi PC, Budke CM, Nguyen H, Qian Y, Cowan LD, et al. Clinical manifestations associated with neurocysticercosis: a systematic review. *PLoS neglected tropical diseases*. 2011;5(5):e1152.
- [2] Carpio A, Escobar A, Hauser WA. Cysticercosis and epilepsy: A critical review. *Epilepsia*. 1998;39(10):1025-40.
- [3] Rajshekhar V, Jeyaseelan L. Seizure outcome in patients with a solitary cerebral cysticercus granuloma. *Neurology*. 2004;62(12):2236-40.
- [4] Del Brutto OH. Prognostic factors for seizure recurrence after withdrawal of antiepileptic drugs in patients with neurocysticercosis. *Neurology*. 1994;44(9):1706-9.
- [5] Nash TE, Del Brutto OH, Butman JA, Corona T, Delgado-Escueta A, Duron RM, et al. Calcific neurocysticercosis and epileptogenesis. *Neurology*. 2004;62(11):1934-8.
- [6] Nash TE, Pretell EJ, Lescano AG, Bustos JA, Gilman RH, Gonzalez AE, et al. Perilesional brain oedema and seizure activity in patients with calcified neurocysticercosis: a prospective cohort and nested case-control study. *The Lancet Neurology*. 2008;7(12):1099-105.
- [7] Cukiert A, Puglia P, Scapolan HB, Vilela MM, Marino Junior R. Congruence of the topography of intracranial calcifications and epileptic foci. *Arq Neuropsiquiatr*. 1994;52(3):289-94.
- [8] Kowacs PA, Rogacheski E, Muzzio J, Werneck LC. The role of the irritative zone and of the number and distribution of calcifications in the severity of epilepsy associated with intracranial calcifications.[Erratum appears in *Arq Neuropsiquiatr*. 2007 Mar;65(1):182]. *Arq Neuropsiquiatr*. 2006;64(4):905-11.
- [9] Kwan P, Arzimanoglou A, Berg AT, Brodie MJ, Allen Hauser W, Mathern G, et al. Definition of drug resistant epilepsy: Consensus proposal by the ad hoc Task Force of the ILAE Commission on Therapeutic Strategies. *Epilepsia*. 2010;51(6):1069-77.
- [10] Velasco TR, Zanello PA, Dalmagro CL, Araujo D, Jr., Santos AC, Bianchin MM, et al. Calcified cysticercotic lesions and intractable epilepsy: a cross sectional study of 512 patients. *J Neurol Neurosurg Psychiatry*. 2006;77(4):485-8.
- [11] Pradhan S, Kathuria MK, Gupta RK. Perilesional gliosis and seizure outcome: A study based on magnetization transfer magnetic resonance imaging in patients with neurocysticercosis. *Annals of Neurology*. 2000;48(2):181-7.

---

\* Corresponding Author



- [12] de Souza A, Nalini A, Kovoov JME, Yeshraj G, Siddalingaiah HS, Thennarasu K. Perilesional gliosis around solitary cerebral parenchymal cysticerci and long-term seizure outcome: a prospective study using serial magnetization transfer imaging. *Epilepsia*. 2011;52(10):1918-27.
- [13] Wiebe S, Jette N. Epilepsy surgery utilization: who, when, where, and why? *Current Opinion in Neurology*. 2012;25(2):187-93.
- [14] Rassi Neto A, Centeno RS, Ferraz F. Tratamento cirúrgico da epilepsia associada à neurocisticercose. *J bras neurocir*. 1998;9(3):99-102.
- [15] Chung CK, Lee SK, Chi JG. Temporal lobe epilepsy caused by intrahippocampal calcified cysticercus: a case report. *Journal of Korean medical science*. 1998;13(4):445-8.
- [16] Ooi WW, Wijemanne S, Thomas CB, Quezado M, Brown CR, Nash TE. Short report: A calcified *Taenia solium* granuloma associated with recurrent perilesional edema causing refractory seizures: Histopathological features. *American Journal of Tropical Medicine and Hygiene*. 2011;85(3):460-3.
- [17] Bianchin MM, Velasco TR, Takayanagui OM, Sakamoto AC. Neurocysticercosis, mesial temporal lobe epilepsy, and hippocampal sclerosis: An association largely ignored. *Lancet Neurology*. 2006;5(1):20-1.
- [18] Singla M, Singh P, Kaushal S, Bansal R, Singh G. Hippocampal sclerosis in association with neurocysticercosis. *Epileptic Disorders*. 2007;9(3):292-9.
- [19] Bianchin MM, Velasco TR, Wichert-Ana L, Takayanagui OM, Leite JP, Sakamoto AC. How frequent is the association of neurocysticercosis and mesial temporal lobe epilepsy with hippocampal sclerosis? *Epilepsia*. 2010;51(11):2359-60.
- [20] Rathore CT, B. ; Kesavadas, C. ; Radhakrishnan, K. Calcified neurocysticercosis lesions and hippocampal sclerosis: Potential dual pathology? *Epilepsia*. 2012;53(4):e60-e2.
- [21] Leite JP, Terra-Bustamante VC, Fernandes RMF, Santos AC, Chimelli L, Sakamoto AC, et al. Calcified neurocysticercotic lesions and postsurgery seizure control in temporal lobe epilepsy. *Neurology*. 2000;55(10):1485-91.
- [22] Chandra PS, Bal C, Garg A, Gaikwad S, Prasad K, Sharma BS, et al. Surgery for medically intractable epilepsy due to postinfectious etiologies. *Epilepsia*. 2010;51(6):1097-100.