

We are IntechOpen, the world's leading publisher of Open Access books Built by scientists, for scientists

6,900

Open access books available

186,000

International authors and editors

200M

Downloads

Our authors are among the

154

Countries delivered to

TOP 1%

most cited scientists

12.2%

Contributors from top 500 universities



WEB OF SCIENCE™

Selection of our books indexed in the Book Citation Index
in Web of Science™ Core Collection (BKCI)

Interested in publishing with us?
Contact book.department@intechopen.com

Numbers displayed above are based on latest data collected.
For more information visit www.intechopen.com



Spinal Cord Schistosomiasis

André Ricardo Ribas Freitas and
Rodrigo Nogueira Angerami

Additional information is available at the end of the chapter

<http://dx.doi.org/10.5772/53771>

1. Introduction

The human central nervous system (CNS) may be affected by infections of several species in the *Schistosoma* genus that infect men. One of the CNS clinical presentation is the spinal cord schistosomiasis, a potentially severe disease, yet, for a long time, a poorly recognized clinical presentation of Schistosomiasis. However, recently, probably as a consequence significant improvements in diagnostic methods, more attention is being given to this clinical form of Schistosomiasis. This emerging medical and scientific interest about the spinal cord schistosomiasis has allowed a better comprehension of its clinical impact and importance as a previously unrecognized public health problem.

Schistosomiasis is among the parasitic diseases with the highest epidemiological importance in the world. According to the World Health Organization, schistosomiasis occurs in 76 countries and 230 million individuals require treatment annually [1,2]. Of these, about 100 million present some clinical manifestation and 20 million present severe forms of the disease [1-5]. Annually, over 200.000 people die as a consequence of schistosomiasis. In the year 2010, around 33.5 million people were treated. Despite advances in the control of the disease, with lowering of mortality and morbidity, schistosomiasis still represents a challenge to public health and has increased its area of transmission throughout the years [2]. Since it hits the poorer regions of the world, being associated with precarious sanitary and adverse social-economical conditions, this disease has been neglected. With the increase of migratory flow and adventure tourism travels, innumerable schistosomiasis cases have been occurring, even in non-endemic countries [6-13]. Schistosomiasis is a disease caused by trematode worms, belonging to the *Schistosoma* genus. There are many species which affect man in different clinical manifestations, elimination methods, intermediary hosts and geographical distribution. These species

share the same pattern in reproductive cycle, the transmission occurring through eggs, a proportion of which are eliminated through urine (*S. haematobium*) or feces (*S. mansoni*, *S. japonicum* and others). These eggs release larvae (miracidium) that infect freshwater molluscs in which the parasites multiply through asexual reproduction. These molluscs release aquatic larvae (cercariae) that actively penetrate the skin of a new, vertebrate host. These larvae become adults that inhabit inside the veins in the digestive system (*S. mansoni* and *S. japonicum*) and of the urinary system (*S. haematobium*). The geographic distribution of each species is varied and depends on the presence of molluscs capable of serving as hosts (each *Schistosoma* species has different molluscs as hosts). Precarious sanitary conditions also contribute in the definition of locations where schistosomiasis occurs [14]. *Schistosoma mansoni* occurs in 74 countries located in Africa, the Middle East, South America and the Caribbean. Its eggs measure about 60 x 140 µm, with lateral spine and are eliminated in the feces, being a main cause of intestinal, hepatosplenic, cardiopulmonary and cerebral diseases, aside from being the main cause of spinal cord schistosomiasis. *S. haematobium* occurs in Africa and in the Middle East and its eggs measure about 60 x 150 µm, with terminal spine, are eliminated in the urine and on rare occasions in the feces, being the main cause of urinary diseases and spinal cord schistosomiasis. *S. japonicum*, *S. mekongi* and *S. malayensis* occur in Asia (they are also called *S. japonicum*-like); eggs measure about 60 x 100 µm, lack spine and are eliminated in the feces, causing hepatic diseases, cerebral neuroschistosomiasis, although there have been rare reports of cases in which spinal cord schistosomiasis was caused by *S. japonicum*. *S. intercalatum* occurs in Africa. Eggs are eliminated in the feces. It causes mild intestinal disease but not neuroschistosomiasis, being the least important species, clinically. The presence of spines in the eggs of *S. mansoni* and *S. haematobium* might explain why medullar and cerebral neuroschistosomiasis are more common in these species. Spine makes it more difficult for the eggs to travel through the vertebral veins, causing them to be stuck in the lumbar or thoracic spinal cord. *S. japonicum*'s eggs, being smaller and lacking spine, migrate more easily to the brain through these veins, crossing the spinal cord without sticking to it. There are, still, species belonging to the *Schistosomatidae* family (ex: *Trichobilharzia regenti*) that can cause cercarial dermatitis (or *summer's itch*) without, however, reaching adult life in men and, therefore, not having any major clinical importance.

2. Clinical forms of schistosomiasis

2.1. Acute phase

Acute forms are basically cercarial dermatitis or summer's itch, cutaneous lesion secondary to the penetration of the skin by the cercaria, and Katayama's fever (or syndrome), which is also called acute or toxemic schistosomiasis and occurs, in genera, after three to nine weeks of cercariae penetration, when they have already become adult worms and start laying eggs. Toxemia is secondary to hypersensitivity reactions to the parasite, being characteristic to patients who do not reside in endemic areas and that are exposed to contaminated water bod-

ies [15,16]. This form presents with fever, chills, cough, weakness, weight loss, diarrhea, vomiting, urticarial reactions, hepatosplenomegaly and eosinophilia. These manifestations last, in general, a few days but can last months and, in rare cases, be fatal. These patients present big periovular necrotic-exudative granulomas dispersed throughout the intestines, liver and other organs [17], and generally present spontaneous clinical improvement after a few weeks, but treatment associating schistosomicides and corticosteroids reduce the persistence time of symptoms and prevents evolution into the chronic phase.

Species	Regions where it occurs	Main affected organs	Most common neurological forms
<i>S. mansoni</i>	Sub-Saharan Africa, Brazil, Egypt, Middle-East, other regions in Africa and in the Americas	Liver, spleen and intestines	Spinal cord schistosomiasis (mainly) and cerebral schistosomiasis
<i>S. haematobium</i>	Sub-Saharan Africa, Brazil, Egypt, Middle-East, other regions in Africa	Bladder, urethra and ureter	Spinal cord (mainly) and cerebral schistosomiasis
<i>S. japonicum</i> and <i>S. japonicum</i> -like	China, South-East Asia and Pacific islands	Liver, spleen and intestines	Cerebral schistosomiasis (mainly) and spinal cord schistosomiasis

Table 1. Geographic distribution, usually affected organs, and most frequent neurological forms according *Schistosoma* species

2.2. Chronic phase

Schistosomiasis' chronic phase is frequently asymptomatic. Symptoms occur with more frequency in patients who are repeatedly exposed to transmissions focuses and end up developing high worm burden. Chronic forms depend on the involved species. Schistosomiasis mansoni chronic forms are usually classified as: intestinal, hepatointestinal, hepatosplenic and decompensated hepatosplenic. In the intestinal and hepatosplenic forms patients usually do not present significant symptoms, but when present they may include abdominal discomfort, fecal urgency, episodes of diarrhea with eventual mucus or blood. Hepatic lesions are caused by egg embolism secondary to inflammatory reaction, but without significant clinical repercussions. With progression of infection and chronic inflammatory process, these patients may present significant periportal fibrosis, leading to portal hypertension. This phase is called hepatosplenic and the patient may suffer ascites and severe esophageal varices [17]. Schistosomiasis japonica may cause the same kinds of manifestations, although liver function is usually more compromised. In schistosomiasis haematobia, oviposition may cause bladder inflammation, alongside blood in the urine and urinary urgency. Lesions in the urinary tract may cause fibrosis and urinary obstruction, leading to obstructive uropathy and increasing the risk of bladder cancer. These chronic forms depend fundamentally on high worm burdens, therefore they

are diseases that affect mainly inhabitants of endemic areas. For instance, hepatosplenic forms of schistosomiasis *mansoni* are more frequent in areas with high endemicity and very rare in areas of low endemicity. Differently, ectopic forms of schistosomiasis occur as consequence of egg or work accumulation in any organ of the patient and, therefore, is not related to high worm burdens. Thus, it can occur in patients of endemic areas or in patients of non-endemic areas with casual exposure to the focus of transmission.

3. Spinal cord schistosomiasis

The human central nervous system (CNS) may be affected by infections of several species in the *Schistosoma* genus that infect men, excluding *S. intercalatum*. Curiously, other species of Schistosomatidae, such as *Trichobilharzia regenti*, may cause brain or medullar lesions in water birds, but in man causes only swimmer's itch [18-20]. The first human case of neurological lesion caused by *Schistosoma* was described in 1889 by Yamagiwa in the necropsy of a patient with epilepsy that presented cerebral granulomas. It is curious that *S. japonicum* life cycle was described 15 years later, a fact that allowed the *a posteriori* identification of the eggs present in those granulomas [21,22]. In 1905, Shimamura and Tsunoda demonstrated for the first time the presence of *S. japonicum* in the spinal cord of a patient with transverse myelitis. Despite the fact that *S. japonicum* was the first species described as a cause of spinal cord medullar lesion, this species has been the less frequently associated with such lesions in the *Schistosoma* genera. The first case of medullar lesion caused by *S. mansoni* was described in 1930 by Muller and Stender and found in a 26 year old patient who had been to Brazil. In 1948, Faust published a review on the 82 cases of ectopic schistosomiasis described thus far [23]. Among these, there were 56 patients with brain compromising and 8 with medullar lesions in the spinal cord. In that occasion, the author highlighted the importance of this form of disease, given that the number of cases was not inconsiderable and that the consequences were, in general, devastating. "In reports of the cases, it has been customary that most authors address ectopic schistosomiasis as rare or really rare. These designations are no more applicable, despite these syndromes being relatively infrequent" [23]. In the same year, Kane and Most wrote yet another review article on literature concerning neurological lesions caused by *Schistosoma*, including the medullary and brain forms, and called attention to the occurrence of 25 cases of cerebral neuroschistosomiasis japonica among north-American soldiers in the Second World War, between the years of 1944 and 1946 [24]. In this study, 88% (22 cases) of the initial fecal exams of North-American military patients with cerebral neuroschistosomiasis japonica were negative for eggs in the stool samples in the first examination and that 40% (10 cases) remained negative after several serial examinations. All patients had confirmation of *Schistosoma* eggs in pathological anatomy examinations, obtained through CNS biopsy or necropsy. The author, at the time, already said that "Cautious and repeated fecal examinations are important for clinical diagnosis, but specific treatment must not be postponed if there are adequate evidence for presumptive diagnosis, even because all fecal examinations may be negative for eggs even when the patient already shows neurological

symptoms". Despite the fact that the authors were referring to cerebral neuroschistosomiasis japonica, the same advice is valid for spinal cord schistosomiasis today.

Up until the 1980's, medullar lesion caused by *Schistosoma* was, in most published cases, confirmed through fragments of nervous tissue obtained through biopsy or necropsy. In 1985, Scrimgeour and Gedjusek published a scientific literature review of the years between 1930 and 1984 in which they identified 52 cases of spinal cord schistosomiasis mansoni and 12 cases of spinal cord schistosomiasis haematobia, confirmed by pathological anatomy medullar examinations. On the occasion, the authors highlighted the importance of suspecting neuroschistosomiasis in any patient who had been exposed to the risk of infection and presented neurological manifestations [25]. The authors reaffirmed that the patients in general had no previous manifestation of schistosomiasis and that only 22% of *S. mansoni* carriers had eggs found in their feces or rectum biopsy and only 25% of the *S. haematobium* carriers had eggs found in their urine or feces [25]. This difficulty in finding the eggs is not casual, nor an abnormal occurrence. It is part of the disease's laboratory findings pattern [26]. Despite having already done some serological examinations that could have confirmed infection by the parasites even without finding eggs, the diagnosis of spinal cord schistosomiasis was still very complicated and controversial at that time, specially because there were no detailed imaging examinations. Some studies already used presumptive diagnosis criteria, in which the presence of lower thoracic or high lumbar medullar symptoms, the demonstration of exposure to *Schistosoma* through parasitological or immunological methods, and the exclusion of other causes for myelitis were enough for attributing the clinical manifestation to spinal cord schistosomiasis [27]. There were, still, some divergences in the literature regarding the acceptance of the parasitological e/or immunological methods for case confirmation, but the risk of sequelae involved in biopsying the medulla led to the confirmation of the diagnosis through pathological anatomical methods being abandoned [28-31]. In the last decades, spinal cord schistosomiasis diagnosis has been reached through confirmation of *Schistosoma* infection using pararitological or serological methods associated with the exclusion of other causes for myelopathy [32-37].

With the technological improvement in the field of immunological methods and imaging examinations, including the introduction of Computerized Tomography (CT) and, mainly, Magnetic Resonance Imaging (MRI), differential diagnosis with other causes of myelopathy has become easier. This can explain, at least in part, the great amount of articles being published in this area [22,38-44]. With the increase in interest for adventure tourism, a growing number of spinal cord schistosomiasis cases, who live in non-endemic areas and are infected in their leisure time, have been described in the literature. Spinal cord schistosomiasis, which had been considered a rare disease from the beginning of the 20th century to the early 80's, now appeared to have been, in fact, under-recognized. In the last years, it has attracted more and more the interest of researchers and is considered one of the forms of schistosomiasis that must be reevaluated from the point of view of disease burden by Public Health Organizations [45].

There are, in the literature, studies that allow an evaluation on the incidence or prevalence in the population with schistosomiasis or exposed to the risk of schistosomiasis. In biblio-

graphical studies of international literature between 1930 and 1984, 64 patients were identified (12 with *S. haematobium* and 52 with *S. mansoni*) and described in the literature [25]. Another bibliographical study published, which included 12 years worth of publications, identified 280 patients with described in the literature [21]. This sudden increase in the number of publications regarding this disease reiterates the hypotheses that the improvement in diagnostic methods has allowed an increase in the recognition of this disease. Thus, neuroschistosomiasis must now be recognized as a problem to be considered by the developers of public policies.

The proportion of patients who go from schistosomiasis to spinal cord schistosomiasis is unknown. But a study done in Bahia with 212 patients with non-traumatic medullar lesion shows that 9.9% (21 cases) of patients had schistosomotic etiology [30]. In another, similar study performed at the Sarah Kubitschek Hospital, in Brazil, with 231 patients, this etiology corresponded to close to 6% of the patients (13 cases) of non-traumatic medullar lesion seen in 4.5 years [36]. There are several indications that this disease has been under-diagnosed [46-49] in endemic areas because of the difficulty of access to more sophisticated diagnostic methods and, in more developed areas, because of the lack of knowledge on the part of the doctors about this disease [26]. This situation has been changing in the last years, particularly in Brazil, due to the improvement in diagnostic tools and better access to medical attention in the country. This may explain the increase of cases in patients of this country that are reported in the literature.

Knowledge of the epidemiological profile of the patient with spinal cord schistosomiasis can be obtained based on case reports or serial cases [26, 42, 50-52]. Spinal cord schistosomiasis occurs more frequently in male patients, with ages between 15 and 50, having low worm burden, up until then not presenting symptomatic neuroschistosomiasis, presenting intestinal and hepatointestinal forms, living in non-endemic areas (who had an eventual exposure to risk of infection) or in endemic areas.

There are several indications that a greater risk for spinal cord schistosomiasis cases in patients is present for patients with low worm burdens [53-55]. This means that spinal cord schistosomiasis can occur in patients with low risk for severe hepatosplenic forms. They are patients who do not present symptoms relating to the digestive tract, which often may lead the assisting physician not to think of schistosomiasis diagnosis. Other patients, aside from not having digestive symptoms, are not frequently exposed to the risk of transmission, making the diagnosis even harder. Examples of said patient profile are tourists who have been only sporadically exposed in areas of schistosomiasis transmission [27, 56, 57], patients who live in urban areas who, usually, have sporadic contact with transmission focuses [58], residents of areas that are recent focuses of transmission [56], and residents of areas with low prevalence for schistosomiasis [26].

Despite the severity of sequelae and disabilities caused by spinal cord schistosomiasis, this form of schistosomiasis is still not being considered in the development of public policies that aim to control the morbidity of schistosomiasis [1, 45, 58].

4. Physiopathology

Knowledge on spinal cord schistosomiasis physiopathology has greatly improved in the last years, although some blanks still remain. It is known that periovular granulomas play a central role in medullar lesion [54, 55]. Although signs of vasculitis with immune complexes deposits close to the granulomas can be found [59], it is believed that these findings have a secondary role in the lesion. The mass effect produced by the granuloma and the edema that surrounds it may lead to the compression of internal structures to the spinal canal, causing secondary and definitive ischemic lesions. The eggs get to the medulla via the Batson venus plexus through embolization or through anomalous worm migration, in which case they would lay their eggs next to the medulla [54, 55]. This plexus was first described in 1940 by Batson, who intended to explain a mechanism for metastases being dispersed to the CNS [60]. It is a network of valveless veins that connects the inferior vena cava to the veins in the vertebrae. This plexus allows the embolization of eggs without the need for collateral circulation or arteriovenous shunts, seen only in the hepatosplenic and cardiopulmonary forms of schistosomiasis. The eggs of *S. mansoni* and of *S. haematobium* are larger, oval-shaped and have spine (terminal in *S. haematobium* and lateral in *S. mansoni*), which may explain why these species are associated with different neurological manifestations, most of them attributed to lesions in the lower levels segments of spinal cord, and, less frequently, higher manifestations in the spinal cord's medulla [54]. *S. japonicum* eggs are smaller, lack a spine, and are round, allowing them to reach the brain more easily through these anastomoses, causing a smaller proportion of medullar lesions. The probability of these eggs getting to the places where the lesion occurred through ectopic oviposition is reinforced in some situations, in which several eggs are found very close together, or even creating cordons. Aside from that, worm couples were found near these locations in medullar veins. The highest proportion of causes occurring in man can be explained by their greater exposure to focuses of transmission and by differences in pelvic anatomy between both sexes [54].

The greater proportion of spinal cord schistosomiasis cases in patients who present the initial form of schistosomiasis when compared to the ones who present the advanced form appears to have immunological and hemodynamic reasons. Pittella and Lana-Peixoto studied extensively the occurrence of *Schistosoma* eggs in necropsy nervous tissue samples, and found eggs in 26% of the patients who presented hepatosplenic forms and 61,1% of the patients who presented cardiopulmonary forms [53, 61]. Periovular reactions in the CNS are intense in patients presenting medullary forms of neuroschistosomiasis, with periovular necrotic-exudative granulomas that are typically found in the initial stages of the disease (Figures 1 and 2).

Patients with hepatosplenic and cardiopulmonary forms usually present discreet periovular reaction, without granulomatous response or with smaller granulomas, in non-productive stages and located in several regions of the CNS [53-55, 61, 62]. Only 10% of the patients who had eggs in the CNS in the necropsy, and presented these advanced forms also presented neurological symptoms when alive. [53]. One of the suggested mechanisms to explain egg dispersion in cases of patients with hepatosplenic and cardiopulmonary schistosomiasis

is that the eggs would get to the CNS by bypassing through collateral portal-like circulation and intrapulmonary arteriovenous shunting, secondary to hemodynamic alterations common to these advanced forms of schistosomiasis. In these cases there is major egg dispersion through the CNS through anastomoses, but few of these eggs cause symptoms given that the inflammatory response in these patients is usually discreet. In patients presenting schistosomiasis in the intestinal and hepatointestinal forms, the most viable way for the worm couples to reach the CNS is Batson's plexus and, therefore, the most common neurological forms are medullary.

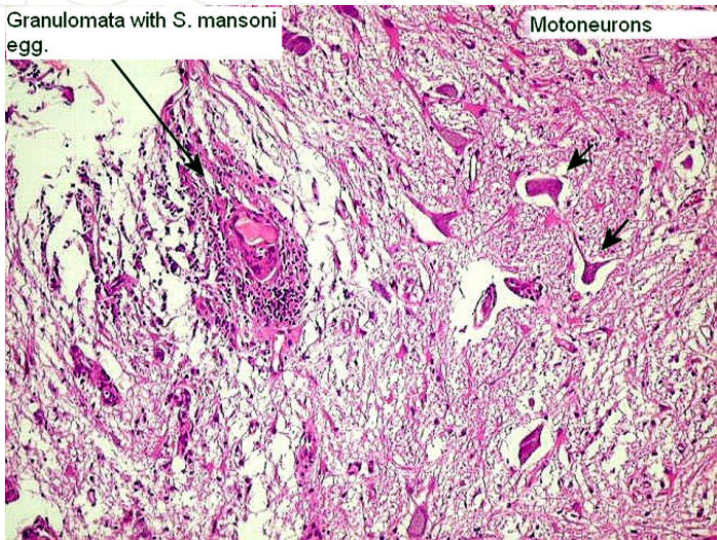


Figure 1. Periovar reaction with granuloma in spinal cord biopsy fragment of a patient with neuroschistosomiasis caused by *Schistosoma mansoni* infection (Optical microscopy, hematoxiline eosine method).

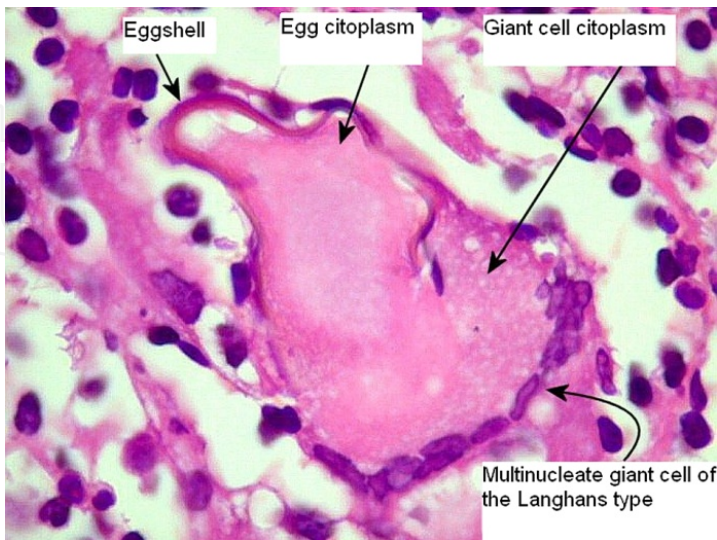


Figure 2. Periovar reaction with granulomatous response in spinal cord biopsy fragment of a patient with neuroschistosomiasis caused by *Schistosoma mansoni* infection (Optical microscopy, hematoxiline eosine method).

5. Schistosomiasis and immune response

During the disease's evolution, immune responses change over time, there being several cytokines that participate with different responses at each moment. Immediately after infection by *Schistosoma*, there is a predominance of T-helper (Th) lymphocytes in action, producing interferon gamma (INF- γ), interleukin (IL)-2, and tumor necrosis factor (TNF)- α . This stage usually lasts an average of 5 to 6 weeks in murine models that corresponds to the acute phase of the disease (Katayama Fever) in humans [63-65]. With the evolution of the disease, this response is substituted by Th2 type and its associated cytokines are IL-4, IL-5, IL-10 and IL-13. At this stage, it is more common for spinal cord schistosomiasis to happen, as shown by the elevated concentration of these cytokines not only in the CSF, but also in the blood and serum from patients with spinal cord schistosomiasis [66]. Concentration of TH1 type cytokines found in patients with spinal cord schistosomiasis was also lower than in patients from the control group. In other words, spinal cord schistosomiasis seems to be more common in patients who present TH2 type of immunological responses, corresponding to the initial chronic phase of the patient with schistosomiasis, right after the acute phase of the disease, but that may last for years. CD4⁺ T-cells (T-helper) play a central role in the formation of the granuloma, so much so that in rats without a thymus there is no formation of granulomas and patients with CD4⁺ T-cell depletion granulomas that may form are, generally, smaller [63-65].

With the evolution of schistosomiasis, TH2 polarized response is attenuated by suppressor T-cells, which modulate immune response, diminishing the production of cytokines, inhibiting the formation of granulomas, and diminishing the size of the granulomas that do form [63-65], a situation which has been observed in patients with hepatosplenic and cardiopulmonary schistosomiasis. This may explain the reason why there are many patients with advanced forms who present multiple eggs in the CNS, without inflammatory reaction around them and that, therefore, do not elicit any symptom [54, 55, 66].

6. Clinical manifestations

The typical clinical manifestations of spinal cord spinal cord schistosomiasis is acute or subacute and presents with lumbar pain with or without radiation to lower limbs, evolving with diminishing of muscular strength in these limbs, with the possibility of presenting, in addition, sensory alterations such as hypoaesthesia, paresthesia and dysesthesia [26]. Clinically, there may be myeloradicular or radicular compromising of the medulla, with lesions in several segments of the medulla. Lesions which are higher in the spinal cord and in a functional section of the medulla may present signs of pyramidal liberation, such as Babinski's or hyperreflexia in the lower limbs. Lower lesions may present themselves as cauda equina syndrome with hypo- or areflexia in the lower limbs and unresponsive plantar-cutaneous reflex. Patients with spinal cord schistosomiasis usually present fecal and urinary retention, or other sphincter alterations, aside from

erectile dysfunction [26]. The amount of time between the beginning of the symptoms and the establishment of the complete manifestation normally ranges from a few days to a couple of weeks [21, 26, 66-68]. In general, these patients do not present systemic symptoms. Some patients may present cephalalgia, vomiting and other signs of meningeal irritation, such as Kernig's, Brudzinski's or nuchal rigidity [67]. When there is radiculopathy, patient may present Lasègue's sign. Spinal cord schistosomiasis' typical triad is diminishing of muscular strength, with sensory alterations in the lower limbs associated with bladder dysfunction, this triad is found in 92,6% of the cases [26].

7. Diagnosis

Spinal cord schistosomiasis' diagnosis is not always simple, but there is a consensus that an adequate diagnosis must include typical clinical manifestation (medullar and/or radicular symptoms), proof of exposure to *Schistosoma* through parasitological or immunological methods, and exclusion of other possible causes of myelopathy [26, 27, 32-37, 67-69].

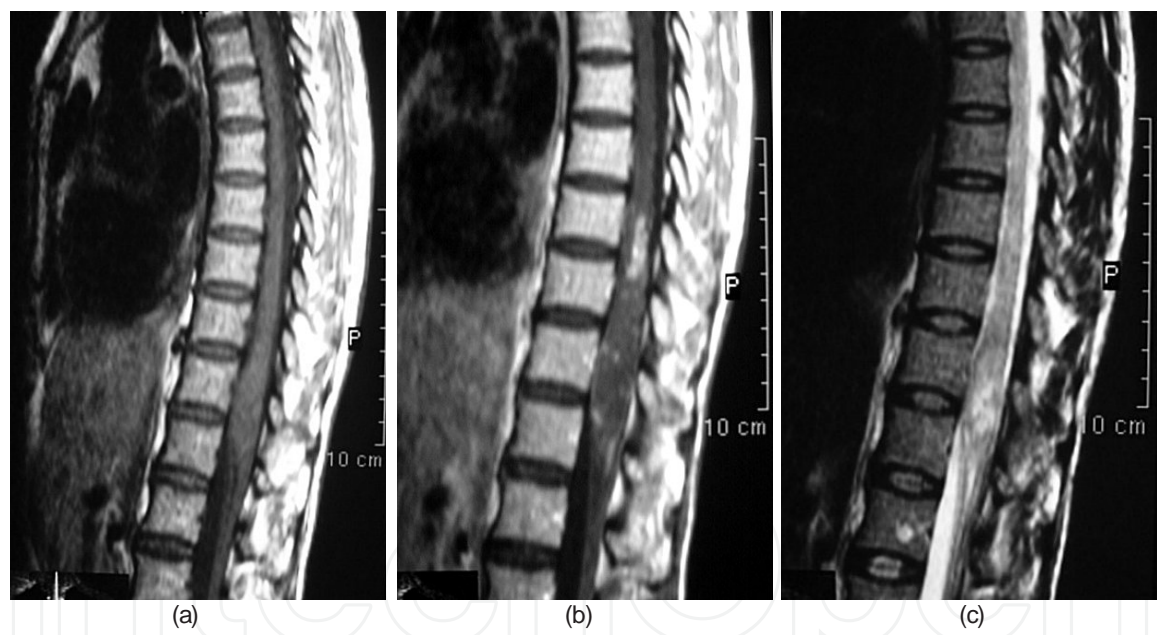


Figure 3. a-c). Sagittal magnetic resonance imaging in T1 phase (Figure 3a), no contrast T2 phase (Figure 3b), and contrast T2 phase (Figure 3c) in a spinal cord schistosomiasis patient.

8. Imaging examinations

MRIs are very important when investigating spinal cord schistosomiasis and may show important data about the location and extension of the lesions. Although it's not an examination that can define completely the etiology, it may collaborate to differential diagnosis by show-

ing inflammatory lesions and ruling out tumorous lesions. The affected area may present with increased volume or just an increase of paramagnetic contrast caption (Figures 3a, 3b, and 3c). The most frequently found aspect is a granulated pattern that may not be exclusive to, but is highly suggestive of, spinal cord schistosomiasis (Figures 4 and 5). A CT picture has a lower sensibility and, in some cases, may show evidence of increased volume or just high contrast caption [30, 38, 39, 41, 43, 44, 50, 68-71].

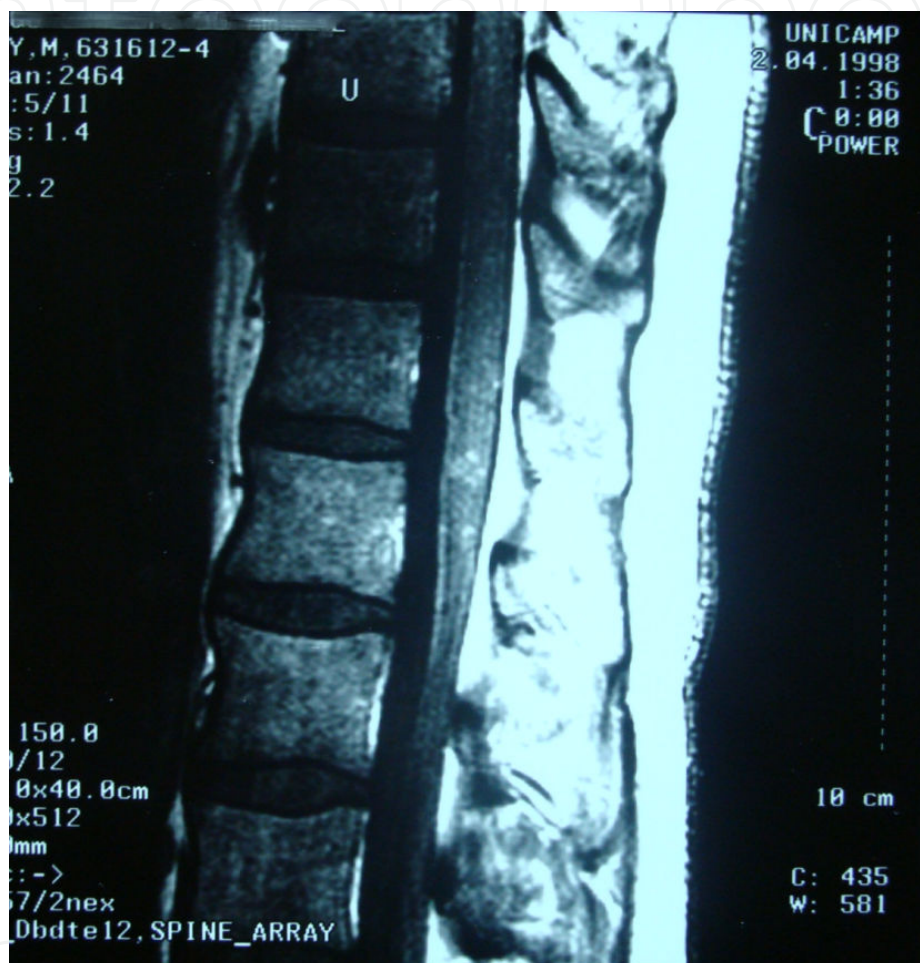

Figure 4. Sagittal magnetic resonance imaging (T2 phase) in a spinal cord schistosomiasis patient. It is observed a granular impregnation of gadolinium magnetic contrast in thoracic-lumbar spinal cord.

9. Laboratory examinations

Nonspecific examinations may suggest the etiology in a clinically suggestive patient. Routine CSF examination may show alterations in a high percentage of the cases, such as increase in proteins in 95% and of leukocytes in 98% of the cases, generally with predominance of lymphocytes and presence of eosinophil granulocytes in 40.8% of the cases

[28]. Despite being highly suggestive of spinal cord schistosomiasis, pelocytoses, high protein concentration and eosinophilia in CSF are not always present [28].

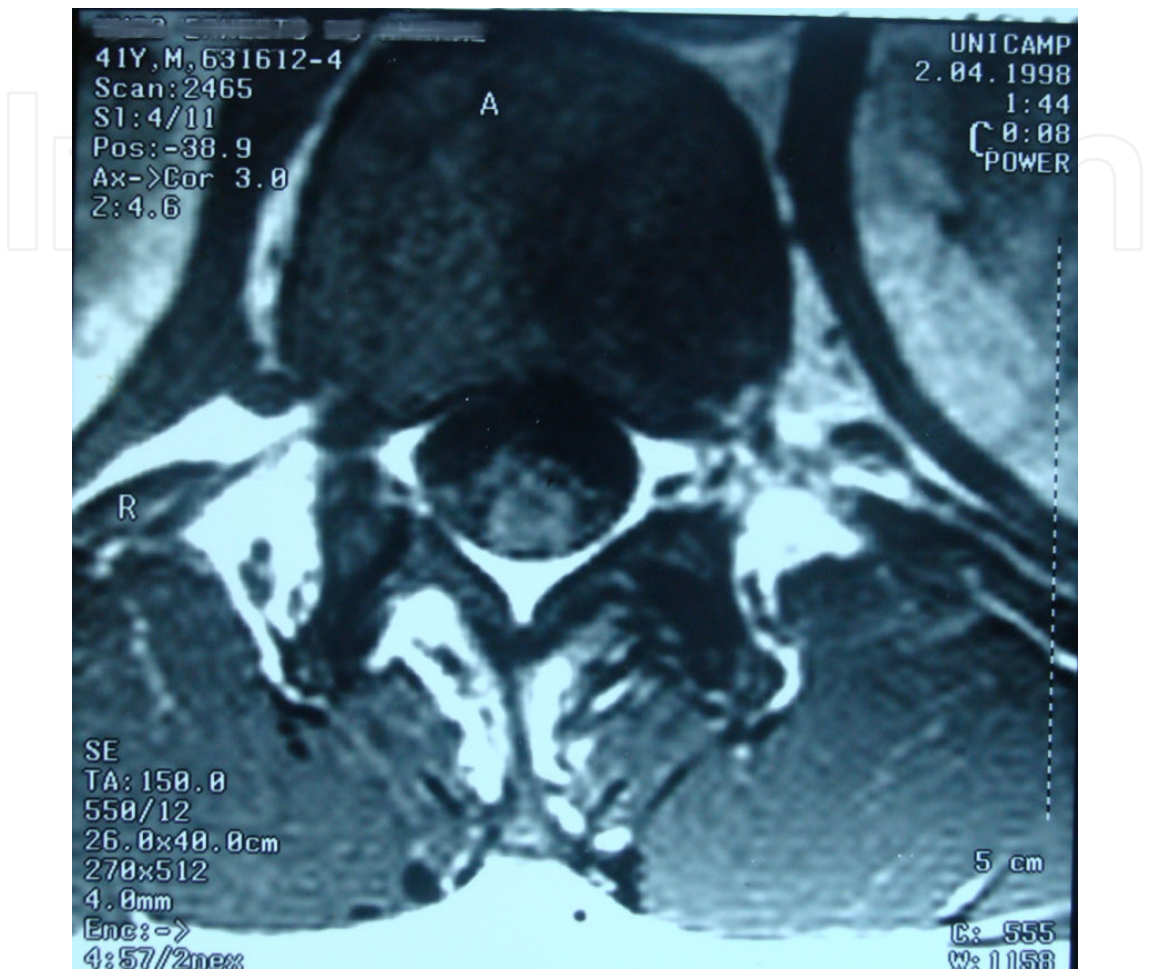


Figure 5. T2 phase axial magnetic resonance imaging in a spinal cord schistosomiasis patient. It is observed a hyper-signal in the thoracic-lumbar spinal cord levels.

Identifying the *Schistosoma* infection through the presence of eggs in the feces (*S. mansoni* and *S. japonicum*) or urine (*S. haematobium*) presents less sensitivity than immunological examinations. In the case of *S. mansoni*, sensitivity varies depending on the methodology and the number of samples being 15.4% [36], 40.0% [26], or 42.5% [42]. Among the several techniques for parasitological examinations, the one which presents the highest sensitivity for *S. mansoni* is Kato-Katz. A study in which 3 to 5 serial fecal samples were collected detected eggs in the feces of 59.4% of the patients [51]. Rectal biopsy, when identifying eggs, shows a positivity ranging from 57.5% [42] to 88,9% [51]. Given that parasitological examinations may be considered to have 100% specificity, any of these tests returning a positive must be considered proof of *Schistosoma* infection, but it may not exclude schistosomiasis when results come back negative.

There are several immunological examination techniques to be used in the serum or CSF. The most used ones try to reveal the presence of antibodies which are specific for soluble egg antigens (SEAs), antigens from the digestive tube of adult worms, or antigens from cercariae. The most used serology techniques are ELISA (Enzyme-linked immunosorbent assay) or indirect immunofluorescence assay. Immunological blood examinations have a sensitivity varying between 80% and 97% and when tested on CSF sensitivity may vary between 56% to 97% [22, 26, 35, 68, 69, 72]. Immunological examinations must be considered as strong evidence of active *Schistosoma* infection, even though many patients who have been cured of the parasites still test positive for a long time and also that there is a chance of cross-reaction with other parasites. Biopsying the medulla is only done, nowadays, in cases when after extensive investigation, the need to rule out tumors is still present [26, 51, 68, 69, 72, 73]. It becomes apparent that no examination may be considered as gold standard for the diagnosis of *Schistosoma* infection and, therefore, analysis of specific examinations must occur alongside analysis of clinical and epidemiological aspects. Also, results from imaging examinations and presence of eosinophil granulocytes in CSF or eosinophilia in peripheral blood must be considered.

A proper investigation must be done to exclude other causes for the medullar and/or radicular lesion, such as bacterial infections (e.g. tuberculosis, syphilis, abscesses), viral infections (e.g. cytomegalovirus, poliovirus, enterovirus, HZV, HSV-1, HSV-2, HIV, HTLV-I) parasitic diseases (e.g. cysticercosis, toxoplasmosis), fungal infections or non-infectious, such as neoplasia, systemic lupus erythematosus, auto-immune vasculitis, diabetic vasculitis, B12 vitamin deficiency, multiple sclerosis, Guillan-Barré Syndrome, among others [26, 51, 68, 69, 72, 73].

10. Treatment

Treatment is done through the use of corticosteroids and schistosomicides. The corticosteroids will diminish the inflammation and lead to regression of the granuloma, being even more important than the schistosomicide. The latter will eliminate the egg production by killing the adult worms and indirectly diminish the production of soluble egg antigens, which are important stimuli for the granulomas. In a few cases, surgical procedures may be necessary to decompress medullar structures. In other cases, treatment is clinical [26, 51, 73]. The schistosomicide may be oxamniquine (15 mg/kg dose for adults and 20 mg/kg for children with up to 5 years of age) or praziquantel (60 mg/kg for children with up to 15 years of age and 50 mg/kg for adults), both in a single dose [73]. The corticosteroid dose is the equivalent to prednisone 1 mg/kg/day, and must be administered for 6 months, with careful suspension, given that patients may present relapses during the process.

In addition, complementary care involves adequate integral approach with psychosocial rehabilitation and motor physical therapy, intermittent bladder checking, prevention of pressure ulcers, among others. Special care must be taken regarding urodynamic aspects [26, 70, 73]. The use of laxatives or enema may be needed for patients with fecal retention.

11. Prognosis

Evolution depends, fundamentally, on early diagnosis and care, better prognosis being associated with an early introduction of the treatment, and particularly the introduction of glucocorticoids [26]. Although symptoms and urological functional alterations do not always respond well to adequate treatment, despite its being started precociously [26, 70, 74, 75]. Patients may recover motor function, sensitivity, sphincter and erectile function control, or they may end up with any combination of absence or recovery of some of the aforementioned functions. Urodynamic alterations have not shown significant improvement in patients who underwent protocol treatment. Ferrari and colleagues (2004) found complete recovery in 31.7% (20) of the patients, 28.3% (18) of the patients presented partial recovery with no functional limitation, 25.4% (16) patients presented partial recovery with functional limitation, and 14.3% (9) of the patients did not improve at all [51]. There were no deaths in this case series. Among the sequelae are paraplegia, paraparesis, dysfunction in the bladder or anal sphincter, sexual dysfunction, definitive sensitivity loss in the affected areas or even paraesthesia and dysesthesia [26, 30, 51]. Detailed studies on the urological aspects, done by Lima (2004) in the Hospital da Restauração in Recife, PE, show that after 9 months of treatment 52 (80%) of 65 patients, showed alterations in urodynamic examinations and 45 (69.2%) showed alterations in voiding cystourethrogram [74].

12. Perspectives

Several factors can actively contribute to the increase in the identification of spinal cord schistosomiasis cases, such as: improvement in diagnostic resources, increase in ecotourism activities with greater exposure of the population to risk of infection, growth of the transmission area, even in urban areas, and lowering of high parasitological loads, without diminishing of the global prevalence of schistosomiasis. There is need of investing in the study of spinal cord schistosomiasis, focusing epidemiological aspects such as: prevalence and incidence, relations between general schistosomiasis incidence and spinal cord schistosomiasis, prevalence and incidence in areas of high and low endemicity, and predisposing factors. Despite how successful controlling the hepatosplenic and cardiopulmonary forms has been throughout the years, control instruments used currently have not shown themselves as sufficient to control the spinal cord schistosomiasis problem. More studies are needed for improving the understanding on the real prevalence of the medullary forms of schistosomiasis. Changes in the Health Surveillance Systems are needed to improve control of schistosomiasis, aiming at a better understanding of the schistosomal morbidity, particularly that of spinal cord schistosomiasis. It is not surprising that schistosomiasis control politics, based on parasitological diagnostic and treatment of the infected, have not been able to reduce the morbidity of the disease due to medullary lesions, since most patients who present this form of schistosomiasis have low worm burdens and present with negative fecal examinations. To reach effective control of spinal cord schistosomiasis, the introduction of more sensitive diagnostic methods and the development of more effective medicines for diagnosis and

treatment of mild forms of schistosomiasis with low worm burdens will be needed in the basic health systems. For an initial diagnosis, the possibility of immediate introduction of serology as a diagnostic instrument in the Basic Health Units. This examination can be used as diagnostic in those patients who are still untreated. But more studies will be necessary for the development of more effective medicines and of more sensitive methods for parasitological removal. It is also important to disclose the occurrence of this form of schistosomiasis, as well as capacitating professionals for attending these patients, particularly in endemic areas and recently formed focus points. A secondary gain of disclosing information on the existence of severe forms may be the population increase in attendance to control measures for this disease.

Differential diagnosis:

- Bacterial infections: tuberculosis, syphilis, abscesses, Lyme's disease.
- Viral infections: cytomegalovirus, poliovirus, enterovirus, HZV, HSV-1, HSV-2, HIV, HTLV, EBV, HBV.
- Other infections: cysticercosis, toxoplasmosis, Chagas disease, fungal infections
- Non-infectious: neoplasia, systemic lupus erythematosus, auto-immune vasculitis, diabetic vasculitis, B12 deficiency, multiple sclerosis, polyradiculopathy, Guillan-Barré Syndrome, spinal disc herniation, syringomyelia

Typical clinical manifestation:

- Lumbar pain with or without radiation to lower limbs
- Paraesthesia or diminishing of lower limb sensitivity
- Paraparesis or paraplegia
- Anal and bladder sphincter dysfunction
- Evolution is generally acute or subacute (between 2 to 60 days)

Presumptive diagnosis:

- Low thoracic or high lumbar medullar symptoms,
- Proof of exposure to *Schistosoma spp* through parasitological or immunological methods and
- Exclusion of other causes for myelitis

Typical epidemiological profile of patients with spinal cord schistosomiasis:

- Ages between 15 and 50
- Predominantly male
- Low worm burden
- Patients thus far do not present symptomatic schistosomiasis or present intestinal and hepatointestinal forms (IS or HIS)
- Patients may reside in endemic areas or non-endemic areas, with eventual exposure to risk of infection

Acknowledgements

A special acknowledgment is dedicated to Luana Hughes Freitas for the discussion of the central ideas, inspiration and encouragement for the production of this document. The authors also acknowledge Nicole Montenegro, Marcela Montenegro Coelho e Bruno Montene-

gro Coelho for their dedication and support for studies in medullary neuroschistosomiasis. Acknowledgment is also due to Professor Luciano de Souza Queiroz, Department of Pathology, FCM-UNICAMP who produced the images of optical microscopy.

Author details

André Ricardo Ribas Freitas¹ and Rodrigo Nogueira Angerami²

1 Municipal Secretary of Health of Campinas and Department of Public Health State, Faculty of Medical Sciences, University of Campinas – UNICAMP, Campinas-SP, Brazil

2 Municipal Secretary of Health of Campinas and Department of Clinical Medicine, Faculty of Medical Sciences, State University of Campinas – UNICAMP, Campinas-SP, Brazil

References

- [1] World Health Organization DoCoTD. Reports of the WHO informal consultation on schistosomiasis control, WHO/CDS/CPC/SIP/99.2. Geneva, WHO, 1998.
- [2] World Health Organization (WHO) <http://www.who.int/mediacentre/factsheets/fs115/en/index.html> (accessed 7 September 2012)
- [3] World Health Organization. The Control of Schistosomiasis. Geneva, 1993.
- [4] World Health Organization. Report of informal consultation on schistosomiasis in low transmission areas: control strategies and criteria for elimination. Geneva, 2001.
- [5] World Health Organization. Prevention and control of schistosomiasis and soil-transmitted helminthiasis. Geneva, 2002.
- [6] Thors C, Holmblad P, Maleki M, Carlson J, Linder E. Schistosomiasis in Swedish travellers to sub-Saharan Africa: Can we rely on serology? *Scand J Infect Dis* 2006; 38(9):794-799.
- [7] Agbessi CA, Bourvis N, Fromentin M, Jaspard M, Teboul F, Bougnoux ME, Hanslik T. Acute schistosomiasis in French travellers. *Rev Med Interne* 2006; 27(8):595-599.
- [8] Grandiere-Perez L, Ansart S, Paris L, Faussart A, Jaureguiberry S, Grivois JP, Klement E, Bricaire F, Danis M, Caumes E. Efficacy of praziquantel during the incubation and invasive phase of *Schistosoma haematobium* schistosomiasis in 18 travelers. *Am J Trop Med Hyg* 2006; 74(5):814-818.
- [9] Ansart S, Perez L, Vergely O, Danis M, Bricaire F, Caumes E. Illnesses in travelers returning from the tropics: a prospective study of 622 patients. *J Travel Med* 2005; 12(6):312-318.

- [10] Greenwald B. Schistosomiasis: implications for world travelers and healthcare providers. *Gastroenterol Nurs* 2005; 28(3):203-205.
- [11] Cantiniaux S, Serratrice J, De Roux-Serratrice C, Disdier P, Perez L, Bricaire F, Caumes E, Mary C, Weiller PJ. A group fever: safari's fever. *Rev Med Interne* 2004; 25(12):931-933.
- [12] Ranque S, Gazin P, Delmont J. Schistosomiasis and tourism in the Dogon country, Mali. *Med Trop (Mars)* 2004; 64(1):31-32.
- [13] Grobusch MP, Muhlberger N, Jelinek T, Bisoffi Z, Corachan M, Harms G, Matteelli A, Fry G, Hatz C, Gjorup I, Schmid ML, Knobloch J, Puente S, Bronner U, Kapaun A, Clerinx J, Nielsen LN, Fleischer K, Beran J, da CS, Schulze M, Myrvang B, Hellgren U. Imported schistosomiasis in Europe: sentinel surveillance data from TropNetEurope. *J Travel Med* 2003; 10(3):164-169.
- [14] Gryseels B, Polman K, Clerinx J, Kestens L. Human schistosomiasis. *Lancet* 2006; 368(9541):1106-1118.
- [15] Lambertucci JR, Sousa-Pereira SR, Silva LC. Myeloradiculopathy in acute schistosomiasis mansoni. *Rev Soc Bras Med Trop* 2005; 38(3):277-278.
- [16] Jesus AR, Silva A, Santana LB, Magalhaes A, de Jesus AA, de Almeida RP, Rego MA, Burattini MN, Pearce EJ, Carvalho EM. Clinical and immunologic evaluation of 31 patients with acute schistosomiasis mansoni. *J Infect Dis* 2002; 185(1):98-105.
- [17] Lambertucci JR, Serufo JC, Gerspacher-Lara R, Rayes AA, Teixeira R, Nobre V, Antunes CM. *Schistosoma mansoni*: assessment of morbidity before and after control. *Acta Trop* 2000; 77(1):101-109.
- [18] Horak P, Dvorak J, Kolarova L, Trefil L. *Trichobilharzia regenti*, a pathogen of the avian and mammalian central nervous systems. *Parasitology* 1999; 119 (Pt 6):577-581.
- [19] Kolarova L, Horak P, Cada F. Histopathology of CNS and nasal infections caused by *Trichobilharzia regenti* in vertebrates. *Parasitol Res* 2001; 87(8):644-650.
- [20] Hradkova K, Horak P. Neurotropic behaviour of *Trichobilharzia regenti* in ducks and mice. *J Helminthol* 2002; 76(2):137-141.
- [21] Ferrari TC. Spinal cord schistosomiasis. A report of 2 cases and review emphasizing clinical aspects. *Medicine (Baltimore)* 1999; 78(3):176-190.
- [22] Silva LC, Maciel PE, Ribas JG, Pereira SR, Serufo JC, Andrade LM, Antunes CM, Lambertucci JR. Mielorradiculopatia esquistossomótica. *Rev Soc Bras Med Trop* 2004; 37(3):261-272.
- [23] Faust EC. An inquiry into the ectopic lesions in schistosomiasis. *Am J Trop Med* 1948; 28:175-199.
- [24] Kane CA, Most H. Schistosomiasis of the central nervous system: experiences in World War II and review of the literature. *Arch Neurol Psychiatry* 1948; 59:141-183.

- [25] Scrimgeour EM, Gajdusek DC. Involvement of the central nervous system in *Schistosoma mansoni* and *S. haematobium* infection. A review. *Brain* 1985; 108 (Pt 4): 1023-1038.
- [26] Freitas ARR, Oliveira ACP, Silva LJ. Schistosomal myeloradiculopathy in a low-prevalence area: 27 cases (14 autochthonous) in Campinas, São Paulo, Brazil. *Mem. Inst. Oswaldo Cruz*. 2010 July; 105(4): 398-408.
- [27] Center of Disease Control. Acute schistosomiasis with transverse myelitis in American students returning from Kenya. *MMWR Morb Mortal Wkly Rep* 1984; 33(31): 445-447.
- [28] Livramento JA, Machado LR, da Silva LC, Spina-Franca A. Cerebrospinal fluid syndrome in neuroschistosomiasis. *Arq Neuropsiquiatr* 1985; 43(4):372-377.
- [29] Haribhai HC, Bhigjee AI, Bill PL, Cosnett JE. *Schistosoma* in the spinal cord. *J Neurol Neurosurg Psychiatry* 1988; 51(1):158.
- [30] Peregrino AJ, de Oliveira SP, Porto CA, Santos LA, de Menezes EE, Silva AP, Brito AL, Pinheiro SP, Pinheiro S, Dias AB. Meningiomielorradiculite por *Schistosoma mansoni*: protocolo de investigação e registro de 21 casos. *Arq Neuropsiquiatr* 1988; 46(1):49-60.
- [31] Bloom K, Freed MM. Paraplegia from schistosomiasis. *Paraplegia* 1990; 28(7):455-459.
- [32] Chen AW, Alam MH, Williamson JM, Brawn LA. An unusually late presentation of neuroschistosomiasis. *J Infect* 2006; 53(3):155-158.
- [33] Camargos ST, Dantas FR, Teixeira AL. Schistosomal myelopathy mimicking spinal cord neoplasm. *Scand J Infect Dis* 2005; 37(5):365-367.
- [34] Kamel MH, Murphy M, Kelleher M, Aquilina K, Lim C, Marks C. Schistosomiasis of the spinal cord presenting as progressive myelopathy. Case report. *J Neurosurg Spine* 2005; 3(1):61-63.
- [35] Tesser E, Reis ML, Borelli P, Matas SL, Reis Filho JB. Líquido cefalorraquidiano no diagnóstico da esquistossomose raquimedular. *Arq Neuropsiquiatr* 2005; 63(3A): 661-665.
- [36] Carod Artal FJ, Vargas AP, Horan TA, Marinho PB, Coelho Costa PH. *Schistosoma mansoni* myelopathy: clinical and pathologic findings. *Neurology* 2004; 63(2): 388-391.
- [37] Carod-Artal FJ, Vargas AP. Myelopathy due to *Schistosoma mansoni*. A description of two cases and review of the literature. *Rev Neurol* 2004; 39(2):137-141.
- [38] Artal FJ, Mesquita HM, Gepp RA, Antunes JS, Kalil RK. Neurological picture. Brain involvement in a *Schistosoma mansoni* myelopathy patient. *J Neurol Neurosurg Psychiatry* 2006; 77(4):512.

- [39] Freitas ARR, Oliveira ACP, Faria AV. Quatro casos de mielopatia esquistossomótica em áreas de baixa prevalência na região de Campinas-SP. *Rev Soc Bras Med Trop* 2002; 35 (suppl 1):217.
- [40] Grand S, Movet E, Le Bas JF. Case report: spinal cord schistosomiasis, MRI findings. *Clin Radiol* 1996; 51(10):739-740.
- [41] Leite CC, Souza AF, Valente M, Araujo MA, Jinkins JR. Clinics in diagnostic imaging (52). Spinal cord schistosomiasis. *Singapore Med J* 2000; 41(8):417-419.
- [42] Peregrino AJ, Puglia PM, Nobrega JP, Livramento JA, Marques-Dias MJ, Scaff M. Esquistossomose medular: análise de 80 casos. *Arq Neuropsiquiatr* 2002; 60(3-A): 603-608.
- [43] Saleem S, Belal AI, el-Ghandour NM. Spinal cord schistosomiasis: MR imaging appearance with surgical and pathologic correlation. *AJNR Am J Neuroradiol* 2005; 26(7):1646-1654.
- [44] Sanelli PC, Lev MH, Gonzalez RG, Schaefer PW. Unique linear and nodular MR enhancement pattern in schistosomiasis of the central nervous system: report of three patients. *AJR Am J Roentgenol* 2001; 177(6):1471-1474.
- [45] Richter J. The impact of chemotherapy on morbidity due to schistosomiasis. *Acta Trop* 2003; 86(2-3):161-183.
- [46] Scrimgeour EM. Non-traumatic paraplegia in northern Tanzania. *Br Med J (Clin Res Ed)* 1981; 283(6297):975-978.
- [47] Joubert J, Fripp PJ, Hay IT, Davel GH, van Graan ES. Schistosomiasis of the spinal cord--underdiagnosed in South Africa? *S Afr Med J* 1990; 77(6):297-299.
- [48] Scrimgeour EM. Schistosomiasis of the spinal cord--underdiagnosed in South Africa. *S Afr Med J* 1991; 79(11):680.
- [49] Naus CW, Chipwete J, Visser LG, Zijlstra EE, van LL. The contribution made by *Schistosoma* infection to non-traumatic disorders of the spinal cord in Malawi. *Ann Trop Med Parasitol* 2003; 97(7):711-721.
- [50] Peregrino AJ, Puglia PM, Bacheschi LA, Hirata MT, Brotto MW, Nobrega JP, Scaff M. Diagnosis of schistosomiasis of the spinal cord: contribution of magnetic resonance imaging and electroneuromyography. *Arq Neuropsiquiatr* 2002; 60(3-A):597-602.
- [51] Ferrari TC, Moreira PR, Cunha AS. Spinal cord schistosomiasis: a prospective study of 63 cases emphasizing clinical and therapeutic aspects. *J Clin Neurosci* 2004; 11(3): 246-253.
- [52] Araújo KCGM, Silva CR, Santos AGA, Barbosa CS, Ferrari TCA. Clinical-epidemiologic profile of the schistosomal myeloradiculopathy in Pernambuco, Brazil. *Mem. Inst. Oswaldo Cruz* [serial on the Internet]. 2010; 105(4): 454-459.

- [53] Gonçalves EC, Fonseca AP, Pittella JE. Frequency of schistosomiasis mansoni of its clinicopathological forms and of the ectopic locations of the parasite in autopsies in Belo Horizonte, Brazil. *J Trop Med Hyg* 1995; 98(5):289-295.
- [54] Pittella JE. Neuroschistosomiasis. *Brain Pathol* 1997; 7(1):649-662.
- [55] Pittella JE. The relation between involvement of the central nervous system in schistosomiasis mansoni and the clinical forms of the parasitosis. A review. *J Trop Med Hyg* 1991; 94(1):15-21.
- [56] Vidal, CHF; Gurgel FV; Ferreira MLB, Azevedo-Filho HRC. Epidemiological aspects in neuroschistosomiasis. *Arq. Neuro-Psiquiatr.* 2010; 68(1): 72-75.
- [57] Junker J, Eckardt L, Husstedt I. Cervical intramedullar schistosomiasis as a rare cause of acute tetraparesis. *Clin Neurol Neurosurg* 2001; 103(1):39-42.
- [58] Drumond S C, Silva LCS, Amaral RS, Sousa-Pereira RS, Antunes CM, Lambertucci JR. Morbidity of schistosomiasis mansoni in the state of Minas Gerais, Brazil. *Mem Inst Oswaldo cruz* 2006; 101(suppl. I):37-40.
- [59] Queiroz LS, Nucci A, Facure NO, Facure JJ. Massive spinal cord necrosis in schistosomiasis. *Arch Neurol* 1979; 36(8):517-519.
- [60] Batson OV. The function of the vertebral veins and their role in the spread of metastases. *Ann of Surgery* 1940; 112(1):138-149.
- [61] Pittella JE, Lana-Peixoto MA. Brain involvement in hepatosplenic schistosomiasis mansoni. *Brain* 1981; 104(3):621-632.
- [62] Pittella JE. Partial hypotrophy of the posterior and lateral columns of the spinal cord, representing a sequela of schistosomiasis mansoni: report of an autopsied case and a review of the literature. *Clin Neuropathol* 1989; 8(6):257-262.
- [63] Pearce EJ, Kane M, Sun J, Taylor J, McKee AS, Cervi L. Th2 response polarization during infection with the helminth parasite *Schistosoma mansoni*. *Immunol Rev* 2004; 201:117-126.
- [64] Stadecker MJ, Asahi H, Finger E, Hernandez HJ, Rutitzky LI, Sun J. The immunobiology of Th1 polarization in high-pathology schistosomiasis. *Immunol Rev* 2004; 201:168-179.
- [65] Wynn TA, Thompson RW, Cheever AW, Mentink-Kane MM. Immunopathogenesis of schistosomiasis. *Immunol Rev* 2004; 201:156-167.
- [66] Ferrari TC, Moreira PR, Sampaio MJ, da Cunha AS, de Oliveira JT, Gazzinelli G, Correa-Oliveira R. Intrathecal cytokines in spinal cord schistosomiasis. *J Neuroimmunol* 2006; 177(1-2):136-141.
- [67] Van LH, Perquin WV. Spinal cord schistosomiasis. *J Neurol Neurosurg Psychiatry* 2000; 69(5):690-691.

- [68] Ferrari TC. Involvement of central nervous system in the schistosomiasis. *Mem Inst Oswaldo Cruz* 2004; 99(5 Suppl 1):59-62.
- [69] Carod Artal, FJ. Cerebral and Spinal Schistosomiasis. *Journal Name: Current Neurology and Neuroscience Reports* Url: <http://dx.doi.org/10.1007/s11910-012-0305-4>. (accessed 7 September 2012)
- [70] Silva LC, Maciel PE, Ribas JG, Souza-Pereira SR, Antunes CM, Lambertucci JR. Treatment of schistosomal myeloradiculopathy with praziquantel and corticosteroids and evaluation by magnetic resonance imaging: a longitudinal study. *Clin Infect Dis* 2004; 39(11):1618-1624.
- [71] Faria AV, Cerqueira EMFP, Reis F, Pirani C, Damasceno BP, Menezes-Neto JR, Zanardi VA. Apresentações da esquistossomose no sistema nervoso central: correlação clínica e radiológica. *Radiol Bras* 2002; 35(1):47-50.
- [72] Ferrari TC, Moreira PR, Oliveira RC, Ferrari ML, Gazzinelli G, Cunha AS. The value of an enzyme-linked immunosorbent assay for the diagnosis of schistosomiasis mansoni myeloradiculopathy. *Trans R Soc Trop Med Hyg* 1995; 89(5):496-500.
- [73] Brasil. Ministério da Saúde. Guia de vigilância epidemiológica e controle da mieloradiculopatia esquistossomótica. Brasília - DF, 2006.
- [74] Lima P. Análise das alterações funcionais vesíco-esfincterianas em pacientes com mielopatia esquistossomótica mansônica antes e após o tratamento medicamentoso da doença. PhD thesis. Universidade Federal de São Paulo - UNIFESP, 2004.
- [75] Gomes CM, Trigo-Rocha F, Arap MA, Gabriel AJ, aor de FJ, Arap S. Schistosomal myelopathy: urologic manifestations and urodynamic findings. *Urology* 2002; 59(2): 195-200.

© 2013 The Author(s). Licensee IntechOpen. This is an open access article distributed under the terms of the [Creative Commons Attribution 3.0 License](https://creativecommons.org/licenses/by/3.0/), which permits unrestricted use, distribution, and reproduction in any medium, provided the original work is properly cited.

IntechOpen

IntechOpen