

# We are IntechOpen, the world's leading publisher of Open Access books Built by scientists, for scientists

6,900

Open access books available

186,000

International authors and editors

200M

Downloads

Our authors are among the

154

Countries delivered to

TOP 1%

most cited scientists

12.2%

Contributors from top 500 universities



WEB OF SCIENCE™

Selection of our books indexed in the Book Citation Index  
in Web of Science™ Core Collection (BKCI)

Interested in publishing with us?  
Contact [book.department@intechopen.com](mailto:book.department@intechopen.com)

Numbers displayed above are based on latest data collected.  
For more information visit [www.intechopen.com](http://www.intechopen.com)



---

# Forensic Issues in the Structural or Functional Neuroimaging of Traumatic Brain Injury

---

Robert P. Granacher, Jr.

Additional information is available at the end of the chapter

<http://dx.doi.org/10.5772/51978>

---

## 1. Introduction

### 1.1. Application area

#### *1.1.1. Forensic differences between examinations by a treating physician and examinations for the purpose of legal testimony*

It is not possible to provide a comprehensive forensic neuropsychiatric assessment of a person following traumatic brain injury (TBI) without also including within the examination, at a minimum, structural brain imaging (e.g., magnetic resonance imaging (MRI), or computed tomography (CT)). Functional brain imaging such as positron emission tomography (PET) or single photon emission computed tomography (SPECT) may be useful in very particular or special circumstances, but they should never be the modality of first choice following TBI. [1-2] Table 1 is a listing of the common structural and functional procedures available to the forensic examiner for a TBI assessment. The need for neuroimaging within a forensic assessment of TBI is based on two principles: (1) The first principle is the pathogenesis of TBI generally results in at least some organic changes to the brain, and (2): in the second principle, the forensic physician has an ethical obligation to provide the soundest opinions possible to the trier-of-fact, judge or jury. In light of the possible organic pathology associated with a TBI, the examination of a head trauma patient is incomplete without examination of the integrity of the brain if the data is to be presented in a court of law. Another very important forensic principle in a legal case of alleged TBI is that a very high percentage of those claiming mild traumatic brain injury (MTBI), may in fact be malingering or symptom magnifying. [4] If malingering of a TBI or symptom magnification of complaints to the physicians is probable, obviously the forensic examiner's opinion will be buttressed by the absence of lesions consistent with TBI on neuroimaging.

Structural Imaging:	<ul style="list-style-type: none"><li>• Computed Tomography (CT)</li><li>• Magnetic Resonance Imaging (MRI)</li></ul>
Functional Imaging :	<ul style="list-style-type: none"><li>• Single Photon Emission Computed Tomography (SPECT)</li><li>• Positron Emission Tomography (PET)</li><li>• Functional Magnetic Resonance Imaging (fMRI)</li><li>• Magnetic Resonance Spectroscopy (MRS)</li></ul>

**Table 1.** Methods for Imaging Traumatic Brain Injury

Physicians of all specialties carry an ethical obligation to assist in the application of the judicial process and to assist the courts in carrying out matters brought to them. Physicians also have an ethical obligation to testify on behalf of their patients if asked to do so, but when testifying as a treating physician, the physician is a fact witness, not an opinion witness. In particular, for forensic neuroimaging of TBI, this means that the physician will testify about the facts of the neuroimaging and how it relates to the physician’s patient including the clinical findings, treatment plan, and outcomes. As a general rule, a physician examining a TBI patient where it is known that the patient is in a legal context, should avoid issues of malingering, ratable disability impairment, whether or not the patient is telling the truth, and other factors that will have special importance in a legal forum. If the treating physician ventures into these areas, it puts at risk the doctor-patient relationship, and this should never be allowed to happen.

On the other hand, the physician who has been asked to examine a patient claiming to have been injured by TBI should never imply to the examinee that a doctor-patient relationship exists. Most persons who have suffered a TBI, and then are forensically examined by neuroimaging, are generally not familiar with the exceptions to the doctor-patient relationship, which exists before the law in most modern countries. Thus, the examinee is placed in a very disadvantageous position. The examinee may incorrectly assume that the neuroimaging is being obtained to provide assistance in the diagnosis or treatment for the brain injury. This is absolutely not the case in a forensic examination; the physician is acting as an agent for the entity or person who hired him/her to perform the neuroimaging. The physician examiner in a forensic case should treat the examinee with compassion and appropriate respect, but there should be no doubt left in the examinee’s mind for whom the physician is employed. In this case, it is obviously not the patient. The examinee should always be advised of this difference within the context of the examination at the outset, and it is suggested that this be done in writing as well as verbally. [5]

**1.2. Rules of scientific evidence in the court room**

As a general rule following TBI, if the person who sustained the injury is being assessed to determine the level of cognitive impairment or rehabilitation outcome, the most likely individuals who will order neuroimaging well after the acute TBI will include: neurologists, rehabilitation medicine specialists, neuropsychiatrists, general psychiatrists, internists, pediatricians, and possibly other medical specialties as well. Physicians possessing these specialties or subspecialties are not expected to master neuroimaging techniques at the level

of radiologists or nuclear medicine physicians. However, a general principle of medical practice is that a physician who orders a laboratory test will have the requisite experience and knowledge to use that laboratory test as part of the assessment of an examinee. In other words, use of neuroimaging within a forensic assessment requires that the physician should have a fundamental understanding of the principles of neuroimaging specific to the particular case, when and when not to order neuroimaging, familiarity with the radiologic anatomy of the brain, and that physician should possess an ability to use neuroimaging data in the overall analysis of an examinee following alleged TBI. Thus, it is recommended that a physician ordering neuroimaging following TBI should have a professional relationship with radiologists and/or nuclear medicine physicians who will be providing interpretive reports to the examining physician.

In general, when a non-radiologic physician is asked to examine persons within a court setting to determine if they have damage from an alleged TBI, it is recommended that the examining physician collect reports of the original injury and/or digital discs of previous neuroimaging, and that these be sent to the radiologist or nuclear medicine physician prior to the neuroimaging ordered by the examining physician. This will be very useful to the radiological physician at the time the examinee undergoes neuroimaging, and it will enable a clinical correlation to be determined between the chronic neuroimaging and the acute neuroimaging at the time of injury. Obviously, the examining physician should ask that a computer disc (CD) of the images of the examinee be prepared and sent to this physician with the report. The forensic physician should review the CD of the images, over-read them, and ensure that the forensic physician agrees with the interpretation of the radiologist. This is very important in a court case, because occasionally typographic errors are made in a radiological report. For instance, it is possible that a lesion in the right temporal lobe could be mistakenly reported as being present in the left temporal lobe. The forensic physician should then provide clinical correlation between the neuroimaging he/she orders of the examinee and relate this to the further analysis of medical records, mental examinations, neurological examinations, and neuropsychological test findings to determine the level of functional brain injury.

It is rare that a forensic physician is asked to evaluate a TBI victim during the acute phases following TBI. Almost all forensic medical assessments are made either in the subacute or chronic phase of the TBI. The forensic physician will generally focus upon neurologic, cognitive and behavioral changes following TBI, and any obvious negative neurological or orthopedic outcomes represented peripherally in the cranial nerves, arms or legs. Therefore, in order for the examining physician to provide testimony within reasonable medical probability, it is generally wise not to make outcome diagnoses and predictions about an examinee until at least six months, and up to 1-½ years following the TBI. Precise predictions are difficult with a TBI, but some generalizations can be made: [6]

1. The more severe the injury, the longer the recovery period, and the more impairment a survivor will have once recovery has plateaued.
2. Recovery from diffuse axonal injury takes longer than recovery from focal contusions.

3. Recovery from TBI with associated hypoxic injury is less complete than absent significant hypoxic injury.
4. The need for intracranial surgery does not necessarily indicate a worse outcome. For example, a patient requiring the removal of a subdural hematoma may recover cognition as completely as one who never needed surgery.

The length of time an examinee spends in coma correlates to both posttraumatic amnesia (PTA) and recovery times: [6]

1. A coma lasting seconds to minutes results in PTA that lasts hours to days; the recovery plateau occurs over days to weeks.
2. A coma that lasts hours to days results in PTA lasting days to weeks; the recovery plateau occurs over months.
3. A coma lasting weeks results in PTA that lasts for months; the recovery plateau occurs over months to years.

The aforementioned points about recovery periods and posttraumatic amnesia are extremely important when testifying in court about functional outcome of the TBI. Clearly, these periods of recovery and posttraumatic amnesia allow the forensic physician to testify to the trier-of-fact reasonable predictions about recovery time and outcomes. The litigation of a traumatic brain injury case for worker's compensation benefits or compensation for damages, often requires the forensic physician to provide the court with statements as to how long the individual will need medical assistance, how long the victim of the TBI will require rehabilitation, and to what level the TBI victim can be expected to return to his/her prior baseline.

## 2. Pathophysiology of traumatic brain injury

The forensic physician is often required to provide the court with a description of how a blunt force, a penetrating force, or an explosion can render the victim with a TBI. Much is known about the organic pathogenesis of TBI. The biomechanical forces commonly involved in TBI are usually of three main types: (1) blunt force trauma to the head and/or (2) penetrating injuries to the head and/or (3) blast overpressure brain injury from improvised explosive devices (IEDs), bombs, industrial explosions, and other sources of blast overpressure. The kinetic injury from blunt force trauma or blast overpressure translates into passive parenchymal damage and secondary brain insults. Brain tissue is injured by compressive, tensile and shearing strains, which in turn produce contusions, lacerations, or diffuse axonal injury. [6] The passive damage to brain tissue is generally instantaneous, but secondary brain insults are associated with post-trauma factors including ischemic blood flow, hypoxic injury, and metabolic changes at the cellular level. This cascade of events can occur over hours to several days after TBI and may significantly alter the level of damage and thus the prognosis. [7]

At the moment of blunt force trauma or blast overpressure injury, and less so with penetrating injuries, microporation of the lipid bilayer cell membrane occurs, leading to cell

rupture. This activates voltage- and ligand-gated channels, which in turn produces ischemia. This enables the entry of calcium ions and sodium ions into neurons with egress of potassium ions. The resulting ionic shift produces an altered state of consciousness. [8] Even with a concussion that does not produce evidence of structural brain injury, the concentration of extracellular potassium can be increased for a short period, up to 50 times baseline. For the more severely injured person, excess potassium in the extracellular fluid is sequestered, and there is a direct relationship between extracellular potassium and mortality. [9] As potassium is sequestered, this may produce ischemia secondary to cerebral edema. Another important development of tissue damage is associated with disturbances of calcium homeostasis. The cellular movement of calcium ions into the cell results in metabolic cascades. As the level of intracellular calcium dramatically increases, this in turn, causes the outer membrane of the mitochondria to develop permeability pores, which allows the calcium to interfere with electron transport in the cell. This may result in cell necrosis. [10] The neurochemical cascade that activates certain intracellular enzymes can cause the mitochondria to release proteins that result in programmed cell death (apoptosis). [11] The long-term effect of this confluence of compromise in ionic and molecular transport along the axonal sheath, is cytoskeletal damage. This, in turn, produces axotomy (disruption of the axon) and Wallerian degeneration. [11]

### **3. Structural neuroimaging of traumatic brain injury**

From a forensic standpoint, almost all cases of evaluation of traumatic brain injury will be completed well after the original injury. These evaluations are generally completed by a psychiatrist, neurologist, or physiatrist. Therefore, Variant 5: subacute or chronic closed head injury, the American College of Radiology (ACR) Appropriateness Criteria, enable the physician to determine a rating of appropriateness for examination of an injury by neuroimaging within the period after acute injury. [3] Variant 5 is for persons who demonstrate cognitive and/or neurological deficits at the time of the examination. Table 2 lists the ACR Appropriateness Criteria for Variant 5: closed head injury, subacute or chronic. It is important to note that at this time, the ACR Appropriateness Criteria for acute injuries following closed head injury invariably list CT of the head as the most appropriate neuroimaging modality. On the other hand, the reader should note in Table 2 that for the subacute and chronic head injury with cognitive and/or neurological deficits, MRI now becomes a preferred neuroimaging modality.

#### **3.1. Computed Tomography (CT)**

Neuroradiologists and neurosurgeons generally agree that CT is the most common means used for intracranial evaluation in the emergency department or acute care setting. While this opinion is changing with the evolving nature of high-speed MRI, it continues presently to be the accepted way to manage acute head injuries from a neuroradiological perspective. [12]



Radiologic Procedure	Rating	Comments	RRL*
MRI head without contrast	8		0
CT head without contrast	6		3
Tc-99m HMPAO SPECT head	4	For selected cases.	4
FG-PET head	4	For selected cases	4
MRA head and neck without contrast	4	For selected cases	0
MRA head and neck without and with contrast	4	For selected cases	0
CTA head and neck	4	For selected cases	3
MRI head without and with contrast	3		0
CT head without and with contrast	2		3
X-ray and/or CT cervical spine without contrast	2	Assuming there are no spinal neurologic deficits.	2
X-ray head	2		1
Functional (MRI) head	2		0
US transcranial with Doppler	1		0
Arteriography cervicocerebral	1		3
Rating Scale: 1,2,3 = Usually not appropriate; 4,5,6 = May be appropriate; 7,8,9 = Usually appropriate			* Relative Radiation Level
MRI = Magnetic Resonance Imaging CT = Computed Tomography SPECT = Single photon emission computed tomography FDG-PET = Fluorodeoxyglucose positron emission tomography MRA = Magnetic resonance angiography CTA = Computed tomographic angiography US = Ultrasound			

**Table 2.** American College of Radiology (ACR) Appropriateness Criteria: Variant 5. Subacute or Chronic Closed Head Injury with Cognitive and/or Neurological Deficit(s) [3]

It will be rare that the post-acute injury examination will require CT evaluation unless the examinee has a contraindicated metallic implant or other medical device such as prosthetic cardiac valves, cardiac pacemaker, etc. It is recommended that the examining physician, where possible, get a copy of the original CD of the CT head imaging from the acute care setting so that one can compare the possible pathology at the time the individual was evaluated on an emergency basis with the imaging of a current evaluation. This is because in order to provide the soundest of opinions to the trier-of-fact, upon the assessment of TBI, it is best wherever possible for the examining physician to clinically correlate the neuroimaging findings with that originally obtained at the time of the injury. For example, Figure 1 shows an initial CT following head trauma revealing a contusion of diffuse axonal injury in the left inferior temporal lobe, contusion in the right temporal tip, and an accompanying subarachnoid hemorrhage in the posterior fossa. It can be noted on a CT made approximately six weeks later (Figure 2), that there is now evidence of

encephalomalacia in the left temporal lobe and right temporal lobe, indicated by reduced attenuation of the brain parenchyma, and the subarachnoid blood is absent. As noted in the magnetic resonance imaging section below, it is important to determine later if indicia of injury still remain when the person is examined within the subacute or chronic phase.

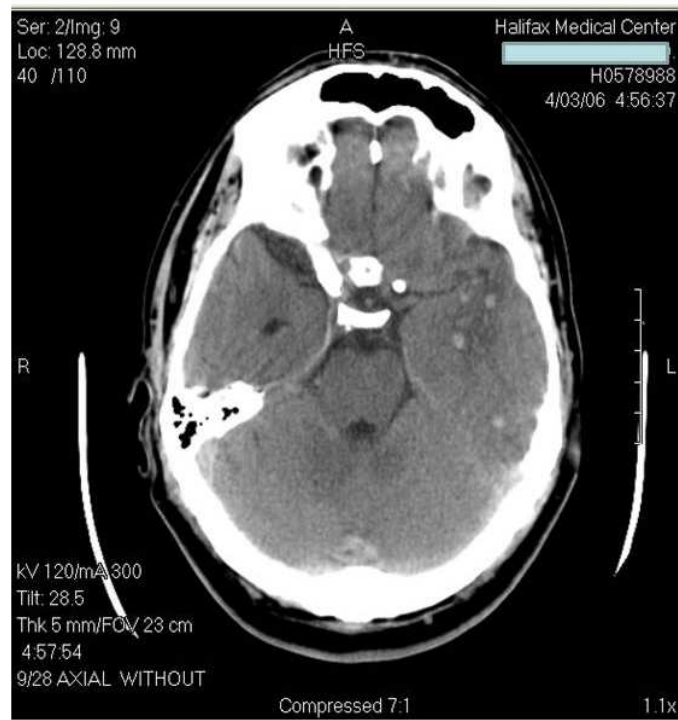


Figure 1.

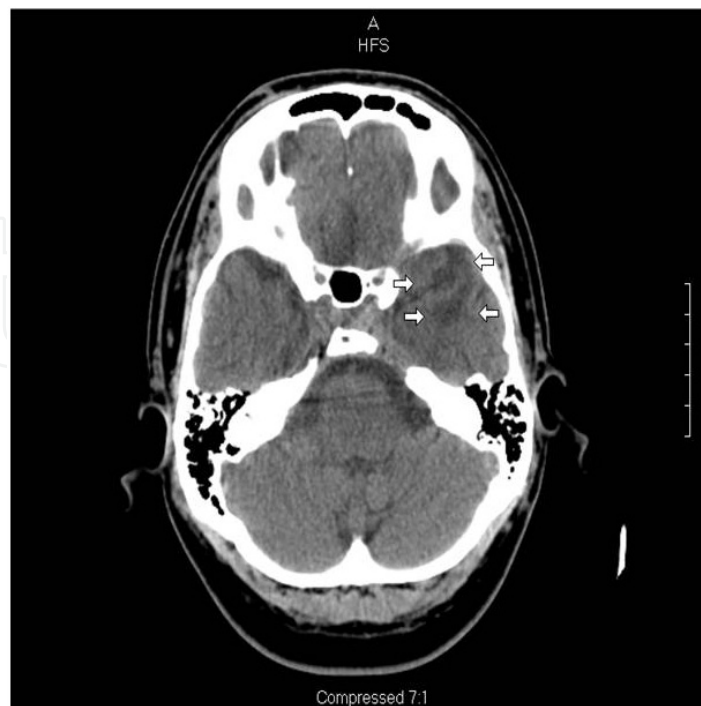

Figure 2.



Figure 3 shows CT evidence of a shear injury in the left frontal lobe of an adolescent following a fall from a moving vehicle onto the ground. When an MRI was obtained three years after injury, it is noteworthy that on the axial T2 gradient echo imaging, evidence of hemosiderin remains in the same anatomic area as a marker of the original shear injury, and the resultant bleeding has left hemosiderin behind (Figure 4). Figures 3 and 4 clearly demonstrate the usefulness of having initial CT imaging for comparison with postinjury MRI.

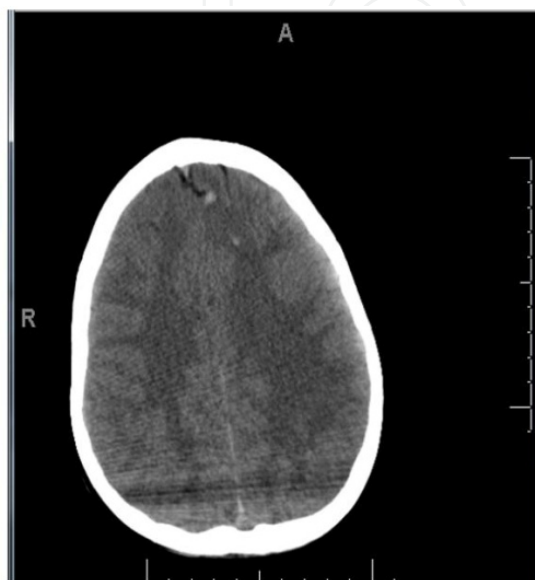

Figure 3.

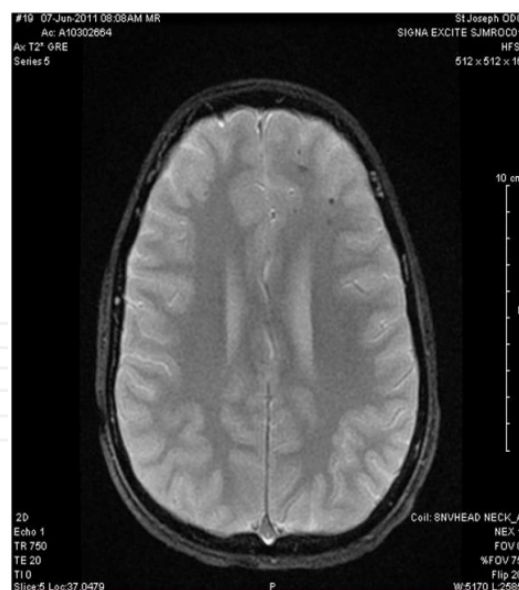


Figure 4.

### 3.2. Magnetic Resonance Imaging (MRI)

MRI has become a powerful tool in the assessment of the aftereffects of traumatic brain injury. From a medico-legal perspective, it is the complex behavioral and cognitive changes

that occur following TBI that will be of most interest. It is hoped that the forensic evaluation of traumatic brain injury will enable a positive medical correlation to be made between the evidence of injury on the MRI and the major changes in cognition that can be detected by neuropsychological assessment. [1] For instance, Figure 5 is an example of the appearance of encephalomalacia on a T2 MRI obtained in a young man who was brutally harmed in a backyard beating. The coronal image (Figure 6) delineates the extensive depth of this lesion on the lateral surface of the anterior left frontal lobe. It correlated very highly with mood changes that are often associated with left anterior frontal injuries as well as alterations of complex executive function confirmed on neuropsychological assessment.

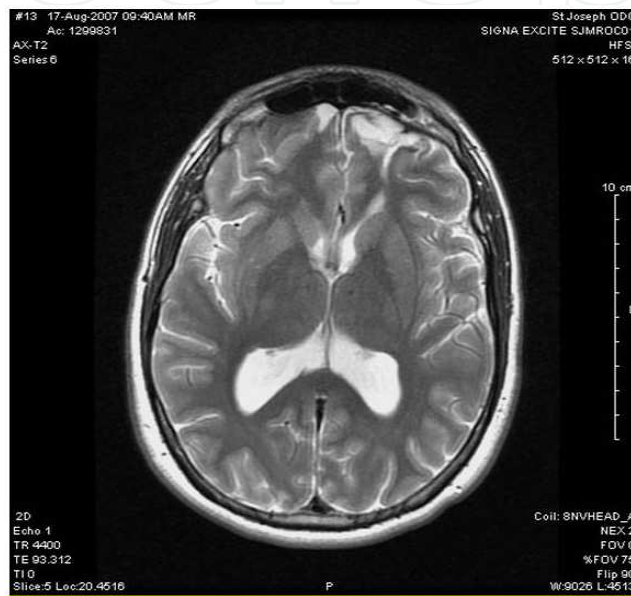


Figure 5.

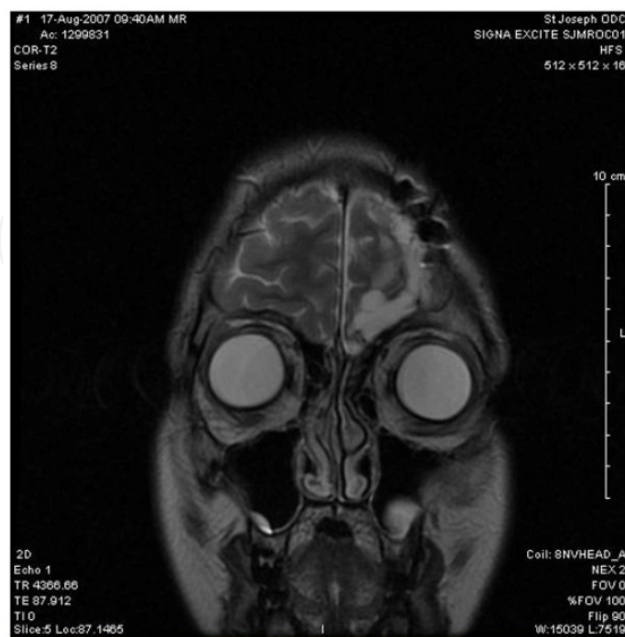

Figure 6.

Another example of the severe trauma that can occur following inflicted head injury is seen in Figures 7 and 8. Severe traumatic brain injury often causes substantial shrinkage of hippocampal structures. This shrinkage will often correlate with a substantial drop in memory skill. Figure 7, a coronal T-2 MRI image, shows significant encephalomalacia overlying the right cerebral hemisphere, which correlates very highly with a substantial enlargement of the hippocampal cistern on the right, following a reduction in hippocampal volume of almost two-thirds. This, in turn, correlates with volume loss in the brain, as demonstrated by the enlarged lateral ventricles. The level of encephalomalacia was quite massive, particularly in the right cerebral hemisphere, which is well demonstrated on the axial FLAIR MRI image in Figure 8.

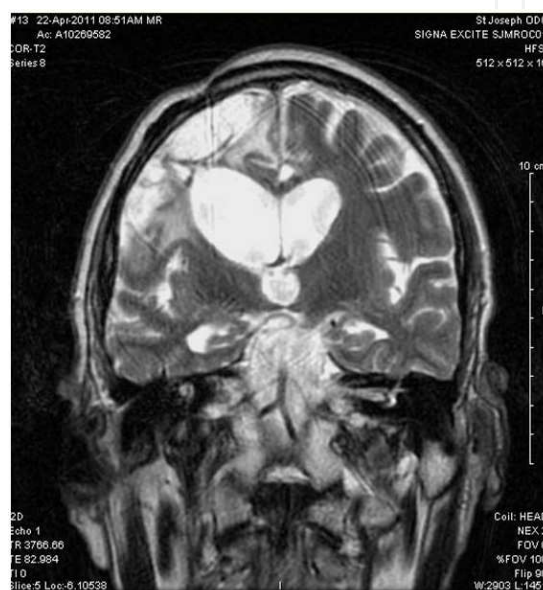

Figure 7.

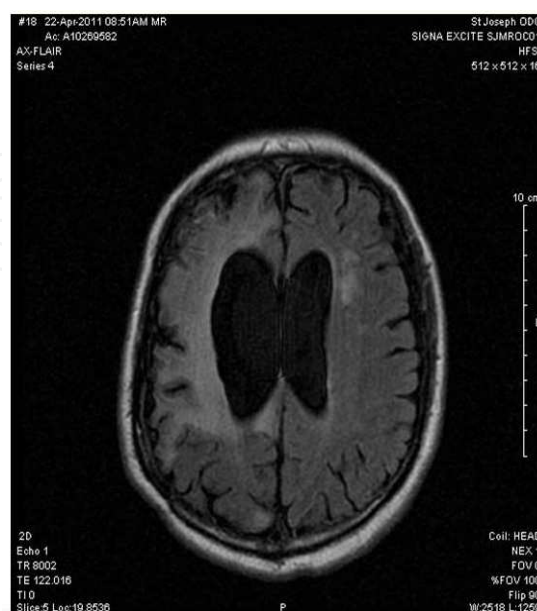


Figure 8.

A perplexing problem often seen in medico-legal evaluations of traumatic brain injury is that of an individual who had a preexisting brain insult and then sustained a second brain trauma. Distinguishing these from each other can be quite complex after the fact. Figure 9 represents a woman who had lung cancer metastatic to the brain 17 years prior to the image in Figure 9. The metastatic lesion was treated with whole-brain radiation, and the resulting white matter gliosis following radiation is demonstrated in Figure 9. The radiation was administered following the surgical excision of the left cerebral hemisphere metastatic lesion from the primary cancer in the lung. This is noted in Figure 10. Lastly, Figure 9 reveals in the right frontal brain, two areas of abnormal signal on axial FLAIR, which probably represents prior small nodes of tumor that were killed by whole-brain radiation, and then ex vacuo lesions developed when the metastatic tumors dissolved. Seventeen years following successful treatment of lung cancer metastatic to brain, her vehicle was struck by a very large tractor-trailer truck. She was seriously injured and required extraction from her automobile and transport to a Level I trauma center by helicopter. When received at the university hospital, her *Glasgow Coma Scale* = 10. She was making incomprehensible sounds and would localize to pain, but otherwise she was not speaking or answering questions. Her chronic phase examination at the time the MRI exemplars in Figures 9 and 10 were obtained, revealed her to be demented. Interviews with her family indicated that following successful treatment for lung cancer, she worked as a clerk for the Internal Revenue Service in the United States. She was able to continue that employment following brain surgery and brain irradiation. As often occurs with individuals who have significant preexisting cerebral disease, a substantial subsequent traumatic brain injury can markedly aggravate or exacerbate the underlying organic brain condition and produce a dementia that was not present prior to trauma. That appears to have occurred in this case.

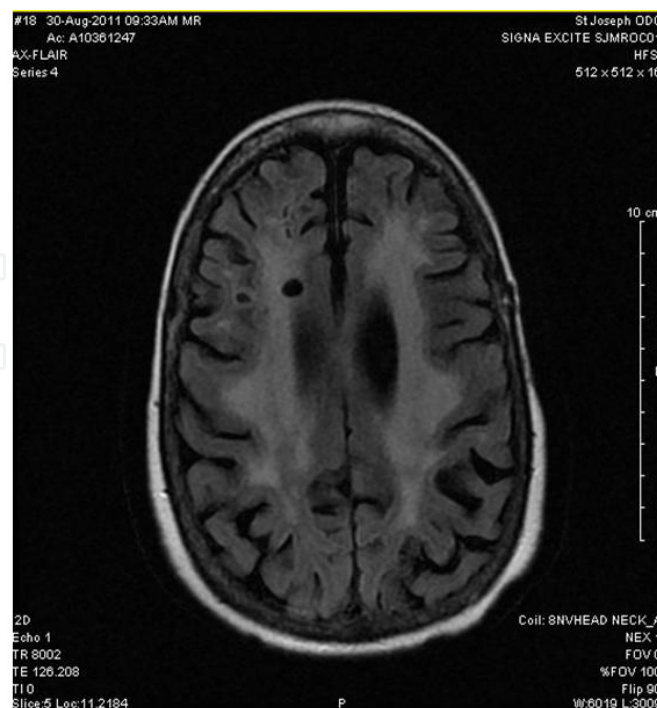
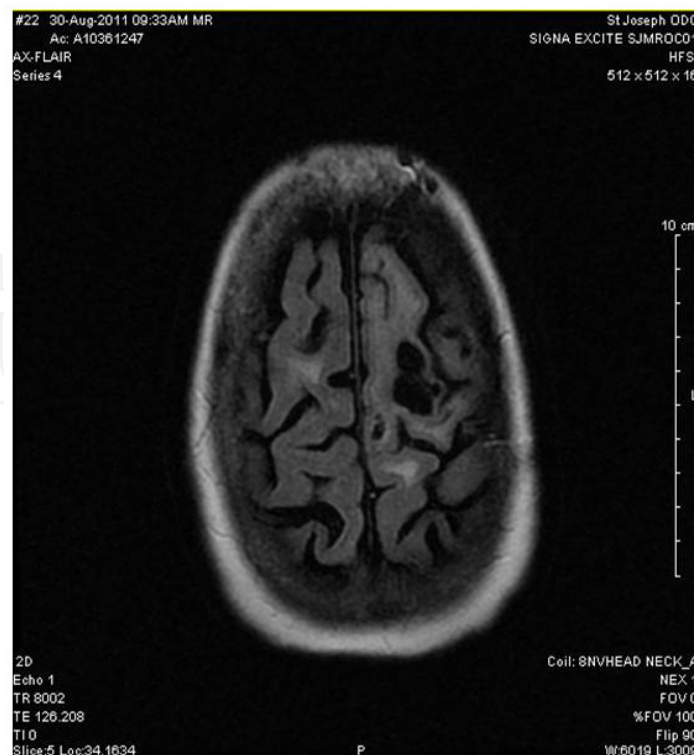


Figure 9.



**Figure 10.**

As stated earlier, while CT of the head has been the imaging modality of choice for the acute care of TBI, MRI is now being used in the acute phase more frequently due to the availability of the newer sequences. Figure 11 reveals a CT image of a man who fell 40 feet down a flight of stairs. His initial *Glasgow Coma Scale* = 7. He was found unconscious, lying facedown when Emergency Medical Services arrived. The initial CT depicted in Figure 11 indicates a focal hyperdensity in the left parietal lobe. Blood was accumulating in the left occipital horn, consistent with intraventricular hemorrhage. It is well known that intraventricular hemorrhage is a primary marker for diffuse axonal injury [1]. A few hours later, a diffusion-weighted image was made by MRI of the same patient. Figure 12 reveals evidence of ischemia near the left corpus callosum.

Returning to the issue of separate TBIs in the same individual with a significant time interval between, Figure 13 gives a graphic example of two independent brain injuries separated by a three-year interval. The first injury occurred in a motor vehicle accident in 2006. The injury can be seen in the lateral margin of the right inferior temporal lobe. Three years later, in 2009, she sustained a slip-and-fall at work and received injury to the inferior pole of the left temporal lobe found by CT. The 2006 injury caused significant orthopedic fractures. No follow-up imaging was ever obtained after injury. It is obvious that the 2006 injury played a substantial role in causing the right inferior temporal encephalomalacia, and this became a significant issue in the apportionment of damages to the 2009 injury.

Not only is it critical to obtain neuroimaging through prior medical evaluations at the time of the forensic examination of traumatic brain injury, but also it is also important to gather any significant preinjury medical information that may be present. A case in point is made



by reviewing Figures 14 and 15. In this case, a 30-year-old man was injured during a fall of more than 15 feet in a grain silo at a river offloading facility. The *Glasgow Coma Scale* = 5T when he arrived at a university hospital trauma center. The initial CT in Figure 14 reveals evidence of a right frontal contusion, a right lenticular contusion, and bilateral intraventricular bleeding, with bilateral effacement. Figure 15 reveals evidence of a midbrain hematoma. Following his injury, he had substantial cognitive complaints, which were corroborated by neuropsychological testing. However, the importance of securing other medical information became clear when it was learned that he was severely beaten at age 7 by his mother's boyfriend; he was found to be learning disabled; during his primary and secondary education, he had difficulty sitting still in school; he could not keep his mind on tasks as a child; he consumed 24 bottles of beer daily over more than a three-year period as a young adult; he had been convicted of two driving-under-the-influence charges; and he had been arrested three times for alcohol intoxication. Moreover, he had spent at least 180 days incarcerated on various occasions for alcohol-related offenses; he used cocaine more than 50 times in his life; he used lysergic acid eight to ten times in his life; and he admitted to using methamphetamine more than 200 times in his life. Had the images in Figures 14 and 15 been the sole information in the case, it is obvious that erroneous or incomplete conclusions could have been presented to a trier-of-fact.

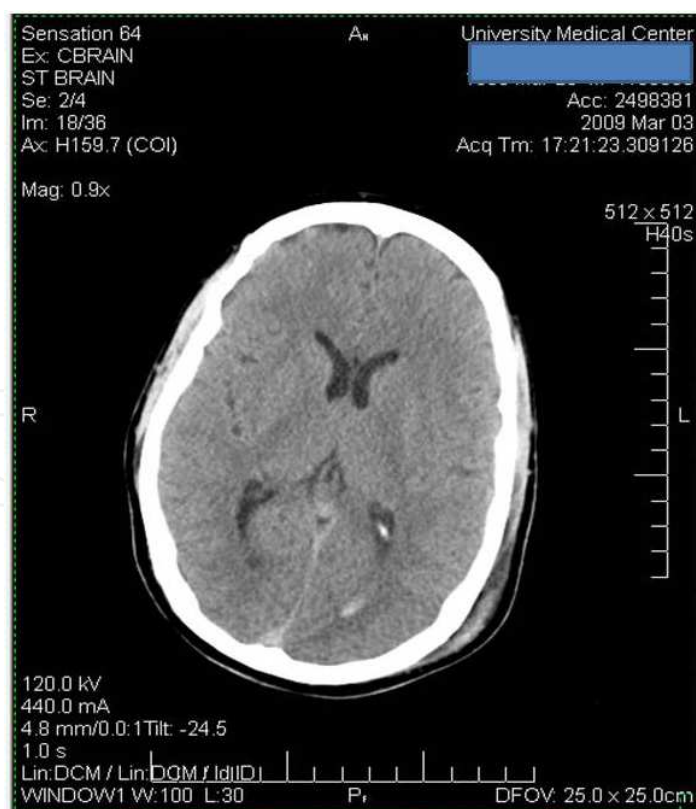


Figure 11.



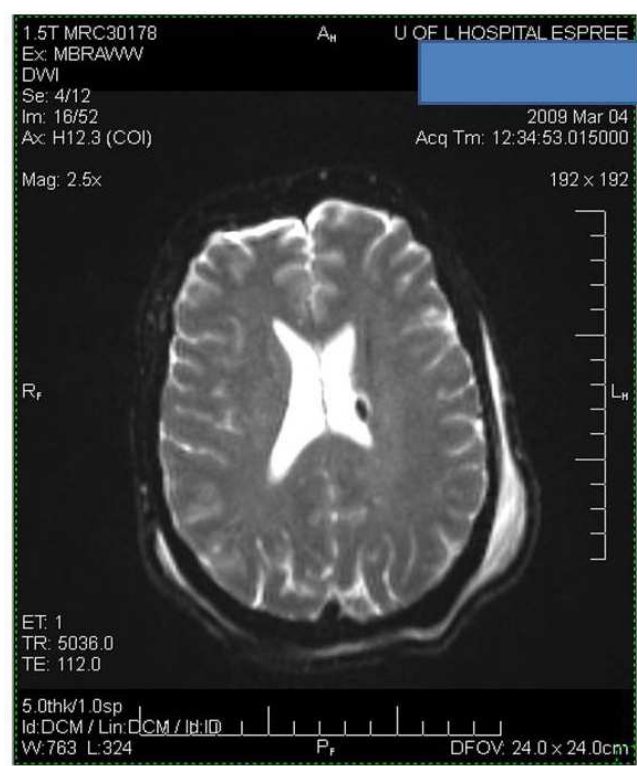


Figure 12.

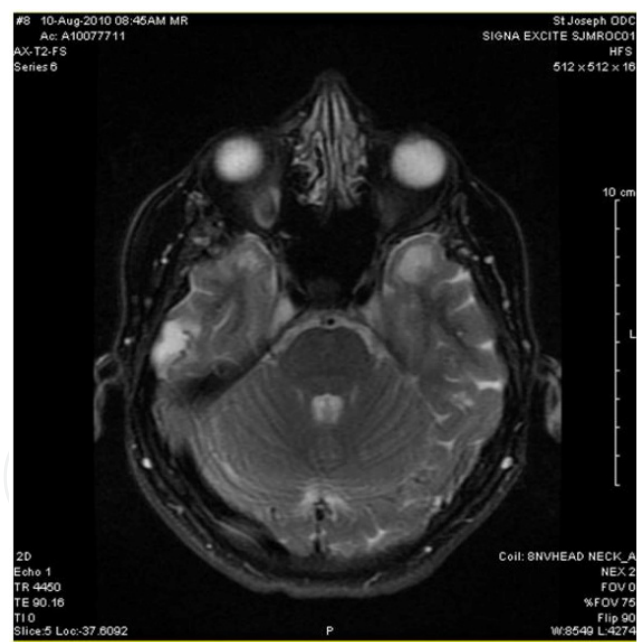

Figure 13.

As was noted above, there are three major causes of traumatic brain injury. Blunt force trauma has been discussed, and the second cause is penetrating injury. The issues with penetrating injury are different than those associated with blunt force trauma. The extent of injury from impalement of the head is extremely variable and depends on (1) the size, shape

and number of impaling projectiles; (2) the velocities of the projectiles when they enter the skull; and (3) the entry/exit sites and the course of the projectile through the brain. [13] The most prominent cause of penetrating brain trauma in the United States is gunshot wounds to the head. Individuals who receive injuries from large caliber, high velocity weapons, rarely survive. The neuroimaging in those who survive rarely, if ever, correlates in an anatomical fashion to the neuropsychological testing used to measure residual brain function.

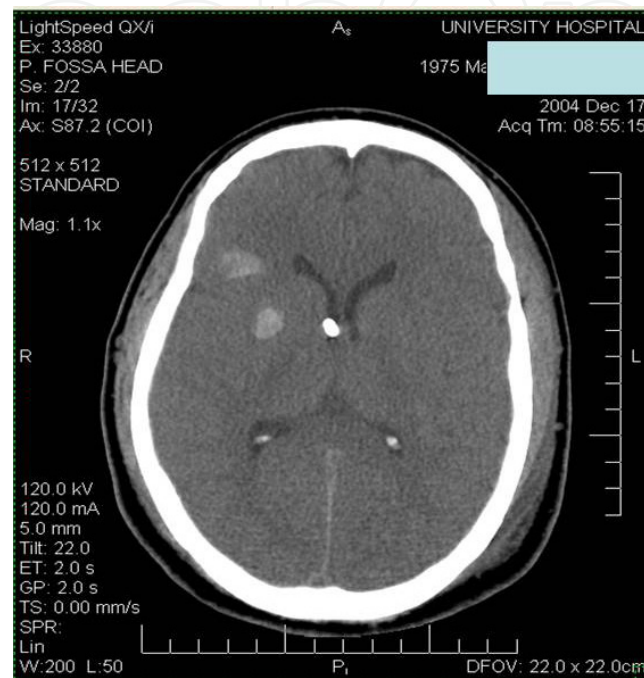


Figure 14.

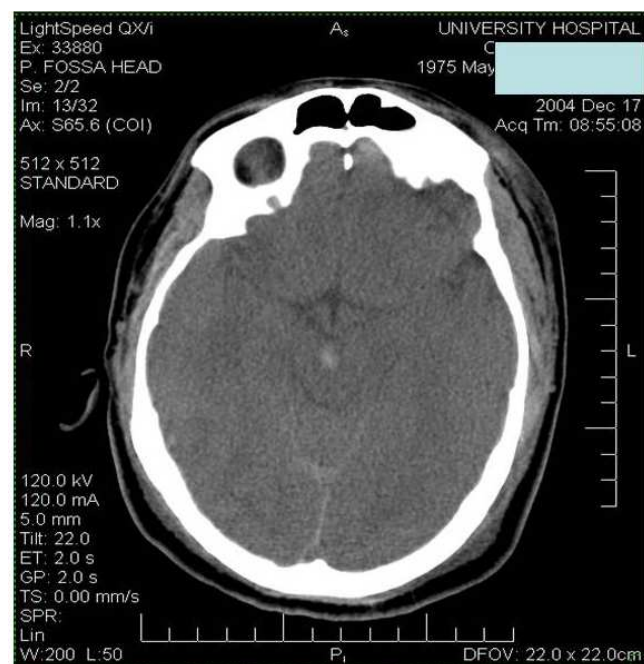


Figure 15.

The third major cause of TBI is blast overpressure brain injury. This is a worldwide phenomenon that has been dramatically changed in terms of outcome to survivors as a result of improvised explosive devices and other high-velocity explosive materials that are now in common usage by terrorists throughout the world. The evaluation of blast overpressure brain injury within a forensic medical setting generally reveals little on neuroimaging unless there has been an association between the type of explosive charge and whether or not it contained projectiles, which could be sent by high velocity as the blast force moves in a radius beyond the explosion site. Little is found on neuroimaging if no penetration of the skull occurs. Table 3 gives a description of the phenomenology of blast overpressure trauma. The forensic physician should be aware of these facts in any person who has sustained a significant blast injury with associated multiple body trauma. As Table 3 demonstrates, head injuries rarely occur in isolation in these kinds of injuries, and it is expected that injuries to the lung, brain, auditory system, bowel and testicle may all occur in single or multiple combinations. A lung or bowel rupture is seen with powerful blast injuries, as gas-filled organs are particularly susceptible to injury by a blast. The cognitive and emotional changes can be quite extensive following blast overpressure head injury and often quite dramatic. [14]

<ul style="list-style-type: none"><li>• Intense overpressurization impulse (at the speed of sound &gt; 700 mph) causes primary, secondary, tertiary, and quaternary injuries.</li><li>• High-order explosives: TNT, C-4, Semtex, nitroglycerin, dynamite and ammonium nitrate/fuel oil.</li><li>• Injuries to lung, brain, auditory system, bowel, and testicles.</li><li>• Cognitive and emotional changes common.</li></ul>
---

**Table 3.** Blast or Explosion Overpressure Trauma [1]

Of the many sequences available in MRI, diffusion tensor imaging (DTI) is becoming one of the more prominent new techniques, particularly for evaluating brain white matter. However, there is a word of caution about the forensic uses of this new tool. The legal profession is being transformed by neuroimaging as applied to civil litigation, particularly in traumatic brain injury cases. A whole new area has developed called Neurolaw. [15] The reader is referred to a recent analysis of diffusion tensor imaging applied in mild traumatic brain injury litigation. [16]. DTI is an MRI-based data-analysis technique, which fundamentally relies on the clinically well established technique of diffusion-weighted imaging (DWI), a common sequence used in MRI to detect strokes and ischemia. DTI is a more refined adaptation of DWI that allows for the determination of the directionality as well as the magnitude of water diffusion in the brain, and more specifically within and between different brain tissue types. [17] A scaled value between 0 and 1 describes the degree of a diffusion process. A value of 0 means that the diffusion is unrestricted in all directions. Tractography is a method using DTI to assess the structural integrity of white matter tracts within the brain. [18-19]

Since 2007, in the United States, DTI has been allowed in court proceedings where TBI is litigated by state court judges on a reasonably regular basis with inability by most defense

lawyers to challenge this concept based on *Daubert* criteria. Wortzel, et al. have concluded that careful analysis of DTI in mild traumatic brain injury literature, guided by *Daubert* criteria, suggests that presently the admission of DTI evidence in mild TBI litigation is seldom medically appropriate.[16] Under the best of circumstances, with DTI data generated by highly experienced laboratories and from patients with clinically unambiguous mild traumatic brain injury, the imaging data may add a quantifiable measure of white matter integrity to the body of evidence describing such patients. However, in these cases, DTI would serve as superfluous evidence. More alarming, though, is the potential use of DTI to prove mild traumatic brain injury in cases where other forms of more reliable and accepted clinical evidence fail to uphold, or directly refute such conclusions, such as the standard MRI sequences, T1, T2 and FLAIR. The compelling visual images of DTI do not add any useful data to whether or not the alleged TBI victim can think, reason, calculate, analyze, or even speak or read. This data cannot be determined from DTI images and requires careful face-to-face neuropsychiatric examination as well as corroborating neuropsychological test data. If misused and left unchallenged, DTI imaging findings in mild TBI may be misleading. An expert witness is required ethically to acknowledge this fact, and particularly for the diagnosis of mild traumatic brain injury. At the single patient level, data are not available in peer reviewed scientific journals and at a generally accepted standard within the medical field.[16] In fact, there is currently no evidence in the medical literature that enables a correlation to be drawn from DTI findings in order to relate this to neuropsychological data, and provide an anatomical relationship between the DTI data and the neuropsychological data. Figure 16 demonstrates the beauty of the images obtained by DTI. However, as noted, it is not possible at this time to draw a fundamental positive correlation between elements of the DTI image and the functional capacity of a person's brain after TBI. In other words, DTI images cannot tell a jury if a person can think, reason, calculate, remember, or speak.

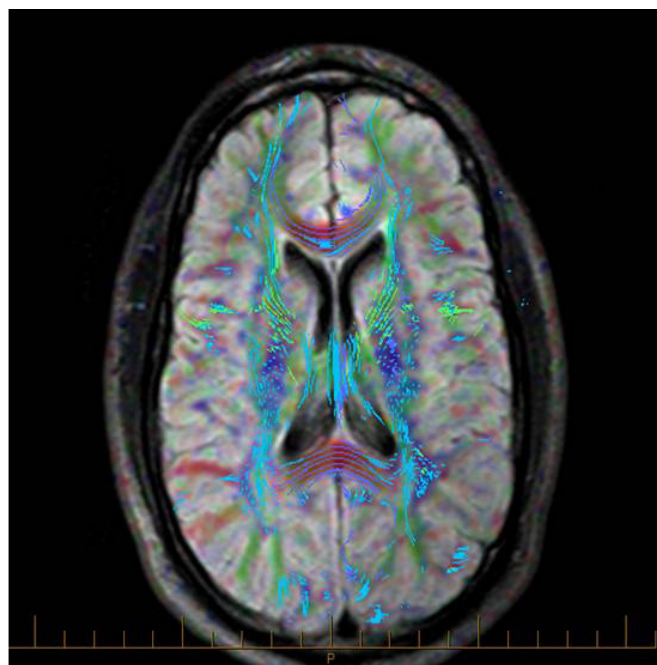


Figure 16.

Susceptibility-weighted imaging (SWI) is a high-resolution 3D echo MR imaging technique with phase post-processing that accentuates the paramagnetic properties of blood products such as deoxyhemoglobin, intracellular methemoglobin, and hemosiderin. It is particularly useful for detecting intravascular venous deoxygenated blood as well as extravascular blood products. It is also quite sensitive to the presence of other substances such as iron, some forms of calcification, and air. In traumatic brain injury, its greatest use is for the detection of posttraumatic blood products. It may be useful for detecting some of the secondary manifestations of traumatic brain injury such as hypoxic/anoxic injury. Figure 17 depicts significant evidence of multiple microhemorrhages in the left frontal cerebral hemisphere with a few hemorrhages in the posterior right cerebral hemisphere. These images were obtained following a high-speed, single vehicle collision into a tree by a teenager operating his automobile at high speed. These images were made many months after the original impact, indicating the ability of SWI to detect hemosiderin deposits well after the trauma. [20]

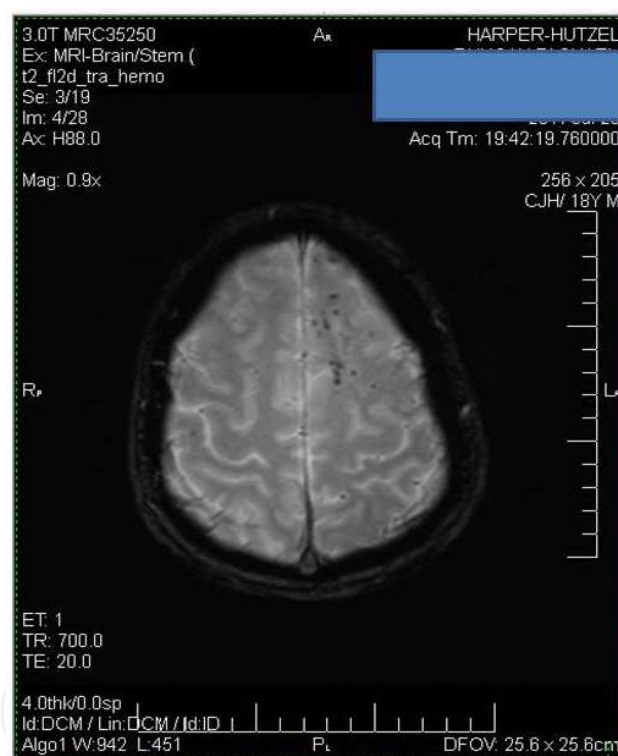


Figure 17.

#### 4. Functional neuroimaging

Functional neuroimaging as applied to TBI, is of two general types: (1) tomographic images based on nuclear scanning using radioactive isotopes, and (2) imaging using functional aspects of magnetic resonance. Nuclear imaging consists primarily of single photon emission computed tomography (SPECT) and positron emission tomography (PET). The functional imaging using magnetic resonance is functional MRI (fMRI) and magnetic resonance spectroscopy (MRS).



#### 4.1. Single Photon Emission Computed Tomography (SPECT)

SPECT is based upon an indirect determination of blood flow in the brain using the distribution of a radiopharmaceutical agent within the brain to approximate almost on a 1:1 basis, regional cerebral blood flow. The commonest tracer used today is Technetium-99 m-hexamethylpropyleneamine oxime (Tc-99 mHMPAO). Other tracers are available for use in SPECT as well, and all are known nuclear medicine pharmaceuticals. To obtain a SPECT brain image, the radioactive tracers are injected into the venous blood of the person to be imaged. After appropriate distribution, the tracer decays, emitting a photon that is detected and recorded by a gamma camera. The data from the gamma camera are then reconstructed by computer, and tomographic sectioning is undertaken.

SPECT has numerous sources of potential measurement error, which are important in a legal case. SPECT imaging requires that regional radiation counts be normalized to a brain area that is theoretically free from injury. This sets a standard of relative flow values (RFV) in SPECT. Nuclear medicine physicians commonly base these relative values upon an anatomical region such as the thalamus or cerebellum, which is assumed theoretically to be uninjured in TBI. (It is not uncommon for either of these structures to be injured in TBI.) The reader is advised to again review Table 2, the American College of Radiology Appropriateness Criteria for subacute or chronic closed head injury. [3] This table demonstrates that for the subacute or chronic closed head injury, SPECT is considered appropriate 4/9 on a 1-9 rating scale. Recently, the appropriateness of SPECT imaging has been reviewed in the forensic psychiatric literature when used with testimony in TBI cases. These reviews have concluded that SPECT uses a sole diagnostic imaging modality, lacks scientific merit, and may actually breach the ethics of expert testimony when SPECT is presented to a trier-of-fact as a sole neuroimaging instrument to demonstrate that a TBI has occurred. [21, 22] Currently, the state of the art for SPECT neuroimaging in TBI, particularly in mild traumatic brain injury, is that there is no SPECT profile that is pathognomonic for any level of TBI. [23] Moreover, SPECT imaging is routinely positive in a variety of medical and neurological disorders. Thus, false positives are very high including such common issues as substance abuse, depression, and attention deficit disorder.

#### 4.2. Positron Emission Tomography (PET)

Current PET studies of brain tissue generally utilize intravenous tracers such as 18F-fluorodeoxyglucose (FDG) for quantification of regional brain metabolism. This is based on giving the brain a sugar analog. The brain then attempts to metabolize in the same fashion as it would for glucose. The decay particles from the 18F-FDG are detected and then converted to digital images, which are further converted to colors corresponding to regional differences in 18F-FDG metabolism. Thus, similar to SPECT, PET is a radioisotope-based imaging technology. Its most common current application is for the detection of metastatic cancer or recurrence of cancer.

Using PET for the evaluation of chronic cognitive symptoms potentially related to TBI seems an intuitive choice for the physician. PET has been used for the evaluation of TBI since 1970,



but to this date, more than 40 years later, few studies can be found that directly relate functional imaging findings between PET and cognition following TBI.[1] Moreover, the majority of studies found within the neuropsychological literature and other psychological assessments where PET has been used, have been obtained at time points that were quite disparate from the time at which the imaging occurred. It is rare to find studies where the neuropsychological testing was done at time points that correspond to when the PET images were obtained. [24] Additionally, when one reviews the ACR Appropriateness Guidelines for using PET following TBI (Table 2) to evaluate chronic head trauma with cognitive and neurological deficits, PET is rated 4/9 for that use. [3]

There are a few carefully designed studies, which do find localized abnormal cerebral metabolism rates in the frontal and temporal regions that correlate with subjective complaints and neuropsychological test results obtained during the chronic phase of recovery. [25] However, there are almost no contemporary studies and no significant studies in the last 15 years that find strong correlations between PET neuroimaging of TBI and concurrent correlation with neuropsychological cognitive data. For the forensic examiner, though, there is one situation where PET may be the imaging modality of choice when evaluating a TBI. This would be a patient who may have Alzheimer's disease present before or closely associated with a concurrent TBI. In those cases, PET might be quite useful to differentiate the lesions of Alzheimer's disease from the lesions of TBI, as the current neuroimaging data of Alzheimer's disease using PET is quite specific for the regions that generally are metabolically abnormal. These regions of abnormality in Alzheimer's disease are not regions generally damaged in patients who have sustained cortical injury from traumatic brain injury. It is not recommended that PET be used as a sole neuroimaging modality in assessing a TBI case, especially mild TBI. [22]

### **4.3. Functional Magnetic Resonance Imaging (fMRI)**

Functional magnetic resonance imaging is used routinely to study cognition, and it has become the neuroimaging modality of choice for such studies. Moreover, there is a significant body of medical literature that demonstrates strong correlations between fMRI findings and neuroanatomical areas specific for various domains of cognition. [26] However, while fMRI represents a very advanced approach to brain neuroimaging, this advanced approach does not meet the criteria of real-world data usage to evaluate TBI in a single case. Functional magnetic resonance imaging has not reached an efficient threshold of scientific evidence for routine use for testimony at any level of injury severity after head trauma. Reviewing Table 2, it can be seen that the American College of Radiology rates this technique 2/9 for appropriateness in evaluating subacute or chronic closed head injury. [3]

Functional MRI (fMRI) is a variant of structural MRI. The primary differences between the two are that the dependent variable of interest in fMRI is the change in magnetic susceptibility related to increases in blood flow. These changes occur due to a presumed alteration in neural activity. The focus of fMRI is on regional changes in brain activity rather than anatomic structure, such as noted using classical MRI techniques. The excess blood

flow to the region of interest results in a localized surplus of oxyhemoglobin relative to deoxyhemoglobin in the central venous and capillary beds. Oxyhemoglobin is naturally diamagnetic, while deoxyhemoglobin is paramagnetic. There is a net decrease in the paramagnetic material resulting in an increased signal intensity that can be detected externally (BOLD: blood oxygen level dependent). It is not recommended that fMRI be used for the routine evaluation of traumatic brain injury.[3]

#### 4.4. Magnetic Resonance Spectroscopy (MRS)

Figure 19 shows a more readable spectroscopic graph of the chemicals of interest. Other data are collected numerically and displayed in this case in Figure 20. It is the evidence of decreased N-acetyl aspartate (NAA) that may be the most promising for evaluating neuronal loss and dysfunction in forensic TBI assessment. MRS can be obtained in a standard MRI system by obtaining appropriate software for the analysis. In diffuse axonal injury (DAI), the main abnormalities found using MRS to evaluate TBI are reductions in NAA levels and a reduction in the NAA/creatine ratio. DAI is also associated with an increase in Cho levels and an increase in the Cho/creatine ratio. Choline is associated with myelin and membrane breakdown. Neuronal damage is usually characterized by a reduction in the NAA/creatine ratio in parietal white matter near the corpus callosum. It can be detected by MRS in the more acute phase from the second day forward, and in the chronic phase up to three years post-trauma. [28] Proton MRS is the most widely applicable form of MRS. MRS has been approved by the United States Food and Drug Administration as a noninvasive method providing metabolic information about the brain in general. [29]

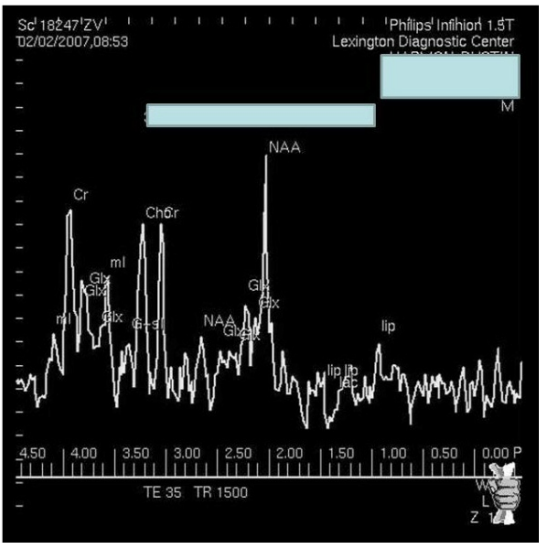


Figure 19.

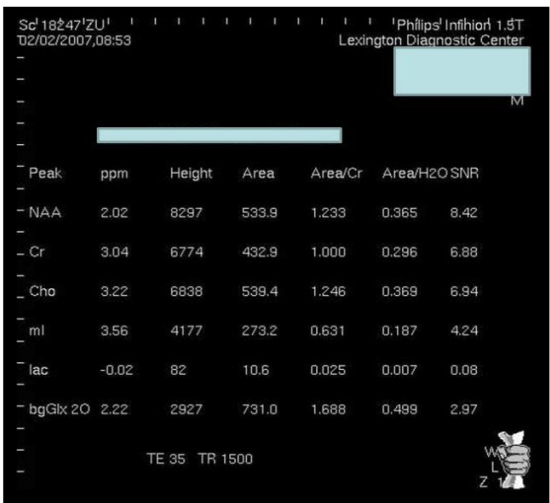


Figure 20.

## Author details

Robert P. Granacher, Jr.

Department of Psychiatry, University of Kentucky College of Medicine,  
Lexington Forensic Neuropsychiatry, Lexington, KY, USA

## 5. References

- [1] Granacher RP. The Use of Structural and Functional Imaging in the Neuropsychiatric Assessment of Traumatic Brain Injury. In: Granacher, RP. *Traumatic Brain Injury: Methods for Clinical and Forensic Neuropsychiatric Assessment*. 2<sup>nd</sup> ed. Boca Raton: CRC Press; 2008. p. 207-246.
- [2] Granacher RP. Neuroimaging in Traumatic Brain Injury. In: Simpson J, editor. *Neuroimaging in Forensic Psychiatry*. Cambridge: Cambridge University Press; 2012. p. 41-61.
- [3] American College of Radiology [home page on the Internet]. Reston, Virginia: ACR Appropriateness Criteria [updated 2008; cited 2012 March 17]. Available from: <http://www.ACR.org/>
- [4] Mittenberg W, Patton C, Craynock E, et al., Base Rates of Malingering and Symptom Exaggeration. *J Clin Exp Neuropsychol*. 2002; 24: 1094-1102.
- [5] Granacher RP. Forensic Issues and TBI. In: *Clinical Manual of Adults with Traumatic Brain Injury*. Washington D.C.: American Psychiatric Press; 2012. [ In press ]
- [6] Blumbergs P, Reilly P, Vink R. Trauma. In: Love S, Lewis D, Ellison D, editors. *Greenfield's Neuropathology*. 8<sup>th</sup> ed. London: Hodder Arnold; 2008. p. 733-812.
- [7] Aarabi B, Eisenberg H, Murphy K, et al. Traumatic Brain Injury: Management and Complications. In: Layon A, Gabrielli A, Friedman W, editors. *Textbook of Neurointensive Care*. Philadelphia: Saunders; 2004. p. 771-794.
- [8] Bullock R, Zauner A, Woodward J, et al. Early Insults to the Injured Brain. *J Neurosurg* 1998; 89: 507-518.
- [9] Marshall L. Head Injury: Recent Past, Present, and Future. *Neurosurg*. 2000; 47: 546-561.
- [10] Maxwell W, Povlishock J, Graham D. A Mechanistic Analysis of Nondisruptive Axonal Injury: A Review. *J Neurotrauma*. 1997; 14: 419-440.
- [11] Buki A, Okonkwo D, Povlishock, J. Postinjury Cyclosporine-A Administration Limits Axonal Damage and Disconnection in Traumatic Brain Injury. *J Neurotrauma*. 1999; 16: 511-521.
- [12] Quisling R, Sohn-Williams L. Neuroradiologic Imaging. In: Layon A, Gabrielli A, Friedman W, editors. *Textbook of Neurointensive Care*. Philadelphia: Saunders; 2004. p. 41-101.
- [13] Osborne A, Salzman K, Barkovich A, editors. *Diagnostic Imaging: Brain*. 2<sup>nd</sup> ed. Salt Lake City: Amirsys; 2010. p. I2.2 – I2.75.
- [14] Taber K, Warden D, Hurley R. Blast Related Traumatic Brain Injury: What is Known? *J Neuropsychiatry Clin Neurosci*. 2006; 18: 141-145.

- [15] Rozen J. The Brain on the Stand: How Neuroimaging is Transforming the Legal System. *The New York Times Magazine*. 2007; March 11. p. 48.
- [16] Wortzel H, Kraus M, Christopher M, et al. Diffusion Tensor Imaging in Mild Traumatic Brain Injury Litigation. *J Am Acad Psychiatry Law*, 2011; 511-523.
- [17] Kraus MF, Susmaras T, Caughlin BP, et al. White Matter Integrity and Cognition in Chronic Traumatic Brain Injury: A Diffusion Tensor Imaging Study. *Brain*. 2007; 130: 2508-2519.
- [18] Sidaros A, Engberg A, Sidaros K, et al. Diffusion Tensor Imaging During Recovery from Severe Traumatic Brain Injury and Relation to Clinical Outcome: A Longitudinal Study. *Brain*. 2008; 131: 559-572.
- [19] Rutgers D, Toulgoat F, Kazejust J., et al. White Matter Abnormalities in Mild Traumatic Brain Injury: A Diffusion Tensor Imaging Study. *AJNR Am J Neuroradiol*. 2008; 29: 514-519.
- [20] Tonga K, Ashwalb S, Obenause A, et al. Susceptibility-weighted MR Imaging: A Review of Clinical Applications in Children. Annual Meeting of the American Society of Neuroradiology, Toronto, Ontario, Canada; April – May 2005.
- [21] Wortzel H, Filley C, Anderson C, et al. Forensic Applications of Cerebral Single Photon Emission Computed Tomography in Mild Traumatic Brain Injury. *J Am Acad Psychiatry Law*. 2008; 36: 310-322.
- [22] Granacher R. Commentary: Applications of Functional Neuroimaging to Civil Litigation of Mild Traumatic Brain Injury. *J Am Acad Psychiatry Law*. 2008; 36: 323-328.
- [23] Ricker J. Functional Neuroimaging in Medical Rehabilitation Populations. In: Delisa, J, Gans B, editors. *Rehabilitation Medicine*, 4<sup>th</sup> ed. Baltimore: Williams and Wilkins; 2005. p. 229-242.
- [24] Ruff R, Crouch J, Troester A, et al. Selective Cases of Poor Outcome Following Minor Brain Trauma: Comparing Neuropsychological and PET Assessment. *Brain Inj*. 1994; 8: 297-308.
- [25] Gross H, Kling A, Henry G, et al. Local Cerebral Glucose Metabolism in Patients with Long-term Behavioral and Cognitive Deficits Following Mild Head Injury. *J Neuropsychiatr Clin Neurosci*. 1996; 8: 324-334.
- [26] Mayberg HS. Towards the Use of Neuroimaging in the Management of Major Depression. The American Neuropsychiatric Association 23<sup>rd</sup> annual meeting; 2012 Mar 21-24; New Orleans, USA.
- [27] Brooks W, Holshouser B. Magnetic Resonance Spectroscopy in Traumatic Brain Injury. In: *Clinical MR Neuroimaging: Physiological and Functional Techniques*, 2<sup>nd</sup> ed. Cambridge: Cambridge University Press; 2010. p. 656-662.
- [28] Sinson G, Bagley L, Cecil K., et al. Magnetization Transfer Imaging in Proton MR Spectroscopy in the Evaluation of Axonal Injury: Correlation with Clinical Outcome After Traumatic Brain Injury. *AJNR Am J Neuroradiol*. 2001; 22: 143-151.
- [29] Bandao L, Domingues R. *MR spectroscopy of the brain*. Philadelphia: Lipincott, Williams and Wilkins; 2004.