

# We are IntechOpen, the world's leading publisher of Open Access books Built by scientists, for scientists

6,900

Open access books available

185,000

International authors and editors

200M

Downloads

Our authors are among the

154

Countries delivered to

TOP 1%

most cited scientists

12.2%

Contributors from top 500 universities



WEB OF SCIENCE™

Selection of our books indexed in the Book Citation Index  
in Web of Science™ Core Collection (BKCI)

Interested in publishing with us?  
Contact [book.department@intechopen.com](mailto:book.department@intechopen.com)

Numbers displayed above are based on latest data collected.  
For more information visit [www.intechopen.com](http://www.intechopen.com)



---

# Activation of Brain Sensorimotor Network by Somatosensory Input in Patients with Hemiparetic Stroke: A Functional MRI Study

---

Hiroyuki Kato and Masahiro Izumiyama

Additional information is available at the end of the chapter

<http://dx.doi.org/10.5772/51693>

---

## 1. Introduction

Stroke is one of the leading causes of disability in the elderly in many countries. Residual motor impairment, especially hemiparesis, is one of the most common sequelae after stroke. Motor recovery after stroke exhibits a wide range of difference among patients, and is dependent on the location and amount of brain damage, degree of impairment, and nature of deficit (Duncan et al., 1992). Full recovery of motor function is often observed when initial impairment is mild, but recovery is limited when there were severe deficits at stroke onset. The motor recovery after stroke may be caused by the effects of medical therapy against acute stroke, producing a resolution of brain edema and an increase in cerebral blood flow in the penumbra and remote areas displaying diaschisis. However, functional improvements may be seen past the period of acute tissue response and its resolution. The role of rehabilitation in facilitating motor recovery is considered to be produced by promoting brain plasticity.

Non-invasive neuroimaging techniques, including functional magnetic resonance imaging (fMRI) and positron emission tomography (PET), enable us to measure task-related brain activity with excellent spatial resolution (Herholz & Heiss, 2000; Calautti & Baron, 2003; Rossini et al., 2003). The functional neuroimaging studies usually employ active motor tasks, such as hand grip and finger tapping, and require that the patients are able to move their hand. Neuroimaging studies in stroke patients have reported considerable amounts of data that suggest the mechanisms of motor functional recovery after stroke. Initial cross-sectional studies at chronic stages of stroke have demonstrated that the pattern of brain activation is different between paretic and normal hand movements, and suggested that long-term recovery is facilitated by compensation, recruitment and reorganization of cortical motor

function in both damaged and non-damaged hemispheres (Chollet et al., 1991; Weiller et al., 1992; Cramer et al., 1997; Cao et al., 1998; Ward et al., 2003a). Subsequent longitudinal studies from subacute to chronic stages (before and after rehabilitation) have revealed a dynamic, bihemispheric reorganization of motor network, and emphasized the necessity of successive studies (Marshall et al., 2000; Calautti et al., 2001; Feydy et al., 2002; Ward et al., 2003b).

When the stroke patients are unable to move their hand, alternative paradigms are necessary to study their brain function. Passive, instead of active, hand movement has been employed for this purpose, and increases in brain activities are found not only in sensory but also motor cortices (Nelles et al., 1999; Loubinoux et al., 2003; Tombari et al., 2004). Functional neuroimaging studies suggest that a change in processing of somatosensory information in the sensorimotor cortex may play an important role in motor recovery after stroke (Schaechter et al., 2006).

Most significant recovery of motor function takes place within the first weeks after stroke and an early introduction of rehabilitation is crucial for a good outcome. Rehabilitation at the early stages of stroke uses physiotherapy, such as massage and passive movement of the paretic hand, as an initial step of rehabilitation, especially in patients with severe motor impairment. However, it is difficult to assess the effects of physiotherapy in patients with severe impairment early after stroke. In this fMRI study, we investigated the effects of somatosensory input on the activity of brain sensorimotor network in stroke patients. Since somatosensory feedback is essential for the exact execution of hand movement, the result can provide a scientific basis for the establishment of rehabilitation strategies.

## **2. Materials and methods**

### **2.1. Subjects**

We selected 6 stroke patients with pure motor hemiparesis (4 men and 2 women, 63-85 years old). Three of them received fMRI during a task of unilateral palm brushing (stimulation of tactile sensation using a plastic hairbrush at approximately 1 Hz), and three other patients received fMRI during a task of unilateral passive hand movement (stimulation of proprioceptive sensation by passive flexion-extension of fingers at approximately 1 Hz). The fMRI studies were performed 5 days to 2 months after stroke onset.

The patients presented with neurological deficits including moderate to severe hemiparesis, and were admitted to our hospital. They received standard medical therapy for stroke and rehabilitation. All of them were right-handed. All the cerebral infarcts were evidenced by MRI, and were located in various regions of the cerebrum. They could hardly move their hands when the fMRI was performed. Clinical data are summarized in Table 1. Three right-handed, normal subjects (59-68 years of age; 2 men and 1 woman) served as controls for a comparison to show normal brain activation during a unilateral hand grip task. This study was approved by the ethics committee of our hospital and informed consent was obtained from all subjects in accordance with the Declaration of Helsinki.

	Age Sex	H	Stroke location	PMH	day	fMRI activation
Palm brushing						
1	68M	L	R corona radiata	HT DM	28	N: L S1M1, L SMA, R Cbll P: R S1M1, R SMA
2	75M	L	R internal capsule	DM	39	N: L S1M1, L SMA P: R S1M1, R SMA, Blt IPC
3	63F	R	L corona radiata	HT DM HL	5	N: R S1M1 P: L S1M1, Blt SPC, R IPC
Passive movement						
4	85F	L	R internal capsule	HT HL	72	N: L S1M1 P: R S1M1
5	79M	R	L MCA cortex	HT HL af	13	N: L S1M1, R Cbll P: R S1M1
6	76M	L	R pons	DM HT	21	N: L S1M1, L SMA, R Cbll P: R S1M1

M = male; F = female; H = hemiparesis; R = right; L = left; MCA = middle cerebral artery; PMH = past medical history; HT = hypertension; DM = diabetes mellitus; HL = hyperlipidemia; af = atrial fibrillation; N = non-affected hand, P = paretic hand; S1M1 = primary sensorimotor cortex; SMA = supplementary motor areas; Cbll = cerebellum; Blt = bilateral; SPC = superior parietal cortex; IPC = inferior parietal cortex;

**Table 1.** Patient characteristics

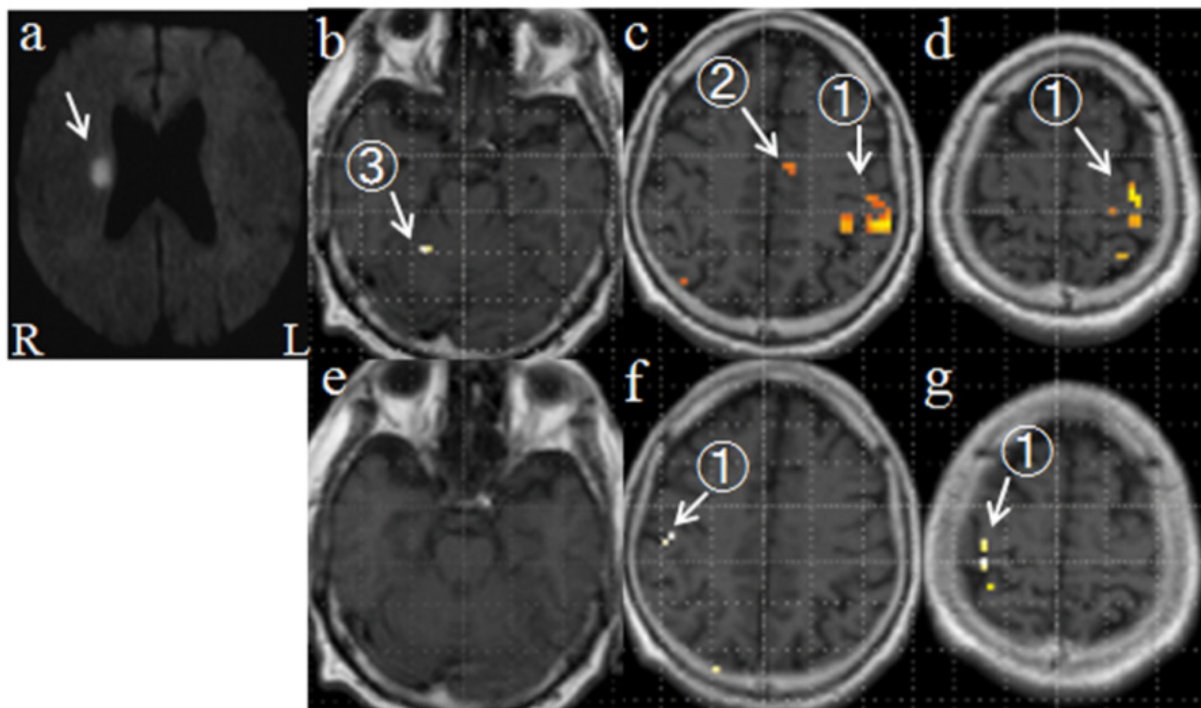
## 2.2. Functional MRI

The fMRI studies were performed using a 1.5 T Siemens Magnetom Symphony MRI scanner as described previously (Kato et al., 2002). Briefly, blood oxygenation level-dependent (BOLD) images were obtained continuously in a transverse orientation using a gradient-echo, single shot echo planar imaging pulse sequence. The acquisition parameters were as follows: repetition time 3 s, time of echo 50 ms, flip angle 90°, 3-mm slice thickness, 30 slices through the entire brain, field of view 192 x 192 mm, and 128 x 128 matrix. During the fMRI scan, the patients and normal controls received or performed a task as mentioned above. This task performance occurred in periods of 30 s, interspaced with 30 s rest periods. The cycle of rest and task was repeated 5 times during each hand study. Therefore, the fMRI scan of each hand study took 5 min to complete, producing 3,000 images. A staff member monitored the patient directly throughout the study, and gave the sensory stimulations or the start and stop signals of hand grip by tapping gently on the knee.

Data analysis was performed using Statistical Parametric Mapping (SPM) 2 (Wellcome Department of Cognitive Neurology, London, UK, <http://www.fil.ion.ucl.ac.uk/spm/>) implemented in MATLAB (The MathWorks Inc., Natick, MA, USA). After realignment and smoothing, the general linear model was employed for the detection of activated voxels. The voxels were considered as significantly activated if  $p < 0.05$  using the FWE analysis. All the measurements were performed with this same statistical threshold. The activation images were overlaid on corresponding T1-weighted anatomic images.

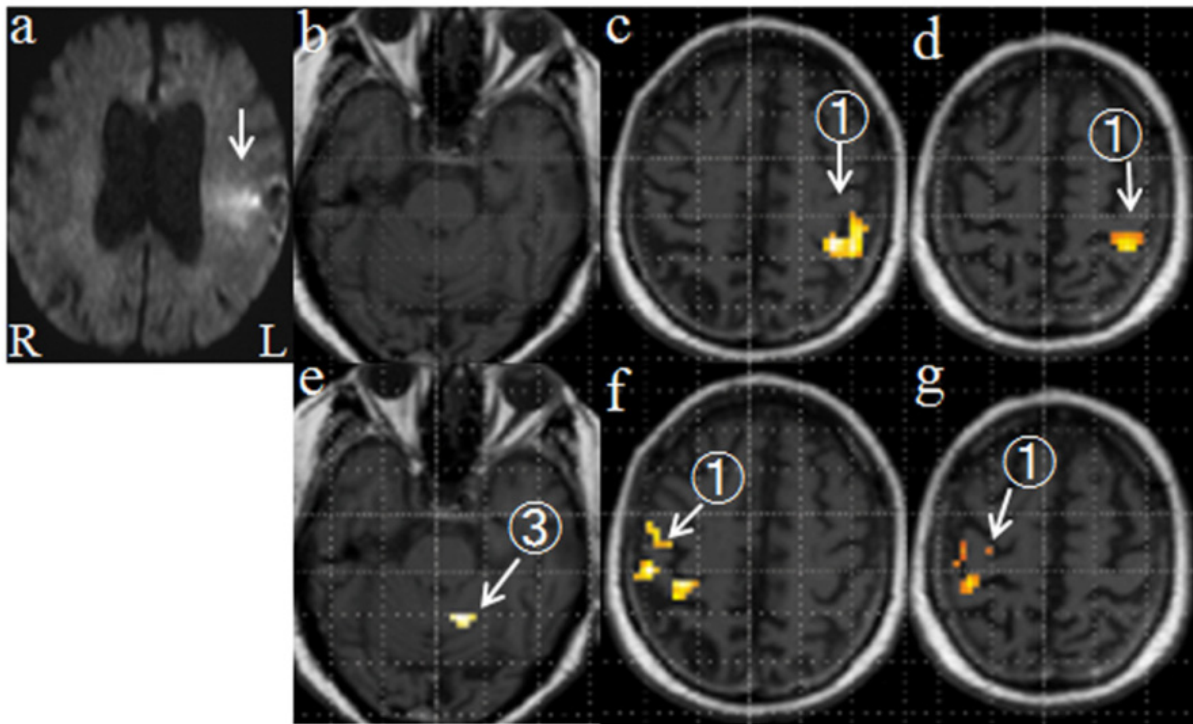
### 3. Results

Both tactile and proprioceptive inputs via the unaffected hand activated contralateral primary sensorimotor cortex (S1M1) in all the patients, and the supplementary motor areas (SMA) and the ipsilateral cerebellum in part of the patients (Table, Figs. 1 & 2). This activation pattern is similar to that activated during active hand movement (Fig. 3), although the activation was less extensive. Both tactile and proprioceptive inputs via the paretic hand also activated the contralateral S1M1 in all the patients, and in SMA and superior and inferior parietal cortices in part of the patients (Table, Figs. 1 & 2), although to a lesser extent as compared with unaffected hand. No cerebellar activation was observed when paretic hand was stimulated.

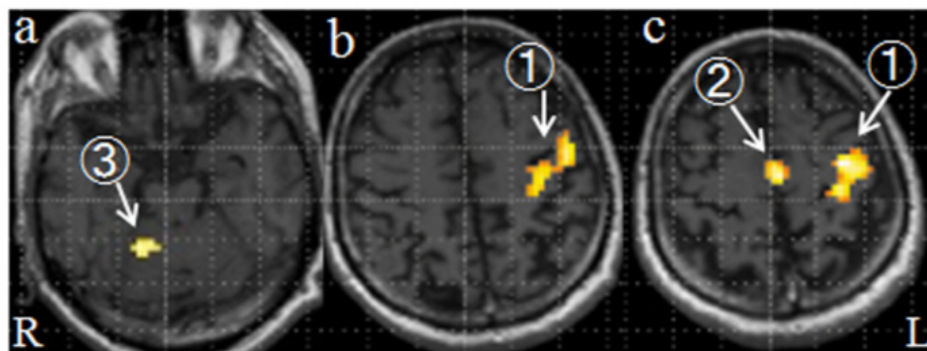


**Figure 1.** fMRI of a 68-year old man (patient 1) who had a cerebral infarct in the right corona radiata (arrow in a, diffusion-weighted MRI). After 28 days of stroke onset, palm brushing of the right (unaffected) hand (b-d) induced activation in the left primary sensorimotor cortex (1), the supplementary motor area (2), and right cerebellum (3). During palm brushing of the left (paretic) hand (e-g), activation in contralateral primary sensorimotor cortex (1) was seen, although less extensive, and no activation was seen in the supplementary motor areas and the cerebellum.





**Figure 2.** fMRI of a 79-year old man (patient 5) who had a cerebral infarct in part of the right middle cerebral artery territory (arrow in a, diffusion-weighted MRI). After 13 days of stroke onset, passive movement of the left (unaffected) hand (e-g) induced activation in the right primary sensorimotor cortex (1) and left cerebellum (3). During passive movement of the right (paretic) hand (b-d), activation in contralateral primary sensorimotor cortex (1) was observed.



**Figure 3.** fMRI of a 61-year old man (control). Active right hand movement (a-c) induced a normal activation pattern in the left primary sensorimotor cortex (1), supplementary motor areas (2) and right cerebellum (3).

## 4. Discussion

### 4.1. Activation of sensorimotor network by somatosensory input

The results demonstrated that somatosensory stimulation of the unaffected hand, both tactile and proprioceptive input, activated sensorimotor network in the brain, and that the activation pattern was similar to that induced by active hand movement. Somatosensory input to the paretic hand also activated the sensorimotor network in the brain, although to a

lesser degree. Of importance was that the activation involved not only postcentral S1 but also precentral M1, as observed in previous reports employing somatosensory stimulation as a task.

Passive movement studies have shown that brain activation during passive movement is seen in regions such as the contralateral sensorimotor cortex, the bilateral premotor cortex, supplementary motor areas, and inferior parietal cortex (Nelles et al., 1999; Loubinoux et al., 2003; Tombari et al., 2004). The similarity of activation patterns between passive and active hand movements highlights the contribution of afferent synaptic activity for central motor control, and suggests that the sensory systems play an important role in central motor control. Additional explanation may be that the repetitive sensory input induces motor imagery in the patients. Imagery of movement activates largely the same brain areas that are activated when movements are actually executed (Decety, 1996; Grezes & Decety 2001).

The brain activation during paretic hand sensory stimulation in this study was reduced as compared to that during unaffected hand sensory stimulation. This reduction may reflect the sensorimotor network damage caused by stroke, although the fMRI BOLD response could be reduced in the cerebral hemisphere of the lesion side (Murata et al., 2006; Mazzetto-Betti et al., 2010). Nevertheless, the result confirms the possibility of inducing sensorimotor transformations even in severely impaired stroke patients.

The observation of S1 and M1 activation during sensory input as well as active movement suggests that the sensorimotor network is functionally connected with each other. Actually, human motor and sensory hand cortices overlap, and are not divided in a simple manner by the central sulcus (McGlone et al., 2002; Morre et al., 2000; Nii et al., 1996). Furthermore, S1 and M1 are heavily interconnected (Jones et al., 1978) and both are the sites of origin of pyramidal tract neurons in the monkey (Fromm & Evarts, 1982). Proprioceptive afferents from the muscle spindles (fibers IA, II), along with the projections from other articular and cutaneous receptors (fibers I to IV), gain access not only to S1 but also to M1 in the monkey (Lemon, 1999; Lemon & Porter, 1976).

Previous studies have also demonstrated the activation of secondary sensorimotor areas induced by passive hand movements, as seen in our study. SMA has rich anatomical connections with many areas in the central nervous system, such as thalamus, dorsal premotor cortex (PMd), spinal cord, and contralateral hemisphere (Juergens, 1984; Rouiller et al., 1994; Dum & Strick, 1996; Dum & Strick, 2005), and may be an important source of descending commands for the generation and control of distal movements in the monkey (He et al., 1995). SMA is also involved in motor learning in man (Halsband & Lange, 2006). Therefore, SMA has been suggested to play a crucial role in the early processes of recovery after lesions of primary motor pathways (Loubinoux et al., 2003).

Ventral premotor cortex (PMv) receives strong projections from S1 (Stepniewska et al., 2006), and PMv neurons project onto cervical and thoracic motoneurons in the monkey (He et al., 1993; Rouiller et al., 1994). The PMv corticospinal neurons supply part of the hand function after M1 lesion in the monkey (Liu & Rouiller, 1999). Nudo and colleagues demonstrated rewiring from M1 to PMv after ischemic brain injury, with substantial

enlargements of the hand representation in the remote PMv that are proportional to the amount of hand representation destroyed in M1 (Frost et al., 2003; Dancause et al., 2005). Nelles et al. (2001) pointed out the crucial role of a network including the lower part of BA40 and PMv, bilaterally, in task-oriented passive training aimed at improving motor recovery in severely impaired stroke patients. These areas could also be crucial for promoting reorganization in the rest of the brain.

#### **4.2. Activation of sensorimotor network by active motor task**

Previous functional neuroimaging studies on poststroke cerebral reorganization from acute to chronic stages revealed several activation patterns during active paretic hand movement (Ward & Cohen, 2004; Jang, 2007; Kato & Izumiyama, 2010). These include (1) a posterior shift of contralateral S1M1 activation (Pineiro et al., 2001; Calautti et al., 2003), (2) perinfarct reorganization after infarction involving M1 (Cramer et al., 1997; Jang et al., 2005a), (3) a shift of M1 activation to the ipsilateral (contralesional) cortex (Chollet et al., 1991; Marshall et al., 2000; Feydy et al., 2002), (4) contribution of the secondary motor areas (Cramer et al., 1997; Carey et al., 2002; Ward et al., 2006), and (5) higher contralateral activity in the cerebellar hemisphere (Small et al., 2002).

These studies have also shown that the expanded activations may later decrease with functional improvements, indicating that best recovery is obtained when there is restitution of activation toward the physiological network over time. The contralesional shift of activation may return to ipsilesional S1M1 activation with functional gains (Feydy et al., 2002; Takeda et al., 2007), but worse outcome may correlate with a shift in the balance of activation toward the contralesional S1M1 (Calautti et al., 2001; Feydy et al., 2002; Zemke et al., 2003). Thus, the patterns of cerebral activation evoked by active hand movement show impaired organization and reorganization of brain sensorimotor network, and best recovery may depend on how much original motor system is reusable. The patterns of activation may also be dependent on the patient's ability to recruit residual portions of the bilateral motor network (Silvestrini et al., 1998).

Early involvement of secondary sensorimotor areas after M1 lesion may temporarily substitute for the original sensorimotor network involving M1. This step may be a prerequisite to M1 functional reconnection through indirect pathways and to its efficacy in processing motor signals. The previous data suggest that different motor areas operate in parallel rather than in a hierarchical manner, and they are able to substitute for each other (Traversa et al., 1997; Loubinoux et al., 2003). Thus, remodeling of activation within a pre-existing network may be an important process for recovery.

#### **4.3. Implication of somatosensory input as a rehabilitation strategy**

There is consensus on the efficacy of physiotherapy. Active training is more efficient than passive training, but active training cannot be applied to very impaired patients. We need to consider other approaches for patients who cannot move the paretic limbs at the early phase of recovery. Physiotherapists apply sensory stimulation and passive movement daily to



acute stroke patients and only these approaches are possible when the patients have complete paralysis. A few studies have validated the efficacy of sensory or proprioceptive stimulation on motor recovery.

Carel et al. (2000) have shown that proprioceptive training induces a reorganization of sensorimotor representation in healthy subjects, and that the anatomical substrates are SMA and S1M1 contralateral to the stimulation. Subsequently, Dechaumont-Palacin et al. (2008) showed that paretic wrist proprioceptive training produced change in SMA, premotor cortex, and a contralesional network including inferior parietal cortex (lower part of BA 40), secondary sensory cortex, and PMv. Thus, increased contralateral activity in secondary sensorimotor areas may facilitate control of recovered motor function by simple proprioceptive integration in severely impaired patients. Brain activation during passive movement increase with time after stroke (Nelles et al., 1999; Loubinoux et al., 2003; Tombari et al., 2004). Nelles et al. (2001) tested a mixed, task-oriented rehabilitative program that is at first passive, then active as recovery permits, and observed hyperactivation of the bilateral low parietal cortex and premotor cortex and a smaller hyperactivation of the ipsilateral M1. Thus, the changes might represent increased processing of sensory information relevant to motor output.

Somatosensory input to the motor cortex, via corticocortical connections with the somatosensory cortex, is important for learning new motor skills (Sakamoto et al., 1989; Pavlides et al., 1993; Vidoni et al., 2010). Somatosensory input may also play a critical role in motor relearning after hemiparetic stroke (Dechaumont-Palacin et al., 2008; Conforto et al., 2007; Vidoni et al., 2009). Schaechter et al. (2012) showed that increased responsiveness of the ipsilesional S1M1 to tactile stimulation over the subacute poststroke period correlated with concurrent motor recovery and predicted motor recovery experienced over the year. This finding suggests that a strong link between change in processing of somatosensory information in the S1M1 during the early poststroke period and motor recovery in hemiparetic patients.

Muscular and peripheral nerve electrical stimulation increases motor output after stroke (Conforto et al., 2002; Kimberley et al., 2004; Wu et al., 2006; Conforto et al., 2010). Peripheral nerve stimulation increases corticomotoneuronal excitability (Kaelin-Lang et al., 2002; Ridding et al., 2000), and activation of S1M1 and PMd in healthy subjects (Wu et al., 2005). If applied to paretic hand of stroke patients paired with motor training, electrical nerve stimulation may enhance training effects on corticomotoneuronal plasticity in stroke patients (Sawaki et al., 2006; Yozbatiran et al., 2006; Celnik et al., 2007).

Thus, increased activity in brain sensorimotor network by somatosensory input may facilitate control of recovered motor function by operating not only at a high-order processing level but also at a low level of simple sensory integration. Therefore, early post-stroke fMRI studies using sensory stimulation as a task may be of great clinical importance and somatosensory stimulation over the poststroke recovery period may form a basis for improving motor recovery in stroke patients.

Another merit of massage or touch therapy may be the psychological effects produced by tactile stimulation, such as relaxation, alleviation of anxiety and depression. These effects may be evoked by stimulation of dopamine and serotonin secretion since increased levels of dopamine and serotonin have been shown in the urine following tactile skin stimulation (Field et al., 2005). Tactile stimulation in the rat evokes an increased dopamine release in the nucleus accumbens of the brain, which is thought to play a key role in motivational and reward processes (Maruyaka et al.; 2012). Relieving anxiety and depression seems important in the early steps of rehabilitation for patients with acute stroke.

## 5. Conclusion

The findings of this study demonstrate that the somatosensory inputs via the normal hand can activate brain sensorimotor network to a comparable extent with the areas that are activated during active hand movement, and that the somatosensory inputs via the paretic hand at the early stages of stroke before clinical motor recovery can also induce activities to some of the brain sensorimotor network. The result suggests that physiotherapy that employs somatosensory input via the paretic hand may be used as a first step to activate rehabilitation-dependent changes in the motor network in the brain toward restoration of motor function. The result may provide new insight into the establishment of rehabilitation strategies after stroke.

## Author details

Hiroyuki Kato

*Department of Neurology, International University of Health and Welfare Hospital, Nasushiobara, Japan*

Masahiro Izumiyama

*Department of Neurology, Sendai Nakae Hospital, Sendai, Japan*

## Acknowledgement

We thank the staff members of the MRI section of Sendai Nakae Hospital, Ms. Fumi Kozuka, Ms. Satsuki Ohi, Mr. Takeru Ohmukai, Ms. Yoko Sato, Ms. Aya Kanai, and Mr. Katsuhiro Aki, for their help to perform fMRI studies. We also thank Dr. Naohiro Saito, Department of Physiology, Tohoku University School of Medicine, Sendai, Japan, for his expert assistance on the fMRI-spm analysis. This study was supported by Grant-in-Aid for Scientific Research (22500473), Japan Society for the Promotion of Science.

## 6. References

Cao, Y.; D'Olhaberriague, L.; Vikingstad, E.M.; Levine, S.R. & Welch, K.M.A. (1998). Pilot study of functional MRI to assess cerebral activation of motor function after poststroke hemiparesis. *Stroke*, 29, 112-122.

- Calautti, C. & Baron, J.-C. (2003). Functional neuroimaging studies of motor recovery after stroke in adults. A review. *Stroke*, 34, 1553-1566
- Calautti, C.; Leroy, F.; Guincestre, J.Y. & Baron, J.-C. (2001). Dynamics of motor network overactivation after striatocapsular stroke: a longitudinal PET study using a fixed-performance paradigm. *Stroke*, 32, 2534-2542
- Carel, C.; Loubinoux, I.; Boulanouar, K.; Manelfe, C.; Rascol, O.; Celsis, P. & Chollet, F. (2000). Neural substrate for the effects of passive training on sensorimotor cortical representation: a study with functional magnetic resonance imaging in healthy subjects. *J. Cereb. Blood Flow Metab.*, 20, 478-484
- Carey, J.R.; Kimberley, T.J.; Lewis, S.M.; Auerbach, E.J.; Dorsey, L.; Rundquist, P. & Ugurbil, K. (2002). Analysis of fMRI and finger tracking training in subjects with chronic stroke. *Brain*, 125, 773-788
- Celnik, P.; Hummel, F.; Harris-Love, M.; Wolk, R. & Cohen, L.G. (2007). Somatosensory stimulation enhances the effects of training functional hand tasks in patients with chronic stroke. *Arch. Phys. Med. Rehabil.*, 88, 1369-1376
- Chollet, F.; DiPiero, V.; Wise, R.J.S.; Brooks, D.J.; Dolan, R.J. & Fracowiak, R.S.J. (1991). The functional anatomy of motor recovery after stroke in humans: a study with positron emission tomography. *Ann. Neurol.*, 29, 63-71
- Conforto, A.B.; Cohen, L.G.; dos Santos, R.L.; Scaff, M. & Marie, S.K. (2007). Effects of somatosensory stimulation on motor function in chronic cortico-subcortical strokes. *J. Neurol.*, 254, 333-339
- Conforto, A.B.; Ferreiro, K.N.; Tomasi, C.; dos Santos, R.L.; Moreira, V.L.; Marie, S.K.; Baltieri, S.C.; Scaff, M. & Cohen, L.G. (2010). Effects of somatosensory stimulation on motor function after subacute stroke. *Neurorehabil. Neural Repair*, 24, 263-272
- Conforto, A.B.; Kaelin-Lang, A. & Cohen, L.G. (2002). Increase in hand muscle strength of stroke patients after somatosensory stimulation. *Ann. Neurol.*, 51, 122-125
- Cramer, S.C.; Nelles, G.; Benson, R.R.; Kaplan, J.D.; Parker, R.A.; Kwong, K.K.; Kennedy, D.N.; Finklestein, S.P. & Rosen, B.R. (1997). A functional MRI study of subjects recovered from hemiparetic stroke. *Stroke*, 28, 2518-2527
- Dancause, N.; Barbay, S.; Frost, S.B.; Plautz, E.J.; Chen, D.; Zoubina, E.V.; Stowe, A.M. & Nudo, R.J. (2005). Extensive cortical rewiring after brain injury. *J. Neurosci.*, 25, 10167-10179
- Decety, J. (1996). The neurophysiological basis of motor imagery. *Behav. Brain Res.*, 77, 45-52
- Dechaumont-Palacin, S.; Marque, P.; De Boissezon, X.; Castel-Lacanal, E.; Carel, C.; Berry, I.; Pastorm, J.; Albucher, J.F.; Chollet, F. & Loubinoux, I. (2008). Neural correlates of proprioceptive integration in the contralesional hemisphere of very impaired patients shortly after a subcortical stroke: an fMRI study. *Neurorihab. Neural Repair*, 22, 154-165
- Dum, R.P. & Strick, P.L. (1996). Spinal cord terminations of the medial wall motor areas in macaque monkeys. *J. Neurosci.*, 16, 6513-6525
- Dum, R.P. & Strick, P.L. (2005). Frontal lobe inputs to the digit representations of the motor areas on the lateral surface of the hemisphere. *J. Neurosci.*, 25, 1375-1386

- Duncan, P.W.; Goldstein, L.B.; Matchar, D.; Divine, G.W. & Feussner, J. (1992). Measurement of motor recovery after stroke: outcome measures and sample size requirements. *Stroke*, 23, 1084-1089
- Feydy, A.; Carlier, R.; Rody-Brami, A.; Bussel, B.; Cazalis, F.; Pierot, L.; Burnod, Y. & Maier, M.A. (2002). Longitudinal study of motor recovery after stroke: recruitment and focusing of brain activation. *Stroke*, 33, 1610-1617
- Field, T.; Hernandez-Reif, M.; Diego, M.; Schanberg, S. & Kuhn, C. (2005). Cortisol decreases and serotonin and dopamine increase following massage therapy. *Int. J. Neurosci.*, 115, 1397-1413
- Fromm, C. & Evarts, E.V. (1982). Pyramidal tract neurons in somatosensory cortex: central and peripheral inputs during voluntary movement. *Brain Res.*, 238, 186-191
- Frost, S.B.; Barbay, S.; Friel, K.M.; Plautz, E.J. & Nudo, R.J. (2003). Reorganization of remote cortical regions after ischemic brain injury: a potential substrate for stroke recovery. *J. Neurophysiol.*, 89, 3205-3214
- Grezes, J. & Decety, J. (2001). Functional anatomy of execution, mental simulation, observation, and verb generation of actions: a meta-analysis. *Hum. Brain Mapp.*, 12, 1-19
- Halsband, U. & Lange, R.K. (2006). Motor learning in man: a review of functional and clinical studies. *J. Physiol. Paris*, 99, 414-424
- He, S.Q.; Dum, R.P. & Strick, P.L. (1995). Topographic organization of corticospinal projections from the frontal lobe: motor areas on the medial surface of the hemisphere. *J. Neurosci.*, 15, 1284-3306
- Herholz, A. & Heiss, W.-D. (2000). Functional imaging correlates of recovery after stroke in humans. *J. Cereb. Blood Flow Metab.*, 20, 1619-1631
- Jang, S.H. (2007). A review of motor recovery mechanisms in patients with stroke. *Neurorehabilitation*, 22, 253-259
- Jang, S.H.; Ahn, S.H.; Yang, D.S.; Lee, D.K.; Kim, D.K. & Son, S.M. (2005). Cortical reorganization of hand motor function to primary sensory cortex in hemiparetic patients with a primary motor cortex infarct. *Arch. Phys. Med. Rehabil.*, 86, 1706-1708
- Jones, E.G.; Coulter, J.D. & Hendry, S.H. (1978). Intracortical connectivity of architectonic fields in the somatic sensory, motor and parietal cortex of monkeys. *J. Comp. Neurol.*, 181, 291-347
- Juergens, U. (1984). The efferent and afferent connections of the supplementary motor area. *Brain Res.*, 300, 63-81
- Kaelin-Lang, A.; Luft, A.R.; Sawaki, L.; Burstein, A.H.; Sohn, Y.H. & Cohen, L.G. (2002). Modulation of human corticomotor excitability by somatosensory input. *J. Physiol.*, 540(Pt 2), 623-633
- Kato, H. & Izumiyama, M. (2010). Restorative and compensatory changes in the brain during early motor recovery from hemiparetic stroke: a functional MRI study, Neuroimaging, Cristina Marta Del-Ben (Ed.), ISBN: 978-953-307-127-5, Sciyo, Available from: <http://sciyo.com/articles/show/title/restorative-and-compensatory-changes-in-the-brain-during-early-motor-recovery-from-hemiparetic-stroke>

- Kato, H.; Izumiyama, M.; Koizumi, H.; Takahashi, A. & Itoyama, Y. (2002). Near-infrared spectroscopic topography as a tool to monitor motor reorganization after hemiparetic stroke. A comparison with functional MRI. *Stroke*, 33, 2032-2036
- Kimberley, T.J.; Lewis, S.M.; Auerbach, E.J.; Dorsey, L.L.; Lojovich, J.M. & Carey, J.R. (2004). Electrical stimulation driving functional improvements and cortical changes in subjects with stroke. *Exp. Brain Res.*, 154, 450-460
- Lemon, R.N. (1999). Neural control of dexterity: what has been achieved? *Exp. Brain Res.*, 128, 6-12
- Lemon, R.N. & Porter, R. (1976). Afferent input to movement-related precentral neurons in conscious monkeys. *Proc. R. Soc. Lond. B. Biol. Sci.*, 194, 313-339
- Liu, Y. & Rouiller, E.M. (1999). Mechanisms of recovery of dexterity following unilateral lesion of the sensorimotor cortex in adult monkeys. *Exp. Brain Res.*, 128, 149-159
- Loubinoux, I.; Carel, C.; Pariente, J.; Dechaumont, S.; Albucher, J.-F.; Marque, C. & Chollet, F. (2003). Correlation between cerebral reorganization and motor recovery after subcortical infarcts. *Neuroimage*, 20, 2166-2180
- McGlone, F.; Kelly, E.F.; Trusson, M.; Francis, S.T.; Westling, G. & Bowtell, R. (2002). Functional neuroimaging studies of human somatosensory cortex. *Behav. Brain Res.*, 135, 147-158
- Marshall, R.S.; Perera, G.M.; Lazar, R.M.; Krakauer, J.W.; Constantine, R.C. & DeLaPaz, R.L. (2000). Evolution of cortical activation during recovery from corticospinal tract infarction. *Stroke*, 31, 656-661
- Maruyama, K.; Shimojo, R.; Ohkubo, M.; Maruyama, H. & Kurosawa, M. (2012). Tactile skin stimulation increases dopamine release in the nucleus accumbens in rats. *J. Physiol. Sci.*, 62, 259-266
- Mazzetto-Betti, K.C.; Leoni, R.F.; Pontes-Neto, O.M.; Santos, A.C.; Leite, J.P.; Silva, A.C. & de Araujo, D.B. (2010). The stability of the BOLD fMRI response to motor tasks is altered in patients with chronic ischemic stroke. *Stroke*, 41, 1921-1926
- Moore, C.I.; Stern, C.E.; Corkin, S.; Fischl, B.; Gray, A.C.; Rosen, B.R. & Dale, A.M. (2000). Segregation of somatosensory activation in the human rolandic cortex using fMRI. *J. Neurophysiol.*, 84, 558-569
- Murata, Y.; Sakatani, K.; Hoshino, T.; Fujiwara, N.; Kano, T.; Nakamura, S. & Katayama, Y. (2006). Effects of cerebral ischemia on evoked cerebral blood oxygenation responses and BOLD contrast functional MRI in stroke patients. *Stroke*, 37, 2514-2520
- Nelles, G.; Jentzen, W.; Jueptner, M.; Mueller, S. & Diener, H.C. (2001). Arm training induced brain plasticity in stroke studied with serial positron emission tomography. *Neuroimage*, 13, 1146-1154
- Nelles, G.; Spiekermann, G.; Jueptner, M.; Leonhardt, G.; Mueller, S.; Gerhard, H. & Diener, C. (1999). Reorganization of sensory and motor systems in hemiplegic stroke patients. A positron emission tomography study. *Stroke*, 30, 1510-1516
- Nii, Y.; Uematsu, S.; Lesser, R.P. & Gordon, B. (1996). Does the central sulcus divide motor and sensory functions? Cortical mapping of human hand areas as revealed by electrical stimulation through subdural grid electrodes. *Neurology*, 46, 360-367



- Pavlidis, C.; Miyashita, E. & Asanuma, H. (1993). Projection from the sensory to the motor cortex is important in learning motor skills in the monkey. *J. Neurophysiol.*, 70, 733-741
- Pineiro, R.; Pendlebury, S.; Johansen-Berg, H. & Matthews, P.M. (2001). Functional MRI detects posterior shifts in primary sensorimotor cortex activation after stroke. Evidence of local adaptive reorganization? *Stroke*, 32, 1134-1139
- Ridding, M.C.; Brouwer, B.; Miles, T.S.; Pitcher, J.B. & Thompson, P.D. (2000). Changes in muscle responses to stimulation of the motor cortex induced by peripheral nerve stimulation in human subjects. *Exp. Brain Res.*, 131, 135-143
- Rossini, P.M.; Calautti, C.; Pauri, F. & Baron, J.C. (2003). Post-stroke plastic reorganization in the adult brain. *Lancet Neurol.*, 2, 493-502
- Rouiller, E.M.; Babalian, A.; Kazennikov, O.; Moret, V.; Yu, X.H. & Wiesendanger, M. (1994). Transcallosal connections of the distal forelimb representations of the primary and supplementary motor cortical areas in macaque monkeys. *Exp. Brain Res.*, 102, 227-243
- Sakamoto, T.; Arissian, K. & Asanuma, H. (1989). Functional role of the sensory cortex in learning motor skills in cats. *Brain Res.*, 503, 258-264
- Sawaki, L.; Wu, C.W.; Kaelin-Lang, A. & Cohen, L.G. (2006). Effects of somatosensory stimulation on use-dependent plasticity in chronic stroke. *Stroke*, 37, 246-247
- Schaechter, J.D.; van Oers, C.A.; Groisser, B.N.; Salles, S.S.; Vangel, M.G.; Moore, C.I. & Dijkhuizen, R.M. (2012). Increase in sensorimotor cortex response to somatosensory stimulation over subacute poststroke period correlates with motor recovery in hemiparetic patients. *Neurorehabil. Neural Repair*, 26, 325-334
- Silvestrini, M.; Cupini, L.M.; Placidi, F.; Diomedì, M. & Bernardi, G. (1998). Bilateral hemispheric activation in the early recovery of motor function after stroke. *Stroke*, 29, 1305-1310
- Small, A.L.; Hlustik, P.; Noll, D.C.; Genovese, C. & Solodkin, A. (2002). Cerebellar hemispheric activation ipsilateral to the paretic hand correlates with functional recovery after stroke. *Brain*, 125, 1544-1557
- Stepniewska, I.; Preuss, T.M. & Kaas, J.H. (2006). Ipsilateral cortical connections of dorsal and ventral premotor areas in New World owl monkeys. *J. Comp. Neurol.*, 495, 691-708
- Takeda, K.; Gomi, Y.; Imai, I.; Shimoda, N.; Hiwatari, M. & Kato, H. (2007). Shift of motor activation areas during recovery from hemiparesis after cerebral infarction: a longitudinal study with near-infrared spectroscopy. *Neurosci. Res.*, 59, 136-144
- Tombari, D.; Loubinoux, I.; Pariente, J.; Gerdolat, A.; Albucher, J.-F.; Tardy, J.; Cassol, E. & Chollet, F. (2004). A longitudinal fMRI study: in recovering and then in clinically stable subcortical stroke patients. *Neuroimage*, 23, 827-839
- Traversa, R.; Cicinelli, P.; Bassi, A.; Rossini, P.M. & Bernardi, G. (1997). Mapping of motor cortical reorganization after stroke. A brain stimulation study with focal magnetic pulses. *Stroke*, 28, 110-117
- Vidoni, E.D.; Acerra, N.E.; Dao, E.; Meehan, S.K. & Boyd, L.A. (2010). Role of the primary somatosensory cortex in motor learning: An rTMS study. *Neurobiol. Learn. Mem.*, 93, 532-539
- Vidoni, E.D. & Boyd, L.A. (2009). Preserved motor learning after stroke is related to the degree of proprioceptive deficit. *Behav. Brain Funct.*, 5, 36

- Ward, N.S.; Brown, M.M.; Thompson, A.J. & Frackowiak, R.S.J. (2003a). Neural correlates of outcome after stroke: a cross-sectional fMRI study. *Brain*, 126, 1430-1448
- Ward, N.S.; Brown, M.M.; Thompson, A.J. & Frackowiak, R.S.J. (2003b). Neural correlates of motor recovery after stroke: a longitudinal fMRI study. *Brain*, 126, 2476-2496
- Ward, N.S. & Cohen, L.G. (2004). Mechanisms underlying recovery of motor function after stroke. *Arch. Neurol.*, 61, 1844-1848
- Ward, N.S.; Newton, J.M.; Swayne, O.B.; Lee, L.; Thompson, A.J.; Greenwood, R.J.; Rothwell, J.C. & Frackowiak, R.S. (2006). Motor system activation after subcortical stroke depends on corticospinal system integrity. *Brain*, 129(Pt. 3), 809-819
- Weiller, C.; Chollet, F.; Fristo, K.J.; Wise, R.J. & Frackowiak, R.S. (1992). Functional reorganization of the brain in recovery from striatocapsular infarction in man. *Ann. Neurol.*, 315, 463-472
- Wu, C.W.; Seo, H.J. & Cohen, L.G. (2006). Influence of electric somatosensory stimulation on paretic-hand function in chronic stroke. *Arch. Phys. Med. Rehabil.*, 87, 351-357
- Wu, C.W.; van Gelderen, P.; Hanakawa, T.; Yaseen, Z. & Cohen, L.G. (2005). Enduring representational plasticity after somatosensory stimulation. *Neuroimage*, 27, 872-884
- Yozbtiran, N.; Donmez, B.; Kayak, N. & Bozan, O. (2006). Electrical stimulation of wrist and fingers for sensory and functional recovery in acute hemiplegia. *Clin. Rehabil.*, 20, 4-11
- Zemke, A.C.; Heagerty, P.J.; Lee, C. & Cramer, S.C. (2003). Motor cortex organization after stroke is related to side of stroke and level of recovery. *Stroke*, 34, e23-28