

We are IntechOpen, the world's leading publisher of Open Access books Built by scientists, for scientists

6,900

Open access books available

186,000

International authors and editors

200M

Downloads

Our authors are among the

154

Countries delivered to

TOP 1%

most cited scientists

12.2%

Contributors from top 500 universities



WEB OF SCIENCE™

Selection of our books indexed in the Book Citation Index
in Web of Science™ Core Collection (BKCI)

Interested in publishing with us?
Contact book.department@intechopen.com

Numbers displayed above are based on latest data collected.
For more information visit www.intechopen.com



High-Dose-Rate Interstitial Brachytherapy as Monotherapy in One Fraction for the Treatment of Favorable Stage Prostate Cancer

Pedro J. Prada

Additional information is available at the end of the chapter

<http://dx.doi.org/10.5772/51758>

1. Introduction

Low dose rate (LDR) brachytherapy has rapidly gained popularity in the USA [1, 2] and Europe [3, 4] as an accepted, effective and safe therapy for localized prostate cancer. Many reports are now available which confirm good outcomes in selected patients with PSA relapse-free survivals that are equivalent to those achieved by surgery.

The potential for a therapy that is equally efficient but less harmful than other interventions is especially attractive for patients with early prostate cancer.

On the other hand, treatment with temporary high dose rate (HDR) brachytherapy with ¹⁹²Ir as monotherapy has a number of advantages compared to LDR. The overall treatment time is decreased from many months with LDR to several minutes with HDR. Besides, HDR improves the dose distribution because of the possibility of accurately controlling the source and vary the source dwell time during treatment. The intraoperative optimization used with HDR allows better source position targeting with the potential for limiting toxicity. There are also advantages in radiation safety for both staff and patient who leave the treatment room without any radioactive implants.

The purpose of this chapter was to determine the possibility to treat patients with favorable stage prostate cancer (5, 6) with HDR monotherapy in one fraction and transperineal hyaluronic acid injection into the perirectal fat.

2. Brachytherapy implant characteristics

Patients received one implant and one fraction of HDR. Fraction dose is 20.5 Gy because it is considered to correspond biologically (biologic effective dose) to > 90 Gy administered at 2 Gy/fraction according to the linear quadratic model, assuming an α/β of 1.2 Gy (7, 8, 9, 10).

Brachytherapy procedure is done under spinal anesthesia with the patient in the lithotomy position (Fig. 1). A Foley catheter is placed, and the bladder is partially filled with 100 cm³ of sterile water. The needles are positioned (Fig. 2) by transperineal placement under real time TRUS guidance using a template. Axial cross-sections is captured in 5mm steps and transferred to the Treatment Planning Software. Prostate gland, normal structures (urethra and rectum) and needle positions are identified and mapped based on the ultrasound image. Dose optimization is done on the reconstructed applicator geometry using dose point and manual optimization algorithms to determine dwell positions and times (Fig. 3).

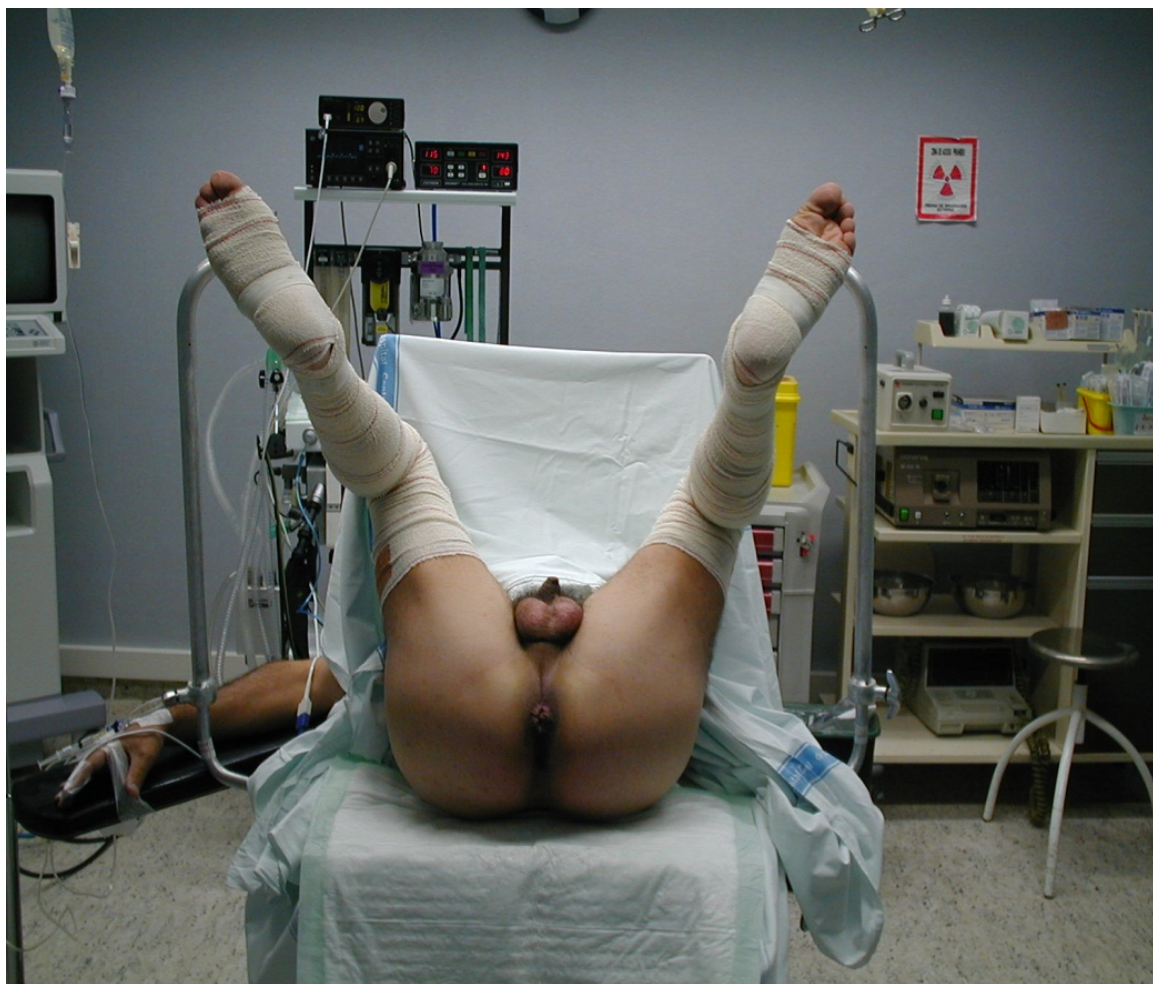

Figure 1. Lithotomy position

IntechOpen

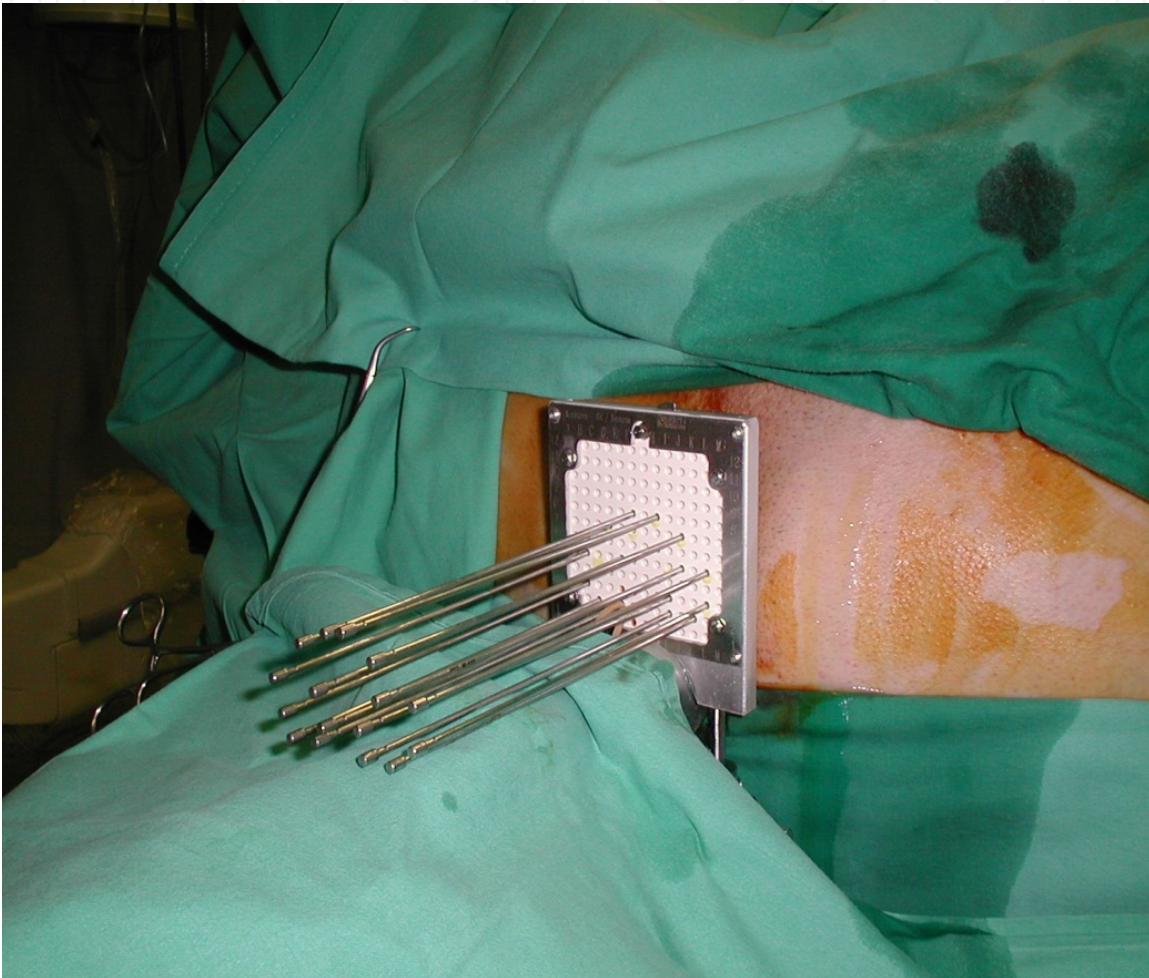


Figure 2. The needles are positioned

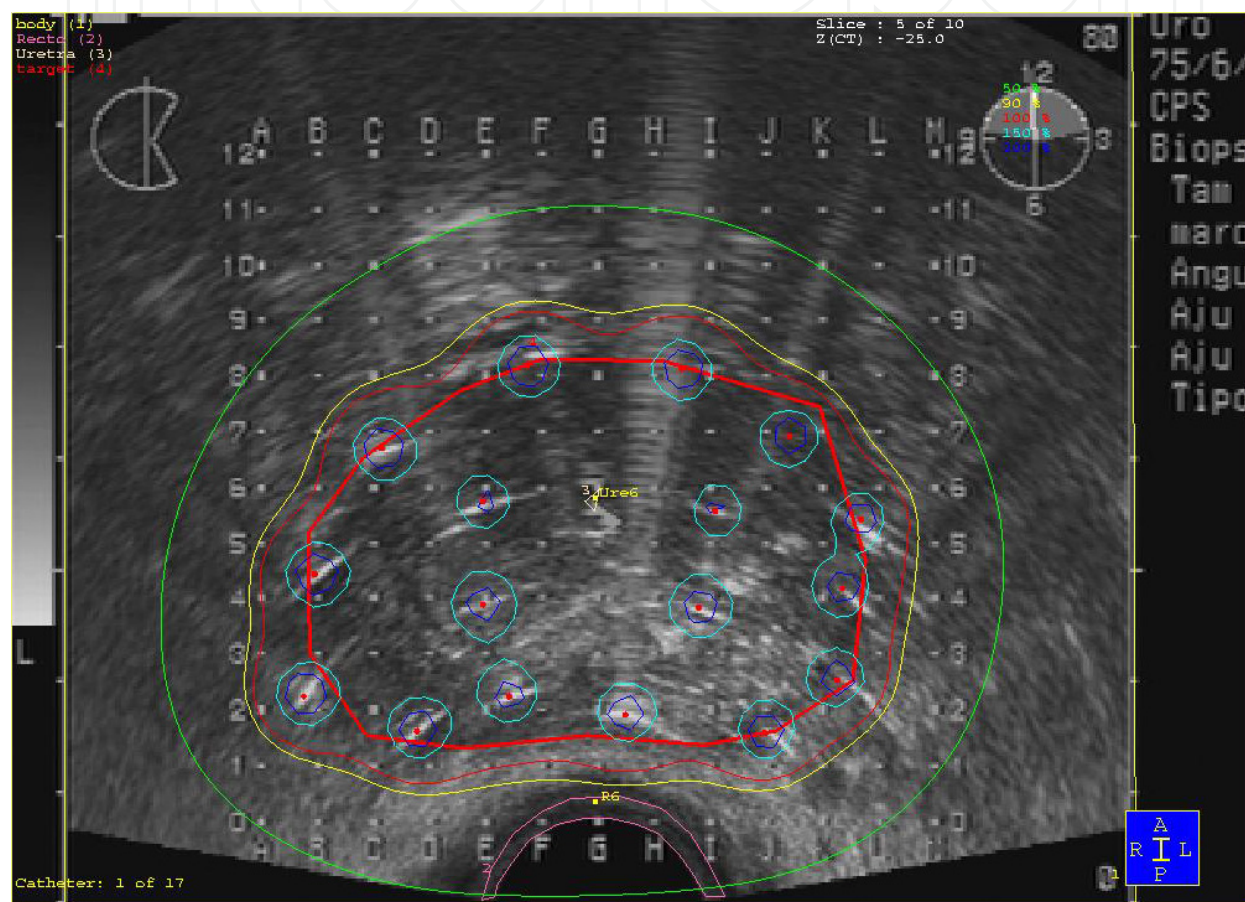


Figure 3. Dose optimization

The prostate without safety margins is then defined as the planning target volume (PTV) to be treated (Fig. 4) with the prescribed dose (PD).

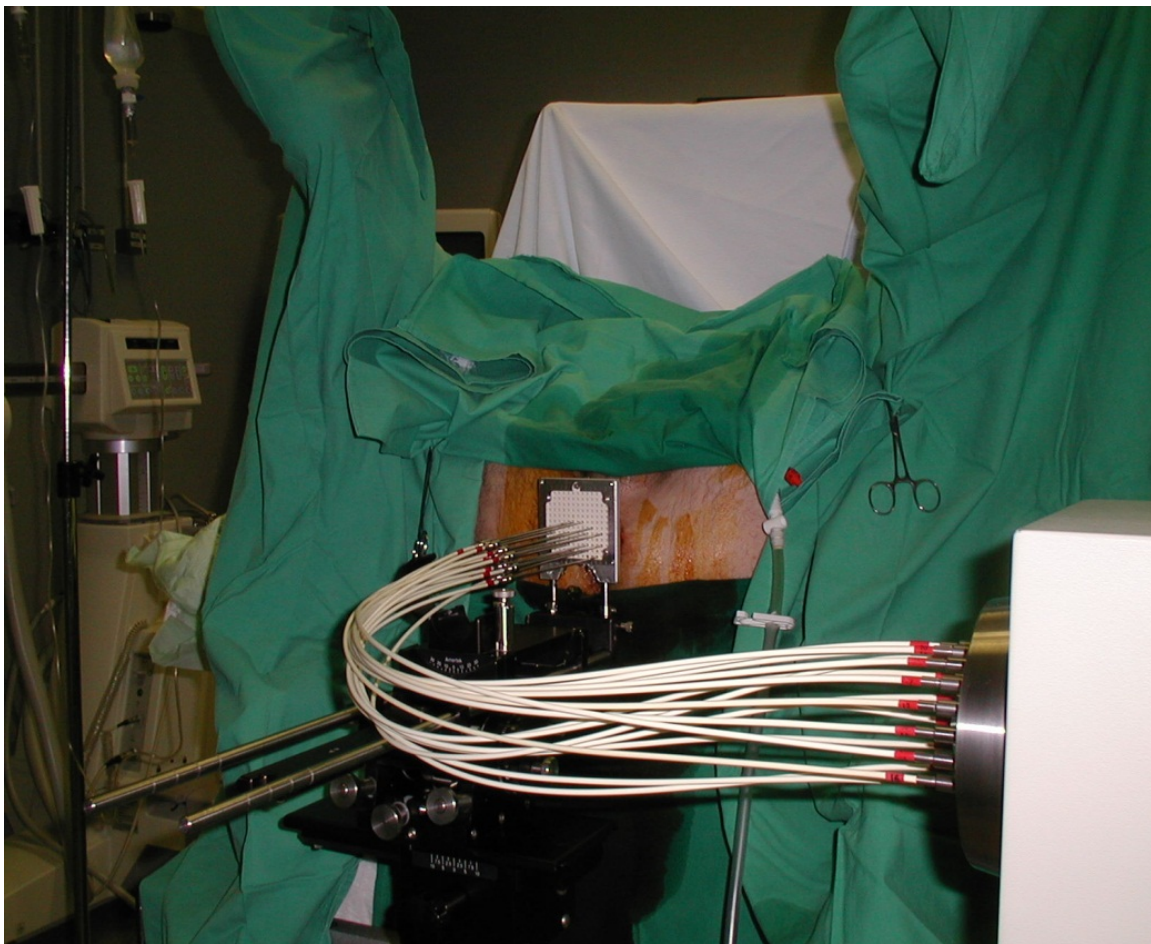


Figure 4. Treatment

Based on the dose volume histograms (DVH) data, the quality of plans and implants is evaluated using following indicators:

- The rectal dose is calculated at the anterior edge of the TRUS probe and is limited to $\leq 75\%$ of the prescription dose.
- The dose to any segment of the urethra is limited to $\leq 110\%$ of the prescription dose. V120 and D100 of the prostatic urethra are determined (volume that received a dose of 120% and dose delivered to 100% of the urethra).
- The PTV V90, V100, V150 and V200 (% of PTV receiving 90%, 100%, 150% and 200% of the PD) are recorded.
- D90 (dose delivered to 90% of the PTV) is calculated.

All patients are discharged from the center on the same day of the procedure between 6-8 hours of implantation.

To decrease rectal toxicity, transperineal hyaluronic acid (HA) injection into the peri-rectal fat is used to consistently displace the rectal wall away from the radiation sources in all patients. We believe that the increase in distance (mean 2 cm along the length of the

prostate) will be enough to provide a significant radiation dose reduction from HDR brachytherapy [11, 12].

3. Hyaluronic acid

The Hyaluronic acid (HA) is a polysaccharide normally found in human tissues as a component of the connective tissue. Normally, it plays a vital role on the skin and in the synovial fluid of the joints. It is normally degradable by the normal enzymatic system in relative short time. However, to make it last for months when used for the treatment of skin wrinkles and osteoarthritis, the compound is modified making it stable for duration close to 1 year before it is reabsorbed by the body. Only one type of HA is used in our Department (Restylane sub-Q).

The total injected amount is related to the need for systematically creating a minimum of a 2 cm space between the prostate and rectum throughout this length. Usually, we use between 6 and 8 cc per patient

4. Technique of hyaluronic acid injection

The injection technique of HA in the perirectal fat occurs before all needles are in treatment position according to the following procedure.

- Step 1. The transrectal ultrasound (TRUS) probe with the transperineal template is placed and fixed in the standard fashion.
- Step 2. Using TRUS guidance, the needle tip is placed in the perirectal fat (Fig. 5), between the posterior prostate capsule and the anterior rectal wall, at the level of the maximum transverse diameter of the prostate (reference level). Then under direct TRUS guidance, the needle tip is advanced to the level of the seminal vesicles.
- Step 3. The needle is connected to the syringe containing of HA. After aspirating to be certain that we are not in a vessel, we proceed to inject between 6 and 8 cc within the space between the seminal vesicles and the apex of the prostate. This is performed under TRUS guidance to see and verify the new space created by the injection of HA (Fig. 6). The total injected amount allows us to create the new space >2 cm.
- Step 4. The needle is removed and all needles treatment is placed under TRUS Guidance. It can be performed as an outpatient. After the discharge from the theater clinic, the patient continues normal-life activities

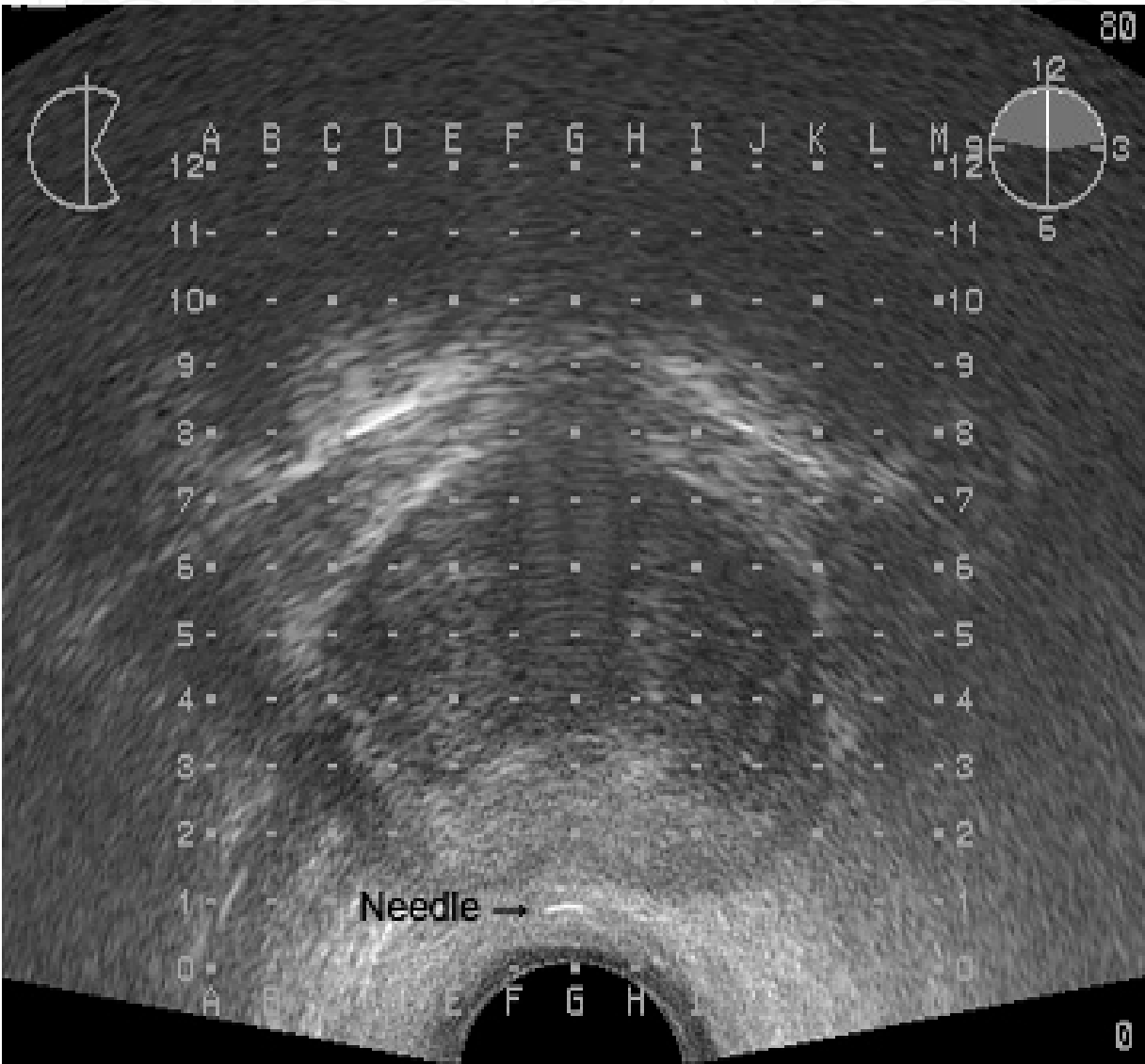


Figure 5. The needle tip is placed in the perirectal fat

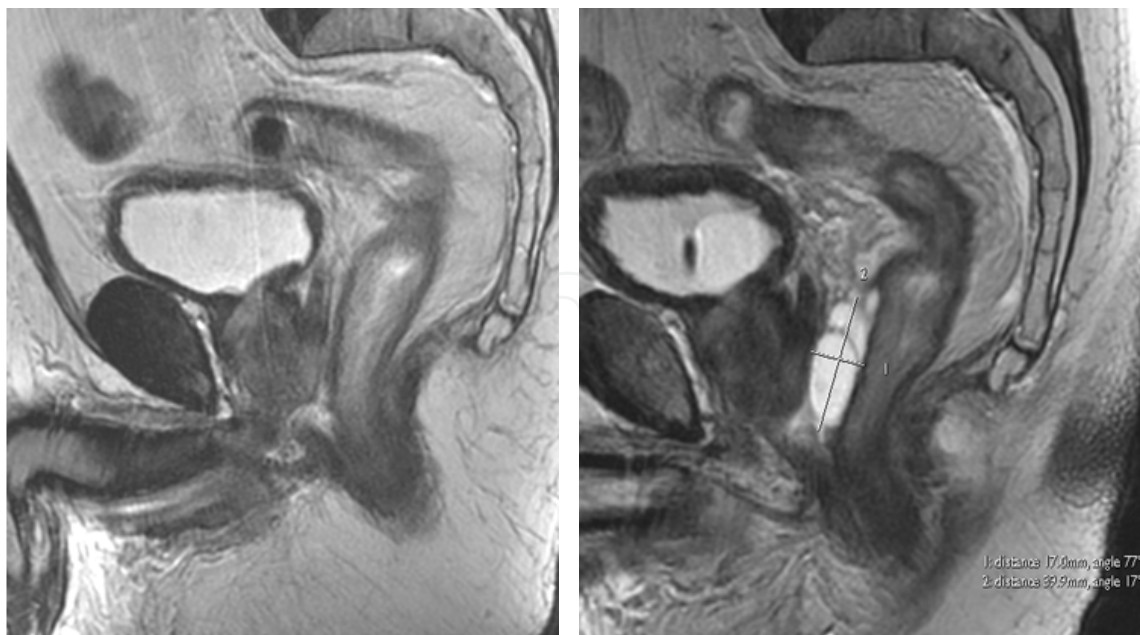


Figure 6. Magnetic resonance image demonstrating the additional perirectal space created by the hyaluronic acid injection

5. Results

In our Centre a total of 70 patients have been treated with this technique and is the first in the medical literature using in patients with favorable risk prostate cancer. Our technique has the great advantage of being practically a one-time procedure which prevents any movement of the needles.

In our series acute and late genitourinary toxicity grade 2 or more was not observed in any patient. The median of flow rate test pretreatment in our study was 12.5 ml/s (3-30 ml/s) but acute urinary retention was seen in only 1 patient, requiring a temporary postimplant bladder catheter during seven days, this results are better than other investigators [13-16].

The lasted follow-up visit the sexual preservation rate was 89% in patients who were potent preoperatively and not receiving hormonal therapy, this result is similar to that other investigators.

The late grade I genitourinary toxicity caused by our treatment was significantly associated with the dose administered to the PTV represented by D90 ($p=0.050$).

In our study no gastrointestinal toxicity, such as anal pain, rectal bleeding, diarrhea, anal ulcer and/or rectourethral fistula has been observed after treatment. We believe that the increase in distance between rectum and posterior prostatic capsule created by the peri-rectal injection of hyaluronic acid is enough to provide a significant radiation dose reduction from HDR brachytherapy and have significantly smaller incidence of mucosal damage [11, 12].

The actuarial biochemical control in our series was 100% and 88% respectively for low and intermediate risk groups at 32 months, but is too early to draw final conclusion respect to biochemical control.

6. Conclusions

High dose rate brachytherapy as monotherapy in one fraction with a transperineal hyaluronic acid injection into the peri-rectal fat to decrease rectal toxicity for patients with favorable risk prostate cancer is feasible and very well tolerated with advantages compared to LDR and HDR brachytherapy as monotherapy using the fractionation schema of 4 fractions administered 2 times daily during two days.

HDR monotherapy in one fraction resulted in a low genitourinary morbidity and no gastrointestinal toxicity but clinical and biochemical control rates will be reported as longer follow-up.

Author details

Pedro J. Prada

Address all correspondence to: pprada@telecable.es

Department of Radiation Oncology, Hospital Universitario Marques de Valdecilla, Santander, Spain

References

- [1] Mettlin CJ, Murphy GP, McDonald CJ, et al. The National cancer data base report on increase use of brachytherapy for the treatment of patients with prostate carcinoma in the USA. *Cancer* 1999; 86: 1877-1882.
- [2] Lee RW, Moughan J, Owen J, et al. The 1999 Patterns of care Study of radiotherapy in localized prostatic carcinoma. A comprehensive survey of prostate brachytherapy in the United States. *Cancer* 2003; 98 (9): 1987-1994.
- [3] Ash D, Flynn A, Battermann J, Reijke T, et al. ESTRO/EAU/EORTC recommendations on permanent seed implantation for localized prostate cancer. *Radiotherapy and Oncology*. 2000, 57:315-321.
- [4] Battermann JJ, Boon TA, Moerland A et al. Results of permanent prostate brachytherapy, 13 years of experience at a single institution. *Radiotherapy and Oncology* 2004; 71:23-28.

- [5] Fleming I, Cooper JS, Henson DE, et al. AJCC Cancer staging Manual, 5th edn. Philadelphia, Pennsylvania; Lippincott-Raven, 1997.
- [6] Zelefsky MJ, Leibel SA, Gaudin PB, et al. Dose escalation with three-dimensional conformal radiation therapy affects the outcome in prostate cancer. *Int J Radiat Oncol Biol Phys* 1998; 41:491-500.
- [7] Brenner DJ, Martinez AA, Edmundson GK, et al. Direct evidence that prostate tumors show high sensitivity to fractionation (low alpha/beta ratio), similar to late-responding normal tissue. *Int J Radiat Oncol Biol Phys* 2002;52:6-13.
- [8] Duchesne GM, Peters LJ. What is the alpha/beta ratio for prostate cancer? Rationale for hypofractionated high-dose-rate brachytherapy.[editorial]. *Int J Radiat Oncol Biol Phys* 1999;44:747-748.
- [9] Fowler JF. The radiobiology of prostate cancer including new aspects of fractionated radiotherapy. *Acta Oncol* 2005;44:265-276.
- [10] Fowler JF. The linear-quadratic formula and progress in fractionated radiotherapy. *Br J Radiol* 1989;62:679-694.
- [11] Prada PJ, Fernandez J, Martinez A, et al. Transperineal injection of hyaluronic acid in the anterior peri-rectal fat to decrease rectal toxicity from radiation delivered with intensity modulated brachytherapy or EBRT for prostate cancer patients. *Int J Oncol Biol Phys*. 2007; 69 (1):95-102.
- [12] Prada PJ, González H, Menéndez C, et al. Transperineal Injection of Hyaluronic Acid in the Anterior Peri-rectal Fat to Decrease Rectal Toxicity from Radiation Delivered with Low Dose Rate Brachytherapy for Prostate Cancer Patients. *Brachytherapy*. 8(2): 210-217, 2009.
- [13] Ghadjar P, Keller T, Rentsch C A, et al. Toxicity and early treatment outcomes in low and intermediate-risk prostate cancer managed by high-dose-rate brachytherapy as a monotherapy. *Brachytherapy* 2009; 8:45-51.
- [14] Martin T, Baltas D, Kurek R, et al. 3-D conformal HDR brachytherapy as monotherapy for localized prostate cancer. A pilot study. *Strahlenther Onkol* 2004; 180:225-232.
- [15] Yoshioka Y, Takayuki N, Yoshida K, et al. High-dose-rate interstitial brachytherapy as a monotherapy for localized prostate cancer: treatment description and preliminary results of a phase I/II clinical trial.. *Int J Oncol Biol Phys* 2000; 48(3):675-681.
- [16] Konishi K, Yoshioka Y, Isohashi F, et al. Correlation between dosimetric parameters and late rectal and urinary toxicities in patients treated with high-dose-rate brachytherapy used as monotherapy for prostate cancer. *Int J Oncol Biol Phys* 2009; 75(4): 1003-1007.