

# We are IntechOpen, the world's leading publisher of Open Access books Built by scientists, for scientists

6,900

Open access books available

186,000

International authors and editors

200M

Downloads

Our authors are among the

154

Countries delivered to

TOP 1%

most cited scientists

12.2%

Contributors from top 500 universities



WEB OF SCIENCE™

Selection of our books indexed in the Book Citation Index  
in Web of Science™ Core Collection (BKCI)

Interested in publishing with us?  
Contact [book.department@intechopen.com](mailto:book.department@intechopen.com)

Numbers displayed above are based on latest data collected.  
For more information visit [www.intechopen.com](http://www.intechopen.com)



---

# Amygdala in Alzheimer's Disease

---

Shira Knafo

Additional information is available at the end of the chapter

<http://dx.doi.org/10.5772/52804>

---

## 1. Introduction

Alzheimer's disease (AD) is a progressive neurodegenerative disease that causes debilitating dementia. For yet unknown reason, AD often leads also to emotional instability. Neuropathologically, AD brains are characterized by the presence of extracellular fibrillar amyloid beta peptide (A $\beta$ ) in amyloid plaques, intraneuronal neurofibrillary tangles consisting of aggregated hyperphosphorylated tau, and elevated brain levels of soluble A $\beta$  oligomers. Plaques and neurofibrillary tangles are observed mostly in the cerebral cortex, but subcortical regions such as nucleus basalis, thalamus, locus coeruleus and raphe nuclei are also affected (Price et al., 1991). The amygdala is another important subcortical region that is severely and consistently affected by pathology in AD. This chapter will discuss the neuropathological features of the amygdala affected by AD and the resulting psychological, emotional and cognitive disturbances in AD patients and in model mice of this disease.

## 2. Emotional disturbances in AD patients

The amygdala is part of the limbic system that plays a major role in the processing and memorizing of emotional reactions (Schafe et al., 2005). The involvement of the amygdala in emotion has been evidenced in monkeys by the overwhelming loss of normal social and affective behavior resulting from bilateral damage to this structure (Izquierdo et al., 2005; Izquierdo and Murray, 2007). The amygdala is affected early in AD and results by neuropsychiatric symptoms leading to functional deficits that greatly contribute to the disability associated with this disease. Due to the early damage to the amygdala, neuropsychiatric symptoms are very common in mild stages of AD. Eventually, approximately 80% of the patients with AD present neuropsychiatric symptoms, such as hallucinations, delusions, paranoia, anxiety, agitation, and affective disturbances during the course of their illness (Mega et al., 1996; Lyketsos et al., 2002). Other symptoms such as dysphoria, irritability, disinhibition and apathy are also common (Kaufer et al., 1998). In

addition to these symptoms, AD patients frequently show personality changes that affect their activities of daily living and the interaction with their caregivers. Personality changes may appear in any phase of dementia but often precede other early clinical manifestations of the disease, such as cognitive impairment and mood changes. These changes may therefore help in the clinical diagnosis of AD at early stages (Robins Wahlin and Byrne, 2011). Interestingly, personality changes and some of the neuropsychiatric symptoms (agitation, dysphoria and apathy) are better correlated with the severity of cognitive, functional and behavioral signs than with the patient's age, gender, education or disease duration (Mega et al., 1996; Talassi et al., 2007). Thus, personality changes and neuropsychiatric symptoms may reflect the impact of progressive brain damage in AD (Robins Wahlin and Byrne, 2011).

### **3. Emotional memory in AD**

Emotional memory is a form of episodic memory defined as memory of arousing emotional events. These memories are sometimes referred to as "flashbulb" memories (Hamann et al., 2000). Results from studies in animals and humans have strongly implicated the amygdala in this memory type (LaBar, 2003; Brierley et al., 2004; Richter-Levin, 2004). While it is recognized that normal people better remember events associated with an emotional component, there is a controversy regarding the strength of emotional memory in AD patients (Satler et al., 2007; Schultz et al., 2009; Huijbers et al., 2011; Nashiro and Mather, 2011; Sundstrom, 2011). Since the amygdala is one of the structures damaged in early stages of the AD pathology, it has been hypothesized that emotional memory should be impaired in AD patients. Indeed, data have shown that unlike healthy individuals, AD patients do not show memory enhancement for emotional events (enhanced memory for emotional compared to neutral stimuli) in spite of normal emotional reactions (Hamann et al., 2000). Notably, the degree of emotional memory impairment has positively been correlated with the extent of the amygdaloid atrophy (Mori et al., 1999a, b; Fleming et al., 2003).

### **4. Pathology of the amygdala in AD patients**

While normal aging primarily affects the prefrontal cortex but relatively spares limbic regions, AD mainly affects limbic regions. The amygdala of AD patients shows a considerable shrinkage, distortion and loss of neurons, and widespread gliosis (Vereecken et al.; Herzog and Kemper, 1980; Cuenod et al., 1993). The amygdaloid atrophy in AD is the result of neuronal death (especially in the magnocellular basolateral amygdalar nuclei group) and loss of dendrites and axons. The accumulation of intraneuronal neurofibrillary tangles, Lewy bodies and extracellular Amyloid  $\beta$  peptide ( $A\beta$ ) deposits in plaques also contribute significantly to the atrophy. Detailed pathological examination of the amygdala of AD patients reveals that many neurofibrillary tangles and  $A\beta$  plaques are located in the accessory basal and cortical nuclei and in the cortical transition area, whereas the mediobasal nucleus is less affected (Kromer Vogt et al., 1990). The medial, lateral, laterobasal and central nuclei are relatively free of neurofibrillary tangles and  $A\beta$  plaques (Kromer Vogt et al., 1990). Interestingly, it has been observed that the morphological

deformation of the amygdala in AD patients is associated with intrinsic damage to its subnuclei and their reciprocal connectivity with other brain areas. Specifically, it has been reported that amygdaloid nuclei receiving input from and giving rise to hippocampal projections are consistently affected by neuropathological alterations in AD. In contrast, amygdaloid nuclei which receive strong cholinergic input from nucleus basalis of Meynert (e.g. laterobasal nucleus) are less affected (Kromer Vogt et al., 1990). To conclude, histological analysis of the amygdala of AD patients allows a thorough examination of this region thus rendering possible to detect nucleus-specific pathologies. Nevertheless, the major limitation of post-mortem analysis is that it is typically performed on brains taken from patients at late stages of the disease. Thus, information is lacking regarding neuropathological alterations in early stages of AD.

## 5. Imaging of the amygdala *in vivo*

Whereas histological procedures are used to investigate the anatomical complexity of the amygdala in brains from AD patients, a standard magnetic resonance imaging (MRI) technique can only detect few internal details and similar resolution cannot be obtained. The discovery that neuronal loss is a cause of amygdaloid atrophy provided the basis for later studies correlating amygdaloid volumetry, as measured with MRI, with the cognitive status of individual AD patients. Indeed, MRI-based volumetry is now regularly used as a research tool to explore the relationship between amygdaloid volume and the onset and progression of AD (de Leon et al., 1996; Mori et al., 1999a; Vasconcelos et al., 2011). While in the past the use of MRI was limited to clinical studies, the recent rise in MRI accessibility allowed its utilization for non-clinical studies aimed at investigating the involvement of the amygdala in emotion, memory processes and personality (Mori et al., 1999a). The main disadvantage of MRI-based amygdaloid volumetry consists in the difficulty to precisely and reliably delineate the contours of the amygdala *in vivo*. This difficulty arises from the similarity in MRI signal intensities between the amygdala and other temporal lobe structures surrounding it (hippocampus proper, subiculum, entorhinal cortex, claustrum and tail of the caudate) (Convit et al., 1999). Nevertheless, new imaging techniques such as ultrahigh field structural MRI enable clear *in vivo* detection and even segmentation of the amygdala (Solano-Castiella et al., 2011), and might be used to investigate the anatomical features of different amygdaloid nuclei in AD patients.

Numerous studies measuring the amygdaloid volume (normalized to intracranial volume) in AD patients at different clinical stages and in healthy age-matched controls showed a correlation of this factor with the neuropsychological performance of each patient. These studies have consistently demonstrated a decrease in amygdaloid volume in AD patients when compared to healthy controls (Horinek et al., 2007; Beacher et al., 2009; Cherubini et al., 2010; Lehmann et al., 2010; Vasconcelos Lde et al., 2011). Importantly, atrophy of the amygdala was found even in preclinical stages of the disease (Fox et al., 1996; Heun et al., 1997; Golebiowski et al., 1999). In fact, in the very early stages of AD, amygdaloid volume reductions were at least as large as hippocampal volume reductions although at this stage

some overlap does exist between patients and healthy controls. Still, the volume of the amygdala has been suggested to be an independent variable in predicting conversion from mild cognitive impairment to AD (Liu et al., 2010).

*Functional MRI.* Increasing number of neuroimaging studies using functional MRI (fMRI) are used to examine the neuronal activity of the amygdala by detecting changes in local blood perfusion, blood volume or blood oxygenation. Injecting contrast agents are often used in this technique. In some studies, voxel-based morphometry (VBM) on MRI was combined with Positron Emission Tomography (PET) to compare activity in specific brain areas in AD patients and healthy controls (Kawachi et al., 2006). Functional MRI studies showed that the amygdala is excessively responsive to human faces (both novel emotional and familiar neutral expressions) in mild AD patients relative to elderly controls (Wright et al., 2007). On the other hand, AD patients presented deficits in the recognition of some facial expressions of emotion (happy, sad, fearful, and neutral expressions) (Kohler et al., 2005). These alterations in the normal activity of the amygdala probably contribute to the significant social and behavioral defects observed in AD patients.

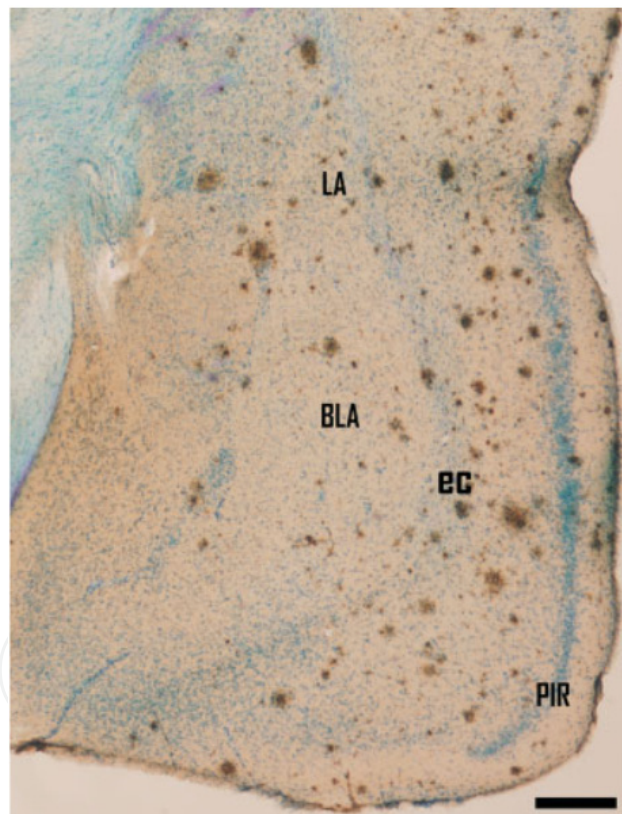
*Positron Emission Tomography (PET).* PET is almost exclusively used to image the brain, and may be used to detect functional abnormalities early in the course of AD, way before anatomical changes occur. For example, PET was used to examine acetylcholine esterase activity *in vivo* in the amygdala and cerebral cortex (Shinotoh et al., 2003). To note, levels of acetylcholine are significantly decreased in AD due to degeneration of the cholinergic magnocellular neurons of the nucleus basalis of Meynert (nbM) that send cholinergic projection mainly to the amygdala (Mesulam, 2004). In fact, the degree of the cholinergic loss is positively correlated with the severity of dementia in AD (Perry et al., 1981), probably due to the importance of nbM in emotional memory consolidation. PET measurements of C-11-labeled N-methyl-4-piperidyl-acetate (MP4A, a specific substrate of AChE) have shown that AChE activity is significantly reduced in patients with AD in both the amygdala and cerebral cortex (Shinotoh et al., 2003). Importantly, these deficits are present in mild to moderate AD, supporting the notion that cortical and amygdaloid functional changes of the cholinergic system occur early in AD (Herholz et al., 2004). These functional alterations are therefore suggested to serve as a physiologic and noninvasive marker for certain neuropsychiatric manifestations of mild AD. In addition, these finding suggest that the amygdala should receive an important attention in studies of the mild or even prodromal stages of AD (Basso et al., 2006) even though considerable evidences continue to support the focus on the hippocampus in MRI studies of AD.

## **6. The use of AD mice model to study the A $\beta$ -dependent changes in the amygdala**

In modern AD research, transgenic mice bearing infrequent mutations leading to familial forms of AD are being used to characterize in details the physiological, morphological and behavioral consequences of AD neuropathology in order to understand the anatomical and synaptic basis of dementia (Selkoe, 1996). These mutations include mutations in amyloid



precursor protein (APP), the precursor of the A $\beta$  peptide, or in presenilin (PS) 1 or 2, the catalytic subunit of the gamma secretase complex, which cleaves APP to form A $\beta$ . Transgenic AD mice model represents an important tool to examine the consequences of *in vivo* A $\beta$  accumulation and were proved to mimic many of the pathological features of AD (Spires and Hyman, 2005; Spires-Jones and Knafo, 2012). APP and APP/PS1 mice present abundant extracellular A $\beta$  plaques, synaptic dysfunction and loss, astrogliosis, activation of microglia and cognitive deficits (Games et al., 1995). The fact that A $\beta$  plaques occupy a minor fraction (less than 5%) of the neuropil (see Fig. 1) in cognitively impaired transgenic mice (Knafo et al., 2009; Merino-Serrais et al., 2011) and the lack of correlation between the plaque load and the degree of cognitive impairment in AD patients (Terry et al., 1991; Terry, 2000), support the notion that fibrillar A $\beta$  in plaques does not contribute significantly to dementia in AD patients. Instead, soluble A $\beta$  assemblies (i.e. oligomeric or protofibrillary A $\beta$  species that linger in aqueous solution after high-speed centrifugation) seem to be the main factors responsible for the structural, synaptic and cognitive deficits in these mice and probably also in initiating disease in AD patients (Selkoe, 2002).



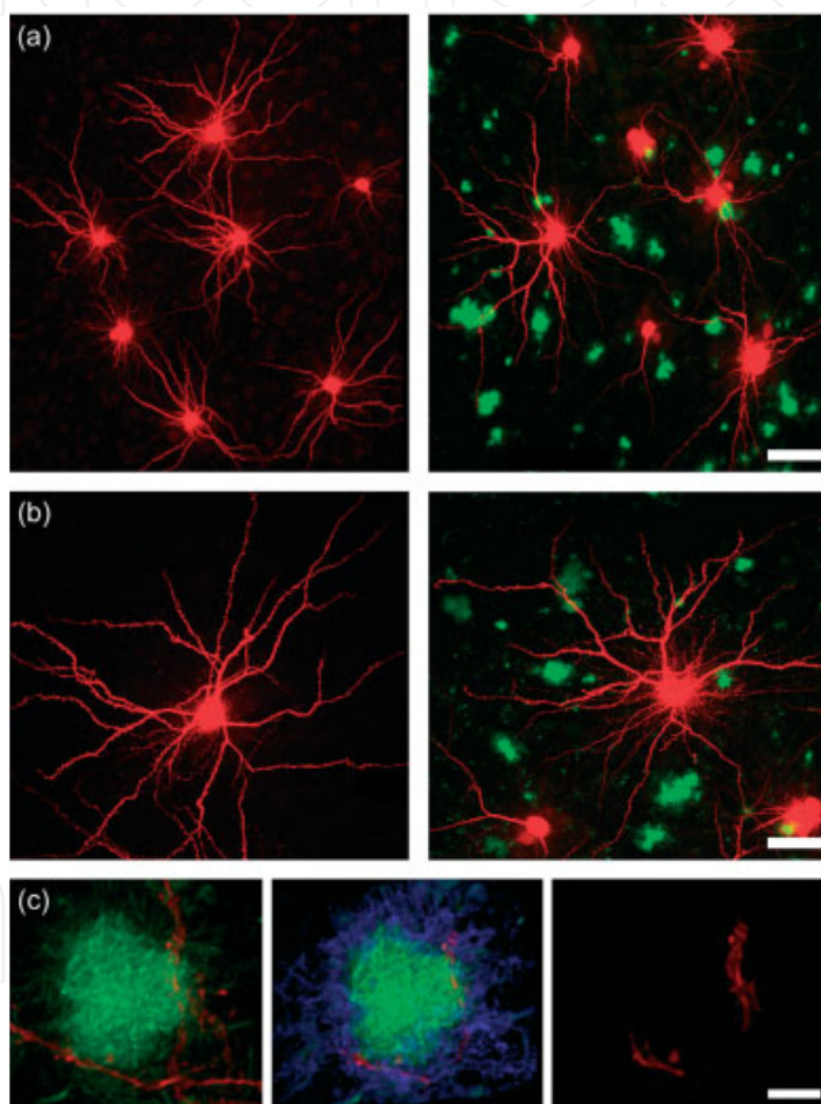
A section stained with the anti-A $\beta$  antibody and Nissl.

BLA = basolateral nucleus of the amygdala; EC = external capsule; LA = lateral nucleus of the amygdala; PIR = piriform cortex. Scale bar, 350  $\mu$ m (Knafo et al., 2009)

**Figure 1.** Coronal sections through the amygdala and adjacent regions showing the pattern of distribution of amyloid plaques.

In a recent study, transgenic mice expressing a chimeric mouse/human amyloid precursor protein (Mo/HuAPP695swe) and a mutant human presenilin 1 (PS1-dE9) (APP/PS1, Borchelt

et al., 1997) were used to study the morphological basis for amygdala-dependent cognitive impairment (Knafo et al., 2009). In this study, the authors first showed a clear impairment of auditory fear conditioning in APP/PS1 mice, a learning task that depends on the lateral nucleus of the amygdala (LA) (Knafo et al., 2009). Importantly, this cognitive deficit did not result from changes in anxiety or sensitivity to shock. Then, the authors used intracellular injection of Alexa594 into projection neurons in the LA, combined with thioflavin-S plaque staining (Fig. 2) and three-dimensional reconstructions of the dendritic trees and spines. The results of this study show that in APP/PS1 mice the morphology of projection neurons in the amygdala is modified, as reflected by changes in dendritic complexity, and that there is a



(a) Panoramic confocal (10x) views of the lateral amygdala showing Alexa594-injected neurons and thioflavin-S-positive plaques in a Tg- mouse (left) and an APP/PS1 mouse (right).

(b) Representative images of projection neurons from a Tg- mouse (left) and an APP/PS1 mouse (right).

(c) The method used to distinguish dendrites and spines within and outside plaques. Left: a plaque suspected of containing a dendrite due to the rotation of its three-dimensional image. Center: the plaque surface is marked with the aid of the IsoSurface tool of Imaris software. Right: the voxels outside the surface are set to zero, leaving only the dendritic segment within the plaque (Knafo et al., 2009).

**Figure 2.** Intracellular injections

significant decrease in number of large spines on these neurons (Knafo et al., 2009). The authors emphasized the finding that the morphological alteration in dendrites and spines occur mainly in plaque-free areas that occupy most of the neuropil. Thus, as spines are main postsynaptic elements of excitatory synapses in the brain (Gray, 1959) and are fundamental in memory, learning and cognition (Lamprecht and LeDoux, 2004) the authors suggested that these changes, rather than changes detected within plaques contribute to the cognitive impairment seen in APP/PS1 mice.

To summarize, amygdala is significantly and consistently affected by A $\beta$  both in patients with AD and in mouse models of this disease. Therefore, this region is a central participant in the pathology of AD (Unger et al., 1991) and its damage may be the structural substrate to the frequent emotional, psychological, and memory disturbances seen in this devastating disorder.

## Author details

Shira Knafo

*Severo Ochoa Center for Molecular Biology, Spanish National Research Council (CSIC)/Autonomous University of Madrid, Madrid, Spain*

## 7. References

- Basso M, Yang J, Warren L, MacAvoy MG, Varma P, Bronen RA, van Dyck CH (2006) Volumetry of amygdala and hippocampus and memory performance in Alzheimer's disease. *Psychiatry Research: Neuroimaging* 146:251-261.
- Beacher F, Daly E, Simmons A, Prasher V, Morris R, Robinson C, Lovestone S, Murphy K, Murphy DG (2009) Alzheimer's disease and Down's syndrome: an in vivo MRI study. *Psychological medicine* 39:675-684.
- Borchelt DR, Ratovitski T, van Lare J, Lee MK, Gonzales V, Jenkins NA, Copeland NG, Price DL, Sisodia SS (1997) Accelerated amyloid deposition in the brains of transgenic mice coexpressing mutant presenilin 1 and amyloid precursor proteins. *Neuron* 19:939-945.
- Brierley B, Medford N, Shaw P, David AS (2004) Emotional memory and perception in temporal lobectomy patients with amygdala damage. *Journal of neurology, neurosurgery, and psychiatry* 75:593-599.
- Cherubini A, Peran P, Spoletini I, Di Paola M, Di Iulio F, Hagberg GE, Sancesario G, Gianni W, Bossu P, Caltagirone C, Sabatini U, Spalletta G (2010) Combined volumetry and DTI in subcortical structures of mild cognitive impairment and Alzheimer's disease patients. *J Alzheimers Dis* 19:1273-1282.
- Convit A, McHugh P, Wolf OT, de Leon MJ, Bobinski M, De Santi S, Roche A, Tsui W (1999) MRI volume of the amygdala: a reliable method allowing separation from the hippocampal formation. *Psychiatry Res* 90:113-123.
- Cuenod C-A, Denys A, Michot J-L, Jehenson P, Forette F, Kaplan D, Syrota A, Boller F (1993) Amygdala Atrophy in Alzheimer's Disease: An In Vivo Magnetic Resonance Imaging Study. In, pp 941-945.



- de Leon MJ, Convit A, George AE, Golomb J, de Santi S, Tarshish C, Rusinek H, Bobinski M, Ince C, Miller D, Wisniewski H (1996) In vivo structural studies of the hippocampus in normal aging and in incipient Alzheimer's disease. *Annals of the New York Academy of Sciences* 777:1-13.
- Fleming K, Kim SH, Doo M, Maguire G, Potkin SG (2003) Memory for emotional stimuli in patients with Alzheimer's disease. *Am J Alzheimers Dis Other Dement* 18:340-342.
- Fox NC, Warrington EK, Freeborough PA, Hartikainen P, Kennedy AM, Stevens JM, Rossor MN (1996) Presymptomatic hippocampal atrophy in Alzheimer's disease. A longitudinal MRI study. *Brain* 119 ( Pt 6):2001-2007.
- Games D et al. (1995) Alzheimer-type neuropathology in transgenic mice overexpressing V717F [beta]-amyloid precursor protein. *Nature* 373:523-527.
- Golebiowski M, Barcikowska M, Pfeffer A (1999) Magnetic resonance imaging-based hippocampal volumetry in patients with dementia of the Alzheimer type. *Dement Geriatr Cogn Disord* 10:284-288.
- Gray EG (1959) Electron microscopy of synaptic contacts on dendrite spines of the cerebral cortex. *Nature* 183:1592-1593.
- Hamann SB, Monarch ES, Goldstein FC (2000) Memory enhancement for emotional stimuli is impaired in early Alzheimer's disease. *Neuropsychology* 14:82-92.
- Herholz K, Weisenbach S, Zündorf G, Lenz O, Schröder H, Bauer B, Kalbe E, Heiss WD (2004) In vivo study of acetylcholine esterase in basal forebrain, amygdala, and cortex in mild to moderate Alzheimer disease. *Neuroimage* 21:136-143.
- Herzog AG, Kemper TL (1980) Amygdaloid Changes in Aging and Dementia. In, pp 625-629.
- Heun R, Mazanek M, Atzor KR, Tintera J, Gawehn J, Burkart M, Gansicke M, Falkai P, Stoeter P (1997) Amygdala-hippocampal atrophy and memory performance in dementia of Alzheimer type. *Dement Geriatr Cogn Disord* 8:329-336.
- Horinek D, Varjassyova A, Hort J (2007) Magnetic resonance analysis of amygdalar volume in Alzheimer's disease. *Current opinion in psychiatry* 20:273-277.
- Huijbers MJ, Bergmann HC, Olde Rikkert MG, Kessels RP (2011) Memory for emotional pictures in patients with Alzheimer's dementia: comparing picture-location binding and subsequent recognition. *Journal of aging research* 2011:409364.
- Izquierdo A, Murray EA (2007) Selective Bilateral Amygdala Lesions in Rhesus Monkeys Fail to Disrupt Object Reversal Learning. *The Journal of Neuroscience* 27:1054-1062.
- Izquierdo A, Suda RK, Murray EA (2005) Comparison of the Effects of Bilateral Orbital Prefrontal Cortex Lesions and Amygdala Lesions on Emotional Responses in Rhesus Monkeys. *The Journal of Neuroscience* 25:8534-8542.
- Kaufer DI, Cummings JL, Christine D, Bray T, Castellon S, Masterman D, MacMillan A, Ketchel P, DeKosky ST (1998) Assessing the impact of neuropsychiatric symptoms in Alzheimer's disease: the Neuropsychiatric Inventory Caregiver Distress Scale. *Journal of the American Geriatrics Society* 46:210-215.
- Kawachi T, Ishii K, Sakamoto S, Sasaki M, Mori T, Yamashita F, Matsuda H, Mori E (2006) Comparison of the diagnostic performance of FDG-PET and VBM-MRI in very mild Alzheimer's disease. *European journal of nuclear medicine and molecular imaging* 33:801-809.
- Knafo S, Venero C, Merino-Serrais P, Fernaud-Espinosa I, Gonzalez-Soriano J, Ferrer I, Santpere G, DeFelipe J (2009) Morphological alterations to neurons of the amygdala and

- impaired fear conditioning in a transgenic mouse model of Alzheimer's disease. *The Journal of pathology* 219:41-51.
- Kohler CG, Anselmo-Gallagher G, Bilker W, Karlawish J, Gur RE, Clark CM (2005) Emotion-Discrimination Deficits in Mild Alzheimer Disease. *American Journal of Geriatric Psych* 13:926-933.
- Kromer Vogt LJ, Hyman BT, Van Hoesen GW, Damasio AR (1990) Pathological alterations in the amygdala in Alzheimer's disease. *Neuroscience* 37:377-385.
- LaBar KS (2003) Emotional memory functions of the human amygdala. *Current neurology and neuroscience reports* 3:363-364.
- Lamprecht R, LeDoux J (2004) Structural plasticity and memory. *Nature reviews* 5:45-54.
- Lehmann M, Douiri A, Kim LG, Modat M, Chan D, Ourselin S, Barnes J, Fox NC (2010) Atrophy patterns in Alzheimer's disease and semantic dementia: a comparison of FreeSurfer and manual volumetric measurements. *Neuroimage* 49:2264-2274.
- Liu Y, Paajanen T, Zhang Y, Westman E, Wahlund LO, Simmons A, Tunnard C, Sobow T, Mecocci P, Tsolaki M, Vellas B, Muehlboeck S, Evans A, Spenger C, Lovestone S, Soininen H (2010) Analysis of regional MRI volumes and thicknesses as predictors of conversion from mild cognitive impairment to Alzheimer's disease. *Neurobiology of aging* 31:1375-1385.
- Lyketsos CG, Lopez O, Jones B, Fitzpatrick AL, Breitner J, DeKosky S (2002) Prevalence of neuropsychiatric symptoms in dementia and mild cognitive impairment: results from the cardiovascular health study. *Jama* 288:1475-1483.
- Mega MS, Cummings JL, Fiorello T, Gornbein J (1996) The spectrum of behavioral changes in Alzheimer's disease. *Neurology* 46:130-135.
- Merino-Serrais P, Knafo S, Alonso-Nanclares L, Fernaud-Espinosa I, DeFelipe J (2011) Layer-specific alterations to CA1 dendritic spines in a mouse model of Alzheimer's disease. *Hippocampus* 21:1037-1044.
- Mesulam M (2004) The Cholinergic Lesion of Alzheimer's Disease: Pivotal Factor or Side Show? *Learning & Memory* 11:43-49.
- Mori E, Ikeda M, Hirono N, Kitagaki H, Imamura T, Shimomura T (1999a) Amygdalar volume and emotional memory in Alzheimer's disease. *Am J Psychiatry* 156:216-222.
- Mori E, Ikeda M, Hirono N, Kitagaki H, Imamura T, Shimomura T (1999b) Amygdalar volume and emotional memory in Alzheimer's disease. *The American journal of psychiatry* 156:216-222.
- Nashiro K, Mather M (2011) Effects of emotional arousal on memory binding in normal aging and Alzheimer's disease. *The American journal of psychology* 124:301-312.
- Perry EK, Blessed G, Tomlinson BE, Perry RH, Crow TJ, Cross AJ, Dockray GJ, Dimaline R, Arregui A (1981) Neurochemical activities in human temporal lobe related to aging and Alzheimer-type changes. *Neurobiology of aging* 2:251-256.
- Price JL, Davis PB, Morris JC, White DL (1991) The distribution of tangles, plaques and related immunohistochemical markers in healthy aging and Alzheimer's disease. *Neurobiology of aging* 12:295-312.
- Richter-Levin G (2004) The amygdala, the hippocampus, and emotional modulation of memory. *The Neuroscientist : a review journal bringing neurobiology, neurology and psychiatry* 10:31-39.
- Robins Wahlin TB, Byrne GJ (2011) Personality changes in Alzheimer's disease: a systematic review. *Int J Geriatr Psychiatry* 26:1019-1029.

- Satler C, Garrido LM, Sarmiento EP, Leme S, Conde C, Tomaz C (2007) Emotional arousal enhances declarative memory in patients with Alzheimer's disease. *Acta neurologica Scandinavica* 116:355-360.
- Schafe GE, Doyere V, LeDoux JE (2005) Tracking the fear engram: the lateral amygdala is an essential locus of fear memory storage. *J Neurosci* 25:10010-10014.
- Schultz RR, de Castro CC, Bertolucci PH (2009) Memory with emotional content, brain amygdala and Alzheimer's disease. *Acta neurologica Scandinavica* 120:101-110.
- Selkoe DJ (1996) Amyloid beta-protein and the genetics of Alzheimer's disease. *The Journal of biological chemistry* 271:18295-18298.
- Selkoe DJ (2002) Alzheimer's disease is a synaptic failure. *Science (New York, NY)* 298:789-791.
- Shinotoh H, Fukushima K, Nagatsuka S, Tanaka N, Aotsuka A, Ota T, Namba H, Tanada S, Irie T (2003) The Amygdala and Alzheimer's Disease. *Annals of the New York Academy of Sciences* 985:411-419.
- Solano-Castiella E, Schäfer A, Reimer E, Türke E, Pröger T, Lohmann G, Trampel R, Turner R (2011) Parcellation of human amygdala in vivo using ultra high field structural MRI. *Neuroimage* 58:741-748.
- Spires TL, Hyman BT (2005) Transgenic models of Alzheimer's disease: Learning from animals. *NeuroRx* 2:423-437.
- Spires-Jones T, Knafo S (2012) Spines, Plasticity, and Cognition in Alzheimer's Model Mice. *Neural Plasticity* 2012.
- Sundstrom M (2011) Modeling recall memory for emotional objects in Alzheimer's disease. *Neuropsychology, development, and cognition Section B, Aging, neuropsychology and cognition* 18:396-413.
- Talassi E, Cipriani G, Bianchetti A, Trabucchi M (2007) Personality changes in Alzheimer's disease. *Aging Ment Health* 11:526-531.
- Terry RD (2000) Cell Death or Synaptic Loss in Alzheimer Disease. *Journal of Neuropathology & Experimental Neurology* 59:1118-1119.
- Terry RD, Masliah E, Salmon DP, Butters N, DeTeresa R, Hill R, Hansen LA, Katzman R (1991) Physical basis of cognitive alterations in alzheimer's disease: Synapse loss is the major correlate of cognitive impairment. *Annals of neurology* 30:572-580.
- Unger JW, Lapham LW, McNeill TH, Eskin TA, Hamill RW (1991) The amygdala in Alzheimer's disease: neuropathology and Alz 50 immunoreactivity. *Neurobiology of aging* 12:389-399.
- Vasconcelos Lde G, Jackowski AP, Oliveira MO, Flor YM, Bueno OF, Brucki SM (2011) Voxel-based morphometry findings in Alzheimer's disease: neuropsychiatric symptoms and disability correlations - preliminary results. *Clinics (Sao Paulo)* 66:1045-1050.
- Vasconcelos LdG, Jackowski AP, Oliveira MOf, Flor YMR, Bueno OFA, Brucki SMD (2011) Voxel-based morphometry findings in Alzheimer's disease: neuropsychiatric symptoms and disability correlations - preliminary results. *Clinics* 66:1045-1050.
- Vereecken THLG, Vogels OJM, Nieuwenhuys R Neuron loss and shrinkage in the amygdala in Alzheimer's disease. *Neurobiology of aging* 15:45-54.
- Wright CI, Dickerson BC, Feczko E, Negeira A, Williams D (2007) A Functional Magnetic Resonance Imaging Study of Amygdala Responses to Human Faces in Aging and Mild Alzheimer's Disease. *Biological Psychiatry* 62:1388-1395.