

We are IntechOpen, the world's leading publisher of Open Access books Built by scientists, for scientists

6,900

Open access books available

186,000

International authors and editors

200M

Downloads

Our authors are among the

154

Countries delivered to

TOP 1%

most cited scientists

12.2%

Contributors from top 500 universities



WEB OF SCIENCE™

Selection of our books indexed in the Book Citation Index
in Web of Science™ Core Collection (BKCI)

Interested in publishing with us?
Contact book.department@intechopen.com

Numbers displayed above are based on latest data collected.
For more information visit www.intechopen.com



The Role of *Helicobacter spp.* Infection in Domestic Animals

Achariya Sailasuta and Worapat Prachasilchai

Additional information is available at the end of the chapter

<http://dx.doi.org/10.5772/53054>

1. Introduction

1.1. Overview and pathogenesis

The discovery of the association of *Helicobacter pylori* with chronic gastritis, peptic ulcers and gastric neoplasia, mucosa-associated lymphoid tissue-type lymphoma and carcinoma, has led to fundamental changes in the understanding of gastric disease in humans. Some humans with *H. pylori* infection develop only mild, asymptomatic gastritis. Whether more severe disease develops thought to be influenced by individual host factors and pathogenicity of the bacteria involved. The odd of developing symptomatic *H. pylori* infection varies by geographic location and age. Different strains of *H. pylori* have recently been identified. Therefore, *H. pylori* should be considered a population of closely related but genetically heterogeneous bacteria of different genotypes and virulence.

A gastric spiral bacteria of superkingdom bacteria, phylum proteobacteria, subphylum delta/epsilon subdivisions, class epsilonproteobacteria, order campylobacter, family helicobacteraceae, genus *Helicobacter spp.* is gram-negative, spiral-shaped bacteria. At least 13 species have been reported, and most are suspected or proven gastric or hepatic pathogens. *Helicobacter spp.* have been reported in humans: mainly *H. pylori*, nonhuman primates: *H. nemestrinae*, cats and dogs various species, including *H. pylori*, *H. felis*, *H. salomonis*, *H. rappini*, *H. heilmannii*, and *H. bizzozeronii*, pigs: *H. heilmannii*, ferrets: *H. mustelae*, and cheetahs: *H. acinonyx*. More recently we have learned that nearly all mammals harbor their own species of *Helicobacter* infection. Some are suggesting now that infection might be benign or even beneficial by protecting against development of esophageal reflux and cancer of the esophagus.

Risk factors for *H. pylori* infection in humans include age and socioeconomic status, with children and those with low socioeconomic status at greater risk. The role of *Helicobacter spp.* in gastrointestinal disease in dogs and cats is uncertain. It has been known for years that gastric *Helicobacter*-like organisms (HLO) are commonly present in stomach of dogs but the relationship of these organisms and gastric disease is unresolved. *H. pylori* transmission is proposed to be fecal-oral, oral-oral, and gastro-oral (via vomited fluids). The exact details of transmission are still unclear. A higher incidence of *H. pylori* infection has been reported by gastroenterologists, suggesting that transmission from patient to physician is possible. It has been suggested that *Helicobacter spp.* infection might be zoonotic by contact with dogs and cats and has been correlated with human *H. heilmannii* infection. There is no correlation between pet ownership and human *H. pylori* infection.

H. pylori is one of the major causes of chronic gastritis and plays an important role in the pathogenesis of peptic ulcer, gastric carcinoma, gastric adenocarcinoma, and primary B-cell gastric lymphoma. *H. pylori* is the second most common cause of cancer morbidity and mortality worldwide, and the development of gastric non-Hodgkin's lymphoma. Histological gastritis is essentially universal among *H. pylori*-infected individuals, but only a few develop a clinically significant outcome, such as peptic ulcer disease or gastric cancer. The clinical significance of this bacterium has recently been emphasized by a National Institutes of Health consensus panel and thus recommending antibiotic therapy for the large majority of peptic ulcer patients who are infected with *H. pylori* and by classification of *H. pylori* as a class I (definite) carcinogen by the World Health Organization. The bacteria were often seen in malignant or ulcerated gastric tissue, and the possibility of an infectious cause of peptic ulcer was considered. *H. pylori* often establishes life-long infections of the gastric mucosa. These bacteria produce a powerful urease that is regulated in response to acid. So the ammonia and carbonate produced by this enzyme most likely create an alkaline microenvironment. This mechanism is unprecedented. Further study shows that the high density of colonization by *H. pylori* occurs in the antrum (lower portion of the stomach) where conditions are less acidic. As the infection becomes more pronounced or under conditions where the antrum becomes more alkaline, the motile bacteria migrate up into the cardia (body) of the stomach. Infection with *H. pylori* bacteria is basically located in three dimensions, as these bacteria not only can move north and south in the mucosa in response to acid levels, but they are able to move freely up and down in the mucus layer that coats the gastric mucosa and provides a protective barrier against the diffusion of strong acid onto the epithelium. The notion of being "off shore" and therefore out of reach of the macrophages and cells of host immune defense may also play an important role in survival of these bacteria. Finally, the mounting evidence suggests that *H. pylori* may control the immune response and selective release of inflammatory factors. The balance between increase of inflammation and immune suppression is a key to the persistence and an area where novel therapeutics, perhaps in combination with vaccine strategies, could be directed.

The discovery of *Helicobacter spp.*, a relative of *Campylobacter spp.* (bacterial pathogens of the lower GI tract), fortunately coincided with the beginning of the genomics era, and is the beneficiary of two completely sequenced genomes of *H. pylori*. The results reveal a small ge-

nome (1.67 megabases) containing some 1553 genes encoding around 1,300 proteins. Despite possessing a limited number of genes, *H. pylori* displays auxotrophy for only a few amino acids and appears to possess most catabolic and anabolic pathways found in bacteria with larger genomes. Recent studies examining essentiality testing on a genome scale suggested that there are few redundancies and backups in metabolic pathways and thus the percentage of *H. pylori* genes found essential may be greater than expected for organisms with larger genomes perhaps opening a door for development of *Helicobacter* selective therapeutics.

Helicobacter-like bacteria have been identified in the stomachs of all mammalian species examined to date. Many epidemiological studies have shown a strong association between chronic *H. pylori* infection and subsequent development of gastric carcinoma in humans. Studies of *H. pylori* and gastric carcinoma from the view point of animal model showed that persistent *H. pylori* infection has recently been achieved in the Japanese monkeys and Mongolian gerbil models, with results demonstrating that the sequential histopathological changes in the gastric mucosa are closely mimic the gastric mucosal changes caused by *H. pylori* infection in humans. Gastric mucosa infected with *H. pylori* exhibited significantly higher gastritis score, reduction in glandular height, increase in the number of Ki-67 positive cells and over expression of p53 protein and p53 gene mutation in the Japanese monkey model. In the Mongolian gerbil model, *H. pylori* infection enhances gastric and also demonstrated that *H. pylori* infection alone can result in the development of gastric carcinoma

In gnotobiotic dogs were used as experimental hosts for *H. pylori* infection. All dogs tested were successfully colonized with *H. pylori*. In addition, two inoculated dogs co-housed with experimental dogs also became colonized which indicating transmission of infection. The subsequent use of dogs as *H. pylori* models has been limited. One recent study showed that conventionally housed dogs are also susceptible to experimental infection. In addition to experimental studies, efforts have been made to determine the presence of natural gastric *Helicobacter* spp. infections in dogs. Surveys of pet dogs have repeatedly failed to show natural infection with *H. pylori*. However, natural infection with other gastric *Helicobacters* commonly occurs. *H. felis*, *H. bilis*, *H. bizzozeronii*, *H. salomonis*, *H. heilmannii* and *Flexispira rappini* have all been identified in surveys of gastric infections in dogs. A significant association between their presence and the occurrence of gastritis has never been demonstrated. There have been many studies confirm other studies which suggested the presence of *Helicobacter* spp. is naturally found in dogs. It has been reported that the gastric biopsies found *Helicobacter*-like organism infection and dogs were postulated to be infected with several species of *Helicobacter* spp. While, it is said to be the most commonly occurring of *Helicobacter*-like organisms in dogs and cats. The role of *Helicobacter* spp. infection in gastrointestinal disease in dogs and cats is uncertain. It has been known for years that gastric *Helicobacter*-like organisms (HLO) are commonly presented in stomach of dogs but the relationship of these organisms and gastric disease is unresolved. Infection with HLO is highly prevalent in dogs. It is seen the clinical sign of vomiting and also clinically healthy pet dogs. *Gastrospirillum hominis*, another *Helicobacter*-like organism, has so far not been cultivated.

H. pylori transmission is proposed to be fecal-oral, oral-oral, and gastro-oral (via vomited fluids). The exact details of transmission are still unclear. A higher incidence of *H. pylori* infection has been reported by gastroenterologists, suggesting that transmission from patient to physician is possible. It has been suggested that *Helicobacter spp.* infection might be zoonotic by contact with dogs and cats and has been correlated with human *H. heilmannii* infection. There is no correlation between pet ownership and human *H. pylori* infection.

Helicobacter spp. produce urease, which breaks down urea into ammonia and bicarbonate ions. In stomach, ammonia has a buffering effect that may help *Helicobacter spp.* colonize on mucosa in the acidic gastric environment. In addition, ammonia is directly toxic to gastric epithelial cells. *H. pylori* infection is associated with increased gastric acid secretion (hyperacidity), which causes inflammation of the gastric antrum (antral gastritis) and duodenal ulceration. It has been proposed that hyperacidity is caused by hypergastrinemia resulting from the inhibition of somatostatin-secreting cells (somatostatin inhibits gastrin release). Hypergastrinemia also increases parietal cell mass through a trophic effect on gastric mucosa. *H. pylori* infection can also be associated with lack of gastric acid (achlorhydria). This is thought to occur when *H. pylori* causes mucosal atrophy in the gastric fundus and body or inhibits functioning of the parietal cells. Chronic gastric inflammation may progress to chronic atrophic gastritis and intestinal metaplasia, which are precancerous conditions. It appears that *Helicobacter spp.* infection significantly alter gastric acid secretion in dogs.

The pathological significance of these organisms in the dog is currently unknown. Study of naturally infected dogs and cats has shown that *Helicobacter spp.* predominantly colonizes the gastric fundus and cardia and is associated with mild to moderate mononuclear cell inflammation in appearance of chronic gastritis. In an experimental study of beagles which infected with *H. felis* and *H. bizzozeronii*-like organisms, it has been concluded that acid secretion was not markedly disturbed by infection and that treatment had been temporarily suppressed. Infected dogs showed no clinical signs and had mild gastritis histologically before and after treatment. No correlation was identified between the severity of inflammation and degree of bacterial colonization. It has been suggested that successful treatment of *Helicobacter spp.* in pet dogs did not change gastric histology and that mild chronic gastritis still persisted.

1.2. *Helicobacter* diagnosis

Non-invasive test methods for detecting *Helicobacter spp.* (e.g., urea breath testing, antibody testing, stool antigen testing) are not routinely available for dogs and cats. Urease testing from breath and blood, has been investigated in dogs but is not widely available. Antibody testing is potentially used but more difficulty apply than in human because of the variety of *Helicobacter spp.* infecting dogs and cats. Nevertheless, antibody testing is being investigated, and infected animals are known to develop antibodies. Theoretically, stool antigen testing could be useful in *H. pylori*-infected cats or in animals infected with *Helicobacter spp.* that have antigenic homology. Thus cross-reactivity with *H. pylori* should be concerned. This has not yet been investigated. The confirmation of the presence of *Helicobacter spp.* in dogs and cats, the invasive methods has already been discussed. Endoscopically obtained gastric mu-

cosal biopsies are commonly used, and direct observation of organisms by histology or cytology and rapid urease testing are common methods. Because of *Helicobacter spp.* distribution in the stomach may be in locally site, evaluation of multiple biopsies and anatomic location (i.e., cardia, fundus, and antrum) is also recommended. Gastric *Helicobacter spp.* was found in the cardia, fundus, body, and pylorus. It has been reported that the most prevalent location of stomach were in cardia, fundus, body and pylorus respectively. In addition, naturally infected dogs has shown that *Helicobacter spp.* predominantly colonizes in the gastric cardia and fundus. *Helicobacter spp.* was demonstrated considerable affinity for parietal cells and is found in their intracellular canaliculi as well as in the cytoplasm. They had been observed in large numbers in the mucus covering the surface epithelium, the gastric pits and the glandular lumina. It appears that *Helicobacter spp.* infection does not significantly alter gastric acid secretion in dogs. Study of naturally infected dogs has shown that *Helicobacter* predominantly colonizes the gastric cardia and fundus. However, the predilection site of infection is recommended as fundic area of the stomach.

Direct observation of *Helicobacter spp.* organisms in biopsy specimens and necropsied dogs usually requires special stains. It has been reported that there was no statistically different significant between the locations of histopathological lesion and *Helicobacter spp.* infection using H&E. The presence of lymphoid follicles in the gastric mucosa has traditionally been considered a common, nonspecific finding in the gastric mucosa of dogs. Most dogs had many bacteria and only mild gastritis. It is suggested that in dogs, the bacteria did not induce histological evident of certain diseases. In naturally infected with *Helicobacter spp.*, the lymphoid follicles are frequently found in subglandular areas and sometimes extended between the glands. Moreover, it was reported that, gnotobiotic dogs which experimentally infected with *Helicobacter spp.* developed large numbers of lymphoid follicles throughout the gastric mucosa, while the dogs had no follicles. The occurrence of lymphoid follicles were indicated the *Helicobacter spp.* infection from gastrointestinal specimens which depend on the sites. In comparable to the *H. pylori* infection in children which frequently results in marked gastric lymphoid hyperplasia, have led to the hypothesis that lymphoid follicles in the human gastric mucosa can result from chronic *H. pylori* antigenic stimulation and, therefore, represent a specific immune response directed against the organisms. Also, by inducing lymphoid tissue formation in the gastric mucosa, *H. pylori* may be a necessary precursor for the development of primary gastric MALT lymphoma. It should be noted that the histopathological changes in the dogs was much less severe than those seen in *H. pylori* gastritis in human which could be due to species variation. It will be of interest to study dogs which have been subjected to different environmental conditions or dietary changes to ascertain if differences in the gastritis profile occur with manipulation of these variables.

The Histopathology diagnosis, *Helicobacter spp.* can be visualized at the high magnification with conventional Hematoxylin & eosin (H&E) stained sections. Bacteria are located in the mucus adherent to the surface epithelium and are often found deep within the crypts. However, H&E staining may be unclear when few bacteria are also presented. In addition, luminal debris on the surface of the epithelium can be mistaken for *Helicobacter*

spp. in H&E stained sections. Although these organisms with certain morphology 2.5-5.0 μm length, 0.5- 1.0 μm width and had five to nine helical turns could be notified. But the other organisms such as *Bacillus* organisms were difficult to histology evaluation. Because of the presented things were presented quite similar to *Helicobacter spp.* in color by H&E staining in histology evaluation (Fig. 1). Using special stains such as Warthin Starry stain (WSS) facilitates histological identification of bacteria. *Helicobacter spp.* was obviously presented in dark-brown color on yellow background. These bacteria were located mainly in the gastric pits and the upper portions of gastric glands, where they were often in intimate association with the epithelial cell surface (Fig. 2). These bacteria were located within the gland lumens, sometimes attached to the epithelial cell surface, and within the cytoplasm of parietal cells. WSS sections of stomach part revealed tightly coiled helical bacteria that were generally 2.5- 5.0 μm length. It is suggested that WSS is high occurrence than H&E. It is likely that the additional of WSS is offset by a reduction in time required for slide evaluation and improvement of identification of *Helicobacter spp.* infection. A sensitive staining technique consisting of a combination of H&E and WSS has been developed. WSS could be used for detecting *Helicobacter spp.* in gastric tissues short period of time, cheap and easy to use. The WSS examination of large numbers of sections in a relatively short period of time. However, the special staining procedure can be technically difficult, and require experiences. Its meaning acceptance among gastrointestinal pathologists has not been proved yet. Other factors that could influence gastric pathology include the number of organisms present, the host species and genotype, environmental factors such as diet, and concurrent infection with undetected organisms. However, it is suggested the significantly different correlations for *Helicobacter spp.* detection between H&E and WSS. Therefore, the diagnostic method of choice for diagnosis of *Helicobacter spp.* infection in canine stomach is depended on the purpose and appropriate site of specimen collection.

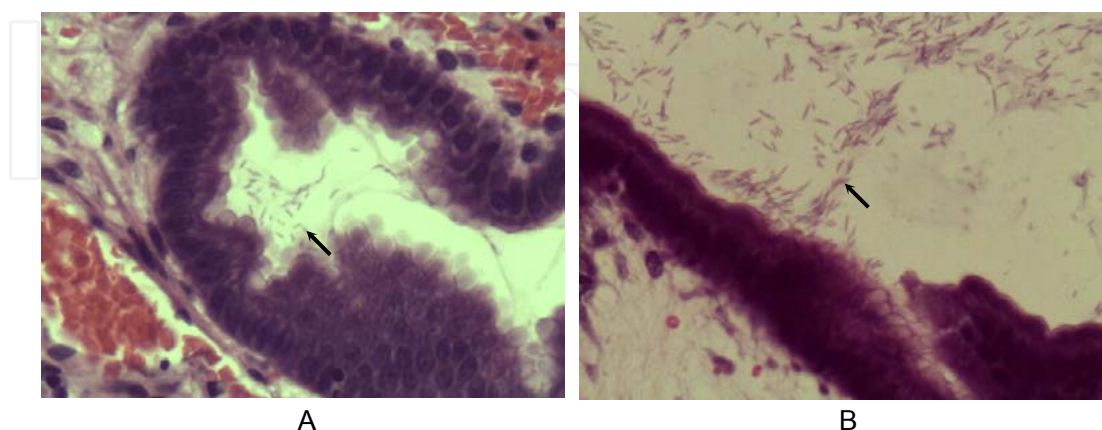


Figure 1. The numerous spiral shape organisms: *Helicobacter spp.* was presented in the surface of gastric mucosa in fundus part of stomach in dog (Arrow) (A) (H&E, Bar = 10 μm) *Helicobacter spp.* was demonstrated on the gastric epithelium in higher magnification. (B) (H&E, Bar = 5 μm)

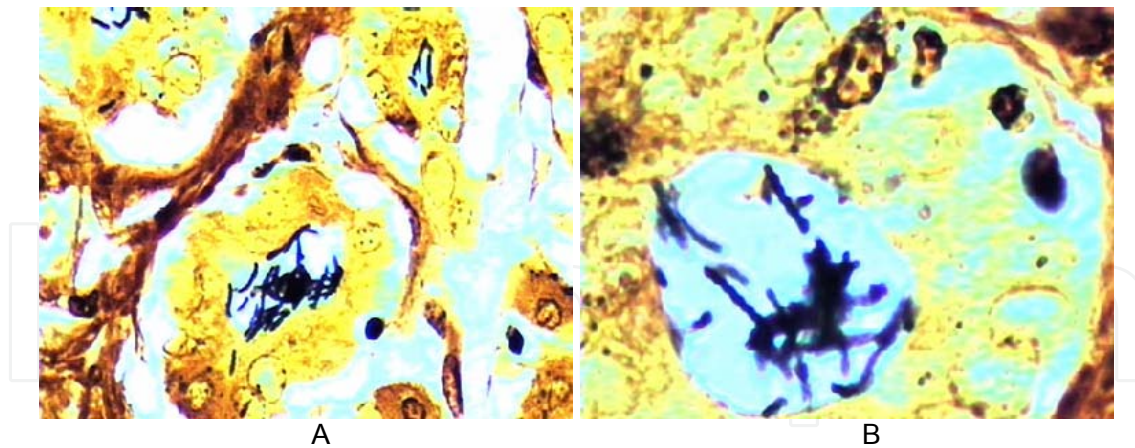


Figure 2. Spiral-shape *Helicobacter spp.* was positive in dark brown color was showing 3.0 - 5.0 µm in length and 0.5 - 1.0 µm in width in the gastric pit in fundus. In higher magnification of spiral-shape with dark brown color of *Helicobacter spp.* (WSS, A : Bar = 10 µm, B : Bar = 5 µm)

In case of Immunohistochemical staining, IHC was much more sensitive for detecting infection than the routinely used H&E and WSS. IHC staining also have been developed to detect *Helicobacter spp.* antigen. The IHC using monoclonal anti-*H. pylori* antibody is the best diagnostic tool for formalin-fixed samples (Fig. 3). And IHC is very high specificity. But IHC is rather expensive, long period of time and good experience. Such IHC are usually not necessary but may prove worthwhile in cases where stains are difficult to evaluate for confirmations.

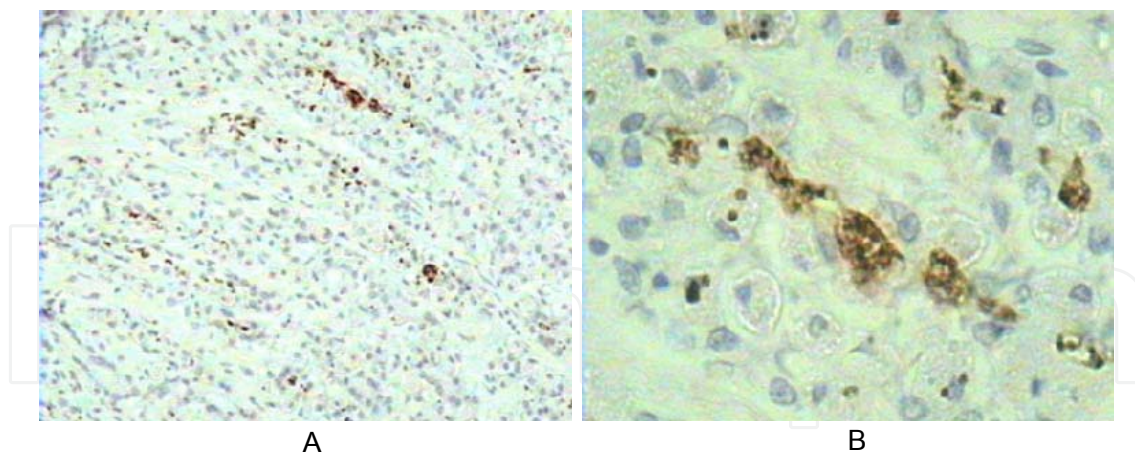


Figure 3. *Helicobacter spp.* demonstrated brown color in positive sites by Immunohistochemistry using rabbit polyclonal anti-*H. pylori* antibody in lumen of gastric gland in fundus part of stomach. Meyer's Hematoxylin counterstained, ABC, DAB (A Bar =20 µm, B Bar =10 µm)

For PCR offers great promise as a highly sensitive and specific technique for the detection of *Helicobacter spp.* and *H. pylori*. PCR technique for the detection of *H. pylori* in gastric biopsy specimens has been described by a number of laboratories although the accuracy of such technique varies widely. The identification of *Helicobacter spp.* in biopsies from dogs using

PCR has been reported and applied for detection of identification to species of *Helicobacter spp.* in dogs with naturally occurring gastric helicobacteriosis. Several observations shown that PCR was sensitive and specific which is in agreement with studies in mice infected with *H. felis* and in humans and cats infected *H. pylori*, which showed that PCR was more sensitive than histology, bacterial culture, and urease mapping. Factors affecting test accuracy of PCR include the choice of primers and target DNA, specimen preparation, bacterial density and technical issues. PCR demonstrated excellent accuracy for the detection of *H. pylori* infection in a limited number of samples. PCR technique for the detection of *H. pylori* is still in its infancy. It is unlikely that such technique will have widespread use in the initial detection of *H. pylori*. However, PCR method hold great promise in the detection of genetic differences between *H. pylori* strains for research and epidemiological studies. Repeat endoscopy or biopsy is required, which is expensive and unappealing to many pet owners. However, an advantage of follow up endoscopy in noninvasive testing is the opportunity to reassess gastric morphologic changes.

2. Treatment

Treatment of the *Helicobacter spp.* infection in dogs is controversial. Whether treatment is needed in all cases and which drugs are preferred. Efficacy of treatment and whether drug resistance is a problem in veterinary patients and should be aware. Recent studies suggested that treatment might only suppress infection but not eradicate it. More reports of post treatment follow-up assessing bacterial status and gastrointestinal (GI) changes are needed for naturally acquired clinical signs in a dog should be considered. A profile of investigations to rule out underlying GI disease (e.g., food inflammatory bowel disease, neoplasia) should be undertaken before treating *Helicobacter spp.* infection. Even with such a work set up, it may be difficult to know whether all GI inflammation is caused by *Helicobacter spp.* infection alone or whether underlying with other inflammatory diseases. This is especially true for patients in which inflammation persists following treatment and apparent *Helicobacter spp.* prevention and control.

The treatment protocols in dogs and cats have been adapted from human medicine and included various combination of antibiotic and antisecretory therapy. Traditional veterinary triple therapy consists of metronidazole, amoxicillin, and bismuth subsalicylate and has been used as initial treatment for *Helicobacter spp.* infection in dogs and cats. Other antimicrobial drugs that have been used in animals in which traditional triple therapy fails include tetracycline and clarithromycin. Antisecretory drugs that have been used include H₂-receptor antagonists and proton-pump inhibitors. Treatment is typically administered for 2 to 4 weeks, but the optimal duration of treatment is unknown. The clinical gastritis resolve following 4 weeks of treatment with traditional veterinary triple therapy (in dogs) or a combination of amoxicillin, metronidazole, and famotidine (in dogs and cats). These therapeutic protocol has been practically used.

Author details

Achariya Sailasuta^{1*} and Worapat Prachasilchai²

*Address all correspondence to: achariya.sa@chula.ac.th

1 STAR, Molecular Biology Research on Animal Oncology, Department of Pathology, Faculty of Veterinary Science, Chulalongkorn University, Bangkok, Thailand

2 Department of Small animal clinic, Department of Companion animals and wildlife clinic, Faculty of Veterinary Medicine, Chiangmai University, Chiangmai, Thailand

References

- [1] Ashton-Key, M., Diss, T.C. and Isaacson. 1996. Detection of *Helicobacter pylori* in gastric biopsy and resection specimens. *J. Clin. Pathol.* 49: 107-111.
- [2] Barber, M. and Franklin, R.H. 1946. Bacteriology and duodenum in cases of peptic ulcer and gastric carcinoma. *Br. Med. J.* 1: 951-953.
- [3] Berg, D.E., Hoffman, P.S., Appelmelk, B.J., Kusters, J.G. 1997. The *Helicobacter pylori* genome sequence: genetic factors for long life in the gastric mucosa. *Trends Microbiol.* 5(12): 468-474.
- [4] Blanchard, J.F. and Czinn, S.J. 2001. *Helicobacter pylori* acquisition and transmission: Where does it all begin ? [editorial]. *Gastroenterology*.121: 483-490
- [5] Buczolits, S., Hirt, R., Rosengarten, R. and Busse, H.J. 2003. PCR-based genetic evidence for occurrence of *Helicobacter pylori* and novel *Helicobacter* species in the canine gastric mucosa. *Vet. Microbio.* 95: 259-270.
- [6] Cattoli, G., van Vugt, R., Zanoni, R.G., Sanguinetti, V., Chiocchetti, R., Gualtieri, M., Vandenbroucke-Graals W. and Kusters, J.G. 1999. Occurrence and characterization of gastric *Helicobacter* spp. in naturally-infected dogs. *Vet. Microbiol.* 70: 239.
- [7] Deltenre, M. and de Koster, E. 2000. How come I've got it ? (A review of *Helicobacter pylori* transmission). *Eur. J. Gastroenterol. Hepatol.* 12: 479-482.
- [8] Dewhirst, F.E., Fox, J.G. and On, S.L. 2000. Recommended minimal standards for describing new species of the genus *Helicobacter*. *Int. J. Syst. Evol. Microbiol.* 50 (6): 2231-2237.
- [9] Dunn, B.E., Cohen, H. and Blaser, M.J. 1997. *Helicobacter pylori*. *Clin. Microbiol. Rev.* 10: 720-741.
- [10] Eaton, K.A. 1999. Man bites dog : *Helicobacter* in the new millennium [editorial]. *J. Vet. Intern. Med.* 13: 505-506.

- [11] Eaton, K.A., Dewhirst, F.E., Paster, B.J., Tzellas, N., Coleman, B.E., Paola, J. and Sherding, R. 1996. Prevalence and varieties of *Helicobacter* species in dogs from random sources and pet dogs: animal and public health implications. *J. Clin. Microbiol.* 34: 3165-3170.
- [12] Eaton, K.A., Dewhirst, F.E., Paster, B.J., Tzellas, N., Coleman, B.E., Paola, J. and Sherding, R. 1996. Prevalence and varieties of *Helicobacter* species in dogs from random sources and pet dogs: animal and public health implications. *J. Clin. Microbiol.* 34: 3165-3170.
- [13] Esteves, M.I., Schrenzel, M.D., Marini, R.P., Taylor, N.S., Xu, S., Hagen, S., Feng, Y., Shen, Z. and Fox, J.G. 2000. *Helicobacter pylori* gastritis in cats with long-term natural infection as a model of human disease. *Am. J. Pathol.* 156(2): 709-721.
- [14] Flatland, B. 2002. *Helicobacter* Infection in Humans and Animals. *Compendium.* 24(9): 688-696.
- [15] Fox, J.G. and Lee, A. 1997. The role of *Helicobacter* species in newly recognized gastrointestinal disease of animals. *Lab. Anim. Sci.* 47: 222-255.
- [16] Fox, J.G. 1998. Gastric helicobacters, in Greene CE (ed.): *Infectious Diseases of the Dog and Cat*. Philadelphia, W.B. Saunders Co. 229-233.
- [17] Fox, J.G., Correa, P., Taylor, N.S., Lee, A., Otto, G., Murphy, J.C. and Rose, R. 1990. *Helicobacter mustelae*-associated gastritis in ferrets. An animal model of *Helicobacter pylori* gastritis in humans. *Gastroenterology.* 99: 352-361.
- [18] Fox, J.G. and Lee, A. 1997. The role of *Helicobacter* species in newly recognized gastrointestinal disease of animals. *Lab. Anim. Sci.* 47: 222-255.
- [19] Freedberg, A.S. and Barron, L.E. 1940. The presence of spirochactes in human gastric mucosa. *Am. J. Dig. Dis.* 38: 443-445.
- [20] Fujioka, T., Murakami, K., Kodama, M., Kagawa, J., Okimoto, T. and Sato, R. 2002. *Helicobacter pylori* and gastric carcinoma from the view point of animal model. *Keio. J. Med.* 51(suppl. 2): 69-73.
- [21] Geyer, C., Colbatzky, F., Lechner, J. and Hermanns, W. 1993. Occurrence of spiral-shaped bacteria in gastric biopsies of dogs and cats. *Vet.Rec.* 133: 18-19.
- [22] Graham, D.Y. 1997. *Helicobacter pylori* infection in the pathogenesis duodenal ulcer and gastric cancer: a model. *Gastroenterology.* 113:1943-1911.
- [23] Graham, D.Y. and Yamaoka, Y. 1998. *Helicobacter pylori* and CagA: relationships with gastric cancer, duodenal ulcer and reflux esophagitis and its complications. *Helicobacter.* 3:145-151.
- [24] Hall, J.A. 2000. Diseases of the stomach, in Ettinger, S.J., Feldman, E.C.(eds): *Textbook of Veterinary Internal Medicine*. Philadelphia. W.B. Saunders: 1154-1181.

- [25] Handt, L.K., Fox J.G., Stalis, I.H., Rufo, R., LEE., G., Linn, J., Li., X. and Kleanthous, H. 1995. Characterization of feline *Helicobacter pylori* strains and associated gastritis in a colony of domestic cats. *J. Clincl. Microbiol.* 33(9): 2280-2289.
- [26] Happonen, I., Saari, S., Castren, L., Tyni, O., Hanninen, M.L. and Westermarck, E. 1996. Occurrence and topographical mapping of gastric *Helicobacter*-like organisms and their association with histopathological changes in apparently healthy dogs and cats. *J. Vet. Med. A.* 43: 305-315.
- [27] Happonen, I., Linden, J., Saari, S., Karjalainen, M.L., JALAVA, K. and Weastermarck, E. 1998. Detection and effects of helicobacters in healthy dogs and dogs with signs of gastritis. *J. Am. Vet. Med. Assoc.* 213: 1767.
- [28] Henry, G.A., Long, P.H., Burns, J.L. and Charbonneau, D.L. 1987. Gastric spirillosis in Beagles. *Am. J. Vet. Res.* 48: 831-836.
- [29] Herbrink, P. and van Doorn, L.J. 2000. Serological methods for diagnosis of *Helicobacter pylori* infection and monitoring of eradication therapy. *Eur. J. Clin. Microbiol. Infect. Dis.* 19: 164-173.
- [30] Hermanns, W., Kregel, K., Breuer, W. and Lechner, J. 1995. *Helicobacter*-like organisms: histopathological examination of gastric biopsies from dogs and cats. *J. Comp. Pathol.* 112: 307-318.
- [31] Huang, J.Q., Sridhar, S., Chen, Y. and Hunt, R.H. 1998. Meta-analysis of the relationship between *Helicobacter pylori* seropositivity and gastric cancer. *Gastroenterology.* 114: 1169-1179.
- [32] Issacson, P.G. and Spencer, J. 1993. Is gastric lymphoma an infection disease? *Hum. Pathol.* 24:569-570.
- [33] Laine, L., Lewin , D.N., Naritoku, W. and Cohen, H. 1997. Prospective comparison of H&E, Giemsa and Genta stains for the diagnosis of *Helicobacter pylori*. *Gastrointest. Endosc.* 45: 463-467.
- [34] Lee, A., Krakowka, S., Fox, J.G., Otto, G., Eaton, K.A. and Murphy, J.C. 1992. Role of *Helicobacter felis* in chronic canine gastritis. *Vet. Pathol.* 29: 487-494.
- [35] Lee, A., Krakowka, S., Fox, J.G., Otto, G., Eaton, K.A. and Murphy, J.C. 1992. Role of *Helicobacter felis* in chronic canine gastritis. *Vet. Pathol.* 29: 487-494.
- [36] Lee, A., Fox, J.C. and Hazell, S. 1993. Pathogenicity of *Helicobacter pylori*: a perspective. *Infect. Immun.* 61: 1601-1610.
- [37] Lee, A. and O'Rourke, J.1993. Gastric bacteria other than *Helicobacter pylori*. *Gastroenterol. Clin. North. Am.* 22(1): 21-42.
- [38] Lin, S.K., Lambert, J.R. and Schembri, M.A. 1994. *Helicobacter pylori* prevalence in endoscopy and medical staff. *J. Gastroenterol. Hepato.* 9: 319-324.

- [39] Marais, A., Mendz, G.L., Hazell, S.L., Megraud, F. 1999. Metabolism and genetics of *Helicobacter pylori*: the genome era. *Microbiol. Mol. Biol. Rev.* 63(3): 642-674.
- [40] Marini, R.P., Labato, M.A., Taylor, N.S., Schrenzel, M.D., Xu, S., Speilman, B., Shen, Z., Yan, L., Feng, L. and Fox, J.G. 2000. Failure to detect *Helicobacter pylori* in gastric endoscopic biopsies from dogs and cats. *Contemp. Topics Lab. Anim. Sci.* 39: 52.
- [41] Montiero, L., de Mascarel, A. and Sarrasqueta, A.M. 2001. Diagnosis of *Helicobacter pylori* infection: Noninvasive methods compared to invasive methods and evaluation of two new tests. *Am. J. Gastroenterol.* 96: 353-357.
- [42] Moss, S.F., Legon, S. and Bishop, A.E. 1992. Effect of *Helicobacter pylori* on gastric somatostatin in duodenal ulcer disease. *Lancet* 340(8825): 930-932.
- [43] Nakajima, S., Graham, D.Y., Hattori, T. and Bamba, T. 2000. Strategy for treatment of *Helicobacter pylori* infection in adults. Updated indications for test and eradication therapy suggested in 2000. *Curr. Pharm. Design.* 6(15): 1503-1514.
- [44] Nomura, A., Stemmerman, G.N., Chyou, P.H., Kato, I., Perez-Perez, G.I. and Blaser, M.J. 1991. *Helicobacter pylori* infection and gastric carcinoma among Japanese Americans in Hawaii. *N. Engl. J. Med.* 325: 1132-1136.
- [45] Parsonnet, J., Friedman, G.D., Vandersteen, D.P., Chang, Vogelman, J.H., Orentreich, N. and Sibley, R.K. 1991. *Helicobacter pylori* infection and the risk of gastric carcinoma. *N. Engl. J. Med.* 325: 1127-1136.
- [46] Peyrol, S., Lecoindre, P., Berger, I., Deleforge, J. and Chevallier, M. 1998. Differential pathogenic effect of two *Helicobacter*-like organisms in dog gastric mucosa. *J. Submicrosc. Cytol. Pathol.* 30: 425.
- [47] Pirarat, N., Makbunsri, T., Sukkamon, S., Amornchailertrat, S., Rungsipipat, A., Sunyasootcharee, B. 2003. The relationship between pathological gastric changes and *Helicobacter* spp. in dog. *Thai J. Vet. Med.* 33(3): 73-80.
- [48] Prachasilpchai, W., Prachasilpchai W., Nuanualsuwan S., Chatsuwan T., Techangamsuwan S., Wangnaitham S., Sailasuta A. 2007. Diagnosis of *Helicobacter* spp. infection in canine stomach. *J. Vet. Sci.* 8(2): 139-145.
- [49] Queiroz, D.M.M., Rocha, G.A., Mendes, E.N., Moura, S.B., Oliveira, A.M.R. and Miranda, D. 1996. Association between *Helicobacter* and gastric ulcer disease of the pars esophagea in swine. *Gastroenterology.* 111: 19-27.
- [50] Radin, M.J., Eaton, K.A., Krakowka, S., Morgan, D.R., Lee, A., Otto, G. and Fox, J. 1990. *Helicobacter pylori* gastric infection in gnotobiotic beagle dogs. *Infect. Immun.* 58(8): 2606-2612.
- [51] Rossi, G., Rossi, M., Vitali, C.G., Fortuna, D., Burrioni, D., Pancotto, L., Capecchi, S., Sozzi, S., Renzoni, G., Braca, G., Del Giudice, G., Rappuoli, R., Ghiara, P. and Taccini, E. 1999. A conventional beagle dog model for acute and chronic infection with *Helicobacter pylori*. *Infect. Immun.* 67: 3112.

- [52] Scott, D., Weeks, D., Melchers, K., Sachs, G. 2000. UreI-mediated urea transport in *Helicobacter pylori*: an open and shut case? *Trends Microbiol.* 8(8): 348-349.
- [53] Simpson, K.W., McDonough, P.L., Strauss- Ayali, Chang, Y.F., Harpending, P. and Valentine, B.A. 1999 (a). *Helicobacter pylori* infection in dogs: effect on gastric structure and function. *Vet. Pathol.* 36: 237-248.
- [54] Simpson, K.W., Strauss- Ayali, D., McDonough, P.L., Chang, Y.F. and Valentine, B.A. 1999 (b). Gastric function in dogs with naturally acquired gastric *Helicobacter* spp. infection. *J. Vet. Intern. Med.* 13: 507-515.
- [55] Smoot, D.T. and Hamilton, F.A. 1995. Summary of the national institutes of health consensus development conference on *Helicobacter pylori*. *Gastrointest. Dis. Today.* 4: 1-10.
- [56] Solnick, J.V., O'Rourke, J., Lee, A., Paster, B.J., Dewhirst, F.E., Tompkins, L.S. 1993. An uncultured gastric spiral organism is a newly identified *Helicobacter* in humans. *J. Infect. Dis.* 168(2): 379-385.
- [57] Solte, M., Bayerdorffer, E. and Morgner, A. 2002. *Helicobacter* and gastric MALT lymphoma. *Gut* 50(Suppl3): 19-24.
- [58] Tomb, J.F., White, O., Kerlavage, A.R., Clayton, R.A., Sutton, G.G., Fleischmann, R.D., Ketchum, K.A., Klenk, H.P., Gill, S., Dougherty, B.A., Nelson, K., Quackenbush, J., Zhou, L., Kirkness, E.F., Peterson, S., Loftus, B., Richardson, D., Dodson, R., Khalak, H.G., Glodek, A., McKenney, K., Fitzgerald, L.M., Lee, N., Adams, M.D., Venter, J.C. 1997. The complete genome sequence of the gastric pathogen *Helicobacter pylori*. *Nature.* 388(6642): 539-547.
- [59] Tompkins, L.S. and Falkow, S. 1995. The new path to preventing ulcers. *Science.* 267: 1621-1622.
- [60] Vaira, D., Holton, J. and Menegatti, M. 2000. Review article: Invasive and noninvasive tests for *Helicobacter pylori* infection. *Aliment. Pnarmacol. Ther.* 14(Suppl. 3): 13-22.
- [61] Yamasaki, K., Suematsu, H. and Takahashi, T. 1998. Comparison of gastric lesions in dogs and cats with and without gastric spiral organisms. *J. Am. Vet. Med. Assoc.* 212: 529-533.
- [62] Zucca, E., Bertoni, F., Rogerreo, E., Bosshard, G., Cazzaniga, G., Pedrinis, E., Biondi, A. and Cavalli, V. 1998. Molecular analysis of the progression from *Helicobacter pylori*-associated chronic gastritis to mucosa-associated lymphoid tissue lymphoma of the stomach. *N. Eng. J. Med.* 338: 804-810.

