

We are IntechOpen, the world's leading publisher of Open Access books Built by scientists, for scientists

6,900

Open access books available

186,000

International authors and editors

200M

Downloads

Our authors are among the

154

Countries delivered to

TOP 1%

most cited scientists

12.2%

Contributors from top 500 universities



WEB OF SCIENCE™

Selection of our books indexed in the Book Citation Index
in Web of Science™ Core Collection (BKCI)

Interested in publishing with us?
Contact book.department@intechopen.com

Numbers displayed above are based on latest data collected.
For more information visit www.intechopen.com



Thoracic Reconstruction

Christodoulos Kaoutzanis, Tiffany N.S. Ballard and Paul S. Cederna

Additional information is available at the end of the chapter

<http://dx.doi.org/10.5772/54137>

1. Introduction

The chest wall is a stable yet flexible structure that provides protection for the intrathoracic organs and plays an important role in respiratory function. The integrity of the chest wall can be affected by a variety of congenital conditions, pathologic processes, or traumatic injuries. The principal goals of reconstruction are to restore the functional and structural integrity of the chest wall to protect the underlying vital organs. It is also essential to consider the aesthetic outcome of the reconstruction, particularly in situations where there are no functional deformities. In every reconstruction, no matter what caused the underlying cause of the chest wall deformity, the bony thorax and the soft tissues must always be considered and addressed. Despite significant improvements in surgical techniques and perioperative care, the management of patients requiring chest wall reconstruction remains an ongoing challenge for any surgeon. Close collaboration between thoracic and reconstructive plastic surgeons is essential in obtaining optimal functional and aesthetic outcomes.

2. Anatomy of the chest wall

The skeleton of the thorax is an osseo-cartilaginous cage with a conical shape. It consists of the sternum, the clavicles, the scapulae, twelve pairs of ribs, and twelve thoracic vertebrae. The anterior surface is formed by the sternum and costal cartilages (Figure 1). Posteriorly, it is formed by the twelve thoracic vertebrae, the posterior portions of the ribs, and the paired scapulae. The ribs are separated by the intercostal spaces to form the lateral chest wall.

All twelve pairs of ribs are connected posteriorly with the vertebral column. The first seven rib pairs, which are also called “true” ribs, are secured to the sternum anteriorly through intervention of the costal cartilages. The remaining five rib pairs, which are also called “false” ribs, do not directly articulate with the sternum. Of these, the 8th, 9th and 10th ribs have confluent attachments of their cartilage with one another at the costal margin. The last

two ribs are also known as “floating” ribs; they are only attached to the posterior vertebrae and remain free anteriorly. Each rib has a head, a neck and a shaft (Figure 2). The head has two facets. The superior facet is used for articulation with the upper vertebrae, whereas the inferior facet is used for articulation with its own vertebrae creating the costovertebral joint. The facet tubercle of the neck of the rib articulates with the transverse process of its own vertebra creating the costotransverse joint. The inferior aspect of the shaft encompasses the costal groove, where the intercostal vessels and nerve run.

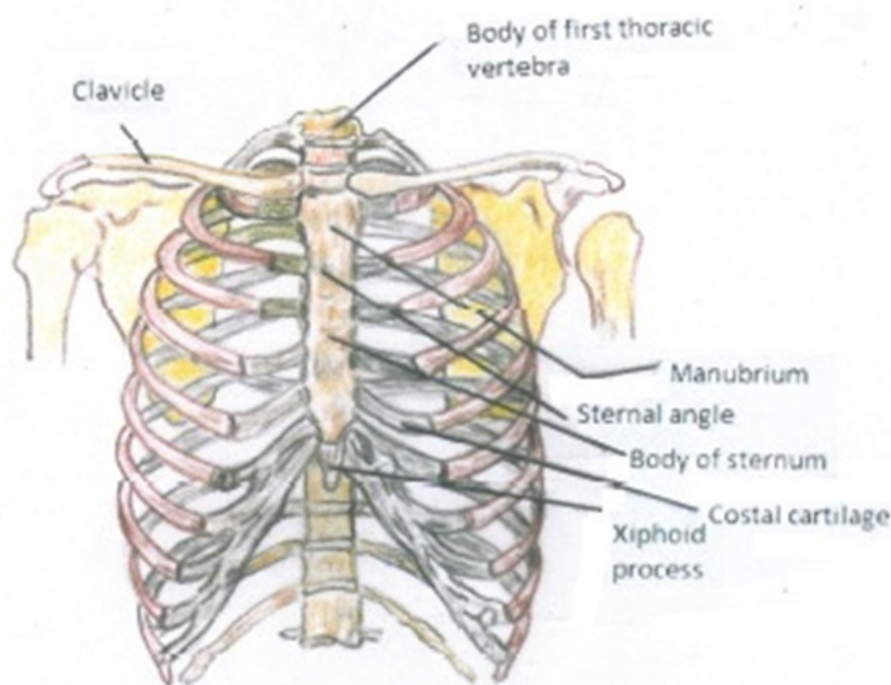


Figure 1. Anterior view of the skeleton of the thorax.

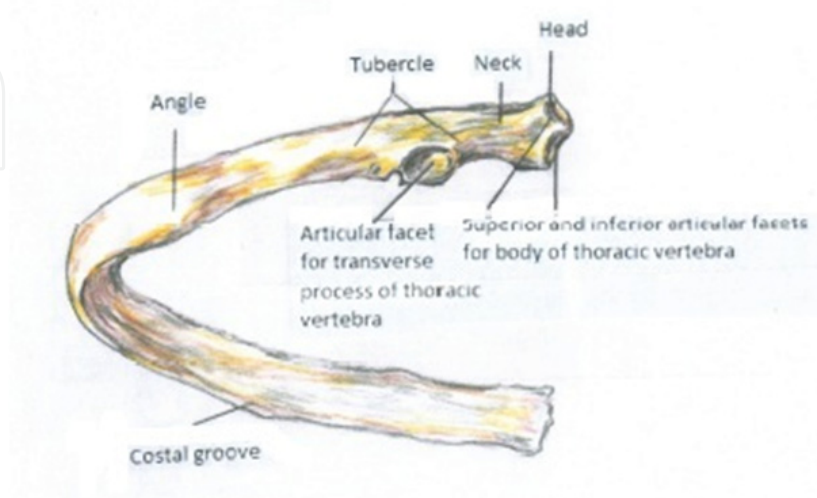


Figure 2. Posterior view of a typical rib.

The spaces between the ribs are filled by the intercostal musculature, which consists of three layers. The external intercostal muscles, with fibers oriented inferoanteriorly, extend from the tubercles of the ribs posteriorly to the costochondral articulation anteriorly. They terminate in thin membranes, the anterior intercostal membranes, which are connected medially with the sternum. The intermediate layer is formed by the internal intercostal muscles, which have fibers that are oriented superoanteriorly. The muscles extend from the sternum to the angle of the ribs posteriorly, where they are connected to the vertebral column by thin aponeuroses called the posterior intercostal membranes. The innermost intercostal muscle is the least developed layer and has fibers oriented vertically or almost parallel to those of the internal intercostal muscle. The internal intercostal muscle extends from the plane of the costochondral articulations anteriorly to the plane of the medial margin of the scapula posteriorly.

The intercostal neurovascular bundle lies beneath the internal intercostal muscles. It is comprised of intercostal arteries, veins and nerves. The anterior and posterior intercostal arteries originate from different vessels but anastomose with each other. The anterior intercostal arteries arise from the internal mammary arteries. The first two posterior intercostal arteries usually arise from the costocervical trunk, which is a branch of the subclavian artery. The remaining nine arteries are branches of the thoracic aorta. The intercostal veins are found superior to the arteries but follow the course of the arteries along the inferior aspect of each rib. They drain into the azygous, hemiazygous and accessory hemiazygous veins.

The dynamic elasticity of the bony and soft tissue components of the chest wall allow for changes in the intrathoracic cavity, hence maintaining the mechanics of ventilation. The muscles of the chest wall play a significant role in this process. The diaphragm and the intercostal muscles represent the primary muscles of respiration, whereas the serratus, pectoralis major and minor, scalenes, latissimus dorsi, trapezius, sternocleidomastoids, and deltoid muscles constitute the main secondary respiratory muscles.

During quiet respiration, inspiration occurs when the diaphragm and the external intercostal muscles contract. The diaphragm is responsible for approximately 75% of the work of breathing, and the intercostal muscles for the remaining 25%. Contraction of the diaphragm causes an increase in the vertical dimensions of the thoracic cavity, while contraction of the external intercostal muscles elevates the ribs and expands the transverse dimensions of the thorax. This reduces the intrathoracic pressure, resulting in flow of atmospheric air into the lungs. Expiration is a passive process that is facilitated by the elastic recoil of the lungs. This increases intrathoracic pressure, which in turn leads to an increase in intrapulmonary pressure above the atmospheric pressure. At that point outflow of air from the lungs occurs. The secondary muscles of respiration are used in addition to the primary respiratory muscles during periods of respiratory distress. Several chest wall muscles have been reported to facilitate inspiration including the serratus, pectoralis, scalenes, latissimus dorsi, deltoid, and trapezius. Active expiration is achieved with contraction of the internal and innermost intercostal muscles as well as the abdominal muscles.

3. Etiology of chest wall defects

Chest wall defects can be divided into acquired and congenital defects. They can involve bony structures, soft tissues, or a combination of both. Several pathological processes can contribute to the development of acquired defects such as neoplasm, infection, radiation injury, and trauma. Congenital defects, although less common and usually asymptomatic, do occasionally cause cardiopulmonary compromise and can be a reconstructive challenge.

3.1. Congenital chest wall deformities

Congenital chest wall anomalies include pectus excavatum (funnel chest), pectus carinatum (pigeon chest), Poland syndrome, asphyxiating thoracic dystrophy (Jeune syndrome), and assorted sternal anomalies such as sternal clefts and sternal hypoplasia. Pectus excavatum is the most common congenital chest wall anomaly (90 percent), followed by pectus carinatum (5 to 7 percent), cleft sternum, pentalogy of Cantrell, asphyxiating thoracic dystrophy, and spondylothoracic dysplasia [1].

Pectus excavatum is a congenital chest wall deformity of unknown etiology, which produces a concave appearance in the anterior chest wall (Figure 3). It is believed that the sternum is pushed in by abnormal growth at the articulation with the cartilage and the ribs. Two different forms of this chest wall deformity have been described. The most common form is seen as an acute posterior curve of the sternum with its deepest point just above the xiphoid process and sharp curvatures in the lower costal cartilages on each side of the sternum. The second type is characterized by a widespread superficial anomaly between the two nipples. The manubrium can be depressed, and there is usually depth asymmetry with one side being deeper than the opposite side. Other associated deformities can be observed during childhood development such as a broad thin chest lateral to the anterior pectus deformity, internally rotated and depressed shoulders, flaring of the costal margins, protuberant abdomen, kyphosis, and scoliosis.

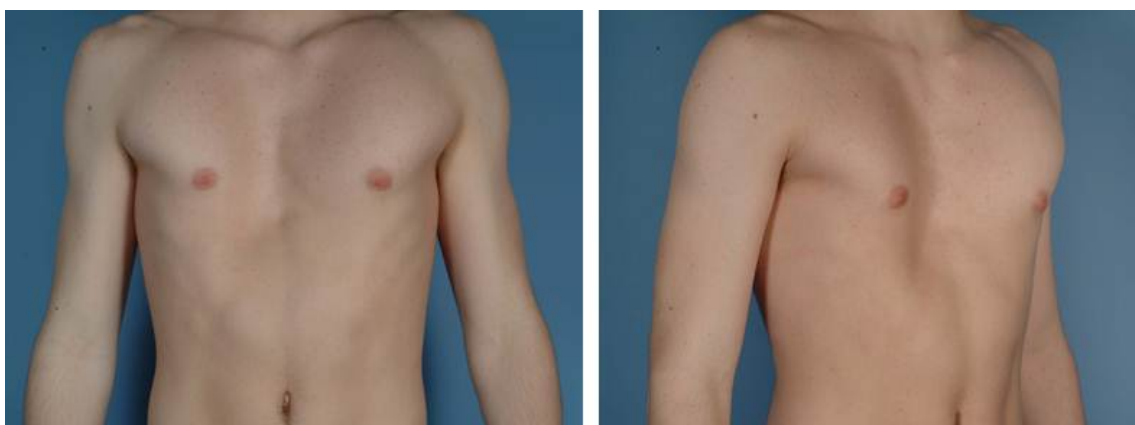

Figure 3. A 15-year-old male with a symmetric pectus excavatum deformity.

The condition is generally noticed at birth and the majority of cases are diagnosed in the first year of life. It is typically asymptomatic during early childhood unless the patient's

sternal depression is unusually severe leading to cardiac or pulmonary compromise. It is not uncommon for patients to first present to the surgeon following the rapid skeletal growth of adolescence, which can worsen the pectus excavatum deformity and make the condition symptomatic. Some affected individuals develop chest and back pain, which is believed to be musculoskeletal in origin or posture related. With regard to the pulmonary function of affected individuals, there is scientific evidence to suggest that dyspnea upon exertion in patients with the deformity is predominantly due to the decrease in pulmonary reserve [2-4]. Although it has been advocated that the decrease in intrathoracic volume may be a contributing factor in the pulmonary impairment seen with the deformity, this association is difficult to prove given the wide variation of pulmonary function amongst healthy individuals, as well as the correlation of pulmonary function with body habitus and physical activity. In patients with severe pectus excavatum, the heart may be displaced into the left chest causing compression of the right ventricle and dramatic impedance of right ventricular outflow. Dr. Ravitch was one of the first to make these observations [5,6]. Several more recent studies have demonstrated improvement in the cardiac function following operative repair of the pectus deformity [7,8].

There are opposing beliefs regarding whether pectus excavatum is a predominantly cosmetic problem or a disorder that leads to significant physiologic impairment. Affected individuals frequently desire correction for aesthetic purposes. The distorted appearance of the chest, especially in young teenagers, can be very distressing resulting in problems with psychosocial well-being, emotional functioning, body image perception, and self-esteem. However, adolescent patients also often present with compression-like discomfort in the anterior chest, dyspnea on exertion, exercise-induced wheezing, palpitations, and tachycardia. The recognition of symptoms and the recommendation for surgical correction remain controversial.

Pectus carinatum represents a spectrum of anterior chest wall protrusion deformities. The classical deformity, also known as “chicken breast” or “pigeon breast” (chondrogladiolar), is characterized by anterior protrusion of the median and lower portions of the sternum associated with lower bilateral costal depression. A less common type, also known as “Pouter pigeon breast” (chondromanubrial), is seen with anterior protrusion of the manubriosternal joint with depression of the body of the sternum. There is accompanying protrusion of the second to the ninth costal cartilages, bilaterally. Lateral deformities have also been reported such as unilateral protrusion of the costal cartilages with sternal rotation about its long axis to the opposite side. *Pectus carinatum* is primarily a symmetrical deformity, but in about one-third of the cases, asymmetric or mixed deformities are identified.

Pectus carinatum occurs approximately one-tenth as often as pectus excavatum. Unlike pectus excavatum, it is rarely noticed at birth. It is typically identified in mid-childhood and accentuated during the rapid skeletal growth in early adolescence. Although the etiology remains unclear, a congenital component with abnormalities in connective tissue development has been postulated given the increased incidence of positive family history and associated anomalies such as Marfan’s syndrome and congenital heart disease. A recent

review of 260 cases with pectus carinatum revealed the presence of positive family history of chest wall deformities in at least 25% of patients [9]. Clinical manifestations of pectus carinatum are quite common and include dyspnea, exertional tachypnea, decreased endurance, and asthmatic-like symptoms [9,10]. Cardiac and hemodynamic changes have also been reported [11]. The psychosocial and aesthetic impairment associated with the deformity is one of the main reasons for patients to seek medical attention and should not be underestimated.

Poland syndrome is a severe form of chest wall and breast hypoplasia. It was first described in the 18th century but the label was not used until 1962 when Clarkson operated on a patient with similar anomalies to that described by Dr. Poland [12]. The initial description included absence of the pectoralis major and minor muscles associated with syndactyly of the ipsilateral hand [13]. Numerous other components of the syndrome have been described, and each of these components can occur with variable severity. The chest wall involvement may include hypoplasia or aplasia of the pectoralis major and minor muscles. Other components of the syndrome include absence of the anterior portions of the second to fifth ribs and associated costal cartilages, as well as hypoplasia or aplasia of the the latissimus dorsi, deltoid, infraspinatus and supraspinatus muscles. The overlying skin and subcutaneous tissue abnormalities include limited subcutaneous chest wall fat, absence of axillary hair, and hypoplasia or aplasia of the breast and nipple. The most common upper extremity abnormalities include syndactyly and brachydactyly, primarily involving the central three digits. The extent of the involvement however, can range from hypoplasia or absence of a single digit to complete agenesis of the arm. Poland syndrome may also be associated with several other anomalies such as Sprengel deformity (winging of the scapula), pectus excavatum, scoliosis, foot anomalies, dextrocardia, renal hyperplasia, and blood dyscrasias.

Most cases of Poland syndrome are sporadic, but familial patterns of inheritance have been reported [14,15]. The etiology of Poland Syndrome is unknown. The syndrome is present from birth, but because the functional disability is usually mild, patients usually present late for evaluation and treatment of the chest deformity and breast asymmetry [16]. Three main factors impact the timing and options for reconstruction: breast development, existence of a latissimus dorsi muscle, and degree of chest wall deformity.

Asphyxiating thoracic dystrophy (Jeune's syndrome) is a rare autosomal recessive disorder characterized by skeletal dysplasias, with respiratory, renal and hepatic manifestations [17-19]. It causes dwarfism with short ribs, short limbs, and characteristic radiologic changes in the ribs and pelvis. There is variability in the severity of clinical and radiologic features. The narrow, bell-shaped thorax and protuberant abdomen together with the short, horizontally placed ribs significantly restrict chest expansion and promote alveolar hypoventilation. The extent of pulmonary impairment varies from negligible to rapidly fatal. Other features include abundant and irregular costal cartilages, high transversely placed clavicles, a small hypoplastic pelvis, variable micromelia, and short digits.

Sternal cleft is an entity within the spectrum of sternal defects related to failure of ventral fusion of the sternum. It is rare and the least severe of the four main congenital chest wall

anomalies. The other three groups of sternal defects include thoracic ectopia cordis, thoracoabdominal ectopia cordis, and cervical ectopia cordis.

Sternal cleft results from failure of fusion of the sternal bars that typically occurs by the eighth week of gestation. The anomaly is characterized by partial or complete separation of the sternum with a normally positioned intrathoracic heart [20]. Despite the sternal separation, skin coverage is intact with normal pericardium and diaphragm. In most infants, the deformity is asymptomatic. Occasionally, functional problems can arise such as respiratory impairment from the paradoxical movement of the sternal defect. Most affected individuals have an upper sternal cleft with a V- or U-shape appearance. Rarely, this can extend down to the xiphoid or be complete. Lower sternal defects are much less common and are primarily associated with thoracic and thoracoabdominal ectopia cordis [20].

Several differences exist between the sternal cleft and the other three conditions. Most importantly, the heart is in the normal position in individuals with sternal cleft, but displaced in the other three conditions. In addition, intrinsic congenital heart disease is rarely seen in sternal clefts as opposed to individuals with the other sternal defects.

3.2. Chest wall tumors

Chest wall tumors include a wide spectrum of bony, soft tissue and cartilaginous neoplasms that can present a diagnostic and therapeutic challenge. They can be classified as primary, locally invasive or metastatic. Primary tumors of the bony skeleton or soft tissues can be further classified as benign or malignant. Chest wall tumors may also result from cancers of contiguous structures, such as the pleura, mediastinum, muscle, lung, breast, and skin. These malignancies can invade adjacent tissues either locally or regionally. The sternum, ribs, clavicles and chest wall soft tissues are common areas of metastasis from primary malignant processes of distant primary sites, such as the breast, lungs, kidneys, and thyroid gland. Benign nonneoplastic conditions, such as cysts and inflammation, can also present as chest wall tumors. All primary tumors of the chest wall, including skeletal and soft tissue neoplasms, account for only 2% of all body tumors. However, more than 50% of these tumors are malignant, thus making their prompt recognition essential in the management and treatment process [21]. Some of the common types of primary benign and malignant tumors will be discussed below.

In general, chest wall tumors start as asymptomatic slowly enlarging nodules that usually progress to painful and sometimes ulcerating lesions. Malignant tumors are much more likely to cause pain as opposed to benign disease. Appropriate diagnostic evaluation includes a thorough patient history and physical examination, as well as evaluation of laboratory parameters and radiological studies. Plain chest radiographs, computed tomography (CT) and bone scans as well as magnetic resonance imaging (MRI) are the most common imaging modalities used. Tissue diagnosis by histologic examination is also usually warranted. The diagnostic yield of the available techniques is inversely related to the invasiveness of the procedure. Fine needle aspiration has a poor diagnostic yield, core needle biopsy has a good diagnostic yield, incisional biopsy has an excellent diagnostic

yield, and excisional biopsy allows for a definitive diagnosis. Selection of the biopsy technique must be individualized and several factors, such as the tumor type and size, should be considered.

The surgical treatment of the majority of chest wall tumors requires careful planning and execution. When surgery is curative, the objective is a wide excision to extirpate the tumor with adequate margins. The extent of the resection should not be restricted by the size of the resulting defect as multiple reconstructive options are generally available. The en bloc resection includes the skin and soft tissue overlying the tumor, the involved sternum, primarily involved and/or adjacent ribs, as well as any attached structures such as the lung, pleura and pericardium. Similar basic principles apply for chest wall resection of any infectious or inflammatory process. Resection should be wide enough to obtain healthy viable tissue at the edges of the wound for proper healing. In certain occasions, if the lesion is deep and the overlying skin is intact, it may be appropriate to spare the skin to facilitate closure.

3.2.1. Benign bone tumors

Fibrous dysplasia is a slowly-enlarging painless lesion. It accounts for approximately 30% of benign chest wall tumors. It originates from the rib shaft and is characterized by fibrous replacement of the medullary cavity of the rib. Radiographically, it has a characteristic ground-glass appearance on plain films. In the presence of multiple lesions associated with skin pigmentation and precocious puberty, Albright's syndrome should be suspected. Conservative management is the treatment of choice. However, if the lesion becomes large enough to cause pressure symptoms and/or pathologic fractures, surgical excision should be considered.

Chondroma is a slowly growing asymptomatic mass arising from the costochondral junction anteriorly. It tends to occur during the second or third decade of life and constitutes about 15% of all benign bony neoplasms of the chest wall. Radiographically, chondroma appears as a lytic lesion with sclerotic margins, thus making a distinction from its malignant counterpart, chondrosarcoma, quite difficult. Often, chondromas cannot be distinguished from chondrosarcomas even on incisional biopsy. Therefore, these lesions should be managed as if they were malignant and complete surgical excision should be performed.

Osteochondroma is the most common benign bone tumor accounting for about 50% of benign chest wall tumors. It originates from the metaphyseal component of the rib and presents as a pedunculated mass capped by viable cartilage. Stippled calcification is often present within the tumor and gives a characteristic radiological appearance. Familial osteochondromatosis is a recognized variant that manifests with multiple rib lesions. Multiple lesions can also be encountered throughout the body in the triad of Albright's syndrome. Surgical resection of an osteochondroma is indicated when the lesion increases in size or becomes symptomatic. The onset of pain in a previously asymptomatic lesion should alert the treating physician to the possibility of malignant degeneration of the tumor.

3.2.2. Malignant bone tumors

Chondrosarcoma is one of the most common primary malignant bone neoplasms, accounting for approximately 30% of such tumors. It tends to occur after the third or fourth decade of life and typically presents with a slowly enlarging painful anterior chest wall mass involving the anterior costochondral junctions of the sternum. The etiology is unknown, however, an association with local trauma to the chest has been made. It has also been suggested that it could arise secondary to malignant degeneration of benign cartilaginous tumors such as chondromas and osteochondromas. Radiographically, a chondrosarcoma has a characteristic appearance as a lobulated mass with poorly defined margins, destroying cortical bone. The radiographic appearance tends to be very similar to that of a benign chondroma. Definitive diagnosis can only be made pathologically, but at times, histological findings can resemble that of chondromas, making the diagnosis challenging. Resection with a 4cm margin is recommended to provide the best chance of local control. Five-year survival after complete resection has been reported to be 70% [22].

Osteogenic sarcomas (osteosarcomas) usually occur in the long bones of the extremities, but can originate from the ribs and account for about 10% of all primary malignant bone neoplasms. They commonly affect teenagers and young adults. They are typically associated with pain. Unlike chondrosarcomas, they are rapidly enlarging and metastases are often present at initial evaluation. They have a characteristic “sunburst” pattern on chest radiographs. Metastatic work up is often indicated prior to the initiation of treatment. The treatment of osteogenic sarcomas includes wide resection of the tumor including the involved bone and adjacent soft tissues. Prognosis is poor and the five-year survival rate after complete excision can be as low as 20% [22]. Adjuvant chemotherapy has been reported to increase the survival rate up to 60% [23].

Ewing’s sarcoma can involve the ribs and accounts for approximately 10% of all primary malignant tumors of the chest wall. Patients usually present with a painful enlarging mass. Fever, malaise, anemia and leukocytosis may also be present. Radiographically, an “onion peel” appearance from periosteal elevation and bone remodeling is typically seen, which is characteristic but not pathognomonic. A large proportion of patients with apparently localized disease at diagnosis have occult metastatic disease. Metastases display a preference for the lung and central nervous system. Treatment incorporates chemotherapy with surgery and/or radiation therapy. Local disease control is critical to long-term cure and definitive surgical margins are desirable. Radiation therapy is considered for local control in poor surgical candidates.

3.2.3. Soft tissue tumors

A variety of benign soft tissue tumors of the chest wall have been reported including fibromas, lipomas, giant cell tumors, connective tissue tumors, neurogenic tumors, and vascular tumors such as hemangiomas. Local excision is typically the treatment of choice.

Desmoid tumors can arise in any skeletal muscle but more than one-third develop in the shoulder and chest wall. They present as poorly circumscribed lesions and can encase nerves or vascular structures. Whatever the cause, there is a high risk of tumor recurrence if inadequately resected [24]. Therefore, aggressive wide surgical excision with negative margins is the most successful primary treatment modality for these tumors.

Sarcomas are the most common malignant soft tissue chest wall tumors. Pleomorphic undifferentiated sarcoma, previously known as malignant fibrous histiocytoma, and rhabdomyosarcoma are the most frequent types. Unlike pleomorphic undifferentiated sarcoma, which typically presents in late adult life with a painless slowly growing mass, rhabdomyosarcoma occurs most frequently in children and young adults as a painless rapidly enlarging mass. Other tumors of the soft tissue chest wall include liposarcomas, neurofibrosarcomas and leiomyosarcomas. Surgical resection with wide margins is typically the standard treatment for all the above-mentioned tumors for local disease control.

3.3. Infection

Chest wall infections can be classified as primary and secondary. Primary infections occur spontaneously, whereas secondary infections can be caused by the progression of a preexisting disease process or as a complication of a previous procedure. Management of these infections must not be overlooked and intervention in a timely fashion is necessary to prevent or minimize potentially devastating consequences. Some of these infections are particularly challenging to treat due to their proximity to major vascular structures and the lack of substantial overlying soft tissues. Treatment options vary from antibiotic administration to complex resections with reconstruction.

The chest wall covers approximately 20% of the total body surface area and can be affected by all the common nonspecific soft tissue infections such as boils and furuncles. Soft tissue abscesses of the chest wall present with the same symptoms and signs of an abscess located anywhere else in the body. Abscesses involving the subpectoral or subscapular spaces can lead to a serious infection. In the majority of cases antibiotic therapy with incision and drainage of the abscess is sufficient treatment. Necrotizing soft tissue infections rarely occur but are rapidly spreading and highly lethal. They may occur postoperatively or as a complication of an empyema or trauma. A high index of suspicion, early diagnosis, and aggressive treatment with appropriate antibiotics and radical debridements are essential to their successful management. Delayed wound closure with skin grafting or muscle transfer has been used [25].

Sternal osteomyelitis, once a rare disorder, has become more common in the last few decades due to the increased frequency of coronary artery bypass grafting and prevalence of intravenous drug abuse. Primary infection is typically seen in intravenous drug abusers, whereas secondary infection is associated with coronary artery bypass grafting. Overall, the most common pathogen is *Staphylococcus aureus*, but *Pseudomonas aeruginosa* is the most common cause in intravenous drug abusers [26]. Several factors have been implicated in the development of poststernotomy osteomyelitis including diabetes, prolonged perfusion time,

a depressed cardiac output, excessive postoperative bleeding, re-exploration for the control of hemorrhage, length of postoperative intubation, and use of bilateral internal mammary arteries for cardiac revascularization [27,28]. Patients with poststernotomy osteomyelitis usually present with pain and drainage at the site. Occasionally, there is a palpable mass overlying the incision. Sternal instability may also be evident. The infection can extend deeply into the mediastinum. CT scan of the chest is the diagnostic study of choice. Treatment with antibiotics and aggressive surgical debridement of the infected area followed by muscle flap reconstruction yields the best clinical outcome [29].

The complexity of *median sternotomy wound infections* has challenged cardiothoracic and plastic surgeons over the last few decades. Prompt identification and treatment are crucial to prevent potentially lethal consequences such as extension to cardiac and aortic suture lines and intracardiac prostheses. It is well known that the surface appearance of the wound may look deceptively insignificant in a patient with a sternal infection. For instance, severe mediastinitis with sternal disruption may be hidden under a small draining sinus tract. Although sternotomy wound infections manifest as a continuum of clinical entities, Jones et al. divided them into three types [30]. Type 1a represents the patient with a suture abscess or infected wound hematoma superficial to the deep fascia, whereas type 1b is associated with exposure of the deep fascial suture layer. Treatment consists of wound drainage and wound packing to allow closure by secondary intention. Sometimes they may be secondarily closed when clean. Type 2a typifies a deeper process with an exposed stable sternotomy, while type 2b is associated with an unstable sternotomy. If the sternum is stable and there is no evidence of bacterial contamination of the parasternal fluid, debridement and closure of the wound may be appropriate. If the sternum is unstable but sterile with intact bilateral sternal blood supply, rewiring can be considered. However, if there is any doubt about the ability of the sternal bone stock to withstand rewiring, sternectomy with muscle flap closure is the safest option. Type 3a is characterized by complete sternal disruption and suppurative mediastinitis with exposure of the heart. Type 3b is associated with any of the types 2a, 2b or 3a and septicemia. All these wounds must be widely debrided and may require delayed closure, particularly when septicemia is present, or when the patient is hemodynamically unstable. Closure of the wound is accomplished with muscle flaps.

Osteomyelitis of the rib is a rare cause of chest wall infection. Diagnosis is usually delayed but the condition commonly presents with fever, pain, and a palpable mass overlying the infected rib segment. A draining sinus tract can also be present. It predominantly occurs from contiguous spread, but the hematogenous route has also been reported [31]. Treatment consists of excision of the diseased bone with care taken to avoid penetration and contamination of the adjacent pleural cavity during resection. Reconstruction with soft tissue coverage is often used for the remaining defect.

Sternoclavicular osteomyelitis usually presents with fever, joint pain, and an associated palpable mass. Several gram-positive and gram-negative organisms have been identified. Sternoclavicular osteomyelitis has been frequently associated with intravenous drug abuse, indwelling central venous catheters, and trauma [32-34]. The majority of patients also have a

long-term immunosuppression related to diabetes mellitus, steroid use, human immunodeficiency virus or an overwhelming acute illness from a distant site [35]. These infections are managed with intravenous antibiotics, aggressive surgical resection and often, soft tissue reconstruction. The joint's proximity to major neurovascular structures and the lack of substantial overlying soft tissues makes surgical management more challenging. A successful approach involves resection of the sternoclavicular joint with partial resection of the manubrium, medial clavicle, anterior first rib and in some cases, an involved portion of the anterior second rib [35]. Reconstruction is typically accomplished with an ipsilateral pectoralis major muscle flap [35,36].

3.4. Radiation

Radiation therapy has saved many lives and plays an important role in the treatment of malignant neoplasms that involve the chest wall. Examples of neoplasms in which radiation therapy is well-established include breast and lung cancer as well as some types of sarcomas and lymphomas. Radiation therapy works by damaging the targeted cells through complicated intracellular processes. The tissues that are included in the field of radiation can potentially suffer both early and late adverse effects. Early adverse effects typically occur within the first few weeks following treatment and may present as erythema, skin hyperpigmentation or desquamation. These changes are generally self-limiting and resolve with moisturizers and local wound care. On the other hand, chronic adverse effects can be progressive, permanent, debilitating and even life-threatening. Some of these late injuries include delayed wound healing, ulceration, infection, tissue fibrosis, malignant transformation, osteoradionecrosis, and constrictive microangiopathic changes to small and medium sized vessels. Management of several of these late injuries such as infected wounds, radiation ulcers and new or recurrent neoplasms, often requires the attention of a reconstructive surgeon. It has been reported that a significant number of patients undergoing chest wall reconstruction will receive radiation therapy in the course of their treatment [37].

The first step in evaluating a patient with a wound related to a late radiation injury is to rule out the presence of a new or recurrent tumor. This is usually accomplished by obtaining imaging studies such as a chest radiograph, computed tomography or magnetic resonance imaging, and possibly bronchoscopy. The two latter imaging studies will also allow better understanding of the extent of radiation injury in adjacent tissues. Once the extent of the disease is determined, an appropriate treatment approach can be proposed.

If there is a mass or an open wound, further work up and evaluation by the extirpative surgeon may be required. Subsequently, the tumor must be completely excised with negative pathologic margins before considering reconstruction of the remaining defect. If tumor is not present, the radiation-induced ulcer or infected wound should be completely resected and debrided. All fibrotic tissue and foreign bodies must be carefully removed, because sternal wires, retained sutures or persistently infected non-viable cartilage and bone may be sources of a chronic sinus tract or open wound. Inadequate debridement with retention of any of the aforementioned non-viable materials or tissues is usually the source

of recurrent infections and wound healing problems. Also, the extent of radiation injury is often underestimated and difficult to appreciate, and therefore, several debridements may be required to establish a clean wound with a well-vascularized bed and edges before proceeding with reconstruction.

The chest wall is a fairly thin structure and most chest wall defects are full thickness following thorough debridement. Therefore, chest wall reconstruction is often required to obtain an airtight seal and preserve respiratory function. Soft tissue coverage is then achieved generally with a musculocutaneous flap or a muscle flap with a skin graft. The most commonly used flaps include the pectoralis major, rectus abdominis, latissimus dorsi, and greater omentum flaps.

4. General principles of reconstruction of composite chest wall defects

Reconstruction of the chest wall has evolved over the last century to be an integral component of therapy for patients with chest wall defects. Developments in therapy include the introduction of tracheal intubation and positive-pressure ventilation, the description of the latissimus dorsi musculocutaneous flap for coverage of an anterior chest wall defect and the discussion of the use of fascia lata grafts for stabilizing the skeletal structures and greater omentum transposition for reconstruction of chest wall defects [38-41]. Since 1970, several authors have made remarkable contributions to the reconstructive field by describing the use of several muscle and musculocutaneous flaps such as the pectoralis major, latissimus dorsi, rectus abdominis, serratus anterior, and external oblique. More recently, free microvascular transfers of muscle or musculocutaneous units have been described, when local flaps were not available.

Chest wall reconstruction can be complex and continues to pose a formidable challenge. Close collaboration between the reconstructive surgeon and the thoracic surgeon can ensure appropriate management of this patient population in order to safely accomplish a desirable and durable outcome. The primary goals of reconstruction are maintenance of structural stability and preservation of physiologic function, as well as an acceptable cosmetic result without compromising the cancer or other primary operation. Two components may be involved; the bony thorax and the soft tissues. Reconstruction of these two components will be discussed in great detail later in the chapter.

Preoperative evaluation is essential in patients undergoing chest wall resection and reconstruction given the extensive nature of these procedures and the potential for life-threatening complications. A simple history and physical examination, as well as laboratory and radiological studies can help identify patients at high risk for developing postoperative complications. Understanding the patient's preoperative pulmonary status is critical and must be comprehensively evaluated preoperatively to determine the presence of respiratory symptoms, history of tobacco use, and exposure to pulmonary irritants. Typically, pulmonary function tests are an essential component of most preoperative workups.

The goals of the reconstruction and the expectations should be discussed with the patient. A teenager with pectus excavatum may have different expectations than an elderly person

with a malignant chest wall tumor. Multiple factors dictate the type of reconstruction of a chest wall defect. These include the patient's history and co-morbid conditions, physical stability and hemodynamic status, as well as the ultimate prognosis. A comprehensive understanding of both the anatomy of the defect and the availability of regional tissue for reconstruction of the defect is essential. The location, extent and etiology of the defect will determine the technique that should be used for reconstruction. Subsequently, the reconstructive surgeon can apply the concepts of the reconstructive ladder and select amongst several techniques including tissue expansion, standard flap transposition, and microsurgical composite tissue transplantation.

4.1. Location of the defect

Defining the location of the chest wall defect is important in the decision-making process regarding technique selection for reconstruction. The chest wall covers a large body surface area and can be divided into several different regions, each with a specific series of reconstructive needs and flap options.

The *anterior chest* area is located between the parasternal and the anterior axillary lines and extends from the clavicle to the inferior costal margin [42]. The breast is included in this area, but for the purpose of this discussion, breast reconstruction will not be analyzed. The skeletal structure of the anterior chest protects intra-thoracic organs, and its semi-rigidity maintains relative negative pressure for inspiration and positive pressure for expiration. Resection of 4 or more consecutive ribs or a defect that is larger than 5 cm in diameter may result in a flail segment and hence "paradoxical chest wall motion", leading to impairment of the respiratory mechanics. Skeletal reconstruction is typically recommended in these cases to restore chest wall stability. Absence of the pectoralis major muscle at the defect base may require a regional flap for wound coverage.

The *sternal* area is located between the two parasternal lines and extends from the jugular notch between the sternal heads of the sternocleidomastoid muscles to the xiphisternal junction [42]. Sternal defects may result in anterior mediastinal exposure, and chest wall instability may develop with possible functional impairment. In the past, it was believed that the extent of sternal components lost can affect the pulmonary status of the patient. However, several authors have examined the functional impact of sternal resections and concluded that sternal resection with or without soft tissue reconstruction is a well-tolerated procedure and in general shows no significant change in postoperative pulmonary function [43-45]. There is a significant amount of controversy which exists regarding the need to reconstruct sternal defects. However, most surgeons would agree that if a patient is experiencing sternal pain from instability, rigid fixation in the midline may improve their symptoms. In addition, the anterior chest wall also provides a rigid base for upper extremity movement. Loss of skeletal chest wall support in patients with sternal wounds may reduce upper extremity and shoulder girdle function [46]. Indeed, the location and size of the sternal defect will have an impact on the stability and physiologic integrity of the chest wall. The physiologic deficit is minimal with loss of the upper sternal body and associated ribs, is

moderate with loss of the entire sternal body and associated ribs, and may be more significant with loss of the manubrium, upper sternal body and associated ribs. However, this does not predict the need for structural reconstruction in these situations. More comprehensive physiologic assessments of outcomes in this patient population are required to answer this difficult question. For now, there is no conclusive evidence to support the necessity for reconstruction of sternal wounds following resection.

The *superior chest* area is located between the deltopectoral groove of the anterior chest and the spine of the scapula of the posterior chest and extends between the base of the neck to the acromioclavicular joints [42]. Chest wall stability should not be compromised with the absence of the clavicle or acromioclavicular joint. Skeletal reconstruction is generally not required for functional reasons because of the natural parietal suspension provided by the sternum, scapula, and attached wide muscles of the thorax. It should be noted that the subclavian artery and vein as well as the brachial plexus may be exposed with defects in the superior chest wall, and under these circumstances, soft tissue reconstruction will be required.

The *lateral chest* area is located between the anterior and posterior axillary lines [42]. The area extends between the apex of the axilla and the inferior costal margin. In general, lateral chest defects extend into either the anterior or posterior thorax or both. Reconstruction to restore skeletal wall stability is often required for extensive rib defects. Bone graft or vascularized bone has been utilized for this purpose. However, the associated donor-site morbidity has led to the more extensive use of alloplastic materials such as Prolene or Marlex mesh, GoreTex patches and methylmethacrylate sandwiches, which will be discussed below. Subsequent coverage of these materials with vascularized soft tissue is necessary. Isolated defects involving the lateral chest wall are uncommon, unless they extend into the axilla. Several neurovascular structures, including the axillary artery and vein and the median and ulnar nerves, could potentially be exposed with such defects. A variety of flaps can be used for closure of axillary defects such as serratus anterior, pectoralis major, and latissimus dorsi muscle flaps. The use of perforator flaps (e.g. thoracodorsal artery perforator flap) has also been proposed given their numerous advantages such as longer vascular pedicle, flexible arc of rotation, and preservation of the integrity of functional limb girdle muscles.

The *posterior chest* area is located between the two posterior axillary lines and extends between the level of the spine of the scapula to the posterior costal margin at the L1 level. Defects of the posterior thorax are typically characterized by a deep dead space. The wound base of the defect may be covered by muscle given the presence of several large muscle groups in this area such as the latissimus dorsi, trapezius and shoulder girdle muscles. Unless the defect extends to adjacent territories, chest wall instability secondary to the absence of ribs is rare due to good muscular support. Exposure of bone and hardware is occasionally seen with central posterior defects. The objectives for reconstruction are to fill the dead space, cover the exposed bone, as well as any exposed hardware or vascular prostheses that cannot be removed, and avoid formation of debilitating axillary and neck contractures. A tension-free reconstruction is desirable. Perforator flaps have been utilized

for these purposes. Their advantages include leaving the underlying muscle intact, consequently preserving function. Also, their flexible long vascular pedicles enable transposition and coverage of defects that cannot be reached by conventional musculocutaneous flaps. In contrast, muscle and musculocutaneous flaps will more reliably cover large deep defects as well as exposed hardware and vascular prostheses. Although reconstruction of the posterior thorax is usually achieved with pedicled flaps, microvascular free-tissue transfer is sometimes necessary. Free flaps are mainly used for large defects that are difficult to reach with pedicled flaps or when regional flaps are unavailable due to extirpation of the muscle or damage of the vascular pedicles following surgical ablation, radiation therapy, or trauma.

4.2. Size of the defect

The size of the chest wall defect is an important determining factor when considering the necessity of soft tissue and/or skeletal reconstruction. Partial thickness defects of the chest wall are usually limited to the skin and subcutaneous tissues with viable muscle in the wound base. These defects can be simply closed with skin grafts or local skin flaps.

Full thickness defects are more challenging. Small full thickness defects of the chest wall can often be closed primarily. Large full thickness defects are readily covered with regional muscle and musculocutaneous flaps or omental pedicled flaps with the aim of obliterating the dead space, controlling infection, and covering any prosthetic materials used in skeletal reconstruction. Microvascular reconstruction with free flaps is occasionally used in cases where the pedicled flaps are either unable to reach the defect or compromised secondary to extirpation, radiation therapy, or trauma. Skin grafts may be used for coverage of muscle flaps to avoid inclusion of a large skin paddle, hence allowing primary closure of the flap donor site. In cases of very large defects, use of a single flap may not provide adequate coverage, and use of chimeric flaps is an option.

4.3. Timing of reconstruction

Contemporary approaches to the management of complex chest wall defects typically requires a multidisciplinary approach involving both the thoracic and reconstructive surgeons. Certainly, an important consideration in the decision-making process is the timing of the reconstruction. Although immediate chest wall reconstruction can be achieved successfully for the majority of the defects, a more careful approach should be adopted for specific conditions such as sternal wound infections, radiation wounds and chronically draining empyemas.

Sternal wound infections are classically seen following cardiac procedures. As mentioned earlier, the surface appearance of these wounds can be deceptive, and delayed recognition and treatment can lead to life-threatening complications. Single-stage repair with sternal debridement and flap closure has been shown to be appropriate in most cases without an increase in either morbidity or mortality [30]. Antibiotics tailored to the offending organisms should be used judiciously. As a general principle, adequate debridement of the necrotic

tissue, evacuation of blood clots, removal of foreign bodies, and excision of devascularized bone and exposed cartilage should be performed prior to considering soft tissue coverage. In cases of inadequate debridement or suppurative mediastinitis, the wound must be left open with frequent dressing changes and the closure must be delayed for at least 48 hours or later if necessary, particularly when septicemia is present or when the patient is hemodynamically unstable [30]. Once the wound is clean, soft tissue reconstruction is usually achieved with regional flaps. The most commonly used flaps are the pectoralis major and rectus abdominis. Other less frequently used flaps include the omentum and latissimus dorsi. It should be noted that, the longer the period of time that elapses between debridement and soft tissue coverage, the greater the risk of damage to vital structures, such as coronary or aortic grafts.

Radiation wounds are another type of chest wall defect that deserve special attention with regard to timing of reconstruction. These wounds may represent soft tissue ulceration or osteoradionecrosis but can also be related to a recurrent tumor or a new primary malignancy. If tumor is present, it should be completely excised with negative pathologic margins before proceeding with reconstruction. If tumor is not present, the key to obtaining a well-healed chest wall reconstruction relies on wide excision and thorough debridement of all nonviable irradiated tissues as well as removal of foreign bodies. Numerous debridements are usually required to establish a clean wound with well-vascularized margins before reconstruction of the resulting defect is considered. This is important for various reasons as a poorly vascularized and fibrotic irradiated wound bed may lead to failure of an attempted primary closure or skin grafting as well as suboptimal healing of a transposed muscle flap. It should also be remembered that the degree of radiation injury often extends beyond the initially established edges of damaged tissue, making serial debridements necessary.

Empyema is the development of infection within the pleural space and can be due to many different etiologies. Postsurgical empyema accounts for 20% of all cases of empyema and most frequently follows pneumonectomy [47]. Although empyemas can occur several years after the initial surgery, they are most frequently encountered in the early postoperative period.

Post-surgical empyemas are generally treated with correction of the underlying cause, appropriate antibiotics, and drainage with chest tube thoracostomy. The response to this treatment for empyemas complicating pulmonary resections highly depends on the state of the remaining lung and its location. If the pleural space is not completely filled by expansion of the remaining lung, elevation of the diaphragm or shifting of the mediastinum, the empyema will likely persist. The previously mentioned treatment is almost never sufficient for the treatment of empyemas which occur after upper lobectomies and pneumonectomies, resulting in chronically draining empyemas. Bronchopleural fistulas may also be present in about 40% of the cases, making treatment more complex [47]. General management of empyemas associated with pulmonary resections includes initial drainage and sterilization of the infected pleural space. Subsequently, the bronchopleural fistula is closed if present, and the pleural space is obliterated with either a muscle flap or antibiotic solution. A variety

of extrathoracic pedicled flaps have been used to obliterate the pleural space including latissimus dorsi muscle, serratus anterior muscle, pectoralis major or minor muscle, rectus abdominis muscle, and omentum.

An important issue in the management of pleural cavities with empyema is the timing of the reconstruction, whether with a muscle flap or antibiotic solution. In general, the initial treatment of an empyema with closed drainage of the pleural space is required for 1-2 weeks until the mediastinum becomes stabilized. It should be noted that open drainage of the pleural space may be considered at any point if the patient becomes medically unstable. If a bronchopleural fistula is identified during the initial period, open drainage is also performed with possible closure of the fistula. Once the patient is medically stable and has entered into the chronic phase after the initial 2-week period, obliteration of the pleural space may be undertaken. There is no established scientific evidence as to the best timing of the closure. Some authors advocate closure at approximately 3 months for benign disease and 6 months to 1 year for malignant disease, whereas others suggest obliteration of the pleural space anytime between 6 weeks and 3 months [47].

The timing of reconstruction is also important for certain *congenital anomalies* such as Poland syndrome. Although some believe that prepubertal patients with the syndrome are candidates for repair, others support the idea of delaying reconstruction until late adolescence [48,49]. Several reasons have been given to support the delayed approach, including the risk of growth inhibition with early intervention and the need for multiple revisions to maintain pace with breast and chest wall growth. Reconstruction of the female breast deformity in Poland syndrome remains controversial. Many females with the condition seek consultation early in development. Some advocate delaying reconstruction until the breasts are fully mature. However, this is a very sensitive age in young women, and if left untreated, the condition may lead to severe psychological and behavioral problems. Therefore, it is often advisable to address the defect with insertion of a tissue expander on the affected side which is then filled to the volume to match the contralateral breast as the young woman matures. Periodic expansion of the breast tissue expander allows adjustment of breast size to match the unaffected contralateral breast until sexual maturity is reached. At that point, the expander can be replaced with a permanent implant.

The timing for repair and reconstruction of pectus deformities can also pose a challenge. A consideration in favor of skeletal reconstruction is the presence of cardiopulmonary compromise, or psychological and behavioral problems caused by the chest wall deformity. However, it should be remembered that severe disability may ensue due to limitation of the growth of the thorax and associated severe chest wall constriction. Therefore, resectional repairs should be delayed, if possible, until after the age of 16 years. In addition, children and young adolescents who present before their growth spurts are not ideal candidates for implant correction. Breast reconstruction in female patients with pectus deformities is usually deferred until patients are well into their pubertal growth. As for all elective procedures, involving the patient in the decision-making process is critical to ensure a successful reconstruction and a satisfied patient.

5. Skeletal reconstruction

The bony thorax plays a vital role in the dynamic stability of the chest and respiratory mechanics. Skeletal reconstruction not only restores skeletal rigidity but also protects the vital organs and vascular structures contained within the thorax. Furthermore, it prevents herniation of thoracic organs, counteracts considerable shrinking of the operated side of the thorax, and maintains an acceptable chest shape while preserving the mechanical forces that enable respiration. The size and location of the skeletal defect generally determine whether skeletal reconstruction is required. The classic teaching is that the loss of two ribs can be compensated by adequate soft tissue reconstruction. However, structural wall support is required when defects involve the loss of more than four consecutive ribs or are greater than 5 cm in diameter to prevent the development of chest wall flail. Larger defects located posteriorly may be an exception, as the overlying scapula can provide support, but if the defect is near the tip of the scapula, reconstruction may be required to prevent entrapment with movement of the arm. In addition, in patients who have undergone radiation, as many as five ribs may be resected without requiring skeletal reconstruction as the resulting radiation fibrosis produces chest wall stiffness and affords inherent stability. Throughout the years, a variety of autogenous and prosthetic grafts have been used to restore the structural integrity of the chest wall.

5.1. Autogenous options

Traditionally, skeletal reconstruction was performed utilizing autogenous materials, such as fascial or split-rib grafts, with limited success. The tensor fascia lata muscle has a long fascial extension that can be easily harvested in the supine position. The fascia lata graft can be taken up to 28 cm in length, and 16 cm in width. It can provide a semirigid skeletal substitute, and has been used with bone chips or bone grafts. The use of fascia lata grafts is limited because they are prone to infections and have been shown to become flaccid over time, decreasing their ability to provide stable skeletal support [40,50]. Autogenous bone grafts are another option for reconstruction of the chest wall skeleton. For successful reconstruction, the bone graft must be opposed to a large surface area of trabecular bone adjacent to the chest wall defect in order to enhance graft survival and osteoconduction [50]. Several donor sites have been reported including the ribs, iliac crest, and fibula. Rib grafts are technically difficult to harvest and produce donor site morbidity, but are useful in preventing flail chests.

5.2. Prosthetic options

One of the most significant developments in chest wall surgery and reconstruction has been the increasing use of synthetic materials. Prior to the creation of these materials, cadaveric bone or the patient's own fascial or split-rib grafts were used for structural support, as described above. The ideal characteristics of a prosthetic material for skeletal reconstruction include rigidity, malleability, inertness, and radiolucency. Today, synthetic materials such as Prolene mesh, Marlex mesh, Gore-Tex, Vicryl mesh, and methylmethacrylate have all but eliminated the use of cadaveric or autogenous materials [51]. These prosthetic materials are widely available, reliable, and can be easily used to reconstruct the chest wall skeleton,

conforming to any size or shape of defect. Their main disadvantage is the potential for infection.

The selection of which synthetic material to use is largely based on the surgeon's preferences as all available materials work reasonably well. Prolene and Marlex mesh are monofilament polypropylene, are porous, and are structurally sound. Prolene is double knitted and can withstand 150 pounds of pressure. A fibrous reaction occurs at the interface between the mesh and flap to provide permanent stability and incorporation into the surrounding tissue. Methylmethacrylate can be used alone or incorporated between two layers of Marlex mesh in a sandwich fashion in situations where rigidity is necessary. Methylmethacrylate is lightweight, versatile, and radiolucent, allowing for subsequent evaluation of the lungs. It undergoes an exothermic reaction during hardening, and therefore the Marlex sandwich is prepared on a side table and only sewn in place after the composite graft has cooled sufficiently [52]. Gore-Tex, which is reinforced polytetrafluoroethylene, has a smooth, nonporous surface, creating a more watertight closure to prevent movement of fluid and air across the reconstructed chest wall. The smooth surface also prevents adhesion formation and incorporation. Gore-Tex is considered easier to suture, stretch, and mold into the wound. Vicryl, or polyglactin 910, is an absorbable mesh with limited strength and is often used for temporary coverage in cases where wound contamination or infection is present [42]. Acellularized dermal matrices (ADM) are newer biologic, nonimmunogenic materials which may be useful in situations where reconstructive material must be placed directly over viscera or into an irradiated or infected operative site. ADM becomes vascularized and undergoes remodeling into the autologous tissue following implantation. Initial studies show that it produces a strong, stable repair, resists infection, and causes minimal adhesions [53]. Following stabilization of the chest with prosthetic mesh, the alloplastic material must be covered with healthy, well-vascularized tissue, often in the form of a muscle or myocutaneous flap.

6. Soft tissue reconstruction

In general, the nature of full thickness chest wall defects requires the recruitment of healthy skin and soft tissue for reconstruction. This includes several options, from local and regional muscle or myocutaneous flaps to more advanced reconstructive techniques such as microsurgical free tissue transfer. The excellent vascularity of these flaps provides the most reliable means of reconstructing complex chest wall defects, enabling the maintenance of physiologic functions and decreasing the risk of infection. Of note, a detailed preoperative history should be obtained regarding which surgical procedures a patient has had in the past to determine which flaps are available for use.

6.1. Muscle and myocutaneous flaps

Pectoralis Major

The pectoralis major muscle flap is the most commonly used muscle flap for reconstruction of sternal, anterosuperior chest, intrathoracic, and neck wounds. It is an ideal flap based on

its proximity, reliability, and versatility. It is a thick, fan-shaped muscle that originates from the anterior surface of the medial aspect of the clavicle, anterior surface of the sternum, and the superior six costal cartilages. The fibers converge laterally and insert as a tendon on the intertubercular groove of the humerus. The muscle creates the anterior axillary fold. It is innervated by the medial and lateral pectoral nerves, and functions to adduct and medially rotate the humerus. The sternocostal head also contributes to extension of the humerus, while the clavicular head flexes the humerus.

It is classified as having a Mathes-Nahai Type V vascular supply, with both a dominant and segmental blood supply, and may be reliably raised on either. The dominant blood supply is derived from the thoracoacromial artery, which arises from the axillary artery. The segmental blood supply comes from the first through sixth intercostal perforating branches of the internal mammary artery. The muscle has a highly consistent vascular anatomy, and the multiple pedicles affords it significant reliability and versatility. When the flap is based on the thoracoacromial pedicle, its reach can be increased by dividing its humeral and clavicular attachments. The flap may be harvested as muscle alone or as a myocutaneous flap, but rates of skin paddle necrosis may be as high as 30% [54-56]. Transposition of the flap results in loss of pectoralis motor function except in cases where the humeral insertion and motor nerves are left intact in reconstruction of the upper sternum. The pectoralis can also be used to fill intrathoracic defects by passing it between the superior ribs. When based on its segmental supply, it is raised as a turnover flap, which requires the division of the humeral and clavicular attachments and may necessitate ligation of the thoracromial vessels to increase its mobility. The turnover flap is particularly useful for midline sternal defects and in cases in which the thoracoacromial vessels are absent or damaged. However, the left pectoralis muscle cannot be based on the segmental supply if the patient has previously had a bypass using the left internal mammary artery. The use of only the medial two-thirds of the muscle as a turnover flap enables the lateral third and anterior axillary fold to be spared, decreasing donor site morbidity.

Rectus Abdominis

The rectus abdominis is a paired muscle running vertically on each side of the anterior abdomen. The muscle originates from the pubis and inserts into the costal cartilages of the fifth through seventh ribs and the xyphoid process. It is innervated segmentally by the thoracoabdominal nerves of the seventh through twelfth thoracic vertebrae. It functions to flex the lumbar spine. It may be harvested as a muscle or myocutaneous flap, and these flaps are useful in the reconstruction of anterior and anterolateral chest wall defects and are also a mainstay in autologous breast reconstruction [57].

The rectus abdominis has a Mathes-Nahai Type III vascular supply, with two dominant pedicles consisting of the superior and deep inferior epigastric arteries. The superior epigastric artery is a branch of the internal mammary artery, while the deep inferior epigastric artery arises from the external iliac artery. The superior and inferior epigastric vessels anastomose through a choke zone periumbilically. In patients who have undergone bypass using the left internal mammary artery (LIMA), the left rectus abdominis can be

based on the eighth intercostal vessel, but the risk for flap loss is increased due to the decreased vascularity. The flap may be pedicled on the superior epigastric vessels or transferred as a free flap based on the inferior epigastric vessels. The overlying skin is supplied by musculocutaneous perforators arising from the deep inferior epigastric system. The skin paddle may be oriented transversely (TRAM) or vertically (VRAM). The transverse orientation allows for harvest of a larger skin paddle, and the donor site can be closed primarily and the transverse scar is well-concealed in the lower abdomen. The skin paddle of the VRAM is oriented directly over the muscle and encompasses a maximal number of perforators, and therefore has a better blood supply than the TRAM (Figure 4). A disadvantage of using the rectus abdominis muscles in chest wall reconstruction is that harvest of the rectus abdominis muscle can lead to abdominal morbidity including abdominal wall weakness, abdominal bulges, and hernias. Perforator flaps, like the deep inferior epigastric perforator flap (DIEP), have been designed to minimize rectus abdominis muscle harvest and the corresponding donor site morbidity, and have become increasingly popular in breast reconstruction. However, these flaps have less utility in chest wall reconstruction due to their less reliable vascularity, and potentially devastating consequences if flap loss occurs.

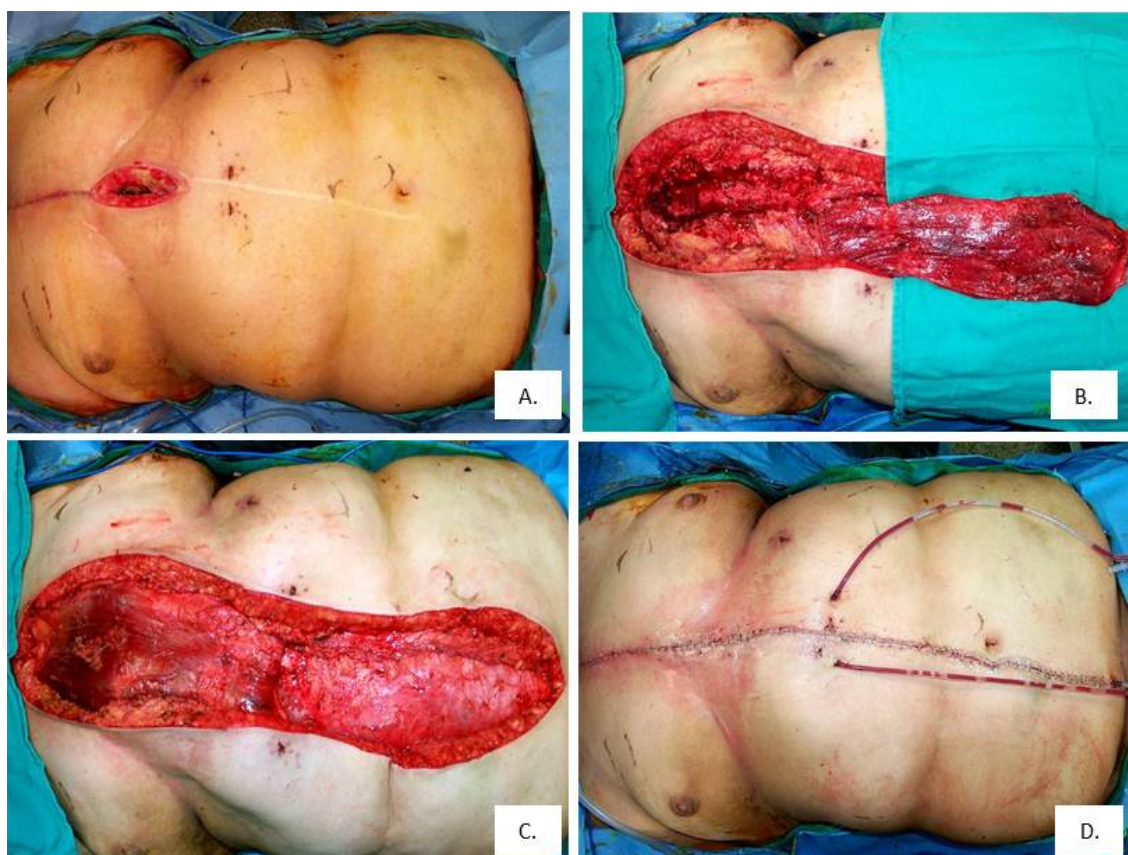


Figure 4. Vertical rectus abdominis muscle (VRAM) flap for closure of a sternal wound. (A) A 68-year-old female developed a median sternotomy wound infection following coronary artery bypass grafting. (B) A right vertical rectus abdominis muscle is elevated and divided from its attachments to the pubis. (C) The rectus abdominis muscle is transpositioned into the defect. (D) Final appearance of the anterior trunk following incision closure and placement of two abdominal drains.

Latissimus Dorsi

Tansini first described the use of a pedicled latissimus dorsi flap in 1906 to cover an anterior chest wall defect following mastectomy [39]. It remains a workhorse flap in chest wall reconstruction due to its reliability, size, and location and can be harvested as muscle alone or as a myocutaneous flap with a skin paddle to reconstruct full-thickness defects. The muscle is thin and broad and fans out from its origin on the thoracic, lumbar, and sacral vertebrae and posterior iliac crest to insert on the intertubercular groove of the humerus. Minor attachments to the inferior angle of the scapula and interdigitations with the external oblique at the anterolateral aspect are also present. Its functions to extend, adduct, and medially rotate the upper extremity. In the absence of this muscle, these functions are generally well-compensated for by the other muscles of the shoulder girdle, including the pectoralis major, teres major, subscapularis, and deltoid muscles. The muscle is innervated by the thoracodorsal nerve, which arises from the posterior cord of the brachial plexus.

The muscle has a Mathes-Nahai Type V vascular supply, with one major vascular pedicle and secondary segmental vascular pedicles. The major blood supply is the thoracodorsal artery. The axillary artery gives off the subscapular artery, which then gives off two branches, first the circumflex scapular artery and then the thoracodorsal artery. The thoracodorsal vessels arise from the subscapular system in 94% of cases, 5% of the time they arise directly from the axillary vessels and the remaining 1% from the lateral thoracic vessels [58]. The thoracodorsal artery also gives off a branch to the serratus anterior. The pedicle enters on the deep aspect of the latissimus dorsi approximately 10 cm from the insertion of the muscle into the humerus and is accompanied by one or two venae comitantes and the thoracodorsal nerve. The significance of the serratus branch is that the latissimus can survive on this collateral if the thoracodorsal artery has been divided, which may occur, for example, during an axillary lymph node dissection. However, in patients with a history of radiation, there is an increased incidence of flap loss when it is based on retrograde flow through the serratus branch. The serratus branch can also be divided to lengthen the vascular pedicle from 7 cm to more than 10 cm [59]. The secondary segmental vascular pedicle is supplied by the ninth to eleventh posterior intercostal and lumbar arteries and associated veins. The latissimus can also survive on this secondary pedicle, and in this case the flap is raised as a turnover flap with the arc of rotation limited to the posterior central trunk. These dual arcs of rotation make the latissimus dorsi flap quite versatile based on the thoracodorsal artery or segmental perforators.

As a result of its versatility, the latissimus flap can be utilized to reconstruct both anterior and posterior ipsilateral chest wall defects as well as neck and shoulder defects (Figure 5). In addition to dividing the serratus branch, the insertion on the humerus can be divided and the pedicle dissected from its investing fascia to increase the reach of the flap. The flap can be elevated as a myocutaneous flap with a skin island that can have any orientation. Primary closure of the donor site is usually possible if the width of the skin island is limited to 8 to 10 cm. If a larger skin island is required for reconstruction, the posterior donor site can be closed with a split thickness skin graft (Figure 5C). Due to its long pedicle and caliber of the thoracodorsal artery and vessels, the muscle is also an ideal choice for microsurgical free tissue transfer when indicated.

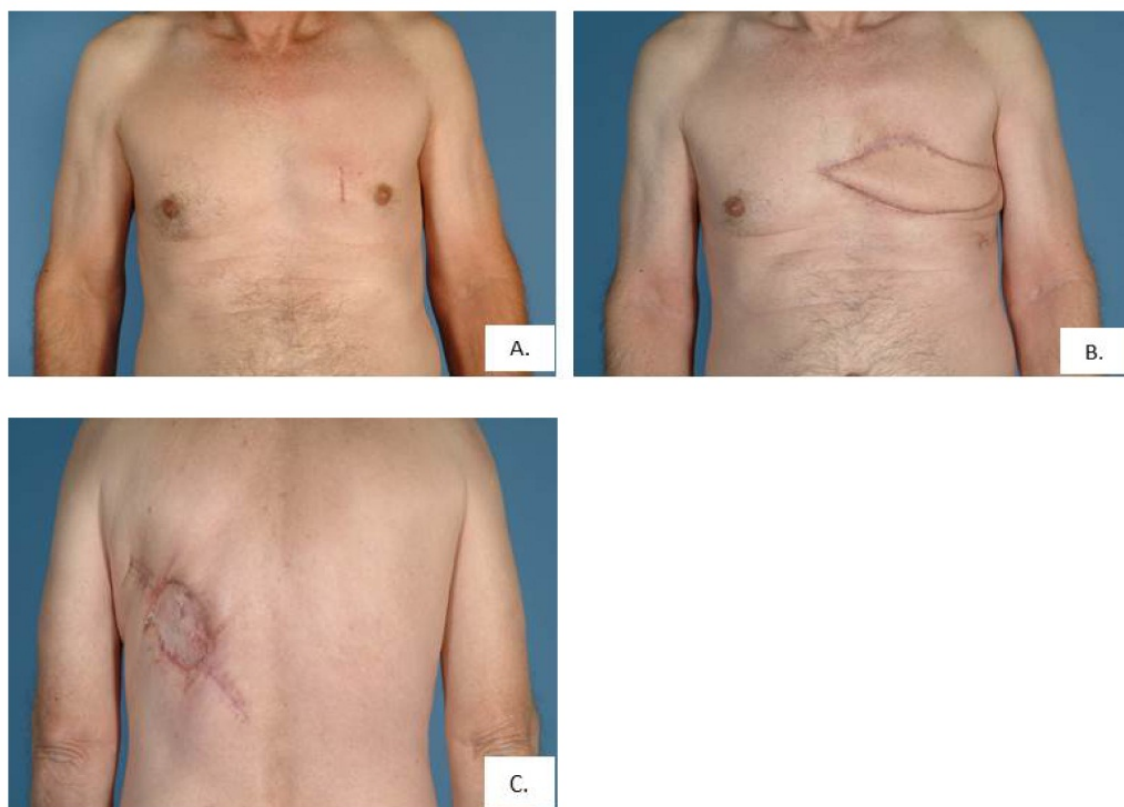


Figure 5. Latissimus dorsi musculocutaneous flap for anterior chest wall reconstruction. (A) A 59-year-old male with a desmoid tumor involving the left anterior chest wall. (B) Appearance of the left anterior chest wall three months following tumor resection and reconstruction with a left latissimus dorsi musculocutaneous flap. (C) Appearance following closure of the donor site with a split thickness skin graft.

The flap is harvested with the patient in the lateral thoracotomy position, with the arm prepped into the field to allow for manipulation during the procedure. A disadvantage of the latissimus is that the patient may need to be repositioned into this position intraoperatively for flap harvest. Donor site seroma rates are also very high, with one series reporting a 79% seroma rate, and donor site incision dehiscence rates are approximately 3% [60,61]. The harvest places a conspicuous scar on the back, may leave a contour irregularity, and may require a skin graft for coverage of the donor site. The functional disability following flap harvest is generally minimal. Functional testing has revealed that the most significant deficit is weakness of the arm and that this is more significant in women than men. However, alternative flaps should be considered in patients who are crutch, walker, or wheelchair dependent and rely on the strength and function of the latissimus dorsi for mobility and for performance of activities of daily living.

External Oblique

The external oblique flap is an option to cover defects located in the lower anterior chest region up to the third intercostal space. It is a broad, thin muscle that originates from the fifth through twelfth ribs and inserts on the inguinal ligament and iliac crest. Its blood supply consists of the lateral cutaneous branches of the inferior eight posterior intercostal

arteries, which provide a segmental blood supply to the muscle. The vessels enter the muscle posteriorly at the midaxillary line and send multiple perforating branches to the overlying skin. Traditionally, dissection included the anterior rectus sheath with the external oblique flap. However, this increases the risk of abdominal morbidity such as the development of abdominal hernias, especially if below the arcuate line, and may necessitate the use of prosthetic or bioprosthetic mesh to close the donor site. Studies have shown that the flap can be safely raised without the anterior rectus sheath by establishing the plane between the external and internal oblique muscles medially, then continuing the dissection laterally until the intercostal neurovascular bundles are encountered [62].

Trapezius

The trapezius flap can be utilized for reconstruction of defects of the upper mid-back, the base of the neck, and the shoulders. It is a broad, diamond-shaped superficial muscle located on the posterior thorax. It originates on the external occipital protuberance, the nuchal ligament, the medial superior nuchal line, and the spinous processes of C7-T12. It inserts on the lateral third of the clavicle, the acromion process, and the scapular spine. It is innervated by the eleventh cranial nerve, the spinal accessory nerve, and functions to move the scapula in a variety of directions. The dominant blood supply to the trapezius is the transverse cervical artery, which is a branch of the thyrocervical trunk arising from the subclavian artery. The overlying skin is supplied by musculocutaneous perforators, and the flap can be harvested as a muscular or myocutaneous flap. The cutaneous portion may extend up to 10 cm below the inferior edge of the muscle flap itself as long as one-third of the skin paddle overlies the trapezius muscle. Primary closure of the donor site is possible if the width of the skin paddle is less than 10 cm. To prevent dehiscence of the donor site closure, shoulder rotation and abduction should be minimized postoperatively for 4 to 6 weeks. Donor site morbidity is decreased if the surgeon preserves the superior 4 cm of the muscle, the spinal accessory nerve, and the insertion at the acromion [63].

Serratus Anterior

The serratus anterior is generally not used as an isolated muscle in chest wall reconstruction. It originates on the surface of the superior eight or nine ribs and inserts on the costal aspect of the medial margin of the scapula. The superior portion of the muscle is supplied by the lateral thoracic artery and the inferior by the thoracodorsal artery. It is innervated by the long thoracic nerve, and injury to this nerve results in the classic winged scapula. It is primarily used for intrathoracic defects and may also be elevated with the latissimus dorsi to carry additional skin and tissue to the anterior surface of the chest for reconstruction.

6.2. Microsurgical free tissue transfer

Local, pedicled flap options are the first choice for reconstruction of chest wall wounds in the majority of patients. However, factors such as trauma, recurrent disease, prior radiotherapy, or previous surgery may reduce or eliminate the possibility of using local or regional flaps. Microsurgical free transfer is therefore a valuable technique in these patients to expand the choices for chest wall reconstruction. The most commonly used flaps include

the latissimus dorsi, rectus abdominis, and omental flaps. Common lower extremity flaps, such as the anterolateral thigh flap or vastus lateralis, are also available. The recipient vessels available include the internal mammary vessels, thoracodorsal vessels, and branches of the thoracoacromial and thyrocervical trunks. Not all patients are suitable candidates for free flap reconstruction, either due to a poor prognosis or medical comorbidities, and therefore patient selection is critically important.

The *anterolateral thigh (ALT) flap* is a versatile fasciocutaneous flap based on the descending branch of the lateral femoral circumflex artery, which arises from the profunda femoris. It has a reliable vascularity and is relatively easy to harvest, making it an ideal choice for microsurgery. The donor site can be closed primarily when the skin paddle is less than 8 x 25 cm. Other advantages of this flap include a lengthy pedicle with good caliber vessels, and the possibility of being harvested as a sensate flap based on the lateral femoral cutaneous nerve of the thigh. Harvest does not require intraoperative repositioning of the patient, affording a two-team approach, and donor site morbidity is low.

6.3. Other methods of reconstruction

Omental Flap

The greater omentum consists of a large fold of peritoneum containing variable amounts of fat and lymphoid tissue. It is associated with the transverse colon and greater curvature of the stomach. It is highly vascularized, with an extensive vascular network supplied by the right and left gastroepiploic arteries, and the short gastric vessels. It may be as large as 36 x 46 cm² and can therefore cover large surface area defects and fill large cavities [64]. The large number of vessels supplying the omentum not only bring in a reliable blood supply, but can also afford a great deal of flexibility with regards to flap design. For coverage of low midline defects, all of the vascular anastomoses may be left intact. The pedicled flap can also be based on either the right or left gastroepiploic artery with its vascular arcade, and divided from the transverse colon and stomach to reach defects located anywhere on the anterior chest. The arc of rotation is 5-10 cm greater when the right gastroepiploic artery is utilized [65]. Once the omentum is transported to its new location, it is covered with a skin graft.

One disadvantage of the omental flap is that harvest requires a laparotomy, although laparoscopic flap harvest has been described. Associated intra-abdominal morbidity includes the potential for development of an abdominal hernia when the omentum is passed into the chest defect via a subcutaneous tunnel. The incidence of hernia development is as high as 21% when this approach is utilized. Therefore, a transdiaphragmatic route is preferred [66]. Flap inset is challenging due to the friable nature of omental tissue. It is also difficult to predict the size of the omentum preoperatively, as the volume of the greater omentum has no direct correlation with a patient's body habitus.

Chimeric Flaps

Chimeric flaps refer to two or more individual flaps that derive their blood supply from separate branches of the same vessel. They are utilized in chest wall reconstruction when

coverage of a large surface area is required. One of the most useful examples is a combination of tissues based on the subscapular trunk, and may include the latissimus dorsi, serratus anterior, and a cutaneous portion based on the circumflex scapular vessels. It is also possible to include a bony component from the scapula. Since all of the branches converge on a single vascular trunk, the subscapular in this case, pedicled transposition on this vessel is possible. Further, free tissue transfer requires only one set of anastomoses. Preoperative angiography is useful for surgical planning to evaluate an individual patient's vascular anatomy.

Skin Grafts

Skin grafts have a limited role in chest wall reconstruction, but are a simple and straightforward means of reconstruction in select cases. They may be utilized for partial thickness defects that involve only the skin and subcutaneous tissues of the chest. They may also be used as an adjunct for coverage of muscle flaps when a skin island is not included in the flap or is not large enough to close the entire defect. When used alone, however, they will not provide the bulk, durability, or vascularity of a muscle flap. In addition, skin grafts will contract during healing, resulting in a poorer aesthetic outcome and potential scar contractures. Lastly, skin grafts may not take when utilized in a radiated field, or may break down in a wound if postoperative radiation therapy is required.

Tissue Expansion

Tissue expansion is a well-established means of stretching skin adjacent to a defect, enabling the use of chest wall tissue for reconstruction of chest wall wounds, thus avoiding distant donor site scars. Its indications in chest wall reconstruction are restricted to partial thickness chest wall defects in which optimal form and contour are required. The skin adjacent to a defect must be suitable to use as advancement flaps following expansion. It is contraindicated for defects associated with chronic infection or radiation-induced injury. The process involves placement of tissue expanders in a subcutaneous pocket beneath healthy skin and gradually inflating the expanders with saline over several months.

Negative Pressure Wound Therapy

Negative pressure wound therapy (NPWT), or vacuum-assisted closure, has become a popular modality for the treatment of a variety of wounds, including sternal wounds. The system involves a pump that applies either continuous or intermittent negative pressure that is connected to an open cell foam covered with a semi-occlusive drape. The exact mechanism of action is unknown, but is possibly due to the induction of cell division, proliferation, and angiogenesis secondary to the mechanical forces transmitted through the foam to the wound surface. The negative pressure also leads to the removal of interstitial edema, promoting blood flow to the wound by decreasing capillary compression. NPWT may be used in the initial management of a wound as a temporary dressing when definitive closure or flap coverage has to be delayed. It can also be utilized as a bolster over skin grafts post-operatively to increase the surface contact, stabilize the graft, and promote take. One advantage of NPWT is that the dressing can be changed approximately every 48-72 hours,

decreasing the number of dressing changes for patients. Absolute contraindications of NPWT include using the dressing over exposed blood vessels or organs, and relative contraindications include the use of the device in wounds containing malignant tumors, untreated osteomyelitis, necrotic tissue, and non-enteric or unexplored fistulas.

Author details

Christodoulos Kaoutzanis

Department of Surgery, Saint Joseph Mercy Health System, Ann Arbor, MI, USA

Tiffany N.S. Ballard

Section of Plastic Surgery, Department of Surgery, University of Michigan Health System, Ann Arbor, MI, USA

Paul S. Cederna

Section of Plastic Surgery, Department of Biomedical Engineering, Department of Surgery, University of Michigan Health System, Ann Arbor, MI, USA

Acknowledgement

We would like to thank Doros Polydorou, M.D. for producing the schematic illustrations for Figures 1 and 2.

7. References

- [1] Van Aalst JA, Phillips JD, Sadove AM (2009) Pediatric chest wall and breast deformities. *Plast Reconstr Surg.* 124: 38e-49e.
- [2] Cahill JL, Lees GM, Robertson HT (1984) A summary of preoperative and postoperative cardiorespiratory performance in patients undergoing pectus excavatum and carinatum repair. *J Pediatr Surg.* 19: 430-433.
- [3] Weg JG, Krumholz RA, Harkleroad LE (1967) Pulmonary dysfunction in pectus excavatum. *Am Rev Respir Dis.* 96: 936-945.
- [4] Quigley PM, Haller JA, Jelus KL, Loughlin GM, Marcus CL (1996) Cardiorespiratory function before and after corrective surgery in pectus excavatum. *J Pediatr.* 128: 638-643.
- [5] Ravitch MM (1951) Pectus excavatum and heart failure. *Surgery.* 30: 178-194.
- [6] Ravitch MM (1961) Operative treatment of congenital deformities of the chest. *Am J Surg.* 19: 588-597.
- [7] Fonkalsrud EW, DeUgarte D, Choi E (2002) Repair of pectus excavatum and carinatum deformities in 116 adults. *Ann Surg.* 236: 304-312; discussion 312-314.
- [8] Peterson RJ, Young WG, Godwin JD, Sabiston DC Jr, Jones RH (1985) Noninvasive assessment of exercise cardiac function before and after pectus excavatum repair. *J Thorac Cardiovasc Surg.* 90: 251-260.
- [9] Fonkalsrud EW (2008) Surgical correction of pectus carinatum: lessons learned from 260 patients. *J Pediatr Surg.* 43: 1235-1243.

- [10] Fonkalsrud EW, Beanes S (2001) Surgical management of pectus carinatum: 30 years' experience. *World J Surg.* 25: 898–903.
- [11] Iakovlev VM, Nechaeva GI, Viktorova IA (1990) Clinical function of the myocardium and cardio- and hemodynamics in patients with pectus carinatum deformity. *Ter Arkh.* 62: 69-72.
- [12] Clarkson P (1962) Poland's syndactyly. *Guys Hosp Rep.* 111: 335-346.
- [13] Poland A (1841) Deficiency of the pectoral muscles. *Guys Hosp Rep.* 6: 191-193.
- [14] Shalev SA, Hall JG (2003) Poland anomaly: Report of an unusual family. *Am J Med Genet.* 118A: 180–183.
- [15] Darian VB, Argenta LC, Pasyk KA (1989) Familial Poland's syndrome. *Ann Plast Surg.* 23: 531-537.
- [16] Moir CR, Johnson CH (2008) Poland's syndrome. *Semin Pediatr Surg.* 17: 161-166.
- [17] O'Connor MB, Gallagher DP, Mulloy E (2008) Jeune syndrome. *Postgrad Med J.* 84: 559.
- [18] de Vries J, Yntema JL, van Die CE, Crama N, Cornelissen EA, Hamel BC (2010) Jeune syndrome: description of 13 cases and a proposal for follow-up protocol. *Eur J Pediatr.* 169: 77-88.
- [19] Yang SS, Langer LO Jr, Cacciarelli A, Dahms BB, Unger ER, Roskamp J, Dinno ND, Chen H (1987) Three conditions in neonatal asphyxiating thoracic dysplasia (Jeune) and short rib-polydactyly syndrome spectrum: a clinicopathologic study. *Am J Med Genet Suppl.* 3: 191-207.
- [20] Shamberger RC (2000) Chest Wall Deformities. In: Shields TW, LoCicero J III, Ponn RB, editors. *General Thoracic Surgery.* Vol 1, 5th ed. Philadelphia: Lippincott Williams and Wilkins. pp. 535-561.
- [21] Pairolero PC (2000) Chest Wall Tumors. In: Shields TW, LoCicero J III, Ponn RB, editors. *General Thoracic Surgery.* Vol 1, 5th ed. Philadelphia: Lippincott Williams and Wilkins. pp. 589-598.
- [22] Burt M, Fulton M, Wessner-Dunlap S, Karpeh M, Huvos AG, Bains MS, Martini N, McCormack PM, Rusch VW, Ginsberg RJ (1992) Primary bony and cartilaginous sarcomas of the chest wall: results of therapy. *Ann Thorac Surg.* 54: 226-232.
- [23] Douglas YL, Meuzelaar KJ, Van Der Lei B, Pras B, Hoekstra HJ (1997) Osteosarcoma of the sternum. *Eur J Surg Oncol.* 23: 90-91.
- [24] Buitendijk S, van de Ven CP, Dumans TG, den Hollander JC, Nowak PJ, Tissing WJ, Pieters R, van den Heuvel-Eibrink MM (2005) Pediatric aggressive fibromatosis: a retrospective analysis of 13 patients and review of literature. *Cancer.* 104: 1090-1099.
- [25] Losanoff JE, Richman BW, Jones JW (2002) Necrotizing soft tissue infection of the chest wall. *J Cardiovasc Surg (Torino).* 43: 549-552.
- [26] Gill EA Jr, Stevens DL (1989) Primary sternal osteomyelitis. *West J Med.* 151: 199-203.
- [27] Culliford AT, Cunningham JN Jr, Zeff RH, Isom OW, Teiko P, Spencer FC (1976) Sternal and costochondral infections following open-heart surgery-A review of 2,594 cases. *J Thorac Cardiovasc Surg.* 72: 714-726.
- [28] Ridderstolpe L, Gill H, Granfeldt H, Ahlfeldt H, Rutberg H (2001) Superficial and deep sternal wound complications: incidence, risk factors and mortality. *Eur J Cardiothorac Surg.* 20: 1168-1175.

- [29] Johnson P, Frederiksen JW, Sanders JH, Lewis V, Michaelis LL (1985) Management of chronic sternal osteomyelitis. *Ann Thorac Surg.* 40: 69-72.
- [30] Jones G, Jurkiewicz MJ, Bostwick J, Wood R, Bried JT, Culbertson J, Howell R, Eaves F, Carlson G, Nahai F (1997) Management of the infected median sternotomy wound with muscle flaps. The Emory 20-year experience. *Ann Surg.* 225: 766-776; discussion 776-778.
- [31] Bishara J, Gartman-Israel D, Weinberger M, Maimon S, Tamir G, Pitlik S (2000) Osteomyelitis of the ribs in the antibiotic era. *Scand J Infect Dis.* 32: 223-227.
- [32] Carlos GN, Kesler KA, Coleman JJ, Broderick L, Terrentine MW, Brown JW (1997) Aggressive surgical management of sternoclavicular joint infections. *J Thorac Cardiovasc Surg.* 113: 242-247.
- [33] Bayer AS, Chow AW, Louie JS, Guze LB (1977) Sternoarticular pyoarthrosis due to gram-negative bacilli. Report of eight cases. *Arch Intern Med.* 137:1036-1040.
- [34] Ross JJ, Shamsuddin H (2004) Sternoclavicular septic arthritis: review of 180 cases. *Medicine (Baltimore).* 83: 139-148.
- [35] Song HK, Guy TS, Kaiser LR, Shrager JB (2002) Current presentation and optimal surgical management of sternoclavicular joint infections. *Ann Thorac Surg.* 73: 427-431.
- [36] Zehr KJ, Heitmiller RF, Yang SC (1999) Split pectoralis major muscle flap reconstruction after clavicular-manubrial resection. *Ann Thorac Surg.* 67: 1507-1508.
- [37] Chang RR, Mehrara BJ, Hu QY, Disa JJ, Cordeiro PG (2004) Reconstruction of complex oncologic chest wall defects: a 10-year experience. *Ann Plast Surg.* 52: 471-479; discussion 479.
- [38] O'Dwyer J (1887) Fifty cases of croup in private practice treated by intubation of the larynx, with a description of the method and of the dangers incident thereto. *Med Rec.* 32: 557-561.
- [39] Tansini I (1906) Sopra il mio nuovo processo di amputazione della mammella. *Gazz Med Ital Torino.* 57: 141.
- [40] Watson WL, James AG (1947) Fascia lata grafts for the chest wall defects. *J Thorac Surg.* 16: 399-406.
- [41] Kiricuta I (1963) The use of the great omentum in the surgery of breast cancer. *Presse Med.* 71: 15-17.
- [42] Mathes SJ (1995) Chest wall reconstruction. *Clin Plast Surg.* 22: 187-198.
- [43] Larson DL, McMurtrey MJ (1984) Musculocutaneous flap reconstruction of chest-wall defects: An experience with 50 patients. *Plast Reconstr Surg.* 73: 734-740.
- [44] Kohman LJ, Auchincloss JH, Gilbert R, Beshara M (1991) Functional results of muscle flap closure for sternal infection. *Ann Thorac Surg.* 52: 102-106.
- [45] Meadows JA 3rd, Staats BA, Pairolero PC, Rodarte JR, Arnold PG (1985) Effect of resection of the sternum and manubrium in conjunction with muscle transposition on pulmonary function. *Mayo Clin Proc.* 60: 604-609.
- [46] Netscher DT, Eladounikdachi F, McHugh PM, Thornby J, Soltero E (2003) Sternal wound debridement and muscle flap reconstruction: Functional implications. *Ann Plast Surg.* 51: 115-122; discussion 123-125.

- [47] Miller JJ Jr (2000) Postsurgical Empyema. In: Shields TW, LoCicero J III, Ponn RB, editors. *General Thoracic Surgery*. Vol 1, 5th ed. Philadelphia: Lippincott Williams and Wilkins. pp. 709-715.
- [48] Fonkalsrud EW, Beanes S, Hebra A, Adamson W, Tagge E (2002) Comparison of minimally invasive and modified Ravitch pectus excavatum repair. *J Pediatr Surg*. 37: 413-417.
- [49] Schaarschmidt K, Kolberg-Schwerdt A, Dimitrov G, Straubeta J (2002) Submuscular bar, multiple pericostal bar fixation, bilateral thoracoscopy: a modified Nuss repair in adolescents. *J Pediatr Surg*. 37: 1276-1280.
- [50] McCormack PM (1989) Use of prosthetic materials in chest wall reconstruction. *Assets and liabilities*. *Surg Clin N Am*. 69: 965-976.
- [51] Losken A, Thourani V, Carlson G, Jones G, Culbertson J, Miller J, Mansour K (2004) A reconstructive algorithm for plastic surgery following extensive chest wall resection. *Br J Plast Surg*. 57: 295-302.
- [52] Anderson B, Burt M (1994) Chest wall neoplasms and their management. *Ann Thorac Surg*. 58: 1774-1781.
- [53] Netscher D, Baumholtz M (2009) Chest reconstruction I: Anterior and anterolateral chest wall and wounds affecting respiratory function. *Plast Reconstr Surg*. 124: 240-252.
- [54] Mehta S, Sarkar S, Kavarana N, Bhathena H, Mehta A (1996) Complications of the pectoralis major myocutaneous flap in the oral cavity: A prospective evaluation of 220 cases. *Plast Reconstr Surg*. 98: 31-37.
- [55] Kroll S, Reece G, Miller M, Schusterman M (1992) Comparison of the rectus abdominis free flap with the pectoralis major myocutaneous flap for reconstruction in the head and neck. *Am J Surg*. 164: 615-618.
- [56] Castelli M, Pecorari G, Succo G, Bena A, Andreis M, Sartoris A (2001) Pectoralis major myocutaneous flaps: Analysis of complications in difficult patients. *Eur Arch Otorhinolaryngol*. 258: 542-545.
- [57] Hartrampf C, Schefflan M, Black P (1982) Breast reconstruction with a transverse abdominal island flap. *Plast Reconstr Surg*. 69: 216-225.
- [58] Rowsell A, Eisenberg N, Davies D, Taylor G (1986) The anatomy of the thoracodorsal artery within the latissimus dorsi muscle. *Br J Plast Surg*. 39: 206-209.
- [59] Moelleken B, Mathes S, Chang N (1989) Latissimus dorsi muscle-musculocutaneous flap in chest wall reconstruction. *Surg Clin North Am*. 69: 977-990.
- [60] Delay E, Gounot N, Bouillot A, Zlatoff P, Rivoire M (1998) Autologous latissimus dorsi breast reconstruction: A 3-year clinical experience with 100 patients. *Plast Reconstr Surg*. 102: 1461-1478.
- [61] Menke H, Erkens M, Olbrisch R. (2001) Evolving concepts in breast reconstruction with latissimus dorsi flaps: Results and follow up of 121 consecutive patients. *Ann Plast Surg*. 47: 107-114.
- [62] Moschella F, Cordova A (1999) A new extended external oblique musculocutaneous flap for reconstruction of large chest wall defects. 103: 1278-1385.
- [63] Villa M, Chang D (2010) Muscle and omental flaps for chest wall reconstruction. *Thorac Surg Clin* 20: 543-550.

- [64] Mathisen D, Grillo H, Vlahakes G, Daggett W (1988) The omentum in the management of complicated cardiothoracic problems. *J Thorac Cardiovasc Surg.* 95: 677-684.
- [65] Das S (1976) The size of the human omentum and methods of lengthening it for transplantation. *Br J Plast Surg.* 29: 144-170.
- [66] Weinzweig N, Yetman R (1995) Transposition of the greater omentum for recalcitrant median sternotomy wound infections. *Ann Plast Surg.* 34: 471-477.