

We are IntechOpen, the world's leading publisher of Open Access books Built by scientists, for scientists

6,900

Open access books available

186,000

International authors and editors

200M

Downloads

Our authors are among the

154

Countries delivered to

TOP 1%

most cited scientists

12.2%

Contributors from top 500 universities



WEB OF SCIENCE™

Selection of our books indexed in the Book Citation Index
in Web of Science™ Core Collection (BKCI)

Interested in publishing with us?
Contact book.department@intechopen.com

Numbers displayed above are based on latest data collected.
For more information visit www.intechopen.com



SubEndometrial Embryo Delivery (SEED) with Egg Donation – Mechanical Embryo Implantation

Michael Kamrava and Mei Yin

Additional information is available at the end of the chapter

<http://dx.doi.org/10.5772/50034>

1. Introduction

Egg quality at retrieval in IVF cycles is one of the prime prognostic factors of a successful outcome in IVF cycles. Thus egg donors provide a unique opportunity for assessing the feasibility of new protocols and techniques. In these situations, where the primary reason for resorting to IVF is peri/post menopausal state of the woman, using egg donors assures that at least the quality of the eggs are optimum, and most often the sperm quality, embryo quality at transfer, the recipient's uterus and endometrial condition are not adversely affected.

In patients undergoing *in vitro* fertilization (IVF) procedures one major set of hurdles, which often prevents healthy embryos from resulting in pregnancies, are problems associated with endometrial receptivity and implantation (1-4). From a clinical practice perspective in our new age of pre-implantation diagnosis and screening, the embryo transfer process may now be regarded as a rate limiting factor. Various techniques for embryo transfer (ET) have been advocated to increase pregnancy rates while reducing side effects from the procedure, such as lost embryos and ectopic pregnancies (5-7, 48). In addition, the advantages of using different catheters have been debated (8-11). These methods, however, use a “blind” technique of catheter introduction into the uterus. Since the embryo(s), having the zona pellucida at time of transfer, floats in the uterine cavity between one to three days from the time of transfer, the problems of “lost embryos” and the occurrence of ectopic pregnancies persist. We have hypothesized that the mechanical insertion of the blastocyst into the endometrium under direct visualization would increase the implantation and clinical pregnancy rate of IVF. The aim of this study was to re-investigate the potential of sub-endothelial ET, a procedure which originated from early mouse experiments (10) and in humans in the mid to late 1990's (12, 13) via trans-abdominal approaches. In contrast to these earlier investigations we propose to use hysteroscopy as a less invasive, visually confirmed, precise and reliable technique to direct and effect the implantation procedure.

2. Materials and methods

2.1. Patients

The study was approved by local review board at West Coast IVF Clinic, Inc. and a fully informed consent was obtained from all patients. There were 21 consecutive patients between 34-50 years of age with a diagnosis of peri/postmenopause or premature ovarian failure with or without tubal disease. They underwent 24 fresh IVF cycles in this study. Controlled ovarian hyperstimulation was initiated with follitropin β (Follistim®, Organon Pharmaceuticals, Inc.). Premature surge of endogenous gonadotropins were controlled with ganirelix acetate (Antagon®, Organon Pharmaceuticals, Inc.). Oocyte retrieval was carried out in an office setting under local anesthesia and mild sedation. Embryo culturing was performed using sequential media (G1 and G2; Vitrolife, or Early Cleavage Medium® supplemented with SSS and Complete Multiblast Medium® with SSS; Irvine Scientific, USA) to day five or six. Up to 2 grade 1 expanded/hatching blastocysts were transferred (Fig 1A). Recipients were down regulated with long acting GnRH analog (Leuprolide acetate Depot, Abbott, USA). The endometrium was primed with Estradiol 2 mg tid until the day of donor egg retrieval, when it was continued or reduced to 1 mg tid. Luteal support was maintained with Progesterone in oil IM 50-100 mg/progesterone vaginal tablets (Endometrin®, Ferring, USA), 100 mg tid. until the day of Pregnancy test. If the test was positive progesterone was continued through the 8th week of pregnancy or sooner until a rise in serum progesterone was noted as the pregnancy progressed.

Serum human chorionic gonadotropin (hCG) was quantified on the tenth or eleventh day after SEED was performed on day six or five after retrieval, respectively. Although the assay sensitivity for detection of hCG was at 2 IU/ml a concentration of >5 IU/ml was used for confirmation of pregnancy.

2.2. Description of hysteroscopic implantation

A lightweight flexible mini- hysteroscope (Storz™) was used for visualization of the endometrial cavity (Fig 1D). The scope incorporates a flexible distal end of 3mm in diameter with a straight through operating channel. In addition, the optic filter is directly connected to a light source, decreasing the weight of the scope. Nitrogen gas instead of CO₂ is used for uterine distention. Nitrogen gas is inert and is used in the trimixture of Nitrogen, Oxygen and Carbon Dioxide utilized for embryo culture in an IVF laboratory. Gas pressure is set at max 70 mm mercury (HG). A maximum of 50 cc of gas is used

during the entire procedure. The transfer catheter is polycarbonate based with a tapered tip (to 500 μ m), beveled to 45-60° (Initially made by Cook OB/GYN™, Spencer, Indiana, USA and subsequently made by Precision Reproduction, LLC Los Angeles, CA 90212 USA). The catheter is inserted to a distance of 0.5cm horizontally and to a depth of approximately 1mm below the surface of the endometrium, and 2 cm away from the junction of tuboendometrial border as observed hysteroscopically where the endometrium is thickest as seen through the

hysteroscope. The embryo(s) is deposited under direct hysteroscopic visualization (Fig 1D) using a 100 μ l Hamilton syringe (Hamilton Company; Nevada, USA). No more than 2 embryos were implanted at any one site.

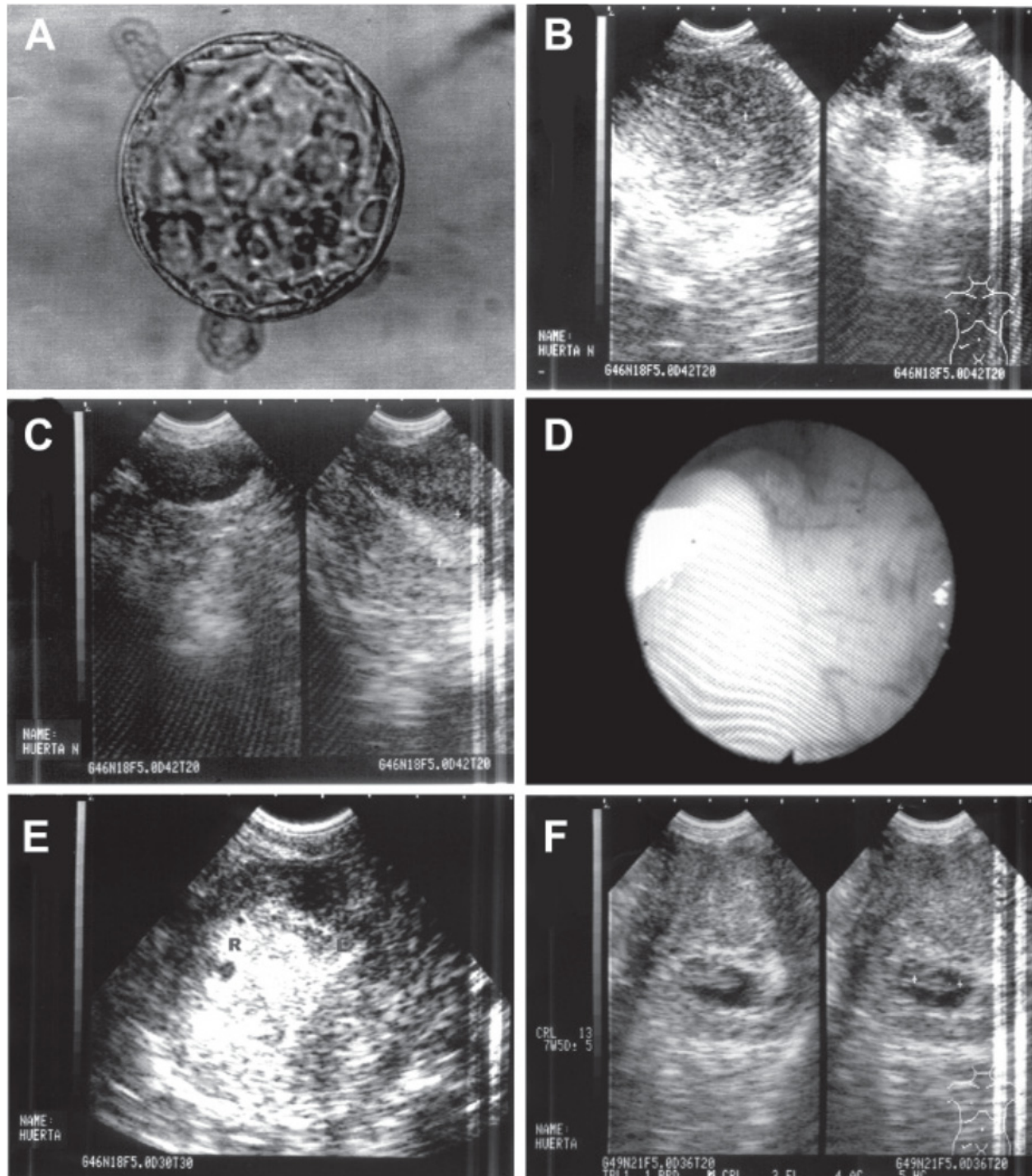


Figure 1. Stages of subendometrial embryo transfer. Expanded hatching blastocyst (A); estrogenic endometrium (B); progestational endometrium (C); subendometrial embryo transfer (D); early gestational sac at 5 weeks (E); fetus at 6 weeks (F).

3. Results

In this series, 24 IVF cycles in 21 patients were completed. Endometrial thicknesses varied between 7 and 16mm by transvaginal ultrasound. There were sixteen positive β hCG's at levels greater than 5 IU/ml. There were five biochemical pregnancies, and eleven clinical pregnancies as evidenced by the presence of a gestational sac (Fig 1E) visualized by ultrasound examination at five weeks of gestation and heart beat at six weeks of gestation (Fig 1F). There were 5 spontaneous abortions. Healthy babies were delivered by seven patients. No ectopic pregnancies (tubal, placenta previa, cervical, or heterotopic) were seen (Table 1). There were 4 twins from day five and none from day 6 implantations.

	Day 5 Implantation	Day 6 Implantation	Combined D5 and D6
Patient starts	14	10	24
Total Pregnancy/Start	8(57%)	8(80%)	16(67%)
Biochemical Pregnancy	2	2	4
Ectopic Pregnancy	0	0	0
Spontaneous Abortions	2	3	5
Multiple Pregnancy	4	0	4
Live/Start	4 (29%)	3 (30%)	7 (29%)

Table 1.

4. Discussion

Various techniques and technologies for ET have been proposed since the introduction of IVF. This list includes ultrasound-controlled transcervical intrauterine transfer or transmyometrial transfer and more invasive procedures, often referred to as surgical ET, which include: gamete intra-fallopian transfer (GIFT), zygote intra-fallopian transfer (ZIFT), pronuclear stage transfer and embryo intrafallopian transfer (EIFT) (14-17). Although ultrasound guided ET was desired to improve successful pregnancy outcomes and reduce side effects, it has been received with mixed results (18-32). It also requires simultaneous coordination of two professionals, the physician who performs the transfer and the ultrasonographer (29). Furthermore, all transcervical and transmyometrial techniques involve "blind" introduction of the embryo(s) via transfer catheters with no real time flexibility of the tip of the transfer catheter and subsequent release of embryo(s) onto the surface of the endometrium. As a result if the embryo fails to adhere, due to some luteal phase defect or other, undefined "implantation window" problem, there is a significant risk that the embryo might be washed out of the cervix or become lodged in the fallopian tubes. In part, to compensate for this potential conceptus loss, physicians have adopted the practice of transferring higher numbers of embryos back to the uterus. Here we re-investigate the potential of surgical implantation of embryos developed to the blastocyst stage *in vitro* by day 5 or 6 post insemination. It does appear that this procedure may enable

circumvention of those problems associated with the maternal receptivity aspect of the so called “window of implantation”(4). Under normal, non-assisted, circumstances, implantation begins six to seven days post ovulation. It involves multiple steps which can be summarized as pre-attachment, attachment-invasion, and decidualization - early placentation (33, 34). The reader is referred to a recent paper by Dominguez et al. (2) for a comprehensive review. Thus far, mechanisms for repairing defects in this process or clinically relevant markers of uterine receptivity have proven elusive. Similarly to the now well-accepted procedure of ICSI (35), where a single sperm is mechanically injected into an oocyte, with the development of this project we aim to develop an instrument and procedure whereby “mechanical” implantation of the embryo is achieved.

Ectopic Pregnancies after IVF specially for tubal disease account for approximately 8-10% of pregnancies (7, 48). Hysteroscopic SEED minimizes the chances of “losing” the embryo, and virtually eliminates ectopic pregnancies (tubal, placenta previa, cervical, or heterotopic) from embryo transfer, as the embryo(s) is embedded into the endometrium and not floating in the uterus. Using the flexible mini-hysteroscope affords an objective and accurate confirmation of the placement of the embryo that should make the procedure replicable, and thus more reliable with more consistent and improved results. Allowing the embryos to reach the blastocyst stage prior to transfer is gaining more acceptance (37-39). It allows both for more normal embryos to be naturally selected and for a more accurate selection of more viable, healthier embryo(s) (40-42). Thus a less number of embryos can be selected for transfer with more certainty for a successful singleton pregnancy (43, 44). This is congruent with the results in this study where there were no multiple pregnancies from day 6 implantations (Table 1).

A previous report on the use of SEED technique documented a promising set of results in patients with a variety of reasons for IVF (36). In this report we wanted to focus on a specific group of patients to better define the role of SEED technique. An overall pregnancy rate of 67% with a live birth rate of 29% was achieved. This is consistent with treating a better prognostic group of patients, i.e. egg donors in contrast with a non selective group of patients (36).

A possible drawback with the transcervical hysteroscopic embryo implantation (SEED) is the potential to scratch the endometrium and trigger some deleterious effect. Yet this is a potential hazard of “blind” procedures as well. The risk of disruption of the uterine lining, however is postulated to be less than “blind” and ultrasound guided transfers due to the advantage of direct visualization of the uterine lining and not requiring movement of the catheter to facilitate identification during ultrasound (32). As opposed to rigid endoscopes which may cause trauma to the uterus, the hysteroscope used in this study is a mini-hysteroscope with a 3mm diameter and flexible tip that allows one to easily follow the curvature of the uterus. With this protocol, though, the physician may then choose a non-scratched portion of the endometrium for implantation. Having said that, a growing number of literature suggests that mild inflammation may very well facilitate, if not be required for implantation and placentation (45-47).

Likewise, visualizing implantation allows for the physician to avoid losing embryos due to intrinsic uterine contractions or those brought on by the transfer, enabling the physician to defer the procedure until the enhanced activity has subsided. Furthermore, visualization allows one to place the embryo at a different location if trauma ensues. Also, the catheter used is semi-rigid to prevent kinking as it passes through the endoscope yet with enough flexibility to bend with the endoscope however bend and become kinked to prevent inadvertent passage into the myometrium. In addition, the uterine cavity is allowed to be distended during introduction of the hysteroscope into the uterus by slow passage through the endocervical canal. This would allow the hysteroscope to move in a gaseous space and not in direct contact with the endometrium as is the case with the blind procedure. In our study, no disruption to the uterine lining or uterine bleeding occurred. Increased cost is another drawback, however utilizing a hysteroscope with an objective replicable procedure that improves results will decrease the costs from multiple failed IVF-ET attempts and improve patient satisfaction.

5. Conclusion

We suggest that using a hysteroscopic subendometrial embryo delivery (SEED) for transferring advanced blastocyst(s) is a reasonable and effective method of embryo transfer. It will virtually eliminate ectopic pregnancies of all locations, i.e. tubal pregnancies as well as placenta previa, cervical, and heterotopic pregnancies, from IVF. Furthermore, it would allow for a targeted objective, reliable, safe and replicable method for single embryo transfer, as new and improved techniques along with modified media for handling, culture, and selection of embryos are introduced. This would greatly alleviate the anxiety, and cost to the patient as it decreases the number of attempts at using IVF in achieving a successful singleton pregnancy.

Author details

Michael Kamrava and Mei Yin
West Coast IVF Clinic, Inc., Beverly Hills, California, USA

Acknowledgement

Supported by West Coast IVF Clinic, Inc. and LA IVF Lab, LLC, Beverly Hills, CA USA

6. References

- [1] Sharkey AM, Smith SK. The endometrium as a cause of implantation failure. *Best Pract Res Clin Obstet Gynaecol* 2003;17:289-307.
- [2] Dominguez F, Avila S, Cervero A, Martin J, Pellicer A, Castrillo JL, Simon C. A combined approach for gene discovery identifies insulin-like growth factor-binding

- protein-related protein 1 as a new gene implicated in human endometrial receptivity. *J Clin Endocrinol Metab* 2003;88:1849-57.
- [3] Jokimaa V, Oksjoki S, Kujari H, Vuorio E, Anttila L. Altered expression of genes involved in the production and degradation of endometrial extracellular matrix in patients with unexplained infertility and recurrent miscarriages. *Mol Hum Reprod* 2002;8:1111-6.
 - [4] Kabir-Salmani M, Murphy C, Hosseini A, Valojerdi M. Ultrastructural Modifications of Human Endometrium during the Window of Implantation. *IJFS* 2:2008:44-59
 - [5] Sharif K, Afnan M, Lenton W, Bilalis D, Hunjan M, Khalaf Y. Transmyometrial embryo transfer after difficult immediate mock transcervical transfer. *Fertil Steril* 1996;65:1071-4.
 - [6] Mansour RT, Aboulghar MA, Serour GI, Amin YM. Dummy embryo transfer using methylene blue dye. *Hum Reprod* 1994;9:1257-9.
 - [7] Velalopoulou A. Ectopic Pregnancy and assisted reproductive technologies: A systematic review. *Ectopic Pregnancy, Modern management and diagnosis Intech* 2011; 45-78.
 - [8] Biervliet FP, Lesny P, Maguiness SD, Robinson J, Killick SR. Transmyometrial embryo transfer and junctional zone contractions. *Hum Reprod* 2002;17:347-50.
 - [9] Ghazzawi IM, Al-Hasani S, Karaki R, Souso S. Transfer technique and catheter choice influence the incidence of transcervical embryo expulsion and the outcome of IVF. *Hum Reprod* 1999;14:677-82.
 - [10] Groutz A, Lessing JB, Wolf Y, Azem F, Yovel I, Amit A. Comparison of transmyometrial and transcervical embryo transfer in patients with previously failed in vitro fertilization-embryo transfer cycles and/or cervical stenosis. *Fertil Steril* 1997;67:1073-6.
 - [11] Nakayama T, Goto Y, Kanzaki H, Takabatake K, Himeno T, Noda Y, Mori T. The use of intra-endometrial embryo transfer for increasing the pregnancy rate. *Hum Reprod* 1995;10:1833-6.
 - [12] Asaad M, Carver-Ward JA. Twin pregnancy following transmyometrial-subendometrial embryo transfer for repeated implantation failure. *Hum Reprod* 1997;12:2824-5.
 - [13] Itskovitz-Eldor J, Filmar S, Manor D, Stein D, Lightman A, Kol S. Assisted implantation: direct intraendometrial embryo transfer. *Gynecol Obstet Invest* 1997;43:73-5.
 - [14] Wimalasundera RC, Trew G, Fisk NM. Reducing the incidence of twins and triplets. *Best Pract Res Clin Obstet Gynaecol* 2003;17:309-29.
 - [15] Pasqualini RS, Quintans CJ. Clinical practice of embryo transfer. *Reprod Biomed Online* 2002;4:83-92.
 - [16] Choe JK, Nazari A, Check JH, Summers-Chase D, Swenson K. Marked improvement in clinical pregnancy rates following in vitro fertilization-embryo transfer seen when transfer technique and catheter were changed. *Clin Exp Obstet Gynecol* 2001;28:223-224.
 - [17] Schoolcraft WB, Surrey ES, Gardner DK. Embryo transfer: techniques and variables affecting success. *Fertil Steril* 2001;76:863-870.

- [18] Lambers MJ, Dogan E, Kosteljik H, Lens JW, Schats R, Hompes PGA. Ultrasonographic-guided embryo transfer does not enhance pregnancy rates compared with embryo transfer based on previous uterine length measurement. *Fertil Steril*. 2006; 86: 867-872.
- [19] Flisser E, Grifo JA. Is what we clearly see really so obvious? Ultrasonography and transcervical embryo transfer - a review. *Fertil Steril*. 2007; 87: 1-5.
- [20] Allahbadia G, Gandhi G, Athavale U, Merchant R, Virk SPS, Kaur K. A blind embryo transfer is a rate limiting step to successful IVF. *Fertil Steril*. 2002; 78 Suppl 1: S157-S158.
- [21] Puerto B, Creus M, Carmona F, Cívico S, Vanrell JA, Balasch J. Ultrasonography as a predictor of embryo implantation after in vitro fertilization: a controlled study. *Fertil Steril*. 2003; 79: 1015-1022.
- [22] Tiras B, Polat M, Korucuoglu U, Zeyneloglu HB, Yarali H. Impact of embryo replacement depth on in vitro fertilization and embryo transfer outcomes. *Fertil Steril*. 2009; 7: 1666.
- [23] Flisser E, Grifo JA, Krey LC, Noyes N. Transabdominal ultrasound - assisted embryo transfer and pregnancy outcome. *Fertil Steril*. 2006; 85: 353-357.
- [24] Gergely RZ, Danzer H, Surrey M, Hill D. Maximal implantation potential (MIP) pointsuggested target for optimal embryo placement within the uterine cavity during embryo transfer. *Fertil Steril*. 2007; 88(1): S328.
- [25] Allahbadia GN, Kadam K, Gandhi G, Arora S, Valliappan JB, Joshi A, et al. Embryo transfer using the SureView catheter-beacon in the womb. *Fertil Steril*. 2010; 93: 344-350.
- [26] Anderson RE, Nugent NL, Gregg AT, Nunn SL, Behr BR. Transvaginal ultrasoundguided embryo transfer improves outcome in patients with previous failed in vitro fertilization cycles. *Fertil Steril*. 2002; 77: 769-775.
- [27] Kol S. Ultrasound-guided embryo transfer - a special role in patients with certain uterine defects. *Fertil Steril*. 2008; 89: 260.
- [28] Kiltz RJ, Woodhouse D, Restive L, Miller D, Sciera A, Fundalinski J. Vaginal vs. abdominal ultrasound guidance for embryo transfer. *Fertil Steril*. 2006; 86 Suppl 1: S245-S246.
- [29] Gergely RZ, DeUgarte CM, Danzer H, Surrey M, Hill D, DeCherney AH. Three dimensional/four dimensional ultrasound-guided embryo transfer using the maximal implantation potential point. *Fertil Steril*. 2005; 84: 500- 503.
- [30] Pinto AB, Wright JD, Keller SL, Odem RR, Ratts VS, William DB. Ultrasound guided embryo transfer in selected patients undergoing IVF. *Fertil Steril*. 2002; 77(3): S19.
- [31] Abou-Setta AM, Mansour RT, Al-Inany HG, Aboulghar MM, Aboulghar MA, Serour GI. Among women undergoing embryo transfer, is the probability of pregnancy and live birth improved with ultrasound guidance over clinical touch alone? A systemic review and metaanalysis of prospective randomized trials. *Fertil Steril*. 2007; 88: 333-341.
- [32] Frattarelli JL, Miller KL. The pre-cycle blind mock transfer is an inaccurate predictor of anticipated embryo transfer depth. *Fertil Steril*. 2006; 86(3): S184.

- [33] Morrish DW, Dakour J, Li H. Life and death in the placenta: new peptides and genes regulating human syncytiotrophoblast and extravillous cytotrophoblast lineage formation and renewal. *Curr Protein Pept Sci.* 2001; 2:245-59.
- [34] Giudice LC. Genes associated with embryonic attachment and implantation and the role of progesterone. *J Reprod Med.* 1999; 44: 165-71.
- [35] Payne D. Embryo viability associated with microassisted fertilization. *Baillieres Clin Obstet Gynaecol.* 1994; 8: 157-75.
- [36] Kamrava, M, Yin M. Hysteroscopic Subendometrial Embryo Delivery (SEED), Mechanical Embryo Implantation. *International Journal of Fertility and Sterility.* Vol 4, No 1, Apr-Jun 2010, Pages: 29-34
- [37] Shapiro BS, Daneshmand ST, Garner FC, Aguirre M, Hudson C, Thomas S. High ongoing pregnancy rates after deferred transfer through bipronuclear oocyte cryopreservation and post-thaw extended culture. *Fertil Steril.* 2009; 92: 1594-1599.
- [38] Goto S, Kadowaki T, Hashimoto H, Koeguchi S, Shiotani M. Stimulation of endometrium embryo transfer can improve implantation and pregnancy rates for patients undergoing assisted reproductive technology for the first time with a high-grade blastocyst. *Fertil Steril.* 2009; 92: 1264-1268.
- [39] Lin PY, Huang FJ, Kung FT, Wang LI, Chang SY, Lan KC. Comparison of the offspring sex ratio between fresh and vitrificationthawed blastocyst transfer. *Fertil Steril.* 2009; 92: 1764-1766.
- [40] Okimura T, Kuwayama M, Segawa T, Takehara Y, Kato K, Kato O. Relations between the timing of transfer, expansion size and implantation rates in frozen thawed single blastocyst transfer. *Fertil Steril.* 2009; 92(3 Suppl 1): S246.
- [41] Stevens J, Schoolcraft WB, Schlenker T, Wagley L, Munne S, Gardner DK. Day 3 Blastomere Biopsy Does Not Affect Subsequent Blastocyst Development or Implantation Rate. *Fertil Steril.* 2000; 74 Suppl 1: S173.
- [42] Weston G, Osianlis T, Catt J, Vollenhoven B. Blastocyst transfer does not cause a sexratio imbalance. *Fertil Steril.* 92: 1302-1305.
- [43] Stillman RJ, Richter KS, Banks NK, Graham JR. Elective single embryo transfer: A 6-year progressive implementation of 784 single blastocyst transfers and the influence of payment method on patient choice. *Fertil Steril.* 2009; 92: 1895-1906.
- [44] Sparks AE, Ryan GL, Sipe CS, Dokras AJ, Syrop CH, Van Voorhis BJ. Reducing the risk of multi-fetal gestation by implementation of a single blastocyst transfer policy. *Fertil Steril.* 2005; 84(Suppl 1): S86-S87.
- [45] Johnson GA, Burghardt RC, Bazer FW, Spencer TE. Osteopontin: roles in implantation and placentation. *Biol Reprod.* 2003; 69(5): 1458-1471.
- [46] Barash A, Dekel N, Fieldust S, Segal I, Schechtman E, Granot I. Local injury to the endometrium doubles the incidence of successful pregnancies in patients undergoing in vitro fertilization. *Fertil Steril.* 2003; 79: 1317- 1322.
- [47] Wilcox AJ, Weinberg CR, O'Connor JF, Baird DD, Schlatterer JP, Canfield RE, et al. Incidence of early loss of pregnancy. *N Engl J Med.* 1988; 319: 189-194.

- [48] Ketefian A, Sproul K, Buyalos R, Hubert G, Kumar A. Ectopic Pregnancy (EP) after In Vitro Fertilization (IVF) and Subsequent Pregnancy Outcomes. *Fert Steril*. 2007 vol 87 suppl 2, S16-17.

IntechOpen

IntechOpen