

# We are IntechOpen, the world's leading publisher of Open Access books Built by scientists, for scientists

6,900

Open access books available

186,000

International authors and editors

200M

Downloads

Our authors are among the

154

Countries delivered to

TOP 1%

most cited scientists

12.2%

Contributors from top 500 universities



WEB OF SCIENCE™

Selection of our books indexed in the Book Citation Index  
in Web of Science™ Core Collection (BKCI)

Interested in publishing with us?  
Contact [book.department@intechopen.com](mailto:book.department@intechopen.com)

Numbers displayed above are based on latest data collected.  
For more information visit [www.intechopen.com](http://www.intechopen.com)



---

# Visceral Artery Aneurysms

---

Petar Popov and Đorđe Radak

Additional information is available at the end of the chapter

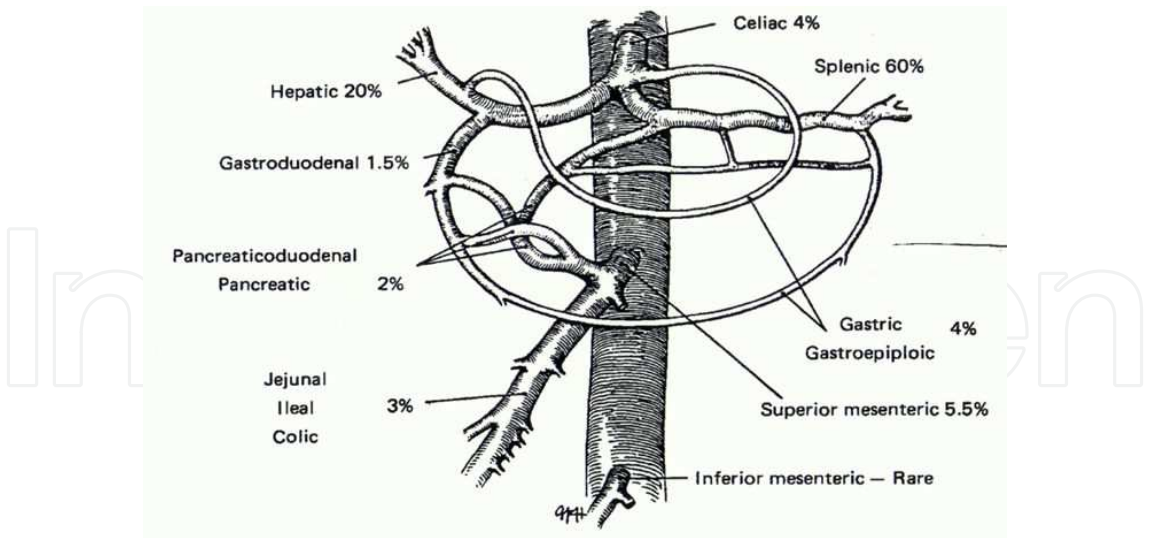
<http://dx.doi.org/10.5772/52814>

---

## 1. Introduction

In clinical practice relatively rare vascular entity, visceral artery aneurysms (VAA) can thrombose, embolise and rupture, causing high morbidity and mortality [1]. Splanchnic aneurysms pose a difficult therapeutic challenge especially in emergency cases. Almost 22% of VAA patients with mortality as high as 8.5%, are diagnosed after rupture with variable clinical manifestations that raise the risk of misdiagnosis and unwarranted treatment [2]. Frequent use of imaging techniques and especially computed tomography scanning have significant impact on the overall increase in the number of new cases. Mostly, VAA are being discovered incidentally during assessment for abdominal pain or other disorders. Regardless of how VAA are discovered, the choice of treatment depends on clinical presentation, underlying etiology, location, general health status, and comorbidity factors. For many years surgical treatment, involving either aneurysm resection with bypass or ligation, were the only therapeutic options, especially in emergency cases [3]. At the present time, however, endovascular techniques are considered the method of choice for first-line treatment and good results have been obtained in emergency cases [4,5].

An estimated 3000 cases have been reported in the literature with an incidence of 1% in the general population and 0.1% to 10% in autopsy series [2]. VAA are described in the literature 200 years ago, and the first successful surgical resection was performed by Cooley and DeBakey in 1949. [6]. The most commonly involved arteries are the splenic artery aneurysms in 60% of cases and the hepatic artery aneurysms in about 20% of cases. Other splanchnic artery aneurysms are discovered in 20-40% of cases. Other sites include the superior mesenteric artery (SMA-5.5%), celiac trunk and gastric artery (4%), gastroepiploic artery, jejunal artery, ileal artery, and colonic artery (3%), and, inferior mesenteric artery, pancreaticoduodenal artery and pancreatic arteries (2%) [2,7,8,9] (Figure 1, Table 1).



**Figure 1.** Visceral artery aneurysms distribution.

Aneurysm localization	Frequency	M/W	Rupture rate	Mortality
Splenic artery	60%	1:4	2%	25% nopregnent
				70% mother
				75% fetus
Hepatic arteries	20%	2:1	20%	35%
SMA	5.5%	1:1	rare	50%
Truncus caeliacus	4%	1:1	13%	50%
Gastric, Gastroepiploic	4%	3:1	90%	50%
Jejunal, Ileal, Colic	3%	1:1	30%	70%
Pancreaticoduodenal	2%	4:1	75% inflammatory	50%
Gastroduodenal			50% noninflammat.	

**Table 1.** Visceral artery aneurysms, frequency and distribution.

The earliest recorded work that describes visceral artery aneurysms was announced by French physician, Beaussiera, 1770, who presented the splenic artery aneurysm in 60-year-old female cadaver during an autopsy demonstration after injection contrast into the aorta and femoral veins [10].

The first record of clinical symptoms of VAA recorded Quinkue in 1871, when he described the classic "triad" of symptoms: abdominal pain, obstructive jaundice and hemobila, caused by hepatic artery aneurysm existence [11,12,13].

The first successful surgical treatment of the common hepatic artery aneurysms by artery ligation has been noted by Kehr in 1903 [14]. Thirty years later, in 1932 Lindboa was the first who preoperatively successfully diagnosed SAA, which is then surgically resolved [15].

Although visceral artery aneurysms are rare they are certainly clinically significant pathological changes, with an incidence of 0.01% to 0.2% in routine autopsies, with increasing tendency of appearance in aging population [2]. By the early nineties, diagnosis and therapeutic management of splanchnic arterial aneurysms weren't enough successful which resulted in the rupture, and the detection of these lesions only on the autopsy table. Advances in surgical and endovascular techniques have led to numerous and qualitative change in the approach to treatment of these lesions.

### 1.1. Aneurysm of the splenic artery

Splenic artery aneurysm is the most common splanchnic aneurysms (58-67% of all cases), the third most prevalent in the abdomen, after aneurysms of the abdominal aorta and iliac arteries. They are usually asymptomatic in nature (27% is associated with pain in the abdomen) [14]. The first splenic artery aneurysm is described Beaussier (1770) [10]. At the middle of the last century (1953), Owens and Coffey gave an extensive review of previously reported SAA in the literature and described 262 cases [16]. American history records the death (1881) President James A. Garfield as a result of rupture of splenic artery aneurysm, two months after he was wounded in the stomach during the assassination attempt [17].



In Anglo-Saxon literature the incidence of occurrence lineal artery aneurysm ranges from 0.7% to 10.4% of the total population based on data obtained from the autopsy report. In the literature, reported splenic aneurysm diameter was found 30 cm in diameter but they are usually less than 3 cm. SAA are usually solitary, saccular in shape and localized in the distal third of artery, the bifurcation region, the splenic hilum. Splenic aneurysms are more common in women (4:1), in the sixth decade of life, as much as 80% of all cases are older than 50 years. One third of those patients have multiple aneurysm localization [19-21].

### 1.2. Clinical presentation

SAA are usually incidental, unexpected findings on the control, the native image of the abdomen, CT scan or angiography. When patients have symptoms, they describe vague pain in the left upper abdominal quadrant and left thigh. Since 40-50% of patients have moderate splenomegaly, and in about 10% of patients auscultation soundness of the left upper quadrant of the abdomen. Rare are those in which the pulsatile tumefaction took hold in the region under [20, 22].

### 1.3. The pathogenesis, formation causes

Of these aneurysms are not completely clear, but increased blood flow through the splenic artery may be a risk factor (hypertension, pregnancy). Some researchers claim that these hemodynamic instability lead to irreversible damage of tunica media and thus represent a predisposing factor for aneurysm formation. Subsequent muscular dystrophy and calcification of damaged artery wall is a secondary process [23, 24]. The recorded incidence of SAA in patients with liver cirrhosis and portal hypertension ranges from 7 to 20% and 8-13% of patients waiting for liver transplantation and after liver transplantation because of the large portosystemic shunt, which causes the increase in splenic artery volume [25]. Other possible causes are essential hypertension, septic embolus, blunt trauma, the weakening of the arterial wall as a result of local inflammation (pancreatitis), subacute bacterial endocarditis. Less common causes are inherited diseases characterized by the development of visceral artery aneurysms multiple or associated with the appearance of polycystic kidney disease and systemic lupus erythematosus. SAA can also occur as a consequence of renal artery fibromuscular dysplasia [26].

After all, arteriosclerosis is the most common histopathological findings and probably postaneurysmatic phenomenon rather than a primary cause of the aneurysm

The risk of *rupture* is difficult to estimate. Until 1980, about 10% of SAA was ruptured at the time of diagnosis, but in more recent series the incidence of rupture is at the level of 3% [2,8,19].

When rupture, SAA usually cause acute abdominal pain, irradiating in the left flank, back and subscapular region and can cause shock, abdominal distension, and finally death. Aneurysms can rupture into free space or omentum minus. The phenomenon of "double" rupture was reported in 20-30% of cases. In these patients if we do not take anything, the initial bleeding in omentum minus can provoke pain and transient hypotension and continues on a further rupture in the peritoneal cavity, which happens in the next 48 hours [19, 27, 28]. This "guard" period between the initial and subsequent bleeding gives room for the timely diagnosis and intervention. Overall mortality from ruptured SAA should be between 10 and 25%. Symptomatic, large and/or rapidly growing aneurysms, pregnancy, portal hypertension, liver transplantation and portocaval shunts are associated with increased risk of aneurysm rupture. Rupture rarely occurs when the diameter is less than 2.5 cm [28]. Pregnancy is associated with 20 to 50% of rupture rate, usually in the third trimester or early postpartum period [24]. Barretin his coworkers, reported rupture rate of 12% in the first two trimester, 69% in the third, 13% during labor, and 6% were recorded in puerperium. Mortality rate of ruptured SAA during pregnancy is about 75% of mothers and 95% for fetus. On the other hand, the mortality rates in women who are not pregnant are considerably less [29].

### 1.4. Treatment

Different therapeutic options are available for patients with SAA, including conventional surgery, endovascular treatment, and, more recently, laparoscopic surgery. Choice of treat-

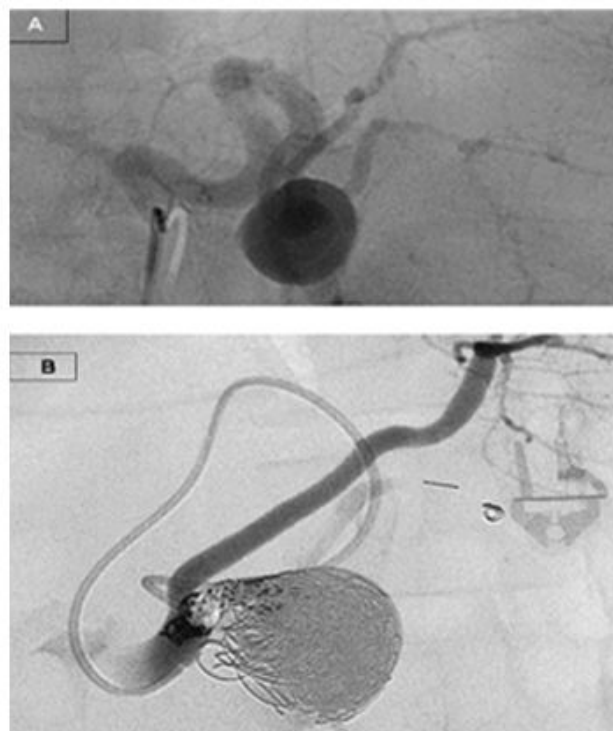
ment depends primarily on clinical presentation, aneurysm location, associated risk factors, and overall patient status [30, 31, 32].

Patients who arrive with signs of rupture, hemorrhagic shock or unstable hemodynamic status require urgent treatment. In such situations some authors used the endovascular approach in solving problems; otherwise, ligation of the splenic artery without further reconstruction was the most used technique [33].

Recently, we use a new, promising option: endovascular coil embolization approach (figure 2,3), stent-graft application and the laparoscopic approach to splenic artery ligation. Selective splenic artery catheterization and coil embolization of aneurysmal sac is proposed in high-risk patients or the rupture of the aneurysm [33,34].

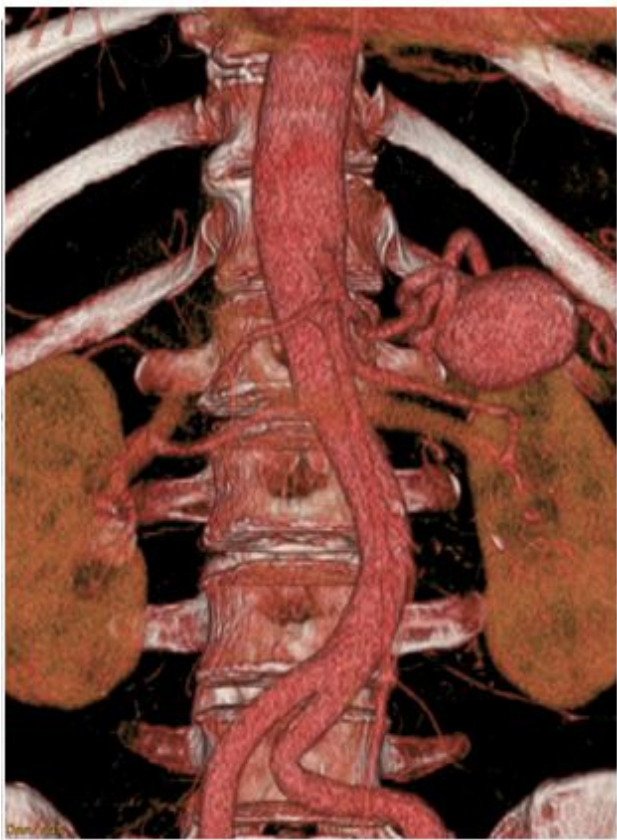Numbers of patients who are treated in this way are rapidly increasing. The data obtained from follow-up investigations are still insufficient to be able to make a final doctrine, especially concerning the possibility of re-creating an even greater place in the aneurysmal sac as a result of recanalization. When the embolization is technically challenging or contraindicated primarily by close contact of the aneurysm with the spleen, there are the possible options for open surgery (figure 4, 5) or laparoscopic artery ligation.

*Treatment is indicated when the aneurysm is symptomatic, with diameter greater than 3 cm, and in pregnant women or women of childbearing age want to get pregnant [28].*

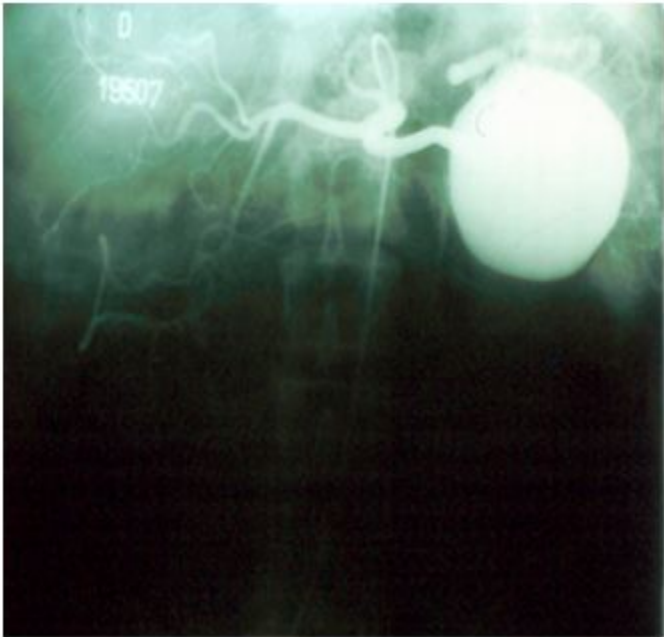


**Figure 2.** Splenic artery aneurysm embolization

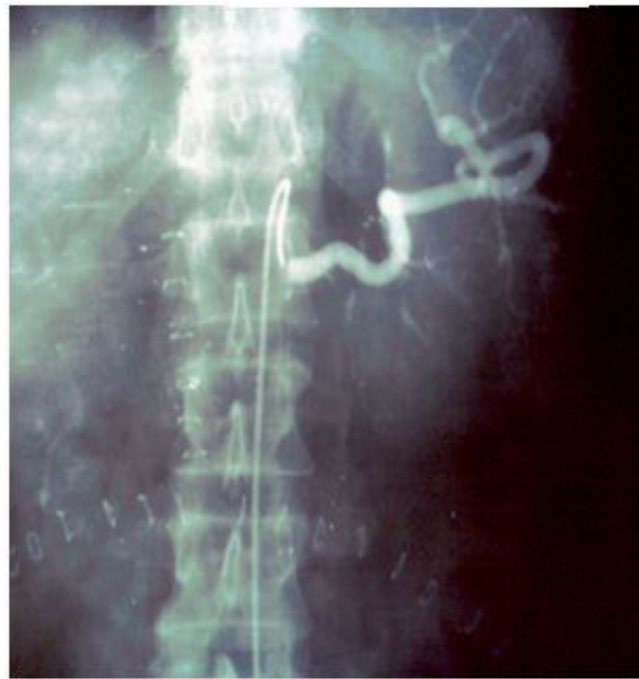



**Figure 3.** Splenic artery aneurysm. MSCT



**Figure 4.** Splenic artery aneurysm angiography before and after surgical reconstruction



**Figure 5.** Splenic artery aneurysm angiography before and after surgical reconstruction

### 1.5. Hepatic Artery Aneurysms

Hepatic artery aneurysms (HAA) is second in height among VAA, accounting for 20% of all splanchnic artery aneurysms. In 1819, Wilson was the first who described it. Historically at the beginning, before antibiotic era, mycotic aneurysms were dominantly present among discovered and treated HAA, but now has been reduced to 10% of all. Most of these aneurysms was admitted to the state of rupture or accidentally discovered during autopsy [2,3,8].

Atherosclerosis is considering a basic cause in about 30-50% occurrence of HAA, while still posing as a secondary process. Less common causes of these lesions are vasculitis, such as polyarthritis nodosa, inflammatory processes caused by cholecystitis or pancreatitis, Marfan's syndrome, Ehlers-Danlos syndrome, fibromuscular dysplasia, cystic medial necrosis (24%) and trauma (22%) [35].

Posttraumatic false aneurysms accounts for about 20%, they are the most often the result or penetrating and crush injuries or wounds, surgical procedures, liver transplantation or occurring after percutaneous needle biopsy of the liver (transhepatic cholangiography) [36].

Aneurysms are more common in man (2:1) and mostly extrahepatic located (80%). Of that, extrahepatic HAA 60% are located on common hepatic artery, 30% involve the right hepatic artery and 5% the left hepatic artery. Right incidence of HAA is unknown. Of the 2,091,965 patients reviewed at the Mayo Clinic for 18 years, hepatic aneurysms were seen in only 36 patients (12% of all VAA), the incidence was 0.002%. There is still some controversy about the incidence of hepatic aneurysm rupture and should be 20% to 80% [36].



*Stanley* describes in his research 162 HAA cases, 75% were located extrahepatically, of which 63% of aneurysms were located on common hepatic artery, 28% on the right hepatic artery and 5% on the left, and finally 4% in both hepatic arteries. Atherosclerotic aneurysms are almost exclusively positioned extrahepatically of which 96% were placed on common hepatic artery. The remaining 25% HAA were intrahepatically located, predominantly pseudoaneurysm arising mainly as a result of vascular injury and trauma [1].

Hepatic aneurysms become clinically apparent when there is erosion of the biliary tree and/or portal vein with subsequent development of portal hypertension, rupture in the retroperitoneal space and/or peritoneal cavity. Bleeding into the abdominal cavity is a catastrophic event, with a mortality rate of 82% [37- 39]. *Quincke's* classic triple symptoms: jaundice, biliary colic's and gastrointestinal bleeding suggests hemobilia that occurs in one third of patients [36].

HAA are often symptomatic. The most common symptom is accompanied by malaise or right-hand abdominal pain radiating to the back, sometimes epigastric pain. Palpable masses are rare finding.

Native roentgen examinations of the abdomen or upper gastrointestinal tract by contrast medium may indicate the presence of HAA, especially if it is visible calcification in the wall of the aneurysmal sac in the right hypochondrium or the existence of a defect in the filling of the duodenum [40].

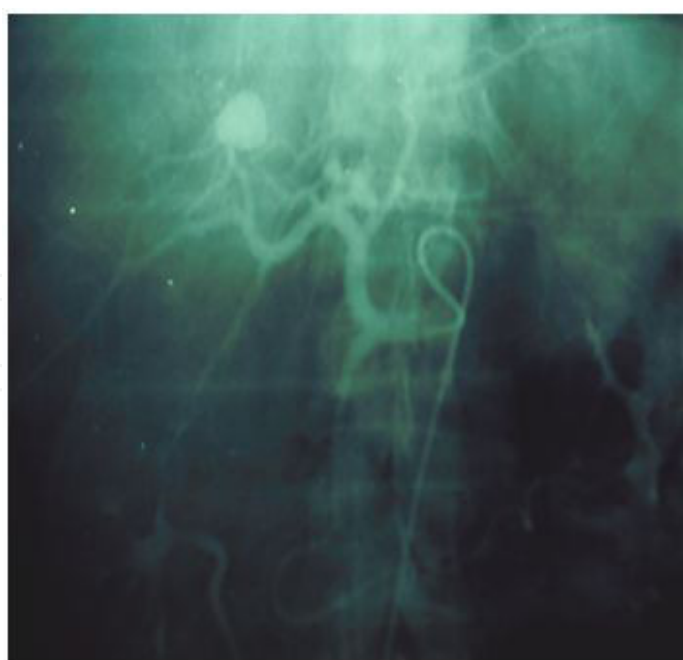
Technological advances in the field of ultrasonography and multi slice scanning (MSCT) easily and accurately allow the diagnosis of aneurysms. Magnetic resonance imaging (MRI) also gives the extraordinary results in the diagnosis of HAA.

Color duplex scan is very important and helpful diagnostic tool in showing intrahepatic lesions. It significantly contributes to the precise detection of the blood flow inside the aneurysmatic sac and allows visualization of the portal system arterialization when the fistula is present. Ultrasound also has their place in monitoring of the previously embolized intrahepatic aneurysms to confirm occlusion of the sac [41].

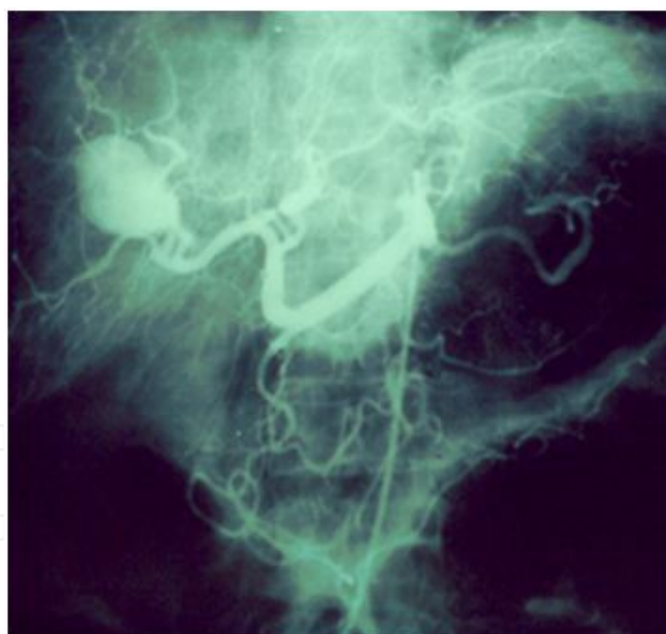
## 1.6. Therapy

Basically, treatments of these lesions today consider selective endovascular embolization of the "feeding" arteries, proximal to the HAA. Different substances are in use successfully, also arterial stents and detachable silicone balloons [40].

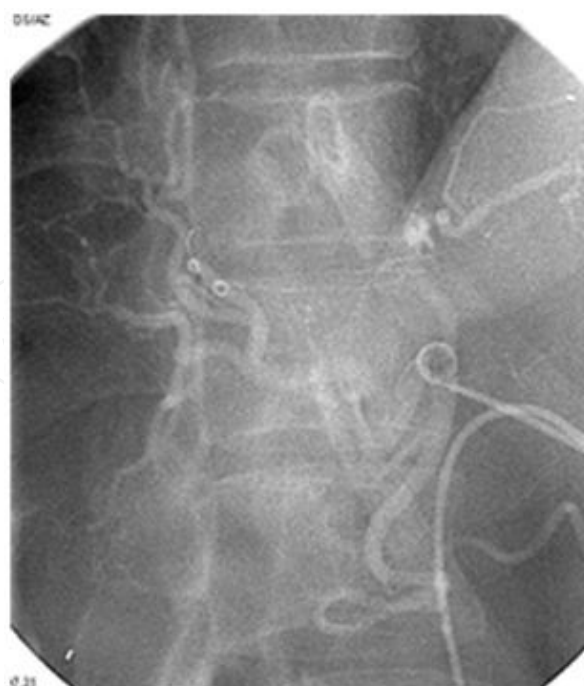
In intact hepatic artery pseudoaneurysm (HAP), occlusion is achieved successfully by percutaneous embolization in 88% -100% cases (figure 8, 10). Good results are recorded with embolization of HAP caused by pancreatitis and ruptured HAP. Repeated embolization is necessary in 30-40% of patients. Rare reports of hepatic necrosis are noted and probably are the result of inadequate catheter placement or embolization, particularly when the portal vena is occluded. Surgical resolution of HAP is solution when endovascular attempt fails, especially for orthostatic liver transplantation (OLT) associated with pseudocysts [39-41].



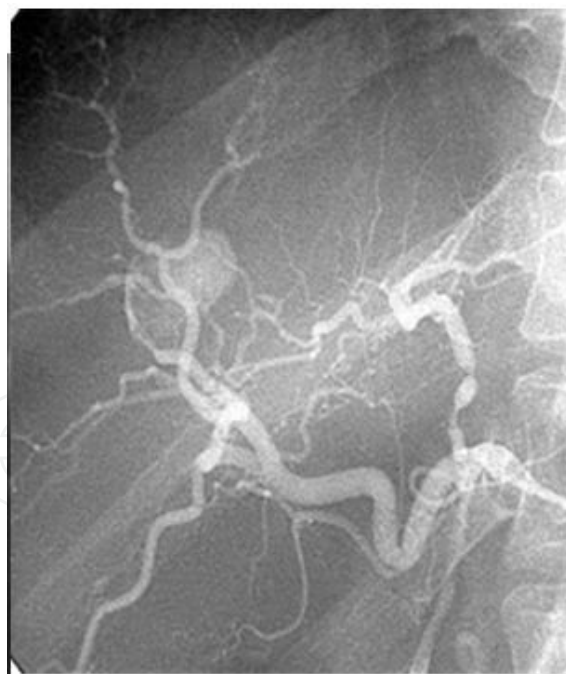
**Figure 6.** Hepatic artery aneurysms- angiography



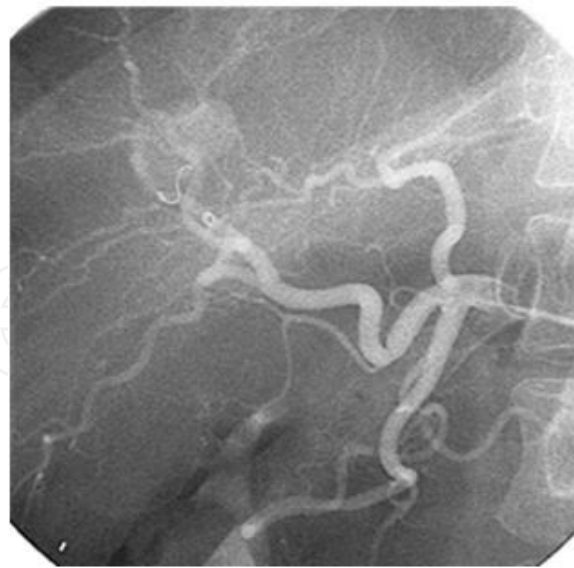
**Figure 7.** Hepatic artery aneurysms- angiography



**Figure 8.** Hepatic artery aneurysms- percutaneous coils embolization



**Figure 9.** Hepatic artery aneurysms- percutaneous coils embolization



**Figure 10.** Hepatic artery aneurysms- percutaneous coils embolization

### 1.7. Celiac artery aneurysm

Aneurysms of celiac trunk represent one of the rarest forms of splanchnic artery aneurysms (3.6% to 4% of all VAA). The incidence of occurrence ranges from 0.005% to 0.01%. Since this anomaly was first described in 1745, fewer than 200 cases were registered in the World Series (Figure 11 - 13) [1 - 3,8, 42].

Although the incidence of rupture was previously 70-85% (first half of the 20th century), advances in diagnosis and early surgical and endovascular intervention significantly reduced the rupture rate on today 7%. Timely diagnosis and proper treatment are crucial for survival, because the operative mortality of ruptured cases fell down from 40% to only 5% [43, 45].

Today 85% of aneurysms were disclosed by angiography, while only 7% by autopsy. There is insignificant frequency in a joint appearance between celiac trunk aneurysm and other peripheral aneurysms. In the first half of last century, the average age of diagnosed patients was 40 years. Men outnumber women nine times, and syphilis (*Treponema pallidum*) was a major cause in 30% of cases. Other recognized causes are arteriosclerosis and medial degeneration. Since that time, the average age of newly diagnosed patients has increased to 55 years and women now comprise almost half of all cases [43, 44, 46].

Existence of the celiac trunk aneurysm by itself is a sufficient indication for surgical reconstruction or endovascular treatment. Simple artery ligation could be final solution sometimes accompanied by the hepatic ischemia.

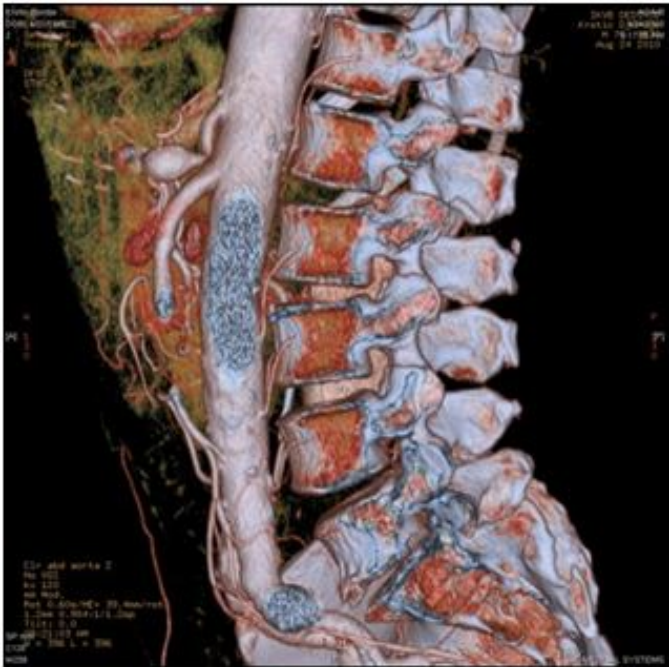

Figure 11. Coeliac artery aneurysms

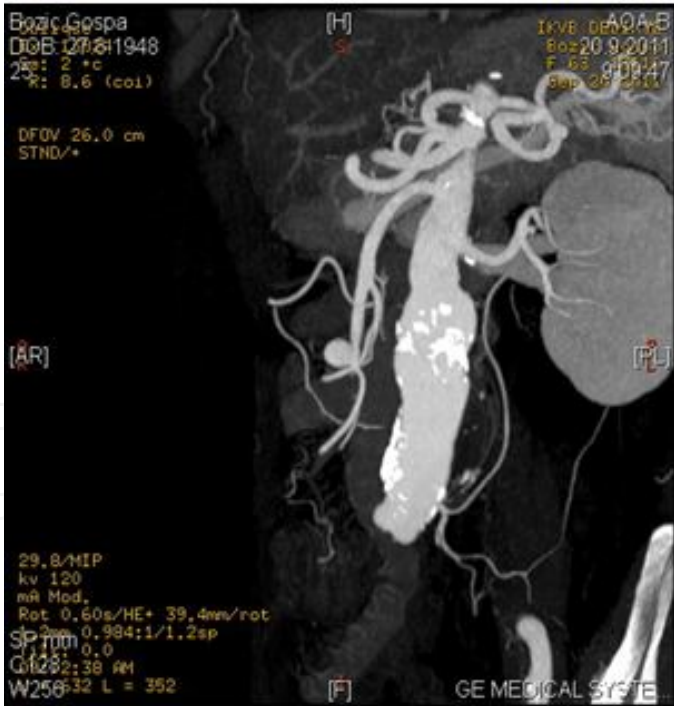
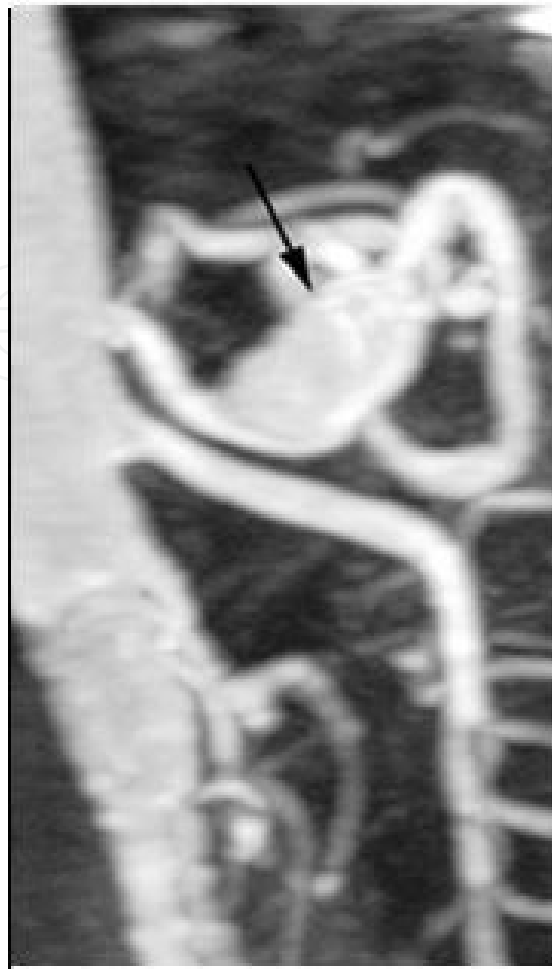
Figure 12. Coeliac artery aneurysms



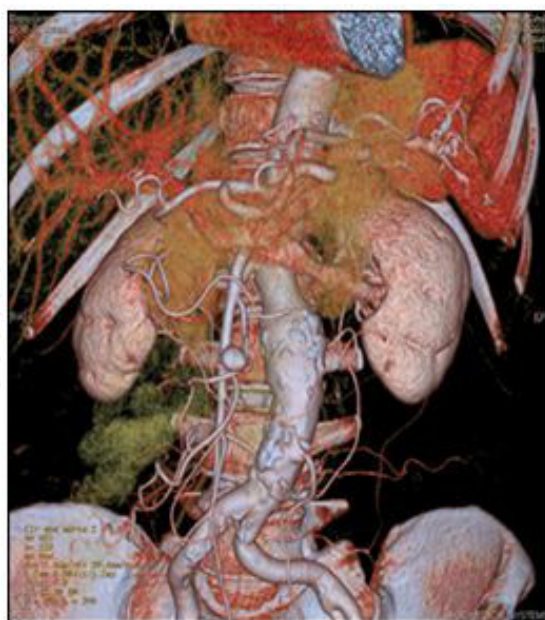

**Figure 13.** Coeliac artery aneurysms

First celiac trunk aneurysm resection was performed in 1958 by Shumacker. Celiac artery occlusion by coil embolization or stent graft implantation are promising way in reating these lesions [5, 45, 46].

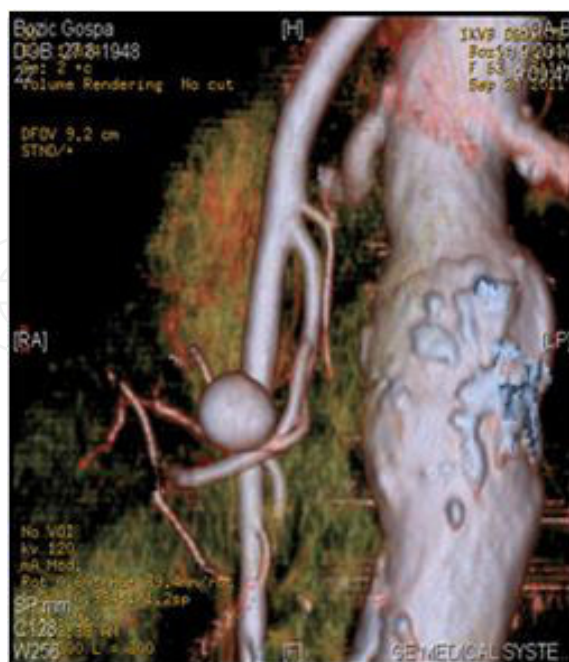## 2. Superior mesenteric artery aneurysms

SMA (figure 14-16) is located on the third most prevalent places among VAA. Until now, sixty percent's of all detected aneurysms are mycotic by etiology [1-3]. It is believed that atherosclerosis is basic cause of the SMA aneurysms occurrence. Other etiological factors are: septic embolus, polyarteritis nodosa, Bechet's syndrome, systemic lupus erithematosus, endocarditis, systemic connective tissue disorders, vasculitis, trauma, cystic medial necrosis, neurofibromatosis and history of intravenous drug abuse. *Stevenson* was made the first surgical attempt to solve the problem. The first successful, surgical treatment of SMA aneurysm was conducted by *DeBakey* and *Cooley* in 1949 [6,47].

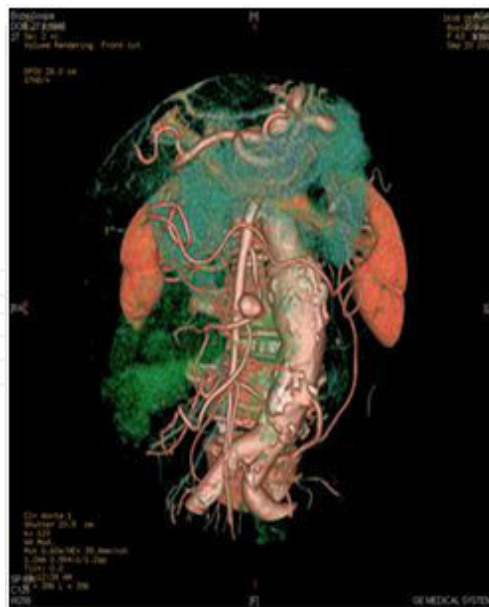

**Figure 14.** Superior mesenteric artery aneurysms- MSCT

Symptoms are generally vague and unclear, accompanied by pain after meals. Diagnostic procedures are the same as for other VAA. Surgical way of dealing with SMA aneurysms has previously been the main way of solving problems. SMA transcatheter embolization of aneurysm sac is particularly suitable for hemodynamically stable patients and more often is the first choice of treatment [48,49].



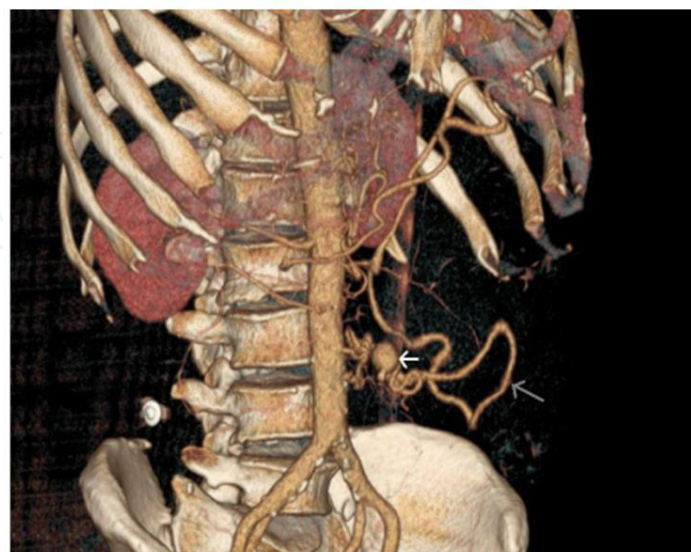
**Figure 15.** Superior mesenteric artery aneurysms- MSCT



**Figure 16.** Superior mesenteric artery aneurysms- MSCT

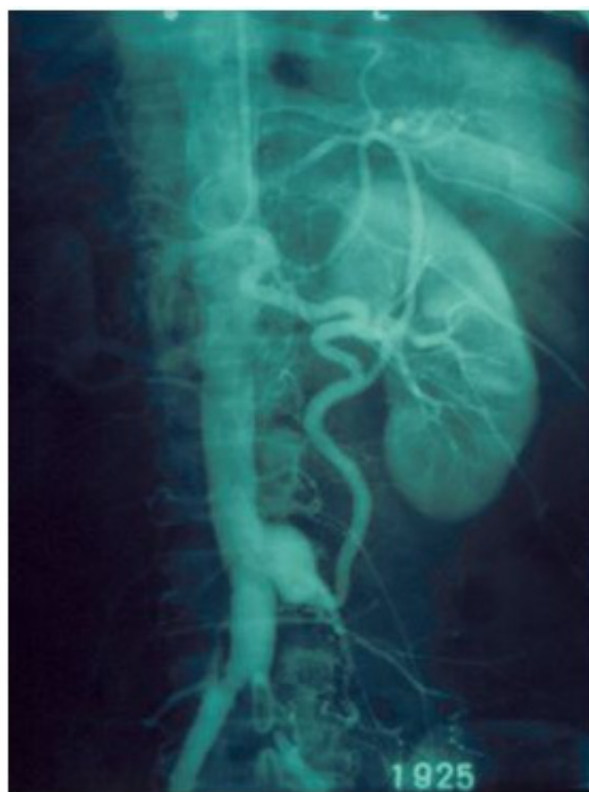
#### *Inferior mesenteric artery aneurysms*

About 1% of total number recorded VAA are aneurysms of the inferior mesenteric artery (IMA)(Figure 17,18). They are usually asymptomatic in nature and the incidence of occurrence is unknown. Basically, the occurrence of atherosclerosis in aneurysms may occur as a secondary consequence of arteritis: Takayasu's arteritis, polyarteritis nodosa, segmental mediolitic arteritis, Behcetov syndromes. Common finding in patients with IMA aneurysms are celiac trunk occlusion and SMA stenosis ("jet disorder" fenomen) [2,3].



**Figure 17.** Inferior mesenteric artery aneurysms

The most common ways of treating these lesions are surgery and in recent years endovascular procedures such as embolization and graft stenting [50,51].

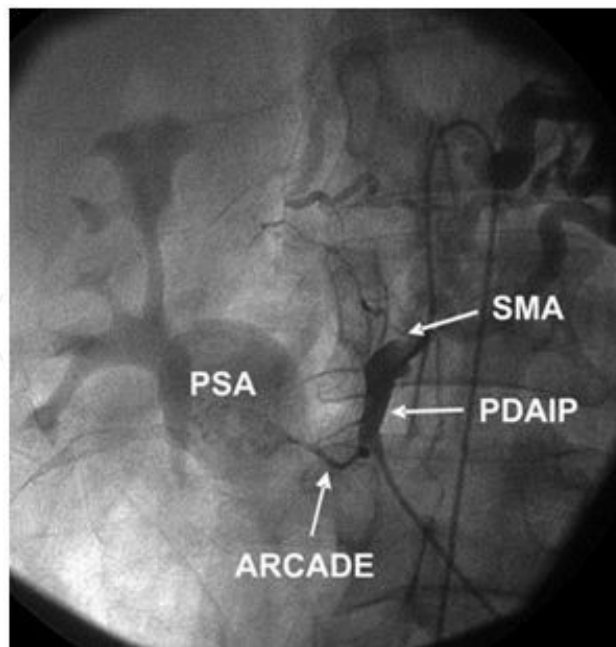


**Figure 18.** Inferior mesenteric artery aneurysms

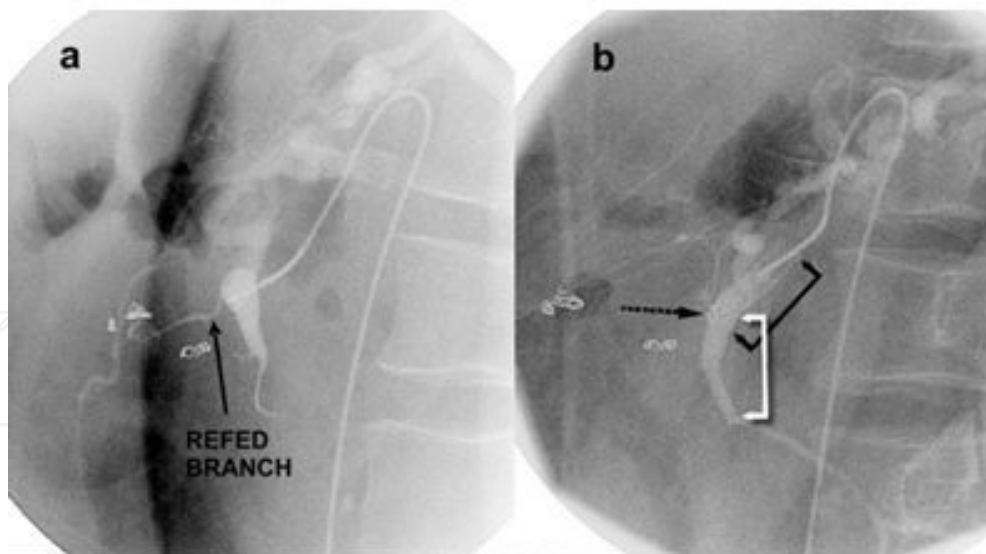
#### *Pancretoduodenal, Gastroduodenal, and less frequent visceral artery aneurysms*

Pancreatico-duodenal artery aneurysm (PDAA) are very rare (less than 2% of all VAA) and usually symptomatic splanchnic aneurysm. Symptoms are abdominal pain, nausea, vomiting, jaundice and sometimes hemorrhage in the digestive system. The different symptoms are probably the result of enlargement and/or rupture of the aneurysm, so it's sometimes difficult to properly characterize and assess the symptoms and diagnose the condition [52,53].

Gastroduodenal artery (GDA) is the least common place has been developing visceral aneurysms (1.5%) Most of GDA aneurysms are pseudoaneurysms, actually a complication of acute or chronic pancreatitis. Other key factors for development of both aneurysms are atherosclerosis, fibromuscular dysplasia, autoimmune disease (systemic lupus erythematosus, Wegener granulomatosis, polyarteritis nodosa), infection and the extreme rare conditions such as congenital absence of celiac trunk [52-55].

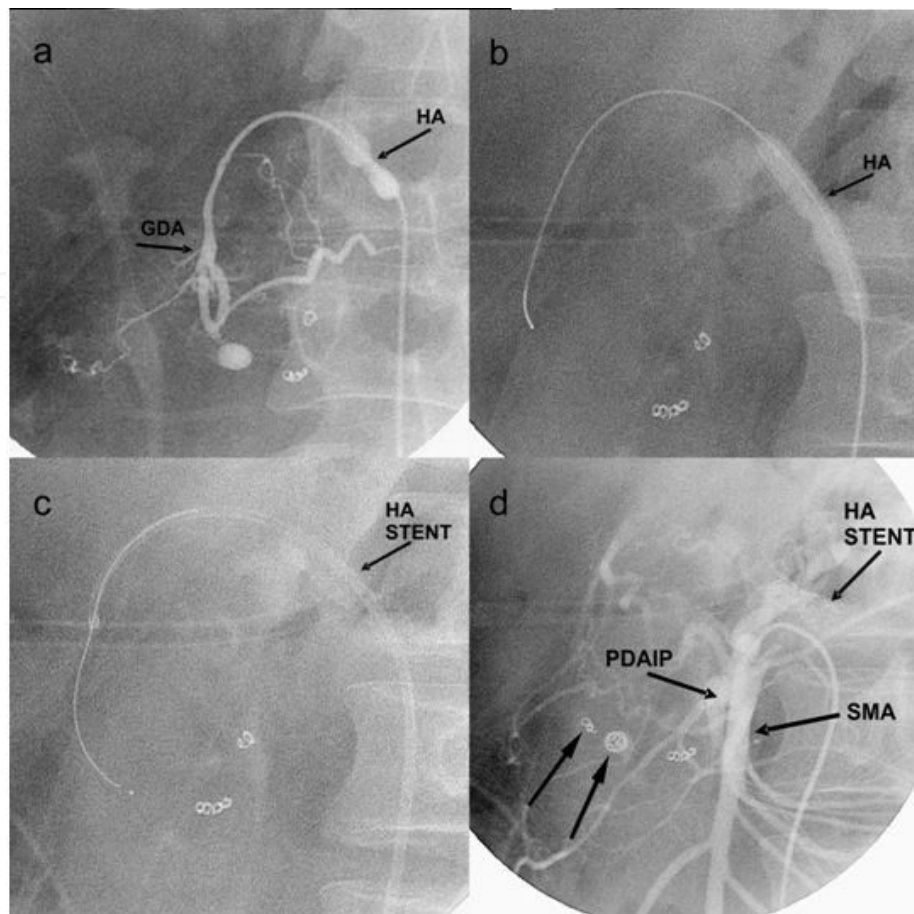


**Figure 19.** Pancreaticoduodenal inferior posterior artery (PDAIP) selective angiography. PSA at the level of the PDAIP and the pancreaticoduodenal superior anterior artery anastomosis. High-grade hepatic artery stenosis relieved by balloon dilatation and placing two stents-Selfx 8.0x32 mm and Wave max Abbot 7.0x28 mm (a,b). Upper aneurysm sack entrance was closed using: Vortx-18 Diamond Shape fiber platinum coils and Vortex Diamond fiber coil 2/4 mm x 4.1 cm.



**Figure 20.** Pancreaticoduodenal inferior posterior artery (PDAIP) selective angiography. PSA at the level of the PDAIP and the pancreaticoduodenal superior anterior artery anastomosis. High-grade hepatic artery stenosis relieved by balloon dilatation and placing two stents-Selfx 8.0x32 mm and Wave max Abbot 7.0x28 mm (a,b). Upper aneurysm sack entrance was closed using: Vortx-18 Diamond Shape fiber platinum coils and Vortex Diamond fiber coil 2/4 mm x 4.1 cm.





**Figure 21.** Pancreaticoduodenal inferior posterior artery (PDAIP) selective angiography. PSA at the level of the PDAIP and the pancreaticoduodenal superior anterior artery anastomosis. High-grade hepatic artery stenosis relieved by balloon dilatation and placing two stents-Selfx 8.0x32 mm and Wave max Abbot 7.0x28 mm (a,b). Upper aneurysm sack entrance was closed using: Vortx-18 Diamond Shape fiber platinum coils and Vortex Diamond fiber coil 2/4 mm x 4.1 cm.

GDA, PDAA and other less frequent visceral aneurysms should be treated regardless of their size and symptomatology. Endovascular techniques have numerous advantages over surgery, such as the precise anatomic localization of the aneurysm, easy access to collateral circulation, the possibility that the procedure be done under local anesthesia, fewer postoperative complications and shorter hospital stay (figure 18-20) [56].

### 3. Conclusion

Splanchnic artery aneurysms are relatively rare, uncommon clinical entities, although their detection in last decades is rising due to an increased use of sophisticated imaging and screening programs for abdominal aortic aneurysms. Potentially most devastating complication is rupture, highly associated with unwanted morbidity and mortality rates; however, the urgent repair of these lesions is still associated with elevated mortality. Elective treatment in chosen patient, should be part of therapeutic strategy. For many years surgical repair and recon-

struction was the gold treatment method. Recently, endovascular coil embolization, *embolotherapy*, and balloon expandable stent-grafts placement has remarkable success rates and represents the first-line treatment for anatomically suitable visceral artery aneurysms and pseudoaneurysm. It is already proved that endovascular treatment associates lower morbidity and mortality rates, lower recurrence and shorter hospital stay than surgical one.

## Author details

Petar Popov<sup>1\*</sup> and Đorđe Radak<sup>2</sup>

\*Address all correspondence to: [popov1960@yahoo.com](mailto:popov1960@yahoo.com)

1 Cardiovascular Institute Dedinje, Vascular department, Belgrade, Serbia

2 Cardiovascular Institute Dedinje, Vascular department Belgrad, Serbia

## References

- [1] Stanley, J. C., Wakefield, T. W., Graham, L. M., Whitehouse Jr, W. M., Zelenock, G. B., & Lindenaure, S. M. (1986). Clinical importance and management of splanchnic artery aneurysms. *J Vasc Surg*, 3, 836-840.
- [2] Carr, S. C., Pearce, W. H., Vogelzang, R. L., Mc Carthy, W. J., Nemcek, A. A., & Jr Yao, J. S. (1996). Current management of visceral artery aneurysms. *Surgery*, 120, 627-33.
- [3] Schanley, C. J., Shah, N. L., & Messina, L. M. (1996). Common splanchnic artery aneurysms: splenic, hepatic, and celiac-review. *Ann Vasc Surg*, 10, 315-22.
- [4] Reidy, J. F., Rowe, P. H., & Ellis, F. G. (1990). Splenic artery aneurysm embolization-the preferred technique to surgery. *Clin Radiol*, 41, 281-2.
- [5] Gabelmann, A., Gorich, J., & Merkle, E. M. (2002). Endovascular treatment of visceral artery aneurysms. *J. Endovasc. Ther*, 9, 38-47.
- [6] De Bakey, M. E., & Cooley, D. A. (1953). Successful resection of mycotic aneurysm of superior mesenteric artery: Case report and review of literature. *Am Surg*, 19, 202-212.
- [7] Sabiston Text Book Of Surgery. 16th Edition; Vascular and visceral artery aneurysm. Section 12,, 2209.
- [8] Carmeci, C., Wisconsin, M., & Mc Clenathan, J. (2000). Visceral artery aneurysms as seen in a community hospital. *Am J Surg*, 179, 486-489.

- [9] Smith, J. A., Macleish, D. G., & Collier, N. A. (1989). Aneurysms of the visceral arteries. *Aust. N. Z. J. Surg*, 59, 329-334.
- [10] Beaussier, M. (1770). Sur un anevrisme de l'artere splinque dont les parnis se sont ossifiees. *Journal Medical Toulouse*, 32, 157.
- [11] Abbas, M. A., Fowl, R. J., Stone, W. M., Panneton, J. M., Oldenburg, W. A., Bower, T. C., Cherry, K. J., & Gloviczki, P. (2003). Hepatic artery aneurysm: factors that predict complications. *J VascSurg*, 38, 41-45.
- [12] Lumsden, A., Samer, G., Mattar, Allen. R. C., & Bacha, E. A. (1996). Hepatic Artery Aneurysms: The Management of 22 Patients. *Jour Surg Res*, 60, 345-350.
- [13] Hulsberg, P., Garza-Jordan, L., Jordan, R., Matusz, P., Tubbs, R. S., & Loukas, M. (2011). Hepatic aneurysm: a review. *Am Surg*, 77(5), 586-91.
- [14] Harlaftis, N. N., & Akin, J. T. (1977). Hemobilia from ruptured hepaticarteryaneurysm: Report of a case and review of the literature. *Am Jour Surg*, 33(2), 229-232.
- [15] Trastek, V. F., Pairolero, P. C., Joyce, J. W., et al. (1982). Splenic artery aneurysms. *Surgery*, 91, 694-699.
- [16] Steinberg, I., & Lord, J. W. (1960). Splenic artery aneurysm. Diagnosis by intravenous abdominal aortography. *JAMA*, 174(1), 74-77.
- [17] New York Times. (1881). How Dr. Bliss Got His Name; Rutkow (2006), James A. Garfield, p.85;Baxter (1891), History of the city of Grand Rapids, Michigan, p. 699; Lamb (1909). *History of the Medical Society of the District of Columbia*, 227, 1817-1909.
- [18] de Vries, J. E., Schattenkerk, M. E., & Malt, R. A. (1982). Complications of the splenic artery aneurysm other than intraperitoneal rupture. *Surgery*, 91, 200-3.
- [19] Sandeep, P., Dave, B., Ernane, R. , Azhar, M. D., Hossain, Peter., Taub, J., Kerstein, M., & Hollier, L. (2000). Splenic Artery Aneurysm in the 1990s. *Ann VascSurg*, 14, 223-229.
- [20] Nishida, O., Moriyasu, F., Nakamura, T., et al. (1986). Hemodynamics of splenic artery aneurysm. *Gastroenterology*, 90, 1042-6.
- [21] Mattar, S. G., & Lumsden, A. B. (1995). The management of splenic artery aneurysms: experience with 23 cases. *Am J Surg*, 169, 580-584.
- [22] Spittel, J. A., Fairbairn, J. F., Kincaid, O. W., & Remine, W. H. (1961). Aneurysm of the splenic artery. *JAMA*, 175, 452-456.
- [23] Stanley, J. C., & Fry, W. J. (1974). Pathogenesis and clinical significance of splenic artery aneurysms. *Surgery*, 76, 898-909.
- [24] Lowry, S. M., O'Dea, T. P., Gallagher, D. I., et al. (1986). Splenic artery aneurysm rupture: the seventh instance of maternal and fetal survival. *ObstetGynecol*, 62, 665-666.

- [25] Ayalon, A., Wiesner, R. H., Perkins, J. D., Tominaga, S., Hayes, D. H., & Krom, R. A. (1988). Splenic artery aneurysms in liver transplant patients. *Transplantation*, 45, 386-9.
- [26] Tazawa, K., Shimoda, M., Nagata, T., et al. (1999). Splenic artery aneurysm associated with systemic lupus erythematosus: report of a case. *Surg Today*, 29, 76-79.
- [27] Agrawa, G. A., Johnson, P. T., & Fishman, E. K. (2007). Splenic artery aneurysms and pseudoaneurysms: Clinical distinctions and CT appearances. *Am J Roentgenol*, 188, 992-9.
- [28] Abbas, M. A., Stone, W. M., Fowl, R. J., et al. (2002). Splenic artery aneurysms: two decades experience at Mayo clinic. *Ann VascSurg*, 16, 442-449.
- [29] Selo-Ojeme, D. O., & Welch, C. C. (2003). Review: spontaneous rupture of splenic artery aneurysm in pregnancy. *EurJ ObstetGynecolReprodBiol*, 109, 124-127.
- [30] Arepally, A., Dagli, M., Hofmann, L. V., Kim, H. S., Cooper, M., & Klein, A. (2002). Treatment of splenic artery aneurysm with use of a stent-graft. *J VascIntervRadiol*, 13, 631-633.
- [31] Guillon, R., Garcier, J. M., Abergel, A., et al. (2003). Management of splenic artery aneurysms and false aneurysms with endovascular treatment in 12 patients. *Cardio-vascInterventRadiol*, 26, 256-260.
- [32] Kreuger, K., Zaehring, M., & Lackner, K. (2005). Percutaneous treatment of a splenic artery pseudoaneurysm by thrombin injection. *J VascIntervRadiol*, 16, 1023-1025.
- [33] Laganà, D., Carrafiello, G., Mangina, M., Dionigib, G., Caronnoc, R., Castelle, P., & Fugazzola, C. (2006). Multimodal approach to endovascular treatment of visceral artery aneurysms and pseudoaneurysms. *Eur Jour Rad*, 59.
- [34] Larson, R. A., Solomon, J., & Carpenter, J. P. (2002). Stent graft repair of visceral artery aneurysms. *J VascSurg*, 36, 1260-1263.
- [35] Salcuni, P. F., Spaggiari, L., Tecchio, T., Benincase, A., & Azzarone, M. (1995). Hepatic artery aneurysm: an ever present danger. *J CardiovascSurg*, 36, 595-9.
- [36] Abbas, M., Fowl, R. J., Stone, W. M., Panneton, J. M., Oldenburg, W. A., Bower, T. C., Cherry, K. J., & Gloviczki, P. (2003). Hepatic artery aneurysm: Factors that predict complications. *J VascSurg*, 38, 41-5.
- [37] Dougherty, M. J., Gloviczki, P., Cherry, K. J., Bower, T. C., Hallett, J. W., & Pairolero, P. C. (1993). Hepatic artery aneurysms: evaluation and current management. *IntAngiol*, 12, 178-84.
- [38] Stouffer, J. T., Weinman, M. D., & Bynum, T. E. (1989). Hemobilia in a patient with multiple artery aneurysms: a case report and review of the literature. *Am. J. Gastroenter.*, 84, 59.

- [39] Venturini, M., Angeli, E., Salvioni, M., De Cobelli, F., Trentin, C., Carlucci, M., et al. (2002). Hemorrhage from a right hepatic artery pseudoaneurysm: endovascular treatment with a coronary stentgraft. *J EndovascTher*, 9, 221-4.
- [40] Schick, C., Ritter, R. G., Jörn, O. B., Thalhammer, A., & Vogl, T. J. (2004). Hepatic artery aneurysm: treatment options. *EurRad*, 14.
- [41] Riesenman, P. J., Bower, T. C., Oderich, G. S., & Bjarnason, H. (2006). Multiple hepatic artery aneurysms: Use of transcatheter embolization for rupture. *Ann VascSurg*, 20(3), 399-404.
- [42] Cavallo, A., Cavallo, L., Orlandi, R., & De Albertis, P. (1991). An aneurysm of the common trunk of the celiac tripod diagnosed with echo-Doppler [in Italian]. *Radiol Med (Torino)*, 82, 694-7.
- [43] Graham, L. M., Stanley, J. C., Whitehouse, W. M., Jr Zelenock, G. B., Wakefield, T. W., Cronenwett, J. L., & Lindenauer, S. M. (1985). Celiac artery aneurysms: historic (1745-1949) versus contemporary (1950-1984) differences in etiology and clinical importance. *J VascSurg*, 2, 757-64.
- [44] Risher, W. H., Hollier, L. H., Bolton, J. S., & Ochsner, J. L. (1991). Celiac artery aneurysm. *Ann VascSurg*, 5, 392-5.
- [45] Rengo, M., Terrinoni, V., Lamazza, A., Cosimati, A., & Bianchi, G. (1997). Treatment of an aneurysm of the coeliac axis, by transluminal steel wire occlusion. *Eur J VascEndovascSurg*, 13, 88-90.
- [46] Sessa, C., Tinelli, G., Porcu, P., Aubert, A., Thony, F., & Magne, J. (2004). Treatment of visceral artery aneurysms: Description of a retrospective series of 42 Aneurysms in 34 patients. *Ann VascSurg*, 18(6), 695-703.
- [47] Stevenson, W. F. (1895). Case of abdominal aneurysm treated by laparotomy and introduction of wire into sac with death. *Lancet*, 1, 22-3.
- [48] Komori, K., Mori, E., & Yamaoka, T. (2000). Successful resection of superior mesenteric artery aneurysm. A case report and review of the literature. *J CardiovascSurg (Torino)*, 41, 475-478.
- [49] Perhnan, M., & Golinger, D. (1967). Mycotic aneurysm of the superior mesenteric artery treated by ligation with survival. *Br J Surg*, 54, 735-8.
- [50] Pérez-Vallecillos, P., Muíño, R. C. I., Seura-Jiménez, Fernández. N. M., Ferrón, J. A., García-Róspide, V., & Palma, P. (2010). Acute retroperitoneal bleeding due to inferior mesenteric artery aneurysm: Case report. *BMC Gastroenterology*, 10, 59.
- [51] Davidovic, L. B., Vasic, D. M., & Colic, M. I. (2003). Inferior mesenteric artery aneurysm: case report and review of the literature. *Asian J Surg*, 26, 176-9.
- [52] Neschis, D. G., Safford, S. D., & Golden, M. A. (1998). Management of pancreaticoduodenal artery aneurysms presenting as catastrophic intra-abdominal bleeding. *Surgery*, 123, 8-12.



- [53] Chiesa, R., Astore, D., Guzzo, G., Frigerio, S., Tshomba, Y., Castellano, R., de Moura, M. R., & Melissano, G. (2005). Visceral artery aneurysms. *Ann Vasc Surg*, 19(1), 42-48.
- [54] Spanos, P. K., Kloppedal, E. A., & Murray, C. A. (1974). Aneurysms of the gastroduodenal and pancreaticoduodenal arteries. *Am Jour Surg*, 127(3), 345-348.
- [55] Popov, P., Sagic, D., Radovanovic, D., Antonic, Z., Nenezic, D., & Radak, Dj. (2008). Pancreaticoduodenal artery pseudoaneurysm embolization. *Vascular*, 16.
- [56] Popov, P., Boskovic, S., Sagic, D., Radevic, B., Iljevski, N., Nenezic, D., Tasic, N., Davidovic, L., & Radak, D. (2007). Treatment of visceral artery aneurysms : Retrospective study of 35 cases. *VASA*, 36.

