

We are IntechOpen, the world's leading publisher of Open Access books Built by scientists, for scientists

6,900

Open access books available

185,000

International authors and editors

200M

Downloads

Our authors are among the

154

Countries delivered to

TOP 1%

most cited scientists

12.2%

Contributors from top 500 universities



WEB OF SCIENCE™

Selection of our books indexed in the Book Citation Index
in Web of Science™ Core Collection (BKCI)

Interested in publishing with us?
Contact book.department@intechopen.com

Numbers displayed above are based on latest data collected.
For more information visit www.intechopen.com



Nonalcoholic Fatty Liver Disease: A Pathological View

Joaquín Cabezas, Marta Mayorga and Javier Crespo

Additional information is available at the end of the chapter

<http://dx.doi.org/10.5772/52622>

1. Introduction

Nonalcoholic fatty liver disease (NAFLD) is the most common liver disorder of our times. The spectrum of this disease goes from steatosis to non-alcoholic steatohepatitis (NASH), cirrhosis and hepatocellular carcinoma. NAFLD can appear in the context of many conditions. Probably, NAFLD could be a component of metabolic syndrome, with its complete phenotypic expression: insulin resistance, obesity, type 2 diabetes, hypertension, hypercholesterolemia, and hypertriglyceridemia.

The pathogenesis involves insulin resistance, hepatic fat deposition, increased oxidant stress, apoptosis, inflammation and fibrosis. At present day, a new hormone has been discovered. Muscle cells products this new hormone, called irisin. Irisin can induce changes in adipose tissue.

Diagnosis of NAFLD cannot be performed with a single test and it should be one of exclusion, as well.

Nowadays, there is not a single therapeutic intervention. The focus of management should be treatment of the risk factors for NASH (insulin resistance, obesity...). Principal methods used for weight management are dietary modifications and life style changes. Then, pharmacotherapy may include insulin sensitizers, cholesterol-lowering agents, anti-obesity and anti-oxidant agents. Morbid obese patients may benefit from surgical weight loss, reducing the progression of NASH.

2. Definition

NAFLD definition [1] requires that there is evidence of hepatic steatosis, either by imaging or by histology and there are no causes for secondary hepatic fat accumulation (Table 1).

NAFLD is usually associated with metabolic risk factors such as metabolic syndrome, obesity, diabetes mellitus, and dyslipidaemia.

| COMMON CAUSES OF SECONDARY HEPATIC STEATOSIS |
|---|
| Macrovesicularsteatosis |
| Excessive alcohol consumption. Hepatitis C (genotype 3) Wilson’s disease. Lipodistrophy Starvation Parenteral nutrition. Abetalipoproteinemia. Medication (amiodarone, methotrexate, tamoxifen, corticosteroids) |
| Microvesicularstatis |
| Reye’s syndrome. Medications (valproate, anti-retroviral medicines) Acutte fatty liver of pregnancy HELLP syndrome Inborn errors of metabolism (LCAT deficiency, cholesterol ester storage disease, Wolman disease) |

Table 1. Causes of secondary fat accumulation.

NAFLD includes a constellation of histological findings that goes from steatosis, to necroinflammation, called NASH and progression to advanced fibrosis and cirrhosis.

3. Epidemiology

NAFLD is becoming the leading cause of liver disease. One of the causes is the increasing of obesity[2].

The incidence of NAFLD has been evaluated in a few number of studies, it ranges from 31-86 cases/1000 person-year in Japan to 29 cases per 100000 person-year in England [3, 4].

The prevalence of NAFLD is increasing. Recent studies presented in the Digestive Diseases Week 2012 summarizes this increased prevalence over the last 20 years [5, 6]. Investigators report an increasing in obesity. This increase is followed by a rising in steatosis and NASH, the presence of steatosis among obese people has increased from 23% in the 80s, 43% in the

90s and finally to 60% nowadays [4]. Even in non-obese patients, the prevalence of steatosis increased from 12%, to 27% and 36%, respectively [5].

In children/adolescents, over the last 20 years, obesity has increased from 11% to 21%, suspected NAFLD from 4% to 10, and the prevalence of altered aminotransferases among obese adolescents has increased from 17% to 37% [6].

4. NAFLD and liver biopsy

Liver biopsy remains the gold standard for characterizing liver histology in patients with NAFLD. However, it is expensive and carries some morbidity and very rare mortality risk. Thus, it should be performed in those who would benefit the most from diagnostic, therapeutic guidance, and prognostic perspectives.

The last guideline for NAFLD management recommends liver biopsy [1]: in patients who are at risk to have steatohepatitis and advance fibrosis; these patients could be identified by the presence of metabolic syndrome and NAFLD fibrosis score; and a liver biopsy should be considered in patients in whom other etiologies are suspected and cannot be excluded without a liver biopsy.

Liver biopsy allows confirming the diagnosis, evaluation and semiquantitation of necroinflammatory lesions and fibrosis.

On the other hand, liver biopsy suffers from challenges. An adequate biopsy represents only 1/50000-1/65000 of the organ. Sampled area should be carefully chosen and sample length must be enough, at least 15mm. This size can reduce sample error. Finally, experienced pathologist is important to have a greater yield of findings.

5. Histology of NAFLD

NAFLD represents a histopathologic spectrum ranging from steatosis alone, to necroinflammation, summarized as NASH; and progression to advanced fibrosis and cirrhosis.

The histologic characterization of NAFLD and NASH may include description of steatosis and cell injury in addition to inflammation and fibrosis. Kleiner and Brunt [7] propose categorizing the histologic changes when studying NAFLD as follows in table 2.

The main histological characteristic of NAFLD is the accumulation of fat in the form of triglycerides within hepatocytes, lesion termed steatosis (Figure 1 and 2); this term is defined by the guideline [1] as NAFL – non-alcoholic fatty liver, where the risk of progression to cirrhosis and liver failure is minimal. The presence of >5% steatotic hepatocytes in a liver biopsy is accepted as the minimum criterion for the histological diagnosis of NAFLD [8].

| CATEGORY | DEFINITION |
|---|--|
| No significant evidence of fatty liver disease. | Insufficientsteatosis for diagnosis of steatosis, without other changes (ballooning, fibrosis) that would suggest steatohepatitis. |
| Steatosis: Steatosis with inflammation. Steatosis with nonspecific fibrosis | Steatosis without specific changes to suggest a form of steatohepatitis. This category may include spotty lobular inflammation and/or mild degrees of fibrosis of uncertain significance. |
| Steatohepatitis: - zone 3 borderline steatohepatitis | Form of steatoshepatitis most common in adults; defined as a zone 3 centered injury pattern that includes steatosis, inflammation, ballooning injury, (often with Mallory-Denk bodies) with or without fibrosis. Borderline steatohepatitsis has some, but not all ofthe features that would allow a diagnosis of steatohepatitis. |
| Zone 1, borderline pattern | Form of steatohepatitis that occurs mainly in young children, characterized by zone 1-centered (portal inflammation, portal-based fibrosis, zone 1 steatosis, ballooning injury in zone 1 if present). |
| Cryptogenetic fibrosis/ cirrhosis | Presence of fibrosis (usually advanced) or cirrhosis, with little ton o steatosis and no changes (ballooning, Mallory-Denk bodies) that would suggest borderline or definite steatohepatitis. Other explanations for fibrosis (besides steatohepatitis) should be considered. |

Table 2. Histologic Categorization of NAFLD [7].

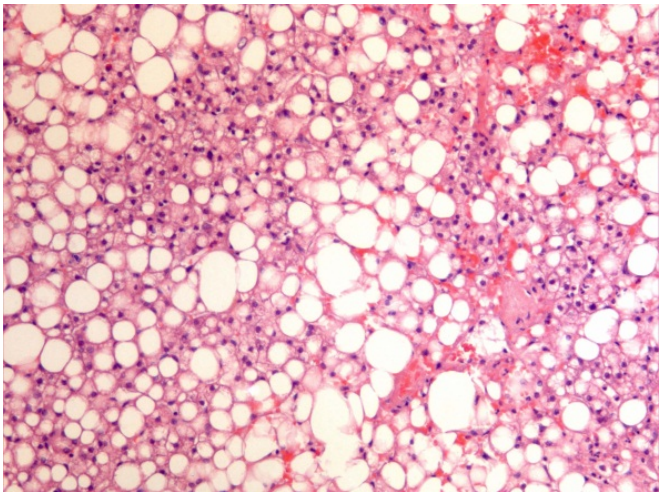


Figure 1. Steatosis. Hematoxylin-eosin stain.

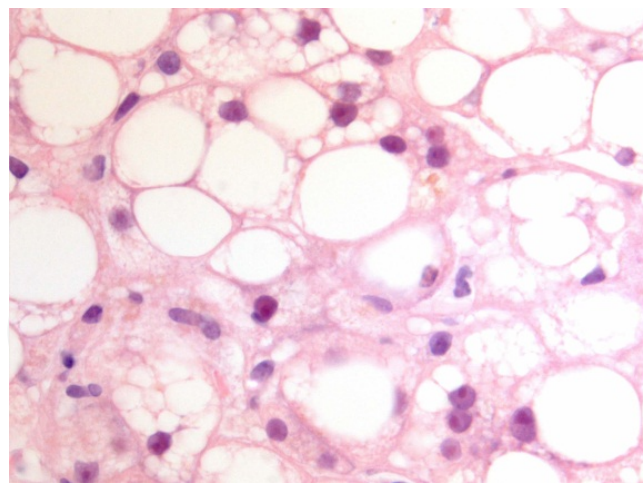


Figure 2. Steatosis. Hematoxylin-eosin stain.

Steatosis in NAFLD is usually macrovesicular, which refers to hepatocytes with single large intracytoplasmatic fat droplet or smaller well defined droplets displacing the nucleus to the cell periphery. This macrovesicularsteatosis is usually present in a zone 3 or panacinar distribution; it differs from zone 1 steatosis that is a common distribution in chronic hepatitis C. Azonal steatosis is most often seen in biopsies with advanced fibrosis [9].

The extent of steatosis can be evaluated and classified semi-quantitative. The most reproducible method follows the acinararchitecture dividing the liver parenchyma in thirds and assessing percentage involvement bay steatoic hepatocytes [8] – table 3.

| STEATOSIS SEMI-QUANTIFICATION | |
|-------------------------------|----------|
| Mild | 0 – 33% |
| Moderate | 33 – 66% |
| Severe | > 66%. |

Table 3. Steatosis semi-quantification according to acinar architecture [8].

NASH, under this concept is the histology pattern of NAFLD, which is at risk of developing advance fibrosis. The minimal criteria for the histopathological diagnosis of adult NASH include steatosis, hepatocyte injury, usually in form of ballooning, and lobular inflammation, typically localized in acinar zone 3 [10, 11].

The key feature for the diagnosis of NASH is the ballooning injury (Figures 3 and 4), and it is considered a marker of apoptosis [12]. This type of cell injury is characterized by a cell that becomes enlarged and the cytoplasm becomes irregularly clumped with optically clear, nonvesiculated areas. Ballooned cells are seen most frequently in zone 3 near the hepatic veins, and lose this localization, becoming portal inflammation more prominent when the disease progresses and in severe cases. Immunostaining of hepatocyte keratins 8 and 18

might help to identify ballooned hepatocytes [13]. Ballooned degeneration is difficult to diagnose even by trained pathologist, for that reason it can show significant inter-observer variation [14].

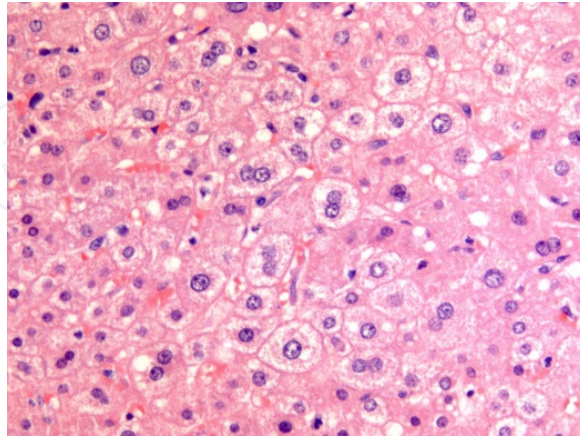


Figure 3. Hepatocyte ballooned. Hematoxylin-eosin stain.

Ballooning degeneration is associated with an increased liver-related mortality [15].

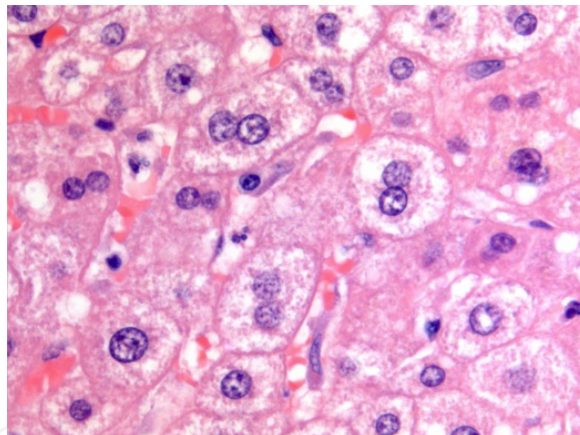


Figure 4. Ballooning hepatocyte. Hematoxylin-eosin stain.

Mallory-Denk Bodies (MDB), also known as Mallory bodies, are eosinophilic, ropey cytoplasmatic inclusion bodies in the hepatocyte of patients with chronic liver disease. This type of lesion contains abnormal cytokeratin 8 and 18 filaments that have been ubiquitinated.

Mallory bodies have an importance in disease progression and it is suggested a possible prognostic role in steatohepatitis [16]. In a recent study, the presence of MBD was significantly associated with liver-related mortality [15].

Both ballooning degeneration and MDB can trigger the development of apoptosis. Apoptotic (acidophil) bodies are common in NASH. They can be identified as rounded, eosinophilic cytoplasmic fragments, which appear to be free within the sinusoids or surrounded by

Kupffer or other inflammatory cells. Apoptosis has been validated as an accurate marker for diagnosis of NASH based on immunochemistry in liver tissue [17].

Inflammatory infiltrates (Figure 5) can be seen in the hepatic acini/lobules or the portal tract. Lobular inflammation is usually mild, consists of a mixed inflammatory cell infiltrate, composed of lymphocytes, some eosinophils, and a few neutrophils. Polymorphs can be observed around ballooned hepatocytes that are called “satellitosis” (Figure 6). Kupffer cells aggregates as lobular microgranulomas and lipogranulomas may appear [10]

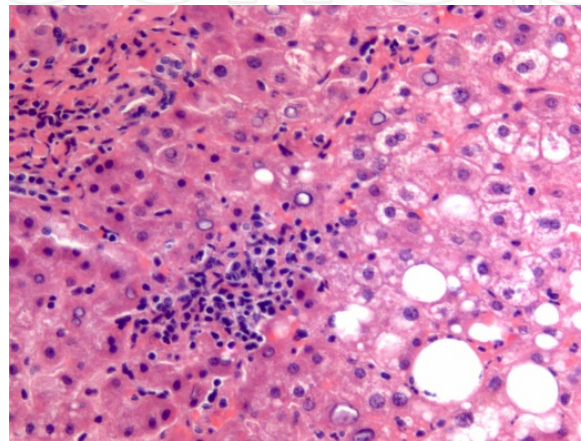


Figure 5. Mononuclear inflammatory infiltration. Hematoxylin-eosin stain.

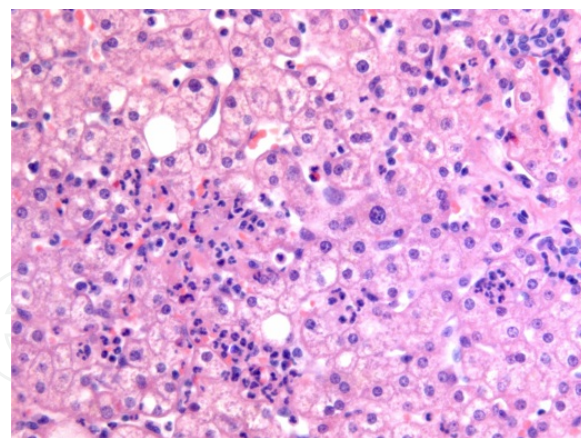


Figure 6. Polymorph around ballooned hepatocytes, “satellitosis”.

Hematoxylin-eosin stain. Portal chronic mononuclear cell inflammation in adult NASH is common and mild. When portal inflammation is greater than lobular other aetiologies should be ruled out, such as chronic hepatitis C [18]. On the other side, a greater portal inflammation than lobular inflammation can be seen in successfully treated patients [19]. In a large database of liver biopsies from the NASH Clinical Research Network, including adults

and children, portal chronic inflammation was associated with clinical and histologic features of severity and advance disease [20].

Vascular alterations in NAFLD. Recent paper has focused the study of NASH in microvessels of the liver [21]. This work has found an intraacinar branch of the hepatic artery in the perivenular region in active steatohepatitis. This finding is important because it can lead to confusion for a portal tract resulting in an equivocal diagnosis. Likewise, the presence of this vessel correlates with higher stage of fibrosis.

Fibrosis in adult NASH usually starts in acinar zone 3 and has characteristic “chicken wire” pattern due to deposition of collagen and other extracellular matrix fibres along the sinusoids of zone 3 and around the hepatocytes (Figure 7 and 8). Portal fibrosis has been reported in cases of morbid obesity-related NASH and in pediatric NASH. Fibrosis predicts clinical outcomes in NASH [22]. There was note from this study that the progression of the fibrosis is accompanied of steatosis reduction. Approximately 37% to 41% of patients with NAFLD have fibrosis progression over 3 to 10 years [22, 23]. The higher rates of fibrosis progression were related to: body mass index, diabetes and low initial fibrosis [22]. When periportal fibrosis was not present, there was a 100% of negative predictive value in predicting liver-related outcomes [23]. Steatosis, inflammation, ballooning and Mallory hyaline were not associated with liver-related mortality after adjusting for the presence of fibrosis [15]. The inclusion of fibrosis explains why the recent classifications for NASH used by Younossi [15] and Matteoni [16], independently correlated with liver-related mortality. This observation shows the importance of fibrosis in NAFLD, patients with NASH and fibrosis portends a higher risk of death [24].

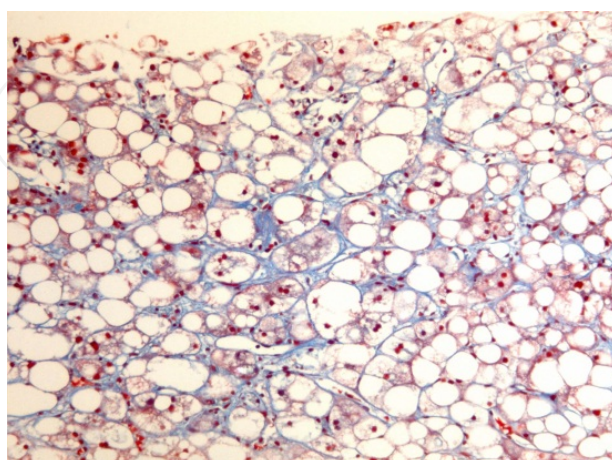


Figure 7. Fibrosis pattern: around hepatocytes. Masson trichrome stain.

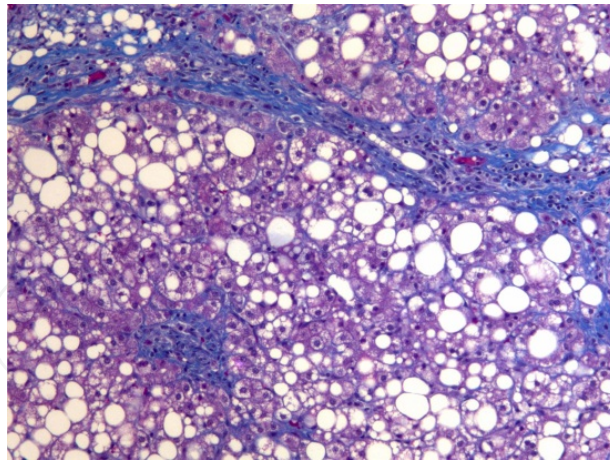


Figure 8. Zone 3 fibrosis perivenular/pericellular. Masson trichrome stain.

Other histological lesions that may be seen in NASH include megamitochondria, glycogenated nuclei and iron deposition.

Megamitochondria (giant mitochondria) are round or needle-shaped, eosinophilic, intracytoplasmatic inclusions more commonly observed in hepatocytes with microvesicular steatosis. This abnormal mitochondria is a result of injury from lipid peroxidation or represent an adaptive change [25]. Glycogenated nuclei are vacuolated nuclei usually observed in periportal hepatocytes. Their presence is more frequent in non-alcoholic etiology and it is rare in alcoholic injury [26].

Finally, hepatic siderosis might be seen in NAFLD. One study of 293 liver biopsies (34,5% of patients with NAFLD) investigates the relationship between iron deposition and NAFLD [27]. Stainable hepatic iron described three histological patterns: hepatocellular pattern, reticuloendothelial system cell – RES - (mainly Kupffer cell) pattern and mixed. RES pattern was associated with advanced fibrosis and higher histological features of portal inflammation, ballooning and definite NASH [27].

6. Histologic scoring systems

NAFLD histologic criteria requires an accumulation of more than 5% of fat deposition, mainly in form of triglycerides. NAFLD was first described by Ludwig and colleagues [28], and since then several systems for grading and staging NAFLD have been proposed.

In 1999, Matteoni and colleagues characterized histologic subtypes that correlate with clinical outcomes [16] – table 4. In 2005, NASH Clinical Research Network developed NAFLD activity score (NAS) [8]. This score comprises four features evaluated semi-quantitatively: steatosis, lobular inflammation, hepatocellular ballooning and fibrosis. Fibrosis was classified separately – table 5. When NAS is >5 sensitivity and specificity for definite NASH were 0,75 and 0,83, respectively. Finally, a recent classification for NAFLD has been proposed by

Younossi and colleagues [15]. This classification includes the evaluation of these histologic features: steatosis with centrilobular ballooning, and/or Mallory-Denk bodies of fibrosis – see table 6.

| CLASSIFICATION OF NONALCOHOLIC LIVER FATTY LIVER DISEASE (NAFLD) BY SUBTYPE | | |
|---|---|-------------------------------|
| NAFLD subtype | Pathology | Clinicopathologic correlation |
| Type 1 | Simple steatosis alone | No NASH |
| Type 2 | Statisis + lobular inflammation only | No NASH |
| Type 3 | Steatosis + hepatocellular ballooning | NASH without fibrosis |
| Type 4 | Steatosis, ballooning, Mallory bodies or fibrosis | NASH with fibrosis |

Table 4. Classification of NAFLD by subtype [16].

| CLASSIFICATION OF NONALCOHLIC FATTY LIVER DISEASE BY NAFLD CLINICAL RESEASCH NETWORK | |
|--|-------|
| Histologic finding | Score |
| Steatosis | 0-3 |
| Lobular inflammation | 0-3 |
| Hepatocellular ballooning | 0-2 |
| NASH requires a score of ≥ 4 with at least 1 point o ballooning injury. | |
| Fibrosis type | Score |
| None | 0 |
| Perisinusoidal zone 3 | |
| Mild | 1A |
| Moderate | 1B |
| Portal/periportal | 1C |
| Persinusoidal and portal/periportal | 2 |
| Bridging | 3 |
| Cirrhosis | 4 |

Table 5. Classification of NAFLD by NAFLD CRN [8].

CLASSIFICATION OF NAFLD BY SUBTYPE

| Pathology | Clinicopathologic correlation |
|---|-------------------------------|
| Simple steatosis alone | No NASH |
| Steatosis + lobular inflammation only | No NASH |
| Steatosis with centrilobular ballooning and/or Mallory-Denk bodies | NASH |
| Any steatosis with centrilobular/pericellular/perisinusoidal or bridging fibrosis | NASH |

Table 6. Classification of NAFLD proposed by Younossi and colleagues [15].

The most important difference between NAS and subtype classifications is that the latter include fibrosis and this provides a better prediction of liver-related mortality in patients with NAFLD [15].

7. NAFLD in special populations

Patients with insulin resistance. Insulin resistance can be estimated using the homeostasis model for assessing of insulin resistance (HOMA-IR), calculated as the product of fasting insulin level (mUI/ml) and plasma glucose level (mmol/ml), divided by 22,5 [29]. Portal fibrosis has been linked to the ductular reaction (ductular proliferation at the portal tract interface arising from progenitor cells in the periportal area and accompanied by neutrophils and stromal changes). These findings correlate the insulin resistance with advanced stages of fibrosis and provide a pathway for fibrosis progression [30].

In some cases in a study with a few number of patients treated with an insulin sensitizer, histologic evaluation of post-treatment liver biopsy showed that increased portal inflammation is a feature related to resolution of NASH, and it is associated to a change in the quality of zone 3 perisinusoidal fibrosis from dense to delicate [19].

NAFLD in bariatric surgery patients. Patients undergoing bariatric surgery for weight loss are at a risk of NAFLD. They often have comorbidities such as: severe obesity, diabetes, hypertension, sleep apnea or coronary artery disease. And high percentage will have metabolic syndrome [31] (see table 7). The prevalence of steatosis and steatohepatitis in these patients undergoing liver biopsy when surgery is performed, is 91% and 37%, respectively [32]. At least a third of morbidly obese patients have portal inflammation, and this is related to the presence of fibrosis [20, 33]. In early stage, localization of fibrosis differs from those nonbariatric populations, in bariatric is portal and in nonbariatric is perisinusoidal [19].

| |
|---|
| The Adult Treatment Panel III clinical definition of the metabolic syndrome: |
| - Requires the presence of three or more of the following features: |
| Waist circumference greater than 102 cm in men or greater than 88 cm in women. |
| Triglyceride level 150mg/dl or greater. |
| High-density lipoprotein (HDL) cholesterol level less than 40 mg/dl in men and less than 50 mg/dl in women. |
| Systolic blood pressure 130 mmHg or greater or diastolic pressure 85 mmHg or greater. |
| Fasting plasma glucose level 110 mg/dl or greater. |

Table 7. Definition of the metabolic syndrome [31].

NAFLD after bariatric surgery. Improvements of major histological features of disease activity, grade of steatohepatitis and rarely fibrosis following therapy (dietary, medicines or surgery) have been reported [34]. After surgical intervention liver histology improve in these features: lobular steatosis, necroinflammatory changes and fibrosis, against no improve in portal abnormalities [35]. Recent meta-analysis [36] shows that patients after bariatric surgery have improvement or resolution in steatosis (91,6%), in steatohepatitis (81,3%), in fibrosis (65,5%) and for complete resolution of NASH was 69,5%.

In the near future, we will have to get used to new types of treatment, for example, “metabolic surgery”, which might be performed to non-morbid obese patients with diabetes, and to the new changes in hepatic parenchyma following endoscopic procedures performed to treat obesity.

NAFLD in children. Pediatric NAFLD can have a different histologic presentation than adult NAFLD. In the first large biopsy series of pediatric NAFLD [37], two different histologic patterns were described with differences in race and gender. Type 1 NASH: similar to adults, more common in Caucasian children. Histologic characteristics are: steatosis, ballooning degeneration and perisinusoidal fibrosis. On the other hand, Type 2 NASH was more common in Asian, Native American and Hispanics. Typical features in the liver biopsy are: steatosis with lymphocytic portal inflammation and portal fibrosis. Children with type 2 were younger and had a greater severity of obesity, and advanced fibrosis. This kind of pattern was described in adult morbid obese patients undergoing bariatric surgery, these patients mean age were slightly lower [33]. Overlap cases with characteristic of both histological types may also be observed in pediatric NASH. A multicentre retrospective cohort study reviewed 130 liver biopsies of children according to these criteria of pediatric NAFLD [38]. The majority of the biopsies presented an overlapping pattern (82%). Advanced fibrosis was associated with the presence of lobular and portal inflammation.

Portal fibrosis is common in pediatric NAFLD and may evolve to periportal fibrosis and bridging fibrosis in some patients, whereas progression to cirrhosis is observed in rare cases [39].

It is not clear, that Type 2 NASH, described as pediatric NASH, is an entity by itself or it is another stage of the spectrum of NASH which could be a predictor of those who have a severe disease [40].

8. Imaging tecnology in NAFLD

Ultrasonography (US), computed tomography (CT), and magnetic resonance (MR) can identify liver steatosis but not steatohepatitis, nevertheless they provide anatomical and morphological information. The sensitivity of these imaging methods is optimal for steatosis over 33%. When advance liver disease, radiology techniques can provide indirect signs of cirrhosis, such as portal hypertension, or may be useful for the screening and diagnosis of hepatocellular carcinoma (HCC)[41]. Imaging technique may help to differentiate diffuse from focal form of steatosis. Hepatic fatty infiltration can present as focal steatosis (a focal area of steatosis in an otherwise normal liver) or as focal fatty sparing (fatty change with sparing of certain areas) [42].

Abdominal US is the most commonly used imaging technique to clinically evaluate the presence of liver steatosis. Advantages include low cost, lack of radiation exposure and wide availability. The brightness of the liver echo is compared with the kidney, the attenuation of the sound beam by the fat results in relatively hypoechoic kidney. For detailed description of sonographic features for staging fatty liver see table 8. This US feature is not characteristic of NAFLD because it can be present in other diffuse parenchymal liver disease. The US can be accurate detecting hepatic steatosis when there is a moderate to severe infiltration [43]. Overall sensitivity and specificity are 60-94% and 66-95%, respectively, however the sensitivity is lower when BMI (body mass index) is over 35 Kg/m². Although this acceptable level of sensitivity it does not provide reproducible quantitative information. US scoring system for fatty liver is based on hyper-echogenic liver tissue, the increased discrepancy of echo amplitude between liver and kidney and the loss of echoes from the walls of the portal system [44]. US cannot differentiate between steatosis and fibrosis, but with advance degrees of fibrosis an increase in coarse echoes without posterior beam attenuation can be seen.

| Features | NORMAL | MILD | MODERATE | SEVERE |
|---|---|---|--------------|--|
| Liver echotexture | Liver parenchyma is homogeneous and no difference in contrast between liver and kidney | Slight increase in echo pattern | Intermediate | Gross discrepancy of the increased hepatic to renal cortical echogenicity |
| Echo penetration an visibility of diaphragm | Liver structure is clearly defined from the surface to diaphragm. The outline of the diaphragm is clearly visualized. | Mild attenuation of sound beam through the liver | Intermediate | Marked attenuation of sound beam through the liver, the diaphragm is not visualized. |
| Clarity of liver blood vessel structure | Vessel wall and lumen of vessel can clearly visualized | Slight decrease definition of portal venule walls | Intermediate | Only the main portal walls can be visualized with absence of all smaller portal venule walls |

Table 8. Ultrasonographic grading system for diagnosis of fatty liver, adapted from [41].

Computer Tomography provides an accurate and a reliable visualization of whole liver, so that not only diffuse but also focal fatty infiltration of the liver parenchyma can be accurately diagnosed. CT enables the evaluation of absolute measurement of attenuation values which are given in Hounsfield units, the difference of attenuation between liver and spleen as well as

the calculation of the liver-to-spleen attenuation ratio, those correlate with steatosis degree. Liver density as measured by CT attenuation units has been shown to have an inverse correlation to the degree of fatty infiltration. Non-enhanced CT provides a high performance in qualitative diagnosis of hepatic steatosis when fatty infiltration is over 30%, obtaining 82% of sensitivity and 100% specificity using histologic analysis of biopsies of liver donors as the reference standard [45], however is not sensitive in detecting mild-to-moderate amounts of steatosis between 5% and 30% [43]. New CT scanning techniques are developing, such as dual-source/dual energy scanners, but their evaluation needs further studies. A drawback of this technique is the liver iron overload because it increases the attenuation. This method is associated with radiation exposure which limits its use in children.

Magnetic Resonance can detect steatosis by exploiting the difference of resonance frequencies between water and fat proton signals. The sensitivity and specificity of MRI in detecting as low as 5% of liver fat infiltration are 85% and 100%, respectively [46]. The detection of the fatty liver can be seen in “white/bright” when applying in-phase T1 images and “black” when applying out-of-phase images, compared to the signal intensity of the spleen and paraspinal muscles. Another technic of MR imaging with fat saturation may quantify more accurately liver fat infiltration, especially in patients who have fibrosis.

MR spectroscopy can reliably quantify even minimal steatosis, as low as 0,5% [47]. It has been based on the ubiquitous protons hydrogen and phosphorus [48], and more than 5% of fat content on MR spectroscopy indicates presence of steatosis [49]. Its routine application is limited by cost and lack of availability, and it remains a research tool.

| Methods (S/s) | Advantages | Disadvantage |
|---|---|---|
| Ultrasonography. (60-95% / 84-100%) | Noninvasive, widely available, low cost, repetition, Useful for screening | Operator dependent. Qualitative assessment of steatosis. Only accurate when moderate-to-severe fat infiltration. |
| Computer tomography, Contrast images. (50-86% / 75-87%) | Noninvasive, semiquantitative assessment of fat content. Detects focal or diffuse infiltration. | Radiation exposure. Iron overload, copper and fibrous tissue could be confounding factors. Not sensitive for mild-to-moderate amounts of steatosis. |
| Magnetic resonance imaging (85% / 100%) | Noninvasive, semiquantitative, and no radiation exposure. Detects focal or diffuse infiltration. | Limitation in patients with iron overload. Not suitable for patients with claustrophobia or implantable devices. |
| MR spectroscopy | Noninvasive, reproducible, accurate quantification. | High cost not widely available. Long time taking images. |

Table 9. Pro’s and con’s of radiologic modalities for the study of NAFLD. S: sensitivity; s: specificity. Adapted from [41].

US, CT and MR are insensitive in differentiating hepatic steatosis from NASH, and they cannot be used to stage fibrosis [43, 48]. But in the near future, a novel method based on MRI

imaging and a new software will be able to stage fibrosis and to distinguish NASH from no-NASH. Professor Romero-Gomez conducts this study and it will be soon published.

Table 9 summarizes advantages and disadvantages of these radiologic methods.

9. Non-invasive assesment in NAFLD

Liver biopsy remains a useful tool to confirm the diagnosis and exclude other disease or helps to discover concomitant chronic liver disease. It provides prognostic information by staging and grading this disease. At present non-invasive diagnostic markers could provide a new tool for differentiating fatty liver from NASH as well as for grading /staging NAFLD.

The investigation of these new diagnostic methods comes from the well known drawbacks of liver biopsy. These include sampling error, inadequate biopsy size, variability in pathologist interpretation, cost and associated morbidity (complications 0,3%, mortality rate 0,01%).

An ideal non-invasive test should be simple, reproducible, readily available, less expensive than liver biopsy, able to predict the full spectrum of liver fibrosis stages, and reflect changes occurring with therapy [48].

Some reviews provide an overview of the role of non-invasive test in NAFLD [48, 50, 51]. We will try to present many of these scores through a table (number 10) to summarize their characteristics. AUROC is a numerical data that assess the performance of a scoring system. AUROC value greater than 0,8 indicate good diagnostic performance. The closer the value to 1, the better performing the scoring system.

| SCORE [Reference] | Variables | Cutoff | AUROC | Sens. (%) | Spec. (%) | PPV (%) | NPV (%) |
|------------------------------------|--|------------|-----------|-----------|-----------|---------|---------|
| NONINVASIVE DIAGNOSIS OF STEATOSIS | | | | | | | |
| SteatoTest [52] | 6 components of FibroTest-ActiTest, BMI, cholesterol, triglycerides, glucose | 0,3 | 0,79-0,86 | 85 | 88 | 46 | 93 |
| | | 0,7 | | | | 63 | 79 |
| Fatty liver Index (FLI) [53] | BMI, waist circumference, triglycerides, GGT | <30 >70 | 0,85 | 87 | 86 | | |
| NONINVASIVE ASSESSMENT IN NASH | | | | | | | |
| Palekar [54] | HA >55 mcg/l, age >50 years, female gender, AST >45 UI/ml, AAR >80. | ≥3 | 0,763 | 73,7 | 65,7 | 68,2 | 71,4 |
| CK-18 [17] | CK-18 plasma (apoptosis marker) | 250 U/l | 0,83 | 75 | 81 | | |

| SCORE [Reference] | Variables | Cutoff | AUROC | Sens. (%) | Spec. (%) | PPV (%) | NPV (%) |
|---|---|---|---|--------------|--------------|-----------------------------|------------------|
| oxNASH [55] | Detection of lipid peroxidation products by chromatography-mass spectrometric | | 0,74-0,83 | 63-81 | 84-97 | | |
| SHIMADA [56] | Serum adiponectin, type 4 collagen 7s level, HOMA-IR | | | 94 | 74 | 94 | 74 |
| NASH Diagnostics [57]* | CK-18, cleaved CK-18, adiponectin, resistin | 0,3825 | 0,73 | 71,4 | 72,7 | 83,3 | 57,1 |
| NashTest [58] | Age, gender, BMI, triglycerides, cholesterol, alfa-2macroglobulin, GGT, haptoglobin, apolipoprotein-A1, total bilirubin | | 0,79 | 29 | 98 | 91 | 71 |
| NONINVASIVE MANAGEMENT OF FIBROSIS IN NAFLD | | | | | | | |
| NAFLD fibrosis score [59] | Age, BMI, IFG/diabetes, AAR, platelet, albumin | ≤1,455 ≥0,676 | 0,88 | | | 56 90 | 93 85 |
| Pediatric NAFLD fibrosis index [60] | Age, waist circumference and triglycerides. | ≥9: rule in liver fibrosis. <3:rule out fibrosis | 0,85 | | | 98,5 75,4** | 44,5 75** |
| | | | | | | **Pre-test probability: 69% | |
| BARD score [61] | BMI ≥28 =1, AAR ≥0,8 =2, diabetes=1, | ≥2: advanced fibrosis | 0,81 | | | | 96 |
| FIB-4 [62] | Age, AST, platelet, ALT | <1,3 >2,67 | 0,80 | | | 43 80 | 90 83 |
| APRI [63] | AST, platelet | 0,98 | Advanced fibrosis: 0,85 | 75 | 86 | 54 | 93 |
| ELF [64] | HA, TIMP1, P3NP. | 0,3576 -0,1068 | For severe fibrosis 0,90. For moderate fibrosis 0,82 | 80 70 | 90 80 | 71 70 | 94 80 |
| | | ELF: -0,2070. | No fibrosis 0,76 | 61 | 80 | 81 | 79 |
| BAAT [65] | Age ≥50years, BMI ≥28kg/m2 =1, triglycerides ≥7mmol/L=1, ALT ≥2N | 0-1, for septal fibrosis | 0,84 | 100 | 47 | | 100 |
| Fibrotest [66] | | 0,30 | F0-1 VS F2-4: 075-085. | 70 | | | 90 |

| SCORE [Reference] | Variables | Cutoff | AUROC | Sens. (%) | Spec. (%) | PPV (%) | NPV (%) |
|--|--|------------|------------------------------|-----------|-----------|---------|---------|
| | | | F0-2 VS F3-4: 0,81-0,92 | | | | |
| | | 0,70 | | | 98 | 73 | |
| Fibrometer [67] | Glucose, AST, platelets, ferritin, <0,611 ALT, weight, age. | | F0-1 vs F2-4: 0,936-0,952 | | | | |
| ULTRASOUND BASED TECHNIQUES IN FIBROSIS DETECTION IN NAFLD | | | | | | | |
| Fibroscan [68] | Transient elastography | 9,9 kPa | F ≥3: 0,99 | 100 | 93 | 77 | 100 |
| | | 16 kPa | F4: 0,998 | 100 | 93 | 86 | 100 |
| ARFI [69] | | 4,24 kPa | F0-2 vsF3-4: 0,90 | 90 | 90 | | |
| ARFI [68] | | 1,77 m/sec | F ≥3: 0,973 | 100 | 91 | 71 | 100 |
| | | 1,90 m/sec | F4: 0,976 | 100 | 96 | 75 | 100 |
| MAGNETIC RESONANCE IMAGING BASED TECHNIQUES | | | | | | | |
| MR elastography[70] | Discriminating NASH from simple steatosis (SS) | 2,74 kPa | SS vs NASH: 0,93 | 94 | 73 | 85 | 89 |
| | | Means: | Simple steatosis. | | | | |
| | | - 2,51kPa. | NASH no fibrosis. | | | | |
| | | - 3,24kPa. | With fibrosis | | | | |
| | | - 4,16kPa. | | | | | |

Abbreviations: AUROC: area under receiver operator curve. Sens.: Sensitivity; Spec.: Specificity; PPV: positive predictive value; NPV: negative predictive value; BMI: body mass index; GGT: Gamma-glutamyl-transpeptidase; HA: hyaluronic acid; AST: aspartate transaminase; AAR: AST/alanine aminotransferase, TIMP-1: tissue inhibitor of matrix metalloproteinase 1; P3NP: aminoterminal peptide of pro-collagen III; ARFI: acoustic radiation force impulse; * Sample: bariatric surgery patients. COMMENTS: BARD score can reliably exclude advance fibrosis, particularly among non-diabetics. FIB-4, as happened with BARD score, is useful in excluding advance fibrosis due its high NPV. Transient elastography and ARFI are based on the variation of the speed wave through liver tissue (generated by vibrator/short-duration acoustic pulses, respectively), this can be measured and converted to a numerical value (in kPa and m/sec, respectively, but ARFI could also be expressed as kPa) which is the liver stiffness and it is proportional to liver fibrosis. An important difference between both systems is that ARFI consists in a probe which can be plugged to a common US machine so both techniques can be performed at the same time.

Table 10. Non-invasive assessment of NAFLD.

APRI and FIB-4 have been evaluated in obese children and they might be useful in this special population [71]. Pediatric NAFLD scores is a noninvasive model evaluated in obese children, and it may help clinicians to predict liver fibrosis but external validation is needed [60].

In the future, new serologic markers, such as CD36, will help to differentiate more accurately between NAFLD stages, we would be able to distinguish simple steatosis from NASH.

Although clinical and laboratory models may be useful in identifying a group of patients at a low risk of advance fibrosis and liver biopsy might be avoided, they are not enough for staging and prognostic purposes if patients are at risk of advance fibrosis [48]. NAFLD Practice Guideline of 2012 recommends NAFLD fibrosis score to identify patients with higher likelihood of having bridging fibrosis and/or cirrhosis [1].

10. New diagnostic platforms in naflD

NAFLD is a disease with wide spectrum: from steatosis through inflammation to fibrosis and finally cirrhosis and hepatocellular carcinoma, even in absence of cirrhosis [72]. The strongest predictor of fibrosis progression in NAFLD is steatohepatitis. The most important features are hepatocellular degeneration (ballooning) and inflammatory cell infiltration.

These new techniques include genomics, metabolomics and proteomics.

Genomics. Gene expression studies provide an insight into possible mechanism of pathogenesis as well as potential biomarkers of disease. One method for studying gene expression is micro-arrays of DNA. A study using this test found 34 genes with different expression in NASH vs controls, these genes were implicated in lipid metabolism and extracellular matrix remodelling [73]. Another study compared gene expression in NASH-related cirrhosis with other causes of cirrhosis. In NASH cirrhosis group genes involved in anti-oxidant stress were underexpressed, along with genes involved in fatty and glucose metabolism [74]. In our centre we used micro-arrays to study gene expression in obese patients with NAFLD [75]. Obese patients with NASH without fibrosis show an overexpression of proinflammatory and proapoptotic genes; and those with fibrosis show an overexpression of fibrogenic genes, including the leptin receptor Ob-Rb.

Most recent genomic tests, such as GWAS (Genome-wide association studies) provide a method for evaluating a large number of single nucleotide polymorphisms (SNP) with the same experiment. A study performed with a GWAS study found a SNP in farnesyl diphosphate farnesyltransferase 1 (FDFT1) which was associated with different histological parameters (a SNP with portal inflammation and another different SNP with fibrosis stage) and the total NAFLD activity score [76]. In an earlier GWAS study [77], an SNP in PNPA3 (adiponutrin/patatin-like phospholipase-3) was strongly associated with both hepatic fat content and hepatic inflammation. The prevalence of this mutation may explain the difference in susceptibility to NAFLD seen in different ethnicities [77]. A subsequent study [78], confirmed the relationship between this SNP and histological score, the no association with metabolic syndrome.

These studies are incredibly interesting and they could help the development of new noninvasive markers, nevertheless all of them share limitations, mainly concerning to sample size. It is easily understandable given the fact that they use expensive and complex tools [51].

Proteomics. Proteomic tools look specifically at protein expression patterns and profiles. There are several approaches to proteomic studies depending on the used tool. These tools are complex; they are based on diverse types of mass-spectrometry. For more detailed information refer to [79, 80]. The different proteomic platforms support the use of either liver tissue or blood. This platform allows identifying, quantifying and comparing proteins in the study groups of interest. That novel approach has been applied for the study of NAFLD [81-84]. These studies have found several proteins related to disease progression: alpha and beta-hemoglobin [84], lumican and FABP1 (fatty acid binding protein-1) [82]; and finally fibrinogen beta-chain, retinol binding protein-4, serum amyloid p-component, lumican, transgrelin-2 and CD5-like antigen, in 6-panel model and complement component 7, transgrelin-2

and insulin growth factor acid labile subunit, in a 3-panel model. These panels performed in the diagnosis of the diverse NAFLD stages get an area under the receiver operator curve (AUROC) ranging from 0,83 to 0,91 [83].

Metabolomics. In the natural history of NAFLD the progression to hepatic fibrosis occurs only in 10 to 25% of cases, leading to cirrhosis, end-stage liver disease or hepatocellular carcinoma. The strongest predictor of fibrotic progression, apart from pre-existing fibrosis, is steatohepatitis. A two-hit model has been proposed as an explanation for why some patients progress to NASH. In a first step, because of insulin resistance, adipose tissue has enhanced triglyceride lipolysis, which leads to increased serum free fatty acids, and impaired hepatic triglyceride export. In this model, hepatic steatosis (hit 1) exposes the liver parenchyma to environmental and extracellular hepatic insults (hit 2), leading to inflammation, steatonecrosis and fibrosis. Impaired mitochondrial oxidation and lipid export may also contribute to hepatic fat deposition.

Leptin system is also implicated, and its receptor expression is related to fibrosis degree [85].

As it was explained in the introduction, irisin is a newly identified hormone. Irisin is produced in muscle cells induced in exercise [86-88]. Irisin activates changes in adipose tissue, and make its change from white adipose tissue to brown adipose tissue, and this causes a significant increase in total body energy expenditure and resistance to obesity-linked insulin resistance. So this advance opens new pathogenic pathways in NAFLD.

Inflammation is considered to be the central clue for the progression of NAFLD, the origins and components are considered in this review [89]. Hepatocytes injured by toxic lipid molecules play a central role in the recruitment of innate immunity involving Toll-like receptors (TLR), Kupffer cells, lymphocytes and neutrophils and possibly inflammasome. On this way, a study was carried to determine the lipidomic signature in NAFLD [90]. Using proteomic tools (mass spectrometry) the investigators found metabolites from nonenzymatic oxidation product of arachidonic acid and from impaired peroxisomal polyunsaturated fatty acid (PUFA). This study links to another, where investigators characterize metabolic profile to distinguish steatosis and NASH [91], they also found arachidonic acid, among other substances, relation to NASH and fibrosis. Metabolomics analysis was performed to NAFLD patients showing a lower concentrations of glutathione, an antioxidant substance, in this group [92].

The key pro-inflammatory signalling pathways in NASH are nuclear factor-kappa B (NF- κ B) and c-Jun N-terminal kinase (JNK). It could be possible that inflammation in NASH could originate outside the liver. Gut microbiota, the related Kupffer/TLR response, inflamed adipose tissue and circulating inflammatory cell can contribute or act as co-factors that triggers or maintain hepatic injury. In a study conducted in our centre to study the relationship between endotoxemia and NAFLD, we found higher levels of LBP (Lipopolysaccharide-binding protein) in patients with NASH when compared to patients with simple steatosis [93]. The LBP increase correlates with the level of tumor necrosis factor alpha (TNF- α) which is overexpressed in patient with NASH and significant fibrosis. [94] Detailed in-

formation in pathophysiology of NAFLD and NASH is not the aim of this paper, if you are interested refer to this review [89].

11. Conclusion

NAFLD is an emerging problem. The study of pathology is ever evolving which is allowing the development of new therapeutic targets, and the emergence of new diagnostic techniques allow better identification of patients who will benefit from new treatments.

Author details

Joaquín Cabezas¹, Marta Mayorga² and Javier Crespo¹

1 Gastroenterology and Hepatology Unit, University Hospital “Marqués de Valdecilla”, Santander, Spain

2 Pathology Department, University Hospital “Marqués de Valdecilla”, Santander, Spain

References

- [1] Chalasani N, Younossi Z, Lavine JE, Diehl AM, Brunt EM, Cusi K, et al. The diagnosis and management of non-alcoholic fatty liver disease: practice Guideline by the American Association for the Study of Liver Diseases, American College of Gastroenterology, and the American Gastroenterological Association. *Hepatology*. 2012;55(6):2005-23. Epub 2012/04/11.
- [2] Younossi ZM, Stepanova M, Afendy M, Fang Y, Younossi Y, Mir H, et al. Changes in the prevalence of the most common causes of chronic liver diseases in the United States from 1988 to 2008. *Clin Gastroenterol Hepatol*. 2011;9(6):524-30 e1; quiz e60. Epub 2011/03/29.
- [3] Whalley S, Puvanachandra P, Desai A, Kennedy H. Hepatology outpatient service provision in secondary care: a study of liver disease incidence and resource costs. *Clin Med*. 2007;7(2):119-24. Epub 2007/05/12.
- [4] Suzuki A, Angulo P, Lymp J, St Sauver J, Muto A, Okada T, et al. Chronological development of elevated aminotransferases in a nonalcoholic population. *Hepatology*. 2005;41(1):64-71. Epub 2005/02/04.
- [5] Lee FY, Evans A, Kim D. Prevalence of fatty liver disease: a community-based autopsy study. Program and abstracts of Digestive Disease Week 2012; May 19-22, 2012; San Diego, California; Abstract 1054.

- [6] Vos MB, Welsh J. Prevalence of suspected NAFLD is increasing among U.S. adolescents. Digestive Disease Week 2012; May 19-22, 2012; San Diego, California. Abstract 705.
- [7] Kleiner DE, Brunt EM. Nonalcoholic fatty liver disease: pathologic patterns and biopsy evaluation in clinical research. *Semin Liver Dis.* 2012;32(1):3-13. Epub 2012/03/16.
- [8] Kleiner DE, Brunt EM, Van Natta M, Behling C, Contos MJ, Cummings OW, et al. Design and validation of a histological scoring system for nonalcoholic fatty liver disease. *Hepatology.* 2005;41(6):1313-21. Epub 2005/05/26.
- [9] Chalasani N, Wilson L, Kleiner DE, Cummings OW, Brunt EM, Unalp A. Relationship of steatosis grade and zonal location to histological features of steatohepatitis in adult patients with non-alcoholic fatty liver disease. *J Hepatol.* 2008;48(5):829-34. Epub 2008/03/07.
- [10] Brunt EM, Tiniakos DG. Histopathology of nonalcoholic fatty liver disease. *World J Gastroenterol.* 2010;16(42):5286-96. Epub 2010/11/13.
- [11] Tiniakos DG. Nonalcoholic fatty liver disease/nonalcoholic steatohepatitis: histological diagnostic criteria and scoring systems. *Eur J Gastroenterol Hepatol.* 2010;22(6):643-50. Epub 2009/05/30.
- [12] Malhi H, Gores GJ, Lemasters JJ. Apoptosis and necrosis in the liver: a tale of two deaths? *Hepatology.* 2006;43(2 Suppl 1):S31-44. Epub 2006/02/01.
- [13] Lackner C, Gogg-Kamerer M, Zatloukal K, Stumptner C, Brunt EM, Denk H. Ballooned hepatocytes in steatohepatitis: the value of keratin immunohistochemistry for diagnosis. *J Hepatol.* 2008;48(5):821-8. Epub 2008/03/11.
- [14] Ratzliff V, Charlotte F, Heurtier A, Gombert S, Giral P, Bruckert E, et al. Sampling variability of liver biopsy in nonalcoholic fatty liver disease. *Gastroenterology.* 2005;128(7):1898-906. Epub 2005/06/09.
- [15] Younossi ZM, Stepanova M, Rafiq N, Makhlof H, Younoszai Z, Agrawal R, et al. Pathologic criteria for nonalcoholic steatohepatitis: interprotocol agreement and ability to predict liver-related mortality. *Hepatology.* 2011;53(6):1874-82. Epub 2011/03/02.
- [16] Matteoni CA, Younossi ZM, Gramlich T, Boparai N, Liu YC, McCullough AJ. Nonalcoholic fatty liver disease: a spectrum of clinical and pathological severity. *Gastroenterology.* 1999;116(6):1413-9. Epub 1999/05/29.
- [17] Feldstein AE, Wieckowska A, Lopez AR, Liu YC, Zein NN, McCullough AJ. Cytokeratin-18 fragment levels as noninvasive biomarkers for nonalcoholic steatohepatitis: a multicenter validation study. *Hepatology.* 2009;50(4):1072-8. Epub 2009/07/09.
- [18] Brunt EM. Nonalcoholic steatohepatitis: pathologic features and differential diagnosis. *Semin Diagn Pathol.* 2005;22(4):330-8. Epub 2006/08/31.

- [19] Neuschwander-Tetri BA, Brunt EM, Wehmeier KR, Oliver D, Bacon BR. Improved nonalcoholic steatohepatitis after 48 weeks of treatment with the PPAR-gamma ligand rosiglitazone. *Hepatology*. 2003;38(4):1008-17. Epub 2003/09/27.
- [20] Brunt EM, Kleiner DE, Wilson LA, Unalp A, Behling CE, Lavine JE, et al. Portal chronic inflammation in nonalcoholic fatty liver disease (NAFLD): a histologic marker of advanced NAFLD-Clinicopathologic correlations from the nonalcoholic steatohepatitis clinical research network. *Hepatology*. 2009;49(3):809-20. Epub 2009/01/15.
- [21] Gill RM, Belt P, Wilson L, Bass NM, Ferrell LD. Centrizonal arteries and microvessels in nonalcoholic steatohepatitis. *Am J Surg Pathol*. 2011;35(9):1400-4. Epub 2011/08/13.
- [22] Adams LA, Sanderson S, Lindor KD, Angulo P. The histological course of nonalcoholic fatty liver disease: a longitudinal study of 103 patients with sequential liver biopsies. *J Hepatol*. 2005;42(1):132-8. Epub 2005/01/05.
- [23] Ekstedt M, Franzen LE, Mathiesen UL, Thorelius L, Holmqvist M, Bodemar G, et al. Long-term follow-up of patients with NAFLD and elevated liver enzymes. *Hepatology*. 2006;44(4):865-73. Epub 2006/09/29.
- [24] Pagadala MR, McCullough AJ. The relevance of liver histology to predicting clinically meaningful outcomes in nonalcoholic steatohepatitis. *Clin Liver Dis*. 2012;16(3):487-504. Epub 2012/07/25.
- [25] Caldwell SH, Chang CY, Nakamoto RK, Krugner-Higby L. Mitochondria in nonalcoholic fatty liver disease. *Clin Liver Dis*. 2004;8(3):595-617, x. Epub 2004/08/28.
- [26] Pinto HC, Baptista A, Camilo ME, Valente A, Saragoca A, de Moura MC. Nonalcoholic steatohepatitis. Clinicopathological comparison with alcoholic hepatitis in ambulatory and hospitalized patients. *Dig Dis Sci*. 1996;41(1):172-9. Epub 1996/01/01.
- [27] Nelson JE, Wilson L, Brunt EM, Yeh MM, Kleiner DE, Unalp-Arida A, et al. Relationship between the pattern of hepatic iron deposition and histological severity in nonalcoholic fatty liver disease. *Hepatology*. 2011;53(2):448-57. Epub 2011/01/29.
- [28] Ludwig J, Viggiano TR, McGill DB, Oh BJ. Nonalcoholic steatohepatitis: Mayo Clinic experiences with a hitherto unnamed disease. *Mayo Clin Proc*. 1980;55(7):434-8. Epub 1980/07/01.
- [29] Levy JC, Matthews DR, Hermans MP. Correct homeostasis model assessment (HOMA) evaluation uses the computer program. *Diabetes Care*. 1998;21(12):2191-2. Epub 1998/12/05.
- [30] Richardson MM, Jonsson JR, Powell EE, Brunt EM, Neuschwander-Tetri BA, Bhathal PS, et al. Progressive fibrosis in nonalcoholic steatohepatitis: association with altered regeneration and a ductular reaction. *Gastroenterology*. 2007;133(1):80-90. Epub 2007/07/17.
- [31] Grundy SM, Cleeman JI, Daniels SR, Donato KA, Eckel RH, Franklin BA, et al. Diagnosis and management of the metabolic syndrome: an American Heart Association/

National Heart, Lung, and Blood Institute Scientific Statement. *Circulation*. 2005;112(17):2735-52. Epub 2005/09/15.

- [32] Machado M, Marques-Vidal P, Cortez-Pinto H. Hepatic histology in obese patients undergoing bariatric surgery. *J Hepatol*. 2006;45(4):600-6. Epub 2006/08/11.
- [33] Abrams GA, Kunde SS, Lazenby AJ, Clements RH. Portal fibrosis and hepatic steatosis in morbidly obese subjects: A spectrum of nonalcoholic fatty liver disease. *Hepatology*. 2004;40(2):475-83. Epub 2004/09/16.
- [34] Vuppalanchi R, Chalasani N. Nonalcoholic fatty liver disease and nonalcoholic steatohepatitis: Selected practical issues in their evaluation and management. *Hepatology*. 2009;49(1):306-17. Epub 2008/12/10.
- [35] Dixon JB, Bhathal PS, Hughes NR, O'Brien PE. Nonalcoholic fatty liver disease: Improvement in liver histological analysis with weight loss. *Hepatology*. 2004;39(6):1647-54. Epub 2004/06/09.
- [36] Mummadi RR, Kasturi KS, Chennareddygar S, Sood GK. Effect of bariatric surgery on nonalcoholic fatty liver disease: systematic review and meta-analysis. *Clin Gastroenterol Hepatol*. 2008;6(12):1396-402. Epub 2008/11/07.
- [37] Schwimmer JB, Behling C, Newbury R, Deutsch R, Nievergelt C, Schork NJ, et al. Histopathology of pediatric nonalcoholic fatty liver disease. *Hepatology*. 2005;42(3):641-9. Epub 2005/08/24.
- [38] Carter-Kent C, Yerian LM, Brunt EM, Angulo P, Kohli R, Ling SC, et al. Nonalcoholic steatohepatitis in children: a multicenter clinicopathological study. *Hepatology*. 2009;50(4):1113-20. Epub 2009/07/29.
- [39] Roberts EA. Non-alcoholic steatohepatitis in children. *Clin Liver Dis*. 2007;11(1):155-72, x. Epub 2007/06/05.
- [40] Hsu E, Murray K. Is nonalcoholic Fatty liver disease in children the same disease as in adults? *Clin Liver Dis*. 2012;16(3):587-98. Epub 2012/07/25.
- [41] Cuadrado A, Orive A, Garcia-Suarez C, Dominguez A, Fernandez-Escalante JC, Crespo J, et al. Non-alcoholic steatohepatitis (NASH) and hepatocellular carcinoma. *Obes Surg*. 2005;15(3):442-6. Epub 2005/04/14.
- [42] Charatcharoenwitthaya P, Lindor KD. Role of radiologic modalities in the management of non-alcoholic steatohepatitis. *Clin Liver Dis*. 2007;11(1):37-54, viii. Epub 2007/06/05.
- [43] Saadeh S, Younossi ZM, Remer EM, Gramlich T, Ong JP, Hurley M, et al. The utility of radiological imaging in nonalcoholic fatty liver disease. *Gastroenterology*. 2002;123(3):745-50. Epub 2002/08/29.
- [44] Hamaguchi M, Kojima T, Itoh Y, Harano Y, Fujii K, Nakajima T, et al. The severity of ultrasonographic findings in nonalcoholic fatty liver disease reflects the metabolic

- syndrome and visceral fat accumulation. *Am J Gastroenterol*. 2007;102(12):2708-15. Epub 2007/09/27.
- [45] Park SH, Kim PN, Kim KW, Lee SW, Yoon SE, Park SW, et al. Macrovesicular hepatic steatosis in living liver donors: use of CT for quantitative and qualitative assessment. *Radiology*. 2006;239(1):105-12. Epub 2006/02/18.
- [46] Mazhar SM, Shieh morteza M, Sirlin CB. Noninvasive assessment of hepatic steatosis. *Clin Gastroenterol Hepatol*. 2009;7(2):135-40. Epub 2009/01/03.
- [47] Cassidy FH, Yokoo T, Aganovic L, Hanna RF, Bydder M, Middleton MS, et al. Fatty liver disease: MR imaging techniques for the detection and quantification of liver steatosis. *Radiographics*. 2009;29(1):231-60. Epub 2009/01/27.
- [48] Grandison GA, Angulo P. Can nash be diagnosed, graded, and staged noninvasively? *Clin Liver Dis*. 2012;16(3):567-85. Epub 2012/07/25.
- [49] Reeder SB, Cruite I, Hamilton G, Sirlin CB. Quantitative assessment of liver fat with magnetic resonance imaging and spectroscopy. *J Magn Reson Imaging*. 2011;34(4):729-49. Epub 2011/09/20.
- [50] Adams LA, Feldstein AE. Non-invasive diagnosis of nonalcoholic fatty liver and nonalcoholic steatohepatitis. *J Dig Dis*. 2011;12(1):10-6. Epub 2010/11/26.
- [51] Miller MH, Ferguson MA, Dillon JF. Systematic review of performance of non-invasive biomarkers in the evaluation of non-alcoholic fatty liver disease. *Liver Int*. 2011;31(4):461-73. Epub 2011/03/09.
- [52] Poynard T, Ratziu V, Naveau S, Thabut D, Charlotte F, Messous D, et al. The diagnostic value of biomarkers (SteatoTest) for the prediction of liver steatosis. *Comp Hepatol*. 2005;4:10. Epub 2005/12/27.
- [53] Bedogni G, Bellentani S, Miglioli L, Masutti F, Passalacqua M, Castiglione A, et al. The Fatty Liver Index: a simple and accurate predictor of hepatic steatosis in the general population. *BMC Gastroenterol*. 2006;6:33. Epub 2006/11/04.
- [54] Palekar NA, Naus R, Larson SP, Ward J, Harrison SA. Clinical model for distinguishing nonalcoholic steatohepatitis from simple steatosis in patients with nonalcoholic fatty liver disease. *Liver Int*. 2006;26(2):151-6. Epub 2006/02/02.
- [55] Feldstein AE, Lopez R, Tamimi TA, Yerian L, Chung YM, Berk M, et al. Mass spectrometric profiling of oxidized lipid products in human nonalcoholic fatty liver disease and nonalcoholic steatohepatitis. *J Lipid Res*. 2010;51(10):3046-54. Epub 2010/07/16.
- [56] Shimada M, Kawahara H, Ozaki K, Fukura M, Yano H, Tsuchishima M, et al. Usefulness of a combined evaluation of the serum adiponectin level, HOMA-IR, and serum type IV collagen 7S level to predict the early stage of nonalcoholic steatohepatitis. *Am J Gastroenterol*. 2007;102(9):1931-8. Epub 2007/05/22.

- [57] Younossi ZM, Jarrar M, Nugent C, Randhawa M, Afendy M, Stepanova M, et al. A novel diagnostic biomarker panel for obesity-related nonalcoholic steatohepatitis (NASH). *Obes Surg*. 2008;18(11):1430-7. Epub 2008/05/27.
- [58] Poynard T, Ratziu V, Charlotte F, Messous D, Munteanu M, Imbert-Bismut F, et al. Diagnostic value of biochemical markers (NashTest) for the prediction of non alcoholic steato hepatitis in patients with non-alcoholic fatty liver disease. *BMC Gastroenterol*. 2006;6:34. Epub 2006/11/14.
- [59] Angulo P, Hui JM, Marchesini G, Bugianesi E, George J, Farrell GC, et al. The NAFLD fibrosis score: a noninvasive system that identifies liver fibrosis in patients with NAFLD. *Hepatology*. 2007;45(4):846-54. Epub 2007/03/30.
- [60] Nobili V, Alisi A, Vania A, Tiribelli C, Pietrobattista A, Bedogni G. The pediatric NAFLD fibrosis index: a predictor of liver fibrosis in children with non-alcoholic fatty liver disease. *BMC Med*. 2009;7:21. Epub 2009/05/05.
- [61] Harrison SA, Oliver D, Arnold HL, Gogia S, Neuschwander-Tetri BA. Development and validation of a simple NAFLD clinical scoring system for identifying patients without advanced disease. *Gut*. 2008;57(10):1441-7. Epub 2008/04/09.
- [62] Shah AG, Lydecker A, Murray K, Tetri BN, Contos MJ, Sanyal AJ. Comparison of noninvasive markers of fibrosis in patients with nonalcoholic fatty liver disease. *Clin Gastroenterol Hepatol*. 2009;7(10):1104-12. Epub 2009/06/16.
- [63] Kruger FC, Daniels CR, Kidd M, Swart G, Brundyn K, van Rensburg C, et al. APRI: a simple bedside marker for advanced fibrosis that can avoid liver biopsy in patients with NAFLD/NASH. *S Afr Med J*. 2011;101(7):477-80. Epub 2011/09/17.
- [64] Guha IN, Parkes J, Roderick P, Chattopadhyay D, Cross R, Harris S, et al. Noninvasive markers of fibrosis in nonalcoholic fatty liver disease: Validating the European Liver Fibrosis Panel and exploring simple markers. *Hepatology*. 2008;47(2):455-60. Epub 2007/11/27.
- [65] Ratziu V, Giral P, Charlotte F, Bruckert E, Thibault V, Theodorou I, et al. Liver fibrosis in overweight patients. *Gastroenterology*. 2000;118(6):1117-23. Epub 2000/06/02.
- [66] Ratziu V, Massard J, Charlotte F, Messous D, Imbert-Bismut F, Bonyhay L, et al. Diagnostic value of biochemical markers (FibroTest-FibroSURE) for the prediction of liver fibrosis in patients with non-alcoholic fatty liver disease. *BMC Gastroenterol*. 2006;6:6. Epub 2006/03/01.
- [67] Cales P, Laine F, Boursier J, Deugnier Y, Moal V, Oberti F, et al. Comparison of blood tests for liver fibrosis specific or not to NAFLD. *J Hepatol*. 2009;50(1):165-73. Epub 2008/11/04.
- [68] Yoneda M, Yoneda M, Mawatari H, Fujita K, Endo H, Iida H, et al. Noninvasive assessment of liver fibrosis by measurement of stiffness in patients with nonalcoholic fatty liver disease (NAFLD). *Dig Liver Dis*. 2008;40(5):371-8. Epub 2007/12/18.

- [69] Palmeri ML, Wang MH, Rouze NC, Abdelmalek MF, Guy CD, Moser B, et al. Noninvasive evaluation of hepatic fibrosis using acoustic radiation force-based shear stiffness in patients with nonalcoholic fatty liver disease. *J Hepatol.* 2011;55(3):666-72. Epub 2011/01/25.
- [70] Chen J, Talwalkar JA, Yin M, Glaser KJ, Sanderson SO, Ehman RL. Early detection of nonalcoholic steatohepatitis in patients with nonalcoholic fatty liver disease by using MR elastography. *Radiology.* 2011;259(3):749-56. Epub 2011/04/05.
- [71] Yang HR, Kim HR, Kim MJ, Ko JS, Seo JK. Noninvasive parameters and hepatic fibrosis scores in children with nonalcoholic fatty liver disease. *World J Gastroenterol.* 2012;18(13):1525-30. Epub 2012/04/18.
- [72] Torres DM, Harrison SA. Nonalcoholic steatohepatitis and noncirrhotic hepatocellular carcinoma: fertile soil. *Semin Liver Dis.* 2012;32(1):30-8. Epub 2012/03/16.
- [73] Younossi ZM, Gorreta F, Ong JP, Schlauch K, Del Giacco L, Elariny H, et al. Hepatic gene expression in patients with obesity-related non-alcoholic steatohepatitis. *Liver Int.* 2005;25(4):760-71. Epub 2005/07/07.
- [74] Sreekumar R, Rosado B, Rasmussen D, Charlton M. Hepatic gene expression in histologically progressive nonalcoholic steatohepatitis. *Hepatology.* 2003;38(1):244-51. Epub 2003/06/28.
- [75] Cayon A, Crespo J, Guerra AR, Pons-Romero F. (Gene expression in obese patients with non-alcoholic steatohepatitis). *Rev Esp Enferm Dig.* 2008;100(4):212-8. Epub 2008/06/20. Expresion genica en pacientes obesos con enfermedad hepatica por deposito de grasa.
- [76] Chalasani N, Guo X, Loomba R, Goodarzi MO, Haritunians T, Kwon S, et al. Genome-wide association study identifies variants associated with histologic features of nonalcoholic Fatty liver disease. *Gastroenterology.* 2010;139(5):1567-76, 76 e1-6. Epub 2010/08/17.
- [77] Romeo S, Kozlitina J, Xing C, Pertsemlidis A, Cox D, Pennacchio LA, et al. Genetic variation in PNPLA3 confers susceptibility to nonalcoholic fatty liver disease. *Nat Genet.* 2008;40(12):1461-5. Epub 2008/09/30.
- [78] Speliotes EK, Butler JL, Palmer CD, Voight BF, Hirschhorn JN. PNPLA3 variants specifically confer increased risk for histologic nonalcoholic fatty liver disease but not metabolic disease. *Hepatology.* 2010;52(3):904-12. Epub 2010/07/22.
- [79] Griffin TJ, Aebersold R. Advances in proteome analysis by mass spectrometry. *J Biol Chem.* 2001;276(49):45497-500. Epub 2001/10/05.
- [80] Kito K, Ito T. Mass spectrometry-based approaches toward absolute quantitative proteomics. *Curr Genomics.* 2008;9(4):263-74. Epub 2009/05/20.

- [81] Younossi ZM, Baranova A, Ziegler K, Del Giacco L, Schlauch K, Born TL, et al. A genomic and proteomic study of the spectrum of nonalcoholic fatty liver disease. *Hepatology*. 2005;42(3):665-74. Epub 2005/08/24.
- [82] Charlton M, Viker K, Krishnan A, Sanderson S, Veldt B, Kaalsbeek AJ, et al. Differential expression of lumican and fatty acid binding protein-1: new insights into the histologic spectrum of nonalcoholic fatty liver disease. *Hepatology*. 2009;49(4):1375-84. Epub 2009/03/31.
- [83] Bell LN, Theodorakis JL, Vuppalanchi R, Saxena R, Bemis KG, Wang M, et al. Serum proteomics and biomarker discovery across the spectrum of nonalcoholic fatty liver disease. *Hepatology*. 2010;51(1):111-20. Epub 2009/11/04.
- [84] Trak-Smayra V, Dargere D, Noun R, Albuquerque M, Yaghi C, Gannage-Yared MH, et al. Serum proteomic profiling of obese patients: correlation with liver pathology and evolution after bariatric surgery. *Gut*. 2009;58(6):825-32. Epub 2008/04/12.
- [85] Cayon A, Crespo J, Mayorga M, Guerra A, Pons-Romero F. Increased expression of Ob-Rb and its relationship with the overexpression of TGF-beta1 and the stage of fibrosis in patients with nonalcoholic steatohepatitis. *Liver Int*. 2006;26(9):1065-71. Epub 2006/10/13.
- [86] Kelly DP. Medicine. Irisin, light my fire. *Science*. 2012;336(6077):42-3. Epub 2012/04/12.
- [87] Pedersen BK. A muscular twist on the fate of fat. *N Engl J Med*. 2012;366(16):1544-5. Epub 2012/04/20.
- [88] Bostrom P, Wu J, Jedrychowski MP, Korde A, Ye L, Lo JC, et al. A PGC1-alpha-dependent myokine that drives brown-fat-like development of white fat and thermogenesis. *Nature*. 2012;481(7382):463-8. Epub 2012/01/13.
- [89] Farrell GC, van Rooyen D, Gan L, Chitturi S. NASH is an Inflammatory Disorder: Pathogenic, Prognostic and Therapeutic Implications. *Gut Liver*. 2012;6(2):149-71. Epub 2012/05/10.
- [90] Puri P, Wiest MM, Cheung O, Mirshahi F, Sargeant C, Min HK, et al. The plasma lipidomic signature of nonalcoholic steatohepatitis. *Hepatology*. 2009;50(6):1827-38. Epub 2009/11/26.
- [91] Barr J, Vazquez-Chantada M, Alonso C, Perez-Cormenzana M, Mayo R, Galan A, et al. Liquid chromatography-mass spectrometry-based parallel metabolic profiling of human and mouse model serum reveals putative biomarkers associated with the progression of nonalcoholic fatty liver disease. *J Proteome Res*. 2010;9(9):4501-12. Epub 2010/08/06.
- [92] Kalhan SC, Guo L, Edmison J, Dasarthy S, McCullough AJ, Hanson RW, et al. Plasma metabolomic profile in nonalcoholic fatty liver disease. *Metabolism*. 2011;60(3):404-13. Epub 2010/04/29.

- [93] Ruiz AG, Casafont F, Crespo J, Cayon A, Mayorga M, Estebanez A, et al. Lipopolysaccharide-binding protein plasma levels and liver TNF- α gene expression in obese patients: evidence for the potential role of endotoxin in the pathogenesis of non-alcoholic steatohepatitis. *Obes Surg.* 2007;17(10):1374-80. Epub 2007/11/15.
- [94] Crespo J, Cayon A, Fernandez-Gil P, Hernandez-Guerra M, Mayorga M, Dominguez-Diez A, et al. Gene expression of tumor necrosis factor α and TNF-receptors, p55 and p75, in nonalcoholic steatohepatitis patients. *Hepatology.* 2001;34(6):1158-63. Epub 2001/12/04.