

We are IntechOpen, the world's leading publisher of Open Access books Built by scientists, for scientists

6,900

Open access books available

185,000

International authors and editors

200M

Downloads

Our authors are among the

154

Countries delivered to

TOP 1%

most cited scientists

12.2%

Contributors from top 500 universities



WEB OF SCIENCE™

Selection of our books indexed in the Book Citation Index
in Web of Science™ Core Collection (BKCI)

Interested in publishing with us?
Contact book.department@intechopen.com

Numbers displayed above are based on latest data collected.
For more information visit www.intechopen.com



Non-Odontogenic Oral and Maxillofacial Infections

Petr Schütz and Hussein Hassan Hamed Ibrahim

Additional information is available at the end of the chapter

<http://dx.doi.org/10.5772/54304>

1. Introduction

While odontogenic infections are daily encountered in dental and oral and maxillofacial surgery practices, some practitioners may be unfamiliar with the wide range of other infections of diverse etiology, some of them relatively uncommon, or even rare. Patients so affected come to their attention either through referrals from primary care providers or due to patients' uncertainty about where to seek help for diseases manifesting themselves in the orofacial area. Also in hospital environment, where majority of oral and maxillofacial surgeons practice, one regularly receives requests for consultations about patients who need interdisciplinary cooperation despite the fact that their conditions primarily belong to the sphere of specializations like ENT surgery, ophthalmology, dermatology and others. The purpose of this chapter is to provide an update on such conditions and demonstrate the ways oral and maxillofacial surgeon can participate in their diagnosis and management.

2. Facial skin infections

2.1. Impetigo

Impetigo is a highly contagious infection of the superficial epidermis. It is usually caused by *Staphylococcus aureus* or Group A streptococci [1]. The form of impetigo that penetrates deeper into the dermis and may leave a scar is called ecthyma. Impetigo occurs most frequently among economically disadvantaged children aged 2–5 years, although older children and adults may also be afflicted under conditions of poor hygiene, high humidity and warm temperatures. Prospective studies of streptococcal impetigo have demonstrated that the responsible microorganisms initially colonize the unbroken skin. Inoculation of surface organisms into the skin happens after a mean interval of 10 days by abrasions, minor trauma, or insect bites [2].

2.1.1. Clinical presentation

The most frequent locations of impetigo are the face and extremities. Two clinical forms are recognized: non-bullous and bullous. The lesions of non-bullous impetigo begin as papules that rapidly evolve into vesicles surrounded by an area of erythema. Then they become pustules that gradually enlarge and break down over a period of 4–6 days to form characteristic golden yellow crusts [3]. (Figure 1)

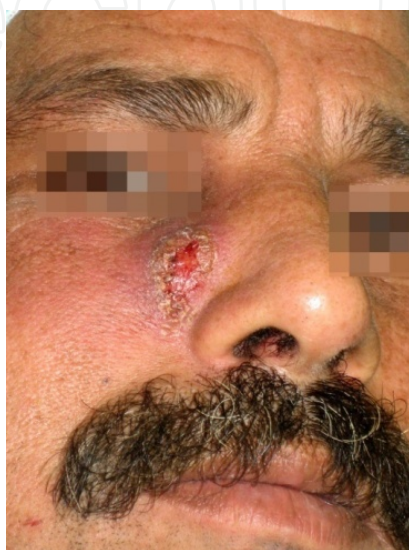

Figure 1. Non-bullous impetigo of paranasal skin with a central denuded area and peripheral crust.

Bullous lesions appear initially as superficial vesicles that rapidly enlarge to form flaccid bullae filled with clear yellow fluid, which later becomes darker, more turbid, and sometimes purulent. The bullae may rupture, often leaving a thin brown crust resembling lacquer [4]. The lesions heal slowly and leave depigmented areas. Bullous impetigo is caused by strains of *S. aureus* that produce a toxin causing cleavage in the superficial skin layer. In the past, nonbullous lesions were usually caused by streptococci. Now, most cases are caused by staphylococci alone or in combination with streptococci [5].

2.1.2. Treatment

The therapeutic approach to impetigo depends on the number of lesions, their extent and location (in a face proximity to eyelids or mouth), and the need to limit spread of infection to other individuals. The best topical agent is mupirocin, although resistance has been described; other agents, such as bacitracin and neomycin, are considerably less effective. Topical therapy with mupirocin is equivalent to oral systemic antimicrobials and may be used when lesions are limited in number. Patients who have numerous lesions or who are not responding to topical agents should receive oral antibiotics effective against both *S. aureus* and *Streptococcus pyogenes*. The preferred antibiotics are penicillinase resistant penicillins or first-generation cephalosporins, because *S. aureus* currently accounts for most cases of bullous impetigo, as well as for a substantial portion of nonbullous infections [3].

2.2. Folliculitis

Folliculitis is defined as purulent infection of hair follicles limited to the epidermis. Predisposing factors are hot and humid conditions, obesity, diabetes mellitus, long-term antibiotic or corticosteroid use, and immunosuppression [1].

2.2.1. Clinical presentation and etiology

Folliculitis is characterized by clusters of small, erythematous papules or pustules, usually in body areas prone to friction and heavy perspiration. The face belongs to the most often involved areas. The most common form of folliculitis is *sycosis barbae* a staphylococcal infection related to shaving. (Figure 2)

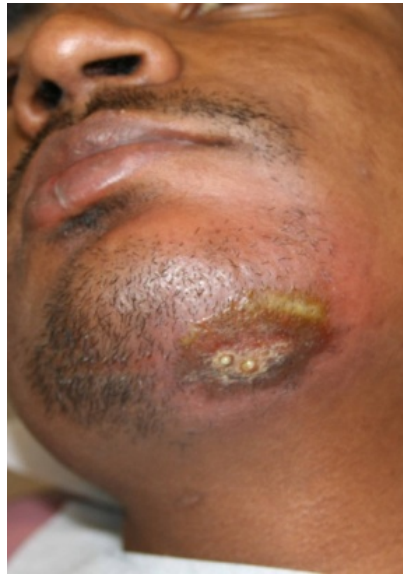

Figure 2. Sycosis barbae with peripheral cellulitis.

The fungal counterpart of sycosis barbae is *tinea barbae* caused by various dermatophytes. Other possible etiological agents include *Enterobacteriaceae* (often associated with prolonged antibiotic therapy), *Pseudomonas aeruginosa* (associated with hot tubs and wet suits) [6], *Malassezia furfur*, herpes simplex virus, varicella-zoster virus and *Demodex* mites. Non-infectious folliculitis include eosinophilic folliculitis thought to be an autoimmune process directed against the sebocytes [7] and a papulopustular follicular eruption after treatment with epidermal growth factor receptor (EGF-R) inhibitors [8].

2.2.2. Treatment

Uncomplicated superficial folliculitis may respond to improved hygiene supported by use of antibacterial soap. If this simple measure is not sufficient, topical antibiotic cream can be used. Refractory or deep infections may require administration of systemic antibiotics. Selection of appropriate antibiotic is based on knowledge of the common microorganisms involved in the particular type of infection before results of microbiology examination and antibiotic sensitivity tests are available. Herpetic folliculitis responds to oral antivirals (e.g.

valaciclovir). Eosinophilic folliculitis may respond to isotretinoin, metronidazole, UV-B phototherapy, indometacin or itraconazole [1]. Infectious folliculitis may progress to involve deeper layer of the dermis and finally spread to subcutaneous tissue.

2.3. Furuncle and carbuncle

Furuncle is purulent infection involving the hair follicle and extending to surrounding subcutaneous tissue. (Figure 3)

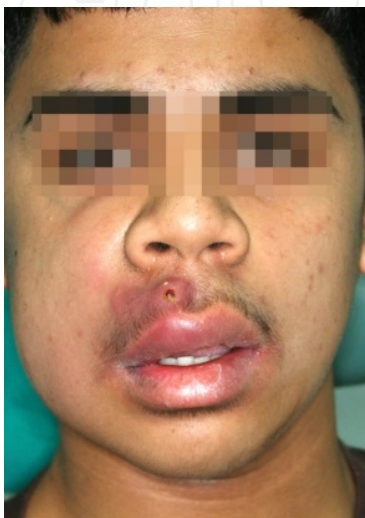

Figure 3. Furuncle of the upper lip. Note progression of infection to right paranasal area.

Furuncles can occur anywhere on hairy skin. A carbuncle is the coalescence of several furuncles with pus draining from multiple follicular orifices. Carbuncles frequently develop on the nape and are more likely to be seen in diabetic patients [3]. In immunocompetent individuals, furuncles and carbuncles are usually caused by *S. aureus*. (Figure 4)

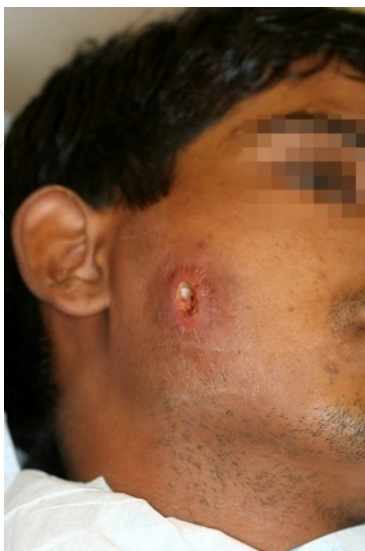

Figure 4. Carbuncle of right cheek in an immunocompetent patient.

2.3.1. Clinical presentation

In the face, furuncles are frequently seen on the chin, upper lip and paranasal area. Each lesion consists of an inflammatory nodule and an overlying pustule through which hair emerges. Furuncles of the nasal vestibule can be insidious and not obvious upon cursory examination and their symptoms, namely swelling of upper lip and infiltrate of upper oral vestibule, can lead to false impression of odontogenic infection. In patients affected by a facial furuncle, fever and malaise are common. Lesions are extremely painful and they are surrounded by area of cellulitis and collateral edema. (Figure 5)

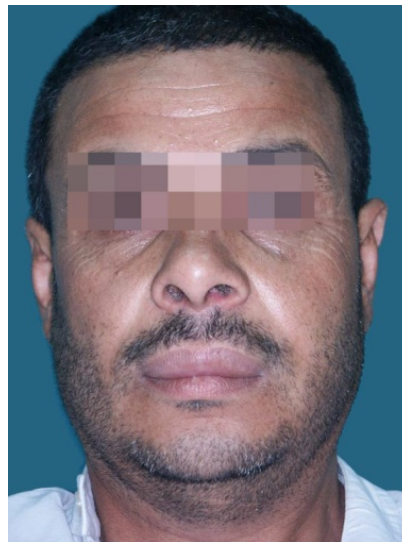

Figure 5. Furuncle of the nasal vestibule referred with suspicion of an odontogenic abscess.

2.3.2. Treatment

Small furuncles may burst and heal spontaneously [1]. Application of moist hot dressing can promote drainage. Also gentle removal of overlying crust and necrotic central plug can be helpful; however attempts to express purulent content should be discouraged. Conservative management is preferable and only rarely cases of furuncles or carbuncles progressing into subcutaneous abscess require incision and drainage. In the face, whenever possible, this should be done through intraoral route to avoid facial scarring. Systemic antibiotics are necessary in instances of substantial collateral cellulitis, alteration of general condition and signs of developing facial thrombophlebitis. This initial empirical therapy should be aimed at supposed staphylococcal etiology. Until recently, staphylococcal infections acquired outside of the healthcare setting have been frequently methicillin-sensitive and responsive to a wide range of antibiotics. Since 1980, methicillin-resistant staphylococcus aureus (MRSA) infections have been reported in community outbreaks. These organisms have been called community-acquired or community-associated MRSA, as opposed to hospital acquired MRSA [9]. Hospital acquired MRSA is usually resistant to at least three β -lactam antibiotics and is usually susceptible only to vancomycin, sulfamethoxazole, and nitrofurantoin. Com-

munity acquired MRSA is more likely to be susceptible to clindamycin and has varying susceptibility to tetracycline, fluoroquinolone, erythromycin and vancomycin [10]. Outbreaks of furunculosis may occur in families and other groups involved in close personal contact, like prisoners, members of sports teams or outdoor recreation groups [3,11]. Inadequate personal hygiene and exposure to others with furuncles play important role. Control of outbreaks may require bathing with antibacterial soaps, thorough laundering of clothing, towels, bed spreads, separate use of towels and washcloths. Eradication of staphylococcal carriage among colonized persons should be attempted. The prevalence of nasal staphylococcal colonization in the general population is 20–40%, but not all carriers develop recurrent skin infections. Eradication of nasal colonization can be achieved by application of mupirocin ointment twice daily in the anterior nares for the first 5 days each month [12].

2.4. Cellulitis

Cellulitis is diffusely spreading soft tissue infection not associated with underlying suppurative foci. It involves rapidly spreading areas of edema, erythema, and may be accompanied by lymphangitis and regional lymphadenitis [13].

2.4.1. Clinical presentation

In orofacial areas cellulitis is routinely seen as an early stage of odontogenic infections and it is present also at the periphery of other defined skin infections and infected traumatic wounds (Figure 6).

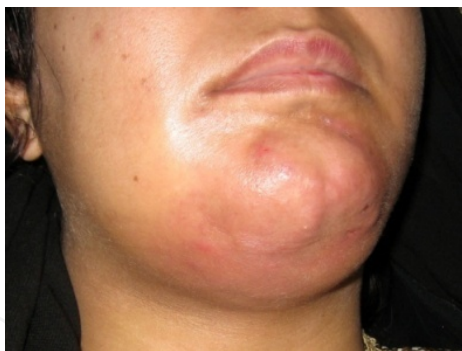

Figure 6. Nonodontogenic facial cellulitis following expression of comedones.

It can also occur as disease per se when organisms enter through breaches in the skin. The breaks in the skin can be small and clinically inconspicuous. Predisposing factors for these infections include conditions that make the skin more fragile or local host defenses less effective, such as obesity, previous cutaneous cuts, venous insufficiency, lymphatic obstruction or other causes [3]. Cellulitis of non-odontogenic origin is most commonly caused by β -hemolytic streptococci (usually group A) but may also be caused by other streptococcal species. Less frequently, *S. aureus* may be involved, especially in cases involving penetrating trauma. An etiologic diagnosis of simple cellulitis is frequently difficult and generally unnecessary for patients with mild signs and symptoms [3].

2.4.2. Treatment

Antibiotic treatment alone is effective in most patients with simple cellulitis. Therapy should include an antibiotic active against streptococci. A large percentage of patients can receive oral medications. Suitable agents include dicloxacillin, cephalexin, clindamycin, or erythromycin. Parenteral therapy is indicated for severely ill patients or for those unable to tolerate oral medications. Reasonable choices include a penicillinase-resistant penicillin such as nafcillin, a first-generation cephalosporin such as cefazolin, or clindamycin or vancomycin for patients with penicillin allergies [3]. In cases of uncomplicated cellulitis, 5 days of antibiotic treatment is as effective as a 10-day course [14].

2.5. Erysipelas

Erysipelas is a well-demarcated, painful skin infection characterized by intense erythema. It is almost always caused by β -hemolytic streptococci. The term erysipelas is often used inconsistently and some physicians use it to describe simple cellulitis. The distinction between these two terms relates to the depth of inflammation; erysipelas affects the upper dermis, including the superficial lymphatics, whereas cellulitis involves the deeper dermis and subcutaneous fat. In practice however, distinguishing between cellulitis and erysipelas clinically may be difficult [3].

2.5.1. Clinical presentation

Erysipelas is distinguished clinically from other forms of cutaneous infection by the following two features: The lesions are raised above the level of the surrounding skin, and there is a clear line of demarcation between involved and uninvolved tissue [15]. (Figure 7)

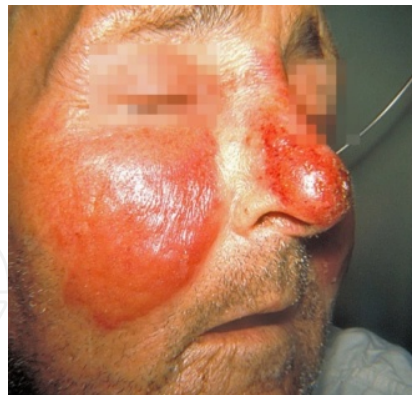

Figure 7. Facial erysipelas.

The skin surface may resemble an orange peel because superficial cutaneous edema surrounds the hair follicles, which causes dimpling. Vesicles, bullae, and cutaneous hemorrhage in the form of petechiae or ecchymoses may develop. Systemic manifestations like fever, tachycardia, hypotension, and leukocytosis may occur, even before the skin abnormalities appear. In older textbooks, pictures of erysipelas of the face characteristically involved the butterfly area, which is nowadays rarely seen.

2.5.2. Treatment

The first-line treatment of erysipelas is intravenous benzyl-penicillin. In penicillin allergic patients, clindamycin may be used. Anti-staphylococcal drugs are considered if patients fail to improve or have features suggestive of staphylococcal infection like bullous eruptions [1].

2.6. Craniofacial necrotizing fasciitis

Necrotizing fasciitis (NF) is rapidly progressing bacterial infection spreading along the deep fascial planes with relative sparing of skin and underlying muscles [16]. Necrotizing infection may involve any combination of dermis, subcutaneous tissue, fascia or muscle. Blood supply to the fascia is typically more tenuous than that of muscle or healthy skin, making the fascia more vulnerable to infectious processes. Additionally, the propensity for fluid collection between involved fascia and adjacent tissues further weakens fascial immune protection [9]. The incidence of NF increases with age and most adult cases occur in patients with underlying chronic illness like diabetes, alcohol/drug abuse, immunosuppression, malignancy or chronic systemic diseases. Most patients with NF have polymicrobial infections with an average of 4.4 organisms isolated per infection [17,18]. Although these polymicrobial infections can spread widely and become life-threatening, they tend to be less aggressive than infections caused by a limited number of highly virulent pathogens. These may cause very rapidly spreading necrotizing infections in an immunologically intact host through production of exotoxins. Such pathogens most commonly include *S. pyogenes* (group A hemolytic streptococcus), group B streptococcus, community acquired MRSA, and *Clostridium spp* [9]. Involvement of the head and neck is rare. Only 67 cases were reported between 1945 and 1990. Recently, increased awareness of the condition resulted in more reports of cervico-facial NF appearing in the literature. Cervico-facial NF can be divided into two groups: cervical and craniofacial. Cervical NF is characterized more frequently by polybacterial etiology, mainly odontogenic source of infection, predominance of males and higher mortality. Craniofacial NF does not have gender preference, has lower mortality, but cosmetic and functional consequences are often severe.

2.6.1. Clinical presentation

Craniofacial NF predominantly originates from periorbital regions; only one microorganism is usually identified from cultures, most commonly group A hemolytic streptococci. Initial symptoms may resemble simple cellulitis or erysipelas. The distinguishing features are fast progression, pain disproportionate to clinical findings, systemic toxicity and presence of gas. Gas is best detected by CT scan. Fully developed specific clinical picture includes edema that extends beyond skin erythema, cutaneous anesthesia, skin ecchymosis that precedes skin necrosis and presence of bullae [8].

2.6.2. Treatment

The promptness of initial surgical debridement is considered decisive for favorable outcome [19,20]. Patients treated surgically on the day of admission have distinctively better progno-

sis. The early incision and debridement of all involved spaces can salvage the skin, which later in the progress of disease succumbs to necrosis due to thrombosis of feeding vessels. All necrotic tissues should be excised, the defects should be kept open and debridement should be repeated until a completely healthy granulating wound is obtained. While the surgical treatment should be performed promptly, it cannot be as aggressive as in the extremities and trunk, where large areas of skin and subcutaneous tissue are often sacrificed. It is necessary to preserve as much of the anatomic structures as possible to avoid significant cosmetic disfigurement and functional limitations. Simultaneous immediate antibiotic therapy should consist of high-dose penicillin G or ceftriaxone in addition to metronidazole and clindamycin for anaerobic coverage. Clindamycin is a potent suppressor of bacterial toxin synthesis, facilitates phagocytosis of *S. pyogenes* by inhibiting M-protein synthesis and causes suppression of lipopolysaccharide-induced monocyte synthesis of TNF- α [21]. Numerous recent published reports claim substantial reduction in mortality and length of hospital stay when hyperbaric oxygenotherapy is used as adjunctive treatment [22].

3. Infected tissue fillers

Injectable soft tissue fillers (ISTFs) are widely popular in facial rejuvenation. ISTFs are usually injected into the deep dermis or dermal – subdermal junction for wrinkles, skin creases or depressed scars [23]. Recently there is a tendency to more frequent use of fillers injected into deep subcutaneous layers for augmentation [24]. ISTFs are effective in treating volume loss and soft tissue redistribution [25].

3.1. Tissue fillers

All ISTFs with exception of autologous fat are foreign alloplasts. Host tissue response to their presence depends on material type [26]. They can be differentiated as volumetric and structural, or fibroplastic, based on the biomechanics of filling effect [27]. Another practically important property is their time of tissue survival differentiating them into temporary, long lasting or semi-permanent and permanent (Table 1).

The most commonly used ISTFs are homogenous polymer gels, both degradable and nondegradable. They are volumetric; the filling effect stems from the gel itself. Common representatives of *degradable homogenous ISTFs* are hyaluronic acid and collagen. They are hydrophilic and closely resemble substances normally present in tissues. Both are degraded by naturally occurring enzymes. *Nondegradable homogenous ISTFs* are represented by polyacrylamide hydrogel and silicone gel. Polyacrylamide gel is hydrophilic, consisting of polyacrylamide, to which water molecules are loosely attached. These water molecules are readily exchanged with those of the surrounding tissue. The macrophages enter the gel, become transformed into fibroblasts that connect and eventually form a vascular fibrous network. Polyacrylamide hydrogel is widely resistant to degradation and phagocytosis [26]. Silicone gel differs from the other polymer gels by being hydrophobic, which results in dispersion in the tissue in the form of rounded vacuoles or droplets, which do not interact with the host

tissue. However they stimulate response of macrophages and foreign body giant cells and are frequently seen within these cells as small round inclusions. *Combination or structural ISTFs* are composed of two components: Solid microparticles dissolved in a transient carrier gel. Microparticles remain in the tissue after the carrier gel has been degraded and thus, elicit a foreign-body reaction, which results in fibrosis responsible for the final filling effect. Some of the microparticles are nondegradable and add to the resulting filling effect, others are slowly degraded over a period of several years [26].

Category	Brand name	Description	Duration
Collagen	Zyderm	Highly purified bovine dermal collagen in a phosphate-buffered physiological saline containing 0.3% lidocaine	2-4 months
	Zyplast	Highly purified bovine dermal collagen cross-linked with glutaraldehyde in a phosphate-buffered physiological saline containing 0.3% lidocaine	3-6 months
	Cosmoderm	Highly purified human-based collagen in a phosphate-buffered physiological saline containing 0.3% lidocaine	3-6 months
	Cosmoplast	Highly purified human-based collagen cross-linked with glutaraldehyde in a phosphate-buffered physiological saline containing 0.3% lidocaine	3-4 months
HA derivatives	Hylaform	HA of rooster combs, 500µ particles, 20 % cross-linked	3-6 months
	Restylane	HA from <i>S. equi</i> , cross-linked with BDDE; NASHA; 400 µ gel particles, 1% cross-linked	6 months
	Perlane	HA from <i>S. equi</i> , cross-linked with BDDE; NASHA; 940-1090 µ gel particles	6-12 month
	Juvederm	HA from <i>S. equi</i> cross-linked with BDDE in homogenized gel	3-6 months
	Prevelle Silk	HA from <i>S. equi</i> cross-linked with 0.3% lidocaine in homogenized gel	2-3 months
CHA derivatives	Radiesse	CHA microspheres 25-45 µ in a gel of water, glycerin, and sodium carboxymethylcellulose	1-2 years
PLL derivatives	Sculptra	Poly-L-lactic acid mixed with mannitol and sodium carboxymethylcellulose	1-2 years
PMM derivatives	Artefill	PMM microspheres 30-50 µ in water-based gel of 3.5% bovine collagen, 0.3% lidocaine, phosphate buffer, and 0.9% NaC	Permanent
Silicone	Silikon 1000	Purified polydimethylsiloxane	Permanent
Hydrogels	Aquamid	97.5% apyrogenic water and 2.5% polyacrylamide	Permanent
	Bio-Alcamid	96% apyrogenic water and 4% polyalkylimide	Permanent
Autogenous fat	-	Hand –held syringe aspirate, usually from hips or abdomen, sedimented or centrifuged	Semi-permanent

Table 1. Overview of ISTFs. HA = hyaluronic acid, CHA = Calcium hydroxylapatite, BDDE = butanediol diglycidyl ether, NASHA = nonanimal stabilized hyaluronic acid, PLL = Poly-L-lactic acid, PMM = polymethylmetacrylate

3.2. Complications of tissue fillers

Complications can be attributed to the product properties, method of delivery and reaction of the recipient's immune system. It is convenient to divide complications according to the time of onset. *Immediate complications* are usually related to faulty application. They include palpable or visible implants due to superficial injection, uneven distribution, overcorrection, undercorrection and hypersensitivity. The most serious immediate complication is vascular compromise by mechanism of either direct arterial embolization of filler or local overfilling leading to venous compression in the treated area [28]. *Early onset complications* appear between 2 – 3 days or weeks after injection. Early non-inflammatory nodules are localized accumulations of filler material. Early inflammatory nodules are red, painful and should be treated as infections. If there is any fluctuation or impending skin erosion, incision and drainage with culture should be performed. Empiric antibiotic treatment should begin with a macrolide or tetracycline and should be continued for 4 to 6 weeks [29]. *Late* (several weeks to 1 year) *or delayed* (>1 year) *complications* usually present as nodules or subdermal masses. Stimulatory fillers such as polylactic acid and calcium hydroxylapatite, or silicone may give rise to fibrotic nodules. Immune response to filler material or chronic infection can lead to formation of granulomas [30-34]. They should be treated as foreign body infections with macrolide or tetracycline, and strong consideration should be given to two-drug therapy. If there is no response in 7 to 10 days, intralesional corticosteroids can be injected while maintaining the patient on oral antibiotics [29]. Infrequent but the most serious late complications of ISTF present themselves as acute facial cellulitis or abscess.

3.3. Role of biofilms

Delayed complications of ISTFs have been attributed to biofilms [35]. Biofilms are defined as a structured community of microorganisms encapsulated within a self-developed polymeric matrix and irreversibly adherent to a living or inert surface [36]. They are also often characterized by structural heterogeneity, genetic diversity and complex community interactions. They respond to stimuli, grow and maintain a homeostatic environment. Extracellular polymeric matrix of biofilms may interfere with macrophage phagocytosis and allow for easier exchange of extrachromosomal DNA plasmids encoding antimicrobial resistance. All surgical implants like orthopedic appliances, heart valves, indwelling catheters, stents or other forms of foreign material may be compromised by biofilms. Active clinical infections can flare up weeks, months and even years after initial surgery. Bacteremia caused by dental treatment, contaminated surgery, or trauma can activate infective response of a chronic biofilm. Once the biofilm has been activated, it leads to acute purulent infection. The active infection can be controlled with antibiotic therapy, but the underlying biofilm can persist and generate a recurrence [27,37,38]. The biofilm theory remains a popular explanation for late infectious complications of ISTFs; but it has been recently challenged and requires further proof [39].

3.4. Clinical presentation and diagnosis

Acute purulent inflammation caused by infected facial ISTF closely resembles acute odontogenic infection: it causes painful facial swelling, redness, extensive collateral edema and palpable in-depth fluctuation. Deep buccal space and periorbital region are most frequently involved. The general condition is usually altered by fever, malaise and pain. Laboratory sings of acute bacterial infection are present. However, intraoral clinical and x-ray examination fails to discover an odontogenic source of infection, and even if possible odontogenic infectious focus is identified, typical signs of acute odontogenic infection, such as oral vestibule swelling and redness, tooth mobility, or sensitivity to axial percussion are missing [40]. (Figure 8)

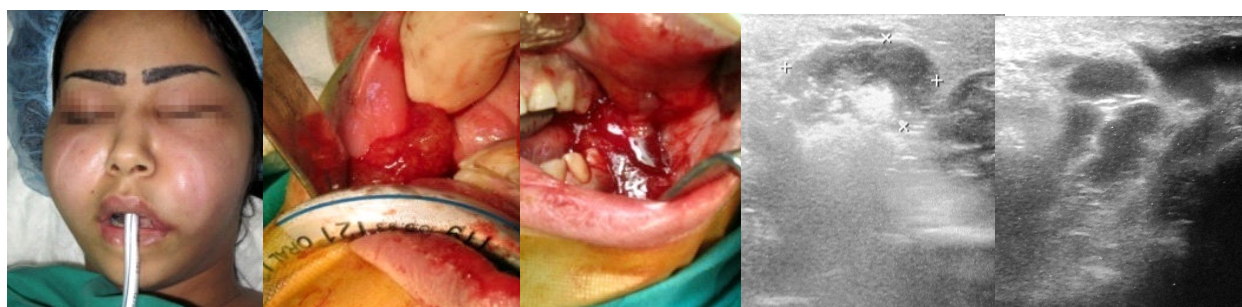

Figure 8. A. 32y old female underwent cheek augmentation by injections of unknown substance in a cosmetic salon 3 years earlier. One week before admission she underwent another injection in periorbital areas. B. Foreign glue-like material with blood admixture drained from the right buccal space. C. Large amount of foreign material mixed with sanguinopurulent exudate drained from the left buccal space. D. Sonography (US) of left cheek. E. US of right cheek; note hypoechoogenic loci with scattered hyperechogenic foci of foreign material in the subcutaneous layer.

Many patients fail to report filler injections on initial interview because they do not consider them as medical procedures or are embarrassed [41,42]. Patients with acute facial infections of uncertain origin should therefore be specifically questioned about a history of cosmetic procedures. Despite of it, some patients will admit application of ISTF only later, when they are confronted with finding of foreign material in a drained exudate. Ultrasound (US) examination can be helpful in establishing the presence of ISTF and its precise location [41,42]. CT imaging may be indicated if there is a suspicion of infection spread, especially orbital cellulitis.

3.4.1. Treatment

Treatment should follow established principles of dealing with acute purulent infection i.e. eliminate source of infection, drain involved anatomical spaces and provide antibiotic and supportive therapy. When ISTF becomes infected, antibiotic treatment can only mitigate the process and sooner or later after discontinuation of medication recurrence is inevitable. It is therefore necessary to remove all infected material, which is usually identical with drainage of involved spaces. Only small amounts of ISTFs can be removed by aspiration [43], thus in cases of deep abscesses incision and drainage is the treatment of choice. To avoid facial scar-

ring, intraoral incision is the preferred route. More than one deposit of filler material can be present in any treated area and while one focus is drained another one can remain dormant and consequently undetected on clinical examination. This can lead to recurrence [40]. Characteristic histopathologic findings allow the identification of the specific filler agent. This can be important especially in litigation cases where a number of different fillers have been injected in the same site over the time, or where patients had not been correctly informed about fillers and potential risks [44].

4. Cervico-facial lymphadenitis

A disease process involving lymph nodes (LNs) is referred to as lymphadenopathy. Lymphadenopathies have multiple etiologies, the most common of which are infection, neoplasia and autoimmune diseases. Inflammation of LN is known as lymphadenitis. The lymphatic system of the cervicofacial region serves as the initial line of defense against infections of all structures within the head, neck, and upper respiratory tract [45].

4.1. Anatomy and pathophysiology

Diagnosis of the lymphatic infections must be based on the knowledge of anatomic location of LNs, the area and the pattern of lymphatic drainage, and their defense mechanism [45,46]. The lymphatic system of the head and neck contains about 300 nodes, and the extranodal lymphatics of the palatine, pharyngeal and lingual tonsils are known as the lymphatic ring of Waldeyer. All the lymphatics from the head and neck drain into the deep cervical LNs [47]. Superficial nodal enlargement usually reflects invasion through an epithelial surface (e.g. skin, oral mucosa), whereas deep nodal enlargement results from an infectious process involving more central structures (e.g. middle ear, posterior pharynx). [45] Lymph nodes contain T- and B-lymphocytes as well as antigen-presenting macrophages (dendritic cells). Tissue lymph enters the LN via one or more afferent vessels and percolates through a series of reticuloendothelial-lined channels that coalesce and drain through an efferent lymphatic vessel. [45] Once infection occurs, a series of LN reactions follow according to the type and nature of the infectious agent. These will result into signs and symptoms with presentation, which can be acute, subacute, or chronic and can be localized or generalized. Infection of the LNs of the orofacial region can be bacterial, viral, protozoal or fungal. The most common pathogens causing lymphadenitis in the orofacial region include bacterial pathogens as *S. aureus*, *S. pyogenes*, *Bartonella Henselae*, *Francisella tularensis*, *Treponema pallidum*, as well as tuberculous and non-tuberculous *Mycobacteria*. Many cases of cervical adenopathy associated with viral illnesses are due to reactive hyperplasia. Causes of the associated upper respiratory tract infection include rhinovirus, parainfluenza virus, influenza virus, respiratory syncytial virus, coronavirus, adenovirus, and rheovirus. Other common viral etiologies include cytomegalovirus and Epstein-Barr virus. Less frequent etiologies include mumps, measles, rubella, varicella, herpes simplex, human herpes virus 6 (roseola), and coxsackie viruses. Approximately 10% of patients with acquired infections due to *Toxo-*

plasma gondii also present with cervical lymphonoditis. Fungal infections of orofacial LNs are mentioned later.

4.2. Acute bacterial lymphadenitis

Most cases of acute bacterial lymphadenitis occurs in children aged 1 to 4 years. Forty percent to 80% of cases in this age group are due to *S. aureus* or *Strep. pyogenes*. Lymphadenitis due to *Strep. pyogenes* should be suspected if the patient presents with the typical vesicular, pustular, or crusted lesions of impetigo involving the face or scalp. The most commonly involved LNs in decreasing order of frequency are the submandibular, upper cervical, submental, occipital, and lower cervical nodes. [45]

4.2.1. Clinical presentation and diagnosis

Patients typically present with concomitant pharyngitis, tonsillitis, acute otitis media, or impetigo. Acute cervical lymphadenitis can also occur following animal bites or scratches. However, there may be a time gap between initial infection at the site of entry and lymphadenitis. LNs enlargement is mostly unilateral, associated with systemic manifestations, such as fever, and malaise. Infected LNs tend to be quite tender with collateral cellulitis and edema. Erythema and increased temperature of the overlying skin are signs of impending liquefaction. Diagnosis is usually based on the clinical picture. Laboratory tests are nonspecific and seldom required. In contrast, laboratory evaluation plays a crucial role in determining the etiology of subacute, chronic, and generalized lymphadenopathy.

4.2.2. Treatment

Because staphylococci and streptococci are the most common pathogens, initial therapy usually includes a β -lactamase resistant antibiotic; this agent is used because of the high incidence of penicillin resistance in isolated staphylococci. Other treatment options include cephalexin, oxacillin, or clindamycin. Very young patients or patients with severe symptoms may require hospitalization for initiation of parenteral antibiotic therapy and close observation. For older patients with dental or periodontal disease, the antibiotic regimen should include coverage for anaerobic oral flora (i.e., penicillin V or clindamycin). Reports from multiple centers have documented an increasing frequency of community-acquired methicillin-resistant *S. aureus* (CA-MRSA) skin and soft tissue infections, including lymphadenitis. Failure to respond to appropriate first-line antibiotic therapy should prompt consideration of expanding coverage to include methicillin-resistant strains of *S. aureus*. [45] Therapy is usually administered for 10 days and continued for at least 5 days beyond resolution of acute signs and symptoms. If a primary site is identified, cultures should be obtained and treatment directed to that site as well. There should be marked clinical improvement after 2 to 3 days of therapy, although complete resolution of nodal enlargement may require several weeks [45]. If there is no response to conservative therapy, an attempt to identify etiologic agent can be done by fine needle aspiration (FNA) under US control. The aspiration of an affected node is successful in 60% to 88% of cases [46]. Fluctuance develops in about 25% of patients. Adequate drainage should be ascertained by incision under GA and no loculations

or pockets of pus left behind. Specimens of pus should be sent for Gram stain, aerobic and anaerobic cultures, as well as for acid-fast stains and mycobacterial culture. In immunocompromised patients also KOH preparation, fungal cultures and tissue biopsy should be considered. (Figure 9)

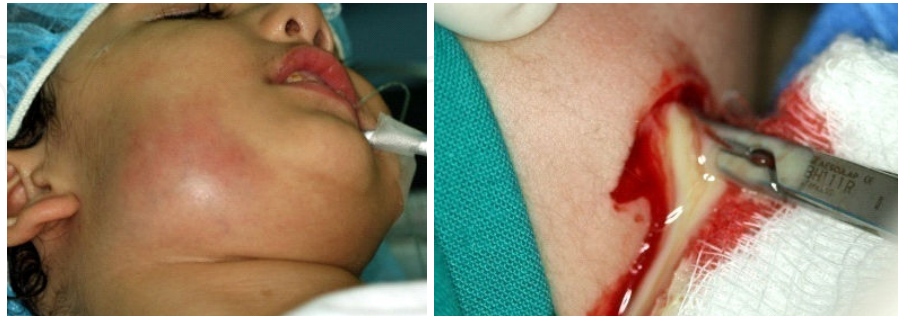

Figure 9. A. Abscessed submandibular lymph node in 4y old boy with a 10-day history of submandibular swelling treated by amoxicillin. Infection source was not indentified. B. Culture of drained pus yielded *S. aureus*.

Drainage should be maintained by insertion of drains (e.g. Penrose or corrugated rubber drain), left in place for 2-3 days. Dressings are changed whenever it becomes saturated by exudate. Antibiotic therapy can be discontinued as soon as clinical improvement is obvious.

4.3. Cat scratch disease

Cat scratch disease (CSD) follows inoculation of *Bartonella Henselae* through broken skin or mucous membranes. *B. Henselae* is a small, pleomorphic gram negative bacillus. The reservoir for *B. Henselae* is the domestic cat and 1/3 of cats or more are infected. Cat fleas become infected and replicate *B. Henselae* following ingestion of blood from an infected cat. Experimentally, *B. Henselae* was transmitted by transferring fleas from bacteremic cats to specific pathogen-free cats. In another experiment, cats have been infected with *B. henselae* by intra-dermal inoculation of feces derived from infected fleas. Although the exact mode of transmission of *B. henselae* to humans remains unclear, contamination of the claws or teeth with infected flea feces may be required for transmission. [47]

4.3.1. Clinical presentation and diagnosis

CSD presents as regional lymphadenitis associated with a characteristic skin lesion at the site of inoculation. An erythematous skin papule or pustule typically develops 3-10 days after contact with an infected cat (scratch, bite or lick). The patient may suffer low-grade fever and malaise, anorexia, headache and splenomegaly. Regional lymphadenitis develops 5 days to 2 months later. Often the primary site of involvement has resolved by the time lymphadenopathy is noted. The most common sites of lymphadenopathy are the axilla (52%) and the neck (28%). Patients usually present with a single large tender node. Involved LNs undergo sequential changes of lymphoid hyperplasia, granuloma formation, microabscess development, and in some cases suppuration. The most common atypical presentation of

CSD is Parinaud's oculoglandular syndrome (POS). This occurs in up to 17% of CSD patients due to autoinoculation of the eye by rubbing it with their hands after cat contact. POS is manifested either as conjunctivitis with parotid swelling caused by intraparotid lymphadenitis or as an ocular granuloma. Diagnosis of CSD has traditionally required the presence of 3 of 4 criteria: Contact with a cat resulting in a primary lesion, regional lymphadenopathy in the absence of other causes of lymphadenopathy, a positive skin test, and the presence of characteristic histopathological features. The CSD skin test is performed by intradermal injection of heat-inactivated material obtained from a node of a patient fulfilling the diagnostic criteria of the disease. Because of safety concerns about the use of human-derived reagents and the lack of widespread availability, serologic testing for antibodies to *B. henselae* is considered a suitable alternative to skin testing. Aspirate from lymph node contains no bacteria that can be cultured by routine methods. Isolation of *Bartonella* is typically time-consuming, often requiring a 2- to 6-week or longer incubation for primary isolation. The resulting isolate must then be identified by biochemical or genetic methods. [48]

4.3.2. Treatment

The disease is usually self-limited. Treatment is mainly supportive, with reassurance, hot moist compresses and analgesics. It may be necessary to aspirate pus or surgically remove an excessively large lymph node. Benefits of antibiotic therapy is doubtful. Azithromycin has been shown to be associated with more rapid resolution of nodal enlargement. Tetracycline or erythromycin therapy may also be helpful. [49]

4.4. Tularemia

Tularemia is a highly contagious disease caused by *Francisella tularensis*, a fastidious gram-negative coccobacillus, characteristically isolated as small, poorly staining gram-negative rods seen mostly as single cells. *Francisella tularensis* is maintained in the environment by various terrestrial and aquatic mammals such as ground squirrels, rabbits, hares, voles, muskrats, water rats, and other rodents. In many parts of the world, the disease caused by *F. tularensis* is known under colloquial names such as rabbit fever, hare fever, deerfly fever, and lemming fever. A wide range of arthropod vectors have been implicated in the transmission of tularemia between mammalian hosts, specially ticks, biting flies and mosquitoes. [51]

4.4.1. Clinical presentation and diagnosis

Tularemia in humans can occur in several forms, depending to a large extent on the route of entry. Many cases of disease caused by lower-virulence strains are undiagnosed. The most common form of the disease is ulceroglandular tularemia, which usually occurs as a consequence of a bite from an infected arthropod vector. After an incubation period of 3 to 5 days, the patient experiences the sudden onset of flu-like symptoms, especially chills, fever, headache, and generalized aches. An ulcer forms at the site of infection. Bacteria are disseminated from this site via the lymphatic system to regional LNs. The enlargement of these LNs often resembles the classical bubo associated with bubonic plague. During early bacteremic

phase of the infectious bacteria may be disseminated also to other tissues such as the spleen, liver, lungs, kidneys, intestine, central nervous system, and skeletal muscles. A rare variation of ulcero-glandular disease is oculo-glandular tularemia, where the conjunctiva is the initial site of infection, usually as a result of the transfer of bacteria on the fingertips. The disease is marked by the appearance of ulcers and nodules on the conjunctiva, and without treatment the infection spreads to the regional LNs. The ingestion of infected food or of bacteria in drinking water can result in oropharyngeal tularemia, characterized by sore throat with enlargement of the tonsils and the formation of a yellow-white pseudo membrane, accompanied by swollen cervical LNs. Other, more serious clinical forms of disease are gastrointestinal and pneumonic tularemia. Isolation of bacteria from clinical specimens is possible; however, it needs a special culturing technique. Because of the difficulty in culturing *F. tularensis*, most cases of tularemia are diagnosed on the basis of clinical picture and/or serology. The detection of serum antibodies is most frequently achieved by agglutination or an ELISA. [51]

4.4.2. Treatment

The drugs of choice for the treatment of tularemia include streptomycin, gentamicin and ciprofloxacin. Ciprofloxacin was the antibiotic with the lowest level of therapeutic failure and with the fewest side effects and was also shown to be suitable for children and in a case where relapse was evident after initial gentamicin therapy [52].

4.5. Syphilis

Syphilis is a sexually transmitted disease caused by infection with *Treponema pallidum*, a Gram-negative bacterium, which is an obligate internal parasite of spiral shape. Natural infection with *T. pallidum* is limited to the human host and is usually transmitted by sexual contact; the infectious lesion is on the skin or mucous membrane. *Treponema pallidum* rapidly penetrates intact mucous membranes or microscopic dermal abrasions and, within a few hours, enters the lymphatics and blood to produce systemic infection. The disease progresses in a series of overlapping stages: primary, secondary, latent, and tertiary. Disease transmission between mother and child in utero results in congenital syphilis. [53]

4.5.1. Clinical presentation and diagnosis

Incubation time from exposure to development of primary lesions at the site of inoculation averages 3 weeks but can range from 10-90 days. A papule develops at the site of infection and breaks down to form an ulcer - chancre. The lesion is usually singular, painless, with base infiltration and hardened high margins. After the appearance of the chancre, regional lymphadenopathy occurs. Secondary syphilis develops about 4-10 weeks after the appearance of the primary lesion. Systemic manifestations include malaise, fever, myalgias, arthralgias, lymphadenopathy, and rash. Widespread mucocutaneous lesions are observed over the entire body and may involve the palms, soles, and oral mucosa. The skin lesions are usually macular, discrete, reddish brown, and 5 mm or smaller in diameter; however, they can be pustular, annular, or scaling. The two principal oral lesions associated with secondary

syphilis are mucous patches and maculopapular lesions involving the hard palate and manifesting as flat to slightly raised firm red lesions. Of these, wet mucous patches are the most contagious. Even untreated the patient will eventually lose infectivity and pass into latent stage. Tertiary syphilis develops 4-8 years later with progressive multi-organ involvement. The typical tertiary stage lesion is gumma, which in orofacial regions usually involves the hard palate and tongue. [54,55] Regardless of the stage of disease and location of lesions, histopathologic hallmarks of syphilis include endarteritis and a plasma cell rich infiltrate. However, lesional histopathology is not diagnostic. Definitive diagnostic methods are dark field examination and direct immunofluorescent tests of lesional exudates that detect presence of *Treponemata*, but are applicable only in presence of primary or secondary lesions. Diagnosis is commonly made by serologic testing; however, no one test is sufficient in itself. The most commonly used screening tests are the Rapid Plasma Reagin (RPR) and the Venereal Disease Research Laboratory (VDRL). These are non-specific, non-treponemal tests that use reagin, cardiolipin-lecithin-cholesterol antigens to test for antibodies against *T. pallidum*. The most specific serologic tests for syphilis are the fluorescent treponemal antibody absorbed assay (FTA.Abs) and the microhemagglutination essay for antibody to *T. pallidum* (MHA-TP). These detect antibodies that are produced against treponemal antigens. [54]

4.5.2. Treatment

Parenteral penicillin G is the drug of choice for all stages of syphilis. Selection of the appropriate penicillin preparation is important, because *T. pallidum* can reside in sequestered sites like CNS and aqueous humor that are poorly accessed by some forms of penicillin. Penicillin desensitization may be used in patients with known penicillin allergies if necessary. The Jarisch-Herxheimer reaction is an acute febrile reaction frequently accompanied by headache, myalgia, fever, and other symptoms that usually occur within the first 24 hours after the initiation of any therapy for syphilis. Patients should be informed about this possible adverse reaction. [56] Studies on the efficacy of ceftriaxone and azithromycin as an alternative for the treatment of syphilis in penicillin allergic patients are presently inconclusive, and Center for Disease Control (CDC) guidelines neither support nor refute its use. [53]

4.6. Infectious mononucleosis

Infectious mononucleosis (IM), a common cause of cervical lymphadenitis, is caused by Epstein-Barr virus (EBV), and is its most frequent clinical manifestation. IM is called also "glandular fever". EBV is ubiquitous herpes virus associated with nasopharyngeal carcinoma, Burkitt's lymphoma, Hodgkin's disease, and other lymphoproliferative disorders in immune-deficient individuals. Young children most likely acquire primary EBV infection from close contact that involves exchange of oral secretions via shared items such as toys, bottles, and utensils. Before the age of 10, primary infection is usually asymptomatic or produces an acute illness that is often not recognized as being due to EBV. In adolescents and young adults, primary EBV infection is acquired chiefly by direct intimate oral contact which allows for salivary exchange, and frequently presents as IM. That is where another colloquial name "kissing disease" comes from. Aside from oral transmission, there are reports about

transmission by sexual intercourse, contaminated blood, transplanted hematopoietic cells, solid organs, or by intrauterine transmission. [57]

4.6.1. *Clinical presentation and diagnosis*

Infectious mononucleosis most often begins insidiously, with vague malaise, followed several days later by fever, fatigue, sore throat, and swollen posterior cervical lymph nodes. Some patients experience an abrupt influenza-like onset, with fever, chills, and body aches. Hepatitis, documented by abnormal liver function tests, is seen in 80% of cases. A useful clinical clue unique to primary EBV infection is eyelid edema, which gives the patient a slit-eyed appearance and may be accompanied by facial puffiness. Virtually all patients given penicillin derivatives develop a rash. Complications include conjunctivitis, hemophagocytic syndrome, myocarditis, neurologic diseases other than meningoencephalitis, pancreatitis, parotitis, pericarditis, pneumonitis, psychological disorders, and splenic rupture. [57] The diagnosis of infectious mononucleosis cannot be made on clinical grounds alone. The appropriate laboratory tests include detection of the presence of atypical lymphocytes, Paul-Bunnell test, monospot test, and detection of EBV antibodies against the viral capsid.

4.6.2. *Treatment*

The treatment is mainly symptomatic during periods of fever and malaise and includes limitation of activities, supplementation fluids, nutrition, antipyretics and analgesics. Corticosteroids are indicated for management of complications, such as impending airway obstruction, autoimmune anemia, and autoimmune thrombocytopenia. A number of antiviral drugs have been also used with varying degree of efficiency. [58]

4.7. Rubella

Rubella is an acute febrile illness of viral origin characterized by rash and lymphadenopathy that affects children and young adults. *Rubella virus* is a member of the *Togaviridae* family but in spite of that, it is not transmitted by arthropods. The usual way of transmission is by droplets from the nose or throat. Rubella is commonly known as German measles or 3-day measles. [59] Infection during the early pregnancy may result in serious congenital malformations and mental disability. Widespread immunization against rubella is critical to preventing this so called congenital rubella syndrome. [60]

4.7.1. *Clinical presentation and diagnosis*

Rubella infection begins with low grade fever and swollen, tender lymph nodes, usually in the back of the neck or behind the ears. Morbilliform rash appears on the face and spreads downward to the trunk and extremities. As it spreads down, it usually clears on the face. This rash is often the first sign of illness that a patient or a parent notices. No feature of the rash is pathognomic and it looks like many other viral rashes. Other symptoms of rubella, more common in teens and adults, include headache, loss of appetite, mild conjunctivitis with rhinitis, swollen lymph nodes in other parts of the body, and arthralgia. A clinical diag-

nosis of rubella may be difficult, because many exanthematic diseases may mimic rubella infection. The laboratory diagnosis of rubella can be made either through serologic testing or by viral culture. The serologic diagnosis consists of demonstrating the presence of rubella-specific IgM antibody in a single serum sample or observation of a significant (>4-fold) rise in rubella-specific IgG antibody titers between the acute and convalescent serum specimens drawn 2-3 weeks apart. The nasopharyngeal or throat swab taken 6 days before and after onset of rash is a good source of rubella virus that can be cultured and identified. [59]

4.7.2. Treatment

Rubella is mild self-limited illness and no specific treatment is indicated. Maintenance of good hydration, especially replacement of fluids lost through diarrhea or emesis, is the mainstay of management. Intravenous rehydration may be necessary if dehydration is severe. In children and patients with clinical signs of vitamin A deficiency vitamin A supplementation should be considered. Post exposure prophylaxis should be considered in unvaccinated contacts. [59]

4.8. Toxoplasmosis

Toxoplasma gondii is a coccidian protozoan of worldwide distribution that can infect a wide range of animals, birds as well as humans. The cat was identified as the definitive host; however *T. gondii* is unusual in that its propagation does not require passage through the definitive host (felids in whose intestinal tissues the sexual cycle occurs). About 1/3 of the world's human population is estimated to be infected. Humans can be infected from tissue cyst present in raw or undercooked meat, or from oocysts that are the product of sexual cycle in cat intestines. Oocysts are very resistant to harsh environmental conditions and are highly infectious. [61] Avoidance of cats during pregnancy is essential, because of the risk of transmission to the fetus with serious consequences, especially when transmission occurs in early pregnancy.

4.8.1. Clinical presentation and diagnosis

Primary infection in the immunocompetent individual is usually asymptomatic. In approximately 10% of this patient group, a non-specific and self-limiting illness is manifested most typically by isolated cervical or occipital lymphadenopathy lasting for less than four to six weeks. Toxoplasmic lymphadenitis most frequently involves a solitary lymph node without systemic symptoms or extranodal disease. The lymph nodes are usually discrete, non-tender, and do not suppurate. Toxoplasmosis can also cause localized lymphadenopathy outside the head and neck areas or generalized lymphadenopathy. After the acute phase, almost all patients will remain chronically infected with tissue cysts that are dormant and cause no clinical symptoms. In contrast, toxoplasmosis in patients who are immunocompromised can be a life-threatening infection. In an immune-deficient patient, the infection can become acutely disseminated and result in pneumonitis, chorioretinitis and encephalitis. [62,63] Toxoplasmic lymphadenitis is most often diagnosed by lymph node biopsy and/or serological assays. Pathological features diagnostic of toxoplasmic lymphadenitis include a re-

active follicular hyperplasia, irregular clusters of epithelioid histiocytes encroaching on and blurring the margins of the germinal centers, and focal distention of sinuses with monocy-toid cells. The presence of these histological abnormalities alone, when typical, can suffice for the diagnosis. However, to increase the diagnostic yield, serological testing (ELISA, PCR, and IFA) is recommended both in patients with the classical histological features and in those patients with atypical histological findings. Fine needle aspiration cytology (FNAC) is rarely useful for the diagnosis, since it allows visualization of only a few isolated cells and does not permit the evaluation of lymph node architecture. *Toxoplasma gondii* may be cul-tured in the presence of living cells where the typical intracellular and extracellular organ-ism can be seen. [63]

4.8.2. Treatment

Acute infection can be treated with a combination of pyrimethamine and sulfadiazine or tri-sulfapyrimidines. Treatment with pyrimethamine, sulfadiazine and folinic acid is usually re-served for patients who are immunocompromised and those patients who are immunocompetent but have severe or persistent symptoms. Duration of treatment varies from 2-4 months depending upon resolution of clinical signs and symptoms. Alternative drugs include spiramycin, clindamycin, trimethoprim-sulfamethoxazole and various other sulfonamide drugs. Spiramycin is recommended for use in pregnancy till delivery. [63]

5. Orofacial tuberculosis

Tuberculosis (TB) is chronic granulomatous infection caused by *Mycobacterium tuberculosis* or *Mycobacterium bovis*. TB is one of the most prevalent diseases in the world. In 2010, there were estimated 12 million prevalent cases (178 cases per 100 000 population) and 1.1 million deaths worldwide among human immunodeficiency virus (HIV) negative persons. Of the 8.8 million incident cases in 2010, 1.0 million – 1.2 million (12–14%) were among people liv-ing with HIV. Approximately 1.4 million people died of TB in 2010. TB is the second leading cause of death from an infectious disease worldwide, after HIV. Most of the estimated num-ber of cases in 2010 occurred in Asia (59%) and Africa (26%). The five countries with the largest number of incident cases were India, China, South Africa, Indonesia and Pakistan. The high incidence of TB in developing countries is associated with poor hygiene. [64] Pri-mary disease most commonly affects the lungs, with secondary infection to other organs and tissues, either by hematogenic or lymphatic spread, or by inoculation of infected spu-tum. Extrapulmonary TB (EPTB) constitutes 15% to 20% of all cases of TB among immuno-competent adults, and it accounts for more than 50% of the cases in HIV positive individuals. [65] The proportion of EPTB among all TB cases in different parts of the world has increasing tendency. [66] Most of the extrapulmonary TB infections are secondary. [65] Head and neck TB is responsible for nearly 10% of all extrapulmonary manifestations of the disease. [67] Primary infection of orofacial region can happen by droplet transmission from a TB patient and affect Waldeyer's ring, with secondary spread to lymphatic nodes. Lymph nodes of the neck can also be affected by spread from the pulmonary focus via hemato-ge-

nous or lymphatic routes [68]. TB cervical lymphadenitis seems to be the most frequent manifestation of EPTB in the maxillofacial region [68-71]. Oral mucosa TB is relatively uncommon. The intact oral mucosa acts as a natural barrier to the mycobacterial invasion because of its epithelial thickness, tissue antibodies, oral saprophytes, and salivary enzymes, as well as cleansing action of the saliva [72]. Oral primary or secondary infection is possible if natural barrier of healthy mucosa or skin is violated by pre-existing inflammatory process or trauma. Consumption of infected milk is thought to be an important source of infection of the oral cavity [68]. Secondary infection by direct inoculation from a pulmonary source to the larynx, oral cavity and nasopharynx is also possible. Some reports cite oral mucosa [73] or mandible and adjacent masticatory muscles [74] as the most frequent location of orofacial TB. Involvement of the temporomandibular joint (TMJ) has been repeatedly reported in recent years and is considered by some authors as frequently misdiagnosed condition [67,75-7]. Other infrequent head and neck locations reported have include the eye, ear, salivary glands, nose, thyroid, nasopharynx, retropharyngeal space and larynx [68,69,71].

5.1. Clinical presentation and diagnosis

Because of frequent absence of classic symptoms associated with pulmonary disease, such as fever, cough, weight loss, anorexia, and night sweats, diagnosing EPTB can be a clinical challenge [76]. In the neck, according to ENT literature, the posterior triangle nodes, upper jugular and supraclavicular nodes are most commonly involved [68-70]. Maxillofacial literature describes submandibular and submental nodes as the most often involved lymphatic nodes [73,74,78]. This discrepancy obviously reflects referral bias. Most patients present with an isolated discrete node or a collection of matted nodes. Fluctuant mass or draining sinuses are seen in less than 10% of cases [69,78-9] (Figure 10).

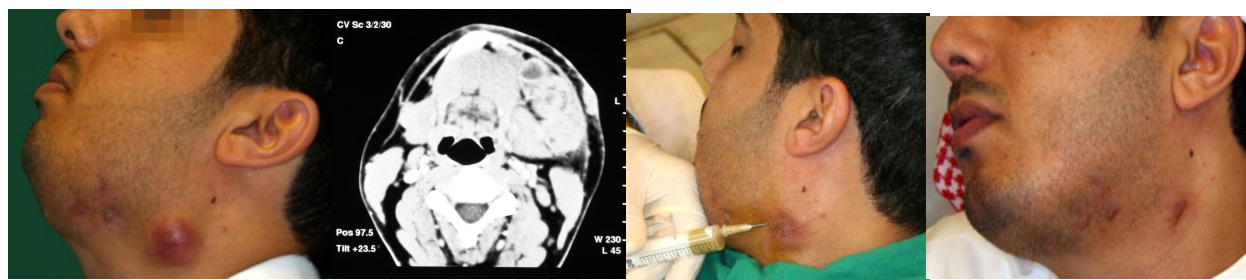


Figure 10. A. 35y old male presented with a 6-month history of lasting recurrent abscesses in the left submandibular area. He was repeatedly prescribed courses of antibiotics without success. B. CT examination revealed multiple enlarged lymphatic nodes with signs of liquefaction. C. Aspiration yielded several ml of pus, which was sent for microbiology examination. Culture results reported presence of *Mycobacterium tuberculosis*. D. After 6 months of combined chemotherapy with INH, rifampicin and ethambutol.

The most frequent locations of oral TB are tongue, vestibular buccal mucosa, gingiva, hard and soft palate. Sometimes the initial presentation can be non-healing extraction wound. Lesions of the oral cavity usually present as painful ulcer and thus mimic squamous cell carcinoma. Most TB lesions are located in the anterior portions of the oral cavity such as the

buccal mucosa or vestibule area near the corner of the mouth or lower lip; in contrast the usual location of oral squamous cell carcinoma is on the lateral border of the tongue and retromolar area [73]. Underlying bone can also get directly infected but TB osteomyelitis is probably more frequently due to hematogenic spread. The posterior mandible is more commonly involved, especially the ramus of the mandible and the attached musculature. Rich arterial supply of the masseter and medial pterygoid muscles can play important role as the lesions are frequently seen to involve the outer cortical plates, whereas the medullary bone is unaffected [74]. Tuberculosis of TMJ can be a hematogenic infection or develop by progression from TB otitis media [68,77]. Presenting clinical features are pain, trismus, and swelling. Thus, TMJ TB should be considered in the differential diagnosis of patients presenting with pain and stiffness of the joint [76]. Diagnostic process should begin with imaging methods depending on a location of the lesion: US and CT with contrast or MRI for neck lesions, panoramic X-ray and/or CT for facial bone lesions, MRI for evaluation of TMJ. Patients suspected of EPTB should have biopsy with acid fast smear, histopathology and culture of the lesion, chest radiograph, and sputum culture. While active pulmonary TB occurs infrequently in immunocompetent patients with EPTB, HIV seropositive patients with normal chest films can have active pulmonary TB. Mycobacterial sputum cultures should be performed in this group of patients regardless of chest film results [79]. FNAC is a minimally invasive diagnostic tool and has an established role in the diagnosis of EPTB, including oral lesions. It is easily performed and can be easily repeated. The complication rate following FNAC is small compared to surgical biopsy. Cytology smears should show the epithelioid granuloma with or without necrotic material. In patients with equivocal results on FNAC there may be need for open biopsy when the suspicion of TB is high. Granulomas with necrosis, which are more specific for TB, are more common in excisional biopsy specimens compared with FNAC specimens [79]. Patients with lymphatic EPTB show variable response to the tuberculin skin test [78]. The Mantoux test is positive in more than 90% cases of osteoarticular TB. However, a positive test may also indicate a hypersensitivity reaction to tuberculin proteins or a previous exposure rather, than active TB infection [76]. The diagnosis of TB in the absence of a positive culture requires a combination of epidemiologic and histopathologic criteria as well as a trial of antituberculous medication [79].

5.2. Treatment

Conservative therapy with anti-tuberculous drugs (isoniazid, rifampicin, pyrazinamide, ethambutol and streptomycin) is the mainstay of treatment. In majority of patients the therapy is started based on pathology results while waiting for culture results, which are not available before 3 weeks. Treatment duration is typically 6 months, and this duration has been shown to be as effective as regimens of 9–18 months. [79] Adjuvant surgical intervention can be necessary in cases of TB lymphadenitis with large, matted lymph nodes or fluctuant, cold abscesses in the neck. However, these nodes often lie adjacent to great vessels and, if due care is not exercised, injury to great vessels or incomplete excision of the nodes may occur. TB of the TMJ may require abscess drainage, sequestrectomy or even condylectomy. TB of the facial bones may require sequestrectomy and/or saucerization. TB of the saliva-

ry gland, oral cavity and ear respond very well to antituberculous therapy and do not require surgical management.

6. Atypical (non-tuberculous) mycobacteriosis

Nontuberculous mycobacteria (NTM) are ubiquitous organisms that typically reside in soil. They are facultative pathogens and their pathogenicity depends on the interaction between the microorganism and the host's immune system. About 90% of NTM infections involve the pulmonary system. Other frequent locations are lymph nodes, skin, soft tissues and bones. [80] Even less frequent are central nervous system disease, keratitis, and otitis media [81]. The most frequently isolated species is *Mycobacterium avium* and *M. intracellulare* (known together as *M. avium-intracellulare* complex), followed by *M. scrofulaceum*, *M. kansasii*, *M. malmoense*, and *M. hemophilum*. However, a growing number of previously unrecognized slow-growing mycobacteria have been recently implicated. Some NTM species are ubiquitous and others have more restricted distribution. Evidence of human-to-human transmission is lacking.[82-3]

6.1. Clinical presentation and diagnosis

In orofacial region the most prevalent location of infection by NTM are lymphatic nodes. The disease most commonly affects children with peak incidence at 1-5 years of age [82-4]. The port of entry is probably oropharyngeal mucosa and the lymphatic vessels that drain the mouth and pharynx. Primary infectious focus can also be facial skin [84]. The disease is usually unilateral and affects jugulodigastric, submandibular, parotid/pre-auricular, submental, and posterior triangle lymph nodes. Most patients are otherwise healthy and a chronic neck mass that does not respond to antimicrobial therapy is their sole clinical sign. On average the cervicofacial lymphadenopathy is present for 12 weeks before the proper diagnosis is established and treatment initiated [82]. The size of the infected lymph node can range from 1 to 6 cm and is typically non-tender. The nodes can occasionally liquefy, which is accompanied by fixation of overlying skin, violaceous discoloration, parchment-like transformation of skin and finally formation of draining sinus. In untreated cases, healing usually occurs by unsightly fibrotic scarring and calcification. (Figure 11)

Contrast-enhanced CT imaging picture characteristic of NTM lymphadenitis is asymmetrical lymphadenopathy with contiguous, low density ring-enhancement. Inflammatory changes involving the subcutaneous tissue, such as fat stranding are absent but necrotic foci within skin and subcutaneous tissue are not uncommon [85]. PPD testing has been shown to produce variable results. NTM-specific antigen skin testing can be a useful diagnostic measure, but it is rarely readily available [82]. Diagnosis depends upon the identification of NTM. This requires obtaining material for culture. Tissue samples by FNAC or tissue biopsy are usually necessary, because sampling of draining or ulcerated lesions by swabs do not provide sufficient diagnostic yield. FNAC is the preferred diagnostic technique for patients who do not undergo surgical excision. Histological appearance of necrotizing granuloma-

tous inflammation with various degrees of caseation is also diagnostic. The most important differential diagnosis is TB lymphadenitis. [82]

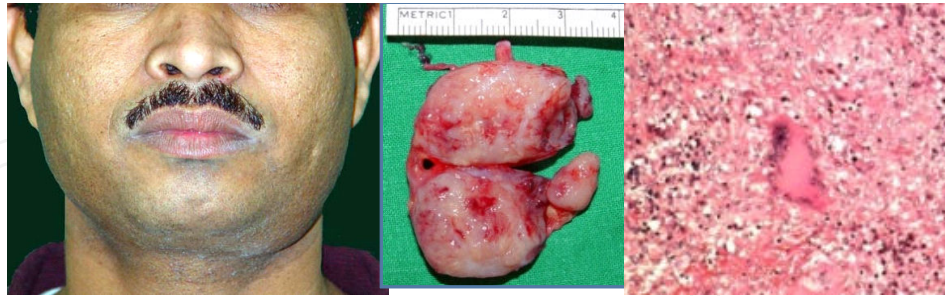


Figure 11. A. 36y old man had a 3-month history of lasting submandibular swelling not responding to antibiotic therapy. FNAC examination gave the result of granulomatous necrotizing lymphadenitis. B. Lymphatic node was extirpated under GA. Chest X-ray, PPD test a sputum culture were negative. C. Histopathology examination revealed epithelial granulomas with giant cells. No fast acid staining organisms were observed. Because lymph node culture also failed, presumptive diagnosis of NTM infection was made. Patient was lost to further follow-up.

6.2. Treatment

Treatment of uncomplicated NTM lymphadenitis is surgical excision [86-7]. Total excision should be performed as early as possible to prevent spread and subsequently more difficult surgery with possible cosmetic consequences. Adjacent normal-appearing enlarged lymph nodes should also be excised. Curettage might be considered as an alternative in cases of adherence of the facial nerve branches. Incision and drainage lead to sinus tract formation with chronic discharge and should be avoided [87]. In a clinical trial including 100 children with culture or polymerase chain reaction confirmed diagnoses, surgery was more effective than chemotherapy with cure rates 96% and 66%, respectively. However, for patients with discharging sinus or proximity of facial nerve branches, chemotherapy can be the preferred therapeutic modality. Chemotherapy must also be considered for patients in whom surgical treatment is unsuccessful. Chemotherapy usually includes clarithromycin and rifabutin. [86]

7. Salivary gland infections

Salivary glands (SGs) are exocrine, merocrine glands. Major SGs are the parotid, submandibular and sublingual. The minor SGs are distributed through the mucosa of the oral cavity. While both major and minor SGs can become infected, infection usually affects major SGs, especially the parotid gland. Infection of SGs can be bacterial, viral, fungal, or as was recently documented, protozoal.

7.1. Bacterial infections

Bacterial infections of the SGs typically result from retrograde propagation of bacteria through their ducts from oral cavity. This process is promoted by stasis of salivary flow. [88]

Predisposing factors for the ductally ascending infection are dehydration, xerogenic drugs and salivary gland diseases associated with reduced saliva secretion or ductal obstructions. Other possible modes of infection are through transitory bacteremia, especially in the neonatal period, or direct spread from adjacent infectious processes. [89,90]

7.1.1. Acute bacterial sialadenitis

The parotid gland is the most common site of acute suppurative salivary infection. Saliva of the parotid gland is primarily serous and therefore provides less protection against ascending bacteria. On the other hand, mucoid saliva produced by the submandibular and sublingual glands contains many antimicrobial protective elements, including lysozymes and IgA antibodies. Mucins also contain sialic acid, which agglutinates bacteria, preventing its adherence to host tissues. Specific glycoproteins found in mucins bind epithelial cells, competitively inhibiting bacterial attachment to these cells. [89] Submandibular sialadenitis is less frequent and accounts for approximately 10% of all cases of sialadenitis of the major SGs. Majority of submandibular gland infections is related to sialolithiasis of Wharton's duct. Submandibular secretions are more mucinous, and therefore more viscid; they also are more alkaline, containing a higher percentage of calcium phosphates. These circumstances contribute to the fact that 85-90% of salivary calculi are located in the submandibular duct. [89] (Figure 12)

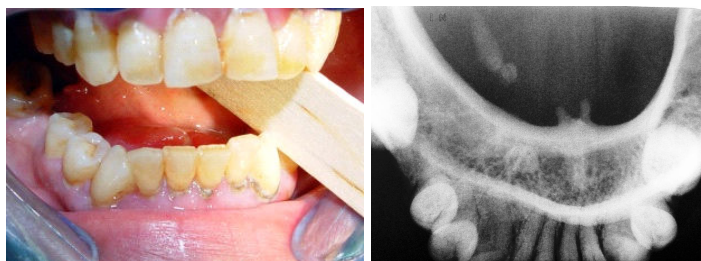

Figure 12. A. 40y old female patient presented with painful infiltrate of right sublingual area and trismus. Mucosa of oral floor was erythematous and right Wharton's duct orifice discharged pus. B. Occlusal intraoral X-ray film disclosed presence of 2 sialoliths. These were removed after incision of distal portion of the duct, which was irrigated by saline. Infection resolved in 1 week.

The most common pathogens associated with acute bacterial infections of SGs are *S. aureus* and anaerobic bacteria. The predominant anaerobes include *Prevotella* and *Porphyromonas*, *Fusobacterium* spp. and *Peptostreptococcus* spp. Less frequent are streptococci including *S. pneumoniae*, and gram-negative organisms, including *Escherichia coli*, *Klebsiella pneumoniae*, and *Pseudomonas aeruginosa*. [91]

7.1.1.1. Clinical presentation and diagnosis

Local symptoms include a rapid onset of pain, swelling, and induration of the involved gland. Overlying skin can become purplish as infection progresses. Stensen's or Wharton's ducts may appear erythematous and gentle massage of the gland will frequently result in a

suppurative discharge from the duct orifice. In submandibular infections, a calculus may be palpable along the course of Wharton's duct. Because of the resistance of the fibrous capsule, particularly that surrounding the parotid gland, palpation of the abscessed gland may fail to reveal fluctuance. Systemic manifestations like fever, chills, malaise are frequent. [92] Laboratory examination reveals leukocytosis with neutrophilia. Purulent secretions from duct orifice should be sent for microbiology examination. CT or US imaging of the gland may reveal abscess formation; however they are not indicated at the beginning of the disease. In the case of submandibular gland infection, orthopantomogram may disclose a salivary stone. Sialography is contraindicated in the acute phases of sialadenitis because it is extremely painful and can exacerbate the existing inflammation. [89]

7.1.1.2. Treatment

Elimination of the etiological factor such as ductal obstruction by sialolith is essential. Other therapeutic measures include proper hydration, stimulation of saliva flow, analgesics and local heat application to ease the discomfort. Capable patients should be instructed on regular external or bimanual massage, starting from the distal bed of the gland and working in the direction of duct drainage. [92] Initially broad-spectrum antimicrobial therapy is indicated to cover all possible aerobic and anaerobic pathogens. Clindamycin, cefoxitin, imipenem, the combination of metronidazole and macrolide or penicillin plus a β -lactamase inhibitor, provide adequate coverage. Later the therapy should be guided by results of culture and antibiotic sensitivity. Presence of methicillin-resistant staphylococci may mandate the use of vancomycin or linezolid. [90] In most cases of acute submandibular sialadenitis removal of duct obstruction and conservative therapy are sufficient to resolve the disease. In cases of acute bacterial parotitis, especially in medically compromised patients like diabetics, infection process often reaches the stage of abscess, despite antibiotic treatment. US, CT or MRI imaging help to recognize this condition. In such instances evacuation of pus becomes necessary. Small, superficially located abscess can be aspirated. The classical approach to drainage of parotid abscess involves anteriorly based facial flap, and multiple, superficial, radial incisions in the parotid fascia parallel to the facial nerve branches [89]. Based on our experience, we consider such radical surgery unnecessary and impractical, and instead utilize incision placed in natural skin crease, as close as possible to the abscess, and dissect bluntly using fine mosquito forceps (Figure 13).

7.1.2. Chronic bacterial sialadenitis

Like in acute sialadenitis, the causative event in chronic sialadenitis is believed to be a lowered secretion rate with subsequent salivary stasis. This can be due to neglected underlying obstruction (duct stenosis, stone or foreign body). Another major cause of chronic sialadenitis is Sjögren's syndrome. Approximately 2% of patients with Sjögren's syndrome are affected each year [93]. Repeated acute suppurative infections lead over time to permanent damage characterized by sialiectasis, ductal ectasia, and progressive acinar destruction combined with a lymphocytic infiltrate. The structure of parenchyma and function of the gland are gradually destroyed. This leads to decrease in salivary secretion and further promotes

recurrences in a vicious circle. Some authors feel that chronic sialadenitis is in most instances either autoimmune or of unknown etiology with superimposed bacterial infections and should not be designated as a chronic bacterial infection [94].

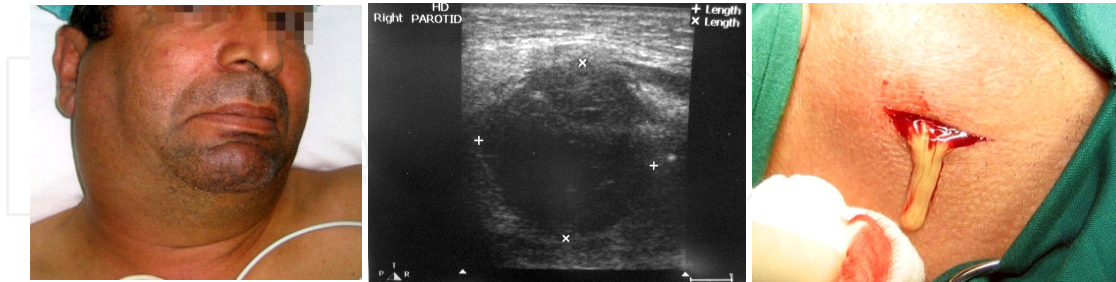


Figure 13. A. 55y old diabetic man presented with a 2-week swelling of the right parotid gland treated via antibiotics. B. US examination revealed an abscess cavity in lower pole of the parotid gland. C. Abscess was drained from small skin incision parallel to natural skin crease.

7.1.2.1. Clinical presentation and diagnosis

Chronic sialadenitis is characterized by recurrent moderate swelling of the affected gland alternating with asymptomatic remissions. During flare-up the duct orifice appears inflamed with accompanying purulent discharge. Symptomatology tends to become progressively more severe with increasing number of flare-ups. Eventually in some patients, the clinical manifestations of a flare-up can mimic that seen in acute sialadenitis including abscess formation [95]. With recurrent infection the gland atrophies and is replaced by fibrotic tissue, which makes it permanently palpable. Many patients with chronic parotitis seek medical attention because of a non-tender asymptomatic parotid lump or diffuse swelling. Chronic sclerosing sialadenitis of submandibular gland, characterized by progressive periductal fibrosis, dilated ducts with a dense lymphocyte infiltration with lymphoid follicle formation and acinar atrophy, is known as Küttner's tumor. It creates a diagnostic dilemma, because clinically it resembles a submandibular gland tumor and it is the known fact that 80% of tumors presenting in this organ are malignant [96]. Clinical diagnosis of chronic sialadenitis needs validation by imaging. Common diagnostic methods are US and sialography. Sialography can evaluate the possible cause and the location of obstruction and enables assessment of progression; however, it is an invasive method and is currently being supplanted by MRI sialography, which provides 3-dimensional images of the salivary gland without contrast medium or exposure to ionizing radiation [97]. A new effective method for diagnosis and also treatment of the obstructive disorders of SGs is sialoendoscopy [98,99]. FNAC or incisional biopsy is advised for lesions that are still not diagnosed after complete clinical and radiographic evaluation.

7.1.2.2. Treatment

An appropriate antibiotic should be used during an acute flare-up. Specific treatment is instituted for any structural abnormality, stricture or calculus. Oral and dental hygiene with

mouthwashes, massage and compresses are useful. In the majority of cases of chronic parotitis, the disease will subside without an operation. More aggressive treatment is justified only for those patients with persistent problems. Total parotidectomy is advised only with frequent attacks and severe, progressive disability [100]. In a case of chronic submandibular sialadenitis, when the function is destroyed, the treatment is by surgical excision. Interventional sialoendoscopy is an innovative approach to management of chronic sialadenitis. It mainly includes sialolith or ductal polyp removal. When present, sialodochitis can be controlled by continuous lavage and drug perfusion in the duct. It has also been reported that polyethylene stents can be used to prevent obstruction of the duct lumen by postoperative edema, to allow particles of calculus to be washed out by the saliva and to reduce the possibility of stenosis. [99]

7.1.3. Juvenile recurrent parotitis

This separately recognized suppurative disease of the parotid glands is characterized by recurrent unilateral or bilateral parotid swellings that may persist into adulthood. Age of onset is most commonly between 3 and 6 years, while complete remission is usual at the time of puberty. An early age at the first episode is associated with an increased risk of recurrences. The episodes of parotid swelling may occur several times per year and overall number of recurrences can reach several dozen. [101,102] The etiology and pathogenesis of this condition are largely unknown. Numerous factors were suggested as causative: congenital malformation of the ductal system, hereditary and genetic factors, allergy, autoimmune disease, IgA or IgG3 deficiency [102,103].

7.1.3.1. Clinical presentation and diagnosis

Findings include recurrent episodes of glandular swelling which typically last for several days up to 2 weeks, and which may occur more than 10 times per year, generalized malaise and pain. On clinical examination the affected gland is swollen and tender, mostly without overlying skin changes. Saliva expressed from the duct is thick and contains floccules of inspissated mucus or pus. US is the appropriate initial imaging investigation, and is usually supplemented by sialography after acute symptoms have subsided. (Figure 14)

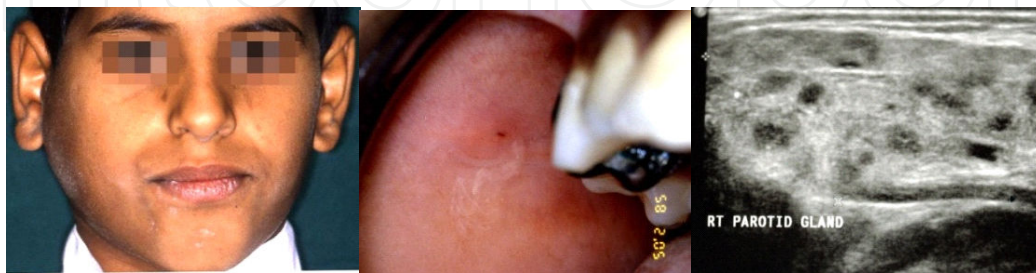

Figure 14. A. 15y old boy with history of recurrent right parotid swelling since the age of 6. B. Orrifice of Stensen's duct is slightly erythematous and expressed saliva contains whitish floccules. C. US examination showed numerous hypoechoic loci consistent with sialectasis.

7.1.3.2. Treatment

Acute episodes are managed conservatively with hydration, stimulation of salivation, fomentations and analgesic-antipyretic medication. Patients with fever and frank purulent exudation may require a course of antibiotics. The sialography with iodinated oil may itself cause an improvement of the condition [104].

7.2. Viral infections

Viral infection of the SGs most commonly occurs through hematogenous dissemination, although infection by retrograde ductal migration does occur. Viral infestation of salivary parenchyma can be accompanied with local and/or systemic manifestations. There is a wide range of viral infections that can involve SGs, which include *Coxsackie virus A and B3*, *Parainfluenza virus B*, *Influenza virus*, *ECHO virus type 9*, *Epstein-Barr virus*, *HIV*, enteroviruses, *Cytomegalovirus* and *Lymphocytic choriomeningitis virus*. [89,92]

7.2.1. Mumps

Mumps is the most common childhood viral disease, causing nonsuppurative acute sialadenitis. Adults are rarely infected due to life-long immunity incurred by childhood exposure or MMR vaccination. Mumps virus, the causative agent of mumps infection, is an enveloped RNA virus that belongs to the genus *Rubulavirus* in the family *Paramyxoviridae*. The virus is endemic in the community and spreads efficiently by air-borne droplets from salivary, nasal and urinary excretions. The incubation period is between 15 to 24 days and averages 18-19 days. Infective virus is shed through the saliva for up to a week following gland enlargement. [89]

7.2.1.1. Clinical presentation and diagnosis

Mumps is characterized by pain and swelling of one or both parotid glands, accompanied by low-grade fever, arthralgia, malaise, and headache. Bilateral parotid gland swelling occurs in most cases, but submandibular gland swelling can also occur in rare cases. Progression of parotid gland swelling can be rapid and sufficient to cause displacement of the pinna. Pain is usually exacerbated by the physiologic stimulus of eating, which causes contractile ejection of saliva from the inflamed gland. Findings at the orifice of the parotid duct are usually absent but sometimes the orifice can become edematous and erythematous. Ductal epithelial desquamation may lead to secondary ductal obstruction and dilatation. While the parotids are the most commonly affected organs, parotitis is not a primary or necessary step for mumps infection. More fulminant infections occasionally progress to include meningoencephalitis, orchitis, pancreatitis, and nephritis. Routinely obtained laboratory tests are usually unremarkable except for occasional leukopenia. Elevations in serum salivary type iso-amylase parallels the pattern and duration of glandular swelling. Laboratory investigation is rarely required given the characteristic features present in all but exceptional cases. A laboratory diagnosis is based on isolation of the mumps virus, detection of viral

nucleic acid, or serological confirmation. Histological examination reveals substantial cytoplasmic vacuolization of acinar cells. [89,92,105]

7.2.1.2. Treatment

As with any viral illness, there is no specific antiviral therapy for mumps and treatment is mostly symptomatic and supportive: supplemental hydration and rest, with dietary modifications to minimize glandular secretory activity. Generally, the symptoms of viremia, including fever, arthralgia, malaise, and headache, begin to abate within 3 to 7 days. The resolution of gland swelling usually requires several weeks, frequently proceeding asymmetrically. [92]

7.3. Fungal infections

Fungal infection is an unusual cause of SG pathology, however there are several reports in the literature about infection of salivary gland with *Candida albicans* [106], *Candida glabrata* [107] *Apophysomyces elegans* [108] and *Rhizopus* spp. [109]. Fungal salivary infection usually occurs in debilitated hosts and this is maybe due to the toxicity of saliva to fungi under normal conditions. The definite diagnosis is made by culturing the purulent discharge from duct or by culture of the pus obtained at surgical drainage of the abscess, but most readily by tissue biopsy. The treatment will involve an appropriate anti-fungal medication depending on the laboratory analysis, incision and drainage of any formed abscess and total or partial excision of the gland because some infections are invasive and life threatening.

7.4. Parasite infections

Apart from involvement of the parotid gland by toxoplasmosis [110], we were able to find only one case of parasitic SG infestation in the English literature. A nematode larva, morphologically consistent with *Strongyloides stercoralis* was found in the cytological examination of a 41-year-old man who underwent incision and drainage of a right-sided parotid swelling because of poor response to the aspiration and drainage with intravenous antibiotic therapy. The abscesses regressed significantly after administration of Ivermectin. [111]

7.5. Granulomatous infections

Granulomatous SG infections not infrequently represent a manifestation of a chronic granulomatous disease involving the lymphatic network in and around the parotid gland. Also direct infiltration of the adjacent glandular parenchyma occurs in fulminant cases. Manifestations frequently feature asymptomatic gradual enlargement of a nodule within the gland substance, suggesting a neoplasm. Included among these diseases are mycobacterial diseases (tuberculous and atypical forms), actinomycosis, cat scratch disease, and tularemia. [92] For details see respective sections of this chapter.

8. Paranasal sinuses infections

Sinusitis is one of the most common conditions in primary care. Because infection causes inflammation of both the sinuses and the nasal cavity, the term "rhinosinusitis" instead of the more common sinusitis has been recently coined [112,113]. The precipitating factor in acute sinusitis seems to be blockage of the sinus ostium, typically the maxillary sinus ostium situated under the middle turbinate, with mucus retention and subsequent infection. Viral infection of upper respiratory tract triggers most cases. Only 0.2-2% of cases become complicated by bacterial infection [113]. Worsening symptoms after 5 days or persistent symptoms beyond 10 days (but less than 12 weeks) indicate non-viral rhinosinusitis; whereas viral disease lasts less than 10 days [112]. A small proportion of cases of bacterial sinusitis can arise as a result of periapical infection or untreated post-extraction oro-antral communication. Odontogenic maxillary sinusitis comprises 10–12% of bacterial sinusitis; however, recent studies suggest that this figure is much more frequent and closer to 30%. [114]

8.1. Clinical presentation and diagnosis

Acute rhinosinusitis, according to The European Academy of Allergology and Clinical Immunology, is characterized by two or more of the following symptoms: nasal congestion with blockage, discharge (anterior or postnasal drip), facial pain and/or pressure and reduction or loss of smell, lasting less than 12 weeks. Additional symptoms, not invariably present, are toothache of upper teeth, pain on stooping, and fever or malaise. [115]

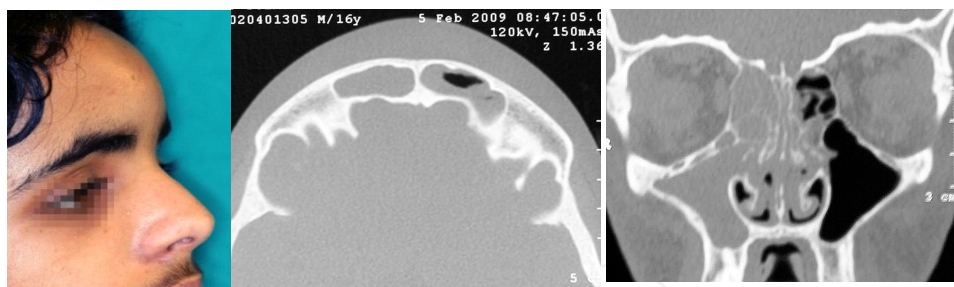


Figure 15. A. 16y old male hospitalized in ENT department was referred to rule out odontogenic source of his right sided pansinusitis. B. Notice distended edematous soft tissues of forehead. C. Complete opacification of all right sided paranasal sinuses. Patient was treated by endoscopic sinus surgery and intravenous antibiotics.

Chronic rhinosinusitis is characterized by nasal congestion or blockage lasting more than 12 weeks and accompanied by at least one of the following symptoms: facial pain or pressure, discolored nasal discharge or postnasal drip and reduction or loss of smell. Most instances of sinusitis are diagnosed clinically. In the workup of suspected acute rhinosinusitis, plain radiography is neither useful nor warranted [115]. X-ray examination of the sinuses, CT, ultrasonography, sinus puncture, and culture of aspirate can be helpful in complicated and chronic cases [112]. Dental symptoms, such as pain and dental hypersensitivity, do not reliably predict an odontogenic cause. The most usual characteristic of an odontogenic sinusitis is the presence of unilateral symptoms [114]. The complications of sinusitis are due largely to

the proximity of the paranasal sinuses to the anterior cranial fossa and orbit, as well as the venous drainage of the mid-facial structures into the intracranial venous sinuses. Up to 75% of orbital infections are attributable to sino-nasal disease, namely ethmoiditis. Frontal sinusitis may lead to osteomyelitis of the frontal bone (Pott's puffy tumor) [116]. Other life-threatening complications include extradural and subdural empyema, meningitis, intracranial abscess, and cavernous sinus thrombosis. (Figure 15)

8.2. Treatment

Acute rhinosinusitis is managed symptomatically with analgesics and topical steroid spray. Symptom relief can also be achieved with the use of topical saline douches and sprays. Antibiotics are recommended if symptoms are severe, persistent (>5 days), or progressive. [112,118] The gold standard for establishing bacterial etiology of acute rhinosinusitis is a maxillary sinus tap. However, it is not a routine procedure and is usually reserved for research purposes or for patients not responding to initial medical therapy. A suitable alternative may be nasopharyngeal culture. [118] Even in the absence of detectable sinus bacterial infection, the presence of nasopharyngeal bacterial colonization can result in the development of secondary bacterial sinusitis. Inflammation of the mucosal lining of the paranasal sinus causes a functional obstruction of the osteomeatal complex. It is thought that oxygen within the sinus is depleted as molecular oxygen is absorbed, resulting in negative pressure promoting the aspiration of bacteria from the nasopharynx. Another mechanism of paranasal sinus inoculation with bacteria is nose blowing. [118] Once a bacterial cause is established based on clinical presentation, empiric antimicrobial therapy should be initiated, depending on the resistance patterns of the usual pathogens: *S. pneumoniae*, *H. influenzae* and *M. catarrhalis*. Antibiotics that cover β -lactamase producing bacteria, like amoxicillin-clavulanate, are reasonable choices. Other options include cephalosporins or macrolides. [112] If an antibiotic is effective, clinical improvement should be seen within 2–3 days [118].

Clinical studies have recently confirmed that about 60% of presumed bacterial sinusitis resolves spontaneously without antibiotics. For instance, in a double-blind, randomized, placebo-controlled factorial trial of 240 adults (aged ≥ 16 years) with acute non-recurrent bacterial sinusitis, neither an antibiotic nor a topical steroid alone or in combination were effective in altering the symptom severity, the duration, or the natural course of the condition [119]. Despite this evidence, antibiotics are still overused, which adds to treatment costs, puts patients at risk of adverse events and adds to growing antimicrobial resistance [113]. Treatment of *chronic rhinosinusitis* should begin with topical nasal steroids along with aggressive treatment of any underlying cause or comorbid allergy. Oral steroids should be reserved for refractory cases. Caution should be taken in at-risk groups, including patients with diabetes or active peptic ulceration. Antibiotics may be indicated in patients who have failed to respond to initial intranasal steroid therapy or in those who have severe symptoms with evidence of persistent nasal bacterial infection. [112,113] Surgery for rhinosinusitis should be considered only after conservative treatment has failed or complications develop. In acute rhinosinusitis sinus lavage performed endoscopically or via external trephination of canine fossa can drain pus and decompress the affected sinus. Traditional open sinus proce-

dures for chronic rhinosinusitis, like Caldwell-Luc operation, have been supplanted by endoscopic techniques. With a better understanding of normal mucociliary clearance pathways and anatomy of the osteomeatal complex, functional endoscopic sinus surgery is now the mainstay of surgical treatment. [112] Patients with recurrent acute sinusitis or chronic sinusitis should be evaluated for underlying allergy. As many as 60% of patients with chronic sinusitis have allergic sensitivities to perennial allergens like house dust mites, cockroaches, pet dander and fungi. These allergies should be identified and treated before the patients are considered for sinus surgery [113]. Although symptoms and exam findings in odontogenic and nonodontogenic sinusitis are similar, odontogenic sinusitis differs in the pathogenesis, spectrum of microbiology findings and treatment strategies and its therapy is therefore not discussed in this chapter.

9. Orbital infections

Infections of the orbit make up less than 1% of all orofacial acute bacterial inflammations. Their rarity may lead to late diagnosis and consequential serious complications: impairment of visual acuity, blindness, or in extreme cases even death due to intracranial spread [120]. The orbit is surrounded by frontal bone, major and minor wing of sphenoid bone, orbital facet of vertical plate of palatine bone, lamina papyracea of ethmoid bone, lacrimal bone, maxilla and zygomatic bone. Several of these bones contain pneumatized paranasal sinuses. The ethmoidal sinus and maxillary sinus are separated from the orbital cavity by very thin bone shell. There are also numerous bony foramina and fissures containing neurovascular bundles, along which the infection processes can spread into orbit and intracranially: optical foramen, superior and inferior orbital fissure, anterior and posterior ethmoidal foramen, infraorbital canal and foramen, nasolacrimal canal, supraorbital and supratrochlear foramen. Another route of orbital involvement by adjacent infectious process is thrombophlebitis of orbital veins, which are connected to facial venous system by angular, infraorbital, supraorbital, supratrochlear and pterygoid plexus veins. The ophthalmic veins communicate also with the veins of the sinuses, especially the ethmoid sinus. The ophthalmic veins drain into the cavernous sinus, and therefore infections can spread intracranially. Veins in this region are valveless and can have retrograde flow. This makes venous orbital system prone to congestion. [121] Orbital infections are usually classified as pre-septal or post-septal according to their relationship to orbital septum, connective tissue membrane, which arises from the orbital margin and radiates into upper and lower tarsus of the eyelids. [121]. Conditions regarded as preseptal orbitocellulitis are quite frequent. They accompany many orofacial and upper respiratory infection processes, especially odontogenic infections originating in the maxilla. Children are regularly affected by this scary-looking condition; however, it recedes readily after the underlying cause has been eliminated. In these cases periorbital soft tissues and eyelids are affected by edema, but ocular findings like globe position, motility and vision remain normal. Only post-septal processes can therefore be considered true orbital infections. (Figure 16)

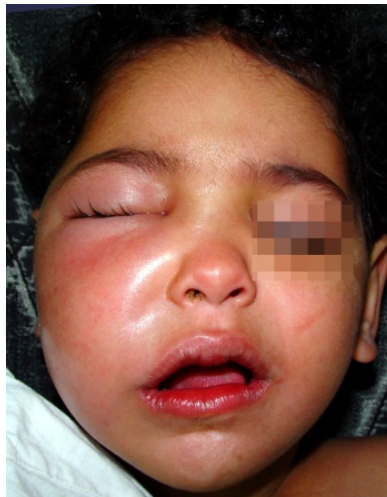

Figure 16. old girl hospitalized in the ophthalmology ward was referred to rule out odontogenic source of preseptal orbitocellulitis. Note crusted nasal secretion suggesting acute rhinosinusitis.

In postseptal orbital cellulitis there is diffuse edema of the orbital contents and actual infiltration of the adipose tissue with inflammatory cells and bacteria, but no discrete formation of abscess. In subperiosteal orbital abscess, there is a collection of pus between the periosteum and the bony wall of the orbit, while in intraorbital abscess pus collection is present within the orbital tissues. [122,123] (Figure 17)

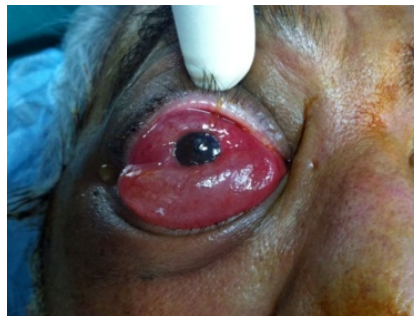

Figure 17. Clinical presentation of acute postseptal orbitocellulitis with chemosis, proptosis and ophthalmoplegia. Courtesy of Dr. Sabreyah Al-Saleh, Ophthalmology Department, Al-Adan Hospital.

The close relationship between the orbit and paranasal sinuses is responsible for the majority of orbital infections, especially in children. Paranasal sinusitis, mostly ethmoiditis followed by maxillary sinusitis, precedes 60 – 84% of orbital infections. [124,125] Other sources of orbital infections are trauma, retained foreign bodies, periorbital suppurative skin diseases, hordeolum or chalazion, dacryocystitis and conjunctivitis. Odontogenic infection of the orbit is rare. The pathway can be via the maxillary sinus, the canine fossa with a thrombophlebitis of the angular vein, or the pterygopalatine fossa and infratemporal fossa and further through the inferior orbital fissure. [120] The causative microorganisms in acute orbital infections are usually those associated also with paranasal sinusitis. Before introduction of vaccination, *H. influenzae* was the most common pathogen responsible for orbital cellulitis.

Currently, the most common bacterial isolates include the *Staphylococcus* species, *Pseudomonas* species, *Streptococcus* species, *Moraxella catarrhalis*, and *Eikenella corrodens* as well as anaerobic organisms like *Peptostreptococcus*, *Fusobacterium*, and microaerophilic *Streptococcus*. [121] In young children aerobes prevail, while in older patients anaerobes can also be found. Polymicrobial infections are more frequent in adult patients. [122]

9.1. Clinical presentation and diagnosis

Symptoms depend on the stage of the infectious process, which begins with postseptal orbital cellulitis accompanied by swelling and erythema of eyelids, conjunctival chemosis, limited ocular motility, visual disturbances and proptosis due to developing intraconal edema. Development of subperiosteal abscess can lead to displacement of the bulbus with resulting diplopia. Intraconal progress of infection is marked by increasing exophthalmia, abnormal pupillary reflexes, ophthalmoplegia, impaired color vision and decreasing visual acuity. Eyeball is painful to touch and patient suffers from severe headache. The disease is accompanied by septic fever and laboratory signs of acute bacterial infection. Untreated or inadequately treated disease finally progresses into thrombophlebitis of cavernous sinus with complete paralysis of related cranial nerves, loss of vision, altered mental status and generalized sepsis. Mortality rate of cavernous sinus thrombophlebitis remains high. There is usually very little to be gained by conventional radiology examination. Plain radiographs are reserved for very young children in whom the risk of sedation for the CT scan and radiation burden outweigh the possible diagnostic yield [121]. CT scan or MRI imaging should be performed without delay to serve as an indicator and guide for surgical intervention. It will help to elucidate the status of the paranasal sinuses, where majority of infections originate. Although CT still remains the modality of choice for the diagnostic workup of orbital infection, MRI should be considered particularly in the pediatric population [126]. Recently, there was some progress in employment of US as a readily available, inexpensive imaging method for diagnosing and monitoring orbital infections, especially in children, where radiation dose is a major concern [127].

9.2. Treatment

Patients with cellulitis, without evidence of a subperiosteal or intraorbital abscess, can usually be treated with parenteral antibiotics alone. The antibiotic should be broad spectrum and to cover aerobes as well as anaerobes. Second- or third-generation cephalosporins, ampicillin-sulbactam, ticarcillin-clavulanate, clindamycin, aminoglycosides, fluoroquinolones or carbapenems are among those recommended. [121,128] Surgical incision and drainage of the subperiosteal or intraorbital abscess is the mainstay of therapy and should be considered an emergency procedure. Primary source of infection should be addressed at the same time. The optimal way of draining orbital abscess is endoscopic access via paranasal sinuses, namely in cases originating in sinusitis [128]. Otherwise, surgical access to the orbit is through periorbital skin incisions like Lynch, infraorbital or lateral eyebrow. Cosmetic approaches used in orbital traumatology are not indicated here, because they do not allow placement of proper drains and/or they would bring purulent exudate into the conjunctival

sac and contaminate the cornea. Surgical intervention should be complemented by aggressive intravenous antibiotic therapy without waiting for results of microbiology examination and sensitivity testing. Benefits of corticosteroid therapy aimed at reducing orbital edema is questionable. It should be administered only if mycotic etiology has been ruled out.

10. Interstitial fungal infections

There are about 100,000 different species of fungi worldwide, but only a few are pathogenic for humans, and most of them show distinct geographic distribution. With the exception of candidiasis, other fungal infections are extremely rare and consequently medical and dental practitioners have limited experience and knowledge in their diagnosis and management. Accurate and early diagnosis, which often is not easy, should lead to prompt and aggressive therapy to prevent spread, dissemination and death. Fungal infections rarely afflict healthy immunocompetent individuals. However, recent years saw a dramatic increase in the numbers of immunocompromised patients, above all HIV infected persons, diabetics, patients with hematologic malignancies, transplant recipients and other patients receiving immunosuppressive drugs. Clinicians should be aware of these rare mycoses and include them in the differential diagnosis when dealing with unusual or unexplained symptoms. The laboratory methods available to diagnose fungal infections include biopsy and culture of tissue, body fluids, secretions, tests for antigens and serum antibodies. Biopsy investigation is the key to correct diagnosis and should include special stains such as periodic acid-Schiff and Grocott-Gomori methenamine silver nitrate. For yeasts, culture is necessary to identify the etiologic agents. Filamentous fungi, in particular zygomycetes and dimorphic fungi can be diagnosed by histological examination and pertinent stains with or without isolation of the fungus from the same site. [129]

10.1. Candidiasis

Candida, the most common cause of opportunistic infection worldwide, is thin-walled, small yeast (4-6 μ) that reproduce by budding. The genus *Candida* includes approximately 154 species, but only 6 are frequently isolated in human infection. *Candida albicans* is the most abundant and significant species. Other causative agents include *C. tropicalis*, *C. glabrata*, *C. parapsilosis*, *C. krusei*, and *C. lusitaniae*. Invasive *Candida* disease is composed of a variety of entities, including candidemia, disseminated candidiasis, endocarditis, meningitis, and endophthalmitis. [130] In orofacial areas the most frequent form of *Candida* infection is stomatitis. It takes on several well known clinical manifestations, like angular cheilitis, denture stomatitis and rhomboid median glossitis. These superficial mucosal diseases are usually due to local compromising factors and can be found in otherwise healthy individuals. Topical antifungal treatment with correction of underlying problem is usually sufficient for cure. Disorders of cell-mediated immunity are associated with severe or recurrent pseudomembranous candidiasis, whereas neutropenia or impaired neutrophil functions are associated with invasive infections. [131] (Figure 18)

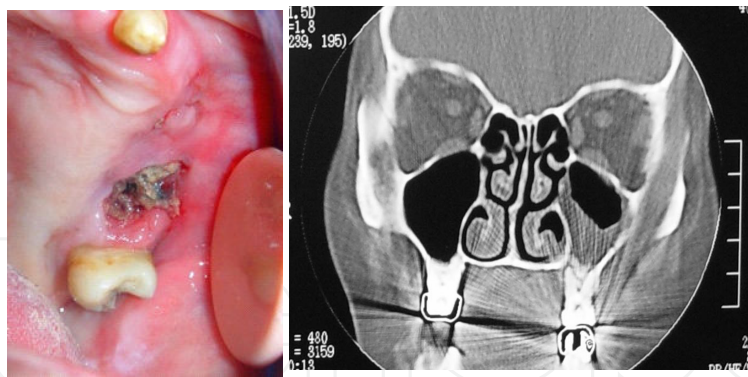


Figure 18. A. 40y old diabetic woman was referred by a dentist for evaluation of non-healing wound after extraction of tooth 26 done 6 months earlier. B. CT examination revealed partial opacification of the maxillary sinus and signs of osteomyelitis. The patient underwent surgical debridement. Histopathology examination revealed massive *Candida* infiltration.

10.2. Cryptococcosis

The *Cryptococcus* genus includes spherical opportunist yeasts that generally lack a mycelium but have a polysaccharide capsule. Two *Cryptococcus* species can cause diseases in humans. *Cryptococcus neoformans* is ubiquitously distributed. It has been isolated in the soil and in the feces of birds, such as pigeons, canaries, and parrots. *Cryptococcus gattii* has the koala bear as a natural reservoir, and it is endemic in Australia, where it is also frequently found on eucalyptus trees. *Cryptococcus neoformans* infection generally affects immunocompromised hosts, whereas *C. gattii* is more often isolated in immunocompetent subjects. [129] Cryptococcosis is one of the most common life-threatening systemic fungal infections in HIV infected patients with mortality rate of 30-40%. The onset of the infection follows inhalation of the spores, with primary localization in lungs from which they spread through the bloodstream to the central nervous system, causing meningitis. There have been only sporadic reports of orofacial manifestations. The affected locations included oral mucosa, parotid gland, paranasal sinuses and temporal area with associated osteomyelitis. [132-6]

Combination of amphotericin-B and flucytosine is the treatment of choice for the first 2 weeks, followed by fluconazole maintenance therapy.

10.3. Aspergillosis

Aspergillosis is an infection caused by a fungus of the *Aspergillus* family. *Aspergillus* species are commonly found in the soil and decaying vegetation. Infections due to *Aspergillus* species are caused in most cases by *Aspergillus fumigatus*, far ahead of *Aspergillus flavus*, *Aspergillus niger*, *Aspergillus terreus* and other *Aspergillus* species. [137] The manifestation and severity of the aspergillosis depends upon the immune status of the patient. Although *Aspergillus* conidia inhalation is very common, the disease is rare in healthy subjects. Patients at highest risk are those with hematological malignancies and severe neutropenia, AIDS, chronic obstructive pulmonary disease, solid organ transplant recipients, and patients in the

intensive care unit receiving steroids. Invasive *Aspergillus* infections most commonly affect the lung and paranasal sinuses. Other forms of the disease are central nervous aspergillosis, osteomyelitis, endophthalmitis, endocarditis, and disseminated form of aspergillosis. [129,137] The maxillary sinus is the most common orofacial site of invasive aspergillosis. The disease is characterized by spread of the fungus from the sinus into adjacent structures. If not aggressively treated, it can invade the brain, causing a high mortality rate. Commonly reported symptoms of invasive sinus aspergillosis are nasal congestion, nasal discharge, abnormal findings in the nasal cavity, buccal swelling with pain, and hypoesthesia. Primary oral invasive aspergillosis is rare. The most frequently affected site is the gingiva, followed by the hard palate. The necrotic mucosal ulceration can progress to affect underlying bone. [138] A case of mandibular involvement has also been reported after tooth extraction in a diabetic patient. [129] Successful treatment of invasive aspergillosis requires prompt diagnosis and rapid institution of aggressive therapy. Any delay or nonaggressive therapy can result in the spread of infection with lethal consequences. Treatment of choice is surgical debridement with antifungal therapy using amphotericin B, itraconazole, voriconazole, and echinocandins. [137,138] The most frequent form of aspergillosis encountered in maxillofacial area of immunocompetent patients is *Aspergillus* mycetoma (AM) of the maxillary sinus. Also known as aspergilloma or fungus ball, it is a noninvasive extramucosal mycotic infection. Predisposing factors include poorly ventilated sinus, a pre-existing chronic sinusitis, or foreign bodies in the sinus. Overfilling of endodontic sealers into the sinus may be a cause. Zinc oxide contained in sealers paralyzes the epithelial cilia and causes edema and hyperemia of the soft tissues that may promote *Aspergillus* growth. Symptomatic patients usually present with signs of chronic sinusitis with nasal secretions, pain, and sometimes facial edema. The disease can be also asymptomatic and is revealed during routine radiographic examination. The treatment of AM is surgical. Traditional Caldwell-Luc procedure, which has been used until recently, has detrimental consequences for sinus physiology. It was supplanted by endoscopic sinus surgery with middle meatal antrostomy. Combined approach with intraoral surgical access remains reserved for selected cases in which endoscopic surgery does not permit complete removal of fungus material and foreign bodies. General or local antifungal drugs are not indicated. [139]

10.4. Zygomycosis

Zygomycosis is fungal infection also known under designations phycomycosis or mucormycosis. The term phycomycosis is obsolete and refers to some of organisms currently classified as *Zygomycota*. The term mucormycosis refers to fungi in the order *Mucorales*. While the term zygomycosis includes also *Entomophthorales*, the order of *Zygomycetes*, as possible etiological agents, the term mucormycosis excludes this group and concerns only organisms belonging to the order of *Mucorales*. The order of *Entomophthorales* is of limited concern because it does not possess the same degree of invasiveness as *Mucorales*. Two genera of *Entomophthorales* are known to be implicated in human disease: *Conidiobolus* and *Basidiobolus*, responsible for subcutaneous infections and, less frequently, for disseminated forms. [140]

The phylum *Zygomycota* comprises about 600 species, principally occurring in soil enriched with decaying organic matter. The usual human pathogens belong to genera *Absidia*, *Mucor*, *Rhizomucor* and *Rhizopus*. The predominant human pathogen is *Rhizopus (oryzae) arrhizus*, accounting for 60% of all forms of zygomycosis and 90% of rhino-orbito-cerebral zygomycosis cases. [141] The mechanism of inoculation is most often by inhalation of spores and therefore respiratory tract or lungs are affected. Up to one half of all zygomycosis cases originate in paranasal sinuses. Another important infection route is percutaneous inoculation. This includes traumatic and surgical wounds, medicine or illicit drug injections, tattoo, insect bites or stings. Deglutition of contaminated food, drinks, herbal or homeopathic remedies can lead to infections of digestive tract. Other organs can be affected either by direct or hematogenous spread due to angioinvasive nature of the fungus. The infection typically occurs in immuno-compromised patients. The main target group consists of poorly controlled diabetes mellitus patients. Diabetic ketoacidosis leads to dysfunction of monocytes/macrophages and impairment of action of neutrophils. Another target group is patients with solid tumors, leukemias and lymphomas with chemotherapy-induced neutropenia being the principal risk factor. Other risk factors are systemic steroids, myelosuppressive therapy in bone marrow and solid organ transplant recipients, iron overload and its deferoxamin treatment in patients on dialysis. Wide-spectrum antibiotics can promote zygomycosis by eliminating bacterial competition. [141-3] Cases of zygomycosis have also been reported among healthy individuals with no known risk factor. [144] Many of these cases have been ascribed to *Apo-physomyces elegans*, relatively recently discovered *Zygomycete*. [145] The majority of cases in previously healthy patients follow invasive procedures or trauma with extensive damage of soft tissues. Local ischemia and resulting acidosis can provide favorable conditions for proliferation of an infection.

10.4.1. Clinical presentation and diagnosis

Majority of orofacial zygomycosis cases originate in paranasal sinuses, especially in diabetic patients. Initial signs include nasal obstruction, mucopurulent or bloody nasal discharge, nasal crusting, facial pain, headache, facial swelling, and cellulitis. In acutely progressing cases, orbital involvement is a common clinical feature, even on presentation. (Figure 19)

Zygomycosis should be considered in all patients with orbital inflammation associated with multiple cranial nerve palsies and retinal or orbital infarction, regardless of their immunologic status. Initial orbital involvement is an alarming sign, because it can lead to intracranial progression with grave prognosis. CT scan at this initial stage often reveals only minimal mucosal thickening of the sinuses. Blood tests, cerebrospinal fluid examinations, and cultures from paranasal sinuses fluid are of no diagnostic help; only the detection of typical fungal hyphae in the infected tissue is diagnostic. The early collection of biopsy sample is therefore of utmost importance. [146-8] Chronically developing zygomycosis of paranasal sinuses results in extensive necrosis and destruction of mid-facial bony architecture and can manifest itself by hard palate ulceration over necrotic bone and finally palate perforation. (Figure 20)

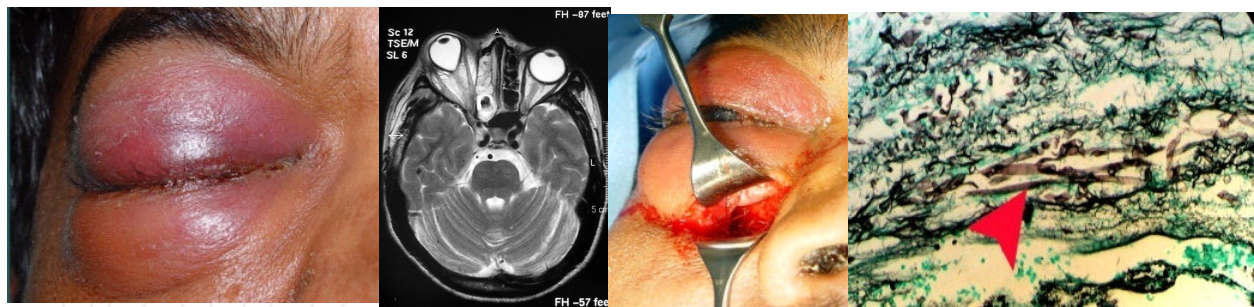


Figure 19. A. Ten day orbital cellulitis in a previously healthy young man, unsuccessfully treated by antibiotics and corticosteroids. B. MRI scan revealed proptosis with stretching of the optical nerve, deformation of the bulbus, thickening of ocular muscles, inflammatory changes of orbital fat, homolateral ethmoid cells and temporal fossa. C. Exploratory orbitotomy encountered bulging avascular periorbital. D. Grocott-Gomori stain of biopsy specimen depicted hyphae of zygomycete, which was classified by subsequent culture as *Apophysomyces elegans*. Despite orbital exenteration and Amphotericin B therapy the patient died 5 days later due to intracranial invasion. [145]

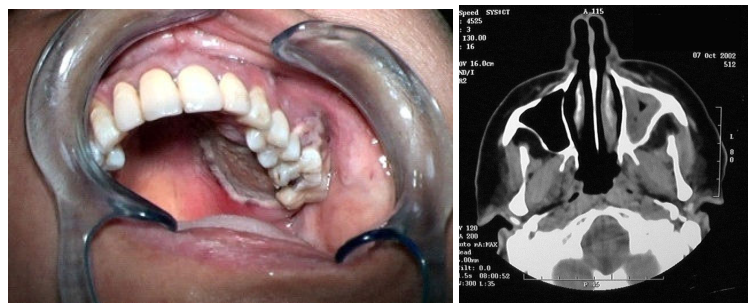


Figure 20. A. Female patient treated by chemotherapy for acute myeloid leukemia was referred for evaluation of extensive palatal necrotic ulcer. B. CT scan revealed nearly complete opacification of maxillary sinus. Patient underwent partial maxillectomy and was diagnosed with zygomycosis. She died later due to complications of chemotherapy.

10.4.2. Treatment

Effective therapy requires prompt surgical intervention, systemic antifungal drug administration and reversal of the underlying immunocompromising condition. The only agent active against most *Zygomycetes* species has been until recently amphotericin B. It is the drug of choice for treatment of zygomycosis and it is recommended that therapy should be started as soon as the diagnosis is confirmed. The use of amphotericin B is limited by frequent side effects, most importantly the dose-limiting nephrotoxicity. Most of the negative side effects can be avoided by using preparations of amphotericin B combined with lipid structures. Also introduction of new azoles such as posaconazole and voriconazole may provide hope for better therapeutic outcomes. [149,150] *Zygomycetes* invading host tissues have a tendency to grow inside vascular channels, which leads to thrombosis and subsequent ischemic tissue necrosis. Intracavitary/interstitial and cerebrospinal fluid perfusion pathways may ensure availability of antibiotic in tissues affected by intra-arterial invasion by mycelia and thrombosis. [151] The overall mortality rate of zygomycosis is approximately 44% but

for patients with rhinocerebral form it reaches 85% and remains more or less unchanged despite progress in antifungal pharmacotherapy. [152]

10.5. Histoplasmosis

Histoplasmosis is a mycosis caused by *Histoplasma capsulatum*, a saprophytic dimorphic fungus found globally in soil. Dimorphic fungi are microorganisms that can grow either in mycelial form in the external environment or in yeast-like form in the host tissues. The morphologic transformation from mold to yeast confers virulence to these microorganisms, so that they are able to cause disease even in immunocompetent hosts. [129] Endemic locations of histoplasmosis include the Ohio and Mississippi River valley, scattered areas of Central and South America, Africa, Asia, the Far East, and Australia. [153] Human contamination occurs by inhalation of the airborne spores, which are phagocytosed by pulmonary macrophages and reside within a membrane-bound vacuole. Immunocompetent persons exposed to a low inoculum develop antigen-specific CD41 T-lymphocyte mediated cellular immune responses with activation of macrophages and the disease is controlled. [154] In immunocompromised host, mainly HIV-positive patients, *H. capsulatum* can spread through the reticuloendothelial system and lead to potentially lethal generalized disease. Upper aerodigestive involvement has been reported in patients with chronic pulmonary and chronic disseminated forms of histoplasmosis and may be the initial or only manifestation of the disease. [155] It may also be the first manifestation of AIDS. Lesions frequently present as painful ulcers covered by pseudomembrane, nodules, or vegetations. Oral lesions associated with *H. capsulatum* may occur in isolation or associated with pharyngeal and laryngeal lesions and are present in 30% to 50% of patients with disseminated histoplasmosis. They may mimic other ulcerated lesions, such as squamous cell carcinoma, tuberculosis, and other deep mycoses. [156-8] Specific complication of pulmonary histoplasmosis is the development of a mediastinal granuloma, characterized by a mediastinal mass (3-10 cm) comprised mostly of caseous mediastinal lymph nodes that have matted together and broken down into a single semiliquid encapsulated lesion. Histoplasmosis infection in the neck is a rare presentation and is probably due to the spread of histoplasmosis from the mediastinum to cervical lymph nodes. Neck masses have histopathology characteristics similar to histoplasmosis mediastinal granulomas. [159] Surgical treatment of histoplasmosis orofacial lesions by itself is not effective and must be complemented by antifungal therapy. Typical management of severe disease first involves treatment with amphotericin B, followed by oral itraconazole. Treatment with itraconazole will need to continue for at least 1 year. In milder cases, oral itraconazole or ketoconazole is sufficient. [156]

11. Deep neck infections

Infections of deep fascial compartments of the head and neck can be challenging in diagnosis and management. Because of the anatomic communication between fascial neck spaces, the infection processes easily spread beyond the original site and can lead to life threatening complications. Most deep neck abscesses are polymicrobial; the average number of isolates

is five (range 1–10). Anaerobic bacteria can be isolated from most abscesses when appropriate culture techniques are employed. Predominant anaerobic organisms isolated in peritonsillar, lateral pharyngeal and retropharyngeal abscesses are *Prevotella*, *Porphyromonas*, *Fusobacterium* and *Peptostreptococcus* spp. Aerobic organisms are group A β -hemolytic streptococci, *S. aureus* and *H. influenzae*. [90,160]

11.1. Peritonsillar abscess

The most common deep neck infection is peritonsillar abscess. Peritonsillar abscesses mostly occur as a complication of repeated episodes of bacterial tonsillitis, but they can occasionally occur as a complication of a viral infection, such as Epstein–Barr virus mononucleosis. The infection penetrates into the potential space between the superior constrictor pharyngis muscle and the tonsillar capsule. [90,161]

11.1.1. Clinical presentation and diagnosis

The peritonsillar abscess is usually preceded by acute pharyngotonsillitis. The initial focus of infection may have been resolved by the time of presentation. [161] Affected tonsil is swollen and inflamed, but the soft palate does not bulge. The uvula is edematous and pushed towards the opposite side of the infection. Patients have difficulty in swallowing or speaking. They may be drooling because of pain on swallowing. Pain gradually increases in severity, radiates to the ear and causes trismus as a result of spasm of the medial pterygoid muscle. The breath has a foul odor. Ipsilateral cervical lymph nodes are enlarged and tender. CT examination, or intra-oral US, is helpful in distinguishing between abscess and cellulitis. [90]

11.1.2. Treatment

The therapy of choice is needle aspiration or incision and drainage of the abscess under local or general anesthesia, supported by administration of parenteral antibiotics. Hospitalization and general anesthesia are required in younger children. It is important to obtain adequate specimens for microbial culture from the abscess as a variety of organisms can be recovered. Specimens are best collected at the time of surgical drainage by needle aspiration. [160] Patients with a peritonsillar abscess and a history of recurrent tonsillitis should be considered for tonsillectomy after the acute episode has subsided. It is also possible to drain abscesses by tonsillectomy during the acute stage of the disease.

11.2. Parapharyngeal abscess

The parapharyngeal space is a crevice extending from the level of hyoid bone to the base of the skull. Its lateral border is made up by the medial pterygoid muscle and part of ascending ramus of the mandible, the deep lobe of parotid gland with its investing fascia and inner surface of sternocleidomastoid muscle with its investing fascia. The medial border is composed of the buccopharyngeal fascia covering the lateral surface of the superior constrictor muscle. The pterygomandibular raphe, formed by the junction of the buccinator and the su-

perior constrictor pharyngis muscles, is the anterior border. In this area parapharyngeal space has intimate relationship to pterygomandibular space. The posterior border is made up by the alar fascia and along it parapharyngeal space communicates with the retropharyngeal space. Superior border is the skull base and inferiorly parapharyngeal space communicates with paravisceral neck space. The styloid process and muscles attached to it, together with surrounding loose connective tissue and stylohyoid ligament, create styloid septum, dividing the parapharyngeal space into prestyloid and retrostyloid compartments. The prestyloid compartment does not contain any important structures except ascendant palatine artery, and is closely adjacent to the tonsillar fossa and the medial pterygoid muscle. The retrostyloid compartment contains internal carotid artery, internal jugular vein, the cranial nerves IX - XII, and the cervical sympathetic trunk, as well as lymphatic nodes. Parapharyngeal space can be infected from various sources including the pharynx, tonsils, parotid gland, submandibular space, retropharyngeal space, masticator space, and local lymph nodes. The most frequent source of parapharyngeal infection is peritonsillar abscess. [162] Complications arising from infections of the parapharyngeal space are caused predominantly by involvement of the retrostyloid compartment. They include Horner's syndrome or cranial nerves IX to XII palsies. Involvement of the vagus nerve or laryngeal edema and obstruction can lead to sudden death. Suppurative jugular thrombophlebitis (Lemierre syndrome) is characterized by an anaerobic septic thrombus occluding the internal jugular vein, often with bacteremia and metastatic foci of infection. [163] Carotid artery erosion and rupture also can occur, with devastating consequences, characteristically preceded by small "herald bleeds". [164] In addition, infections of the parapharyngeal space can spread to other spaces of the head and neck.

11.2.1. Clinical presentation and diagnosis

The clinical manifestations of the parapharyngeal space infection depend on whether the prestyloid, retrostyloid or both compartments are involved. The clinical symptoms of infection of the prestyloid compartment are dysphagia, trismus, and pain involving the ipsilateral side of the neck with potential projection to the ipsilateral ear. Flexion of the neck intensifies pain by physical compression of the space. On physical examination, swelling and induration may be noticed at the angle of the mandible and parotid area. When an adequate oro-pharyngeal examination is not hampered by trismus, the lateral pharyngeal wall is often found displaced medially. There may be other physical findings associated with the portal of infection, like tonsillitis or pharyngitis. However, often the infection focus does not cause prominent symptoms. An antecedent pharyngitis or tonsillitis may already have resolved. Isolated infections of the retrostyloid compartment of the parapharyngeal space lack the intense trismus associated with prestyloid compartment infections. Occasionally, the parotid gland, which is adjacent to the retrostyloid compartment, may become swollen. Edema may involve the epiglottis and larynx, leading to dyspnea. An oropharyngeal examination may miss swelling of the pharyngeal wall because the swelling can be hidden behind the palatopharyngeal arch. Some of patients thus have no specific localizing signs and may present with sepsis of occult origin. The diagnosis may become apparent only on imaging or after the development of neurologic or vascular complications. Infections of either compart-

ment are associated with systemic toxicity, fevers, chills, and potentially rigors. [90, 161] (Figure 21).

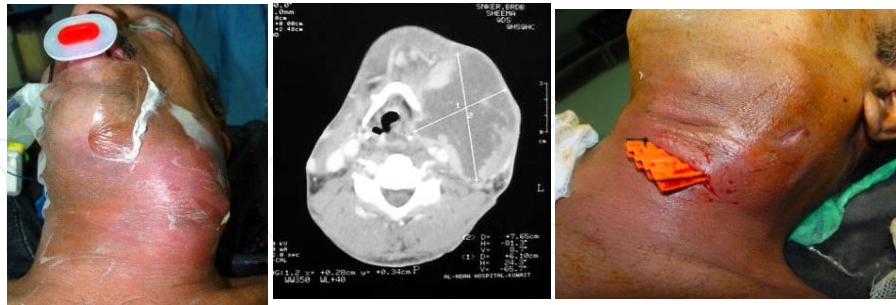


Figure 21. A. Huge neck abscess previously managed by insufficient incision and antibiotic therapy. B. CT scan with contrast shows displacement of airway and compression of great vessels. C. Drainage of abscess by liberal neck incision.

11.2.2. Treatment

Infections of the parapharyngeal space, especially prestyloid compartment, are usually suppurative and have tendency to spread rapidly. They should be managed by early surgical drainage and antibiotic therapy. Some authors suggest that infections localized to the retrostyloid compartment with no clinical evidence of sepsis or airway compromise may respond to intravenous antibiotics without surgery. [165] These two forms can be differentiated by contrast CT scans. [166]

11.3. Retropharyngeal abscess

The retropharyngeal space is surrounded anteriorly by the posterior wall of the pharynx, superiorly by occipital bone and bilaterally by loose connective tissue contiguous with both parapharyngeal spaces. The posterior wall is made up by the alar fascia derived from the deep layer of cervical fascia. Retropharyngeal space extends caudally and communicates with the mediastinum. Retropharyngeal abscesses occur more frequently in children. It is surmised that young children are more prone to retropharyngeal abscesses due to the numerous lymph nodes in the space, while in adolescents and adults retropharyngeal lymphatics are regressed [167] Retropharyngeal abscesses in adult age occur mostly in immunocompromised patients or as a foreign body complication. [168]

11.3.1. Clinical presentation and diagnosis

Clinical manifestations of retropharyngeal space infections and abscesses can vary from mild retropharyngeal pain and malaise to severe respiratory distress and systemic toxicity. Patients often experience an abrupt onset of high fever that is associated with drooling, dysphagia, neck pain on hyperextension, and dyspnea. Respiratory distress can develop because of the anterior displacement of the pharyngeal wall and the supraglottic structures. On transoral examination, bulging of the posterior oropharynx may be seen or palpated, al-

though palpation of the lesion may lead to abscess rupture with aspiration or asphyxiation. The oropharynx can be examined carefully, only in a cooperative patient, who should be placed in the Trendelenburg position. Suction equipment must be ready in the event of abscess rupture. [90,161] The CT scan is the gold standard imaging technique, and plays a critical role in surgical decision-making. Described abnormalities are the presence of fluid-like opacities with rim enhancement, scalloping, gas collections, soft-tissue swelling, and obliterated fat planes.

11.3.2. *Treatment*

Management includes intravenous administration of antibiotics and drainage of the abscess. Intraoral approach is currently the preferred route. A needle aspiration might be a sufficient treatment when it retrieves pus. If not, the surgical procedure should be completed by incision and drainage. Most abscesses can be drained by peroral incision and suction. When the risk of airway obstruction is great, tracheostomy may be needed. External incision is required rarely, when the abscess is extending laterally to the great vessels or inferiorly towards the mediastinum. [90] However, several studies dealing with pediatric population pointed out the poor correlation between CT scan abnormalities and pus finding during the surgery [169] or reported successful treatment of CT diagnosed abscesses by antibiotics without surgery. [170]

11.4. **Danger space and prevertebral space infections**

The danger space is located posterior to the alar fascia and is bounded by the prevertebral fascia posteriorly. It is delineated superiorly by the base of the skull; inferiorly it extends through the posterior mediastinum to the diaphragm. Infections of the danger space usually develop by direct spread from adjacent spaces. Infections of danger and prevertebral space can extend throughout the posterior mediastinum and may involve the retroperitoneum. Occasionally, the purulent material from the posterior mediastinum ruptures into the pleural cavity, causing a pyothorax and secondary pleural effusions. Another feared consequence of mediastinal invasion is pericarditis with pericardial effusion and potentially tamponade. [162] The prevertebral space is the crevice between the prevertebral fascia and spinal column. It extends from the base of the skull down to the coccyx and is contiguous with the sheath of psoas muscle. Infections of the prevertebral space usually develop from hematogenic osteomyelitis/discitis of the cervical spine. They can also result from iatrogenic penetrating injuries of the trachea or esophagus. Infections of the prevertebral space behave in a different manner from infections of the retropharyngeal and danger spaces. Complications commonly arise from spinal epidural cord compression resulting in paralysis. They can also lead to psoas muscle abscess, because of the open communication of the prevertebral space down to the psoas muscle. Infections of the vertebrae or disc may cause local destruction with mechanical instability of the spine. [162]

11.5. Bezold's abscess

Bezold's abscess occurs when a purulent mastoiditis erodes the bone of the mastoid tip. The infection process is prevented from reaching the skin surface by the intervening neck musculature. When left untreated, the pus can track along the fascial planes of the digastric or sternocleidomastoid muscles and spread downward to the carotid sheath. The classic Bezold's abscess was first reported in 1881 following a cadaver study in which pus was found to track from the medial side of the mastoid process through the incisura digastrica. Treatment consists of incision and drainage of neck abscess and elimination of mastoid infection in addition to wide spectrum antibiotics. [171] (Figure 22)

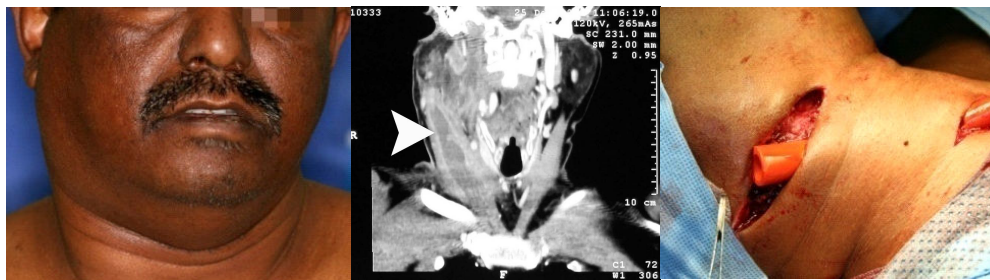

Figure 22. A. Patient treated for otitis media developed painful neck swelling with torticollis. B. CT examination revealed abscess cavity involving the right sternocleidomastoid muscle. C. The abscess was drained from two neck incisions placed in skin creases.

11.6. Cervical Necrotizing Fasciitis

Cervical necrotizing fasciitis (CNF) is a rapidly progressing destructive, polymicrobial infection that spreads alongside deep fascial planes of the neck. It most frequently develops from odontogenic sources, but can be also caused by progression of tonsillar and pharyngeal abscesses, injury to the tissues by a foreign body or catheterization, and postoperative wound infections. If not treated promptly and radically, it can reach the thorax and develop into descending necrotizing mediastinitis. CNF complicated by mediastinitis has 41% mortality according to the recent literature review. [172] (Figure 23)

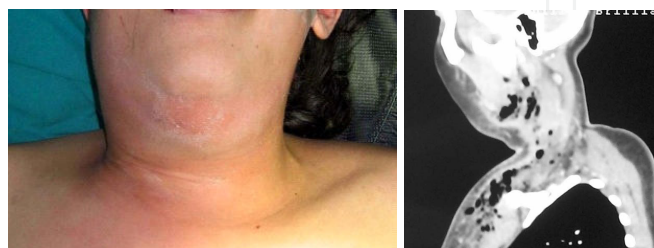

Figure 23. Fig. 23. A. Involvement of neck and upper chest wall with necrotizing fasciitis. B. CT scan shows extensive hallmark gas formation.

General principles of diagnosis and management of NF are described in the previous section dealing with facial skin infections. Early aggressive incision and drainage and debridement, along with close surveillance with repeat CT scans and retreatment, when indicated, are compulsory if any chances for favorable outcome are to be retained. No definitive treatment for descending necrotizing mediastinitis has been established. The primary treatment currently involves drainage through a combined cervical and thoracic approach, although some authors believe that cervical drainage alone is sufficient. [173]

Author details

Petr Schütz* and Hussein Hassan Hamed Ibrahim

*Address all correspondence to: petrschutz@yahoo.com

Al-Adan Dental Center, Al-Adan Hospital, Ministry of Health, State of Kuwait

References

- [1] Torok ME, Conlon CP: Skin and soft tissue infections. *Medicine* 2009;37(11) 603-609.
- [2] Ferrieri P, Dajani AS, Wannamaker LW, Chapman SS. Natural history of impetigo. I. Site sequence of acquisition and familial patterns of spread of cutaneous streptococci. *The Journal of Clinical Investigation* 1972;51(11) 2851-2862.
- [3] Stevens DL, Bisno AL, Chambers HF, Everett ED, Dellinger P, Goldstein EJC et al.: Practice guidelines for the diagnosis and management of skin and soft-tissue infections. *Clinical Infectious Diseases* 2005;41(10) 1373-1406.
- [4] Hirschmann JV. Impetigo: etiology and therapy. *Current Clinical Topics in Infectious Diseases* 2002;229(1) 42-51.
- [5] Darmstadt GL, Lane AT. Impetigo: an overview. *Pediatric Dermatology*. 1994;11(4) 293-303.
- [6] Gregory DW, Schaffner W. Pseudomonas infections associated with hot tubs and other environments. *Infectious Disease Clinics of North America* 1987;1(3) 635-648.
- [7] Nervi SJ, Schwartz RA, Dmochowski M. Eosinophilic pustular folliculitis: a 40 year retrospect. *Journal of the American Academy of Dermatology* 2006;55(2) 285-289.
- [8] Duvic M. EGFR inhibitor-associated acneiform folliculitis: assessment and management. *American Journal of Clinical Dermatology* 2008;9(5) 285-294.
- [9] May AK. Skin and soft tissue infections. *The Surgical Clinics of North America* 2009;89(2) 403-420.

- [10] Zimbelman J, Palmer A, Todd J. Improved outcome of clindamycin compared with beta-lactam antibiotic treatment for invasive *Streptococcus pyogenes* infection. *The Pediatric Infectious Disease Journal* 1999;18(12) 1096–1100.
- [11] Zimakoff J, Rosdahl VT, Petersen W, Scheibel J. Recurrent staphylococcal furunculosis in families. *Scandinavian Journal of Infectious Diseases* 1988;20(4) 403–5.
- [12] Raz R, Miron D, Colodner R, Staler Z, Samara Z, Keness Y. A 1-year trial of nasal mupirocin in the prevention of recurrent staphylococcal nasal colonization and skin infection. *Archives of Internal Medicine* 1996;156(10) 1109–1112.
- [13] Swartz MN. Clinical practice. Cellulitis. *The New England Journal of Medicine* 2004;350(9) 904–912.
- [14] Hepburn MJ, Dooley DP, Skidmore PJ, Ellis MW, Starnes WF, Hasewinkle WC. Comparison of short-course (5 days) and standard (10 days) treatment for uncomplicated cellulitis. *Archives of Internal Medicine* 2004;164(15) 1669–1674.
- [15] Bisno AL, Stevens DL. Streptococcal infections in skin and soft tissues. *The New England Journal of Medicine* 1996;334(4) 240–245.
- [16] Green RJ, Dafoe DC, Raffin TA. Necrotizing fasciitis. *Chest* 1996;110(1) 219–229.
- [17] Elliott DC, Kufera JA, Myers RA. Necrotizing soft tissue infections: risk factors for mortality and strategies for management. *Annals of Surgery* 1996;224(5) 672–683.
- [18] Brook I, Frazier EH. Clinical and microbiological features of necrotizing fasciitis. *Journal of Clinical Microbiology* 1995;33(9) 2382–2387.
- [19] Shindo ML, Nalbone VP, Dougherty WR. Necrotizing fasciitis of the face. *Laryngoscope* 1997;107(8) 1071–1079.
- [20] Panda NK, Simadri S, Sridhara SR. Cervicofacial necrotizing fasciitis: can we expect a favourable outcome? *The Journal of Laryngology and Otology* 2004;118(10) 771–777.
- [21] Schurr C, Burghartz M, Miethke T, Kesting M, Hoang N, Staudenmaier R. Management of facial necrotizing fasciitis. *European Archives of Oto-rhino-laryngology* 2009;266(3) 325–331.
- [22] Krenk L, Nielsen HU, Christensen ME. Necrotizing fasciitis in the head and neck region: an analysis of standard treatment effectiveness. *European Archives of Oto-rhino-laryngology* 2007;264(8) 917–922.
- [23] Buck DW 2nd, Alam M, Kim JY. Injectable fillers for facial rejuvenation: A review. *Journal of Plastic, Reconstructive & Aesthetic surgery* 2009; 62(1) 11-18.
- [24] Lahiri A, Waters R. Experience with Bio-Alcamid, a new soft tissue endoprosthesis. *Journal of Plastic, Reconstructive & Aesthetic surgery* 2007;60(6) 663-667.
- [25] Davis EC, Callender VD. Aesthetic dermatology for aging ethnic skin. *Dermatologic Surgery* 2011;37(7) 901- 917.

- [26] Christensen LH. Normal and pathologic tissue reactions to soft tissue gel fillers. *Dermatologic Surgery* 2007;33(Suppl 2) 168-175.
- [27] Monheit GD, Rohrich RJ. The nature of long-term fillers and the risk of complications. *Dermatologic Surgery* 2009;35(Suppl 2) 1598-1604.
- [28] Kwon D-Y, Park MH, Koh S-B, Dhong E-S, Baek S-H, Ryu HJ, Park KW. Multiple arterial embolism after illicit intranasal injection of collagenous material. *Dermatologic Surgery* 2010;36(7) 1196-1199.
- [29] Sclafani AP, Fagien F. Treatment of injectable soft tissue filler complications. *Dermatologic Surgery* 2009;35(Suppl 2) 1672-1680.
- [30] Ficarra G, Mosqueda-Taylor A, Carlos R. Silicone granulomas of the facial tissues: A report of seven cases. *Oral Surgery, Oral Medicine, Oral Pathology, Oral Radiology, and Endodontics* 2002;94(1) 65-73.
- [31] Lombardi T, Samson J, Plantier F, Husson C, Küffer R. Orofacial granulomas after injection of cosmetic fillers. Histopathologic and clinical study of 11 cases. *Journal of Oral Pathology & Medicine* 2004;33(2) 115-120.
- [32] Poveda R, Bagan JV, Murillo J, Jimenez J. Granulomatous facial reaction to injected cosmetic fillers - a presentation of five cases. *Medicina Oral, Patología Oral y Cirugía Bucal* 2006;11(1) E1-5.
- [33] Karagozoglu H, van der Waal I. Polyacrylamide soft tissue filler nodule mimicking a mucoepidermoid carcinoma. *International Journal of Oral and Maxillofacial surgery* 2008;37(6) 578-580.
- [34] Jham BC, Nikitakis NG, Scheper MA, Papadimitriou JC, Levy BA, Rivera H. Granulomatous foreign-body reaction involving oral and perioral tissues after injection of biomaterials: A series of 7 cases and review of the literature. *Journal of Oral and Maxillofacial Surgery* 2009;67(2) 280-285.
- [35] Rohrich RJ, Monheit G, Nguyen AT, Brown SA, Fagien S. Soft-tissue filler complications: The important role of biofilms. *Plastic and Reconstructive Surgery* 2010;125(4) 1250- 256.
- [36] Costerton JW, Steward PS, Greenberg EP. Bacterial biofilms: a common cause of persistent infections. *Science* 1999; 284(5418) 1318-1322.
- [37] Rohrich RJ, Nguyen AT, Kenkel JM: Lexicon for soft tissue implants. *Dermatologic Surgery* 2009;35(Suppl 2) 1605-1611.
- [38] Christensen LH. Host tissue interaction, fate, and risks of degradable and nondegradable gel fillers. *Dermatologic Surgery* 2009;35(Suppl 2) 1612-1619.
- [39] Lemperle G, Nicolau P, Scheiermann N. Is there any evidence for biofilms in dermal fillers? *Plastic and Reconstructive Surgery* 2011;128(2) 84e-85e.

- [40] Schütz P, Ibrahim HH, Hussain SS, Ali TS, El-Bassuoni K, Thomas J. Infected facial tissue fillers: Case series and review of the literature. *Journal of Oral and Maxillofacial Surgery* 2012;doi:10.1016/j.joms.2011.11.014
- [41] Shelke LW, Van Den Elzen H, Erkamp PPM, Neumann HAM. Use of ultrasound to provide overall information on facial fillers and surrounding tissue. *Dermatologic Surgery* 2010;36(Suppl 3) 1843-1851.
- [42] Wortsman X, Wortsman J, Orlandi C, Cardenas G, Sazunic I, Jemec GBE. Ultrasound detection and identification of cosmetic fillers in the skin. *Journal of the European Academy of Dermatology and Venereology* 2012;26(3) 292-301.
- [43] Wilson YSH, Ellis DAF. Large needle suction aspiration of permanent fillers. *Laryngoscope* 2011;121(10) 2146-2149.
- [44] Requena L, Requena C, Christensen L, Zimmermann US, Kutzner H, Cerroni L. Adverse reactions to injectable soft tissue fillers. *Journal of the American Academy of Dermatology* 2011;64(1) 1-34.
- [45] Gosche JR, Vick L. Acute, subacute, and chronic cervical lymphadenitis in children. *Seminars in Pediatric Surgery*. 2006;15(2) 99-106.
- [46] Darville T, Jacobs RF. Lymphadenopathy, lymphadenitis and lymphangitis. In: Jenson HB, Baltimore RS (eds.) *Pediatric Infectious Diseases: Principles and Practice*, 2nd edition, Philadelphia: Saunders, 2002. p610-629.
- [47] Breitschwerdt EB, Kordick DL. Bartonella infection in animals: carriership, reservoir, potential, pathogenicity, and zoonotic potential for human infection. *Clinical Microbiology Reviews* 2000;13(3) 428-438.
- [48] Anderson BE, Neuman MA. Bartonella spp. as emerging human pathogens. *Clinical Microbiology Reviews* 1997;10(2) 203-219.
- [49] Bass JW, Freitas BC, Freitas AD, Sisler CL, Chan DS, Vincent JM, Person DA, Claybaugh JR, Wittler RR, Weisse ME, Regnery RL, Slater LN.. Prospective randomized double blind placebo-controlled evaluation of azithromycin for treatment of cat-scratch disease. *The Pediatric Infectious Disease Journal* 1998;17(6) 447-452.
- [50] Shapiro DS, Schwartz DR. Exposure of Laboratory Workers to Francisella tularensis despite a bioterrorism procedure. *Journal of Clinical Microbiology* 2002;40(6) 2278-2281.
- [51] Ellis J, Oyston PCF, Green M, W. Titball RW. Tularemia. *Clinical Microbiology Reviews* 2002;15(4) 631-646.
- [52] Risi GF, Pombo DJ. 1995. Relapse of tularemia after aminoglycoside therapy — case report and discussion of therapeutic options. *Clinical Infectious Diseases* 1995;20(1) 174-175.
- [53] Euerle B. Syphilis. <http://emedicine.medscape.com/article/229461-overview> (accessed 17 July 2012)

- [54] Scott CM, Flini SR. Oral syphilis - re-emergence of an old disease with oral manifestations. *International Journal of Oral and Maxillofacial Surgery* 2005;34(1) 58-63.
- [55] Compilato D, Amato S, Campisis G. Resurgence of syphilis: a diagnosis based on unusual oral mucosa lesions. *Oral Surgery, Oral Medicine, Oral Pathology, Oral Radiology, and Endodontics* 2009;108(3) e45-e49.
- [56] [Guideline] Workowski KA, Berman S. Sexually transmitted diseases treatment guidelines, 2010. *MMWR. Recommendations and reports : Morbidity and mortality weekly report. Recommendations and reports / Centers for Disease Control* 2010;59(RR-12) 1-110.
- [57] Odumade OA, Hogquist KA, Balfour HH Jr. Progress and problems in understanding and managing primary Epstein-Barr virus infections. *Clinical Microbiology Reviews* 2011;24(1) 193-209.
- [58] David Lawee. Mild infectious mononucleosis presenting with transient mixed liver disease. Case report with a literature review. *Canadian Family Physician* 2007;53(8) 1314-1316.
- [59] Ezike E. Pediatric rubella. <http://emedicine.medscape.com/article/968523-overview> (accessed 10 July 2012).
- [60] Castillo-Solorzano C, Carrasco P, Tambini G, Reef S, Brana M, de Quadros CA. New horizons in the control of rubella and prevention of congenital rubella syndrome in the Americas. *The Journal of Infectious Diseases* 2003;187(Suppl 1) 146-152.
- [61] Kim K, Weiss LM. Toxoplasma: the next 100 years. *Microbes and Infection* 2008;10(9) 978-984.
- [62] McCabe RE, Brooks RG, Dorfman RF, Remington JS. Clinical spectrum in 107 cases of toxoplasmic lymphadenopathy. *Reviews of Infectious Diseases* 1987;9(4) 754-774.
- [63] Taila AK, Hingwe AS, Johnson LEI. Toxoplasmosis in a patient who was immunocompetent: a case report. *Journal of Medical Case Reports* 2011;5:16 <http://www.jmedicalcasereports.com/content/5/1/16> (accessed 3 August 2012)
- [64] World Health Organization: Global tuberculosis control: WHO report 2011. http://www.who.int/tb/publications/global_report/2011/gtbr11_full.pdf (accessed 7 May 2012).
- [65] Sharma SK, Mohan A:. Extrapulmonary tuberculosis. *The Indian Journal of Medical Research* 2004;120(4) 316-354.
- [66] Peto HM, Pratt RH, Harrington TA, LoBue PA, Armstrong LR. Epidemiology of extrapulmonary tuberculosis in the United States,1993-2006. *Clinical Infectious Diseases* 2009;49(9) 1350-1357.
- [67] Helbling CA, Lieger O, Smolka W, Iizuka T, Kuttenger J. Primary tuberculosis of the TMJ: Presentation of a case and literature review. *International Journal of Oral and Maxillofacial Surgery* 2010;39(8) 834-838.

- [68] Prasad KC, Sreedharan S, Chakravarthy Y, Prasad SC. Tuberculosis in the head and neck: Experience in India. *Journal of Laryngology and Otology* 2007;121(10) 979-985.
- [69] Nalini B, Vinayak S. Tuberculosis in ear, nose, and throat practice: its presentation and diagnosis. *American Journal of Otolaryngology* 2006;27(1) 39-45.
- [70] Nohrström E, Kentala E, Kuusela P, Mattila PS: Tuberculosis of the head and neck in Finland. *Acta Oto-laryngologica* 2007;127(7) 770-774.
- [71] Menon K, Bem C, Goulesbrough D, Strachan DR. A clinical review of 128 cases of head and neck tuberculosis presenting over a 10-year period in Bradford, UK. *Journal of Laryngology and Otology*. 2007;121(4) 362-368.
- [72] Pekiner FN, Erseven G, Borahan MO, Gümrü B: Natural barrier in primary tuberculosis inoculation: oral mucous membrane. *The International Journal of Tuberculosis and Lung Disease* 2006;10(12) 1418.
- [73] Wang WC, Chen JY, Chen YK, Lin LM. Tuberculosis of the head and neck: A review of 20 cases. *Oral Surgery, Oral Medicine, Oral Pathology, Oral Radiology, and Endodontics* 2009;107(3) 381-386.
- [74] Andrade NN, Mhatre TS. Orofacial Tuberculosis—A 16-Year Experience With 46 Cases. *Journal of Oral and Maxillofacial Surgery* 2012;70(1) e12-e22.
- [75] Kreiner M. Tuberculosis of the temporomandibular joint: Low prevalence or missed diagnosis? *Journal of Craniomandibular Practice* 2006;24(4) 234.
- [76] Ranganathan, LK, Mathew GC, Gandhi S, Manohar M. Tuberculosis of temporomandibular joint presenting as swelling in the preauricular region. *Journal of Oral and Maxillofacial Surgery* 2012;70(1) e28-31.
- [77] Gandhi S, Ranganathan LK, Bither S, Koshy G. Tuberculosis of temporomandibular joint: a case report. *Journal of Oral and Maxillofacial Surgery* 2011;69(6) e128-130.
- [78] Weiler Z, Nelly P, Baruchin AM, Oren S. Diagnosis and treatment of cervical tuberculous lymphadenitis. *Journal of Oral and Maxillofacial Surgery* 2000;58(5) 477-481.
- [79] Polesky A, Grove W, Bhatia G. Peripheral tuberculous lymphadenitis: epidemiology, diagnosis, treatment, and outcome. *Medicine (Baltimore)* 2005;84(6) 350-362.
- [80] Falkinham JO 3rd. Epidemiology of infection by nontuberculosis mycobacteria. *Clinical Microbiology Reviews* 1996;9(2) 177-215.
- [81] Griffith DE, Aksamit T, Brown-Elliott BA, Catanzaro A, Daley C, Gordin F, Holland SM, Horsburgh R, Huitt G, Iademarco MF, Iseman M, Olivier K, Ruoss S, von Reyn CF, Wallace RJ Jr, Winthrop K; ATS Mycobacterial Diseases Subcommittee; American Thoracic Society; Infectious Disease Society of America. An official ATS/IDSA statement: diagnosis, treatment, and prevention of nontuberculous mycobacterial disease. *American Journal of Respiratory and Critical Care Medicine* 2007;175(4) 367-416.

- [82] Penn R, Steehler MK, Sokohl A, Harley EH. Nontuberculous mycobacterial cervicofacial lymphadenitis - a review and proposed classification system. *International Journal of Pediatric Otorhinolaryngology* 2011;75(12) 1599–1603.
- [83] Lindeboom JA, Prins JM, Bruijnesteijn van Coppenraet ES, Lindeboom R, Kuijper EJ. Cervicofacial lymphadenitis in children caused by *Mycobacterium haemophilum*. *Clinical Infectious Diseases* 2005;41(11) 1569–1575.
- [84] Lindeboom JA, Kuijper EJ, Bruijnesteijn van Coppenraet ES, Prins JM. First case of an oculofacial lesion due to *Mycobacterium haemophilum* infection in an immunocompetent child. *Oral Surgery, Oral Medicine, Oral Pathology, Oral Radiology, and Endodontics* 2006;101(6) 774–776.
- [85] Robson CD, Hazra R, Bames PD, Robertson RL, Jones D, Husson RN. Nontuberculous mycobacterial infection of the head and neck in immunocompetent children: CT and MR findings. *American Journal of Neuroradiology* 1999;20(10) 1829–1835.
- [86] Lindeboom JA, Kuijper EJ, Prins JM, Bruijnesteijn van Coppenraet ES, Lindeboom R, Prins JM. Surgical excision versus antibiotic treatment for nontuberculous mycobacteria cervical lymphadenitis in children: a multicenter randomized, controlled trial. *Clinical Infectious Diseases* 2007;44(8) 1057–1064.
- [87] Lindeboom JA. Surgical treatment for nontuberculous mycobacterial (NTM) cervicofacial lymphadenitis in children. *Journal of Oral Maxillofacial Surgery* 2012;70(2) 345–348.
- [88] Fox PC. Bacterial infections of salivary glands. *Current opinion in dentistry* 1991;1(4) 411–414.
- [89] McQuone SJ. Acute viral and bacterial infections of the salivary glands. *Otolaryngologic Clinics of North America* 1999;32(5) 793–811.
- [90] Brook I. Non-odontogenic abscesses in the head and neck region. *Periodontology* 2000, Vol. 49, 2009, 106–125
- [91] Brook I. The bacteriology of salivary gland infections. *Oral and Maxillofacial Surgery Clinics of North America* 2009;21(3) 269–274.
- [92] Kane WJ, McCaffrey TV: Infectious Diseases of the Salivary Glands. In: Cummings CW, Fredrickson JE, Harker LA, Krause C, and Schuller D. (eds.) *Otolaryngology-Head and Neck Surgery*, St. Louis: C.V. Mosby; 1991.
- [93] Rice DH. Chronic inflammatory disorders of the salivary glands. *Otolaryngologic clinics of North America* 1999;32(5) 813–818.
- [94] Templer JW. Parotitis. <http://emedicine.medscape.com/article/882461-overview> (accessed 18 August 2012).
- [95] Mandel L. Differentiating acute suppurative parotitis from acute exacerbation of a chronic parotitis: Case reports. *Journal of Oral and Maxillofacial surgery* 2008;66 1964–1968.

- [96] Kiverniti E, Singh A, Clarke P. Küttner's tumour: an unusual cause of salivary gland enlargement. *Hippokratia* 2008;12(1): 56-58.
- [97] Kalinowski M, Heverhagen JT, Rehberg E, Klose KJ, Wagner H-J. Comparative study of MR sialography and digital subtraction sialography for benign salivary gland disorders. *American Journal of Neuroradiology* 2001;23(10) 1485-1492.
- [98] Qi S, Liu X, Wang S. Sialoendoscopic and irrigation findings in chronic obstructive parotitis. *Laryngoscope*. 2005;115(3) 541-545.
- [99] Yu C, Zheng L, Yang C, Shen N. Causes of chronic obstructive parotitis and management by sialoendoscopy. *Oral Surgery, Oral Medicine, Oral Pathology, Oral Radiology, and Endodontics*. 2008;105(3) 365-370.
- [100] Sharma R. Superficial parotidectomy for chronic parotid sialadenitis. *International Journal of Oral and Maxillofacial Surgery* 2012; <http://dx.doi.org/10.1016/j.ijom.2012.04.003>
- [101] Sitheewue M, Sivachandran Y, Varathan V, Ariawardana A, Ranasinghe A. Juvenile recurrent parotitis: clinical, sialographic and ultrasonographic features. *International Journal of Pediatric Dentistry* 2007;17(2) 98-104.
- [102] Kolho KL, Saarinen R, Paju A, Stenman J, Stenman UH, Pitkäranta A. New insights into juvenile parotitis. *Acta Paediatrica* 2005;94(11) 1566-1570.
- [103] Reid E, Douglas F, Crow Y, Hollman A, Gibson J. Autosomal dominant juvenile recurrent parotitis. *Journal of Medical Genetics* 1998;35 417-419.
- [104] Katz P, Hartl DM, Guerre A. Treatment of juvenile recurrent parotitis. *Otolaryngologic Clinics of North America* 2009;42(6) 1087-1091.
- [105] Hviid A, Rubin S, Mühlemann K. Mumps. *Lancet*. 2008;371(9616) 932-944.
- [106] Even-Tov E, Niv A, Kraus M, Nash M. Candida parotitis with abscess formation. *Acta Oto-laryngologica* 2006;126(3) 334-336.
- [107] Leibowitz JM, Montone KT, Basu D. Warthin tumor presenting as a fungal abscess in an immunocompetent host: case report and review of the literature. *Head & Neck* 2010;32(1) 133-136.
- [108] Goyal A, Tyagi I, Syal R, Marak RS, Singh J. Apophysomyces elegans causing acute otogenic cervicofacial zygomycosis involving salivary glands. *Medical Mycology* 2007;45(5) 457-461.
- [109] Chandu A, MacIsaac RJ, MacGregor DP, Campbell MC, Wilson MJ, Bach LA. A case of mucormycosis limited to the parotid gland. *Head & neck*. 2005;27(12) 1108-1111.
- [110] Hadi U, Rameh C. Intraglandular toxoplasmosis of the parotid gland pre- or postoperative diagnosis? *American Journal of Otolaryngology* 2007;28(3) 201-204.

- [111] Tsai YT, Yeh CJ, Chen YA, Chen YW, Huang SF. Bilateral parotid abscesses as the initial presentation of strongyloidiasis in the immunocompetent host. *Head & Neck*. 2012;34(7) 1051-1054.
- [112] Ah-See KW, Evans AS. Sinusitis and its management. *British medical journal* 2007;334(7589) 358-361.
- [113] Meltzer EO, Hamilos DL. Rhinosinusitis diagnosis and management for the clinician: a synopsis of recent consensus guidelines. *Mayo Clinic proceedings* 2011;86(5)427-443.
- [114] Patel NA, Ferguson BJ. Odontogenic sinusitis: an ancient but underappreciated cause of maxillary sinusitis. *Current Opinion in Otolaryngology & Head & Neck Surgery* 2012, 20(1) 24–28.
- [115] Fokkens W, Lund V, Bachert C, Clement P, Hellings P, Holmstrom M, Jones N, Kallerga L, Kennedy D, Kowalski M, Malmberg H, Mullol J, Passali D, Stammberger H, Stierna P; EAACI. EAACI position paper on rhinosinusitis and nasal polyps executive summary. *Allergy* 2005;60(5) 583-601.
- [116] Karaman E, Hacizade Y, Isildak H, Kaytaz . Pott's puffy tumor. *The Journal of Craniofacial Surgery* 2008;19(6) 1694-1697.
- [117] Lang EE, Curran AJ, Patil N, Walsh RM, Rawluk D, Walsh MA. Intracranial complications of acute frontal sinusitis. *Clinical Otolaryngology and Allied Sciences* 2001;26(6) 452-457.
- [118] Mandal R, Patel N, Ferguson BJ. Role of antibiotics in sinusitis. *Current Opinion in Infectious Diseases* 2012;25(2) 183–192.
- [119] Williamson IG, Rumsby K, Bengt S, Moore M, Smith PV, Cross M, Little P. Antibiotics and topical nasal steroid for treatment of acute maxillary sinusitis: a randomized controlled trial. *Journal of the American Medical Association*. 2007;298(21) 2487-2496.
- [120] Blake FAS, Siegert J, Wedl J, Gbara A, Schmelzle R: The acute orbit: etiology, diagnosis, and therapy. *Journal of Oral and Maxillofacial Surgery* 2006;64(1) 87-93.
- [121] Schwarz G. Etiology, diagnosis, and treatment of orbital infections. *Current Infectious Disease Reports* 2002;4(3) 201–205.
- [122] Vairaktaris E, Moschos MM, Vassiliou S, Baltatzis S, Kalimeras E, Avgoustidis D, Pappas Z, Moschos MN. Orbital cellulitis, orbital subperiosteal and intraorbital abscess. Report of three cases and review of the literature. *Journal of Cranio-maxillofacial surgery* 2009;37(3) 132-136.
- [123] Thakar A, Tandon DA, Thakar MD, Nivsarkar S. Orbital cellulitis revisited. *Indian Journal of Otolaryngology Head & Neck Surgery* 2000;52(3) 235-242. *an Journal of Otolaryngology and Head and Neck Surgery* Vol. 52 No. 3, July - 0

- [124] Moloney JR, Badham NJ, McRae A. The acute orbit. Preseptal (periorbital) cellulitis, subperiosteal abscess and orbital cellulitis due to sinusitis. *Journal of Laryngology and Otology*. Supplement 1987;12 1-18.
- [125] O’Ryan F, Diloreto D, Barber HD, Bruckner R. Orbital infections: diagnosis and surgical treatment. *Journal of Oral and Maxillofacial Surgery* 1988;46(11) 991-997.
- [126] De Wyngaert R, Casteels I, Demaerel P. Orbital and anterior visual pathway infection and inflammation. *Neuroradiology* 2009;51(6) 385–396.
- [127] Kaplan DM, Briscoe D, Gatot A, et al: The use of standardized orbital ultrasound in the diagnosis of sinus induced infections of the orbit in children: A preliminary report. *International Journal of Pediatric Otorhinolaryngology* 1999;48(2) 155-162.
- [128] Lusk R. Complications of Sinusitis. In: Mitchell RB, Pereira KD, eds. *Pediatric Otolaryngology for the Clinician*. Totowa, NJ: Humana Press; 2009.
- [129] Iatta R, Napoli C, Borghi E, Montagna MT. Rare mycoses of the oral cavity: a literature epidemiologic review. *Oral Surgery, Oral Medicine, Oral Pathology, Oral Radiology, and Endodontology* 2009;108(5) 647-655.
- [130] Anaissie EJ: *Clinical Mycology and Antifungal Therapy*. http://www.medscape.org/viewarticle/495502_print (accessed 20 August 2012)
- [131] Maartens G, Wood MJ. The clinical presentation and diagnosis of invasive fungal infections. *The Journal of Antimicrobial Chemotherapy* 1991;28(Suppl A) 13-22.
- [132] Mehrabi M, Bagheri S, Leonard MK Jr, Perciaccante VJ. Mucocutaneous manifestation of cryptococcal infection: report of a case and review of the literature. *Journal of Oral and Maxillofacial Surgery* 2005;63(10) 1543-1549.
- [133] Liew C, Barreto L, Mills C. Interesting case: An unusual case of oral ulceration. *British Journal of Oral and Maxillofacial Surgery* 2006;44(5) 350.
- [134] Kantarciğlu AS, Gulenc M, Yücel A, Uzun N, Taskin T, Sakiz D, Atlas K. Cryptococcal parotid involvement: an uncommon localization of *Cryptococcus neoformans*. *Medical Mycology* 2006;44(3) 279-278.
- [135] Scheer M, Rabbels J, Neugebauer J, Cornely OA, Drebbel U, Zöeller JE. Combined intra- and extracranial cryptococcal infection of a 20-year-old patient in right temporal area. *Journal of Oral and Maxillofacial Surgery* 2011;69(1) 222-226.
- [136] Prendiville S, Bielamowicz SA, Hawrych A, Deeb ZE. Isolated cryptococcal sphenoid sinusitis with septicemia, meningitis, and subsequent skull base osteomyelitis in an immunocompetent patient. *Otolaryngology--Head and Neck Surgery* 2000;123(3) 277-279.
- [137] Karthaus M. Prophylaxis and treatment of invasive aspergillosis with voriconazole, posaconazole and caspofungin: review of the literature. *European Journal of Medical Research* 2011;16(4) 145-152.

- [138] Fuqua TH, Sittitavornwong S, Knoll M, Said-Al-Naief N. Primary invasive oral aspergillosis: an updated literature review. *Journal of Oral and Maxillofacial Surgery* 2010;68(10) 2557-2563.
- [139] Costa F, Polini F, Zerman N, Robiony M, Toro C, Politi M. Surgical treatment of Aspergillus mycetomas of the maxillary sinus: Review of the literature. *Oral Surgery, Oral Medicine, Oral Pathology, Oral Radiology, and Endodontology* 2007;103(6) e23-e29.
- [140] Bigliazzi C, Poletti V, Dell'Amore D, Saragoni L, Colby TV. Disseminated basidiobolomycosis in an immunocompetent woman. *Journal of Clinical Microbiology* 2004;42(3) 1367-1369.
- [141] Ribes JA, Vanover-Sams CL, Baker DJ. Zygomycetes in human disease. *Clinical Microbiology Reviews* 2000;13(2) 236-301.
- [142] Nithyanandam S, Jacob MS, Battu RR, Thomas RK, Correa MA, D'Souza O. Rhino-orbito-cerebral mucormycosis. A retrospective analysis of clinical features and treatment outcomes. *Indian Journal of Ophthalmology* 2003;51(3) 231-236.
- [143] Pagano L, Offidani M, Fianchi L, Nosari A, Candoni A, Piccardi M, Corvatta L, D'Antonio D, Girmenia C, Martino P, Del Favero A; GIMEMA (Gruppo Italiano Malattie EMatologiche dell'Adulto) Infection Program. Mucormycosis in hematologic patients. *Haematologica* 2004;89(2) 207-214.
- [144] Verma GR, Lobo DR, Walker R, Bose SM, Gupta KL. Disseminated mucormycosis in healthy adults. *Journal of Postgraduate Medicine* 1995;41(2) 40-42.
- [145] Schütz P, Behbehani JH, Khan ZU, Ahmad S, Kazem MA, Dhar R, Eskaf W, Hamed HH and Cunnigham L, Jr.: Fatal rhino-orbito-cerebral zygomycosis caused by *Apophysomyces elegans* in a healthy patient: clinical therapeutic conference. *Journal of Oral Maxillofacial Surgery*, 2006;(64)12 1795-1802.
- [146] Roden MM, Zaoutis TE, Buchanan WL, Knudsen TA, Sarkisova TA, Schaufele RL, Sein M, Sein T, Chiou CC, Chu JH, Kontoyiannis DP, Walsh TJ. Epidemiology and outcome of zygomycosis: a review of 929 reported cases. *Clinical Infectious Diseases* 2005;41(5) 634-653.
- [147] Fairley C, Sullivan TJ, Bartley P, Allworth T, Lewandowski R. Survival after rhino-orbital-cerebral mucormycosis in an immunocompetent patient. *Ophthalmology* 2000;107(3) 555-558.
- [148] Dhiwakar M, Thakar A, Bahadur S. Improving outcomes in rhinocerebral mucormycosis—early diagnostic pointers and prognostic factors. *Journal of Laryngology and Otology* 2003;117(11) 861-865.
- [149] Adler-Moore J, Proffit TR: AmBisome. Liposomal formulation, structure, mechanism of action and preclinical experience. *The Journal of Antimicrobial Chemotherapy* 2002;49(Suppl 1) 21-30.

- [150] Page RL 2nd, Schwiesow J, Hilts A. Posaconazole as salvage therapy in a patient with disseminated zygomycosis: case report and review of the literature. *Pharmacotherapy* 2007;27(2) 290-298.
- [151] Adler DE, Milhorat TH, Miller JI. Treatment of rhinocerebral mucormycosis with intravenous, interstitial and cerebrospinal fluid administration of amphotericin B: Case report. *Neurosurgery* 1998;42(3) 644-648.
- [152] Islam MN, Cohen DM, Celestina LJ, Ojha J, Claudio R, Bhattacharyya IB. Rhinocerebral zygomycosis: an increasingly frequent challenge: update and favorable outcomes in two cases. *Oral Surgery, Oral medicine, Oral Pathology, Oral Radiology, and Endodontology* 2007;104(5) e28-e34.
- [153] Cano MV, Hajjeh RA. The epidemiology of histoplasmosis: a review. *Seminars in Respiratory Infections* 2001;16(2) 109-18.
- [154] Woods JP, Heinecke EL, Luecke JW, Maldonado E, Ng JZ, Retallack DM, Timmerman MM. Pathogenesis of *Histoplasma capsulatum*. *Seminars in Respiratory Infections* 2001;16(2) 91-101.
- [155] Scully C, Almeida OP. Orofacial manifestations of the systemic mycoses. *Journal of Oral pathology and Medicine* 1992;21(7) 289-94.
- [156] Akin L, Herford AS, Cicciù M. Oral presentation of disseminated histoplasmosis: A case report and literature review. *Journal of Oral and Maxillofacial Surgery* 2011 ; 69(2) 535-541.
- [157] Mignogna MD, Fedele S, Lo Russo L, Ruoppo E, Lo Muzio LA. A case of oral localized histoplasmosis in an immunocompetent patient. *European Journal of Clinical Microbiology & Infectious Diseases* 2001;20(10) 753-5.
- [158] Rahman MT, Bakar NH, Philip R, Shamsudin AR. Oral histoplasmosis presenting as oral ulcer in a non-HIV patient. *The Southeast Asian Journal of Tropical Medicine and Public Health* 2004;35(2) 388-390.
- [159] Johnson JA, Loyd JE, Wheat LJ, Netterville JL. A case series and review of histoplasmosis infection in the neck. *Archives of Otolaryngology--Head & Neck surgery* 2010;136(9) 916-919.
- [160] Brook I. Microbiology and management of peritonsillar, retropharyngeal, and parapharyngeal abscesses. *Journal of Oral and Maxillofacial Surgery* 2004;62(12) 1545-1550.
- [161] Sakaguchi M, Sato S, Ishiyama T, Katsuno S, Taguchi K. Characterization and management of deep neck infections. *International Journal of Oral and Maxillofacial Surgery* 1997;26(2) 131-4.
- [162] Reynolds SC, Chow AV. Life-threatening infections of the peripharyngeal and deep fascial spaces of the head and neck. *Infectious Disease Clinics of North America* 2007;21(2) 557-576

- [163] Dool H, Soetekouw R, van Zanten M, Grooters E. Lemierre's syndrome: three cases and a review. *European Archives of Oto-rhino-laryngology* 2005;262(8) 651–4.
- [164] Singh I, Meher R, Agarwal S, Raj A. Carotid artery erosion in a 4-year child. *International Journal of Pediatric Otorhinolaryngology* 2003;67(9) 995–998.
- [165] Sichel JY, Attal P, Hocwald E, Eliashar R. Redefining parapharyngeal space infections. *The Annals of Otology, Rhinology, and Laryngology* 2006;115(920) 117–123.
- [166] Boscolo-Rizzo P, Marchiori C, Zanetti F, Vaglia A, Da Mosto MC. Conservative management of deep neck abscesses in adults: the importance of CECT findings. *Otolaryngology--Head and Neck surgery* 2006;135(6) 894–899.
- [167] Chang L, Chi H, Chiu NC, Huang FY, Lee KS. Deep neck infections in different age groups of children. *Journal of Microbiology, Immunology, and Infection* 2010;43(1) 47–52.
- [168] Harkani A, Hassani R, Ziad T, Aderdour L, Nouri H, Rochdi Y, Raji A. Retropharyngeal abscess in adults: Five case reports and review of the literature. *ScientificWorldJournal* 2011;11 1623–1629.
- [169] Hoffmann C, Pierrot S, Contencin P, Morisseau-Durand MP, Manach Y, Couloigner V. Retropharyngeal infections in children. Treatment, strategies and outcomes. *International Journal of Pediatric Otorhinolaryngology* 2011;75(9) 1099–1103.
- [170] McClay JE, Murray AD, Booth T: Intravenous antibiotic therapy for deep neck abscesses defined by computed tomography. *Archives of Otolaryngology--Head & Neck Surgery* 2003;129(11) 1207–1212.
- [171] Uchida Y, Ueda H, Nakashima T. Bezold's abscess arising with recurrent cholesteatoma 20 years after the first surgery: with a review of the 18 cases published in Japan since 1960. *Auris, Nasus, Larynx* 2002;29(4) 375–378.
- [172] Sarma T, Sengupta T, Miloro M, Kolokythas A. Cervical necrotizing fasciitis with descending mediastinitis: literature review and case report. *Journal of Oral and Maxillofacial surgery* 2011;70(6) 1342–1350.
- [173] Roccia F, Pecorari GC, Oliaro A, Passet E, Rossi P, Nadalin J, Garzino-Demo P, Berone S. Ten years of descending necrotizing mediastinitis: management of 23 cases. *Journal of Oral and Maxillofacial Surgery* 2007;65(9) 1716–24.