

We are IntechOpen, the world's leading publisher of Open Access books Built by scientists, for scientists

6,900

Open access books available

186,000

International authors and editors

200M

Downloads

Our authors are among the

154

Countries delivered to

TOP 1%

most cited scientists

12.2%

Contributors from top 500 universities



WEB OF SCIENCE™

Selection of our books indexed in the Book Citation Index
in Web of Science™ Core Collection (BKCI)

Interested in publishing with us?
Contact book.department@intechopen.com

Numbers displayed above are based on latest data collected.
For more information visit www.intechopen.com



Role of Endoscopic Sinus Surgery in Pediatric Acute Complicated Sinusitis

Timothy P. McEvoy, Charles A. Elmaraghy and
Kris R. Jatana

Additional information is available at the end of the chapter

<http://dx.doi.org/10.5772/52551>

1. Introduction

Sinus surgery was initially done transnasally or by a transmaxillary approach with the use of external lighting (often a headlight) and the surgeon's direct vision. Endoscopic techniques for intranasal surgery were first pioneered for adult applications and were gradually applied to pediatric sinus surgery as endoscope technology improved and smaller diameter endoscopes became available. Techniques that were developed in Europe were championed by Kennedy in the United States, with an emphasis on targeted removal of diseased tissue and preservation of normal mucosa [1, 2].

In 1989, Gross *et al.* published one of the first case series documenting functional endoscopic sinus surgery in the pediatric population. They noted that all 57 children in the series tolerated the procedure well and that there were no major complications [3]. Since that time, endoscopic intranasal surgical techniques in children have become commonplace for applications ranging from chronic sinusitis and nasal polyposis to the treatment of complications of acute sinusitis as well as approaches to the skull base.

2. Equipment

2.1. Camera and monitors

Initially, endoscopic sinus surgery was performed with the surgeon looking directly through the optical telescope. As digital cameras improved, the images could be magnified and viewed on a monitor allowing the surgeon better visualization as well as improving

their working room and ability to operate. In recent years, improvements in the size and reasonable cost of high-definition monitors and cameras have allowed these to become commonplace in many operating rooms and clinics.

2.2. Endoscopes

There are a variety of endoscopes that can be used for pediatric sinus surgery. Depending on the size of the patient, the 4.0 mm diameter endoscope (used for adult sinus procedures) provides the best field of view and resolution. If the child's anatomy is too small to accommodate the 4.0 mm endoscope, a 2.7 mm diameter endoscope can be used. However, the 2.7 mm telescope is more fragile and can be easily broken if too much pressure is placed on the shaft.

Depending on the surgical application, different angled endoscopes are available to provide optimal visualization into the sinuses. The 0 degree endoscope is one of the easiest endoscopes to use as it provides a straight-on view. Scopes with angled tips that allow for views of 30, 45 and 70 degrees are frequently used for endoscopic sinus surgery. During a particular procedure, the surgeon may switch endoscopes frequently depending on which portion of the anatomy they would like to view and operate upon. The 0 degree scope is most commonly used for visualizing the ethmoid and sphenoid sinuses, however angled scopes are most commonly used for viewing the maxillary and frontal sinuses. The angle of most scopes is fixed, however the scope can be turned to visualize in any direction. A scope is now available, which is a heavier than others, that allows for adjustment of the angle on a single scope. The stem of scope, which is where the light cord attaches, can be turned to facilitate looking in other directions. In order to avoid interference of instruments used, scopes that have the light cord coming off the same side or opposite side that the scope is directed are available. Both the standard and reverse-post scopes are an important component of a surgeon's armamentarium.




Figure 1. Telescopes, from left to right, 0, 30, 70 degree respectively.

2.3. Endoscopic surgical instruments

Miniaturized versions of adult sinus surgery instruments are available from several instrument manufacturers. These instruments allow surgeons to open particular sinuses while avoiding disturbing normal mucosa.

Another important instrument for endoscopic sinus surgery is the microdebrider. Several manufacturers have produced powered devices that can remove tissue during endoscopic sinus surgery. For example, a 4.0 and a 2.9 mm microdebrider blade can be used depending on the size of the patient. The smaller powered instruments do tend to get clogged with bone chips more frequently. In addition, endoscopic drills exist which can precisely remove bone.

3. Pertinent sinonasal embryology

During fetal development the nasal placode is noted at around four and a half weeks. The nasal cavity is then formed due to the fusion of the medial and lateral nasal processes. The turbinates develop shortly thereafter at around 40 days [4]. Ethmoid budding is noted around 11 to 12 weeks and maxillary budding is noted around 14 to 15 weeks of development [5].

The progression of sinus development was initially documented via cadaver studies, and a recent large-scale imaging study helped re-confirm these findings through non-invasive MRI scanning to evaluate the volume of the paranasal sinuses of patients with healthy sinuses undergoing scans for other reasons. It was found that initial pneumatization was noted for the maxillary and ethmoid sinuses at birth, for the sphenoid sinus at 9 months, and for the frontal sinus after 5 years of age. Additionally the development of the paranasal sinuses was noted to be ongoing until at least the late teen years [5].

The fact the sinuses are continuing to develop as children grow becomes important in considering the possible acute complications of sinusitis that will be discussed later in this chapter. The peak time for development of the frontal sinus and the diploic venous system is in adolescence [6], which partially explains why adolescents are the most common age group afflicted by intracranial complications of sinusitis.

4. Clinical presentation of pediatric acute complicated sinusitis

Due the relative rarity of cases of acute complicated sinusitis in children, the exact incidence is unclear. The most frequent complications of sinusitis in children are extracranial and include periorbital/orbital cellulitis and subperiosteal/orbital abscess. These two complications comprise up to 90 percent of complications of sinusitis in children [7]. Ophthalmological evaluation is critical in these cases to thoroughly assess the status of the eye. However, in the subset of patients who require inpatient admission for treatment, the incidence of intracranial-

al complications has been estimated to be around 3% based on a large review of patients admitted with sinusitis [8]. Interestingly, male patients account for 60-70% of the cases of complications of acute sinusitis [9].

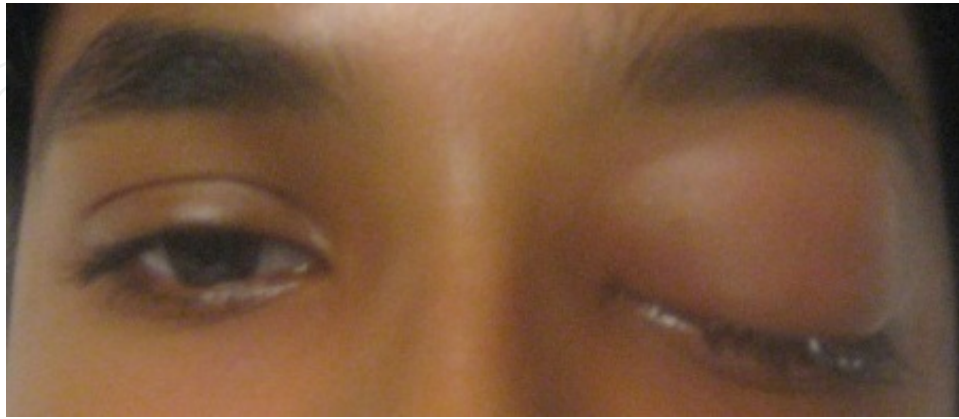

Figure 2. Left periorbital cellulitis with associated subperiosteal abscess

Orbital complications and intracranial complications can present somewhat differently, but at times they can have overlapping symptoms. In addition to systemic symptoms of fever and change in energy level and nasal symptoms of congestion and purulent drainage, patients with orbital complications such as cellulitis and abscess typically develop erythema and edema of the eyelid as well as proptosis [10]. Decreased ocular motility is also a frequent sign of orbital cellulitis and abscess with a reported incidence of approximately 35% and 80% respectively [7]. Visual acuity can be worsened, and in severe cases nonreactive pupils are noted. Complete ophthalmological evaluation is an important part of the management of these patients with orbital complications.

Intracranial complications can present in a somewhat non-specific manner with the most frequent symptoms being fever in about 75% and headache in 67-92% of children [11-13]. Other systemic symptoms include nausea and vomiting and lethargy. Some patients with intracranial pathology can present with extracranial complications at the same time, such as orbital cellulitis and forehead abscesses [11]. A significant number of patients with intracranial complications of sinusitis (38-59%) will present with *normal* neurological exams [11, 13], which makes diagnosis more difficult and emphasizes the importance of proper imaging studies in the evaluation of these patients. Patients that present with central neurologic signs and symptoms can present with an altered level of consciousness, cranial nerve palsies, hemiparesis, new onset seizures, visual disturbances, slurred speech, and meningeal signs [7, 11-13].

Of note, patients with intracranial complications of sinusitis have a high incidence of seizures and anticonvulsant therapy as prophylaxis should be considered for all patients with intracranial complications [13].

5. Role of imaging in pediatric acute complicated sinusitis

5.1. Computed Tomography (CT)

CT scanning is the gold standard for imaging of the paranasal sinuses. Unlike for patients with chronic sinusitis for whom non-contrast studies may be sufficient, children with possible complications of acute sinusitis require contrast-enhanced studies. One drawback of CT scanning is that it does lack specificity due to mucosal changes that may be considered incidental and due to the slow resolution of edema after infections [10, 14]. Although there is a priority to avoid the radiation of a CT scan in children, it remains a crucial imaging modality for diagnosis and management of acute complicated sinusitis. CT can often miss intracranial involvement in cases of acute complicated sinusitis up to 50% of the time. Patients 7 years and older with orbital infections have been shown to have about a 10% incidence of concomitant intracranial involvement [15].

5.2. Magnetic Resonance Imaging (MRI)

Contrast-enhanced MRI scans are necessary for patients who are suspected of having intracranial complications of sinusitis. MRI is superior to CT in that it is able to delineate early cerebritis changes as well as provide further detail regarding the meninges, marrow spaces as well as the orbital apex and cavernous sinus [10, 14].

5.3. Intraoperative surgical guidance

Image guidance systems are used widely by both otolaryngologists and neurosurgeons for adult applications. Data regarding the utility of image guidance in children is not as abundant. However, literature reviews of the indications and safety of image guidance in pediatric sinus and skull base surgery supports its use for complex cases and cases with distorted anatomy which includes cases of acute complicated sinusitis. Additionally, there were no complications that were reported in either retrospective studies [16, 17]. Image guidance can include CT and/or MRI, however, for cases of acute complicated sinusitis, CT is the most useful for defining bony landmarks within the sinonasal cavity. MRI can certainly assist with soft tissue landmarks when needed in complex cases.

6. Role of medical management

Medical management of children with acute complicated sinusitis is mainly centered around the administration of IV antibiotics. Broad-spectrum antibiotics are chosen until culture-directed therapy can be provided. Adjunctive therapy to help reduce mucosal edema includes systemic steroids and decongestants, and topical decongestants (oxymetazoline) and topical steroids. However, there is not much literature to support the use of these agents in the setting of acute complicated sinusitis, but there is no definitive evidence that these would be harmful. Additionally, nasal saline irrigation or nasal saline spray can be helpful to clear se-

cretions in the sinonasal cavity. However, the utility of topical therapies depend on the age and developmental level of each child.

7. Complications of acute sinusitis

7.1. Periorbital and orbital cellulitis

About 60 to 85% of orbital and periorbital infections are attributed to the paranasal sinuses [14]. Periorbital cellulitis is the most frequent complication of sinusitis in the pediatric population. Fortunately, most cases of periorbital cellulitis will respond to medical management with nasal decongestants and systemic antibiotics. For all cases of orbital cellulitis the involvement an ophthalmologist is crucial for full assessment of the eye.

It is important to distinguish pre-septal periorbital cellulitis from post-septal (orbital) cellulitis. The orbital septum is an important landmark. It is a continuation of the orbital periosteum that extends to the tarsal plate.

Garrett *et al.* examined CT scans of 100 consecutive patients with periorbital cellulitis and noted that children with a dehiscence of the lamina papyracea have a higher incidence of requiring endoscopic sinus surgery to address periorbital infection [18]. Jatana *et al.* reported a rare case of recurrent periorbital sinusitis in a young child which ultimately required endoscopic surgical management; this patient had an abnormal lateralized uncinate and a dehiscence of the lamina papyracea. Congenital anatomical abnormalities may contribute to the pathophysiology of this complication of sinusitis; this highlights the importance of imaging studies including high-resolution CT and consideration of early surgical intervention particularly in the event of recurrence [19].

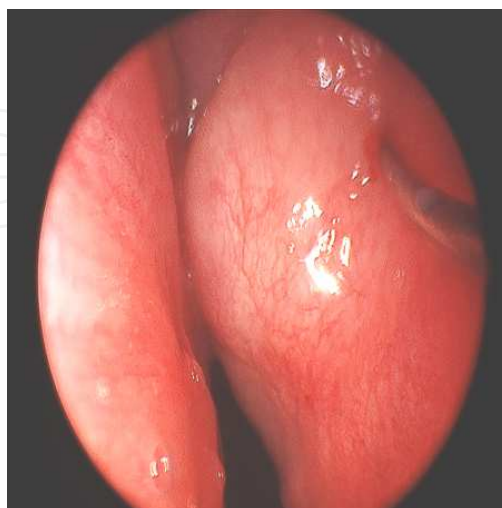


Figure 3. Endoscopic view with a 0 degree telescope demonstrating scarring of left middle meatus impairing sinus drainage and causing periorbital cellulitis.

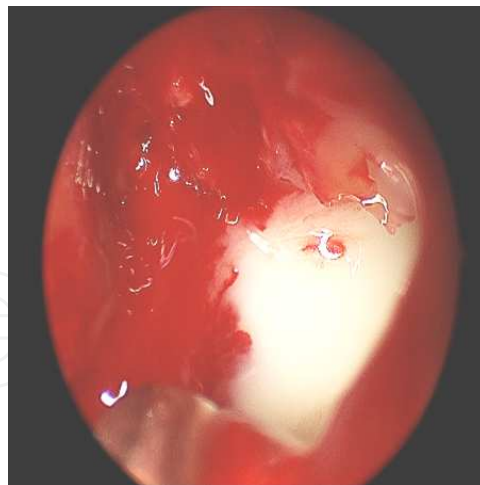

Figure 4. Endoscopic view of the left maxillary sinus with a 30 degree telescope showing frank purulence after a maxillary antrostomy was created.

7.2. Subperiosteal abscess

The concept of the orbital septum as a continuation of the periosteum becomes important to understand the development of a subperiosteal abscess. The periosteum of the medial orbit lies next to the lamina papyracea; the lamina papyracea is very thin and porous and a potential space can be dissected by an infectious process. The spread of infection from the ethmoid sinuses can lead to phlegmon and abscess between the bone and the orbital periosteum. In rare cases, subperiosteal abscess can also be caused by frontal or maxillary sinusitis [14, 20]. Oxford and McClay suggested guidelines to help determine if surgical treatment is warranted for subperiosteal abscesses. They recommend medical management with frequent re-evaluation of the eye if the following criteria are met: normal vision, pupil, and retina, no ophthalmoplegia, IOP<20mmHg, proptosis<5mm, and an abscess width of <4 mm [21].

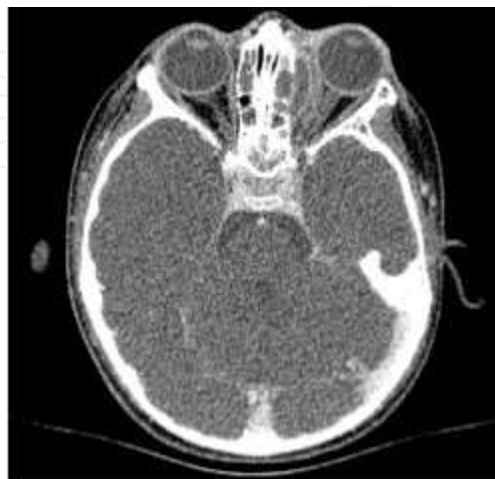

Figure 5. CT scan with contrast, axial, with demonstration of left subperiosteal abscess (enhancing rim).

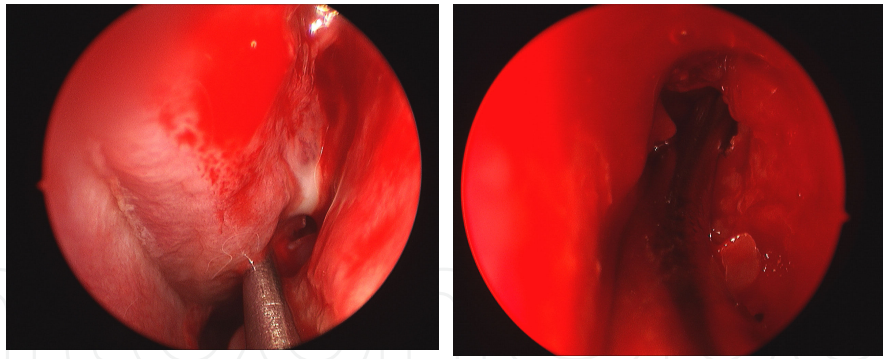


Figure 6. Left-Endoscopic view of left middle meatus with 0 degree telescope, purulence encountered in the ethmoid sinuses; Right-After endoscopic surgical removal of a portion of the lamina papyracea for drainage of the subperiosteal abscess, a blunt probe was placed through the defect. The left periorbital area is immediately medial to the tip of the probe.

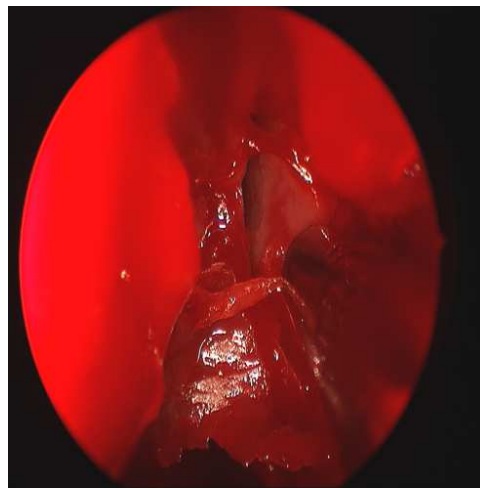


Figure 7. Endoscopic view with a 0 degree telescope of left lamina papyracea and periorbital area, the instrument is on the periorbital area after removal of a portion of the lamina papyracea. Using endoscopic visualization, an incision through the periorbital area (parallel to the medial rectus muscle) could be made if orbital decompression was needed; this is an important consideration in cases of orbital cellulitis/abscess.

The recent trend in treatment for subperiosteal abscesses along the lamina has been to proceed with endoscopic treatment with external approaches reserved for treatment failures and abscess that are not accessible via the lamina [22]. Some authors suggest that patients who fail to improve 24 hours after endoscopic drainage could undergo re-imaging to see if they would benefit from an additional drainage procedure [20]

7.3. Orbital abscess

When a post-septal infection organizes, an orbital abscess can occur. Orbital abscesses are accessible endoscopically by making an incision in the periorbital area. Some orbital abscesses require an orbitotomy, which is an external incision to approach the intraorbital contents. Endoscopic treatment of the sinuses is important in addition to drainage of the abscess. Orbital

abscesses are true emergencies as they are often associated with acute vision changes secondary to pressure on the optic nerve or vasospasm of the retinal artery.

7.4. Meningitis

Meningitis can be seen in conjunction with other suppurative complications of sinusitis. Enhancement of the meninges is seen on CT or MRI if performed with contrast [14]. Meningitis as the sole complication of sinusitis does not always need to be treated with endoscopic surgery. Patients can be started on broad-spectrum antibiotics that cross the blood brain barrier and their clinical progress can be watched closely for 48 hours [23]. Any patient with bacterial meningitis needs to have a close follow-up with audiological testing as significant hearing loss can occur.

7.5. Epidural abscess

Epidural abscess is a collection of purulence external to the dural layer. For children with epidural abscesses due to paranasal sinus infections, there is some controversy as to the appropriate treatment. Some neurosurgeons feel that if the sinuses are addressed surgically and antibiotics are used, some patients may be able to avoid craniotomy, but this belief is not shared by all in the specialty [24]. Regardless of the exact surgical treatment modality (endoscopic treatment alone or in conjunction with craniotomy), it is important to treat patients with a multidisciplinary team that includes infectious disease, otolaryngology, and neurosurgery specialists.

7.6. Subdural empyema

Subdural empyema is a collection of purulence between the dura and arachnoid layers. It is considered to be a surgical emergency. Coordination between the neurosurgery and otolaryngology teams is paramount to address the collection via a craniotomy and to address the sinus disease that was causative via endoscopic sinus surgery [6, 25].

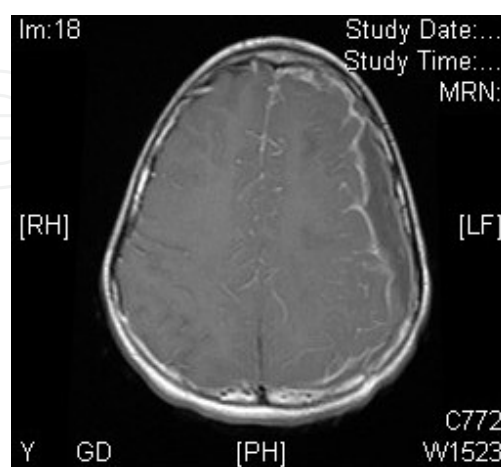


Figure 8. T1 contrast enhanced MRI showing large subdural empyema in left temporal-parietal region in a 9 year-old with mental status changes and paresis.

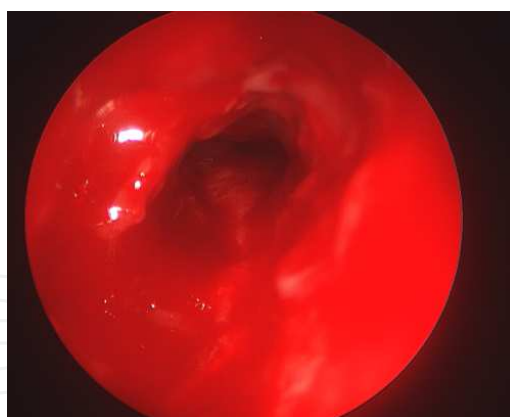


Figure 9. Endoscopic view of the right frontal recess using a 70 degree telescope, purulence was drained from the frontal sinus after craniotomy in this 9 year-old patient.

7.7. Intracerebral abscess

Cerebritis can be considered a pre-cursor of actual abscess within the brain parynchema. Cerebritis can be suggested on contrast-enhanced CT and also on MRI with ill-defined enhancement. Actual abscesses within the brain are best diagnosed with MRI and are at times difficult to distinguish from cystic tumors [14]. Intracerebral abscesses are most frequent in the frontal lobe adjacent to the frontal sinus [10]. In general, neurosurgical drainage of the intracranial abscess and endoscopic sinus surgery for any associated intranasal pathology are of the utmost importance.

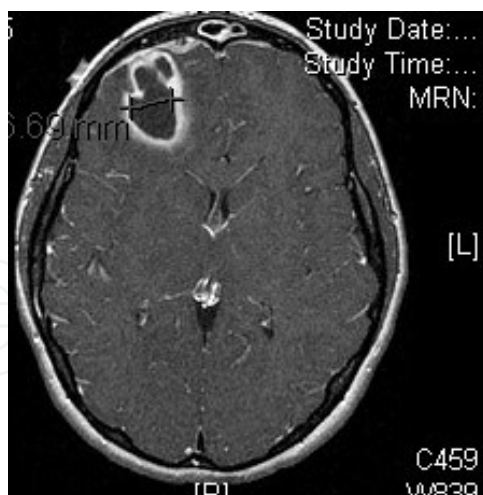


Figure 10. MRI with contrast, showing enhancing abscess within right frontal lobe.

7.8. Pott's Puffy/osteomyelitis

Pott's puffy "tumor" is an infectious complication of sinusitis involving frontal bone osteomyelitis with an associated frontal subperiosteal abscess that creates swelling of the fore-

head [26]. It can also be associated with intracranial abscesses in some cases. The etiology can be infection from sinus disease or due to trauma to the frontal bone resulting in a conduit for spread of infection. Medical management of sinus disease is a component of treatment, but surgical intervention is paramount. The approach to treat Pott's puffy tumor can be endoscopic with a frontal sinusotomy and anterior ethmoidectomy, but a combined approach with an external incision may be required depending on the size of the subperiosteal abscess and whether or not there are associated intracranial complications. Following surgical treatment, patients will require prolonged courses of IV antibiotics until the osteomyelitis has resolved [27].

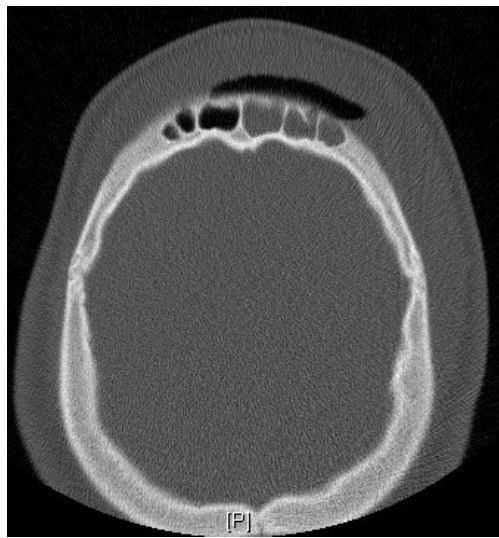

Figure 11. Axial CT showing left frontal sinus opacification and connection to scalp, consistent with Pott's Puffy. Approximately 80 mL of purulence was drained from the scalp abscess.

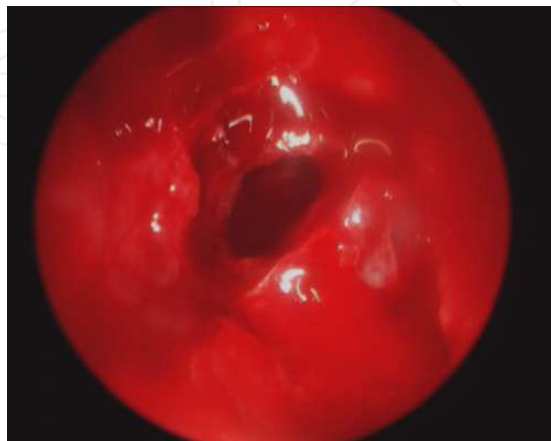


Figure 12. Endoscopic view of the left frontal sinus with a 70 degree telescope.

7.9. Cavernous sinus thrombosis

Cavernous sinus thrombosis can occur due to the spread of infection from the middle third of the face or from the sinuses and orbit due to the valveless venous system in the anatomical region [28]. Emergent drainage of any paranasal sinus or orbital infection is important in conjunction with intravenous antibiotics. Systemic anticoagulation is considered in all of these cases. Despite aggressive treatment, cavernous sinus thrombosis remains a life-threatening illness (in addition to causing cranial neuropathy and blindness) that requires multidisciplinary care in an intensive care unit setting.

8. Complications of endoscopic sinus surgery

Major complications after endoscopic sinus surgery include CSF leak, orbital injury and hemorrhage. A recent retrospective study by Ramakrishnan *et al.* looked at overall rates of major complications after endoscopic sinus surgery. The overall rate of major complications across all age groups was 1%. This was divided among patients with CSF leak (0.17%), patients with orbital injuries (0.07%), and patients with significant hemorrhage that required blood transfusion (0.76%). This data represents significant improvement from previous retrospective analyses. When the complications were stratified by age, they found that CSF leak was less likely to occur in children, but orbital injury was more likely in the pediatric population. This likely stems from smaller maxillary sinuses and lower orbital floors in young children.

Concerns have been raised that sinus surgery in children could affect facial growth. An animal study looking at facial growth in piglets that underwent endoscopic sinus surgery revealed decreased facial growth on the operative side. This same study investigated the types of bone that were removed from pediatric patients who underwent endoscopic sinus surgery and noted that children less than 9 years old had immature bone in contrast to children over 9 years old and older who had more mature bone in their specimens [29].

A quantitative study in pediatric patients was performed by Senior *et al.* in order to evaluate facial growth using CT scan images and volumetric analysis. Their study looked at patients who underwent sinus surgery due to orbital cellulitis and abscess and re-evaluated the patients 4 to 10 years later. There was no statistically significant difference in sinus volume from the operated side to the non-operated side. However, a small difference in orbital volume was noted from the operated side to the non-operated side. Overall, they concluded that sinus surgery in children has minimal impact on sinus and facial growth [30].

9. Post-operative management

9.1. Inpatient

Patients with acute complicated sinusitis will require close monitoring after surgical intervention. Patients with intracranial involvement may require intensive care unit man-

agement until they show clinical improvement. These patients generally need multidisciplinary involvement including the surgical teams of neurosurgery, otolaryngology and ophthalmology as well as an infectious disease specialist. Serial ophthalmological examinations are important to optimize visual outcomes when the orbit is involved. Given the consequences of persistent or recurrent infection, the threshold for repeat imaging and possible return to the operating room must remain low. Antibiotic therapy can be tailored to the particular culture results when available. Adjunctive therapy such as topical and systemic decongestants and nasal saline spray or irrigation are also of importance during this period.

9.2. Outpatient

Primary outpatient management of complicated acute sinusitis is not the standard of care. Once patients are stabilized clinically, they can often be treated with outpatient antibiotic regimens via PICC lines or in some cases be transitioned to an oral regimen. From the otolaryngologist's perspective, some children who have endoscopic sinus surgery may need to return to the operating room for debridement during the healing process. During the early years of endoscopic sinus surgery, taking children back to the operating room two to three weeks after surgery for debridement was the standard of care [31]. However, after further evaluation, this approach was found to have no benefit in terms of nasal obstruction, drainage or cough [32]. A secondary procedure in the operating room should be considered for select patients depending on how well they are able to irrigate as well as how easily they tolerate endoscopic exam and gentle debridement in the clinic. The threshold for return to the operating room for patients who underwent major dissections should be lower than for those who had more limited procedures [33]. Parents must be informed at the time of the initial surgery that multiple surgical procedures may be required. Surveillance of scar tissue formation, which is more common in the setting of acute infection, can be performed endoscopically in the office. If there is concern that the sinuses are not draining properly, revision surgery should be performed to prevent return of the previous complication.

10. Open surgical approaches

10.1. Lynch incision

Although intranasal approaches are frequently the preferred route for accessing the paranasal sinuses and the medial orbit, patients and their families should be counseled that external approaches to the anterior ethmoid region may be required. The Lynch approach leaves a scar that courses from the medial brow along the side of the nose but may be required in cases where the medial orbit cannot be accessed endoscopically due to severe edema or inflammatory tissues that interfere with endoscopic visualization.

10.2. Trephination

Trephination is another adjunctive external approach that is particularly helpful to access the frontal sinus. It requires a small external incision but can help minimize operating room time in patients that are clinically unstable. Additionally, a case series reported the use of mini-trephination of the frontal sinus with drain placement as a possible adjunct for patients with sinusitis complicated with intracranial infection [34]. An endoscope can also be used for improved visualization of the frontal sinus through the trephination and has been described by Jatana *et al.* to assist in repair of a subclinical CSF leak from an isolated posterior table frontal sinus fracture that caused recurrent meningitis in a pediatric patient [35].

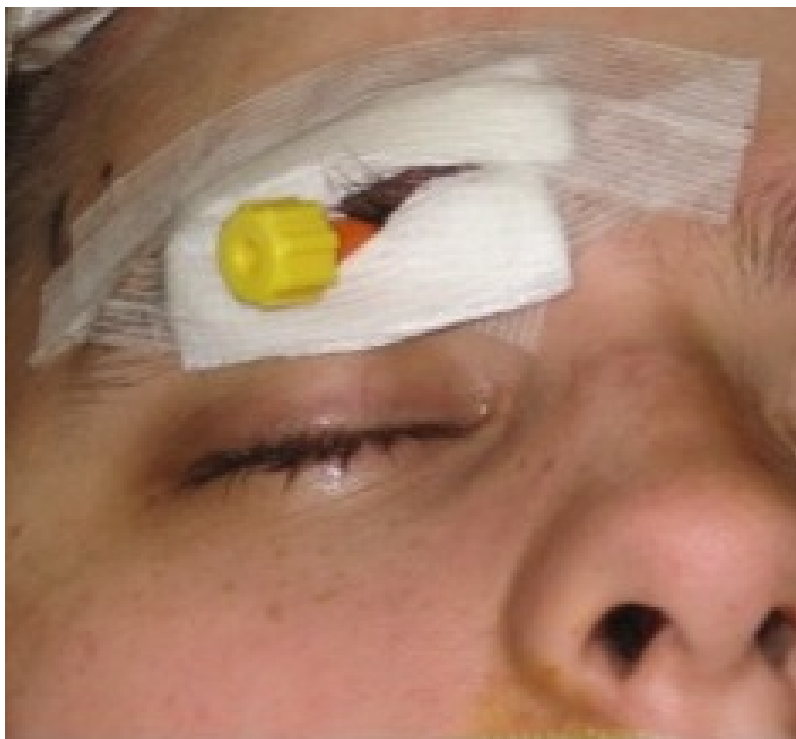

Figure 13. Right frontal sinus trephination performed in conjunction with an endoscopic approach and a drain for irrigation was placed into the right frontal sinus.

10.3. Transcaruncular

Another external approach that does not have the drawback of visible scarring is the transcaruncular approach. This approach is performed by making a transconjunctival incision just lateral or medial to the lacrimal caruncle and then dissecting to the anterior medial orbital wall. Dissection then continues by elevating the periorbital fat from the lamina until the abscess is accessed. This approach can be used in conjunction with endoscopic drainage of a subperiosteal abscess to ensure that the entire cavity is adequately drained and reduce the risk of recurrence [36].

11. Conclusion

Endoscopic surgical techniques are an important component of treatment for acute complicated sinusitis in the pediatric population. Given the diverse nature or presenting signs and symptoms, a high index of suspicion for complications of sinusitis must be maintained for patients presenting with complaints previously described. Using endoscopic approaches to the sinuses, the otolaryngologist is an important member of the multidisciplinary team that cares for patients with complications of sinusitis.

Author details

Timothy P. McEvoy¹, Charles A. Elmaraghy^{1,2} and Kris R. Jatana^{1,2}

*Address all correspondence to: Kris.Jatana@nationwidechildrens.org

1 Department of Pediatric Otolaryngology-Head and Neck Surgery, Nationwide Children's Hospital, Columbus, Ohio, USA

2 Department of Otolaryngology-Head and Neck Surgery, Wexner Medical Center at The Ohio State University, Columbus, Ohio, USA

References

- [1] Kennedy DW. Functional endoscopic sinus surgery. Technique. Arch Otolaryngol. (1985). Epub 1985/10/01., 111(10), 643-9.
- [2] Kennedy DW, Zinreich SJ, Rosenbaum AE, Johns ME. Functional endoscopic sinus surgery. Theory and diagnostic evaluation. Arch Otolaryngol. (1985). Epub 1985/09/01., 111(9), 576-82.
- [3] Gross CW, Gurucharri MJ, Lazar RH, Long TE. Functional endonasal sinus surgery (FESS) in the pediatric age group. The Laryngoscope(1989). Epub 1989/03/01., 99(3), 272-5.
- [4] al, R., & , . Embryology and Anatomy of the Paranasal Sinuses. 4th ed(2003).
- [5] Adibelli, Z. H., Songu, M., & Adibelli, H. Paranasal sinus development in children: A magnetic resonance imaging analysis. American journal of rhinology & allergy. (2011). Epub 2011/06/30., 25(1), 30-5.
- [6] Yucel, O. T., & Ogretmenoglu, O. Subdural empyema and blindness due to cavernous sinus thrombosis in acute frontal sinusitis. International journal of pediatric otorhinolaryngology(1998). Epub 1999/04/06., 121 EOF-5 EOF.

- [7] Oxford, L. E., & Mc Clay, J. Complications of acute sinusitis in children. *Otolaryngology--head and neck surgery : official journal of American Academy of Otolaryngology-Head and Neck Surgery*(2005). Epub 2005/07/19., 133(1), 32-7.
- [8] Lerner DN, Choi SS, Zalzal GH, Johnson DL. Intracranial complications of sinusitis in childhood. *The Annals of otologyrhinology, and laryngology*. (1995). Pt 1):Epub 1995/04/01., 288 EOF-93 EOF.
- [9] DeMuri GP, Wald ER. Complications of acute bacterial sinusitis in children. *The Pediatric infectious disease journal*(2011). Epub 2011/07/14., 30(8), 701-2.
- [10] Vazquez, E., Creixell, S., Carreno, J. C., Castellote, A., Figueras, C., Pumarola, F., et al. Complicated acute pediatric bacterial sinusitis: Imaging updated approach. *Current problems in diagnostic radiology*(2004). Epub 2004/06/25., 33(3), 127-45.
- [11] Germiller JA, Monin DL, Sparano AM, Tom LW. Intracranial complications of sinusitis in children and adolescents and their outcomes. *Archives of otolaryngology--head & neck surgery*(2006). Epub 2006/09/20., 132(9), 969-76.
- [12] Kombogiorgas, D., Seth, R., Athwal, R., Modha, J., & Singh, J. Suppurative intracranial complications of sinusitis in adolescence. Single institute experience and review of literature. *British journal of neurosurgery*(2007). Epub 2007/12/12., 21(6), 603-9.
- [13] Hicks, C. W., Weber, J. G., Reid, J. R., & Moodley, M. Identifying and managing intracranial complications of sinusitis in children: a retrospective series. *The Pediatric infectious disease journal*(2011). Epub 2011/03/19., 30(3), 222-6.
- [14] Reid JR. Complications of pediatric paranasal sinusitis. *Pediatric radiology*(2004). Epub 2004/07/28., 34(12), 933-42.
- [15] Herrmann BW, Forsen JW, Jr. Simultaneous intracranial and orbital complications of acute rhinosinusitis in children. *International journal of pediatric otorhinolaryngology*(2004). Epub 2004/04/15., 68(5), 619-25.
- [16] Parikh, S. R., Cuellar, H., Sadoughi, B., Aroniadis, O., & Fried, M. P. Indications for image-guidance in pediatric sinonasal surgery. *International journal of pediatric otorhinolaryngology*(2009). Epub 2009/01/23., 73(3), 351-6.
- [17] Benoit, Silvera. V. M., Nichollas, R., Jones, D., Mc Gill, T., & Rahbar, R. Image guidance systems for minimally invasive sinus and skull base surgery in children. *International journal of pediatric otorhinolaryngology*(2009). Epub 2009/08/22., 73(10), 1452-7.
- [18] Garrett, M. G. J., & Elmaraghy, Jatana. K. R. Radiographic findings in pediatric periorbital cellulitis. *American Society of Pediatric Otolaryngology (ASPO); San Diego, California*(2012).
- [19] Jatana KR, Grischkan JM, Skomorowski MJ, Elmaraghy CA. Recurrent unilateral periorbital cellulitis in a pediatric patient--an anatomic abnormality. *International journal of pediatric otorhinolaryngology*(2008). Epub 2008/08/16., 72(10), 1577-80.

- [20] Noordzij JP, Harrison SE, Mason JC, Hashisaki GT, Reibel JF, Gross CW. Pitfalls in the endoscopic drainage of subperiosteal orbital abscesses secondary to sinusitis. *American journal of rhinology*(2002). Epub 2002/05/28., 16(2), 97-101.
- [21] Oxford, L. E., & Mc Clay, J. Medical and surgical management of subperiosteal orbital abscess secondary to acute sinusitis in children. *International journal of pediatric otorhinolaryngology*(2006). Epub 2006/08/15., 70(11), 1853-61.
- [22] Soon VT. Pediatric subperiosteal orbital abscess secondary to acute sinusitis: a 5-year review. *American journal of otolaryngology*. (2011). Epub 2009/12/25., 32(1), 62-8.
- [23] Younis, R. T., Anand, V. K., & Childress, C. Sinusitis complicated by meningitis: current management. *The Laryngoscope*(2001). Epub 2001/09/25., 111(8), 1338-42.
- [24] Heran, N. S., Steinbok, P., & Cochrane, D. D. Conservative neurosurgical management of intracranial epidural abscesses in children. *Neurosurgery*(2003). discussion 7-8. Epub 2003/10/02., 53(4), 893-7.
- [25] Waseem, M., Khan, S., & Bomann, S. Subdural empyema complicating sinusitis. *The Journal of emergency medicine*(2008). Epub 2007/12/25., 35(3), 277-81.
- [26] Blumfield, E., Misra, M., Pott's, puffy., tumor, intracranial., orbital, complications., the, initial., presentation, of., sinusitis, in., healthy, adolescents. a., & case, series. *Emergency radiology*(2011). Epub 2011/03/08., 18(3), 203-10.
- [27] Parida, P. K., Surianarayanan, G., Ganeshan, S., & Saxena, S. K. Pott's puffy tumor in pediatric age group: A retrospective study. *International journal of pediatric otorhinolaryngology*(2012). Epub 2012/06/19.
- [28] Cannon ML, Antonio BL, McCloskey JJ, Hines MH, Tobin JR, Shetty AK. Cavernous sinus thrombosis complicating sinusitis. *Pediatric critical care medicine : a journal of the Society of Critical Care Medicine and the World Federation of Pediatric Intensive and Critical Care Societies*(2004). Epub 2003/12/31., 5(1), 86-8.
- [29] Mair EA, Bolger WE, Breisch EA. Sinus and facial growth after pediatric endoscopic sinus surgery. *Archives of otolaryngology--head & neck surgery*(1995). Epub 1995/05/01., 121(5), 547-52.
- [30] Senior, B., Wirtschafter, A., Mai, C., Becker, C., & Belenky, W. Quantitative impact of pediatric sinus surgery on facial growth. *The Laryngoscope*(2000). Epub 2000/11/18., 110(11), 1866-70.
- [31] Mair EA. Pediatric functional endoscopic sinus surgery: postoperative care. *Otolaryngologic clinics of North America*(1996). Epub 1996/02/01., 29(1), 207-19.
- [32] Mitchell RB, Pereira KD, Younis RT, Lazar RH. Pediatric functional endoscopic sinus surgery: is a second look necessary? *The Laryngoscope*. (1997). Epub 1997/09/18., 107(9), 1267-9.

- [33] Cable BB, Mair EA. Pediatric functional endoscopic sinus surgery: frequently asked questions. *The Annals of otologyrhinology, and laryngology*. (2006). Epub 2006/10/19., 115(9), 643-57.
- [34] Mc Intosh, D. L., & Mahadevan, M. Frontal sinus mini-trephination for acute sinusitis complicated by intracranial infection. *International journal of pediatric otorhinolaryngology*(2007). Epub 2007/07/14., 71(10), 1573-7.
- [35] Jatana, K. R., Ryoo, C., Skomorowski, M., Butler, N., & Kang, D. R. Minimally invasive repair of an isolated posterior table frontal sinus fracture in a pediatric patient. *Otolaryngology--head and neck surgery : official journal of American Academy of Otolaryngology-Head and Neck Surgery*. (2008). Epub 2008/05/28., 138(6), 809-11.
- [36] Pelton RW, Smith ME, Patel BC, Kelly SM. Cosmetic considerations in surgery for orbital subperiosteal abscess in children: experience with a combined transcaruncular and transnasal endoscopic approach. *Archives of otolaryngology--head & neck surgery*(2003). Epub 2003/06/18., 129(6), 652-5.