

We are IntechOpen, the world's leading publisher of Open Access books Built by scientists, for scientists

6,900

Open access books available

185,000

International authors and editors

200M

Downloads

Our authors are among the

154

Countries delivered to

TOP 1%

most cited scientists

12.2%

Contributors from top 500 universities



WEB OF SCIENCE™

Selection of our books indexed in the Book Citation Index
in Web of Science™ Core Collection (BKCI)

Interested in publishing with us?
Contact book.department@intechopen.com

Numbers displayed above are based on latest data collected.
For more information visit www.intechopen.com



Iatrogenic Pseudoaneurysms

Charles P.E. Milne, Regent Lee and Ashok I. Handa

Additional information is available at the end of the chapter

<http://dx.doi.org/10.5772/51494>

1. Introduction

A pseudoaneurysm refers to a defect in an arterial wall, which allows communication of arterial blood with the adjacent extra-luminal space. Blood extravasates out of the artery, but is contained by surrounding soft tissue and compressed thrombus which form a cavity or sac.[1] There is often a narrow tract stemming from the arterial wall to the pseudoaneurysm sac, termed the 'neck'. A pseudoaneurysm is distinct from a 'true' aneurysm, which results from dilation of all layers of the arterial wall.

Pseudoaneurysms are typically the result of traumatic arterial injury. With the increasing utilisation of percutaneous arterial interventions worldwide, iatrogenic arterial injury has become the predominant cause of pseudoaneurysm formation. The highest incidence of iatrogenic pseudoaneurysm formation is observed in the common femoral artery as a result of inadequate seal of the arterial puncture site following catheterisation procedures. It is reported that femoral pseudoaneurysms occur in up to 0.2% of diagnostic and 8% of interventional procedures.[2] Approach to the management of a pseudoaneurysm depends on its anatomical location. This chapter will focus primarily on the management of iatrogenic femoral pseudoaneurysms, with an overview of other peripheral and visceral iatrogenic pseudoaneurysms.

2. Femoral iatrogenic pseudoaneurysms

2.1. General considerations

Factors which may increase the risk of iatrogenic femoral pseudoaneurysm formation after femoral catheterisation can be broadly categorised into procedural or patient factors. 'Procedural' factors include low femoral puncture, inadvertent catheterisation of the superficial femoral artery or profunda femoris artery, interventional rather than diagnostic procedures, and inadequate compression following removal of the sheath. 'Patient' factors include obesity and the need for anticoagulation post-procedure.[2]

Patients with femoral pseudoaneurysms typically present with pain and swelling of the affected groin, along with a palpable mass which may be pulsatile with a thrill or bruit.[1] Clinical diagnosis can usually be made in slim patients, but can be difficult in those who are obese, where a high index of suspicion is required to prompt further investigation. Small pseudoaneurysms may resolve spontaneously without intervention. Pseudoaneurysms which persist may enlarge and lead to complications related to compression of the adjacent femoral vein, nerve, and overlying skin. This can lead to leg swelling, deep vein thrombosis, compressive neuropathy and skin necrosis. Although rare, pseudoaneurysms may also expand and eventually rupture.[3]

2.2. Diagnosis

Duplex ultrasonography (DUS) is the modality of choice for diagnosis of femoral pseudoaneurysms, particularly in centres with a dedicated vascular ultrasound laboratory.[4] DUS has been reported to have a sensitivity of 94% and a specificity of 97% in the detection of femoral pseudoaneurysms.[5] Compared to other imaging techniques, DUS is safe and non-invasive. It can also be performed at the bedside. Clear views of the femoral vessels and associated pathology can be achieved rapidly in experienced hands. Another advantage of DUS is that definitive treatment (discussed later) can be performed in the same session.

On DUS, a pseudoaneurysm appears as a hypoechoic sac adjacent to the affected artery, with colour flow observed within it. Thrombus may be identified within part of the sac. The hallmark of diagnosis is the demonstration of a neck communicating between the sac and the affected artery, with a 'to-and-fro' waveform.[1] The 'to' representing blood flow into the pseudoaneurysm and the 'fro' representing blood flow out of the pseudoaneurysm. Waveform analysis of the affected artery is useful to establish a baseline for subsequent comparison. The adjacent vein should be inspected for compression or the presence of thrombus.

Computed Tomography Angiography (CTA) is another effective diagnostic modality, particularly in centres without ready access to vascular ultrasound services. It is also useful in cases where duplex ultrasound findings are equivocal or the anatomy is not well defined.[2] CTA allows accurate assessment of the pseudoaneurysm, its surrounding structures, arterial inflow and distal run-off to the leg. Drawbacks of CTA include radiation exposure (of particular concern in younger patients) and use of iodinated contrast agents (with risk of anaphylaxis and nephropathy).[6] Use of contrast is important to establish that active flow is present within the pseudoaneurysm cavity, which would be otherwise indistinguishable from a haematoma. Patients with mild renal impairment can be pre-hydrated before a CTA to minimise the risk of nephropathy. In those with moderate to severe renal impairment, alternative imaging should be considered.[6]

Magnetic Resonance Angiography (MRA) has emerged as an alternative to CTA in recent years. Gadolinium-enhanced MRA allows 3D visualisation of the pseudoaneurysm and

surrounding structures. Problems with the technique include availability, time duration and cost. In patients with allergies to iodinated contrast, MRA is a potential alternative imaging technique.[1] Gadolinium-based agents are also associated with the rare complication of nephrogenic systemic fibrosis in patients with impaired renal function which should be considered as a relative contra-indication.[6]

2.3. Approach to management

A proportion of iatrogenic femoral pseudoaneurysms will resolve spontaneously without any form of intervention. An accepted approach is to monitor small (less than 3cm), stable, asymptomatic pseudoaneurysms, as the majority of them will thrombose within 4 weeks.[7] In one large series of small (<3cm) pseudoaneurysms, Toursarkissian *et al* reported a rate of spontaneous thrombosis of ~90% at 60 days of follow-up.[7] However, the need for regular follow-up resulting in possible delayed discharge from the hospital, and difficulty in patients reducing their activity while awaiting pseudoaneurysm resolution, has led to the early active management of most pseudoaneurysms.[2] An exception may be for very small (<1cm), stable, asymptomatic pseudoaneurysms, which could be managed conservatively with repeat imaging at one week after diagnosis to see if spontaneous thrombosis has occurred. In addition, spontaneous thrombosis of the pseudoaneurysm may be less likely in patients who are fully anticoagulated or receiving combination antiplatelet therapy, where active management is preferred.

Traditionally, most iatrogenic femoral pseudoaneurysms requiring intervention were treated with open surgical repair. With the increasing availability of DUS during the 1990s, less invasive treatment options using DUS-guidance gained popularity. These methods included ultrasound-guided compression (UGC) and percutaneous ultrasound-guided thrombin injection (UGTI). [8,9]

Open surgical repair (OSR) has traditionally been considered the 'gold standard' treatment for iatrogenic femoral pseudoaneurysms, as the arterial defect is repaired definitively. Principle steps of OSR involve obtaining proximal and distal control of the affected artery, evacuating the aneurysm sac and repairing the defect in the arterial wall (either by primary or patch closure).[10] Complications of OSR include blood loss and infection. Other major adverse events such as myocardial infarction or death are recognised. In high cardiac risk patients, OSR may be performed under local or regional anaesthesia. Recovery time and inpatient stay may be prolonged following OSR.

The advent of less invasive treatment strategies utilising ultrasound (discussed later), have led to a paradigm shift in treatment strategies. OSR is now typically reserved for emergency situations such as rapidly expanding pseudoaneurysms, ruptured pseudoaneurysms, pseudoaneurysms causing mass effect (with overlying skin ischaemia or neurovascular compromise), or when other treatment options have failed.[11] Infective complication of iatrogenic femoral pseudoaneurysms are less common but represent a distinct entity which require open surgical treatment over other interventional techniques and will be considered later in this chapter.

2.3.1. Ultrasound-Guided Compression

Ultrasound-Guided Compression (UGC) of pseudoaneurysms to induce thrombosis of the aneurysm sac was proposed as an alternative to surgery by Fellmeth *et al* in 1991.[8] Principles of UGC involve locating the aneurysm sac using the ultrasound transducer and applying enough pressure to stop flow within the sac, but maintain flow in the affected artery.[5] Flow within the sac is reassessed at 10 - 20 minute intervals until thrombosis is achieved.[1] Unfortunately, efficacy of this technique is limited, with success rates between 62% - 86%.[1,2] Compression times can also be lengthy. This occupies vascular ultrasound laboratory resources and can be uncomfortable for both the patient and clinician.[9] Other problems include incompressible pseudoaneurysms, limited success in patients being treated with anticoagulants & some early recurrences.[9] Despite this, before other minimally invasive treatment options were available, Perkins *et al* reported that UGC reduced the need for open surgery by about 50%, avoiding the associated risks of surgery in these patients.[9]

2.3.2. Ultrasound-Guided Thrombin Injection

Ultrasound-Guided Thrombin Injection (UGTI) of pseudoaneurysms is a technique first described by Kang *et al* in 1998.[12] The technique involves needle infiltration of the aneurysm sac using ultrasound guidance and injection of thrombin to induce thrombosis of the cavity. Previously published studies have documented rates of thrombosis between 86 - 100% (the majority successful on the first attempt).[2] The procedure has the advantage of being relatively quick and simple. The most serious complication of UGTI is distal arterial embolisation, which is a relatively rare outcome (less than 2% in reported series). If this occurs, intra-arterial thrombolysis may be undertaken.[13]

At the Oxford University Hospitals, UGTI has been used as first-line therapy for the treatment of iatrogenic femoral pseudoaneurysms. Between August 2005 and July 2011, 94 patients underwent UGTI for treatment of iatrogenic pseudoaneurysms. Patients were included in a prospective registry and underwent follow up DUS examination to assess treatment efficacy. 97% of pseudoaneurysms suitable for UGTI were successfully treated by this technique, avoiding the risks associated with surgical repair. 91.1% of treatments were successful on the first attempt, and no significant complications were recorded.

In our experience, we have found UGTI to be a simple, quick and safe technique for the treatment of suitable pseudoaneurysms. For small pseudoaneurysms (<1cm), a repeat DUS was performed one week later to see if spontaneous thrombosis had occurred. Pseudoaneurysms with a neck width >1cm were not treated by this method, as wide necks may be related to higher risk of thromboembolic complications.[14] Given the availability of DUS in most major vascular surgery units, UGTI should be the treatment of choice for all suitable iatrogenic pseudoaneurysms.

2.4. Technique of UGTI

Our unit has adapted the original technique for UGTI described by Kang *et al* for the treatment of suitable femoral iatrogenic pseudoaneurysms.[12] Each procedure is performed

by a vascular surgeon (or senior surgical fellow), together with a specialist vascular ultrasonographer. The patient is placed in the supine position. The ultrasonographer uses B-mode and colour flow imaging to define the pseudoaneurysm. As a baseline, pre-procedure imaging of adjacent major vessels (e.g. common femoral artery and vein) is performed. 500 IU of lyophilised human thrombin is dissolved in 1ml calcium chloride solution. This is drawn into a 2ml syringe and a 22 gauge spinal needle is attached.

A safe angle of approach to the aneurysm sac is confirmed by the ultrasonographer and vascular surgeon. The area of skin puncture is prepared with chlorhexidine solution. The ultrasonographer provides a constant good view of the pseudoaneurysm using B-mode imaging while the needle is advanced slowly into the pseudoaneurysm cavity. The needle tip is positioned away from the neck of the pseudoaneurysm, but within a flowing component of the sac. Appropriate positioning within the sac is confirmed by the ultrasonographer using multiple views. Once the ultrasonographer and vascular surgeon are satisfied with the needle position, thrombin injection is performed. On occasions, the needle tip may be difficult to identify on ultrasound and a 20 gauge spinal needle is used to improve visualisation.

Thrombin injection is then performed slowly under constant colour flow imaging to observe thrombosis of the aneurysm sac. When colour flow within the cavity stops completely, injection is ceased. It is uncommon for us to require more than **0.25ml** of thrombin solution to achieve thrombosis, even for relatively large pseudoaneurysms. Another way of ensuring controlled injection of thrombin is to administer small (e.g. 0.125ml) aliquots of solution at a time whilst assessing colour flow within the aneurysm sac.

All patients are followed up at one week with repeat duplex ultrasound. Further injections may be undertaken at this stage if deemed appropriate. We advise caution and consideration of alternative treatment if more than two injections are required.

2.5. Infected femoral pseudoaneurysms

Infected femoral pseudoaneurysms are more commonly seen in the intravenous drug using (IVDU) population, arising from repeated non-sterile needle groin punctures as part of the pursuit of easy peripheral venous access. However, it may also complicate iatrogenic pseudoaneurysms. Clinical presentation mirrors that for non-infected femoral pseudoaneurysms, with the added serious complication of infection. The 'aneurysmal abscess' carries with it a significant risk of sepsis, rupture, limb loss and death.[15] Diagnosis can be made by DUS, but direct DUS imaging can be challenging due to inflammation and even gas. CTA avoids these problems, and can give an appreciation of the extent of inflammation/infection.

Primary repair is not recommended as appropriate surgical management by some authors because the ongoing infection and destruction of the arterial wall usually results in secondary haemorrhage and infection.[15] Ligation and excision of the infected artery and pseudoaneurysm, with aggressive debridement of surrounding infected tissue is the

preferred approach. There is debate among vascular surgeons regarding whether a bypass procedure is required during the same operation.[15]

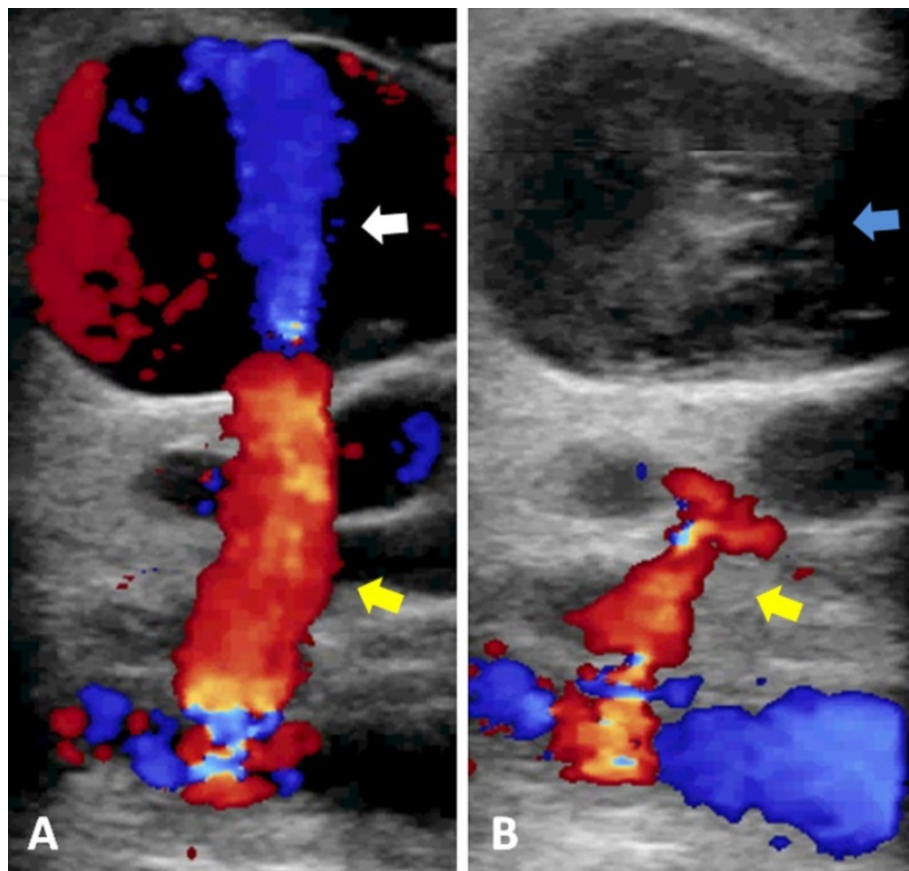


Figure 1. Panel A- DUS of femoral pseudoaneurysm demonstrating “to and fro” flow (yellow arrow) between the native artery and the pseudoaneurysm via the neck. There is colour signal in the pseudoaneurysm (white arrow) representing active blood flow. Panel B: Thrombosed pseudoaneurysm following UGTI. The pseudoaneurysm sac now contains newly formed thrombus (blue arrow). Note the residual blood flow within the pseudoaneurysm neck after thrombosis of the pseudoaneurysm sac.

In our experience, ligation and excision of the infected artery and pseudoaneurysm, with aggressive debridement of surrounding infected tissue is well tolerated overall. This also avoids extended procedure times and potential complications associated with infection of bypass grafts. A recent review publication by Georgiadis et al showed an early occurrence of rest pain in 10.8% of patients and early risk of amputation in 5.7% of patients. Triple ligation (for pseudoaneurysms occurring at the common femoral bifurcation) likely results in worse outcomes for patients than single ligation.[15] In these patients, we advocate close monitoring of the affected limb in the immediate post-operative period and consideration for immediate extra-anatomical bypass if signs of limb-threatening ischemia develop.

2.6. Other peripheral iatrogenic pseudoaneurysms

In addition to femoral pseudoaneurysms, the most common sites for iatrogenic pseudoaneurysm formation are the brachial artery and popliteal artery. As with femoral

iatrogenic pseudoaneurysms, most peripheral iatrogenic pseudoaneurysms occur following catheterisation of the affected artery. Clinical features will vary depending on the location and size of the pseudoaneurysm. Symptoms and signs will relate to the pseudoaneurysm itself and its effects on neighbouring structures. For example, brachial pseudoaneurysms often cause pain and swelling in the cubital fossa, along with a palpable mass. The mass may be pulsatile with a thrill or bruit. Compression of the adjacent brachial veins or median nerve can occur, as well as ischaemic compromise of the overlying skin. Arm swelling, deep vein thrombosis, compressive neuropathy, skin necrosis and rupture are also potential complications. Similarly, DUS is the modality of choice for diagnosis of other peripheral pseudoaneurysms, particularly in centres with a dedicated vascular ultrasound laboratory. CTA is best relied on in centres without ready access to vascular ultrasound services, in cases where duplex ultrasound findings are equivocal or the anatomy is not well defined.

The options available for management of peripheral pseudoaneurysms are the same as for femoral pseudoaneurysms. Given easy percutaneous access to the peripheries, UGTI should be the treatment of choice for all suitable iatrogenic peripheral pseudoaneurysms. Published series have reported successful outcomes of UGTI with pseudoaneurysms involving the femoral, popliteal, tibial, axillary, brachial and radial arteries.[16] Radial artery iatrogenic pseudoaneurysms following arterial line insertion in critical care settings can be better treated with radial artery ligation if there is clinically good perfusion via the ipsilateral ulnar artery.

Carotid artery pseudoaneurysms are a rare subset of pseudoaneurysms. Carotid aneurysms make up less than 1% of all carotid pathologies, and of these, roughly 1 in 3 are pseudoaneurysms.[13] In modern practice, the more common causes include inadvertent catheterisation during attempted internal jugular vein central line placement, trauma (blunt or penetrating), and pseudoaneurysm formation in the anastomotic suture line following carotid endarterectomy. Local infection (e.g. TB, syphilis) causing pseudoaneurysm formation is rarely seen these days.

A pulsatile neck mass is the most common clinical presentation, followed by neurological symptoms such as TIA, stroke and Horner's syndrome.[13] Diagnosis can again be made by duplex ultrasound, however, with the possibility of endovascular intervention, CTA is best to define aortic arch anatomy and suitability for endovascular repair. The potential severe sequelae of carotid pseudoaneurysms mandates surgical intervention. Given small numbers, only case series data is available for different types of carotid aneurysm repair, with only a small subset of these comprising pseudoaneurysms. Open surgical intervention includes resection and patch angioplasty, resection and interposition grafting, and ligation.[13] The latter should be considered a last resort. Surgical reconstruction of all types of carotid aneurysm is associated with a combined stroke and mortality rate of about 10%.[17]

Endovascular interventions include covered stent grafts, bare stenting with trans-stent coiling, autogenous vein covered stents, and endovascular balloon occlusions.[13] Outcome data is limited to case series, but the data is promising. In a large single-centre series

spanning 20 years, Zhou et al report that endovascular intervention is an effective alternative to open surgery, particularly for patients with high surgical risk or distally located aneurysms that preclude a safe surgical approach.[13]

2.7. Visceral iatrogenic pseudoaneurysms

Iatrogenic pseudoaneurysms arising from the thoraco-abdominal aorta and other visceral branches have all been reported. These are typically the complications of prior surgery (vascular or non-vascular) or endovascular intervention of arterial or venous pathologies.[18-21] Patients with visceral iatrogenic pseudoaneurysms may remain chronically asymptomatic with detection only after investigation for other complaints. Alternatively, presentation may be with local compressive symptoms, or even rupture. Endovascular treatment in the form of direct thrombin injection [22], coiling [23], occlusion devices [24], and endograft stenting [25,26] have all been described and often considered be first line option of treatment in most cases [27,28]. Open surgical repair of visceral iatrogenic pseudoaneurysms can be challenging, especially when in a previously exposed surgical field. Although there has been increasing utilization of endovascular techniques for the treatment of visceral iatrogenic pseudoaneurysms, there remains a clear role for OSR in selected situations, such as when local mass effect of pseudoaneurysms requires concurrent treatment.[27]

3. Conclusion

The incidence of iatrogenic pseudoaneurysms is increasing as a result of progressive uptake of percutaneous arterial interventions for cardiovascular disease and the increased use of combination antiplatelet therapy. Femoral iatrogenic pseudoaneurysms represent the most common form of this pathology, but the incidence of other peripheral / visceral pseudoaneurysms is also likely to increase in the future. In experienced hands, thrombin injection under DUS guidance can offer prompt resolution of the pathology. However, no large randomized trials to date have definitively addressed the efficacy of this treatment technique. Physicians should be aware of the potential for pseudoaneurysm formation following percutaneous arterial interventions, and be familiar with the clinical findings and potential treatment options.

Author details

Charles P.E. Milne and Regent Lee

Oxford Regional Vascular Unit, John Radcliffe Hospital, Oxford, UK

Ashok I. Handa*

Oxford Regional Vascular Unit, John Radcliffe Hospital, Oxford, UK

Nuffield Department of Surgical Sciences, John Radcliffe Hospital, Oxford, UK

* Corresponding Author

Acknowledgement

This work is funded by the Nuffield Department of Surgical Sciences.

Regent Lee is a Lumley Surgical Research Fellow and Foundation of Surgery Research Scholar with the Royal Australian College of Surgeons.

4. References

- [1] Saad NE, Saad WE, Davies MG, Waldman DL, Fultz PJ, Rubens DJ. Pseudoaneurysms and the role of minimally invasive techniques in their management. *Radiographics* 2005;25 Suppl 1:S173-89.
- [2] Ahmad F, Turner SA, Torrie P, Gibson M. Iatrogenic femoral artery pseudoaneurysms--a review of current methods of diagnosis and treatment. *Clin Radiol* 2008;63:1310-6.
- [3] De Raet J, Vandekerckhof J, Baeyens I. Ruptured femoral pseudo-aneurysm through the skin: a rare vexing complication following aortobifemoral reconstruction. *Acta Chir Belg* 2006;106:420-2.
- [4] Middleton WD, Dasyam A, Teefey SA. Diagnosis and treatment of iatrogenic femoral artery pseudoaneurysms. *Ultrasound Q* 2005;21:3-17.
- [5] Morgan R, Belli AM. Current treatment methods for postcatheterization pseudoaneurysms. *J Vasc Interv Radiol* 2003;14:697-710.
- [6] Thomson K. Safe use of radiographic contrast media. *Australia Prescriber* 2010; :29-33.
- [7] Toursarkissian B, Allen BT, Petrinesc D et al. Spontaneous closure of selected iatrogenic pseudoaneurysms and arteriovenous fistulae. *J Vasc Surg* 1997;25:803-8; discussion 808-9.
- [8] Fellmeth BD, Roberts AC, Bookstein JJ et al. Postangiographic femoral artery injuries: nonsurgical repair with US-guided compression. *Radiology* 1991;178:671-5.
- [9] Perkins JM, Gordon AC, Magee TR, Hands LJ. Duplex-guided compression of femoral artery false aneurysms reduces the need for surgery. *Ann R Coll Surg Engl* 1996;78:473-5.
- [10] Cronenwett J, editor *Rutherford's Vascular Surgery*. 7th ed: Saunders Elsevier: Philadelphia, 2010.
- [11] Brummer U, Salcuni M, Salvati F, Bonomini M. Repair of femoral postcatheterization pseudoaneurysm and arteriovenous fistula with percutaneous implantation of endovascular stent. *Nephrol Dial Transplant* 2001;16:1728-9.
- [12] Kang SS, Labropoulos N, Mansour MA, Baker WH. Percutaneous ultrasound guided thrombin injection: a new method for treating postcatheterization femoral pseudoaneurysms. *J Vasc Surg* 1998;27:1032-8.
- [13] Zhou W, Lin PH, Bush RL et al. Carotid artery aneurysm: evolution of management over two decades. *J Vasc Surg* 2006;43:493-6; discussion 497.
- [14] Edgerton JR, Moore DO, Nichols D et al. Obliteration of femoral artery pseudoaneurysm by thrombin injection. *Ann Thorac Surg* 2002;74:S1413-5.
- [15] Georgiadis GS, Lazarides MK, Polychronidis A, Simopoulos C. Surgical treatment of femoral artery infected false aneurysms in drug abusers. *ANZ J Surg* 2005;75:1005-10.

- [16] Friedman SG, Pellerito JS, Scher L, Faust G, Burke B, Safa T. Ultrasound-guided thrombin injection is the treatment of choice for femoral pseudoaneurysms. *Arch Surg* 2002;137:462-4.
- [17] El-Sabroun R, Cooley DA. Extracranial carotid artery aneurysms: Texas Heart Institute experience. *J Vasc Surg* 2000;31:702-12.
- [18] Skourtis G, Bountouris I, Papacharalambous G et al. Anastomotic pseudoaneurysms: our experience with 49 cases. *Ann Vasc Surg* 2006;20:582-9.
- [19] Monney P, Pellaton C, Qanadli SD, Jeanrenaud X. Aortic pseudo-aneurysm caused by complete dehiscence of the left coronary artery 7 years after a composite mechanical-valved conduit aortic root replacement (Bentall operation). *Eur Heart J* 2012;33:60.
- [20] Putterman D, Niman D, Cohen G. Aortic pseudoaneurysm after penetration by a Simon nitinol inferior vena cava filter. *J Vasc Interv Radiol* 2005;16:535-8.
- [21] Konia M, Uppington J, Moore P, Liu H. Ascending aortic pseudoaneurysm: a late complication of coronary artery bypass. *Anesth Analg* 2008;106:767-8.
- [22] Schellhammer F, Steinhaus D, Cohnen M, Hoppe J, Modder U, Furst G. Minimally invasive therapy of pseudoaneurysms of the trunk: application of thrombin. *Cardiovasc Intervent Radiol* 2008;31:535-41.
- [23] Moneley D, Johnston KW, Tan KT, G O. Endovascular Treatment of an Iatrogenic Visceral Aortic Segment Aneurysm Following a Translumbar Vertebral Biopsy. *EJVES Extra* 2008;15:39-41.
- [24] Sharma RP, Shetty PC, Burke TH, Shepard AD, Khaja F. Treatment of false aneurysm by using a detachable balloon. *AJR Am J Roentgenol* 1987;149:1279-80.
- [25] Medina CR, Indes J, Smith C. Endovascular treatment of an abdominal aortic pseudoaneurysm as a late complication of inferior vena cava filter placement. *J Vasc Surg* 2006;43:1278-82.
- [26] Pasklinsky G, Gasparis AP, Labropoulos N et al. Endovascular covered stenting for visceral artery pseudoaneurysm rupture: report of 2 cases and a summary of the disease process and treatment options. *Vasc Endovascular Surg* 2008;42:601-6.
- [27] Kapoor BS, Haddad HL, Saddekni S, Lockhart ME. Diagnosis and management of pseudoaneurysms: an update. *Curr Probl Diagn Radiol* 2009;38:170-88.
- [28] Keeling AN, McGrath FP, Lee MJ. Interventional radiology in the diagnosis, management, and follow-up of pseudoaneurysms. *Cardiovasc Intervent Radiol* 2009;32:2-18.