

We are IntechOpen, the world's leading publisher of Open Access books Built by scientists, for scientists

6,900

Open access books available

186,000

International authors and editors

200M

Downloads

Our authors are among the

154

Countries delivered to

TOP 1%

most cited scientists

12.2%

Contributors from top 500 universities



WEB OF SCIENCE™

Selection of our books indexed in the Book Citation Index
in Web of Science™ Core Collection (BKCI)

Interested in publishing with us?
Contact book.department@intechopen.com

Numbers displayed above are based on latest data collected.
For more information visit www.intechopen.com



Role of Corticosteroids in Treatment of Vitiligo

Nooshin Bagherani

Additional information is available at the end of the chapter

<http://dx.doi.org/10.5772/48384>

1. Introduction

Vitiligo is the most frequent pigmentary disorder (Bagherani et al., 2011; Nazer et al., 2011;Yaghoobi et al., 2011a; as cited in Wolff et al., 2007). It is an acquired, idiopathic and progressive skin disease (Bagherani et al., 2011; Shameer et al., 2005; Yaghoobi et al., 2011a), characterized by sharply demarcated depigmented lesions on any part of the body (Van Geel et al., 2004). This disease can also affect hair and mucosal areas such as mouth and genitalia (Gawkrodger et al., 2010).

Vitiligo usually begins after birth (Gawkrodger et al., 2010). Regarding the studies retrieved from PubMed since 1995, it has been shown that approximately 50% of the vitiligo cases have its onset before the age of 20 years and 25% before the age of 14 years (Kakourou, 2009).

The incidence rate of vitiligo is between 0.1-2% of the world population (Bagherani et al., 2011; Yaghoobi et al., 2011a,b; as cited in Alkhateeb et al., 2003). Its incidence in those with racially pigmented skin is higher, although reliable figures are not available (Burns et al., 2004; Howitz et al., 1977) . The prevalence has been reported as high as 4% in some South Asian, Mexican and American populations (Parsad et al., 2003; Sehgal & Srivastava, 2007; Szczurko & Boon, 2008).

Both sexes are equally afflicted by vitiligo (Krüger et al., 2011; Njoo & Westerhof, 2001; Wolf et al.,2007) . In some studies, a female preponderance has been reported (Burns et al., 2004; Howitz et al. 1977; Wolf et al., 2007), but the discrepancy can be attributed to a presumed increase in reporting of cosmetic concerns by female patients (Wolf et al.,2007).

This disorder afflicts all races and has a long history (Koranne & Sachdeva, 1988). Vitiligo was first described more than 3,000 years ago in pre-Hindu Vedic and ancient Egyptian texts (Mahmoud et al., 2008; as cited in Millington & Level, 2007). It has been introduced based on its visual phenotype (Yaghoobi et al., 2011a,b; as cited in Birlea et al., 2008; Howitz et al., 1977).

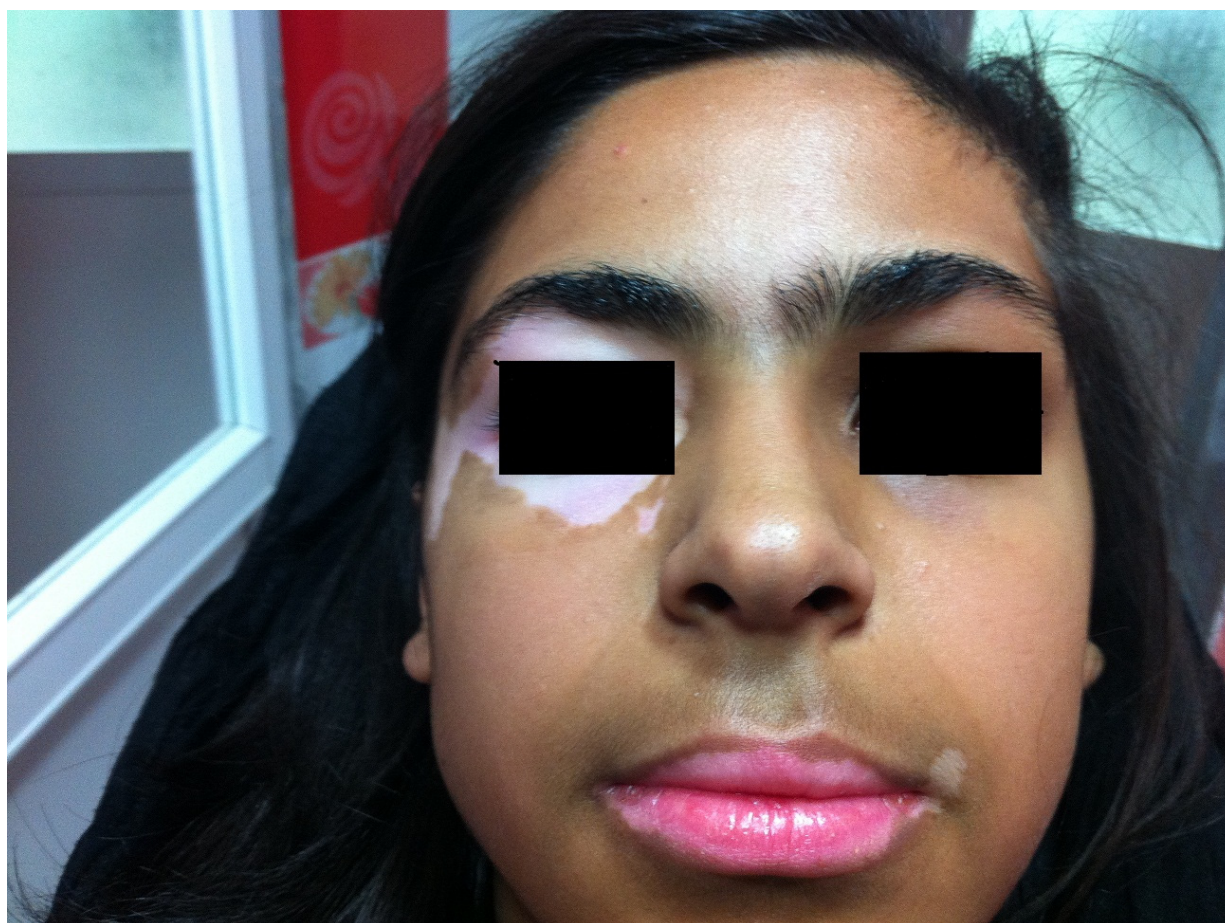


Figure 1. Vitiligo can affect skin, hair and mucous membranes

Studies have shown that approximately 20% of vitiligo patients have at least one first-degree relative with this disorder; so, it seems that the relative risk for first-degree relatives of vitiligo patients is increased by 7- to 10- fold (Wolff et al., 2007; Yaghoobi et al., 2011b). Only a few vitiligo susceptibility genes have been introduced with certainty. Currently, there is strong support for HLA, PTPN22, NALP1 and perhaps CTLA4. All of these genes are associated with autoimmune susceptibility (Spritz, 2008; Boisy & Spritz, 2009).

Although vitiligo is not painful or life-threatening, its disfiguring manifestation has a devastating effect on patient's psychosocial wellbeing. Patients often complain from stigmatization such as curiosity by other people, rejection and discrimination at work, low self-esteem, embarrassment, impaired quality of life, and higher prevalence of sexual difficulties, especially in women (Krüger et al., 2011). Hence, treatment of vitiligo seems important.

2. Clinical manifestation of vitiligo

Vitiligo is categorized as a depigmentation disorder, where the loss of active melanocytes causes the appearance of white patches on the skin (Whitton et al., 2008; Yaghoobi et al., 2011b). These patches are of various sizes and shapes. Involvement often is symmetrical (Yaghoobi et al., 2011b).

Vitiligo lesions present as one or more amelanotic macules or patches that appear chalk- or milk-white in color, surrounded by normal or hyperpigmented border. Sometimes, the lesions have a red inflammatory border (Yaghoobi et al., 2011b).

Vitiligo lesions enlarge centrifugally with an unpredictable rate and can involve any body site (Wolff et al., 2007). Initial lesions appear most frequently on the hands, forearms, feet and face (Tonsi, 2004; Wolff et al., 2007). The most affected sites are face, upper chest, dorsal part of hands, axillae and groin. It has a tendency to involve the skin around orifices. Lesions also appear at trauma sites (James et al., 2006; Yaghoobi et al., 2011b). Vitiligo lesions are sensitive to ultraviolet light and burn readily (Lotti et al., 2008b).

Vitiligo is currently classified in to two subtypes: a) segmental (type B), and b) non-segmental (type A) (Le Poole et al., 1993a; Yaghoobi et al., 2011b). Type B is more rare and characterized by focal lesions restricted to a segment. This type has a rapid onset and a stable course (Lotti et al., 2008b; Yaghoobi et al., 2011b). Type A is more common and has a potential lifelong evolution. Köbner phenomenon and autoimmune diseases are more associated with this subtype of vitiligo (Lotti et al., 2008b; Yaghoobi et al., 2011b).

In another view, vitiligo is classified based on distribution and extension of lesions (Nordlund classification) (Table-1) (Nordlund & Lerner, 1982; Lotti et al., 2008b; Yaghoobi et al., 2011b). In this classification, generalized vitiligo is the most common type of vitiligo in both adults and children (Kakourou, 2009).

Localized	
Focal	One or more macules with casual distribution
Unilateral	One or more macules are localized in a unilateral body region, with a dermatometric distribution
Mucosal	Unique involvement of mucous membranes
Generalized	
Vulgaris	Presence of scattered stains extensively disseminated
Acrofacialis	Patches are localized on distal extremities and face
Mixed	Coexistence of acrofacialis and vulgaris forms
Universalis	Depigmented lesions completely or almost completely (≥80% of body surface) cover the skin surface

Table 1. Nordlund clinical classification of vitiligo (Kakourou, 2009; Nordlund & Lerner, 1982; Lotti et al., 2008b; Yaghoobi et al., 2011b).

3. Diagnosis and differential diagnosis of vitiligo

Diagnosis of vitiligo is based on its clinical manifestation (Lotti et al., 2008b; Yaghoobi et al., 2011b). Wood's light is 365 nm, used commonly for diagnosing and confirming diagnosis of some dermatologic diseases (James et al., 2006). Vitiligo diagnosis can be confirmed with Wood's lamp examination. Its lesions are enhanced with this examination (Wolf et al., 2007).

The differential diagnoses of vitiligo have been listed in Table-2.

Acquired disorders

Post inflammatory hypopigmentation

Chemical leukoderma

Tinea versicolor

Pityriasis alba

Lichen sclerosus et atrophicus

Morphea

Sarcoidosis

Leprosy

Tertiary stage of pinta

Congenital disorders and syndromes

Nevus depigmentosus

Hypomelanotic macules of tuberous sclerosis

Piebaldism

Albinism

Vogt-Kianagi syndrome

Waardenburg's syndrome

Ziprkowski-Margolis syndrome

Table 2. List of differential diagnoses of vitiligo (Burns et al., 2004; James et al., 2006; Kakourou, 2009; Wolff et al., 2007; Yaghoobi et al., 2011b)

4. Etiology and pathogenesis of vitiligo

Vitiligo is a multifactorial disorder. It is related to both genetic and nongenetic factors (Bagherani et al., 2011; Bolognia, et al., 2008). Regarding the observed variation in its clinical manifestation, it seems likely that its pathogenesis may differ among patients (Bagherani et al., 2011; as cited in Boisy & Spritz, 2009).

Genes certainly play important role in vitiligo pathogenesis (Bagherani et al., 2011; spritz, 2008). It seems that this disorder is part of a broader, genetically determined, autoimmune, and autoinflammatory diathesis (Bagherani et al., 20011; Lebwohl et al., 2006; spritz, 2008). HLA types associated with vitiligo include in A2, DR4, DR7, and Cw6 (Bagherani et al., 2011; James et al., 2006). There are linkage signals on chromosome 1, 7, and 17 in Caucasian families with generalized vitiligo and autoimmune diseases (Bagherani et al., 2011; Jin et al., 2010). Studies have shown that HLA, PTPN22, NALP1 and CTLA4 are associated with autoimmune susceptibility in vitiligo patients (Spritz, 2008; Boisy & Spritz, 2009). Mutation is another pathogenesis suggested for vitiligo (Le Poole et al., 1993a).

Autoimmunity is the most popular hypothesis for vitiligo pathogenesis (Daneshpazhooh et al., 2006; Yaghoobi et al., 2011b). Regarding the autoimmune hypothesis, antibodies develop against melanocyte surface antigens (Mahmoud et al., 2008). Many patients with generalized vitiligo have serum autoantibodies and circulating autoreactive T cells against melanocytes

and their components (Yaghoobi et al., 2011b). In a study, an elevated ratio of CD4⁺/CD8⁺ T cells was seen, which was a sign of imbalanced lymphocyte immune response (Pichler et al., 2009). In another study, small amount of IgG and C3 deposits in the basement-membrane zone and keratinocytes were seen in vitiligo lesions (Uda et al., 1984).

The melanocytes of vitiligo patients are susceptible to environmental triggers or other stressors. These events can possibly result in melanocyte death by necrosis, apoptosis or pyroptosis, consequent presentation of tolerogens and loss of immune tolerance, and ultimately autoimmunity directed against melanocytes (Boisy & Spritz, 2009; Mahoney & Rosen, 2005).

Increased level of soluble IL-2 receptor, IL-6 and IL-8 in vitiligo patients suggests that T cell activation may be a component in vitiligo pathogenesis (Mandelcorn-Monson et al 2003; Namazi, 2005). The detection of significantly higher expression of IL-6 and TNF- α in vitiligo skin, compared with healthy skin indicates an imbalance of epidermal cytokines at sites of lesions (Moretti et al., 2002).

Oxidant stress may also play an important pathogenic role in vitiligo (Wolff et al., 2007). It is suggested that the imbalance in the oxidant-antioxidant system rather than oxidative stress might play such role in this disease (Helmy et al., 2004).

As another probable pathogenesis, it is suggested that carious factors including localized trauma, stress and autoimmune predisposition can act synergistically to disappear melanocytes from the epidermis (Gauthier et al., 2003; Yaghoobi et al., 2011b).

Melanocyte growth factor deficiency is another hypothesis about vitiligo pathogenesis (Hossani-Madani & Halder, 2010; Njoo & Westerhof, 2001).

In human melanocytes, there is expression of 1,25-dihydroxy-vitamine D3 receptor. Defect in calcium uptake has been seen in keratinocytes and melanocytes of vitiligo lesions. This defect can inhibit melanogenesis via downregulation of tyrosinase activity (Lotti et al., 2008b).

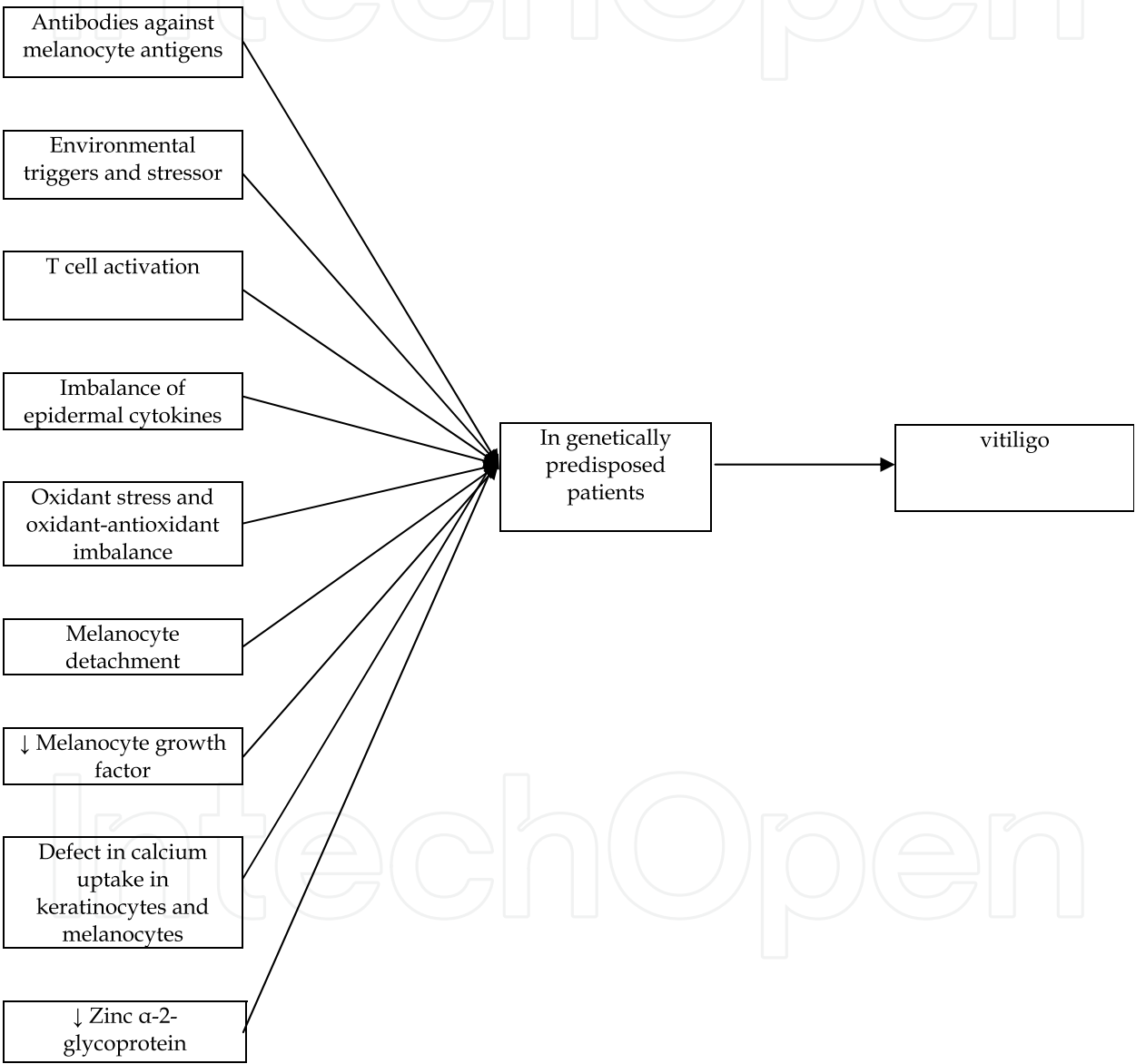
The melanocytorrhagy is a hypothesis which was described by Gauthier and colleagues for the first time. According to this hypothesis, melanocyte detachment from the basal layer and transepidermal migration can trigger melanocyte death in vitiligo (Gauthier et al., 2003).

Zinc α -2-glycoprotein is a plasma glycoprotein which regulates melanin production by normal and malignant melanocytes (Bagherani et al., 2011; Hale, 2002). For the first time, as a hypothesis, Bagherani and colleagues suggested that there might be association between this glycoprotein and vitiligo, which should be confirmed (Bagherani, 2011, 2012a, b; Bagherani et al., 2011; Yaghoobi et al., 2011a).

Other etiopathogeneses which have been suggested for vitiligo are summarized in: accumulation of toxic compounds, impaired melanocyte migration and/ or proliferation, altered cellular environment, infection, neural and autocyctotoxic factors (Yaghoobi et al., 2011b).

Whatever its etiology or pathogenesis, it seems that stress or certain life events such as loss of close relations, bereavement, moving home, giving birth or losing a job can trigger the onset or progression of vitiligo. On the other hand, in one study, Krüger and colleagues showed that there is no difference in levels of cortisol and β -endorphin between patients and controls, indicating that stress per se is not a significant contributor in vitiligo (Krüger et al. 2011). Hence, the role of stress in onset and progression of vitiligo should be assessed.

The probable pathogenesis of vitiligo have been summarized in diagram1.



Scheme 1. The probable pathogenesis of vitiligo

5. Pathology of vitiligo

Histopathologically, the most prominent feature of vitiligo is the alteration of melanocytes in the dermo-epidermal junction (Elder et al., 2009; Yaghoobi et al., 2011b). Most of the

studies confirm the complete absence of melanocytes in the fully depigmented skin in vitiligo; thus, it seems that only hair follicles can act as a reservoir (Dogra & Bhusahan, 2005; Le Poole et al., 1993).

There is inconstant lymphonuclear infiltrate in the advancing margins of lesions (Ogg et al., 1998; Lotti et al., 2008b). In the outer border of lesions, melanocytes are often prominent which show long dendritic processes filled with granules of melanin (Moellman et al., 1982).

In this disorder, melanocytes are degenerated and seem to be replaced by Langerhans cells (Lotti et al., 2008b). In addition, the epidermis of regions around the margins of vitiligo has abnormality of keratinocytes (Burn et al., 2004). In long-lasting lesions, there are degenerative changes in nerves and adnexal structures of the skin (Elder et al., 2009).

6. Association between vitiligo and other disorders

Disorders associated with vitiligo have been listed in Table-4. Hashimoto's thyroiditis is the most common associated disorder in children vitiligo; so, thyroid function test should be screened annually in all children with vitiligo (Kakourou, 2009).

Autoimmune disorders
Autoimmune thyroid disease (particularly Hashimoto thyroiditis and Graves disease)
Pernicious anemia
Systemic lupus erythematosus
Lichen sclerosis
Morphea
Scleroderma
Diabetes mellitus
Adrenal insufficiency (Addison's disease)
Alopecia areata
Hypoparathyroidism
Myasthenia gravis
Gonadal failure
Inflammatory bowel disease
Rheumatoid arthritis
Psoriasis
Chronic urticaria
Autoimmune polyglandular syndrome
Sutton or halo nevus
Others
Malignant melanoma
Asthma

Table 3. Disorders associated with vitiligo (Alkhateeb et al., 2003; Birlea et al., 2008; Bolognia et al, 2008; Burn's et al., 2004; Daneshpazhooh et al., 2006; James et al., 2006; Lebwohl et al., 2006; Pichler et al., 2009; Yaghoobi et al., 2011b; Zhang et al., 2009)

7. Treatment of vitiligo

The disfigurement related to vitiligo causes emotional stress for the patient and his or her family, which necessitates treatment (Lebwol et al., 2006; Yaghoobi et al., 2011b). Although vitiligo is generally resistant to most of treatments, spontaneous repigmentation can occur in more than 10-20% of patients (Lotti et al., 2008b; Yaghoobi et al., 2011b).

Emotional stress can induce and exacerbate vitiligo and vice versa (Kakourou, 2009). On the other hand, it seems that poor patient satisfaction can cause poor adherence to treatment with consequently poor response. Studies have shown that the likelihood of dermatological patient satisfaction is increased by the physician's ability to exhibit empathy (Boehncke et al., 2002); thus, at the beginning of treatment, psychological interventions are important and suggested as a way of improving quality of life (Gawkrodger et al., 2010).

The aim of vitiligo treatment is stopping the disease progress and restoring the loss of melanocytes in the lesions (Gawkrodger et al., 2010; Njoo et al., 1999). Some treatments can achieve both aims (Gawkrodger et al., 2010).

Although a variety of therapeutic modalities have been introduced for treatment of vitiligo, there is still no universally effective and safe therapy (Njoo et al., 1999). However, sunscreens and camouflage products should be offered to all patients (Gawkrodger et al., 2010).

Almost all therapy modalities for vitiligo have borrowed from therapies whose prime target has been another disease (Gawkrodger et al., 2010). Till 2010, 68 treatments for vitiligo had been evaluated in clinical trials during 43 years (Eleftheriadou et al., 2011; as cited in Whitton et al., 2010).

7.1. Topical corticosteroids

In many instances, the first line therapy for vitiligo is topical medicaments. Regarding topical therapy that might be effective in treatment of vitiligo, topical corticosteroids are the usual first line treatment (Gawkrodger et al., 2010). The ease of application, high rate of compliance, and low cost are the advantages of topical corticosteroid therapy for vitiligo (Coskun et al., 2005; Kostovic et al., 1999).

According to the high incidence of corticosteroid side effects in children, recommended treatments for children with vitiligo differ slightly from those for adults (Gawkrodger et al., 2010). In generalized vitiligo, the use of topical steroids is impractical because of associated side effects (Mahmoud et al., 2008).

Topical corticosteroids are available in a variety of potencies and preparations (Ference & Last, 2009). Studies have shown that use of highly potent or potent topical corticosteroids can repigment vitiligo, but only in a small proportion of cases (Clayton, 1977; Gawkrodger et al., 2010; Kandil, 1974). In another study, the responses to corticosteroid therapy in vitiligo patients range between 20% and 90% improvement, usually not be a complete cure (Clayton, 1977; Kandil, 1974; Lepe et al., 2003; Njoo et al., 1998).

Studies have shown that clobetasol is the most effective topical corticosteroid for treatment of vitiligo because it can very often produce pigmentation (Lepe et al., 2003).

7.2. Topical calcineurin inhibitors

Regarding the autoimmune hypothesis of vitiligo pathogenesis due to humoral and cellular dysfunction, the topical use of immunomodulating calcineurin inhibitors such as tacrolimus and pimecrolimus, in addition to corticosteroids which are also immunosuppressive, appears reasonable for treatment of this disease (Coskun et al., 2005). They act at the level of gene expression and suppress proinflammatory cytokines such as interleukins TNF- α and INF (Berti et al., 2009 ; Mahmoud et al., 2008).

The efficacy of topical calcineurin inhibitors in treatment of vitiligo is comparable with topical corticosteroids (Mahmoud et al., 2008). They can be used as a treatment of choice for the vitiligo lesions on the head and neck, especially when the disease is long lasting (Berti et al., 2009). The treatment response of segmental vitiligo is appropriate to calcineurin inhibitors (Kakouro, 2009; Silverberg et al., 2004).

These agents have no side effects seen in long-term use of corticosteroids (Lebwohl et al., 2003; Mahmoud et al., 2008). Pruritus, burning sensation, and erythema are the adverse reactions of topical calcineurin inhibitors (Lepe, et al, 2003). Although topical application of these agents is not related to immunosuppression, the long-time risk from their application to the skin is still unknown (Berti et al., 2009)

7.3. Phototherapy

Phototherapy has been mainstay treatment for vitiligo for several years (Gawkrodger et al., 2010). It is appropriate for extensive vitiligo, especially active one (Gawkrodger et al., 2010). Ultraviolet (UV)-based therapy includes photo therapy [ultraviolet B (UVB)], photochemotherapy [psoralen plus ultraviolet A (UVA) or PUVA], and targeted phototherapy (excimer laser and excimer lamp) (Hamzavi et al., 2012).

The efficacy of phototherapy is related to lesional location. While face and neck lesions show good responses to phototherapy, acral lesions are resistant (Lee et al., 2010).

Photosensitizers used in photochemotherapy either increase the sensitivity of the skin (psoralen) or increase the sensitivity of melanocytes (kellin) via activating melanocytes and melanosomes and inducing IL-1 synthesis (Mahmoud et al. 2008).

The risk of skin cancer in PUVA- treated vitiligo patients is not clear (Gawkrodger et al., 2010). In a cohort study, Nijsten and Stern showed that exposure to PUVA increased the risk of nonmelanoma skin cancer dramatically (Nijsten & Stern, 2003).

In a retrospective study on 97 patients during 10 years, Kwok and colleagues concluded that response to PUVA is often followed by relapse. They emphasized that careful patient counseling before PUVA therapy is necessary, because this treatment seldom causes extensive repigmentation which is cosmetically acceptable (Kwok et al., 2002).

UVB, in the form of narrow band (NB-UVB) (311nm-313nm) or broad band (BB-UVB) (290nm-320nm), can inhibit cytokines induction and secretion, and stimulate inactive melanocytes of the outer root sheath of hair follicles for migrating to vitiligo lesions (Mahmoud et al. 2008).

NB-UVB uses the effective part of ultraviolet B and excludes erythema-inducing ray; so it has a definite edge over BB-UVB. The Excimer light is a NB-UVB source for treating localized areas (Gawkrodger et al., 2010).

The advantages of NB-UVB are shorter sessions of phototherapy and suitability in pregnancy and children. In addition, it causes no phototoxicity, xerosis, or hyperkeratosis as seen with PUVA (Rath et al., 2008). Treatment with NB-UVB can produce approximately 42.9% repigmentation in vitiligo patients after 6 months of therapy (Hamzavi et al., 2004). One clinical trial showed that segmental vitiligo was resistant to NB-UVB. In this study, Anbar and colleagues showed that response to UVB was better in earlier lesions especially lesions on the face, trunk and limb (Anbar et al., 2006).

Studies have revealed that NB-UVB is superior to PUVA when comparing the rate of pigmentation. In addition, these studies showed that UVB results in improved color-matched repigmentation and has lower incidence of side effects, comparing to PUVA (Parasad et al., 2006; Yones et al., 2007). In a meta-analysis of studies on generalized vitiligo, the highest mean success rates were achieved orderly with NB-UVB (63%; 95% CI, 50-76%), BB-UVB (57%; 95% CI, 29-82%), and PUVA phototherapy (51%; 95% CI, 46%-56%). This analysis also revealed that PUVA is associated with the highest rates of side effects. On the other hand, El Mofty and colleagues showed that NB-UVB photo therapy had a similar repigmentary effect as PUVA (El Mofty et al., 2006). By comparing these findings, NB-UVB is choice treatment for extensive vitiligo.

Combination of NB-UVB and calcipotriol has no increase in efficacy comparing to NB-UVB alone, because calcipotriol is rapidly degraded (>90%) by UV (Mahmoud et al, 2008; Sitek et al., 2007). Findings have shown that combination of PUVA and calcipotriol is more effective than PUVA alone (Mahmoud et al., 2008).

Some studies have shown a synergistic activity in combination therapy with topical tacrolimus and UVB phototherapy. In addition, Tacrolimus can prevent UVB-induced erythema by suppressing early-phase events of the inflammatory process. But this combination may increase the risk of skin cancer because findings in animals have shown that topical calcineurin inhibitors have no effect on the clearance of DNA photoproducts (Mahmoud et al., 2008).

Excimer laser is another treatment option for vitiligo, which has a wavelength of 308 nm. Its efficacy in treatment of vitiligo lesions on face, neck and genitalia is good (>70% repigmentation) (Mahmoud et al., 2008).

Low- energy helium-neon laser (632.8 nm) is effective in treatment of vitiligo. This kind of laser has a biostimulation effect rather than thermal effect. In vitro study on cultured

keratinocytes and melanocytes conducted by Yu and colleagues showed that helium-neon laser could stimulate proliferation and migration of melanocytes. Their study on the efficacy of this kind of laser on patients with segmental vitiligo revealed positive responses (> 50% repigmentation in 60% of patients with segmental vitiligo) (Yu et al., 2003).

7.4. Vitamin D derivatives

Calcipotriol is a vitamin D₃ analogue that inhibits T-cell activation. It also stimulates growth and differentiation of keratinocytes and melanocytes, induces melanogenesis by reducing the disturbed calcium influx into melanocytes, and restores calcium homeostasis (Lebwohl et al., 2003; Mahmoud et al., 2008).

Several studies have shown that calcipotriol, as a monotherapy has little or no treatment response in vitiligo patients (Mahmoud et al., 2008). Some other studies have shown that calcipotriol is 77% effective in treating adults with vitiligo (Ermis et al., 2001; Lepe et al., 2003).

Katayama and colleagues showed that clinical response to tacalcitol [1 α ,24(OH)₂D₃] was unfavorable in treatment of vitiligo, but it in combination with solar irradiation had favorable responses (Katayama et al., 2003).

7.5. Systemic immunosuppressive agents

Systemic immunosuppressive is another option for treatment of vitiligo (Dogra & Bhusahan, 2005; Gawkrödger et al., 2010; Kovacs & Missouri, 1998). Systemic corticosteroids and azathioprine are immunosuppressives with well-known efficacy in treatment of this disorder (Gawkrödger et al., 2010).

The efficacy of intralesional and oral corticosteroids have been assessed in limited trials with unknown significance (Whitton et al., 2008; Yaghoobi et al., 2011b). Dogra and Bhusahan reported a patient with vitiligo universalis concurrent with pemphigus vulgaris, treated with dexamethasone-cyclophosphamide pulse therapy. Their patient showed repigmentation on the face after 37 years (Dogra & Bhusahan, 2005).

Azathioprine in combination with PUVA can produce earlier and greater repigmentation in adults with symmetrical vitiligo lesions (Radmanesh & Saedi, 2006).

The efficacy of methotrexate in treatment of vitiligo was assessed for the first time by Nazer and colleagues. They revealed that its efficacy was comparable with NB-UVB and systemic corticosteroids (Nazer et al., 2011).

7.6. Surgical modalities

Surgical modalities are only appropriate for stable vitiligo (Njoo et al., 1999; as cited in Falabella et al., 1995; Hatchome et al., 1990). They are appropriate for cosmetically sensitive sites such as face and back of hands. These modalities are not recommended in children (Gawkrödger et al., 2010).

Surgical treatments have the advantage of rapid and desirable amounts of repigmentation. Patients with positive history of Köbner phenomenon, postinflammatory hyperpigmentation, keloids, or hypertrophic scars are not suitable candidate for surgical interventions (Mahmoud et al., 2008).

The different procedures of surgical modalities include in tattooing, organ-cultured fetal skin allografting, epidermal culture grafting, melanocyte culture grafting, autologous noncultured melanocyte-keratinocyte cell transplantation, epidermal blister grafting, thin Thiersch split skin grafting and miniature punch grafting (Mahmoud et al., 2008).

Among the several surgical modalities for treatment of vitiligo, the highest mean success rates are achieved with split skin grafting and epidermal blister grafting (Njoo et al., 1998). Sometimes multiple modalities are needed for getting to desirable responses (Mahmoud et al., 2008).

Dermabrasion is another treatment option for vitiligo (Hossani-Madani& Halder, 2010; Mahmoud et al., 2008).

7.7. Other complementary modalities

For the first time, Bagherani and colleagues revealed that oral zinc can be effective in treatment of vitiligo (Bagherani et al.,2011; Yaghoobi et al., 2011a).

Oral supplementation with antioxidant pools containing α -lipoic acid before and during NB-UVB significantly improves the clinical effectiveness of phototherapy and reduces vitiligo-associated oxidative stress (Dell'Anna et al., 2007).

Oral sex steroid-thyroid hormone is also effective in treatment of generalized vitiligo. This efficacy is related to the stimulatory effect of melanocyte proliferation and melanin production via alpha-MSH (Ichimiya, 1999; Muto et al., 1995; Nagai et al, 2000).

Levamisole is another option for treatment of vitiligo. It is safe and effective in controlling the activity of the disease process in limited slow-spreading vitiligo. Combination of levamisole with topical corticosteroids can produce faster rate of repigmentation (Pasricha & Khera, 1994).

A rather uncommon, but effective, treatment modality is the combination of pseudocatalase and balneo/climatotherapy at the Dead sea (Krüger et al., 2011; as cited in Schallreuter et al., 2002). Krüger and colleagues showed in their study that group therapy had a strong and long- lasting positive effects in quality of life in vitiligo patients (Krüger et al., 2011).

Ginkgo biloba (Szczurko et al., 2011) , oral L-phenylalanine (Whitton et al., 2008), topical fluorouracil(Tsuji & Hamada, 1983), topical prostaglandin E (PGE2), topical melagenina I and II, minoxidil, homeopathy,placental extract in combination with light exposure (Majid, 2010), ayurvedic medicine, clintologic, and balneologic therapies (Lotti et al., 2008b). are as alternative therapies for vitiligo. As a hypothesis, phenytoin can be effective in treatment of vitiligo (Namazi, 2005).

7.8. Depigmenting agents

Depigmentation can be recommended to adults severely affected by vitiligo (Gawkrodger et al., 2010). It can be achieved with monobenzyl ether of hydroquinone and monomethyl ether of hydroquinone at 20% concentration, either alone or in combination with Q-switched ruby laser (Mahmoud et al., 2008).

8. History of vitiligo treatment with corticosteroids

In human body, inflammatory immune reactions are regulated by endogenous glucocorticoids such as cortisol (Wolverton, 2007). For more than 50 years, steroids have been introduced to be involved in various physiological responses (Falkenstein et al., 2000; as cited in Beato et al., 1996; Beato and Klug, 2000).

For the first time, Kendall described compound E (cortisone) in 1935. In 1948, a Mayo Clinic group described primarily the use of cortisone and adrenocorticotrophic hormone (ACTH) in patients with rheumatoid arthritis (Wolverton, 2007; as cited in Lester, 1989).

Several stronger corticosteroids are now available since their first introduction. They are used as monotherapy or in combination with other agents for increasing efficacy (Tadicherla et al., 2009).

Corticosteroids with a keton group at the C11 position such as cortisone must be reduced to their 11-hydroxyl analogs (hydrocortisone) to be active. This process cannot occur effectively in the skin (Wolverton, 2007). Thus, early attempts to use cortisone failed until 1951, when Sulzberger and colleagues described the use of cortisone and ACTH in a variety of inflammatory dermatoses for the first time (Wolverton, 2007; as cited in Sulzberger et al., 1951). Their success was a cornerstone in dermatology (Wolverton, 2007). Now days, topical corticosteroids are the most commonly prescribed agents in treatment of dermatologic conditions (Tadicherla et al., 2009).

Almost all treatments of vitiligo have borrowed from therapies whose prime targets have been another diseases (Gawkrodger et al., 2010). Topical corticosteroids have been indicated and used during the last three decades for treatment of limited area of vitiligo (Coskun et al., 2005; Hartmann et al., 2004). For two decades, monotherapy with topical corticosteroids has been the most common treatment for vitiligo in children (Lepe et al., 2003; Njoo et al., 1998).

The search for substances, such as calcipotriol and tacrolimus, with the benefits of topical steroids without serious side effects has made big advances in treatment of vitiligo (Lepe et al., 2003; as cited in Assmann et al., 2000).

9. Place of corticosteroids in treatment of vitiligo

Many skin disorders are treated with topical corticosteroids, but evidence of effectiveness has been published only for a small number of disorders (Ference & Last, 2009). For concerning specific indications for topical corticosteroids, skin diseases should be clarified in

which: a) topical corticosteroids are first choice treatment; b) topical corticosteroids are efficacious as alternative or adjuvant treatment; c) the proposed use of topical corticosteroids to be confirmed as effective; and d) topical corticosteroids can be prescribed for symptomatic relief (Giannotti & Pimpinelli, 1992).

In addition to vitiligo, topical corticosteroids are effective for treatment of psoriasis (Ference & Last, 2009), atopic dermatitis, aczema, infantile seborrhoeic eczema, pompholyx, contact dermatitis (Harper, 1988), lichen sclerosus, bullous pemphigoid, pemphigus foliaceus, alopecia areata, phimosis, and radiation dermatitis. Topical corticosteroids may also be effective in other conditions, but data supporting their use in these conditions are from low-level studies. Melasma, chronic idiopathic urticaria, infantile acropustulosis and prepubertal labial adhesions are included in the latter category (Ference & Last, 2009).

Systemic corticosteroid is useful in treatment of skin diseases. In addition to vitiligo, it is also effective in treatment of acute hypersensitivity diseases, connective tissue diseases, and immunological blistering diseases (Barnetson & White, 1992).

Assessment of different vitiligo treatment options is difficult because there is no standardized scoring system for vitiligo (Mahmoud et al. 2008). Some studies concluded that topical corticosteroids and narrowband UVB monotherapy were the most effective and safest forms of treatment for localized and generalized vitiligo, respectively (Whiton et al., 2008).

The ease of application, high rate of compliance, and low cost are the advantages of topical corticosteroid therapy (Coskun et al., 2005; Kostovic et al., 1999) which take it as a first choice in treatment of localized forms of vitiligo (Coskun et al., 2005). A study conducted by AlGhamdi showed that the most two common treatment modalities for vitiligo were topical corticosteroids and NB-UVB in Saudi Arabia (AlGhamdi, 2009).

Clobetasol is the most effective topical corticosteroid for treatment of vitiligo because it can often produce pigmentation where other topical steroids have failed (Lepe et al., 2003).

Fluticasone propionate is the first carbothioate corticosteroids, classified as a potent, characterized by high lipophilicity, high glucocorticoid receptor binding and activation, and a rapid metabolic turnover in skin; thus, it has low cutaneous and systemic side effects, even in sensitive areas such as face, the eyelids and intertriginous regions (Kumaran, 2006). It seems that it can be a good treatment option for vitiligo.

Mometasone furoate is a non fluorinated topical corticosteroid. It has high potency and safety profile. Masuria and colleagues have shown that this corticosteroid was a suitable option for treatment of vitiligo in children. In their study, 90-100% repigmentation was achieved in more than 80% of cases with lesions on the face, and more than 60% of patients with vitiligo on the other parts of the body (Masuria et al., 1999).

Several studies have reported use of topical corticosteroids with varying degrees of efficacy in treatment of vitiligo (Coskun et al., 2011; Ongenae et al., 2004). Some of them have shown that the responses to corticosteroid therapy in vitiligo patients range between 20% and 90% improvement, usually not be a complete cure (Lepe et al., 2003; Njoo et al., 1998). A study

assessing intermittent topical clobetasol propionate, conducted by Kumari and colleagues showed 90-100% repigmentation in more than 80% of patients with vitiligo of the face and more than 40% of patients with vitiligo on other parts of the body (Kumari, 1984). Moderate- to high-potency topical corticosteroids are also effective for children vitiligo, but may be associated with systemic absorption (Kwinter et al., 2007).

Repigmentation in vitiligo can be labeled as marginal, perifollicular, diffuse, and combined. Parsad and colleagues, during a study on repigmentation patterns in 352 vitiliginous patches, showed that Perifollicular repigmentation was the most prevalent type of repigmentation. In their study, marginal pattern was the most stable one (93.3%), followed by perifollicular (91.7%) and combined type (84.4%). Diffuse pattern of repigmentation was the least stable (78.5%). They revealed that PUVA predominantly exhibited a perifollicular pattern and topical or systemic corticosteroids produced diffuse one. The majority (80%) of marginal pattern was seen in systemic PUVA and calcipotriol. They also showed that the repigmentation speed was much faster when the initial pigmentation was of diffuse pattern. Hence, corticosteroid in comparison with PUVA and calcipotriol induce faster, but less stable repigmentation (Parsad et al., 2004). In addition, it seems that combination therapies with producing a variety of repigmentation patterns can be remarkably more effective than monotherapy.

Combination of topical and systemic corticosteroids is effective in treatment of vitiligo. During a clinical trial, Majid and colleagues showed that more than 90% of children with rapidly progressive vitiligo went to complete remission after the start of the therapy with combination of methylprednisolone oral minipulse therapy (0.8 mg/kg body weight on two consecutive days every week) and topical fluticasone. In addition, 65% of these children achieved good to excellent repigmentation at the end of six months of therapy (majid et al, 2009).

Westerhof and colleagues, in probably the best controlled study to date of topical medications in vitiligo treatment, assessed the efficacy of topical fluticasone propionate alone or in combination with UVA in 135 adults during 9 months. They revealed that fluticasone alone induced mean repigmentation of only 9% (compared to UVA alone of 8%), whereas fluticasone-UVA combination resulted in mean repigmentation of 31%. They found no corticosteroid atrophy in users (Westerhof et al., 1999).

In a study, Lotti and colleagues showed that monotherapy with NB-UVB and topical betamethasone dipropionate were more effective than topical immunomodulators, calcipotriol and topical phenylalanine. They also revealed that combination of betamethasone dipropionate and NB-UVB resulted in the highest repigmentation rate (Lotti et al, 2008). In other study, Sassi and colleagues also showed that combination of excimer laser and topical hydrocortisone was effective in treatment of recalcitrant vitiligo of the face and neck (Sassi, 2008).

Kumaran, in one study revealed that combination therapy with topical corticosteroids and calcipotriol produced a significantly faster onset of repigmentation along with better stability of repigmentation (Kumaran, 2006).

In one clinical trial, Yaghoobi and colleagues showed that topical corticosteroids plus oral zinc was more effective than topical corticosteroid alone in treatment of vitiligo, but this difference was not statistically significant. It seems that more robust long-term randomized controlled trials with more patients, maybe with higher doses of oral zinc are necessary to confirm the efficacy of oral zinc in treatment of vitiligo (Yaghoobi et al., 2011a).

In a study by Lee and colleagues, it was shown that combination treatment of high-dose methylprednisolone therapy and PUVA may represent a highly effective therapeutic option for generalized vitiligo. In this study, they administered intravenous methylprednisolone for 3 day followed by PUVA twice weekly. This manner of corticosteroid administration can minimize the side effects of corticosteroids (Lee et al., 2007).

Lepe and colleagues have shown that there was no significant difference between the efficacy of clobetasol and tacrolimus used topically for treatment of vitiligo. Their study showed that with clobetasol, perifollicular islands of pigment were observed after 3 weeks of treatment. Because tacrolimus does not produce atrophy or other adverse effects, it may be very useful for younger patients and sensitive areas of the skin such as eyelids. It also can be considered as a replacement therapy for long-term corticosteroid therapy (Lepe et al., 2003).

During a prospective study on 10 patients, Coskun and colleague also showed that topical pimecrolimus was as effective as topical clobetasol to restore skin discoloring in vitiligo (Coskun et al., 2005). On the other side, during a review comparing topical corticosteroids and immunomodulators in treatment of vitiligo, Choi and colleagues showed that the duration from the start of treatment to onset of repigmentation was significantly shorter in the topical immunomodulator. They also concluded that topical immunomodulators can be considered as an alternative to topical corticosteroids in vitiligo treatment (Choi et al., 2008).

In a double-blind randomized trial comparing the efficacy of topical betamethasone and catalase/dismutase superoxide in treatment of vitiligo, Sanclemente and colleagues showed that there was no statistically significant difference on the rate of repigmentation between two agents (Sanclemente et al., 2008).

Camacho and Mazuecos in one study assessed the efficacy of oral and topical L-phenylalanine in combination with sunlight in days and topical clobetasol at nights. They showed that this combination was effective in treatment of vitiligo, with no side effect. Hence, this combination can be recommended to the patients with vitiligo on face and children (Camacho & Mazuecos, 2002).

Systemic corticosteroids can arrest the progression of vitiligo and lead to repigmentation (Mahmoud et al., 2008), but they may produce unacceptable side effects (Lee et al., 2007). There have been few reports on the efficacy of systemic corticosteroids in treatment of vitiligo (Mahmoud et al., 2008).

With using oral corticosteroids, repigmentation can become evident within 4 weeks in most cases (Imamura & Tagami, 1976). In a study on 81 patients with actively spreading vitiligo ,

it has been shown that low daily dose of oral prednisolone (0.3 mg/kg) arrested disease progression in 87.7% and repigmentation in 70.4% of cases. Results of other study also confirmed this rate of efficacy (Mahmoud et al., 2008). Seiter and colleagues in two separated studies concluded that high-dose methylprednisolone pulse therapy was effective in treatment of patients with generalized rapid progressive vitiligo (Seiter et al., 1999, 2000). Kim and colleagues also revealed that low-dose daily oral prednisolone (0.3 mg/kg) was effective in preventing the progression and inducing repigmentation of actively spreading vitiligo, which was resistant to topical corticosteroids or photochemotherapy. They also showed that this dose of prednisolone had no side effect (Kim et al., 1999). In other study, Pasricha and Khaitan showed that oral mini pulse treatment with betamethasone (5 mg as a single oral dose on 2 consecutive days per week) was effective to arrest the vitiligo progression and induce repigmentation (Pasricha & Khaitan, 1993). On the other hand, Rath and colleagues in one study showed that oral minipulse betamethasone (0.1 mg/kg body weight twice weekly on two consecutive days) had only adjunct value and had no efficacy by itself (Rath, 2008).

In one study, Vasistha and Singh showed that there was no significant difference in efficacy of intralesional corticosteroid versus placebo in treatment of vitiligo. In addition, atrophy, telangiectasia, infection and intradermal hemorrhage were some of the side effects of this treatment (Vasistha & Singh, 1979).

The possibility of Köbner phenomenon always exists with any surgical procedure in vitiligo patients. When combined with systemic corticosteroids, this possibility will decrease. In a study, the efficacy of combination of low-dose oral betamethasone and melanocyte – keratinocyte transplantation was assessed in treatment of vitiligo. Mulekar in this study showed that this combination was able to induce complete repigmentation in patients with large vitiliginous areas (Mulekar, 2006). Another study by Barman and colleague also showed that the efficacy of punch grafting in combination with topical corticosteroids was comparable with its combination with PUVA (Barman et al., 2004).

It should be noticed that brand-name corticosteroids may be more expensive, which may reduce patient's compliance. On the other hand, some generic formulation may be less or more potent than their brand-name equivalent (Ference & Last, 2009; as cited in Oslen, 1991).

10. Suggested guideline for treatment of vitiligo

To choose the best therapy for vitiligo with the highest probability of success for an individual patient, identifying the disease characteristics which help predict the therapy outcome is important (Njoo et al., 1999). Thus, beside age, duration of disease, disease localization, extent of depigmentation, and current disease activity should also be considered for clinical decision making (Giannotti & Pimpinelli, 1992; Njoo, et al., 1999; as cited in Antoniou & Katsambas, 1992; Drake et al., 1996). As a rule, it should be noticed that targeted combination therapies in vitiligo are remarkably more effective than single treatments (Lotti et al., 2008a).

In adults and children with skin type I and II, in the consultation, it is better to consider no active treatment. The use of sunscreens and camouflages products are all the things which they need (Gawkrodger et al., 2010).

In adults and children with recent onset of vitiligo and limited involvement, treatment with topical modalities should be considered (Gawkrodger et al., 2010). In vitiligo involvement less than 20% skin surface area, a potent or highly potent topical corticosteroid or topical calcineurin inhibitors are the first choice for a trial period of no more than 2 months. In these situations, combination of topical corticosteroids with excimer laser or UVA is more effective than corticosteroids alone (Hossani-Madani & Halder, 2010).

Treatment with corticosteroids for more than 2 months should be monitored closely for well-known side effects (Gawkrodger et al., 2010). Treatment with corticosteroids should be discontinued if there is no clinical improvement after 2 months of therapy (Mahmoud et al., 2008).

Once- or twice-daily application is recommended for most corticosteroid preparations (Drake et al., 1996; Ference & Last, 2009). More frequent administration does not produce better results (Ference & Last, 2009; as cited in du Vivier, 1976).

When prescribing topical corticosteroids, in addition to its potency, it is important to notice delivery vehicle, frequency of administration, duration of treatment, and side effects. It also is important to that hydration can promote corticosteroid penetration, so applying it after a shower or bath improves effectiveness (Ference & Last, 2009). Topical corticosteroids may differ in potency as well as side effects based on the vehicle in which they are formulated (Ference & Last, 2009; as cited in Pariser, 1991).

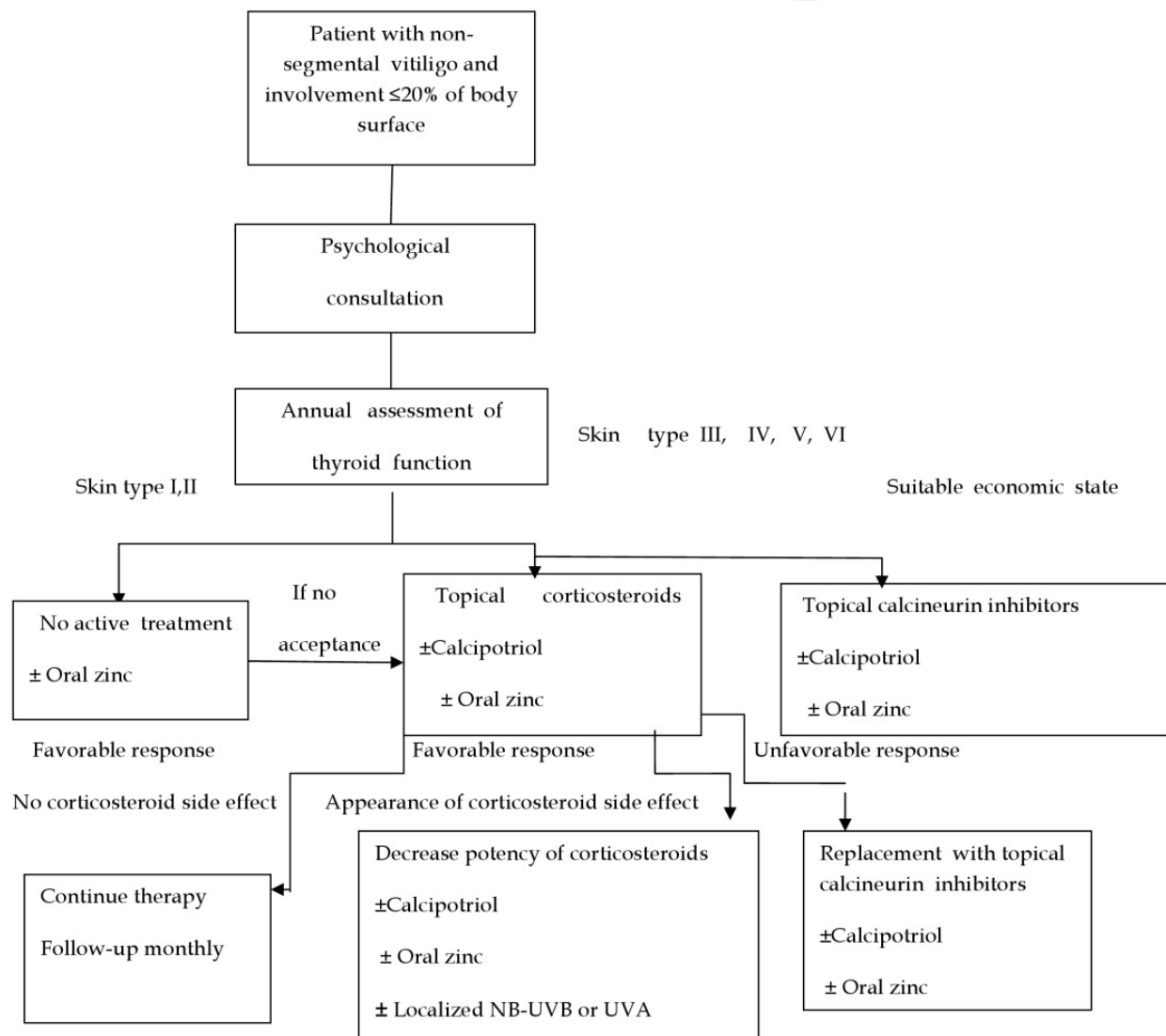
Calcineurin Inhibitors such as tacrolimus and pimecrolimus can be considered as an alternative to a topical steroid especially in children because of better safety profile (Gawkrodger et al., 2010).

One study showed that combination therapy with topical corticosteroids and calcipotriol produced a significantly faster onset of repigmentation along with better stability of repigmentation. They also showed that this combination is able to minimize corticosteroid side effects (Kumaran et al., 2006). In other study, Travis and Siverberg revealed that calcipotriene in combination with corticosteroids could repigment vitiliginous lesions, even in those with previous treatment failure with corticosteroids (Travis & Siverberg, 2004).

Extensive vitiligo (involvement more than 50%) in dark-skinned patients, especially with involvement of cosmetically sensitive areas such as hands and face can produce a severe social disability. In this instance, complete depigmentation of the affected areas might be beneficial. This procedure should be undertaken only by a specialist dermatology unit (Gawkrodger et al., 2010). Because of the psychological and cultural problems following the depigmentation and because of the increased risk of skin cancer in this condition, this procedure is better to be suggested to patients more than 50 years of age.

Surgical treatments are offered to patients with stable vitiligo, who are refractory to medical therapy (Mahmoud et al., 2008); so, these procedures should be suggested only if the disease has been inactive for 6-12 months (Gawkrodger et al., 2010). Segmental vitiligo, characterized by rapid progression followed by stabilization, is the best candidate for surgical interventions (Mahmoud et al., 2008).

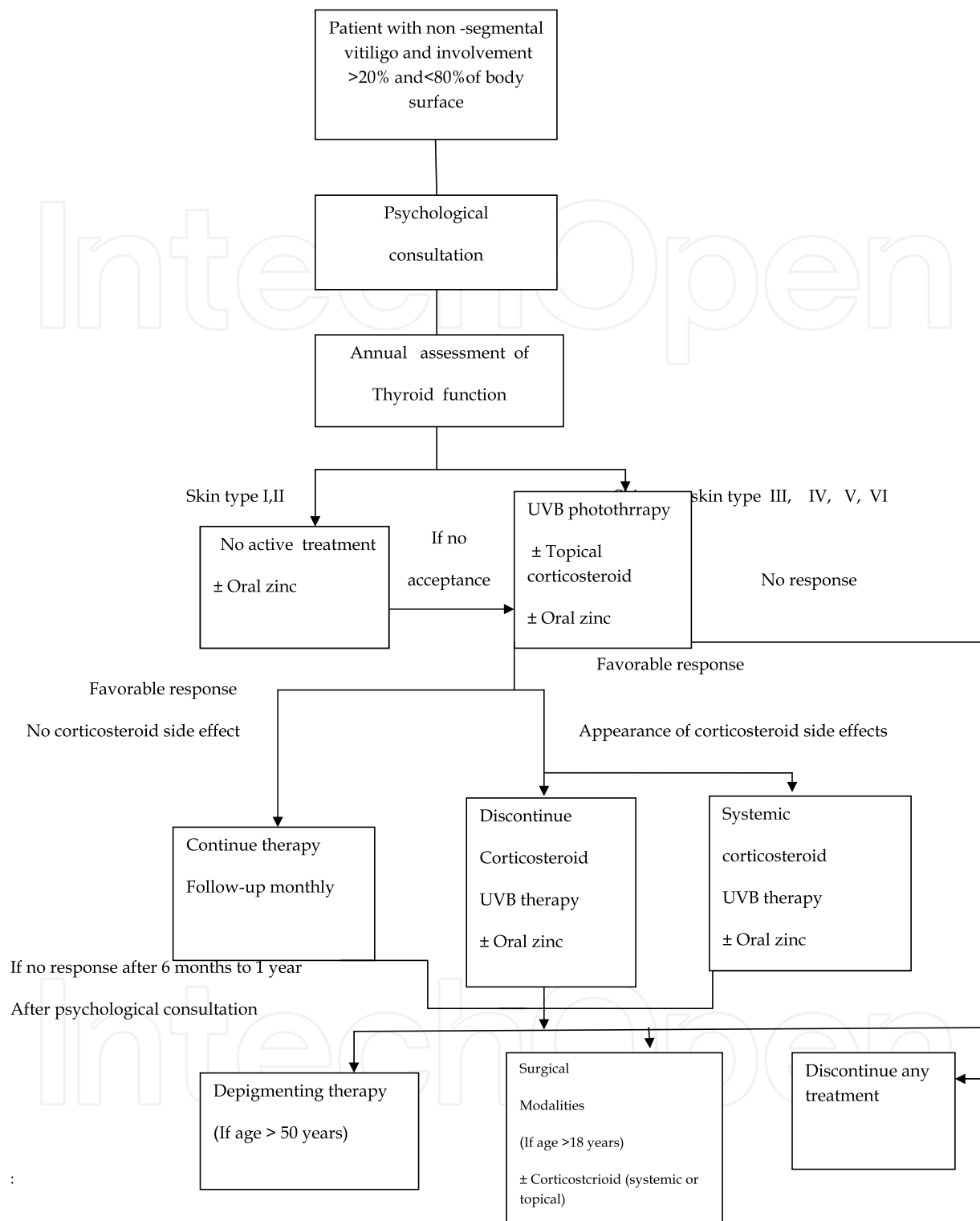
According to the above-mentioned statements about vitiligo and the efficacy of the whole options for treatment of this disorder, the author suggests a vitiligo treatment guideline which has been summarized in the diagrams of 2 to 5.



Notice to the following notes:

- In patients under treatment with oral zinc, serum zinc level must be checked every 1-2 months.
- The first visit after beginning treatment is done after 2 months, and next visits are done every month.

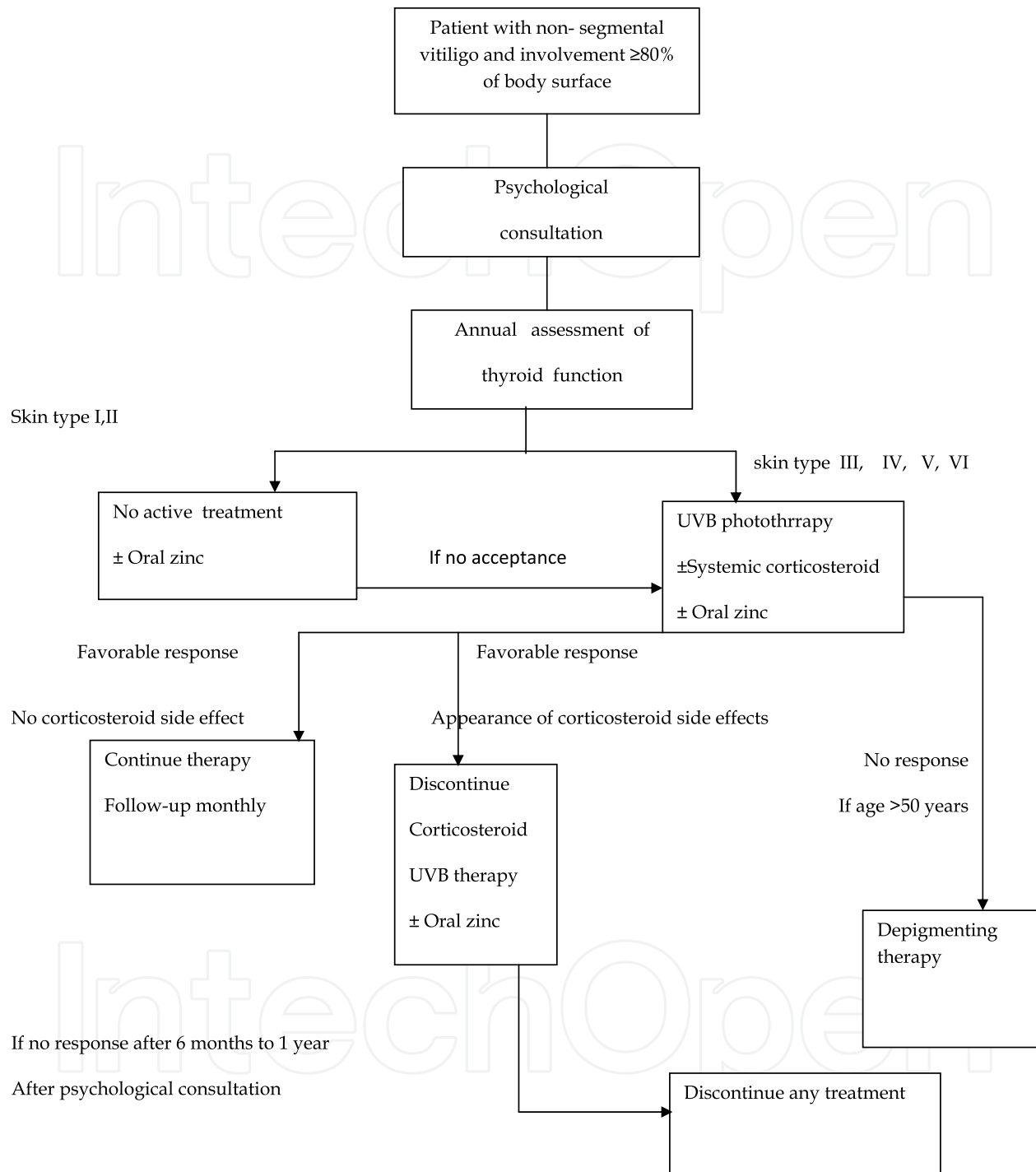
Scheme 2. Suggested treatment guideline for patients with non-segmental vitiligo and involvement $\leq 20\%$ of body surface



Notice to the following notes:

- In patients under treatment with oral zinc, serum zinc must be checked every 1-2 months.
- The first visit after beginning treatment is done after 2 months, and next visits are done every month.
- Topical corticosteroids should be administered for the limited parts especially for exposed areas, for getting better response , while presenting less systemic side effects.

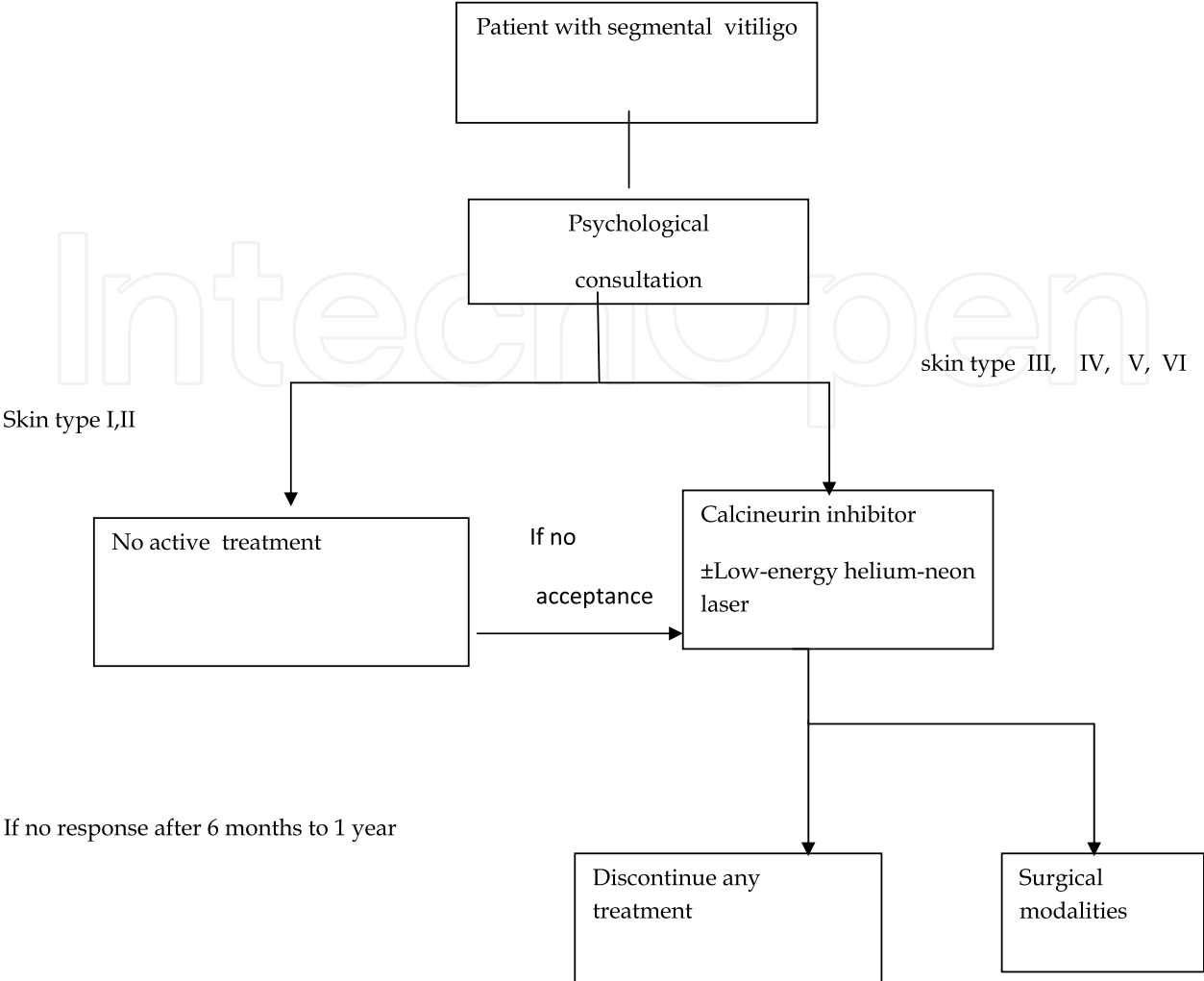
Scheme 3. Suggested treatment guideline for patients with non-segmental vitiligo and involvement >20% and <80% of body surface



Notice to the following notes:

- In patients under treatment with oral zinc, serum zinc must be checked every 1-2 months.
- The first visit after beginning treatment is done after 2 months, and next visits are done every month.

Scheme 4. Suggested treatment guideline for patients with non-segmental vitiligo and involvement $\geq 80\%$ of body surface



Scheme 5. Suggested treatment guideline for patients with segmental vitiligo

11. Assessment of vitiligo

In the first step, the diagnosis of vitiligo should be confirmed. Often its diagnosis is straightforward, although it is not always so. In vitiligo, the skin texture is usually normal. In the next step, the effect of vitiligo on the patients must be assessed; so the examination should include record of the disease distribution, extent and involvement of mucous membrane (Gawkrödger et al., 2010).

The definition of active or stable vitiligo is not the same in different clinicians' viewpoints. To date, disease activity is mainly assessed based on medical history and physical examination. Thus, the size of lesions along with their number and the grade of repigmentation are recorded using photographic tools in any follow-up visit (Njoo et al., 1999).

One of the vitiligo-associated skin manifestations is Köbner phenomenon, defined as " the development of vitiligo lesions at sites of specifically traumatized skin". Some epidemiological studies have shown that this phenomenon occurs in most patients with

vitiligo (Njoo et al., 1999). Its clinical relevance is not established; however it seems that Köbner may indicate disease activity (Table-2)(Njoo et al., 1999; as cited in Hatchome et al., 1990). Njoo and colleagues have concluded that experimental Köbner phenomenon can function as a valuable clinical factor to assess disease activity (Njoo et al., 1999).

Disease activity	VIDA Score
Active, in the past 6 weeks	+4
Active, in the past 3 months	+3
Active, in the past 6 months	+2
Active, in the past 1 year	+1
Stable, for at least 1 year	0
Stable, for at least 1 year and spontaneous repigmenting	-1

*Active refers to expansion of existing lesions or appearance of new lesions; stable refers to condition when these symptoms are not present.

Table 4. Vitiligo disease activity (VIDA) score based on the patient's own opinion (Njoo et al., 1999).

Assessment of different vitiligo treatment options is difficult because there is no standardized scoring system for vitiligo (Mahmoud et al. 2008). The percentage of depigmentation in association with total body surface can be estimated by using the hand-palm rule, i.e., a lesion in the size of the patient's palm is equal to 1% of the total body surface (Kakourou, 2009). Vitiligo Area Scoring Index or VASI can be achieved by this rule. For each body region, the VASI is determined by the hand unite rule. The total body VASI is calculated by the following formula by considering the contribution of all body regions (possible rang: 0-100) (Hamzavi et al., 2004):

$$\text{VASI} = \sum [\text{Hand Unites}] \times [\text{Residual Depigmentation}]$$

Because VASI is not accurate, Van Geel and colleagues have introduced a more accurate manner so-called a digital image analysis system for assessing vitiligo lesion surfaces both before and after different therapeutic modalities (Van Geel et al., 2004).

Patients with vitiligo have a high prevalence of autoimmune thyroid disease or other autoimmune diseases; so, thyroid function should be checked in these patients (Gawkrodger et al., 2010).

12. Probable mechanisms of corticosteroid function in treatment of vitiligo

Regarding the classic genomic theory of action, in human body, steroids such as glucocorticoids bind to specific receptors, which are intracellular transcription factors, and exert positive or negative effects on the expression of target genes (Falkenstein et al., 2000; as cited in Beato et al., 1996; Beato and Klug, 2000). These effects are mediated by a specific delay and sensitivity toward inhibitors of transcription and translations (Falkenstein et al., 2000; as cited in Beato, 1989; Evans, 1988; Fuller, 1991).

In addition to the delayed genomic actions, steroids also have rapid nongenomic effects (Falkenstein et al., 2000). These nongenomic effects on cellular function involve conventional second messenger cascades, include in phospholipase C (PLC) (Falkenstein et al., 2000; as cited in Civitelli et al., 1990), phosphoinositide turnover (Falkenstein et al., 2000; as cited in Morelli et al., 1993; Morley et al., 1992), intracellular pH (Falkenstein et al., 2000; as cited in Jenis et al., 1993), free intracellular calcium (Ca^{2+}) (Falkenstein et al., 2000; as cited in Boland & Norman, 1990), and protein kinase C (PKC) (Falkenstein et al., 2000).

Topical corticosteroids like human steroid hormones exert their effects through both direct and indirect mechanisms, which are mediated via the glucocorticosteroid receptors. These drugs affect every aspect of cutaneous inflammatory cells and immunologic mediators. They can reduce the number of lymphocytes and epidermal antigen-presenting cells. These drugs also can reduce the synthesis and secretion of IL-1, IL-2, IFN- γ and TNF (Wolverton, 2007).

Topical corticosteroids are effective for disorders characterized by hyperproliferation, inflammation, and immunologic involvement (Ferenc & Last, 2009).

Corticosteroids can be effective in treatment of vitiligo via the following mechanisms:

1. Corticosteroids can reduce the number of epidermal antigen-presenting cells so-called Langerhans' cells. They also decrease the cellular receptors of Langerhans' cells, indicating decreased antigen-presenting function (Wolverton, 2007). On the other hand, melanocytes in vitiligo lesions are replaced by Langerhans' cells (Lotti et al., 2008b). It seems that this increasing in the number of Langerhans' cells in vitiligo may be responsible for introducing unknown antigens to immune system in this disorder; thus, it appears that corticosteroid with decreasing these antigen-presenting cells in vitiligo lesions can suppress the process of its appearance.
2. Corticosteroids are able to reduce the number of lymphocytes and its antibody-dependent cellular toxicity (Wolverton, 2007). In vitiligo, the number of lymphocytes are increased in the progressing border of vitiligo lesions (Ogg et al., 1998; Lotti et al., 2008b). On the other hand, increased level of soluble IL-2 receptor, IL-6 and IL-8 in vitiligo patients suggests that T cell activation may be responsible in vitiligo pathogenesis (Mandelcorn-Monson et al 2003; Namazi, 2005). It is concluded that corticosteroids can treat vitiligo by decreasing the number of lymphocytes and their actions.
3. Topical corticosteroid can reduce the synthesis and secretion of IL-1, IL-2, IFN- γ and TNF (Wolverton, 2007). The detection of significantly higher expression of IL-2, IL-6 and TNF- α in vitiligo indicates an imbalance of epidermal cytokines at sites of lesions (Mandelcorn-Monson et al 2003; Moretti et al., 2002; Nazer et al., 2011). Thus, it seems that corticosteroids via decreasing these cytokines are able to suppress the vitiligo activity.
4. Studies have shown that patients with a positive Köbner phenomenon respond significantly better to topical corticosteroids (Njoo et al., 1999). Because the positive Köbner phenomenon is indicator of active vitiligo (Njoo et al., 1999; as cited in Xunquan

- et al., 1990), it reveals that corticosteroids may act by suppressing abnormal immune responses present in actively spreading lesions of this disorder.
5. Systemic corticosteroids can reduce complement-mediated cytotoxicity by autoantibodies to melanocytes and antibody titer to surface antigens of melanocytes in serum of users (Han et al., 1993; Mahmoud et al., 2008). On the other hand, there is positive correlation between the presence of autoantibodies and the efficacy of topical corticosteroids (Takei et al., 1984). Thus, these findings suggest that corticosteroid can be effective in treatment of vitiligo via decreasing the rate of autoantibodies-associated melanocyte cytotoxicity.
 6. In a study, Bleehen showed that the melanocytes in the steroid-treated repigmented areas were more dendritic and dopa-positive. They also contained more melanosomes of normal size, shape and melanization, when comparing to pigmented margins of untreated lesions (Bleehen, 1976).
 7. As a hypothesis, Bagherani suggested that the level of zinc α -2 glycoprotein in vitiligo lesions decreases (Bagherani, 2011, 2012a,b). On the other hand, studies have shown that corticosteroids are able to increase ZAG expression. Regarding these findings, it seems that corticosteroids are effective in treating vitiligo via enhancing ZAG (Bagherani, 2011, 2012a,b; Russell & Tisdale, 2005).
- The mechanisms of corticosteroids in treatment of vitiligo has been summarized in Diagram 6.

13. Prognostic factors effective in treatment of vitiligo

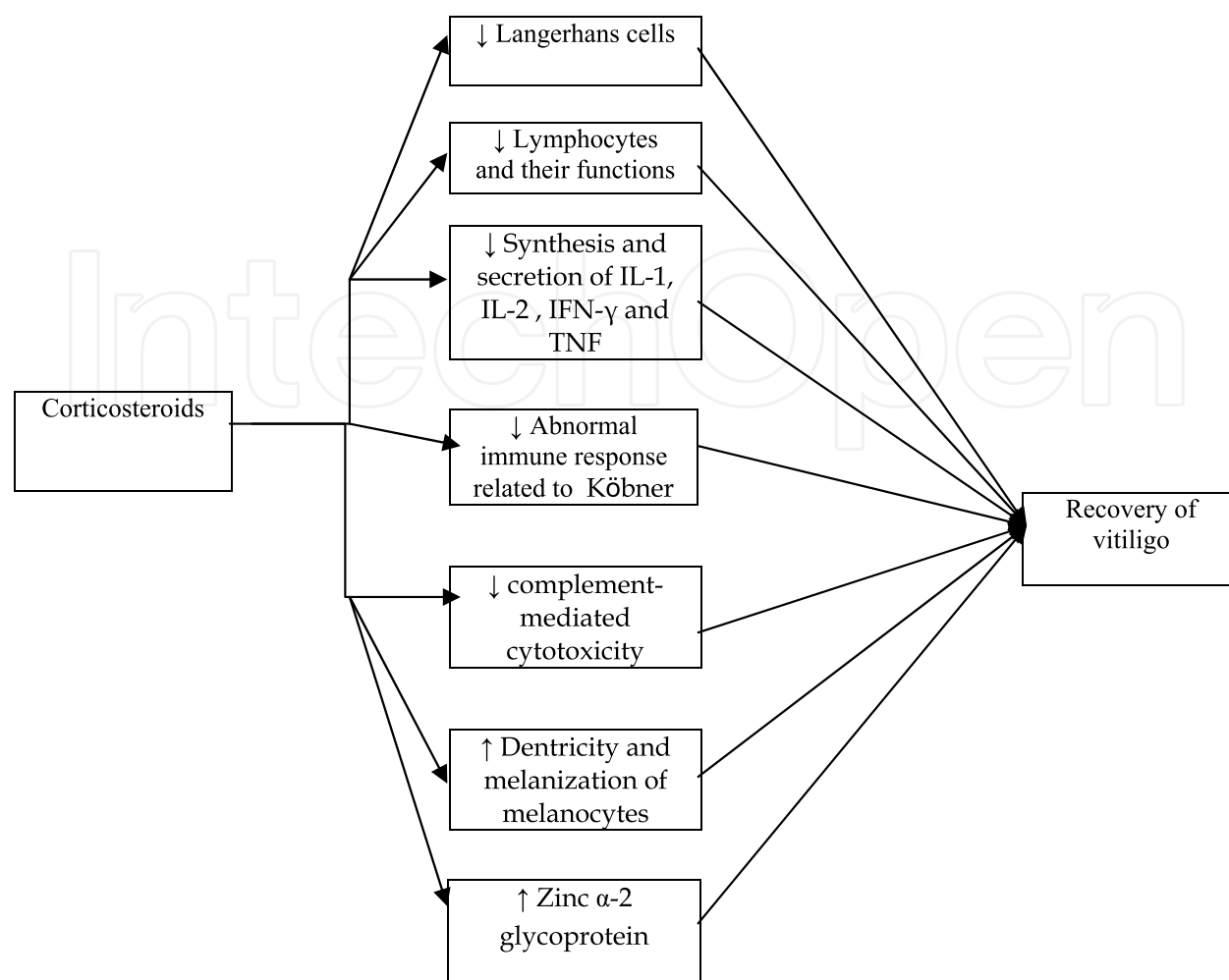
The course of vitiligo is unpredictable, but progressive. In some patients, vitiligo can be stable for many years; while in others lesions can increase in size and number. Segmental vitiligo has a stable course and resistant to treatment (Yaghoobi et al., 2011b).

Spontaneous repigmentation can appear in more than 10-20% of patients with vitiligo. This repigmentation is partial, and occurs mainly in children and in sun-exposed areas (Yaghoobi et al., 2011b).

Beside patient's age, duration, localization, extent and current activity of the disease are important for predicting the outcome of therapy in vitiligo (Njoo, et al., 1999; as cited in Antoniou & Katsambas, 1992; Drake et al., 1996). Studies have shown that younger or darker skinned patients and also those with vitiligo of the face and neck seem to respond better to therapy (Wolverton, 2007; as cited in Cockayne et al., 2002). The treatment result in Asian patients is better (Kumari, 1984). Lesions in the exposed areas response better to treatment (Imamura & Tagami, 1976). Lesions on the thorax also responded better than those on the abdomen, legs and hands (Gawkrodger et al., 2010).

It has been revealed that long lasting disease is relatively resistant to local corticosteroid, probably because of the depletion of melanocytic reserves in the hair follicles (Njoo et al., 1999; as cited in Geraldez & Gutierrez, 1987).

Takei and colleagues have shown that there is positive correlation between the antibodies and positive microsome test, thyroid test, DNA test and the efficacy of topical corticosteroids (Takei et al., 1984).



Scheme 6. The mechanisms of corticosteroids in treatment of vitiligo

In a study comparing the efficacy of clobetasol and tacrolimus in treatment of vitiligo, Lepe and colleagues have revealed that with both treatments, new pigments were conserved and the best effects of repigmentation were observed in the face and areas with greater density of hair follicles. During this 2-month study, no pigment on the dorsum of hands or areas devoid of hair follicles was seen (Lepe et al., 2003).

Kim and colleagues in one study on the efficacy of low-dose oral corticosteroid in treatment of vitiligo, showed that the response rate was statistically significant in male sex, patient age of 15 years or under, and a disease duration of 2 years or less (Kim et al., 1999).

Although it has been frequently reported that the Köbner phenomenon may be indicative of vitiligo activity, it is not clear whether patients with a positive Köbner have a different prognosis than patients with the negative one. In one study, Njoo and colleagues showed that experimental Köbner phenomenon might predict responsiveness to local corticosteroid therapy but not to UVB therapy. They revealed that patients with a positive experimental Köbner responded significantly better to topical corticosteroid combined with UVA therapy than do those with a negative one, suggesting this therapy is most effective when administered during the active stage of vitiligo (Njoo et al., 1999).

Studies have shown that patients with a good response to corticosteroid-UVA combination therapy have significantly shorter disease duration than do those with a poor response to this combination therapy (Njoo et al., 1999; as cited in Geraldez & Gutierrez, 1987).

Medical therapies are equally effective in active and stable vitiligo, while surgical procedures are only appropriate for stable one (Njoo et al., 1999; as cited in Falabella et al., 1995; Hatchome et al., 1990).

14. Side effects of corticosteroids in vitiligo patients

For the first time, Hench and colleagues presented a report concerning the side effects and toxicity of corticosteroids (Wolverton, 2007; as cited in Hench et al., 1950). It is difficult to quantify the incidence rate of side effects caused by topical corticosteroids (FERENCE & LAST, 2009; HENGGE ET AL., 2006).

The usefulness and side effects of topical corticosteroids are a direct result of their anti-inflammatory properties. They are also dependent on the frequency of administration, duration of treatment, and where on the body the drug is used (FERENCE & LAST, 2009). Prolonged use of topical corticosteroids may cause side effects (FERENCE & LAST, 2009; HENGGE ET AL. 2006). When low- to high-potency corticosteroids are used for less than three months, side effects are rare with the exception of intertriginous areas, face and neck or when occlusion is used (Drake et al., 1996; FERENCE & LAST, 2009).

Young age (infancy/children), liver disease, renal disease, hypothyroidism, obesity, lack of physician supervision, amount and potency of topical corticosteroids are risk factors which increase the chance of systemic side effects of topical corticosteroids. Young age, potency of corticosteroids and site (face, neck, axillae, groin and upper inner thighs) can enhance local side effects of topical corticosteroids (Wolverton, 2007).

Recurrence after cessation of corticosteroid therapy and their side effects including skin atrophy, telangiectasia, striae, (Coskun et al., 2005; Kostovic et al., 1999), hypopigmentation, and hypertrichosis (FERENCE & LAST, 2009; HENGGE ET AL., 2006) are the most limiting factors in treatment of vitiligo with corticosteroids. These potential side effects must be monitored closely especially in children.

Skin atrophy is a common complication of topical corticosteroids after only 2 months treatment (Gawkrödger et al., 2010; as cited in Whitton et al., 2010). In one study conducted by Clayton on 23 vitiligo patients, skin atrophy was seen in all users of clobetasol propionate (used for 8 weeks) (Clayton, 1977). In other study on 23 vitiligo patients with betamethasone valerate, Kandil noted hypertrichosis in 2, and acne in 4 subjects (Kandil, 1974). Hypopigmentation is more apparent in darker skin. Repigmentation often occurs after corticosteroids discontinuing (FERENCE & LAST, 2009; HENGGE ET AL., 2006).

Chronic application of topical corticosteroids can result in tolerance and tachyphylaxis (Drake et al., 1996; FERENCE & LAST, 2009; Wolverton, 2007). Other less common, but important, side effects of topical corticosteroid include in: purpura, psedoscars, ulceration, delayed wound healing, aggravation of cutaneous infection, hyperpigmentation, , perioral

dermatitis, contact dermatitis (allergic or irritant), photosensitization, rebound flare, steroid-induced acne, steroid-induced rosacea, folliculitis, miliaria, granuloma gluteal infantum, reactivation of Kaposi's sarcoma and ocular effects (cataracts and glaucoma) (FERENCE & LAST, 2009; HENGE ET AL., 2006; WOLVERTON, 2007).

Topical high- and ultra-high- potency corticosteroids can be absorbed enough to cause systemic manifestations such as Cushing syndrome, Hypothalamic-pituitary-adrenal suppression, aseptic necrosis of the femoral head, decreased growth rate, hypertension, hyperglycemia, and peripheral edema (FERENCE & LAST, 2009; HENGE ET AL., 2006; WOLVERTON, 2007).

Birth defects have been reported in animals, when used large amounts of topical corticosteroids; but this effect has not yet been reported in humans (Drake, 1996; FERENCE & LAST, 2009). Topical corticosteroids are classified by the U.S. Food and Drug Administration as pregnancy category C (FERENCE & LAST, 2009).

It is not reported whether topical corticosteroids can be excreted in breast milk; thus it is better to use topical corticosteroids to the breast immediately following nursing (FERENCE & LAST, 2009).

Topical corticosteroids may differ in potency as well as side effects based on the vehicle in which they are formulated. Topical corticosteroids in ointment vehicle can cause maceration and folliculitis in intertriginous areas (e.g., groin, gluteal cleft, axilla). In addition, their greasy nature may result in poor patient's satisfaction and compliance (FERENCE & LAST, 2009).

Corticosteroids in cream base are able to vanish into skin, make them cosmetically appealing. Although creams are generally less potent than ointments of the same medication and so have less side effects, skin irritation, stinging, and allergic reactions are more with creams because they often contain preservatives. Contact dermatitis also is seen more with non-fluorinated steroids (e.g., hydrocortisone and budesonide) (FERENCE & LAST, 2009; HENGE ET AL., 2006).

Occlusion increases penetration of topical corticosteroids; so it can increase their side effects. Irritation, folliculitis, and infection can develop rapidly from occlusive dressings (Drake et al., 1996; FERENCE & LAST, 2009).

Side effects are common with systemic corticosteroids in vitiligo patients, include weight gain, acne, menstrual irregularity and hypertrichosis (Radakovic et al., 2001).

15. Prevention and treatment of corticosteroid side effects in vitiligo patients

Multiple daily applications of corticosteroids do not lead to better and faster response. It only increase incidence rate of side effects. Intermittent therapy with steroid-free intervals can be as effective as continuous treatment (Giannotti, 1988). For the first time, Reichling and Kligman suggested alternate-day corticosteroid use in 1961 (Wolverton, 2007; as cited in Reichling & Kligman, 1961). This is an important way for decreasing side effects of corticosteroids. In addition, this alternate-day use can maintain significant anti-inflammatory effect over the 48- hour period between doses (Wolverton, 2007).

Topical corticosteroid therapy requires physician's close supervision to optimize benefits and minimize adverse effects. The follow-up visit is the most effective form of supervision (Wolverton, 2007).

For decreasing the side effects, choosing the least potent topical corticosteroids necessary to achieve an appropriate response and then tapering the potency as quickly as possible is a key point (Wolverton, 2007).

If longer duration is needed, corticosteroid should be gradually tapered to avoid rebound symptoms, and treatment should be resumed after a steroid-free period of at least one week. This schedule can be repeated chronically, until the condition resolves (Drake et al., 1996; Ference & Last, 2009).

For preventing tolerance and tachyphylaxis to topical corticosteroids, ultra-high-potency corticosteroids should not be used for more than 3 weeks continuously (Drake et al., 1996; Ference & Last, 2009).

Occlusion can increase corticosteroid penetration. A simple plastic dressing is able to increase corticosteroid penetration several folds. Thus occlusion should not be applied to the face or intertriginous areas (Drake et al., 1996; Ference & Last, 2009).

Adjunctive therapy with other immunosuppressive drugs and pulse therapy are another ways for decreasing the side effects of corticosteroids. These advances in corticosteroid therapy occurred during the 1970s and 1980s (Wolverton, 2007). Topical immunomodulator calcineurin inhibitors such as tacrolimus and pimecrolimus don't produce atrophy or other side effects of corticosteroids (Coskun et al., 2005; Gawkrödger et al., 2010), so they can be very useful for patients with vitiligo involvement in sensitive areas of the skin such as eyelids, and also they should be considered in other skin disorder currently treated with topical corticosteroids for prolonged periods (Coskun et al., 2005).

Combination therapy with corticosteroid and calcipotriol, not only produces faster onset of repigmentation in vitiligo patients, but also decreases the incidence rate of side effects (Kumaran, 2006).

Treatment with combination of corticosteroids and retinoids can prevent corticosteroid-induced atrophy (Lepe, 2003).

As a hypothesis, phenitoin by stimulating collagen production and inhibiting its breakdown can prevent corticosteroid-induced skin atrophy (Namazi, 2005).

16. Conclusion

The exact etiology and pathogenesis of vitiligo are unclear; thus, discovery of biological pathways of vitiligo pathogenesis will result in novel therapeutic and prophylactic targets in treatment of this disease (Bagherani et al., 2011).

Several factors have effects on the choice of treatment for vitiligo. The best treatment chosen should be individualized for each patient based on the extent, distribution and the rate of progression of the lesions (Mahmoud et al., 2008). Topical corticosteroids and narrowband

UVB monotherapy were the most effective and safest forms of treatment for localized and generalized vitiligo, respectively (Whiton et al., 2008).

Author details

Nooshin Bagherani

Dr. Nooshin Bagherani's Office, Khoramshahr, Khuzestan province, Iran

17. References

- AlGhamdi, KM. (2009). A survey of vitiligo management among dermatologists in Saudi Arabia. *J Eur Acad Dermatol Venereol*, Vol. 23, N. 11, pp. 1282-1288.
- Alkhateeb, A., Fain, PR., Thody, A., Bennett, DC., & Spritz, RA. (2003). Epidemiology of vitiligo and associated autoimmune diseases in Caucasian probands and their families. *Pigment Cell Res*, Vol. 16, pp. 208-214.
- Anbar, TS., Westerhof, W., Abdel-Rahman, AT., & El-Khayyat, MA. (2006). Evaluation of the effects of NB-UVB in both segmental and non-segmental vitiligo affecting different body sites. *Photodermatol, Photoimmunol & Photo med*, Vol. 22, N. 3, pp. 157-163.
- Antoniou, C., & Katsambas, A. (1992). Guildelines for the treatment of vitiligo. *Drug*, Vol. 43, pp. 490-498.
- Assmann, T., Homey, B., & Ruzicka, T. (2000). Applications of tacrolimus for treatment of skin disorders. *Immunopharmacol*, Vol. 47, pp. 203-213.
- (Bagherani, N.(2012a) The newest Hypothesis about vitiligo. Most of the suggested pathogeneses of vitiligo can be attributed to lack of one factor: Zinc- α 2-glycoprotein. *Current Medicinal Chemistry, 4th international conference on drug discovery & therapy*, Dubi, Feb, 2012
- Bagherani, N.(2012b) The newest hypothesis about vitiligo. Most of the suggested pathogeneses about vitiligo can be attributed to lack of one factor: Zinc- α 2-glycoprotein. *ISRN J. www.isrn.com/journals/dermatology/aip/405268*
- Bagherani, N. (2011). Two Important Discoveries. *International drug discovery science and technology, china*, Nov, 2011
- Bagherani, N., Yaghoobi, R., & Omidian, M. (2011). Hypothesis: Zinc can be effective in treatment of vitiligo. *Indian J Dermatol*, Vol. 56, N.5, pp. 480-484.
- Barman, KD., Khaitan, BK., & Verma, KK. (2004). A comparative study of punch grafting followed by topical corticosteroid versus punch grafting followed by PUVA therapy in stable vitiligo. *Dermatol Surg*, Vol. 30, N. 1, pp. 49-53.
- Barnetson, RS., & White, AD. (1992). The use of corticosteroids in dermatological practice. *Med J Aust*, Vol. 156, N. 6, pp. 428-431.
- Beato, M. (1989). Gene regulation by steroid hormones. *Cell*, Vol. 56, pp. 335-344.
- Beato, M., Chavez, S., & Truss, M. (1996). Transcriptional regulation by steroid hormones. *Steroids*, Vol. 61, pp. 240-251.
- Beato, M., & Klug, J. (2000). Steroid hormone receptors: An update. *Hum Reprod Update*, Vol. 6, pp. 225-236.

- Berti, S., Buggiani, G., & Lotti, T. (2009). Use of tacrolimus ointment in vitiligo alone or in combination therapy. *Skin Therapy Lett*, Vol. 14, N. 4, pp.5-7.
- Birlea, SA., Fain, PR., & Spritz RA (2008). A Romanian population isolate with high frequency of vitiligo and associated autoimmune disease. *Arch Dermatol*, Vol. 144, pp.310-316.
- Bleehen, SS. (1976). The treatment of vitiligo with topical corticosteroids. Light and electronmicroscopic studies. *Br J Dermatol*, Vol. 94, N. 12 (Suppl), pp. 43-50.
- Boehncke, WH., Ochsendorf, F., Paeslack, I., Kaufmann, R., & Zollner, TM. (2002). Decorative cosmetics improve the quality of life in patients with disfiguring skin diseases. *Eur J Dermatol*, Vol. 12, N.6, pp. 577-580.
- Boisy, RE. Spritz, RA. (2009). Frontiers and controversies in the pathobiology of vitiligo: separating the wheat from chaff. *Exp Dermatol*, Vol. 18, pp. 583-585.
- Bolognia, JL., Jorizzo, JL., & Rapini, R. (2008). (Ed.2). (2008). *Dermatology*. Philadelphia, Mosby Elsevier. USA.
- Burns, T., Breathnach, S., Cox, N., & Griffiths C. (Ed. 7). (2004). *Rook's Textbook of Dermatology*. Oxford Blackwell Science. UK.
- Camacho, F., & Mazuecos, J. (2002). Oral and topical L-phenylalanine, clobetasol propionate, and UVA/sunlight- a new study for the treatment of vitiligo. *J Drugs Dermatol*, Vol. 1, N. 2, pp. 127-131.
- Choi, CW., Chang, SE., Bak, H., Choi, JH., Park, HS., Huh, CH., Kim, CW., Kim, SE., Mun, SK., Kim, BJ., & Kim, MN. (2008). Topical immunomodulators are effective for treatment of vitiligo. *J Dermatol*, Vol.35, N. 8, pp. 503-507.
- Civitelli, R., Kim, YS., Gunsten, SL., Fujimori, A., Huskey, M., Avioli, LV., & Hruska, KA. (1990). Nongenomic activation of the calcium message system vitamin D metabolites in osteoblast-like cells. *Endocrinology*, Vol. 127, N., pp. 2253-2262.
- Clayton, R. (1977). A double-blind trial of 0.05% clobetasol propionate in treatment of vitiligo. *Br J Dermatol*, Vol.96, pp.71-73.
- Cockayne, SE., Messenger, AG., & Gawkrödger DJ. (2002). Vitiligo treated with topical corticosteroid: Children with head and neck involvement respond well. *J Am Acad Dermatol*, Vol. 46, N.6, pp. 964-965.
- Coskun, B., Saral, Y., & Turgut, D. (2005). Topical 0.05% clobetasol propionate versus 1% pimecrolimus ointment in vitiligo. *Eur J Dermatol*, Vol. 15, N. 2, pp.88-91.
- Daneshpazhooh, M., Mostofizadeh, GM., Behjati, J., Akhyani, M., & Mahmoud Robati R. (2006). Anti-thyroid peroxidase antibody and vitiligo: a controlled study. *BMC Dermatol*, Vol.6, N. 3.
- de Boland, AR., & Norman, AW. (1990). Influx of extracellular calcium mediates 1,25-dihydroxyvitamin D₃-dependent transcalcitachia (the rapid stimulation of duodenal Ca²⁺ transport). *Endocrinol*, Vol. 127, pp. 2475-2480.
- Dell'Anna, ML., Mastrofrancesco, A., Sala, R., Venturini, M., Ottaviani, M., Vidolin, AP., Leone, G., Calzavara, PG., Westerhof, W., & Picardo, M. (2007). Antioxidants and narrow band-UVB in the treatment of vitiligo: a double-blind placebo controlled trial. *Clin Exp Dermatol*, Vol.32, N.6, pp.631-636.
- Dogra, S., & Bhushan, K. (2005). Repigmentation in vitiligo universalis: role of melanocyte density, disease duration, and melanocyte reservoir. *Dermatology Online Journal*, Vol. 11, N.3, pp.30.
- Drake, LA., Dinehart, SM., Farmer, ER., Goltz, RW., Graham, GF., Hordinsky, MK., Lewis, CW., Pariser, DM., Skouge, JW., Turner, ML., Webster, SB., Whitaker, DC., Lowery, BJ.,

- Nordlund, JJ., Grimes, PE., Halder, RM., & Minus HR. (1996). Guidelines of care for vitiligo. *J Am Acad Dermatol*, Vol. 35, N., pp. 620-626.
- Du Vivier, A. Tachyphylaxis to topically applied steroids. *Arch Dermatol*, Vol.112, N. 9, pp.1245-1248.
- Elder, DE., Elenitsas, R., Johnson, BL JR., Murphy, GF., & Xu, X.(2009).(Ed. 10) *Lever's Histopathology of the skin*, Lippincott Williams & Wilkins, New York.
- Eleftheriadou, V., Whitton, ME., Gawkrödger, DJ., Batchelor, J., Corne, J., Lamb, B., Ersser, S., Ravenscroft, J., & Thomas, KS. (2011). Future research into treatment of vitiligo: where should our priorities lie? Results of the vitiligo priority setting partnership. *British Journal of Dermatology*, Vol. 164, pp. 530-536.
- El Mofty, M., Mostafa, W., Esmat, S., Youssef, R., Azzam, O., Hunter, N., El Hanafi, G., & Fawzi, M. (2006). Narrow band ultraviolet B 311 nm in the treatment of vitiligo: two right-left comparison studies. *Photodermatol Photoimmunol & Photomed*. Vol. 22, N. 1, pp.6-11
- Ermis, O., Alpsöy, E., Cetin, L., & Yilmaz, E. (2001). Is the efficacy of psoralens plus ultraviolet A therapy for vitiligo enhanced by concurrent topical calcipotriol? A placebo-controlled double-blind study. *Br J Dermatol*, Vol.145, pp. 472-475.
- Evans RM. (1988). The steroid and thyroid hormone receptor superfamily. *Science*, Vol. 240, pp. 889-895.
- Falabella, R., Arrunategui, A., Barona, MI., & Alzate, A. (1995). The minigrafting test for vitiligo: detection of stable lesions for melanocyte transplantation. *J Am Acad Dermatol*, Vol. 32, pp.228-232.
- Falkenstein, E., Tillmann, HC., Feuring, M., & Wehling, M.(2000) Multiple actions of steroid hormones- A focus on rapid, nongenomic effects. *Pharmacol Rev*, Vol. 52, N.4, pp.513-556.
- Ference, JD., & Last, AR. (2009). Choosing topical corticosteroids. *American Family Physician*, Vol. 79, N. 2, pp. 135-140.
- Gauthier, Y., Cario, AM., & Taieb, A. (2003). A critical appraisal of vitiligo etiologic theories. Is melanocyte loss a melanocytorrhagy? *Pigment Cell Res*, Vol. 16, N. 4, pp. 322-332.
- Gawkrödger, DJ., Ormerod, AD., Shaw, L., Mauri-Sole, I., Whitton, ME., Watts, MJ., Anstey, AV., Ingham, J., & Young, K. (2010). Vitiligo: concise evidence based guidelines on diagnosis and management. *Postgrad Med J*, Vol.86, N. 1018, pp. 466-471.
- Geraldez, CB., & Gutierrez, GT. (1987). A clinical trial of clobetasol propionate in Filipino vitiligo patients. *Clin Ther*, Vol. 9, pp. 474-482.
- Giannotti B. (1988). Current treatment guidelines for topical corticosteroids. *Drugs*, Vol. 36, N. 5 (Suppl), pp. 9-14.
- Giannotti, B., & Pimpinelli, N. (1992). Topical corticosteroids. Which drug and when? *Drugs*, Vol. 44, N. 1, pp. 65-71.
- Hamzavi, IH., Jain, H., McLean, D., Shpiro, J., Zeng, H., & Lui, H. (2004). Parametric modeling of narrowband UV-B phototherapy for vitiligo using a novel quantitative tool. *Arch Dermatol*, vol. 140, pp.677-683.
- Hamzavi, IH., Lim, HW., & Syed, ZU. (2012). Ultraviolet-based therapy for vitiligo: What's new? *Indian J Dermatol Venereol Leprol*, Vol. 78, N. 1, pp. 42-48.
- Hann, SK., Kim, HI., Im, S., Park, YK., Cui, J., & Bystryrn, JC. (1993). The change of melanocyte cytotoxicity after systemic steroid treatment in vitiligo patients. *J Dermatol Sci*, Vol. 6, N. 3, pp. 201-205.

- Harper, J. (1988). Topical corticosteroids for skin disorders in infants and children. *Drugs*, Vol. 36, N. 5 (suppl), pp. 34-37.
- Hartmann, A., Brocker, EB., & Becker, JC. (2004). Hypopigmentary skin disorders: current treatment options and future directions. *Drug*, Vol. 64, pp. 89-107.
- Hatchome, N., Kato, T., & Tagamit, H. (1990). Therapeutic success of epidermal grafting in generalized vitiligo is limited by the Koebner phenomenon. *J Am Acad Dermatol*, Vol. 22, pp.87-91.
- Helmy, M I., Gayyar, EIMA., Hawas, S., & Eissa, EA.(2004). Role of oxidative stress in the pathogenesis of vitiligo. *J Pan-Arab League Dermatologist*, Vol: 15, pp. 97-105.
- Hench, PS., Kendall, ES., Slocumb, CH., & Polley, HF. (1950). Effects of cortisone acetate and pituitary ACTH on rheumatoid arthritis, rheumatic fever, and certain other conditions; study in clinical physiology. *Arch Intern Med*, Vol.85, N.4, pp. 545-556.
- Hengge, UR., Ruzicka, T., Schwartz, RA., & Cork, MJ. (2006). Adverse effects of topical glucocorticosteroids. *J Am Acad Dermatol*, Vol.51, N.1, pp.1-15.
- Hossani-Madani, AR., & Halder, RM. (2010). Topical treatment and combination approaches for vitiligo: a new insights, new developments. *G Ital Dermatol Venereol*, Vol. 145, N.1, pp. 57-78.
- Howitz, J., Brodthagen, H., Schwartz, M., & Thomsen, K. (1977).Prevalence of vitiligo. *Arch Dermatol*, Vol. 113, pp. 47-52.
- Howitz, J., Brodthagen, H., Schwartz, M., & Thomsen, K. (1977). Prevalence of vitiligo. *Archives Dermatology?*, Vol. 113, pp. 47-52.
- Ichimiya, M. (1999). Immunohistochemical study of ACTH and alpha-MSH in vitiligo patients successfully treated with a sex steroid-thyroid hormone mixture. *J Dermatol*, Vol. 26, N. 8, pp. 502-506.
- Imamura, S., & Tagami, H. (1976). Treatment of vitiligo with oral corticosteroids. *Dermatologica*, Vol. 153, N. 3, pp. 179-185.
- James, WD., Berger, TG., & Elston DM. (Ed 10). (2006). *Andrews disease of the skin. Clinical Dermatology*. Philadelphia: Saunders Elsevier, USA.
- Jenis, LG., Lian, JB., Stein, GS., Baran, DT. (1993). 1α , 25-dihydroxy vitamin D₃-induced changes in intracellular pH in osteoblast-like cells modulate gene expression. *J Cell Biochem*, Vol. 53, pp. 234-239.
- Jin, Y., Riccardi, SL., Gowan, K., Fain, PR., & Spritz, RA. (2010). Fine-mapping of vitiligo susceptibility loci on chromosomes 7 and 9 and interactions with NLPR1 (NALP1). *J Invest Dermatol*, Vol. 130, pp.774-783.
- Kakourou, T. (2009). Vitiligo in children. *World J Pediatr*, Vol. 5, N. 4, pp. 265-268.
- Kandil, E. (1974). Treatment of vitiligo with 0.1 per cent betamethasone 17-valerate in isopropyl alcohol- a double-blind trial. *Br J Dermatol*, Vol. 91, pp. 257-460.
- Katayama, I., Ashida, M., Maeda, A., Eishi, K., Murota, H., & Bae, SJ. (2003). Open trial of topical tacalcitol [1α 24(OH)2D₃] and solar irradiation for vitiligo vulgaris: upregulation of c-Kit mRNA by cultured melanocytes. *Eur J Dermatol*, Vol. 13, N. 4, pp. 372-376.
- Kim, SM., Lee, HS., & Hann, SK. (1999). The efficacy of low-dose oral corticosteroids in the treatment of vitigo patients. *Int J Dermatol*, Vol. 38, N. 7, pp. 546-550.
- Koranue, RV. , & Sachdeva, KG. (1988). Vitiligo. *International Journal of Dermatology*, Vol. 27, pp. 676-681.

- Kostovic, K., Nola, I., Bucan, Z., & Situm, M. (2003). Treatment of vitiligo: current methods and new approaches. *Acta Dermatovenereol Croat*, Vol. 11, pp. 163-17.
- Kovacs, SO., & Missouri, SF. (1998). Vitiligo. *J Am Acad Dermatol*, Vol. 38, pp. 647-666.
- Krüger, Ch., Smythe, JW., Spencer, JD., Hasse, S., Panske, A., Chiuchiarelli, G., & Schallreuter, KU. (2011). Significant immediate and long- term improvement in quality of life and disease coping in patients with vitiligo after group climatotherapy at Dead sea. *Acta Derm Venereol*, Vol.91, pp. 152-159.
- Kumaran, MS., Kaur, I., & Kumar, B. (2006). Effect of topical calcipotriol, betamethasone dipropionate and their combination in the treatment of localized vitiligo. *J Eur Acad Dermatol Venereol*, Vol. 20, N. 3, pp. 269-273.
- Kumari, J. (1984). Vitiligo treated with topical clobetasol propionate. *Arch Dermatol*, Vol. 120, pp.631-635.
- Kwinter, J., Pelletier, J., Khambalia, A., & Pope, E. (2007). High-potency steroid use in children with vitiligo: a retrospective study. *J Am Acad Dermatol*, Vol. 56, N. 2, pp. 236-241.
- Kwok, YKC., Anstey, AV., & Hawk, JLM. (2002). Psoralen photochemotherapy (PUVA) is only moderately effective in widespread vitiligo: a 10-year retrospective study. *Clin Exp Dermatol*, Vol.27, N. 2, pp.104-110.
- Lebwohl, MG., Heymann, WR., Berth-Jones, J., & Coulson, I. (Ed. 2). (2006). *Treatment of skin disease. Comprehensive therapeutic strategies*. Philadelphia Mosby Elsevier, USA.
- Lebwohl, M. Quijije, J. Gilliard, J. Rollin, T., & Watts, O. (2003). Topical calcitriol is degraded by ultraviolet light. *J Invest Dermatol*, Vol. 121, N. 3, pp.594-595.
- Lee, DY., Kim, CR., & Lee, JH. (2010). Recent onset vitiligo on acral areas treated with phototherapy: need of early treatment. *Photodermatol Photoimmunol Photomed*, Vol. 26, N. 5, pp. 266-268.
- Lee, Y., Seo, YJ., Lee, JH., & Park, JK. (2007). High-dose prednisolone and psoralen ultraviolet A combination therapy in 36 patients with vitiligo. *Clin Exp Dermatol*, Vol. 32, N. 5, pp. 499-501.
- Lepe, V., Moncada, B., Castanedo-Cazares, JP., Torres-Alvarez, MB., Ortiz, CA., & Torres-Rubalcava, AB. (2003). A double-blind randomized trial of 0.1% tacrolimus vs 0.05% clobetasol for the treatment of childhood vitiligo. *Arch Dermatol*, Vol. 139, No.5, pp. 581-585.
- Le Poole, IC., Das, PK., Van den Wijngaard, RM., Bos, JD., & Westerhof, W. (1993a). Review of the etiopathomechanism of vitiligo: a convergence theory. *Exp Dermatol*, Vol. 2, pp.145-153.
- Le Poole, IC., Van den Wijngaard, RM., Westerhof, W., Dutrieux, RP., & Das, PK. (1993b). Presence or absence of melanocytes in vitiligo : an immunohistochemical investigation. *J Invest Dermatol*, Vol.100, pp.816-822.
- Lester, RS. Corticosteroids. (1989). *Clin Dermatol*, vol. 7, N. 3, pp. 80-97.
- Long, CC., & Finaly, AY. (1991). The finger-tip unit- a new practical measure. *Clin Exp Dermatol*, Vol. 16, N. 6, pp. 444-447.
- Lotti, T., Buggiani, G., Troiano, M., Assad, GB., Delescluse, J., De Giorgi, V., & Hercogova, J. (2008a). Targeted and combination treatments for vitiligo. Comparative evaluation of different current modalities in 458 subjects. *Dermatol Ther*, Vol.21, N. 1(Suppl), pp. s20-26.
- Lotti, T., Gori, A., Zanieri, F., Colucci, R., Moretti, S. Vitiligo: new and emerging treatment. *Dermatol Ther*, vol.21, pp.110-117.

- Mahmoud, BH., Hexsel, CL. , & Hamzavi, IH. (2008). An update on new and emerging options for the treatment of vitiligo. *Skin Therapy Lett*, Vol. 13, N.2, pp. 1-6.
- Majid, I., Masood, Q., Hassan, I., Khan, D., & Chisti, M. (2009). Childhood vitiligo: Reponse to methylprednisolone oral minipulse therapy and topical fluticasone combination. *Indian J Dermatol*, Vol. 54, N. 2, pp. 124-127.
- Majid, I. (2010). Topical placental extract: Does it increase the efficacy of narrowband UVB therapy in vitiligo? *Indian J Dermatol Venereol Leprol*, Vol. 76, N. 3, pp. 254-258.
- Mandelcorn-Monson, RL., Shear, NH., Yau, E. Sambhara, S., Barber, BH., Spaner, D., & DeBenedette, MA(2003). Cytotoxic T lymphocyte reactivity to gp100, melan A/MART I, and tyrosinase, in HLA-A2-positive vitiligo patients. *J Invest Dermatol*, Vol. 121, pp. 550-556.
- Masuria, BL., Batra, A., Kothiwala, RK., & Khuller, R. (1999). Topical mometasone furoate for the treatment of childhood vitiligo. *Indian J Dermatol Venereol Leprol*, Vol.65, N.5, pp.219-221.
- Millington, GW., & Levell, NJ. (2007). Vitiligo. The historical curse of depigmentation. *Int J Dermatol*, Vol. 46, N.9, pp. 990-995.
- Moellmann, G., Klein-Angerer, S., & Scollay, DA. (1982). Extracellular granular material and degeneration of keratinocytes in the normally pigmented epidermis of patients with vitiligo. *J Invest Dermatol*, Vol. 79, pp. 321-330.
- Morelli, S., de Boland, AR. & Boland, RL. (1993). Generation of inositol phosphates, diacylglycerol and calcium fluxes in myoblasts treated with 1, 25-dihydroxyvitamine D₃. *Biochem J*, Vol. 289, pp. 675-679.
- Moretti, S., Spallanzani, A., Amato, L. ,Hautmann, G., Gallerani, I., Fabianini, M., & Fabbri , P. (2002). New insights into the pathogenesis of vitiligo: imbalance of epidermal cytokines at sites of lesions. *Pigment Cell Res*, Vol.15, pp. 87-92.
- Morley, P., Whitfield, JF., Vanderhyden, BC., Tsang, BK., & Schwartz, JL. (1992). A new, nongenomic estrogen action: The rapid release of intracellular Ca²⁺. *Endocrinol*, Vol. 131, pp. 1305-1312.
- Mulekar, SV. (2006). Stable vitiligo treated by a combination of low-dose oral pulse betamethasone and autologous, noncultured melanocyte-keratinocyte cell transplantation. *Dermatol Surg*, Vol. 32, N. 4, pp. 536-541.
- Muto, M., Furumoto, H., Ohmura, A., & Asagami, C. (1995). Successful treatment pf vitilgo with a sex steroid-thyroid hormone mixture. *J dermatol*, Vol. 22, N. 10, pp. 770-772.
- Nagai, K., Ichimiya, M., Yokoyama, K., Hamamoto, Y., & Muto, M. (2000). Successful treatment of non-segmental vitiligo: systemic therapy with sex hormone-thyroid powder mixture. *Horm Res*, Vol. 54, N. 5-6, pp. 316-317.
- Namazi, MR. (2005). Phenytoin as a novel anti-vitiligo weapon. *J Autimmune Dis*, Vol.2, N.11.
- Nazer, HEI., Emam, H., Abdel Hamid, MF., Aly, D., Shehata, H., Hussein, M., Raafat, M., Salama, I., Abdel Ghaffar, N., Fathy, A., Kotb, A., & Sadek, M. (2011). The effectiveness of narrow-band phototherapy, corticosteroid, and methotrexate on clinical picture and serum level of soluble interleukin-2 receptors among vitiligo patients. *Medical Research Journal*, Vol.10, N.1, pp.18-22.
- Nijsten, TEC., & Stern, RS. (2003). The increased risk of skin cancer is persistent after discontinuation of psoralen+ultraviolet A: a cohort study. *J Invest Dermatol*, Vol. 121, pp. 252-258.

- Njoo, MD., Das, PK., Bos, JD., & Weserhof, W. (1999). Association of the Köbner phenomenon with disease activity and therapeutic responsiveness in vitiligo vulgaris. *Arch Dermatol*, Vol. 135, pp. 407-413.
- Njoo, MD., Spuls, PI., Bos, JD., Westerhof, W., & Bossuyt, PM. (1998). Nonsurgical repigmentation therapies in vitiligo. *Arch Dermatol*, Vol. 134, pp. 1532-1540.
- Njoo, MD., Weserhof, W., Bos, JD., & Bossuyt, PM. (1998). A systemic review of autologous transplantation methods in vitiligo. *Arch Dermatol*, Vol. 134, pp. 1543-1549.
- Njoo, MD., & Westerhof, W. (2001). Vitiligo. Pathogenesis and treatment. *Am J Clin Dermatol*. Pathogenesis and treatment, Vol. 2, N. 3, pp. 167-181.
- Nordlund, JJ. Lerner, AB. (1982). Vitiligo. It is important. *Arch Dermatol*, Vol. 118, pp. 5-8.
- Ogg, GS., Dunbat, PR., Romero, P., Chen, JL., & Cerundulo, V. (1998). High frequency of skin homing melanocyte-specific cytotoxic T lymphocytes in autoimmune vitiligo. *J Exp Med*, Vol. 188, pp. 1203-1208.
- Ongenaes, K., Van Geel, N., De Schepper, S., Vander Haeghen, Y., & Naeyaert, JM. (2004). Management of vitiligo patients and attitude of dermatologists toward vitiligo. *Eur J Dermatol*, Vol. 14, N. 3, pp. 177-181.
- Oslen, EA. (1991). A double-blind controlled comparison of generic and trade-name topical steroids using the vasoconstriction assay. *Arch Dermatol*, Vol. 127, N. 2, pp. 197-201.
- Pariser, DM. (1991). Topical steroids: a guide for use in the elderly patient. *Geriatrics*, Vol. 46, N. 10, pp. 51-54, 57-60, 63.
- Parsad, D., Kanwar, AJ., & Kumar, B. (2006). Psoralen-ultraviolet A vs. narrow-band ultraviolet B phototherapy for the treatment of vitiligo. *J Eur Acad Dermatol Venereol*, Vol. 20, N. 2, pp. 175-177.
- Parsad, D., Pandhi, R., Dogra, S., & Kumar, B. (2004). Clinical study of repigmentation patterns with different treatment modalities and their correlation with speed and stability of repigmentation in 352 vitiliginous patches. *J Am Acad Dermatol*, Vol. 50, N. 1, pp. 63-67.
- Parsad, D., Pandhi, R., & Juneja, A. (2003). Effective of oral Ginkgo biloba in treating limited, slowly spreading vitiligo. *Clinic Exp Dermatol*, Vol. 28, pp. 285-287.
- Pasricha, JS. Khaitan, BK. (1993). Oral mini pulse therapy with betamethasone in vitiligo patients having extensive or fast-spreading disease. *Int J Dermatol*, Vol. 32, N. 10, pp. 753-757.
- Pasricha, JS., & Khera, V. (1994). Effect of prolonged treatment with levamisole on vitiligo with limited and slow-spreading disease. *Int J Dermatol*, Vol. 33, N. 8, pp. 584-587.
- Pichler, R., Sifetos, K., Badics, B., Gutenbrunner, S., Berg, J., & Auböck, J. (2009). Lymphocyte imbalance in vitiligo patients indicated by elevated CD4+/CD8+ T-cell ratio. *Wien Med Wochenschr*, Vol. 159, pp. 337-341.
- Radakovic, FS., Furnsinn, FA., Honigsmann, H., & Tanew, A. (2001). Oral dexamethasone pulse treatment for vitiligo. *J Am Acad Dermatol*, Vol. 44, N. 5, pp. 814-817.
- Radmanesh, M., & Saedi, K. (2006). The efficacy of combined PUVA and low-dose azathioprine for early and enhanced repigmentation in vitiligo patients. *J Dermatol Treat*, Vol. 17, pp. 151-153.
- Rath, N., Kar, HK., & Sabhnani, S. (2008). An open labeled, comparative clinical study on efficacy and tolerability of oral minipulse of steroid (OMP) alone, OMP with PUVA and

- broad/narrow band UVB phototherapy in progressive vitiligo. *Indian J Dermatol Venereol*, Vol. 74, N.4, pp.357-360.
- Roeder, A., Schaller, M., Schäfer-Korting, M., & Korting, HS. (2005). Safty and efficacy of fluticasone propionate in the topical treatment of skin diseases. *Skin Pharmacol Physiol*, Vol. 18, N. 1, pp.3-11.
- Sanclemente, G., Garcia, JJ., Zuleta, JJ., Diehl, C., Correa, C. , & Falabella, R. (2008). A double-blind, randomized trial of 0.05% betamethasone vs. topical catalase/dismutase superoxide in vitiligo. *J Eur Acad Dermatol Venereol*, Vol.22, N. 11, pp. 1359-1364.
- Sassi, F., Cazzaniga, S., Tessari, G., Chatenoud, L., Reseghetti, A., Marchesi, L., Girolomoni, G., & Naldi, L. (2008). Randomized controlled trial comparing the effectiveness of 308-nm excimer laser alone or in combination with topical hydrocortisone 17-butyrate cream in treatment of vitiligo of the face and neck. *Br J Dermatol*, Vol. 159, N. 5, pp. 1186-1191.
- Schallreuter, KU., Moore, J., Behrens-Williams, S., Panske, A., & Harari, M. (2002). Rapid initiation of repigmentation in vitiligo with Dead Sea climatotherapy in combination with pseudocatalase (PC-KUS). *Int J Dermatol*, Vol. 41, pp. 482-487.
- Sehgal, VN., & Srivastava G. (2007). Vitiligo: compendium of clinico-epidemiological features. *Indian J Dermatol Venereol Leprol*, Vol. 73, pp.149-156.
- Seiter, S., Ugurel, S., Pföhler, C., Tilgen, W., & Reinhold, U. (1999). Successful treatment of progressive vitiligo with high-dose intravenous methylprednisolone 'pulse' therapy. *Dermatol*, Vol. 199, N. 3, pp. 261-262.
- Seiter, S., Ugurel, S., Tilgen, W., & Reinhold, U. (2000). Use of high-dose methylprednisolone pulse therapy in patients with progressive and stable vitiligo. *Int J Dermatol*, Vol. 39, N. 8, pp. 624-627.
- Shameer, P. Prasad, PVS. Kaviarasan, PK.(2005). Serum zinc level in vitiligo: a case control study. *Indian Journal of Dermatology, venereology and leprology*, Vol. 71, pp.206-207.
- Silverberg, N., Lin, P., Travis, L., Farley-Li, J, Mancini, AJ., Wagner, AM., Chamlin, SL., & Paller, AS (2004). Tacrolimus ointment promotes repigmentation of vitiligo in children: a review of 57 cases. *J Am Acad Dermatol*, Vol.51, N. 5, pp.760-766.
- Sitek, JC., Loeb, M., & Ronnevig, JR. (2007). Narrowband UVB therapy for vitiligo: does the repigmentation last?*J Euir Acad Dermatol Venereol*, Vol.21, N. 7, pp.891-896.
- Spritz, RA. (2008). The genetics of generalized vitiligo. *Curr Dir Autoimmune*, Vol. 10, pp. 244-257.
- Sulzberger, MB., Witten, VH., & Yaffe, SN. (1951). Cortisone acetate administered orally in dermatologic therapy. *Arch Dermatol Syphilol*, Vol. 64, pp.573-578.
- Szczurko, O. Boon, HS. (2008). A systematic review of natural heath product treatment for vitiligo. *BMC Dermatol*, Vol.8, N.2.
- Szczurko, O. Shear, N. Taddio, A. Boon, H. (2011). Ginkgo biloba for the treatment of vitiligo vulgaris: an open label pilot clinical trial. *BMC Complementary Alternative Medicine*, Vol. 11, N. 21.
- Tadicherla, S., Ross, K., Shenefelt, PD., & Fenske, NA. (2009). Topical corticosteroids in dermatology. *J Drugs Dermatol*, Vol.8, N. 12, pp.1093-1105.
- Takei, M., Mishima, Y., & Uda H. (1984). Immunopathology of vitiligo vulgaris, Sutton's leukoderma and melanoma-associated vitiligo in relation to steroid effects. I. Curculating antibodies for cultured melanoma cells. *J Cut Pathol*, Vol. 11, N. 2, pp. 107-113.

- Russell, ST., & Tisdale MJ. (2005). The role of glucocorticoids in the induction of zinc- α 2-glycoprotein expression I adipose tissue in cancer cachexia. *British J Cancer*, Vol.92, pp.876-881.
- Tonsi, A. (2004). Vitiligo and its management update: a review. *Pak J Med Sci*, Vol. 20, pp. 242-247.
- Travis, LB., & Silverberg, NB. (2004). Calcipotriene and corticosteroid combination therapy for vitiligo. *Peddiatr Dermatol*, Vol. 21, N. 4, pp. 495-498.
- Tsuji, T., & Hamada, T.(1983). Topically administered fluorouracil in vitiligo. *Arch Dermatol*, Vol. 119, pp. 722-727.
- Uda, H., Takei, M., & Mishima, Y. (1984). Immunopathology of vitiligo vulgaris, Sutton's leukoderma and melanoma-associated vitiligo in relation to steroid effects. II. The IgG and C3 deposits in the skin. *J Cutan Pathol*, Vol. 11, N. 2, pp. 114-124.
- Van Geel, N., Vander Haeghen, Y., Ongenae, K., & Naeyaert, JM. (2004). A new digital image analysis system useful for surface assessment of vitiligo lesions in transplantation studies. *European Journal of Dermatology*? Vol. 14, N. 3, pp. 150-155.
- Vasistha, LK., & Singh, G. (1979). Vitiligo and intralesional steroids. *Indian J Med Res*, Vol. 69, pp. 308-311.
- Westerhof, W., Nieuweboer-Krobotova, L. Mulder, PGH., & Glazenburg EJ. (1999). Left-right comparison study of the combination of fluticasone propionate and UV-A vs either fluticasone propionate or UV-A alone for the long-term treatment of vitiligo. *Arch Dermatol*, Vol. 135, pp. 1061-1066.
- Whitton, ME., Ashcrt, DM., & González, U. (2008). Therapeutic intervention for vitiligo. *J Am Acad Dermatol*, Vol. 59, pp. 713-717.
- Whitton, M. Pinart, M. Batchelor, J....(2010). Interventions for vitiligo. *Cochrane Database Sys Rev*, 1, CD003263
- Wolff, K., Goldsmith, LA., Katz, SI., Gilchrest, BA., Paller, AS., & Leffell, DJ. (Ed. 7). (2007). *Fitzpatrick's Dermatology in General Medicine*, Mac Graw Hill, ISBN. 978-0-07-146690-5.USA.
- Wolverton, SE. (Ed. 2). (2007). *Comprehensive Dermatologic Drug Therapy*, Saunders Elsevier, ISBN-10:978-1-4160-2471-2.USA.
- Xunquan, L., Changgeng, S., Peiying, J., Huaiqu, W., Gan-yun, Y., & Yawalkar, S. (1990). Treatment of localized vitiligo with ulobetazol cream. *Int J Dermatol*, Vol. 29, pp. 295-297.
- Yaghoobi, R., Omidian, M., & Bagherani, N. (2011a). Comparison of therapeutic efficacy of topical corticosteroid and oral zinc sulfate-topical corticosteroid combination in the treatment of vitiligo patients: a clinical trial. *BMC Dermatology*, Vol. 11, N. 7.
- Yaghoobi, R., Omidian, M., & Bagherani, N. (2011b). Vitiligo: A review of the published work. *The Journal of Dermatology*, Vol.38, No. 5, pp. 419-431.
- Yones, SS., Palmer, RA., Garibaldinos, TM., Et al. (2007). Randomized double-blind trial of treatment of vitiligo: efficacy of psoralen- UVA therapy vs. narrowband- UVB therapy. *Arch Dermatol*, Vol. 143, N. 5, pp. 578-584.
- Yu, HS., Wu, ChSh., Yu, ChL., Kao, YH., & Chiou, MH. (2003). Helium-neon laser irradiation stimulates migration and proliferation in melanocytes and induces repigmentation in segmental-type vitiligo. *J Invest Dermatol*, Vol. 120, pp.56-64.
- Zhang, Z., Xu, SX., Zhang, FY., Yin, XY., Yang, S., Xiao, FL., Du, WH., Wang, JF., Lv, YM., Tang, HY., & Zhang XJ.(2009). The analysis of genetics and associated autoimmune disease in Chinese vitiligo population. *Arch Dermatol Res*, Vol. 301, pp. 167-173.