

We are IntechOpen, the world's leading publisher of Open Access books Built by scientists, for scientists

6,900

Open access books available

185,000

International authors and editors

200M

Downloads

Our authors are among the

154

Countries delivered to

TOP 1%

most cited scientists

12.2%

Contributors from top 500 universities



WEB OF SCIENCE™

Selection of our books indexed in the Book Citation Index
in Web of Science™ Core Collection (BKCI)

Interested in publishing with us?
Contact book.department@intechopen.com

Numbers displayed above are based on latest data collected.
For more information visit www.intechopen.com



Intracranial and Extracranial Infectious Pseudoaneurysms

Václav Procházka, Michaela Vávrová,
Tomáš Jonszta, Daniel Czerný,
Jan Krajča and Tomáš Hrbáč

Additional information is available at the end of the chapter

<http://dx.doi.org/10.5772/47405>

1. Introduction

Intracranial mycotic pseudoaneurysms are rare and generally lethal. The infectious pseudoaneurysms occur more frequently in the anterior circulation and may be multiple. Haemorrhage is rare but is associated with poor neurological outcome. The outcome in children is comparable, or slightly better, than in adults. Mortality reaches up to 80% in some studies. Cerebral mycotic or infectious aneurysms are a complication of infectious diseases (Cloud et al., 2003). Recently, infectious aneurysms occur more frequently in patients with a history of drug abuse (cocaine, heroine, pervitine, etc.), or in patients with Human Immunodeficiency Syndrome (HIV).

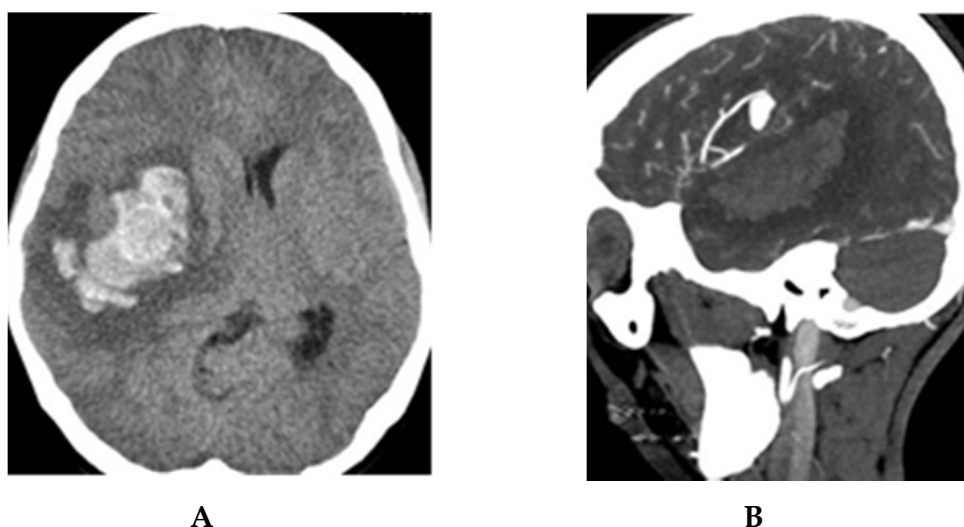
Presenting symptoms are typically headache, focal neurological deficit and/or haemorrhage. Headache is the most common presenting complaint in infectious and dissecting aneurysms.

Treatment of mycotic aneurysms is often difficult; they are managed conservatively with a prolonged course of antibiotics. In case of haemorrhage, surgical or endovascular treatment is used. Although surgery has been a traditional treatment of ruptured infectious pseudoaneurysms, it is associated with a higher rate of mortality (up to 80%). Endovascular treatment seems to be more safe. Parent artery occlusion (PAO) with coil embolisation or droplet of glue has become an attractive alternative treatment due to its low rate of morbidity and mortality. Vasospasm associated with haemorrhage is usually well tolerated in young patients.

2. Selective cases

2.1. Case No. 1

A 17-year-old girl, with the history of desoxyephedrine abuse for the last 2 years, was admitted into the hospital due to severe attack of headache, accompanied with a left-sided hemiparesis. The girl was anorectic, with vaginal discharge. Initial CT/CTA scan showed a large right hemisphere intracerebral haematoma (Fig. 1). The presence of pseudoaneurysm was suspected and confirmed by angiography, located in the right M3-MCA segment (Fig. 2). All vessels in the surrounding area were narrowed, with vessel wall irregularities. Due to the rebleeding risk and marked clinical deterioration at the time of the emergency angiography, parent artery occlusion of M3 MCA segmental branch was performed (Fig. 3).

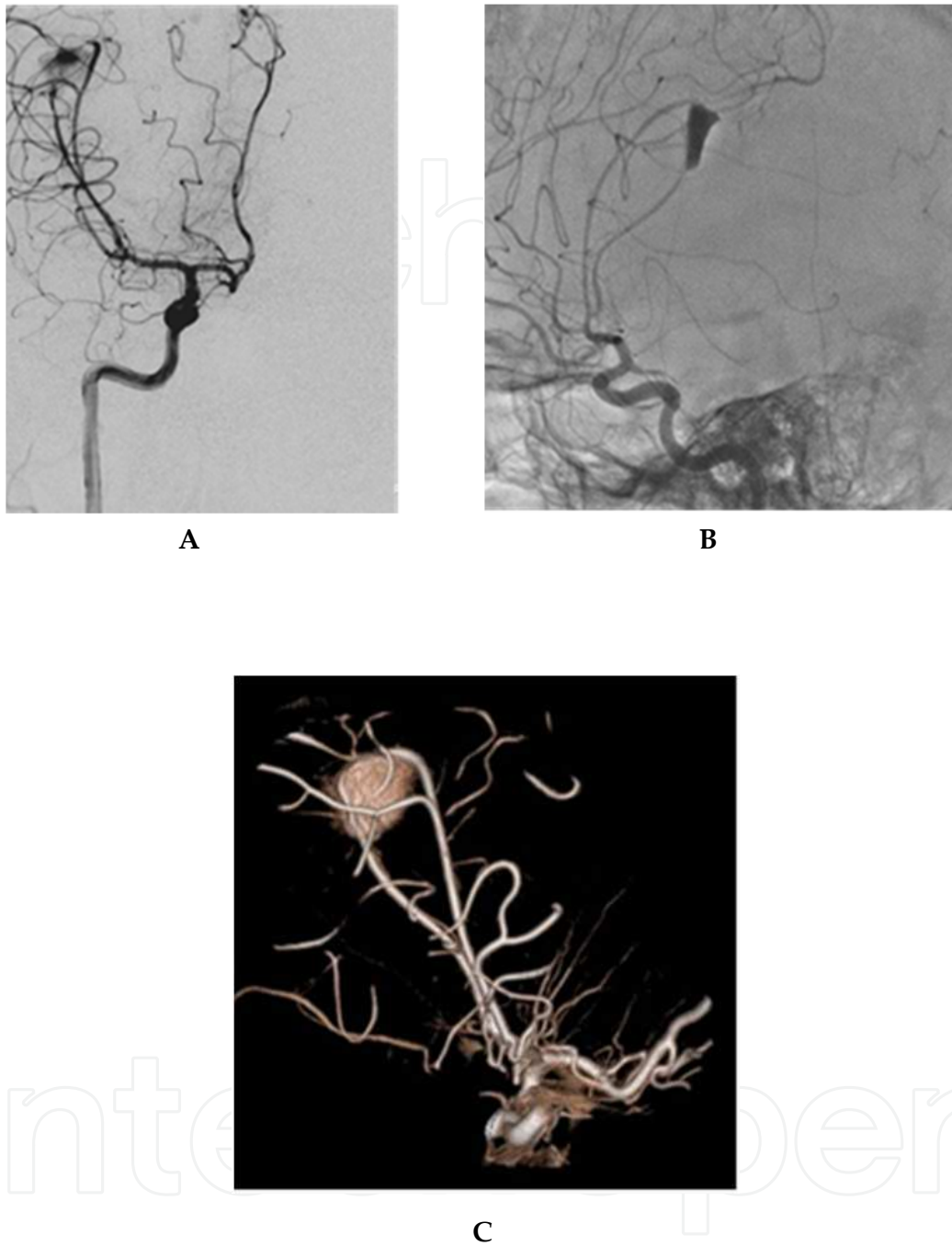


A, CT scan: large intracerebral haematoma in the right hemisphere with midline shift.
B, CTA sagittal view: large depo of contrast media in area of M3 segment of right MCA.

Figure 1. Initial CT/CTA scan

Immediately after the embolisation procedure, neurosurgeon evacuated the residual intracerebral haematoma and a decompressive craniectomy was completed (Fig. 4). The blood analysis confirmed latent infectious stage with a high white blood cell count of $17,9 \times 10^9/l$, CRP 146mg/l and a higher level of fibrinogen 5,252 g/l, with no subsequent shift in coagulation. HIV test was negative.

In addition to the endovascular procedure, intravenous administration of an antibiotic therapy (Claforan, Lek, SLO) was implemented. After a two-month period, the girl was doing quite well, Rankin scale-1, with small residual left-side hemiparesis and completely self-sufficient. All blood tests were normalized. Second control cerebral angiography confirmed a total occlusion of the pseudoaneurysm (Fig.5). At one-year follow-up, digital subtraction angiography was unremarkable, without pseudoaneurysm perfusion and vessel wall inflammation. Surrounding vessels were regular. The girl was back at school and doing well.

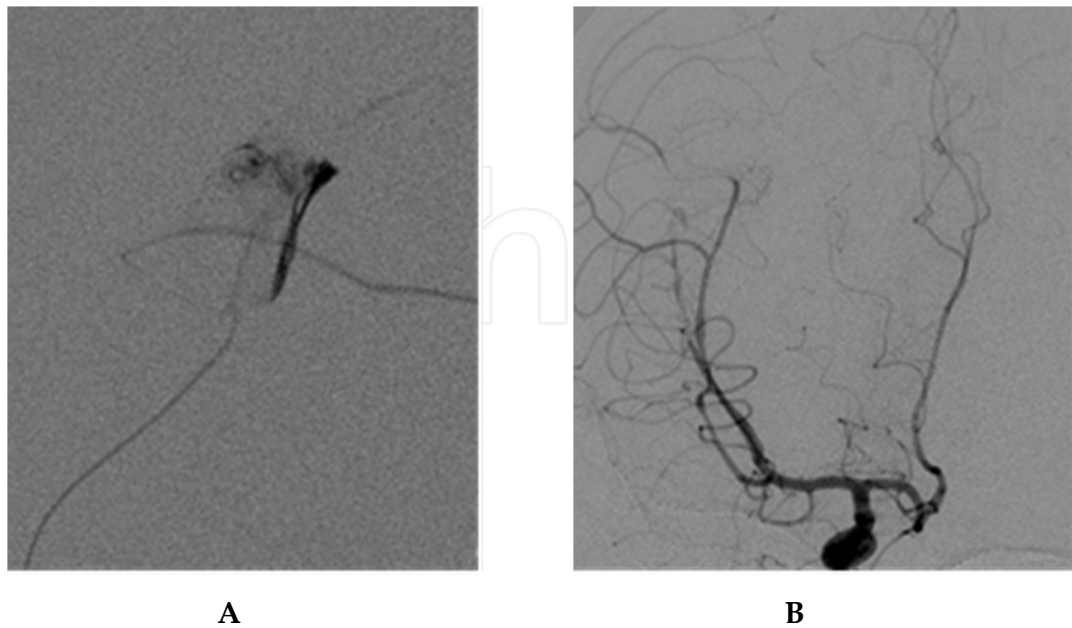


A, Angiography frontal view: M2-3 segment of MCA artery; we see a large pseudoaneurysm, the supplying vessel has irregular shape.

B, Lateral view angiogram with large pseudoaneurysm in the M2-3 segment of the right MCA artery.

C, 3D-XRA reconstruction of the right MCA artery pseudoaneurysm

Figure 2. Digital subtraction angiography with 3D-XRA reconstruction



A, Microcatheter in the parent artery. Control angiography confirmed the correct position of microcatheter just below the aneurysm.

B, Frontal view angiogram confirming pseudoaneurysm occlusion.

Figure 3. Embolisation procedure

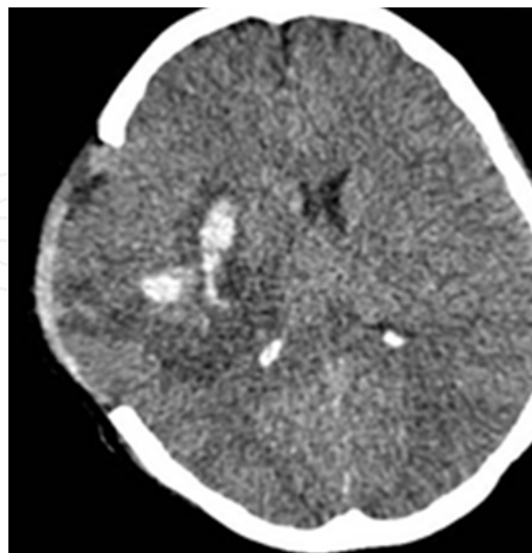
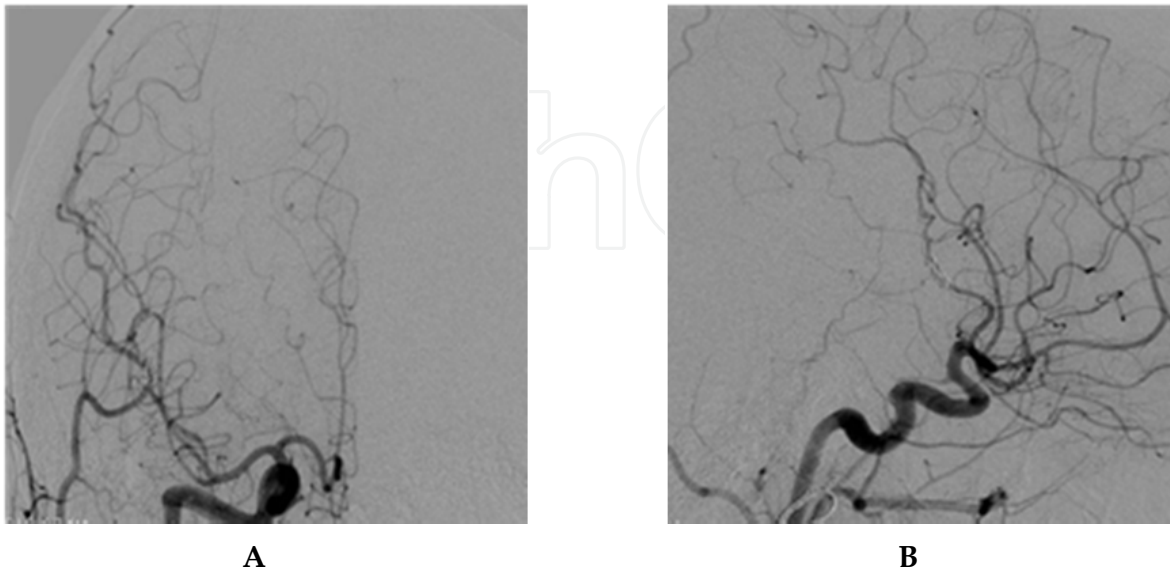


Figure 4. CT scan after neurosurgical removal of large intracerebral haematoma and decompressive craniectomy.

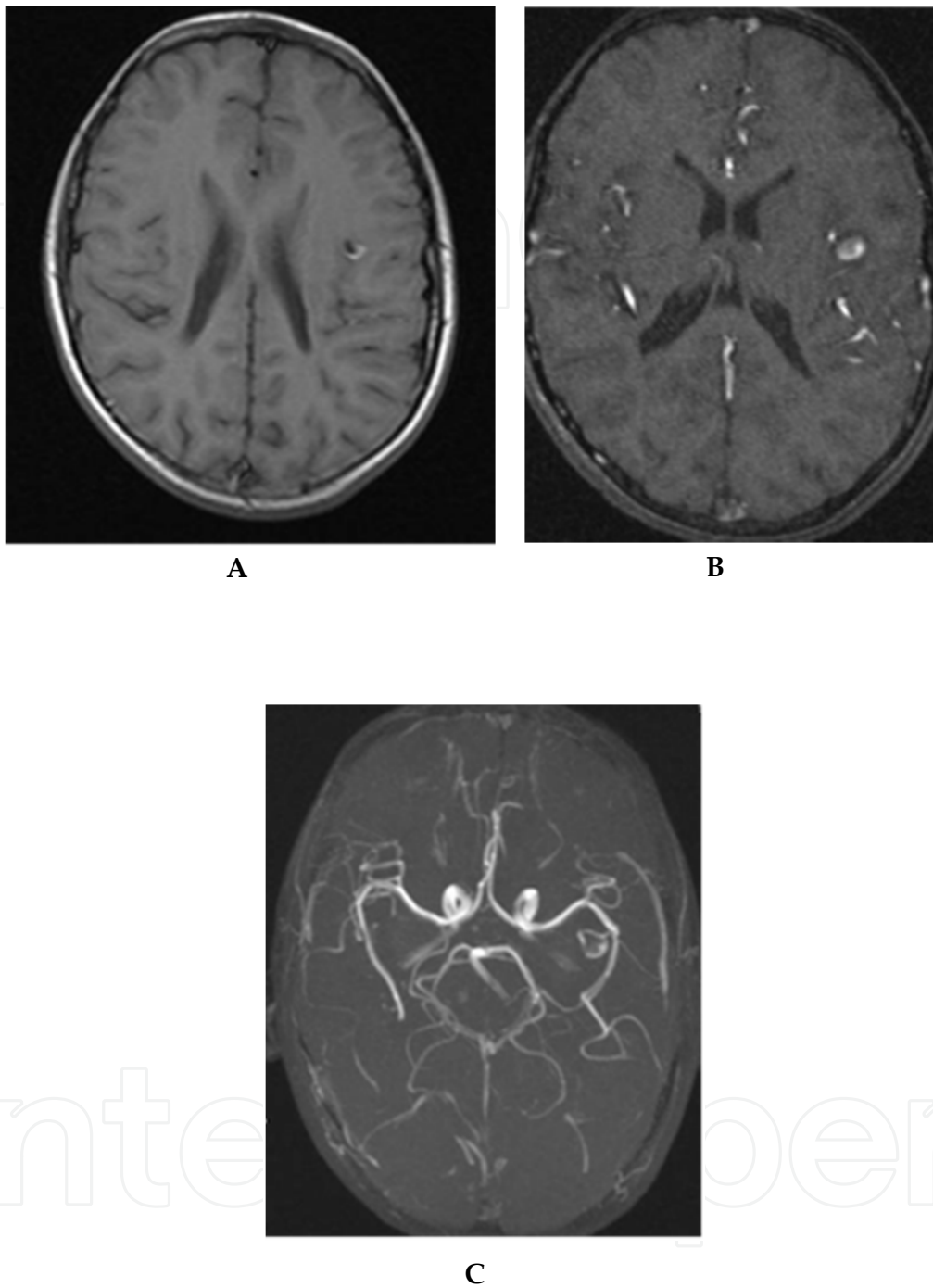


A, One-year follow-up angiography in the AP and lateral view **B**, showing no contrast filling of the pseudoaneurysm, normal shape of the vessels in the region of right MCA artery.

Figure 5. Follow-up angiogram

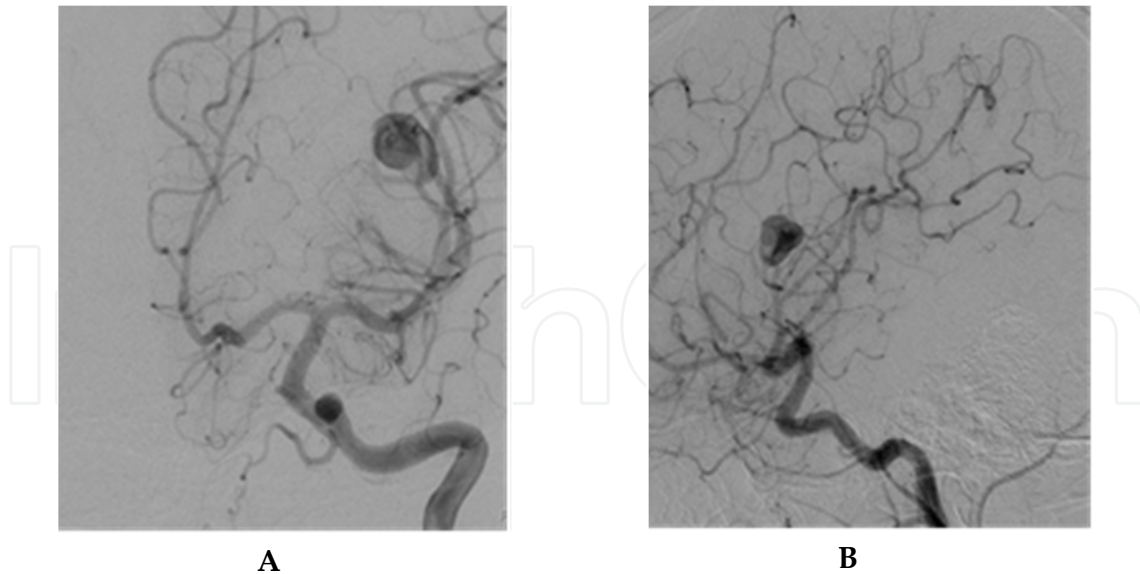
2.2. Case No. 2

A 12-year-old boy, with the history of premature delivery due to the placenta release, (30th week of gestation, having 1300g of body weight and 38cm of height at birth), spent 8 weeks in the incubator on ventilation support and phototherapy due to severe icterus. At 10 months of age, he was admitted into the hospital because of severe pneumonia and was put on assisted ventilation. He also suffered from severe focal seizures, headache, anxiety and impaired locomotion. However, due to the headache deterioration, MRI examination was performed and showed a small area of bleeding in the left opercular insular segment (Fig. 6) suggesting a presence of pseudoaneurysm in the left MCA branch. Peripheral blood counts and CRP levels were in physiological range. Subsequent angiography revealed a mycotic pseudoaneurysm in the left MCA opercular segment (Fig.7) with a straightened supplying artery, while the surrounding vessels were narrowed. Due to the high risk of pseudoaneurysm rupture, the endovascular PAO was directly performed, using coil embolisation. Immediately after the embolization, a weak bradylalia developed due to the Brockas' area MCA supplying territory perfusion, but the condition rapidly disappeared (Fig.8). Seizure attacks following embolisation stopped, and one-month follow-up MRI confirmed pseudoaneurysm thrombosis (Fig.9).



A,B MRI + MRA: Pd T2, MRA axial plane confirmed little area of haemorrhage in the left opercular area, deposits of methemoglobine
C, Based on MRA scan, suspicion of pseudoaneurysm in the region of M2,3 segment of the left MCA was confirmed.

Figure 6. MRI/MRA diagnostic scan for seizure and headache.



A,B, Large pseudoaneurysm in the area of the left MCA artery M3 segment in AP and lateral view, normal size and shape of surrounding vessels.

Figure 7. Digital subtraction angiography of the left intracranial circulation

Six-month follow-up MRA showing no contrast filling of the pseudoaneurysm, and regular shape of the surrounding vessels.

3. Extracranial infectious aneurysms

Pseudoaneurysm of the cervical portion of the internal carotid artery (ICA) is rare but potentially lethal complication of the deep neck infection. Liston was the first to describe pseudoaneurysm in this area in 1843 (Liston,1843). In 1933, Salinger and Pearlman (Salinger & Pearlman, 1933) published a set of 228 pseudoaneurysm cases. This has been the largest group of patients ever reported. Since the introduction of antibiotic treatment, less than 40 pseudoaneurysm cases have been described. In spite of significant advances in the treatment of ICA pseudoaneurysm, this condition is associated with a poor prognosis.

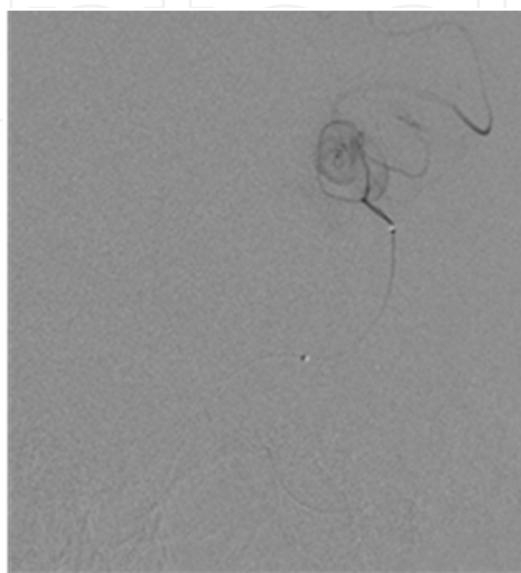
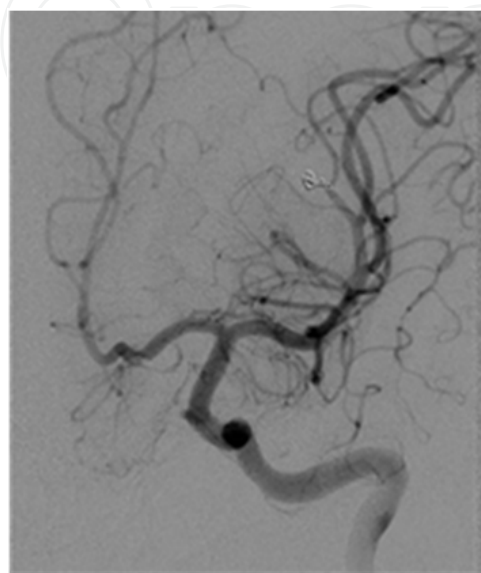
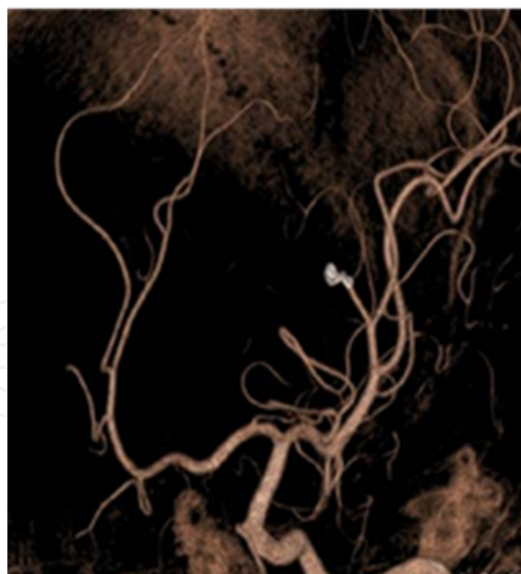
In addition to the systemic antibiotics treatment, surgical management may include ligation of the aneurysm with or without preserving the adjacent vessel wall and an end-to-end anastomosis of the carotid artery. An acceptable alternative treatment to surgery is a stentgraft or bare stent implantation with/without coil embolisation.

4. Selective cases

4.1. Case No. 3

A 56- year-old male, who suffered for one month from sore throat, dysphagia, and left neck stiffness. Parapharyngeal phlegmona was detected on both ultrasound and CT scan, explorative surgery was performed and the patient was put on antibiotics treatment. Ten days later, the patient returned with a painful bulge on his neck. A parapharyngeal abscess

was confirmed on CT scan, with subsequent surgical drainage. The infectious agent cultured from the specimen was *Staphylococcus* species. Five days later, a small fistula in the lower pole of the surgical scar evolved. Prompt follow-up CT scan revealed pseudoaneurysm at the level of the left carotid bifurcation, 18 mm in size (Fig. 10).

**A****B****C**

A, Selective angiogram before pseudoaneurysm embolisation. Microcatheter is positioned just below the pseudoaneurysm.

B, Follow-up angiography after embolisation AP view, pseudoaneurysm exclusion.

C, 3D-XRA reconstruction after embolisation.

Figure 8. Parent artery occlusion embolisation procedure

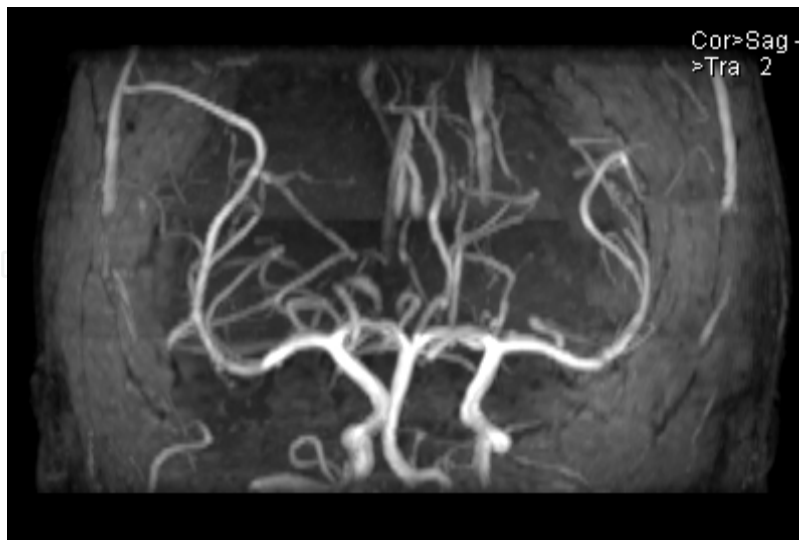


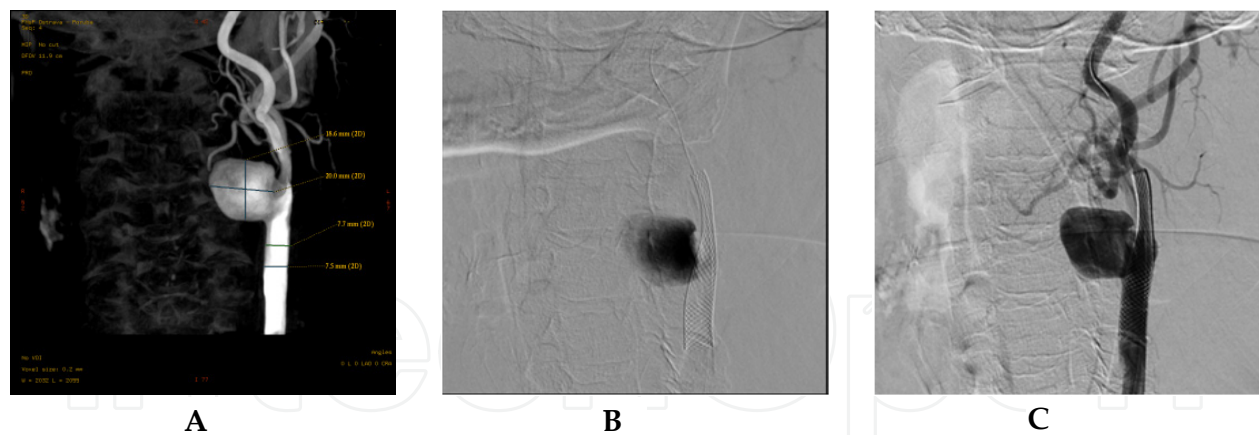
Figure 9. Follow-up MRA

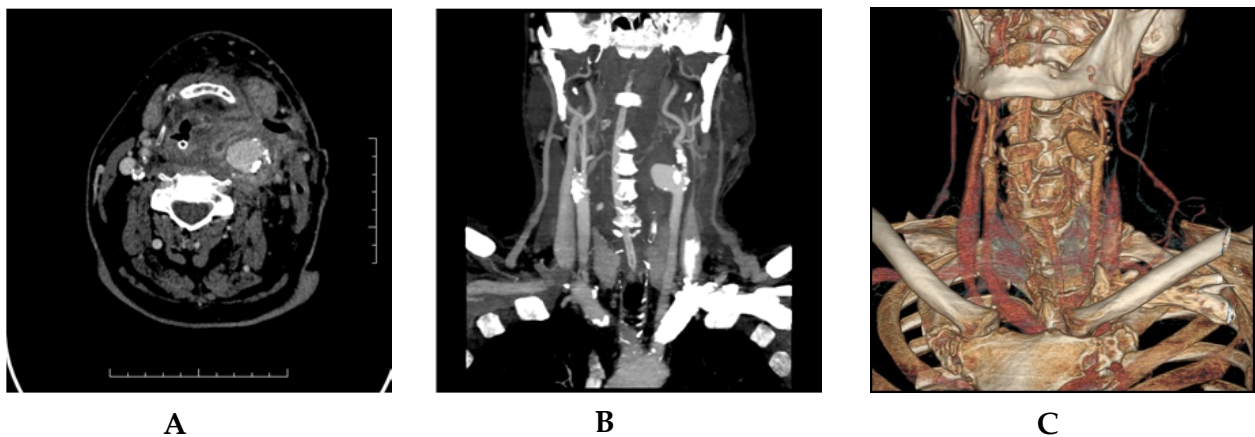

Figure 10. Initial CT scan confirming inflammation and pseudoaneurysm
A, Contrast enhanced CT scan in axial view showing large retropharyngeal inflammation with pseudoaneurysm in the bifurcation of the left common carotid artery.
B, CT scan in MIP projection with large pseudoaneurysm filling
C, CT scan in VRT reconstruction with pseudoaneurysm

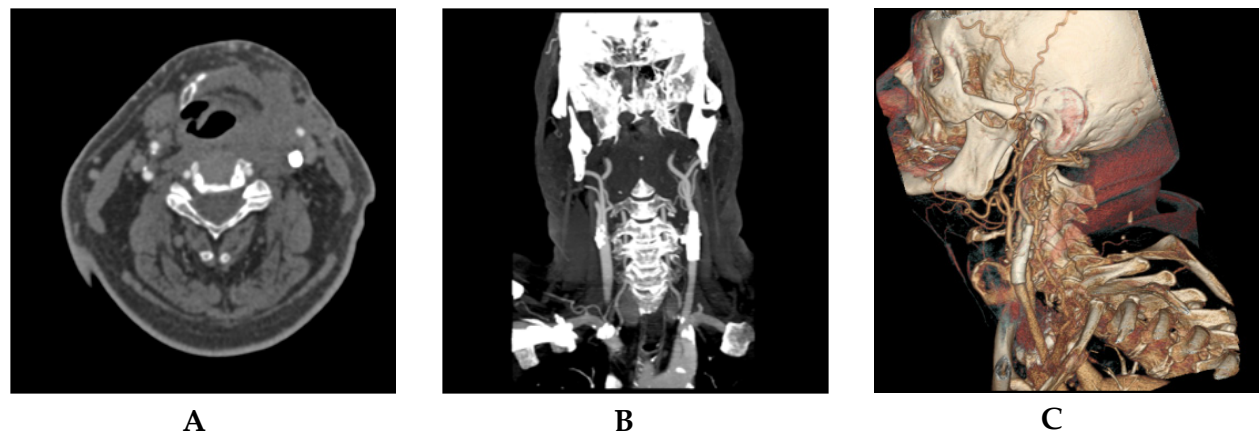
Figure 10. Initial CT scan confirming inflammation and pseudoaneurysm

The vascular surgeon and interventional radiologist were consulted and endovascular approach was agreed upon, as the best treatment option at that particular case. The pathological finding was verified with 3D angiography and two interpolated Wallstents 8/29 (Boston Scientific, USA) were implanted into CCA-ICA region (Fig.11,12). Immediate contrast agent stagnation in the pseudoaneurysm sac was observed. The patient was put on Dalteparine, with the dose of 5000 units per day, which was later followed with dual antiplatelet regime. Dual combination of antibiotics was used (cefotaxime and metronidazole) for prolonged treatment.



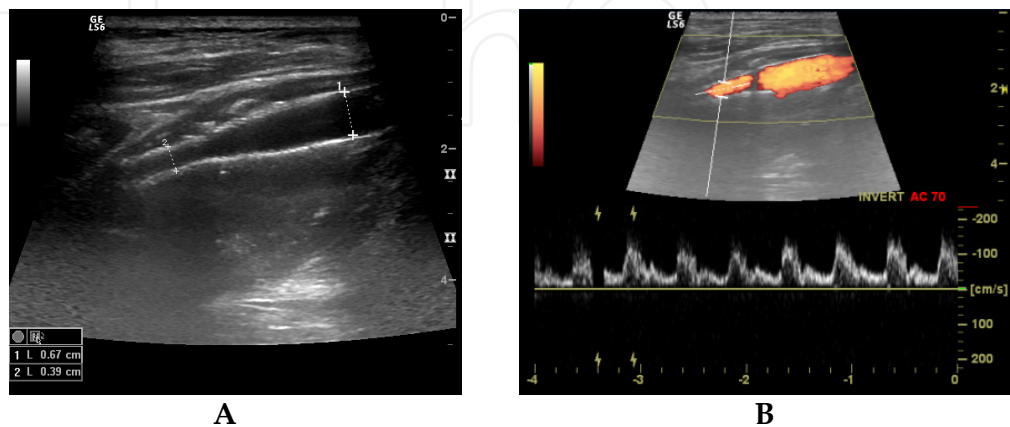
A, 3D-XRA reconstruction with MIP projection of the left CCA bifurcation pseudoaneurysm.
B, Contrast stagnation in pseudoaneurysm after stenting procedure.
C, Two interpolated Wallstents implanted in ICA-CCA

Figure 11. Stenting procedure



A, Follow-up CT scan after Wallstent implantation in axial view.
B, CT scan in MIP projection after stent implantation-exclusion of pseudoaneurysm.
C, CT scan in VRT lateral view with normal perfusion in carotid bifurcation.

Figure 12. Follow-up CT scan after stenting procedure with aneurysm exclusion.



A,B Normal Wallstent perfusion with pseudoaneurysm thrombosis

Figure 13. Ultrasound duplex Doppler follow-up.

The local finding on the vessels was followed with intense ultrasound exams and over the time period of one month, the lesion healed completely with normal carotid vessels patency (Fig. 13).

4.2. Case No. 4

A 17-year-old male with a 5-day history of sore throat, difficult swallowing, pain in the left ear, fever and trismus was examined with CT scan (Fig.14). Inflammation of the left tonsil spreading into the left retrotonsillar and carotid space was confirmed. Laboratory values showed C-reactive protein (CPR) of 175 mg/l and white blood cell count (WBC) of $13,5 \times 10^9/l$. Due to worsening of clinical symptoms and continuing fever, an acute tonsillectomy was indicated and tonsillar culture confirmed *Neisseria* species and *Streptococcus viridans*. The patient was discharged on oral Augmentin (Amoxicillinum trihydraz and Acidum clavulanicum, Smith Kline Beecham Pharmaceuticals, Worthing, Great Britain) five days later. Laboratory results showed CRP 49 mg/l and WBC $5,8 \times 10^9/l$.

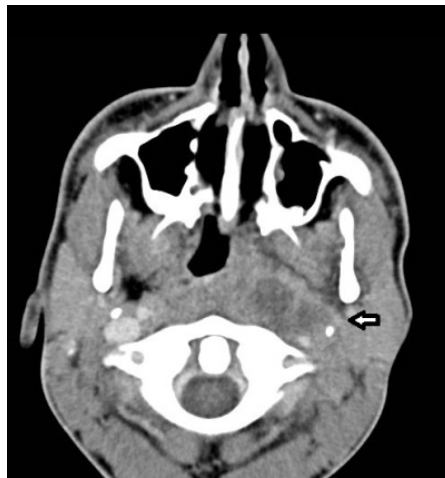

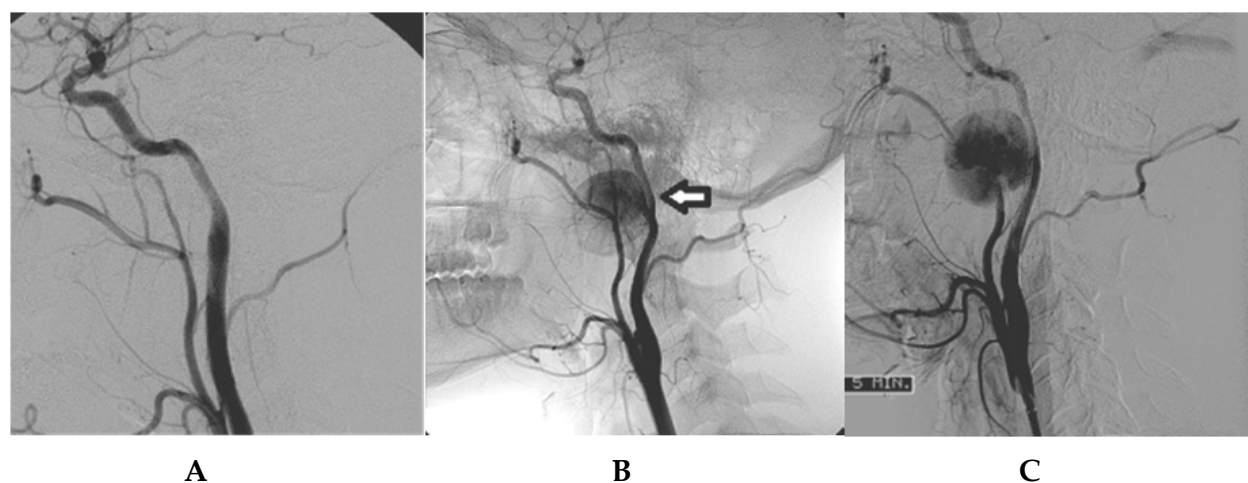
Figure 14. Axial CT scan confirmed an enlarged left tonsil, with an inhomogeneous saturation after i.v. contrast administration. Defiguration of swallowed air-ways and small abscess signs in tonsillar and retrotonsillar space were observed.

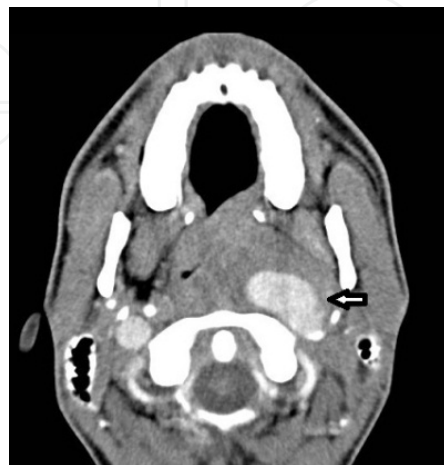

Figure 15. The CT scan shows a large area of pseudoaneurysm in the left retrotonsillar space with a high density.

The patient was readmitted one month later, with a severe pain in the left side of his throat and progressive headache. CT scan was performed with administration of 80 ml of a non-ionic contrast media at a 3.5 ml/s flow rate. A large left ICA pseudoaneurysm was revealed as 18x33 mm dense area in the left retrotonsillar space, extending into the left temporomandibular joint (Fig.15). A vascular surgeon was consulted. However, due to inaccessibility of the skull base pseudoaneurysm, the endovascular treatment was selected as a more feasible approach.

Pseudoaneurysm of the left ICA was visualised (Fig. 16A) and carotid bare Wallstent 7 x 40 mm (Boston Scientific, USA) was promptly implanted into the left ICA. A second angiogram 5 minutes later showed a reduction of the pseudoaneurysm perfusion (Fig 16B). The treatment with Plavix 75 mg and ASA100mg / once a day was continued four weeks. Amoxicillin (Amoxicilinum natricum, Lek Pharmaceuticals, Slovakia) and Klamicin (Klindamycin, Lek Pharmaceuticals, Slovakia) were administered for four weeks. The follow up angiogram in four weeks showed an excellent ICA patency and no pseudoaneurysm filling (Fig 16C). CRP was 17 mg/l, WBC was normal. Patient was discharged doing well.



A, Angiogram of the left common carotid artery confirmed a large pseudoaneurysm at the level of the skull base.
B, The Wallstent immediately after the implantation in the left internal carotid artery.
C, Follow-up angiography after one month confirmed a healed left ICA (C).

Figure 16. Procedure and follow-up angiogram

5. Discussion

Church was the first one to describe an infectious aneurysm in a 13-year-old boy with mitral valve endocarditis in 1869. It has been estimated that infectious aneurysms develop in 3-15% of patients with infectious endocarditis. Intracranial aneurysms are rare in children, accounting for merely 0.5-4.6% of all aneurysms. Several characteristics distinguish them from aneurysms in adults: male predominance; higher incidence of unusual location, such as peripheral or posterior circulation, and a greater count of large or giant aneurysms. These unique features can be attributed to the higher incidence of traumatic, infectious, developmental, and congenital lesions. Subarachnoid haemorrhage is not the exclusive mode of presentation. Neuro-compressive signs and symptoms are frequently observed (Kanaan et al.,1995).

Infectious intracranial pseudoaneurysms develop mostly from the circulating infectious material. The source of this material is obviously located in cardiac valves. Infectious emboli lodges in small distal cerebral arteries and occludes distal arterial flow. Consequently, intense inflammation in the media and adventitia destroys the integrity of the arterial wall and weakens it. The resulting aneurysms are mostly fusiform, eccentric or typical pseudoaneurysms (Chun et al.,2001;Molinari et al.,1973).

Management of the therapy requires multimodality approach. Basically, there exist three possible options. The first one is a medical management of an unruptured infectious pseudoaneurysm with a long course of intravenous antibiotic therapy. This period is usually 6 weeks but may be longer, depending on the impairment of the host immunity. Endovascular therapy is the first line option for patients with ruptured aneurysms. It is a safer, elegant method which decreases the risk of aneurysm rerupture and makes the possible subsequent surgical treatment more safe. In case of multiple aneurysms, there is a benefit of treating more lesions at the same time. Surgical management is the first option for patients in unstable condition, with large intraparenchymal hematoma and increased ICP. The most common location for surgically treated aneurysms is the MCA territory (Lasjaunias et al.,2005;Lasjaunias & Ter Brugge,1997;Rodesch et al.,1987).

Patients with a history of drug abuse desoxyephedrine (Pervitine), cocaine, heroin etc. are frequently affected with brain haemorrhage. These drugs are stimulating. Drugs potentiates dopamine production, which leads to euphoria and high energy, it also suppresses starvation. This drug leads to sympathetic hyperactivity-induced transient hypertension (Gavin,1991;Grinspoon & Bakalar,1981;Lichtenfeld et al.,1984). Hypertension is a predisposing factor for the development and rupture of vulnerable vessels or infectious pseudoaneurysms, which occur more often in drug addicted persons.

Desoxyephedrine, cocaine and its metabolites have been proved as potent cerebral vasoconstrictors (Madden & Powers,1990). In animal models and in human volunteers it was demonstrated that even at a low dose, desoxyephedrine and cocaine can induce cerebrovascular dysfunction and cumulative residual effect in which repeated desoxyephedrine exposure produces delayed and/or prolonged formation and growth of an aneurysm, together with narrowing of vessels. In vivo duration of desoxyephedrine and cocaine-induced vasospasm is unclear (Jain,1963;Nanda et al.,2000). Patients with drug-related aneurysms reportedly have a higher mortality rate than a group of patients with no history of drug abuse.

Pseudoaneurysm of the ICA at the extracranial segment is a rare complication of deep neck area infections, penetrating trauma, tumour invasion and/or radiotherapy. Compared to a true aneurysm, the pseudoaneurysms has no complete native arterial wall. It is composed of extravasated blood that leaked from the area of vessel erosion and is surrounded by inflammatory and fibrous tissues. Pseudoaneurysms of ICA are more frequent in paediatric population. Children are more susceptible to arteritis (Cohen & Rad.,2004). Infection can reach the wall of the carotid artery following a peritonsillar abscesses or pharyngitis. Another pathway for infection may be septicaemia and invasion of the vasa vasorum.

Other possible causes of pseudoaneurysms are penetrating wounds or iatrogenic spread of infection after catheterisation (Alexander et al.,1968; Liston.,1843). The pseudoaneurysms is most likely seen as a result of tonsillitis-induced parapharyngeal abscess, reaching the left ICA adventitia. In our case, ischemia of the carotid artery wall led to its rupture and subsequent development of pseudoaneurysms. We could not exclude a perioperative trauma of ICA during emergency tonsillectomy. Usual bacterial agents causing pseudoaneurysms are *Staphylococcus aureus* or *Streptococcus pyogenes* (Gralla et al.,2004).

A mycotic carotid pseudoaneurysms most likely present as a growing, pulsatile cervical mass, manifested with dysphagia, odynophagia, and fever. Less frequently, lower cranial nerve palsies, Horner's syndrome or trismus may occur. Severe and life-threatening complications may include a carotid artery rupture, intermittent massive nasopharyngeal haemorrhage, and septic or non-septic embolic events leading to a neurological deficit. The usual interval between the infection and the pseudoaneurysms development is between 2 and 8 weeks. The treatment of carotid artery pseudoaneurysms is complex. The typical management of an infected pseudoaneurysms is twofold: systemic antibiotic administration (predominantly penicillin or clindamycin) and/or surgery, with either a traditional by-pass, or a ligation of ICA (Gralla et al.,2004; Heyd & Yinnon,1994; Jebara et al.,1991; Naik et al.,1995). Endovascular therapy of a non-infected and infected carotid artery pseudoaneurysms has been increasingly used (Gralla et al.,2004; Oishi et al.,2002). With this treatment, the ICA lumen may be better preserved. Several approaches are available.

The novel technique "parent artery occlusion" is achieved by positioning detachable balloons distally and proximally to the lesion (Serbinenko,1974). However, this approach demands preliminary evaluation of the collateral pathways in the circle of Willis. The occlusion test requires the patient to be awake, in order to monitor possible neurological deficits. The inherent risk of the occlusion test includes development of neurological deficits and/or failure to identify a delayed ischemia. Another endovascular approach preserving the carotid artery lumen is a stent or stent-graft implantation with/without a coil deposition to the pseudoaneurysms. Since the pseudoaneurysms lacks a true arterial wall, the potential risk of the coils compaction and dislocation is always present. A simple stent or a stent-graft implantation is regarded to be the most effective and faster treatment (Glaiberman et al.,2003;Schonholz et al.,2006).

Choice of the endovascular treatment is mainly influenced by the unfavourable deep location of the pseudoaneurysms nearby the skull base, thus making the conventional surgery more risky. We can initially chose between an uncovered bare stent or two overlapping stents, rather than a covered stentgraft, to minimize the amount of foreign material to be inserted and to lessen the risk of the stentgraft thrombosis or infection.

6. Conclusion

Intracranial infectious pseudoaneurysms can occur not only in connection with a heart disease or HIV patients, but they also frequently occur in younger patients with the history of drug abuse or in prematurely born patients. Last but not least, multimodality approach is

inevitable in the treatment of ruptured or unruptured infectious pseudoaneurysms. Teamwork brings the largest benefit for the successful future outcome.

In the extracranial area, infectious pseudoaneurysms of ICA have traditionally been treated with a surgical resection of the lesion, in addition to the extended i.v. antibiotic course. Recent advances in interventional radiology, together with the development of new materials, opened up a wide spectrum of new endovascular treatment options. A more radical approach involves a complete occlusion of the affected ICA with detachable balloons. It is also possible to conclude, that intra-arterial stent placement offers less invasive option with preservation of the vessel lumen. The use of either a dense-mesh bare stent or a coated stentgraft promises to be a particularly appropriate choice in young individuals presenting with a surgically inaccessible ICA pseudoaneurysms.

Author details

Václav Procházka, Tomáš Jonszta, Daniel Czerný and Jan Krajča
Radiodiagnostic Institute FN Ostrava Poruba, Czech Republic

Michaela Vávrová
Radiodiagnostic department MNOF Ostrava, Czech Republic

Tomáš Hrbáč
Neurosurgery department FN Ostrava Poruba, Czech Republic

7. References

- Alexander DW, Leonard Jr, Trail ML: Vascular complications of deep neck abscesses. A report of four cases. *Laryngoscope*. 78:361-370,1968.
- Cloud GC, Rich PM. et Al. : "Serial MRI of a mycotic aneurysm of the cavernous carotid artery." *Neuroradiology* 45(8): 546-9.,2003.
- Cohen J, Rad I: Contemporary management of carotid blowout. *Curr Opin Otolaryngol Head Neck Surg*. 12: 110-115,2004.
- Gawin FH: „Cocaine addiction”: Psychology and neurophysiology. *Science* 251: 1580-1586,1991
- Glaiberman CB, Towbin RB, Boal DKB: Giant mycotic aneurysm of the internal carotid artery in a child: Endovascular treatment. *Pediatr. Radiol*. 33: 211-15,2003.
- Gralla J, Brekenfeld C, Schmidli J, Caversaccio M, Do Dai-Do, Schroth G: Internal Carotid Artery Aneurysm with Life-Threatening Hemorrhages in a Pediatric Patient. *J Endovasc Ther*. 11:734-738,2004.
- Grinspoon L, Bakalar JB: Adverse effects of cocaine: Selected issues. *Ann. N Y Acad Sci* 362: 125-131,1981.
- Heyd J, Yinnon AM: Mycotic aneurysm of the external carotid artery. *J Cardiovascular Surg (Torino)*. 35:329- 331,1994.

- Chun JY, Smith W, Halbach Van V, Randal, et Al.: „Current Multimodality Management of Infectious Intracranial aneurysma“. *Neurosurgery* 48 (6): 1203-1214,2001.
- Jain K: Mechanism of rupture of intracranial saccular aneurysma. *Surgery* 54: 347-350, 1963.
- Jebara VA, Acar C, Dervanian P, et Al.: Mycotic aneurysms of the carotid arteries – case report and review of the literature. *J Vasc Surg.* 14:215-219,1991.
- Kanaan I, Lasjaunias P et Al.: "The spectrum of intracranial aneurysms in pediatrics." *Minim Invasive Neurosurg* 38(1): 1-9.,1995.
- Lasjaunias P, Ter Brugge KG: Intracranial Aneurysms in Children. *Vascular Diseases in Neonates, Infants and Children*, Springer-Verlag Berlin Heidelberg: 373-392; 1997.
- Lasjaunias P, Wuppalapati S, Alvarez H, Rodesch G, Ozanne A.: Intracranial aneurysms in children aged under 15 years: Review of 59 consecutive children with 75 aneurysms. *Childs Nerv Syst.*21:437-450,2005.
- Lichtenfeld PJ, Rubin DB, Fledman RS: Subarachnoid hemorrhage precipitated by cocaine snorting, *Arch Neurol* 41:223-224,1984.
- Liston R: On a variety of false aneurysms. *Br Foreign Med Rev.* 15:155-161,1843.
- Madden JA, Powers RH: Effect of cocaine and cocaine metabolites on cerebral arteries in vitro. *Life Sci* 47: 1109- 1114,1990.
- Molinari GF, Smith L, Goldstein MN, Satran R: „Pathogenesis of cerebral mycotic aneurysms“. *Neurology* 23: 325-332,1973.
- Naik DK, Atkinson NR, et Al.: Mycotic cervical carotid aneurysm . *Aust N Z J Surg.* 65:620-621,1995.
- Nanda A, Vannemerreddy P, Polin R, Willis B: Intracranial Aneurysma and Cocaine Abuse: Analysis of Prognostic Indicator [Clinical Studies] *Neurosurgery* 46 (5): 1063-1069, 2000.
- Oishi O, Yoshida K, Oyama M, et Al.: Combination of stenting and coil embolisation for carotid artery pseudoaneurysm causing symptomatic mass effect: Case report. *No Schinka Geka-Neurol.Surg* 30(4):437-41,2002.
- Reisner A, Marshall GS, Bryant K, et Al.: Endovascular occlusion of a carotid artery pseudoaneurysm complicating deep neck space infection in a child. *J. Neurosurg.* 91: 510–14,1999.
- Rodesch G, Noterman J, Thys JP, Flament-Durand J, Hermanus N: Treatment of intracranial mycotic aneurysm: Surgery or not. A case report. *Acta Neurochir (Wien)* 85:63-68,1987.
- Salinger S., Pearlman S J., Hemorrhage from pharyngeal and peritonsillar abscesses. *Arch. Otolaryngol.* 1933;18:464-509
- Serbinnenko FA. Balloon catheterization and occlusion of major cerebral vessels *J Neurosurg.* 1974 Aug;41(2):125- 45
- Schonholz C, Krajcer Z, Carlos Parodi J, et al. Stent-graft treatment of pseudoaneurysms and arteriovenous fistulae in the carotid artery. *Vascular.*2006 May-Jun;14(3): 123-9