

We are IntechOpen, the world's leading publisher of Open Access books Built by scientists, for scientists

6,900

Open access books available

185,000

International authors and editors

200M

Downloads

Our authors are among the

154

Countries delivered to

TOP 1%

most cited scientists

12.2%

Contributors from top 500 universities



WEB OF SCIENCE™

Selection of our books indexed in the Book Citation Index
in Web of Science™ Core Collection (BKCI)

Interested in publishing with us?
Contact book.department@intechopen.com

Numbers displayed above are based on latest data collected.
For more information visit www.intechopen.com



Retroperitoneal Haemorrhage as a Dangerous Complication of Endovascular Cerebral Aneurysmal Coiling

Yasuo Murai and Akira Teramoto

Additional information is available at the end of the chapter

<http://dx.doi.org/10.5772/46036>

1. Introduction

Retroperitoneal haemorrhage has been reported as a complication of interventional surgery in less than 3% of all interventional procedures (Ellis et al. 2006, Farouque et al. 2005, Haviv et al. 1996, Kent et al. 1994, Lubavin et al. 2004, Murai et al. 2010, Nasser et al. 1995, Popma et al. 1993, Tiroch et al. 2008, Trimarchi et al. 2010, Witz et al. 1999). Technical advances in neuroendovascular therapy including aneurysm coiling (Bejjani et al. 1998, Murai et al. 2005, Umeoka et al. 2010) or embolization of tumor feeders (Murai et al. 2011) have led to an overall improvement in short- and long-term outcomes of aneurysmal subarachnoid haemorrhage. However, iatrogenic complications such as haematoma or vascular dissections may still occur (Sakai et al. 2001). Although most cases of retroperitoneal haematoma are associated with blunt trauma or rupture of a diseased abdominal artery, interventional surgical accidents are another aetiology (Haviv et al. 1996, Kent et al. 1994, Lodge et al. 1973, Sreeram et al. 1993, Tomlinson et al. 2000). Retroperitoneal haematoma is a relatively rare but serious complication of femoral artery catheterization (Bejjani et al. 1998, Haviv et al. 1996, Illescas et al. 1986, Kalinowski et al. 1998, Kent et al. 1994, Lin et al. 2001, Lodge et al. 1963, Lubavin et al. 1994, Mak et al. 1993, Quint et al. 1993, Raphael et al. 2001, Sreeram et al. 1993, Swayne et al. 1994, Trerotola et al. 1990, Wasay et al. 2001). Tiroch et al. reported a mortality rate of 12% for retroperitoneal haemorrhage patients compared with 1.3% for non-Retroperitoneal haemorrhage patients (Tiroch et al. 2008). Ellis et al. reported 17 patients (10.4%) with retroperitoneal haemorrhage who expired during hospitalization (Ellis et al. 2006). Interventional radiologists and cardiologists have identified the predisposing factors, typical presentation and clinical course of this iatrogenic complication (Haviv et al. 1996, Kalinowski et al. 1998, Kent et al. 1994, Lubavin et al. 2004, Quint et al. 1993, Wita et al. 1999). However, only a small number of cases of retroperitoneal

haemorrhage have been reported following interventional neurovascular therapy because of the low incidence of this complication (Lubicz et al. 2011, Murai et al. 2010). Post-angiographic retroperitoneal haemorrhage is often difficult to diagnose (Illescas et al. 1986, Sharp et al. 1984, Swayne et al. 1994, Trerotola et al. 1990, Witz et al. 1999) and can masquerade as other abdominal diseases. Symptoms are nonspecific (Kent et al. 1994, Kim et al. 2010, Murai et al. 2010, Paul et al. 2010, Raymond et al. 2001) and include abdominal, back and lower extremity pain, with abdominal distension being the most common sign. We report here a case of retroperitoneal haemorrhage following endovascular coiling of a ruptured anterior communicating artery aneurysm, with emphasis on the difficulty in diagnosing retroperitoneal haemorrhage in patients with disturbed consciousness.

2. Representative case presentation

Computed tomography performed at the time of admission on a male patient who complained of headaches revealed a slight subarachnoid haemorrhage (figure 1). His WFNS (the World Federation of Neurosurgical Societies) grade (Teasdale et al. 1988) was I.

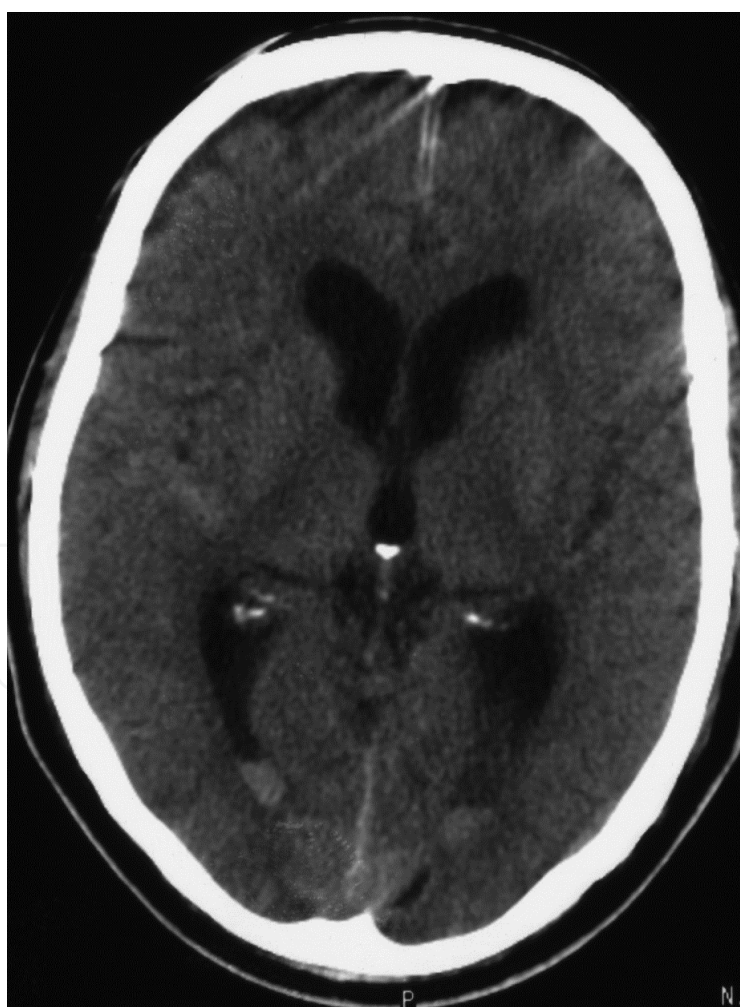


Figure 1. Initial brain computed tomography. Brain computed tomography revealed subarachnoid hemorrhage in the sylvian fissure and lateral ventricle hematoma.

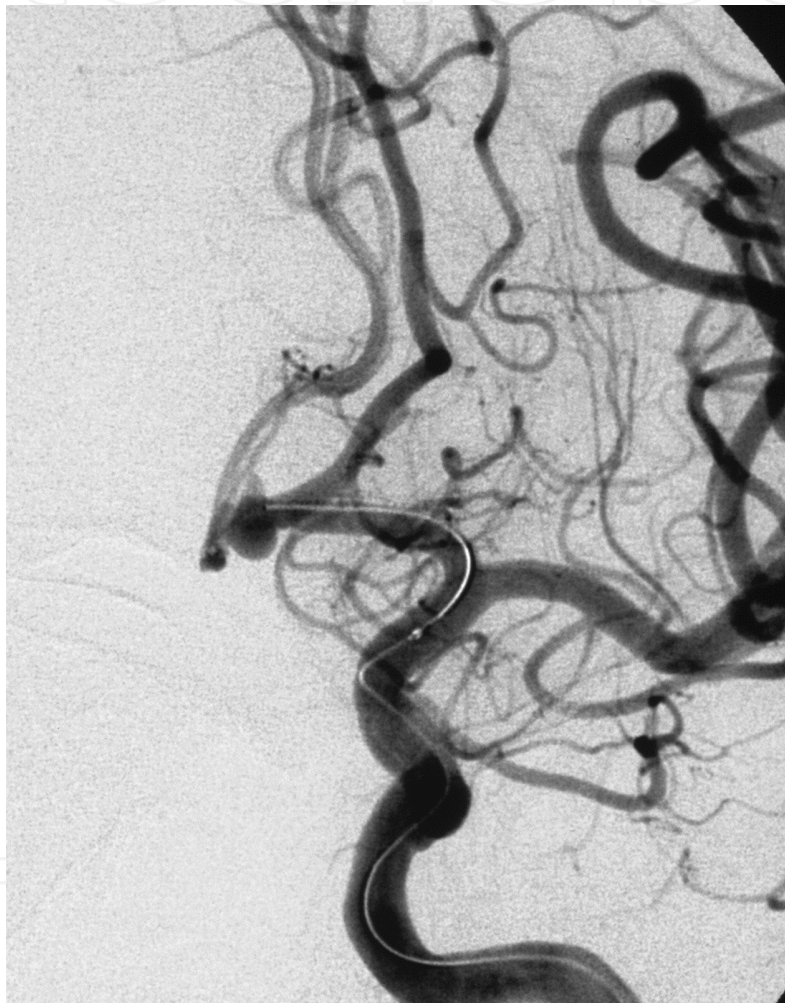
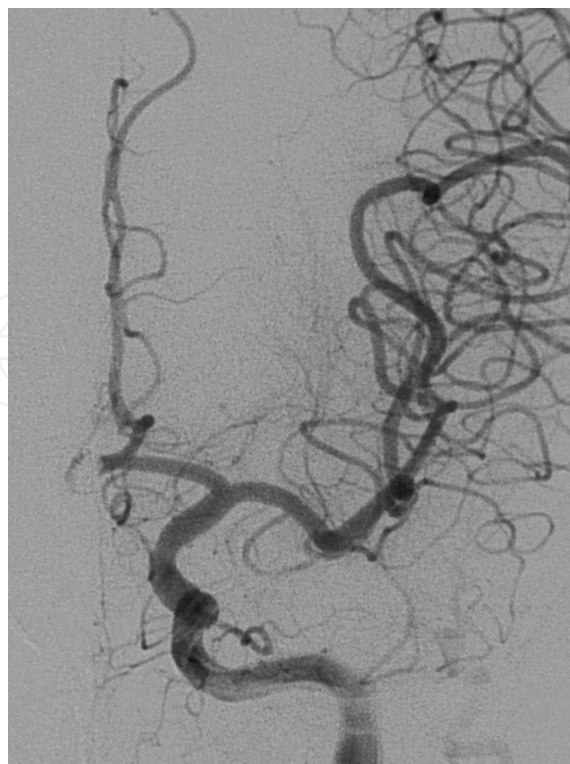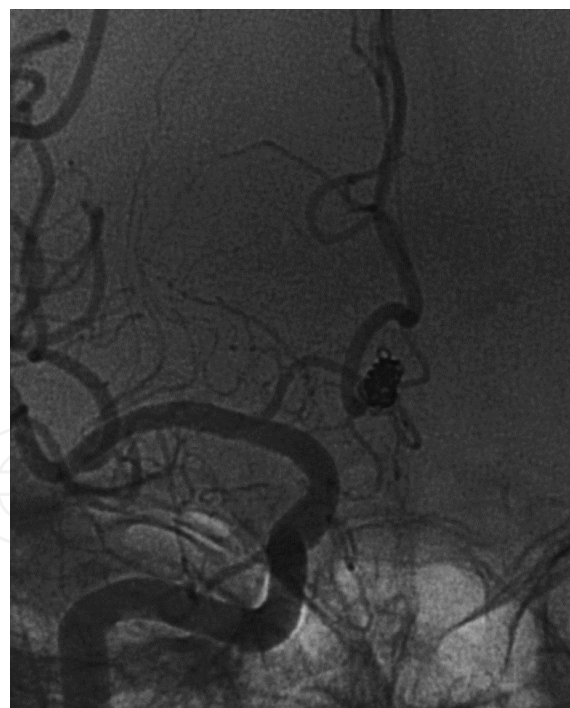


Figure 2. Left carotid angiography. Oblique view of left carotid angiogram indicated anterior communicating artery aneurysm.



(a)



(b)

Figure 3. a) Left carotid angiogram after the coiling. Anterior posterior view of left carotid angiogram indicated coiled anterior communicating artery aneurysm and no perfusion of right distal anterior cerebral artery. b) Right carotid angiogram after the coiling. Anterior posterior view of right carotid angiogram indicated coiled anterior communicating artery aneurysm and perfusion of right distal anterior cerebral artery.

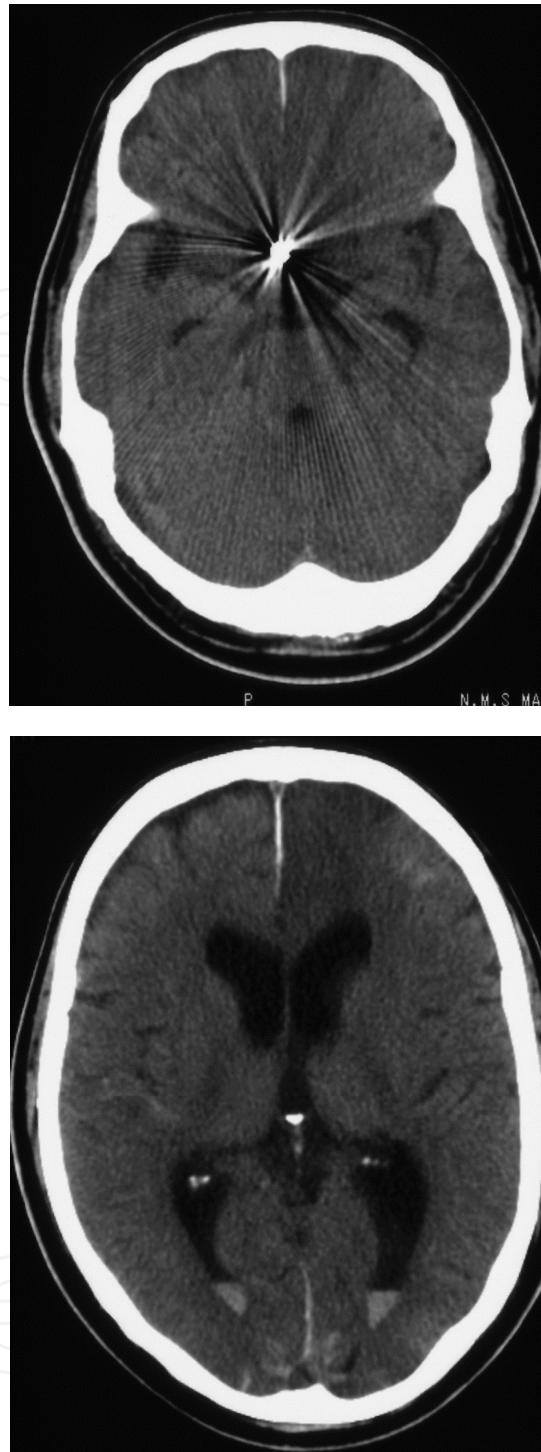


Figure 4. Brain computed tomographic study 20 hours after interventional aneurysmal coiling of anterior communicating artery aneurysm. A low density area is seen on the left anterior cerebral artery territory.

Left internal carotid digital subtraction angiography via right femoral artery access revealed an aneurysm of the anterior cerebral artery. Endovascular aneurysm coiling was performed (figure 2) the following day via right femoral artery access. A 6 French sheath was inserted and the left internal carotid artery was catheterized with the patient under general anaesthesia. Three complex coils were delivered within the lumen of the aneurysm (figure

3.a, 3.b). The patient received a bolus of 5000 units of heparin immediately following the procedure, and thereafter, heparin was infused at a rate of 10000 units per day.

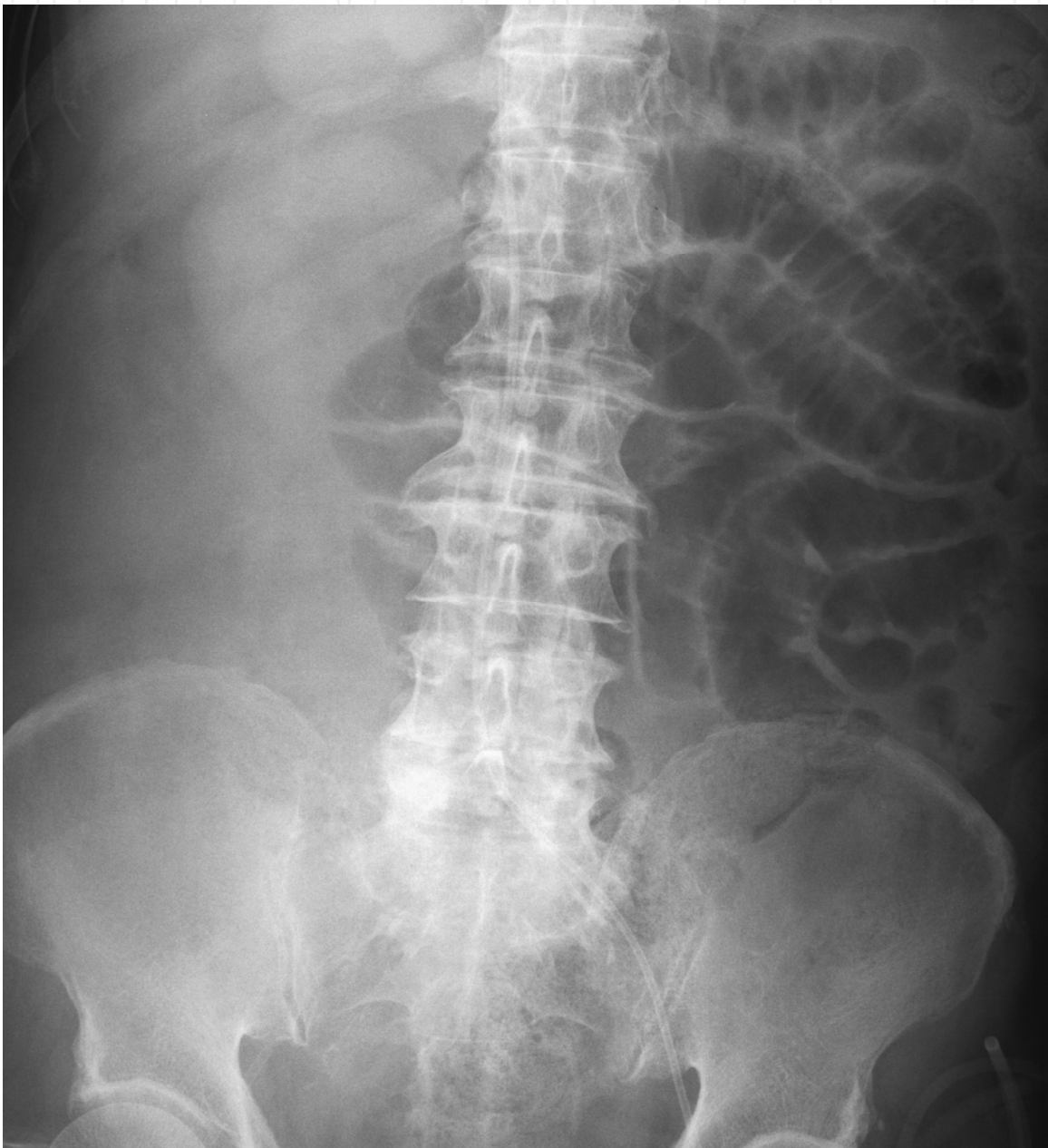


Figure 5. Abdominal X-ray. Abdominal X-ray showing a huge retroperitoneal mass on the right side.

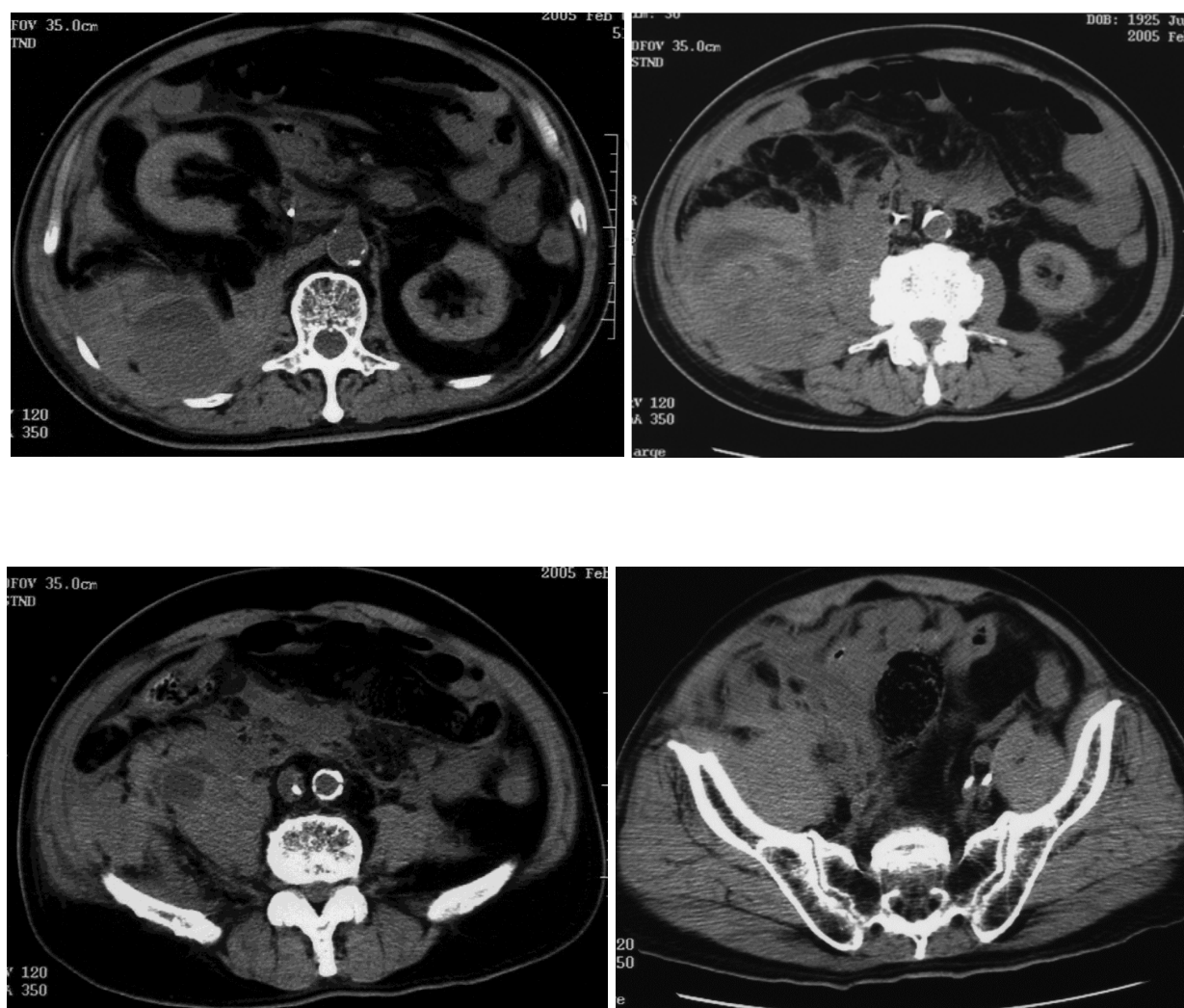


Figure 6. Axial images of abdominal computed tomography.

Abdominal computed tomography 26 hrs after endovascular coiling of an anterior communicating artery aneurysm. A huge retroperitoneal haematoma in the posterior abdominal wall is visible on the right side.

The patient failed to regain consciousness, and brain CT 20 (Fig. 4) hrs after coiling revealed iatrogenic cerebral infarction in the area of distribution of the left anterior cerebral artery. The patient began to become increasingly hypotensive 25 hrs after coiling. He was pale on physical examination and had marked abdominal distension. Abdominal/pelvic roentgenograms (Fig. 5) and CT (Fig. 6) revealed a large retroperitoneal mass on the right side. Abdominal angiography (Fig. 7) was conducted via right femoral artery access.

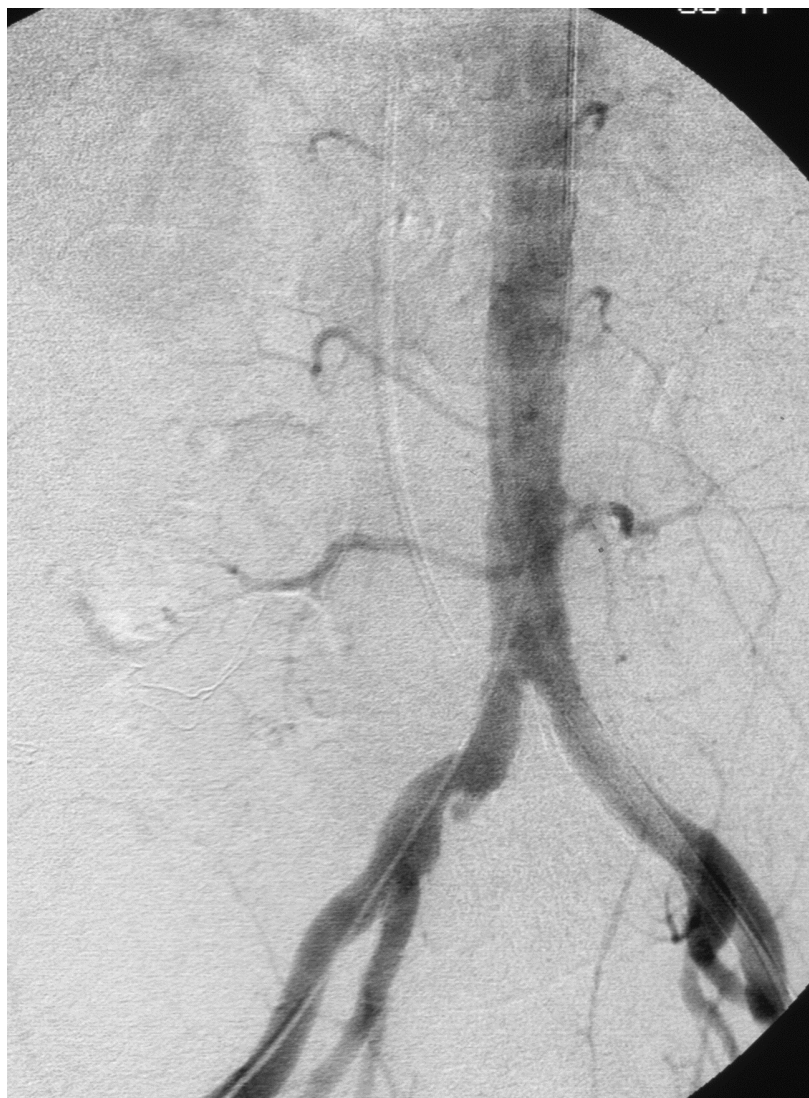

Figure 7. Pervic angiogram. Anterior posterior view of pelvic angiogram indicated no extravasation, abnormal arterial injury, or active bleeding focus.

Author(S)/year	Number of cases	Retroperitoneal hematoma	Rate of complications
AbuRahma/2006	101	1	1%
Ellis / 2006	28378	76	0.26%
Farouque/2003	3508	26	0.74%
Sreeram/1993	7334	11	0.15%
Popma/1993	1413	6	0.5%
Kent/1994	9585	45	0.47%

Table 1. Comparison of incidence of retroperitoneal hematoma in large series.

We did not identify the source of the haemorrhage. The puncture site for endovascular coiling was under the inguinal ligament. The haematocrit continued to fall, and the patient remained hypotensive even with multiple blood transfusions. An emergency laparotomy was performed, but the patient died of multiple organ failure five days after surgery.

3.1. Incidence of retroperitoneal haemorrhage

The low incidence of this complication has made it difficult to study in large numbers of patients. Retroperitoneal haemorrhage complicating percutaneous coronary intervention has been reported to occur in ~0.8% of all procedures (Ellis et al. 2006, Tiroch et al. 2008, Farouque et al. 2005). Ellis et al. reported 163 cases (0.57%) of retroperitoneal haemorrhage out of 28378 percutaneous coronary interventions and confirmed that female gender, body weight and location of sheath placement were risk factors of retroperitoneal haemorrhage (Ellis et al. 2006). Tiroch et al. also reported that the risk factors of RH following percutaneous coronary intervention are chronic renal insufficiency and high arterial puncture, with an incidence rate of 0.49% (17 of 3482 cases)(Tiroch et al. 2008).

3.2. Risk factor of retroperitoneal haemorrhage

Farouque et al. reported that the risk factors of retroperitoneal haemorrhage following percutaneous coronary intervention are female gender, higher femoral artery puncture and low body surface area (Farouque et al. 2005). The incidence of retroperitoneal haemorrhage in their study was 0.74% (26 of 3508 cases). In these studies (Cil et al. 2007, Ellis et al. 2006, Tiroch et al. 2008, Farouque et al. 2005), antithrombotic therapy and vascular closure devices after percutaneous coronary intervention were considered for all cases (Table). Kent et al. reviewed 9585 femoral artery catheterizations and reported 45 cases (0.5%) of retroperitoneal haemorrhage (Kent et al. 1994). These authors also reported the incidence of retroperitoneal haemorrhage after coronary artery stent placement with anticoagulation as less than 2% (Kent et al. 1994). Bejjani et al. reported one case of retroperitoneal haemorrhage after angioplasty where anticoagulant therapy was administered for cerebral vasospasm following subarachnoid haemorrhage (Bejjani et al. 1998). Quint et al. reported the role of femoral vessel catheterization and altered haemostasis in the development of extraperitoneal haematomas (Quint et al. 1993). On the basis of these reports, anticoagulant or thrombolytic therapy should be considered a risk factor of post-catheterization retroperitoneal haemorrhage (Cura et al. 2000, Park et al. 2011, Lodge et al. 1973, Luvian et al. 2004, Sharp et al. 1984, Tomlinson et al. 2000, Wasay et al. 2001, Witz et al. 1999).

3.3. Puncture site and retroperitoneal haemorrhage

Quint et al. studied 44 cases of retroperitoneal haemorrhage with catheterization and altered haemostasis and suggested that these haematomas usually arise from a vessel that is distant to the puncture site (Quint et al. 1993). When the haematoma is not adjacent to the punctured vessels, a haemorrhagic diathesis is the most likely aetiology of the haemorrhage. Sreeram et al. also found that post-catheterization anticoagulation and high arterial puncture were significant risk factors (Sreeram et al. 1993). It has been suggested that some cases of retroperitoneal hematomas after angiography may be unrelated to femoral artery puncture and are more likely due to altered hemostasis. With computed tomographic findings, Quint et al. suggested (Quint et al. 1993) that 25% of retroperitoneal hematomas were remote from the site of femoral artery puncture, with the majority of these being on the contralateral side

to the puncture site. Farouque et al. reported (Farouque et al. 2005) that all instances of retroperitoneal haemorrhage were ipsilateral to the femoral puncture site and contiguous with the presumed site of vessel puncture in the inguinal region. Farouque et al. (Farouque et al. 2005) also suggested that their observations imply that femoral artery puncture was an integral element to the formation of retroperitoneal haemorrhage in all cases.

3.4. Diagnosis and Symptoms of retroperitoneal haemorrhage

The diagnosis of retroperitoneal haemorrhage is difficult because its symptoms mimic other conditions (Akata et al. 1998, Cho et al. 2011, Haviv et al. 1996, Illescas et al. 1986, Kent et al. 1994, Murai et al. 2010). Signs and symptoms are nonspecific and include anaemia in 100%, back pain in 23%, groin pain in 46% and lower abdominal pain in 42% of patients according to Farouque's report (Farouque et al. 2005). Sharp et al. documented six cases of haematomas following femoral vein cannulation for haemodialysis (Sharp et al. 1984). In all cases, the diagnosis was made based on symptoms and abdominal radiography. Haviv et al. reported a case of acute right lower quadrant abdominal pain which was misdiagnosed as acute appendicitis on the basis of abdominal CT (Haviv et al. 1996). Neurological signs, such as lower extremity pain, can result from compression of the femoral nerves. Cho et al reported (Cho et al, 2011) that retroperitoneal hemorrhage can present a diagnostic dilemma because it can present with a variety of symptoms, which, in order of frequency, include abdominal pain, hip and thigh pain, hypotension, anemia, and back pain. These vague symptoms can cause delay of diagnosis and treatment; consequently, it can lead to severe morbidity or mortality (Cho et al, 2011). Kim et al. suggested that anesthesiologists should be aware of the occurrence of retroperitoneal hemorrhage as a consequence of interventional procedures such as femoral arterial puncture. When On clinical suspicion, immediate imaging should be performed to determine the site and extent of the hematoma; fluid and blood product resuscitation is also essential (Kim et al. 2010).

Tiroch et al. also reported on the severity of retroperitoneal haemorrhage (Tiroch et al. 2008). In their study, patients with retroperitoneal haemorrhage had a mortality rate of 12% compared with 1.3% for non-retroperitoneal haemorrhage patients (Tiroch et al. 2008). Ellis et al. reported 17 patients (10.4%) of retroperitoneal haemorrhage who expired during hospitalization (Ellis et al. 2006). Even when patients cannot complain of pain, a definitive diagnosis can still be made by CT (Illescas et al. 1986, Kent et al. 1994). A disturbance in the level of consciousness is not uncommon in patients with subarachnoid haemorrhage, acute phase middle cerebral artery embolism, cerebral vasospasms after subarachnoid haemorrhage or ruptured arteriovenous malformations. Anticoagulant or thrombolytic therapy is commonly administered after interventional procedures have been completed. Such patients are at increased risk of developing retroperitoneal haematomas.

In our case, we continued to monitor the patient's vital signs, conduct physical examinations and record neurological findings during the perioperative period; however, we could not find evidence of a retroperitoneal haematoma (Murai et al. 2010). Unfortunately, disturbance of consciousness due to post-operative cerebral infarction and general anaesthesia makes it

more difficult to find indications of a retroperitoneal haematoma perioperatively. Situations involving disturbance of consciousness, as in this case, are not rare for patients who undergo coiling for a ruptured aneurysm. When the level of consciousness is depressed, physical examination, serial haematocrits and close monitoring of systemic blood pressure should be routinely performed (Murai et al. 2010).

4. Conclusion

Retroperitoneal haematoma following interventional radiology for neurological diseases is relatively rare and can be difficult to diagnose, especially if consciousness is disturbed. This case demonstrates the importance of performing routine physical examinations, sequentially measuring the haematocrit and closely monitoring systemic blood pressure following interventional radiological procedures in patients with altered mental status.

Author details

Yasuo Murai and Akira Teramoto

Department of Neurosurgery, Nippon Medical School, Tokyo, Japan

5. References

- AbuRahma AF, Hayes JD, Deel JT, Abu-Halimah S, Mullins BB, Habib JH, Welch CA, AbuRahma Z (2006). Complications of diagnostic carotid/cerebral arteriography when performed by a vascular surgeon. *Vasc Endovascular Surg.* 40:189-95.
- AbuRahma AF, Elmore M, Deel J, Mullins B, Hayes J (2007). Complications of diagnostic arteriography performed by a vascular surgeon in a recent series of 558 patients. *Vascular.* 15:92-7.
- Akata T, Nakayama T, Kandabashi T, Kodama K, Takahashi S (1998). Massive retroperitoneal hemorrhage associated with femoral vein cannulation. *J Clin Anesth.* 10:321-326.
- Bejjani GK, Bank WO, Olan WJ, Sekhar LN (1998). The efficacy and safety of angioplasty for cerebral vasospasm after subarachnoid hemorrhage. *Neurosurgery.* 42:979-986.
- Cho YD, Lee JY, Seo JH, Kang HS, Han MH (2011). Spontaneous peritoneal and retroperitoneal hemorrhage, rare serious complication following carotid angioplasty with stent. *J Neurol Sci.* 306:160-163.
- Cil BE, Türkbey B, Canyigit M, Geyik S, Yavuz K (2007). An unusual complication of carotid stenting: spontaneous rectus sheath hematoma and its endovascular management. *Diagn Interv Radiol.* 13:46-48.
- Cura FA, Kapadia SR, L'Allier PL, Schneider JP, Kreindel MS, Silver MJ, Yadav JS, Simpfordorfer CC, Raymond RR, Tuzcu EM, Franco I, Whitlow PL, Topol EJ, Ellis SG (2000). Safety of femoral closure devices after percutaneous coronary interventions in the era of glycoprotein IIb/IIIa platelet blockade. *Am J Cardiol.* 86:780-782.

- Ellis SG, Bhatt D, Kapadia S, Lee D, Yen M, Whitlow PL (2006). Correlates and outcomes of retroperitoneal hemorrhage complicating percutaneous coronary intervention. *Catheter Cardiovasc Interv.* 67:541-545.
- Farouque HM, Tremmel JA, Raissi Shabari F, Aggarwal M, Fearon WF, Ng MK, Rezaee M, Yeung AC, Lee DP (200). Risk factors for the development of retroperitoneal hematoma after percutaneous coronary intervention in the era of glycoprotein IIb/IIIa inhibitors and vascular closure devices. *J Am Coll Cardiol.* 45:363-368.
- Haviv YS, Nahir M, Pikarski A, Shiloni E, Safadi R (1996). A late retroperitoneal hematoma mimicking acute appendicitis--an unusual complication of coronary angioplasty. *Eur J Med Res* 1:591-592.
- Illescas FF, Baker ME, McCann R, Cohan RH, Silverman PM, Dunnick NR (1986). CT evaluation of retroperitoneal hemorrhage associated with femoral arteriography. *AJR Am J Roentgenol.* 146:1289-1292.
- Kalinowski EA, Trerotola SO (1998). Postcatheterization retroperitoneal hematoma due to spontaneous lumbar arterial hemorrhage. *Cardiovasc Intervent Radiol* 21:337-339.
- Kent KC, Moscucci M, Mansour KA, DiMattia S, Gallagher S, Kuntz R (1994) Retroperitoneal hematoma after cardiac catheterization: prevalence, risk factors, and optimal management. *J Vasc Surg.* 20:905-910.
- Kim HY, Kim MH, Jung SH, Ryu J, Jeon YT, Na HS, Hwang JY (2010). Retroperitoneal hematoma after coil embolization of cerebral aneurysm -A case report-. *Korean J Anesthesiol.* 59 Suppl:S187-90.
- Lin PH, Dodson TF, Bush RL, Weiss VJ, Conklin BS, Chen C (2001). Surgical intervention for complications caused by femoral artery catheterization in pediatric patients. *J Vasc Surg.* 34:1071-1078.
- Lodge JP, Hall R (1973). Retroperitoneal haemorrhage: a dangerous complication of common femoral arterial puncture. *Eur J Vasc Surg.* 7:355-357.
- Lubavin BV (2004). Retroperitoneal hematoma as a complication of coronary angiography and stenting. *Am J Emerg Med.* 22:236-238.
- Lubicz B, Collignon L, Raphaeli G, De Witte O(2011). Pipeline flow-diverter stent for endovascular treatment of intracranial aneurysms: preliminary experience in 20 patients with 27 aneurysms. *World Neurosurg.* 76:114-119.
- Mak GY, Daly B, Chan W, Tse KK, Chung HK, Woo KS (1993). Percutaneous treatment of post catheterization massive retroperitoneal hemorrhage. *Cathet Cardiovasc Diagn.* 29:40-43.
- Murai Y, Adachi K, Yoshida Y, Takei M, Teramoto A (2010) Retroperitoneal hematoma as a serious complication of endovascular aneurysmal coiling. *J Korean Neurosurg Soc.* 48:88-90.
- Murai Y, Kominami S, Yoshida Y, Mizunari T, Adachi K, Koketsu K, Kobayashi S, Teramoto A (2011) Preoperative liquid embolization of cerebeller hemangioblastomas using N-butyl cyanoacrylate. *Neuroradiology.* 2012, in print
- Murai Y, Kominami S, Kobayashi S, Mizunari T, Teramoto A(2005). The long-term effects of transluminal balloon angioplasty for vasospasms after subarachnoid hemorrhage: analyses of cerebral blood flow and reactivity. *Surg Neurol.*64:122-127.

- Nasser TK, Mohler ER 3rd, Wilensky RL, Hathaway DR (1995). Peripheral vascular complications following coronary interventional procedures. *Clin Cardiol* 18:609–614
- Park SH, Lee SW, Jeon U, Jeon MH, Lee SJ, Shin WY, Jin DK (2011). Transcatheter arterial embolization as treatment for a life-threatening retroperitoneal hemorrhage complicating heparin therapy. *Korean J Intern Med*. 26:352-5.
- Paul AR, Colby GP, Radvany MG, Huang J, Tamargo RJ, Coon AL (2010). Femoral access in 100 consecutive subarachnoid hemorrhage patients: the "craniotomy" of endovascular neurosurgery. *BMC Res Notes*. 3:285.
- Popma JJ, Satler LF, Pichard AD, Kent KM, Campbell A, Chuang YC, Clark C, Merritt AJ, Bucher TA, Leon MB (1993). Vascular complications after balloon and new device angioplasty. *Circulation* 88:1569 –78.
- Quint LE, Holland D, Korobkin M, Cascade PN (1993). Role of femoral vessel catheterization and altered hemostasis in the development of extraperitoneal hematomas: CT study in 44 patients. *AJR Am J Roentgenol*. 160:855-858.
- Raymond J, Guilbert F, Roy D(2001). Neck-bridge device for endovascular treatment of wide-neck bifurcation aneurysms: initial experience. *Radiology*. 221:318-326.
- Raphael M, Hartnell G (2001). Femoral artery catheterization and retroperitoneal haematoma formation. *Clin Radiol*. 56:933-934.
- Sakai N, Murai Y, Suzuki N, Kominami S, Mizunari T, Kobayashi S, Teramoto A, Kamiyama H(2001). A case of iatrogenic carotid artery dissection treated with radial artery graft. *No Shinkei Geka*. 29:837-41.
- Sharp KW, Spees EK, Selby LR, Zachary JB, Ernst CB (1984). Diagnosis and management of retroperitoneal hematomas after femoral vein cannulation for hemodialysis. *Surgery*. 95:90-95.
- Sreeram S, Lumsden AB, Miller JS, Salam AA, Dodson TF, Smith RB (1993). Retroperitoneal hematoma following femoral arterial catheterization: a serious and often fatal complication. *Am Surg*. 59:94-98.
- Swayne LC, Peterson DP, Pohl C (1994). Scintigraphic localization of the bleeding site of a large retroperitoneal hematoma following renal angioplasty. *Clin Nucl Med*. 19:490-492.
- Teasdale GM, Drake CG, Hunt W, Kassell N, Sano K, Pertuiset B, De Villiers JC (1988). A universal subarachnoid hemorrhage scale: report of a committee of the World Federation of Neurosurgical Societies. *J Neurol Neurosurg Psychiatry*. 51:1457.
- Tiroch KA, Arora N, Matheny ME, Liu C, Lee TC, Resnic FS (2008). Risk predictors of retroperitoneal hemorrhage following percutaneous coronary intervention. *Am J Cardiol*. 102:1473-1476.
- Tomlinson MA, Anjum A, Loosemore T (2000). Retroperitoneal haematoma. *Eur J Vasc Endovasc Surg*. 19:558-559.
- Trerotola SO, Kuhlman JE, Fishman EK (1990). Bleeding complications of femoral catheterization: CT evaluation. *Radiology*. 74:37-40.
- Trimarchi S, Smith DE, Share D, Jani SM, O'Donnell M, McNamara R, Riba A, Kline-Rogers E, Gurm HS, Moscucci M; BMC2 Registry (2010). Retroperitoneal hematoma after percutaneous coronary intervention: prevalence, risk factors, management, outcomes, and predictors of mortality: a report from the BMC2 (Blue Cross Blue Shield of Michigan Cardiovascular Consortium) registry. *JACC Cardiovasc Interv*. 3:845-850.

- Umeoka K, Kominami S, Mizunari T, Murai Y, Kobayashi S, Teramoto A (2011). Cerebral artery restenosis following transluminal balloon angioplasty for vasospasm after subarachnoid hemorrhage. *Surg Neurol Int* :2:43.
- Wasay M, Bakshi R, Kojan S, Bobustuc G, Dubey N, Unwin DH (2001). Nonrandomized comparison of local urokinase thrombolysis versus systemic heparin anticoagulation for superior sagittal sinus thrombosis. *Stroke*. 32:2310-2317.
- Witz M, Cohen Y, Lehmann JM (1999) Retroperitoneal haematoma - a serious vascular complication of cardiac catheterisation. *Eur J Vasc Endovasc Surg*. 18:364-365.