

# We are IntechOpen, the world's leading publisher of Open Access books Built by scientists, for scientists

6,900

Open access books available

186,000

International authors and editors

200M

Downloads

Our authors are among the

154

Countries delivered to

TOP 1%

most cited scientists

12.2%

Contributors from top 500 universities



WEB OF SCIENCE™

Selection of our books indexed in the Book Citation Index  
in Web of Science™ Core Collection (BKCI)

Interested in publishing with us?  
Contact [book.department@intechopen.com](mailto:book.department@intechopen.com)

Numbers displayed above are based on latest data collected.  
For more information visit [www.intechopen.com](http://www.intechopen.com)



---

# Saphenous Vein Graft Aneurysms

---

G. Kang and K. Kang

Additional information is available at the end of the chapter

<http://dx.doi.org/10.5772/46035>

---

## 1. Introduction

Saphenous Vein Grafts were introduced to the technique of coronary artery bypass surgery for the treatment of severe coronary artery stenoses more than 40 years ago (1,2). Saphenous vein graft aneurysm defined as abnormal dilation of the bypassed vein graft remains a rare complication but increases the risk of morbidity and mortality (3,4). Vein graft aneurysms are associated with extensive plaque and atherosclerotic debris and can lead to angina and myocardial infarction both with graft occlusion and distal embolization (3,4,5). Saphenous vein aneurysms can rupture with devastating effects leading to shock or fistula formation and also cause compression of surrounding structures. This can lead to enlarged mediastinum (4), atrial fistulas (3), pulmonary leakage with hemoptysis (3), and repeat coronary artery bypass grafting (4). In my practice, I have reported, a leaking saphenous vein graft aneurysm large enough to compress the right heart chambers causing tamponade physiology (4).

## 2. Definition and epidemiology

The aneurysms are uncommon, are usually, 1 cm to 14 cm in size and taking the rarity of reporting into account, the aneurysms are seen in less than 1% of coronary bypass patients on follow up (5). Aneurysms are seen at an average age of 59 years and more often in men (5). Saphenous vein graft aneurysms, like the aneurysms elsewhere are defined as vessel dilations of 1.5 times the size of the reference vessel and were first described 7 years after the first Coronary Bypass surgery in 1975 (6).

### 2.1. Pathophysiology

An aneurysm may be true aneurysm where all the three vessel layers are involved or false where the endothelium or even the media may be disrupted leading to an intramural hematoma or hemorrhage (5). The most common etiology is atherosclerosis but other causes include formation of true or false aneurysms post angioplasty, true aneurysm formation at

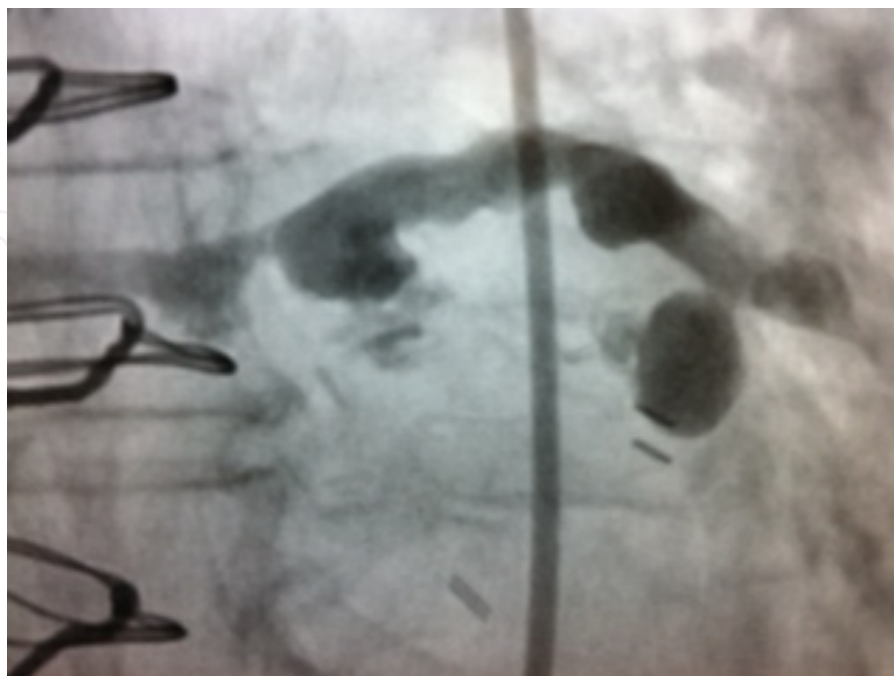the site of a venous valve or false aneurysms at the site of suture rupture or false aneurysm from infectious etiology (5). Aneurysms may result from chronic steroid use or unsuspected harvesting of varicose veins (5).

The true aneurysms are fusiform and often in the middle of the graft and the false aneurysms are saccular and often at the origin of the graft but the aneurysms can be seen anywhere (4,5). Inflammatory causes as in aneurysms elsewhere may also be considered but lack any specific anti-inflammatory therapy (7).

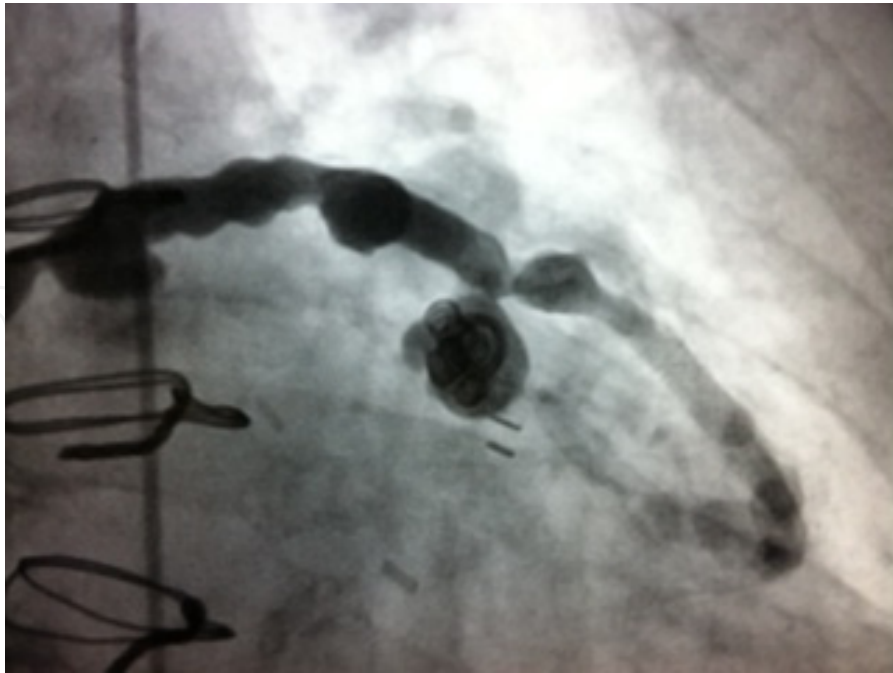### 2.1.1. Symptoms

True aneurysms are often asymptomatic in about half of the patients that present to medical attention and are discovered incidentally on imaging studies (5). They are seen most often in left anterior descending artery venous bypasses followed by right coronary and circumflex artery bypasses, respectively.

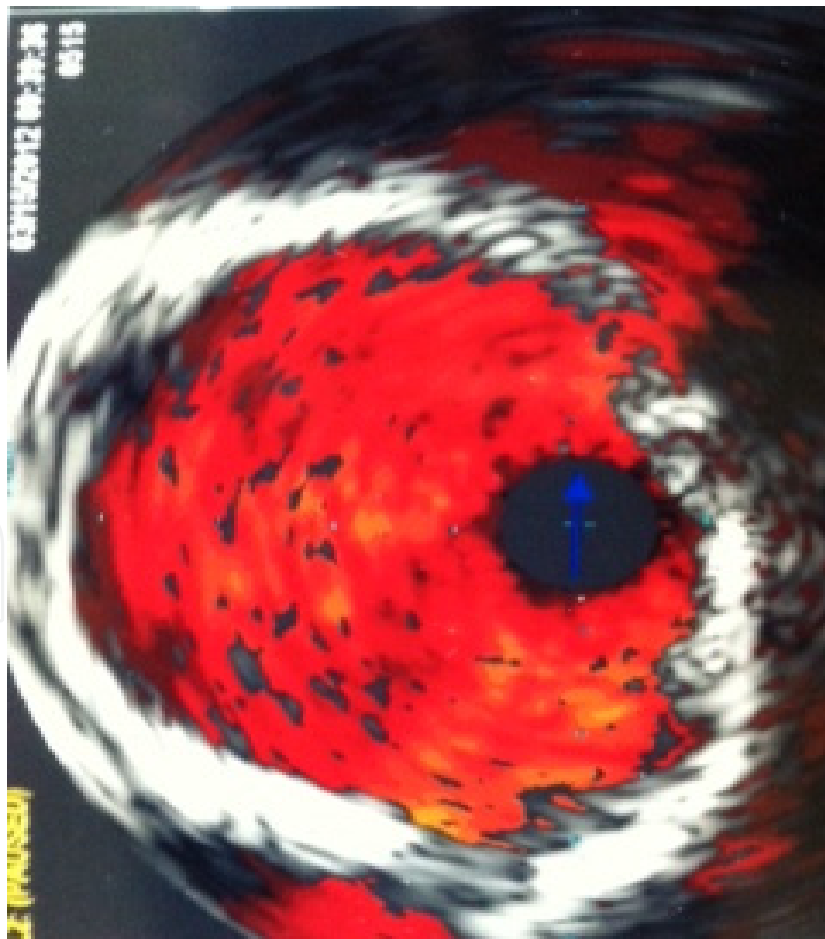
A triad of chest pain, mediastinal enlargement and previous coronary bypass may raise suspicion of a saphenous vein graft aneurysm (4). The symptoms at presentation are usually angina, myocardial infarction, congestive heart failure or variety of symptoms from graft occlusion, embolization, fistula formation or compression of surrounding structures (4,5). False aneurysms are usually symptomatic, however. Only minority of patients with false aneurysms is asymptomatic and the majority of the patients with false aneurysm present with the same symptoms as true aneurysms but the incidence of rupture is higher than with true aneurysms (5). Rupture of the aneurysm into the lung may lead to hemoptysis and into a cardiac chamber can lead to a fistula (8,9,10). Also, compression of left internal mammary artery graft by an aneurysm was recently described (9).



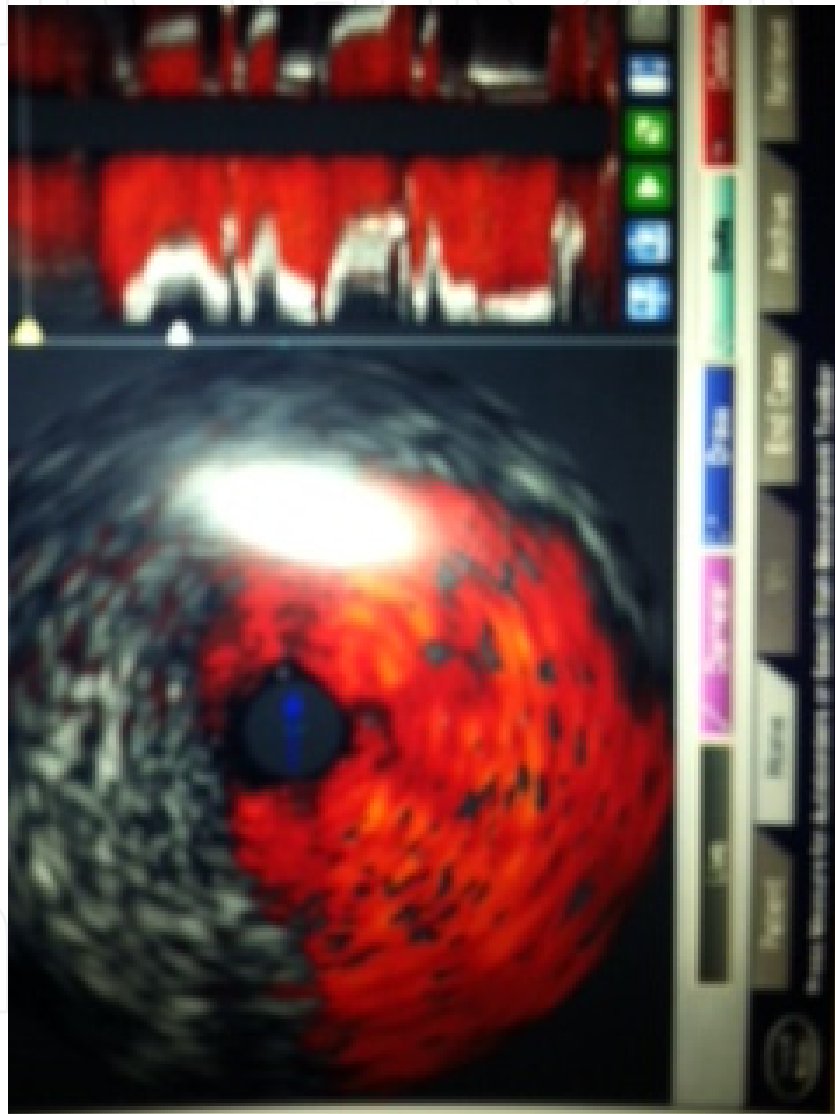
**Figure 1.** Multiple aneurysms and pseudoaneurysms with a narrow neck.



**Figure 2.** Coil embolization of a large pseudoaneurysm on the patient above.

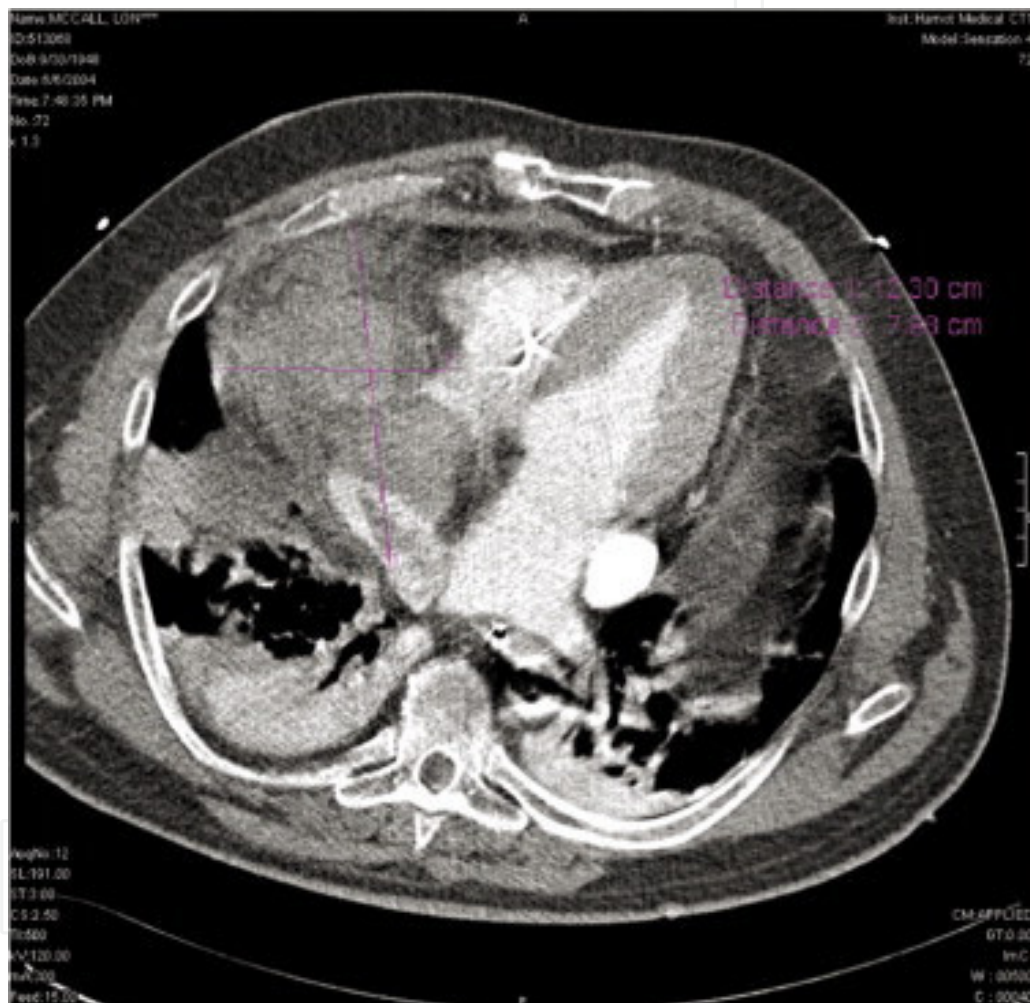


**Figure 3.** Intravascular ultrasound showing pseudoaneurysm at the 20'clock position with disrupted endothelium



**Figure 4.** True aneurysm from 4 to 6O'clock position on intravascular ultrasound

IntechOpen



**Figure 5.** Chest CT scan image of a large leaking aneurysm compressing the right atrium

### 3. Signs

A variety of signs related to the pathophysiology at the time of presentation may be seen. A pulsatile mass on palpation or ischemia causing a gallop rhythm may be noted. If the rupture of the aneurysm occurs then murmurs related to fistula formation or shock secondary to bleeding or compression may be evident (4,5,8,9,10).

### 4. Workup

EKG may show ischemia, infarction or tamponade depending on presentation (4). CXRay may show mediastinal enlargement or pleural effusion (4). Diagnostic test of choice is often coronary angiography that is the gold standard before therapeutic decision-making (5). CT or MRI scanning can also accurately define the extent and size of the aneurysm and the associated complications (4). Echocardiography may show a mass as well (4).

### 5. Conclusion

The average time to diagnosis is 10-20 years post CABG (5) and over that time period, systemic pressures in veins and atherosclerotic disease progression is the most likely cause of aneurysm formation. Medical treatment for atherosclerotic disease is, hence, recommended as primary treatment (4,11). Antiplatelet, cholesterol lowering and anti-hypertensive drugs are standard of care in the treatment (4,11).

The surgical treatment is recommended for large aneurysms but is still controversial as to the size where surgery is necessary (4,11,12). The graft diameter of more than 2 cm is arbitrarily, an indication for surgery (4,5). But, thicker aneurysmal wall or excellent flow through a graft may sway towards medical therapy in borderline cases. Pseudoaneurysms are often treated surgically and distinguished by the narrow neck and ultrasound findings of a disrupted vein graft wall (4,5).

Surgery may involve ligating the aneurysmal graft (4,12,13) and placing a new graft for revascularization (most commonly). Percutaneous techniques are experimental and may include investigational use of stenting and coil embolization or placement of Amplatzer vascular plugs (14). Additionally, covered Jomed stents (Abbott) or even multiple regular stents with prolonged balloon inflation have been tried (15). Other covered stents like Arium iCAST have been tried in our catheterization laboratory. (4,15). In my practice, I have injected platinum coils with expandable hydrogel polymer directly into the pseudoaneurysms with narrow neck or through stent struts for aneurysms with wide neck.

### Author details

G. Kang and K. Kang

*University of Pittsburgh Medical Center/Hamot Hospital, USA*



## Acknowledgement

I acknowledge Hamot Hospital and the patients.

## 6. References

- [1] Favaloro RG. Saphenous vein autograft replacement of severe segmental coronary artery occlusion. Operative technique. *Ann Thorac Surg* 1968;5:334-9.
- [2] Favaloro RG. Saphenous vein graft in the surgical treatment of coronary artery disease. Operative technique. *J Thorac Cardiovasc Surg* 1969;58:178-85.
- [3] Williams M.L., Rampersaud E., Wolfe W.G.: A man with saphenous vein graft aneurysms after bypass surgery. *Ann Thorac Surg* 77. 1815-1817.2004;
- [4] Kang G, Shepherd J, Ferraro R, Butler M, Petrella R. Cardiac tamponade caused by a leaking coronary saphenous vein graft aneurysm. *Am J Emerg Med.* Sep 2007;25(7):858.e1-2.
- [5] Wight , Jr. , Jr.J.N., Salem D., Vannan M.A., Pandian N.G., Rozansky M.I., Dohan M.C., Rastegar H.: Asymptomatic large coronary artery saphenous vein bypass graft aneurysm: a case report and review of the literature. *Am Heart J* 133. 454-460.1997
- [6] Riahi M, Vasu CM, Tomatis LA, et al. Aneurysm of saphenous vein bypass graft to coronary artery. *J Thorac Cardiovasc Surg.* Aug 1975;70(2):358-9.
- [7] Hellmann DB, Grand DJ, Freischlag JA. Inflammatory abdominal aortic aneurysm. *JAMA* 2007;297:395-400
- [8] Fares W, Sharifi M, Steele R, Sarhill N, Sopko J, Ramana CV, et al. Superior vena cava syndrome secondary to saphenous venous graft aneurysm with right atrial fistula. *Catheter Cardiovasc Interv.* Sep 2003;60(1):45-7.
- [9] Agarwal SC, Adams PC, Ahmed JM. Aneurysm of saphenous vein graft causing anterior myocardial infarction by possibly compressing left internal mammary artery. *Int J Cardiol.* May 10 2006;109(2):284-5.
- [10] Nishimura Y., Okamura Y., Hiramatsu T., et al: Hemoptysis caused by saphenous vein graft aneurysm late after coronary artery bypass grafting. *J Thorac Cardiovasc Surg* 129. 1432-1433.2005;
- [11] Dieter R.S., Patel A.K., Yandow D., et al: Conservative vs. invasive treatment of aortocoronary saphenous vein graft aneurysms: treatment algorithm based upon a large series. *Cardiovasc Surg* 11. 507-513.2003;
- [12] Rosin MD, Ridley PD, Maxwell PH. Rupture of a pseudoaneurysm of a saphenous vein coronary arterial bypass graft presenting with a superior caval venous obstruction. *Int J Cardiol* 1989;25:121-3.
- [13] Couto WJ, Livesay JJ, Allam A. Off-pump repair of a giant pseudoaneurysm of a distal saphenous vein bypass graft. *Ann Thorac Surg.* Dec 2005;80(6):2376-8.
- [14] Mylonas I, Sakata Y, Salinger MH, Feldman T. Successful closure of a giant true saphenous vein graft aneurysm using the Amplatzer vascular plug. *Catheter Cardiovasc Interv.* Apr 2006;67(4):611-6



- [15] Ho P.C., Leung C.Y.: Treatment of post-stenotic saphenous vein graft aneurysm: special considerations with the polytetrafluoroethylene-covered stent. J Invasive Cardiol 16. 604-605.2004;

IntechOpen

IntechOpen