

# We are IntechOpen, the world's leading publisher of Open Access books Built by scientists, for scientists

6,900

Open access books available

186,000

International authors and editors

200M

Downloads

Our authors are among the

154

Countries delivered to

TOP 1%

most cited scientists

12.2%

Contributors from top 500 universities



WEB OF SCIENCE™

Selection of our books indexed in the Book Citation Index  
in Web of Science™ Core Collection (BKCI)

Interested in publishing with us?  
Contact [book.department@intechopen.com](mailto:book.department@intechopen.com)

Numbers displayed above are based on latest data collected.  
For more information visit [www.intechopen.com](http://www.intechopen.com)



---

# Hydatid Cysts of the Liver

## – Diagnosis, Complications and Treatment

---

Fethi Derbel, Mohamed Ben Mabrouk,  
Mehdi Ben Hadj Hamida, Jaafar Mazhoud,  
Sabri Youssef, Ali Ben Ali, Hela Jemni, Nadia Mama,  
Hasni Ibtissem, Arifa Nadia, Chedia El Ouni,  
Walid Naija, Moncef Mokni and Ridha Ben Hadj Hamida

Additional information is available at the end of the chapter

<http://dx.doi.org/10.5772/48433>

---

### 1. Introduction

Hydatid disease in people is mainly caused by infection with the larval stage of the dog tapeworm *Echinococcus granulosus*. It is an important pathogenic, zoonotic and parasitic infection (acquired from animals) of humans, following ingestion of tapeworm eggs excreted in the faeces of infected dogs. Hydatid disease is a major endemic health problem in certain areas of the world [1-3].

Cystic hydatid disease usually affects the liver (50–70%) and less frequently the lung, the spleen, the kidney, the bones, and the brain [1-3]. Liver hydatidosis can cause dissemination or anaphylaxis after a cyst ruptures into the peritoneum or biliary tract. Infection of the cyst can facilitate the development of liver abscesses and mechanic local complications, such as mass effect on bile ducts and vessels that can induce cholestasis, portal hypertension, and Budd-Chiari syndrome [4].

Treatment of hydatid liver cyst has to be considered mandatory in symptomatic cysts and recommended in viable cysts because of the risk of severe complications [1]. The modern treatment of hydatid cyst of the liver varies from surgical intervention to percutaneous drainage or medical therapy. Surgery is still the treatment of choice and can be performed by the conventional or laparoscopic approach. However, laparoscopic approach leads to an important rate of recurrence of the disease. Percutaneous Aspiration-Injection-Reaspiration Drainage (PAIR) seems to be a better alternative to surgery in selected cases.

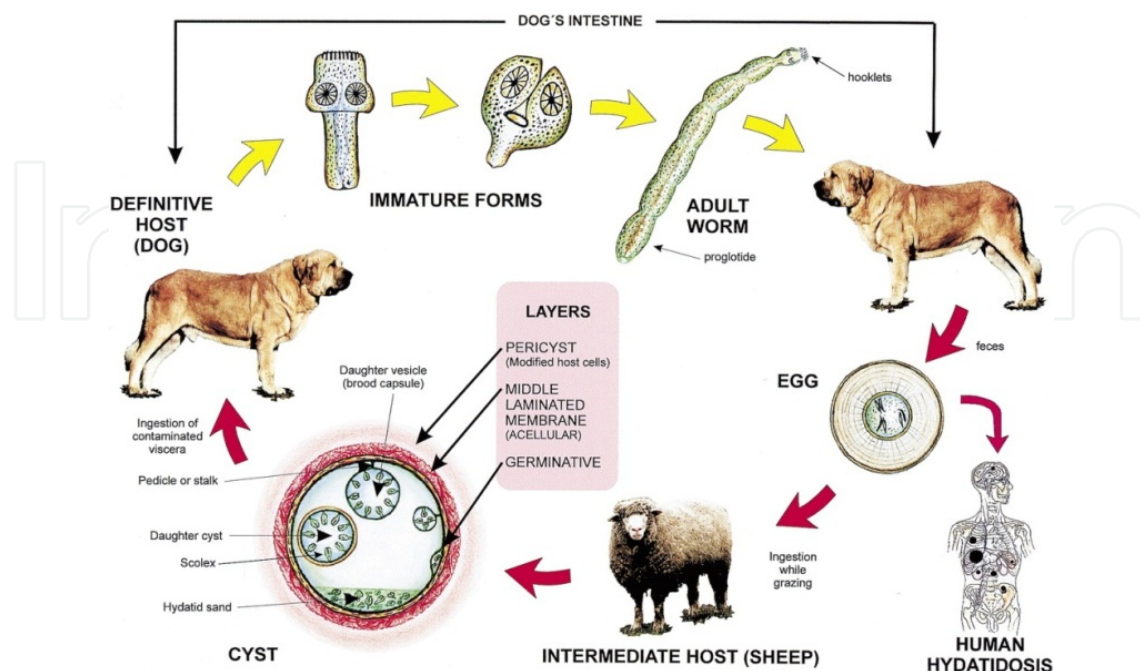
## 2. Epidemiology

*Echinococcus granulosus* is spread almost all over the world, especially in areas where sheep are raised, and is endemic in Asia, North Africa, South and Central America, North America, Canada and the Mediterranean region. In many countries, hydatid disease is more prevalent in rural areas where there is a closer contact between people and dogs and various domestic animals which act as intermediate vectors. Hydatid disease remains frequent and endemic in Tunisia [5]

### 2.1. Life cycle of *Echinococcus granulosus*

The life cycle of *E. granulosus* requires both an intermediate host usually (a sheep, a cattle, or a swine), and a primary canine host. A man becomes both an accidental and an intermediate host through contact with infected dogs or by ingesting food or water contaminated with eggs of the parasite. One can never be surprised to find out that this disease is most commonly found in the temperate and sheep-raising areas of the world [3]

Once the eggs are ingested, they release larvae into the duodenum. The larvae migrate through the intestinal mucosa and gain access to mesenteric vessels which carry them to the liver. The liver is the site of up to 70% of echinococcal lesions. Larvae that escape hepatic filtering are carried to the lung, the site of an additional 15-30% of lesions. From the lungs, larvae may be disseminated to any part of the body. (figure 1). Larvae that escape the host's defenses and persist in a host organ develop into small cysts surrounded by a fibrous capsule. These cysts grow at a rate of 1-3 cm/year and may remain undetected for years. Thus; they can reach very large sizes before they become clinically evident. The cyst wall contains an outer chitinous layer and an inner germinal layer. The germinal layer may develop internal protrusions and eventually form daughter cysts within the original cyst.

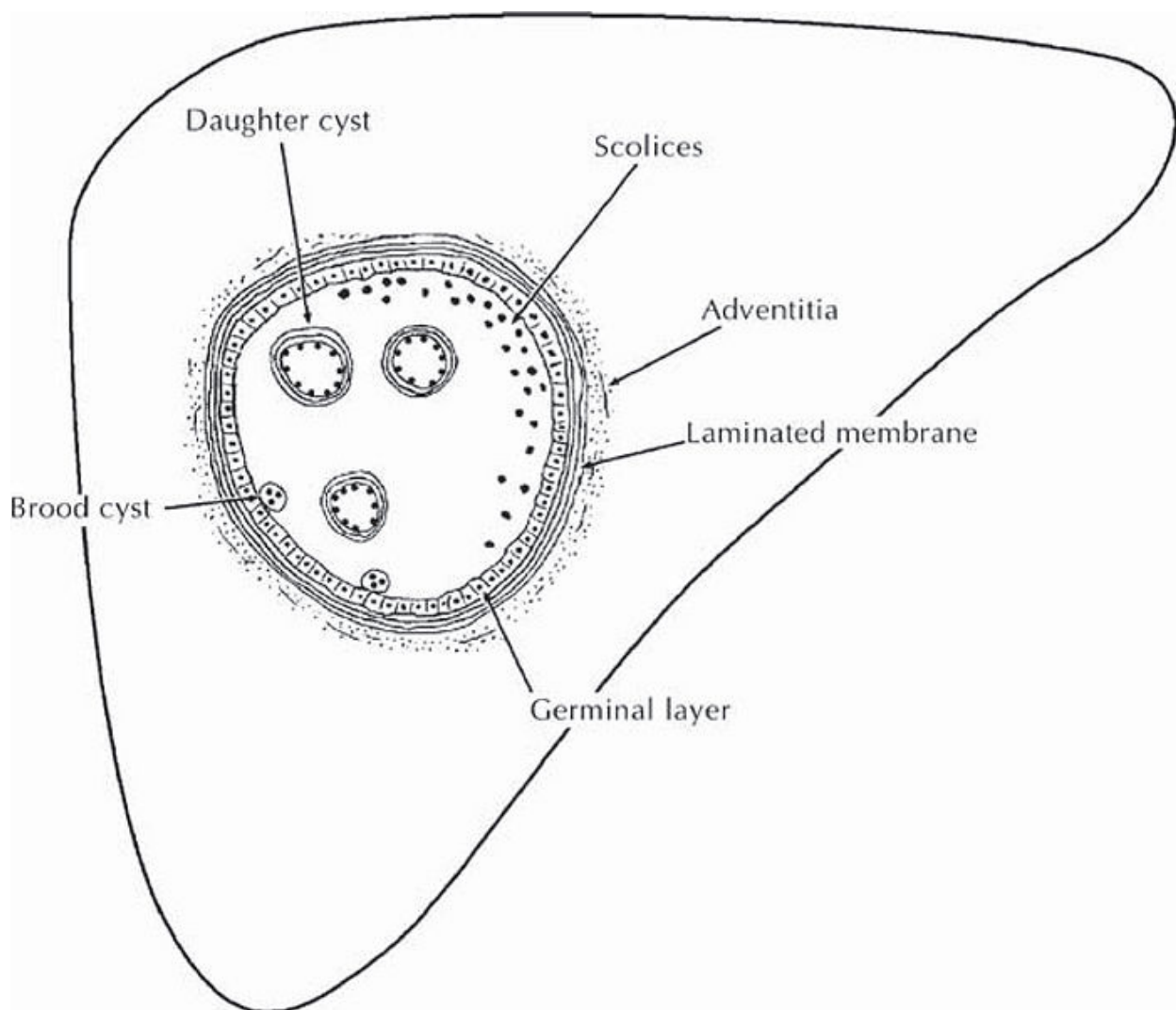


**Figure 1.** The Life cycle of *Echinococcus granulosus*. [in 3]

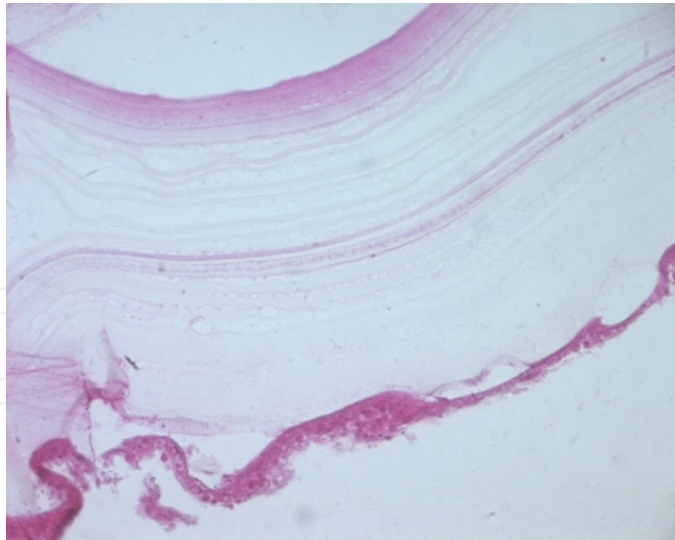
### 3. Pathology - Hydatid cyst structure

A primary cyst in the liver is composed of three layers: (figure 2)

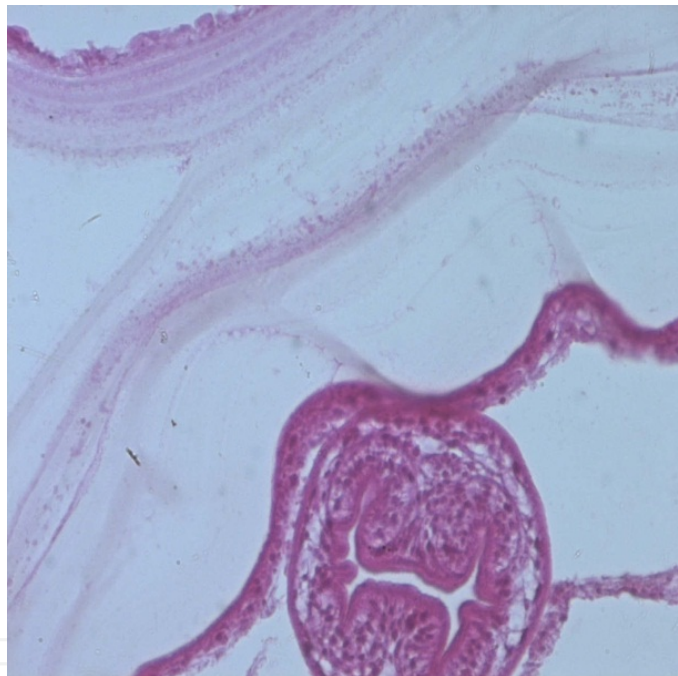
1. Adventitia (pericyst): consisting of compressed liver parenchyma and fibrous tissue induced by the expanding parasitic cyst.
2. Laminated membrane (ectocyst): is elastic white covering, easily separable from the adventitia. (Figure3-4)
3. Germinal epithelium (endocyst) – is a single layer of cells lining the inner aspects of the cyst and is the only living component, being responsible for the formation of the other layers as well as the hydatid fluid and brood capsules within the cyst. In some primary cysts, laminated membranes may eventually disintegrate and the brood capsules are freed and grow into daughter cysts. Sometimes the germinal Epithelium daughter cysts, which if left untreated may cause recurrence.



**Figure 2.** Hydatid cyst of the liver



**Figure 3.** Cystic structures with laminating fibrous wall and inner germinal layer



**Figure 4.** Tissue section of a hydatid cyst showing daughter cyst

#### **4. Natural history and genesis of complications:**

Natural history of the hydatid cyst can be divided into two phases:

- The first phase is that of growth during which rupture can occur when the pressure of the hydatid liquid becomes more important than resistance of the hydatid wall (pericyst). Finally, the complications such as acute allergic manifestations, infection, jaundice, vomique, are only the consequence of the rupture of the cystic wall.
- The second phase is a phase of ageing and of progressive involution. It is the consequence of the overproduction of scolices and daughter cysts. During this phase,



the hydatid cyst will be full of scolices and membranes which replace the hydatid liquid. Calcifications occur in the pericyst; the host is at the origin of the image of pericystic wall. Then the reaction of the host leads to a progressive calcification of the walls.

The hydatid cyst is unique and localized in the right lobe of the liver in 65%. The most frequent extrahepatic locations are the lungs, the spleen and the peritoneum. Liver (55–70%) is the obvious first site after entry through the gut and passage in the portal circulation. Most cysts tend to be located in the right lobe. As the cysts enlarge local pressure causes a mass effect on surrounding tissue producing commensurate symptoms and signs. These may be generalized with upper abdominal pain and discomfort or more specific. Such as; obstructive jaundice. Biliary rupture may occur through a small fissure or bile duct fistula. A wide perforation allows the access of hydatid membranes to the main biliary ducts, which can cause symptoms simulating choledocholithiasis. Alternatively, it may produce a picture very similar to ascending cholangitis with fever, pain and jaundice.

## **5. Complications of hydatid cyst of the liver:**

Echinococcal cysts of the liver can cause complications in about 40% of cases. The most common complications in order of frequency are infection, rupture to the biliary tree; rupture to the peritoneal cavity; rupture to the pleural cavity.

However, rupture in the gastrointestinal tract; bladder and the vessels are very rare.

### **5.1. Infection**

It is the most common complication and can be somewhat symptomatic. The evolution of an infected hydatid cyst is usually latent, subacute and is clinically translated by pains in the right hypochondrium, hepatomegaly, and fever [1-3].

### **5.2. Intrabiliary rupture of hydatid cyst**

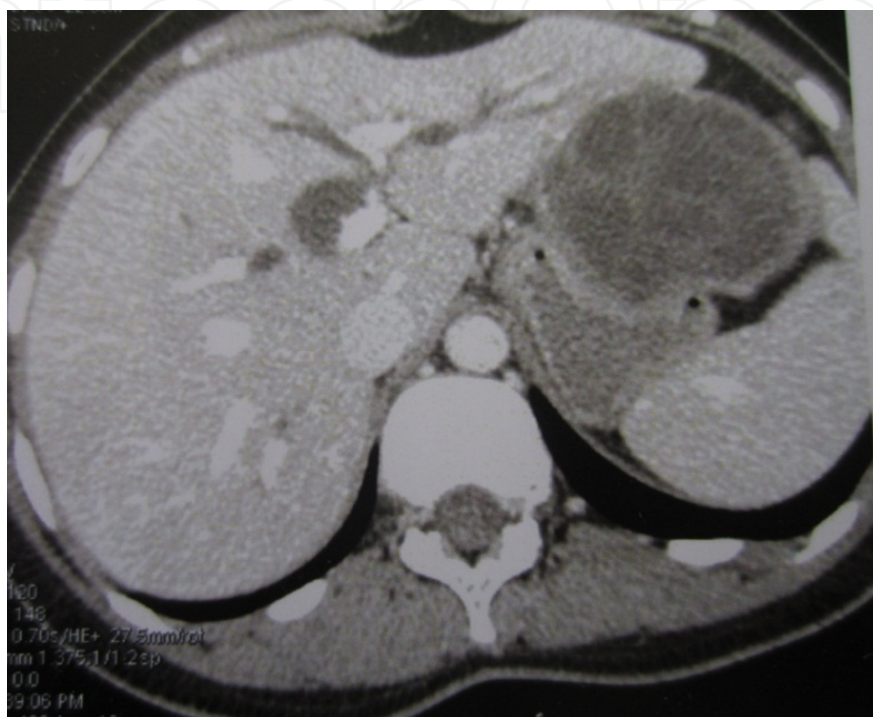
Intrabiliary rupture of a hepatic hydatid cyst is a common complication and may occur in 2 forms: an occult rupture, in which only the cystic fluid drains to the biliary tree and is observed in 10-37% of the patients; and frank rupture, which has an overt passage of intracystic material to the biliary tract and is observed in 3-17% of the patients. Intrabiliary rupture mainly occurs in centrally localized cysts, and an intracystic water pressure up to 80 cm is also a predisposing factor for the rupture. Intrabiliary rupture occurs in the right hepatic duct (55-60% cases), left hepatic duct (25-30% cases), hepatic duct junction, common bile duct (CBD), or cystic duct (8-11%); perforation into the gallbladder may be observed in 5-6% of cases.

The incidence of rupture into the biliary tree ranges between 3 and 17% [4-6].

The rupture of the hydatid cyst in the biliary ducts and the migration of the hydatid material in the biliary tree lead to the apparition of other biliary complications like: cholangitis, sclerosis odditis, hydatid biliary lithiasis etc.

When ruptured into biliary tree, hydatid cysts commonly manifest with findings of biliary obstruction and cholangitis. Diagnosis of this complication can usually be made by using ultrasound and abdominal CT scan.

The presence of dilated common bile duct, jaundice, or both in addition to a cystic lesion of liver and bile ducts dilatation at CT-scan is strongly suggestive of a hydatid cyst with intrabiliary rupture. (Figure 5)



**Figure 5.** CT scan showing hepatic hydatid cyst with dilatation of left intra hepatic duct

### 5.3. The rupture in the thorax

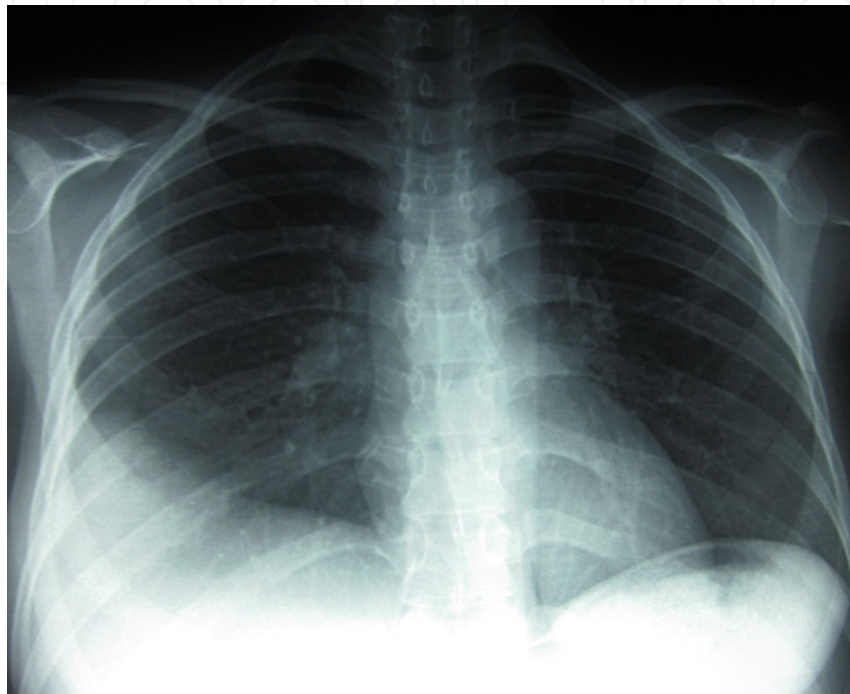
Thoracic complications of hepatic hydatid cysts result from the proximity of hydatid cysts in the liver and the diaphragm and are seen in approximately 0.6% to 16% of cases.

Several factors, such as pressure gradient between thoracic and abdominal cavities, mechanical compression and ischemia of the diaphragm, sepsis in the hepatic cyst, or chemical erosion by bile, participate in promoting Intrathoracic evolution of hydatid cysts of the hepatic dome.[6-10]

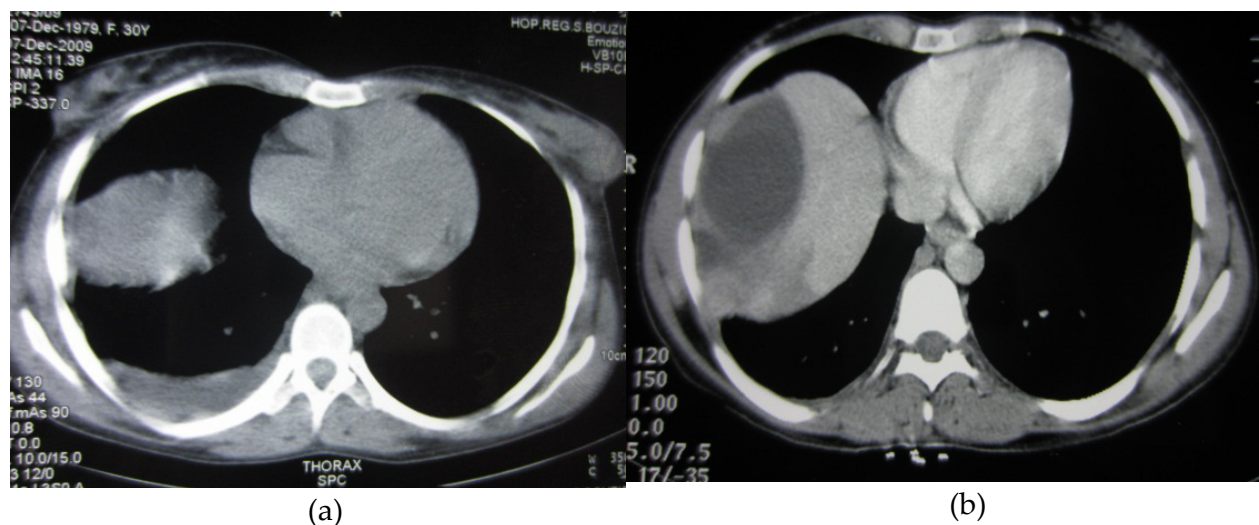
Intrathoracic rupture of hepatic hydatid cyst is a rare but a severe condition causing a spectrum of lesions to the pleura, lung parenchyma, and bronchi. Cyst erosion is associated with pericystic inflammation. Adhesion formation determines whether the rupture is confined to lung parenchyma or the free pleural space, or both. Bronchobiliary fistula leads to hemoptysis and cyst expectoration.

The clinical presentation is predominately pulmonary, with abdominal symptoms being less frequent [11-12]. Coughs, expectoration, and dyspnea are present in 30% of cases.

Diagnosis of thoracic complications is performed with Thoraco-abdominal CT-scan which shows the liver hydatid cyst, and the thoracic complication and sometimes could show the diaphragmatic fistula (figure 6-8). The treatment of this complication is usually made through abdominal approach associated to percutaneous drainage of the pleural collection. The indications for thoracotomy become rare.

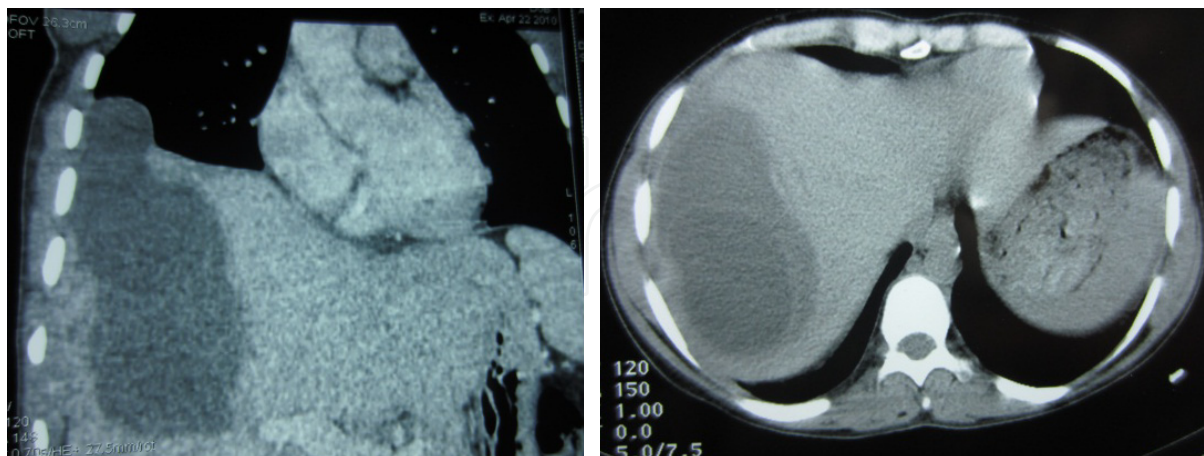


**Figure 6.** Chest radiograph showing a right pleural effusion with atelectasis



**Figure 7.** Thoracic CT-scan showing an atelectasis of the lower lobe of right lung (A) and hydatid cyst of the hepatic dome (B)





**Figure 8.** Abdominal CT-scan showing a hepatic hydatid cyst of segment VII with communication with the right pleura

#### 5.4. The rupture in the peritoneum

Rupture of the cyst in the peritoneal cavity is rare and generally followed by anaphylactic reactions. A free intraperitoneal rupture has been reported between 1% and 8% in the literature [13-14].

Intraperitoneal cysts may rupture spontaneously, due to increased intracystic pressure, or as a consequence of trauma [8-9], leading to the spread of hydatid fluid in the intraperitoneal cavity.

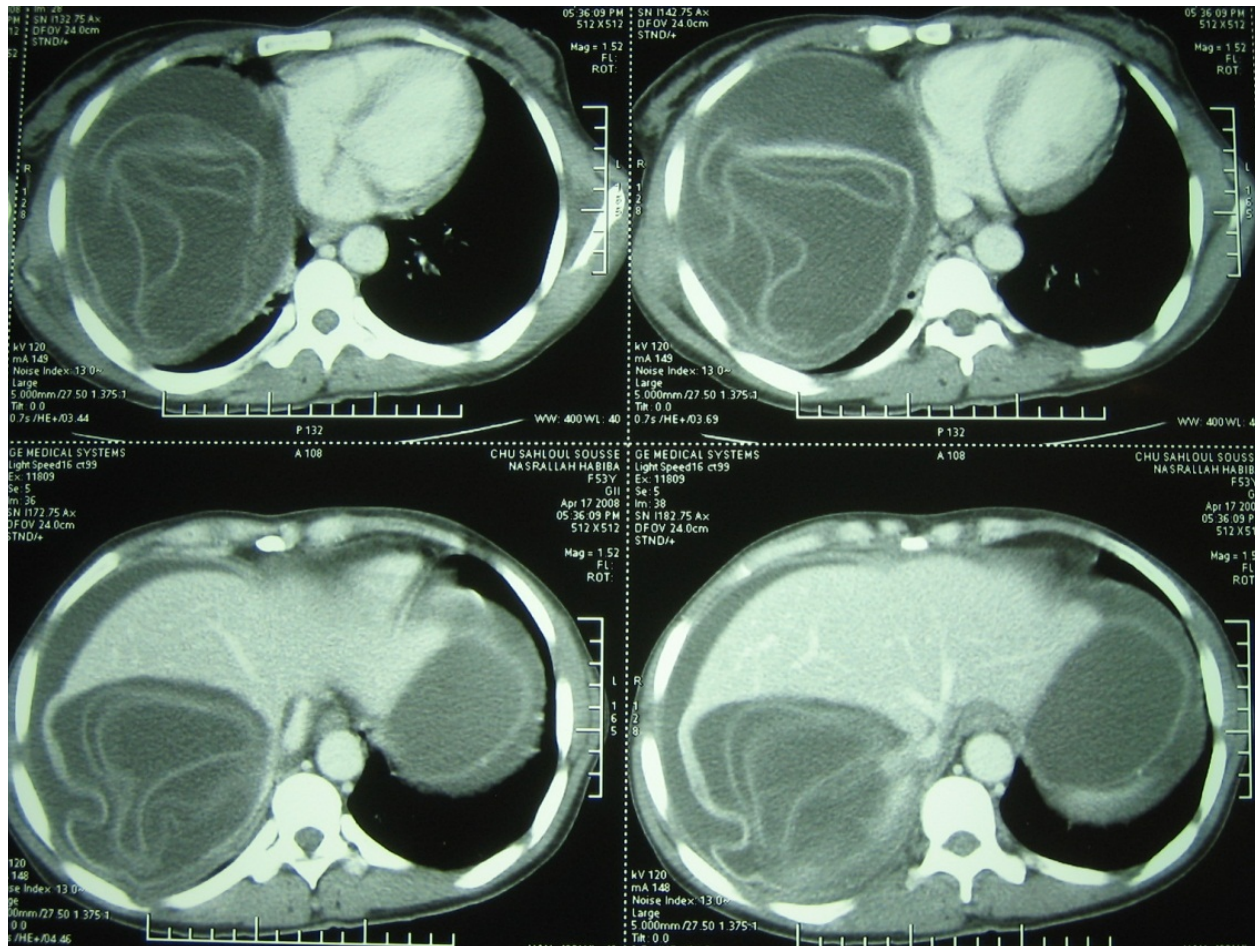
Significant risk factors for hydatid cyst perforation include younger age, cyst diameter of >10 cm, and superficial cyst location.

Rupture into the peritoneum may present as acute abdominal pain. Antigenic fluid released into the peritoneal cavity and absorbed into the circulation may present with acute allergic manifestations. Abdominal pain, nausea, vomiting and urticaria are the most common symptoms. Allergic reactions may be seen in 25% of the cases.

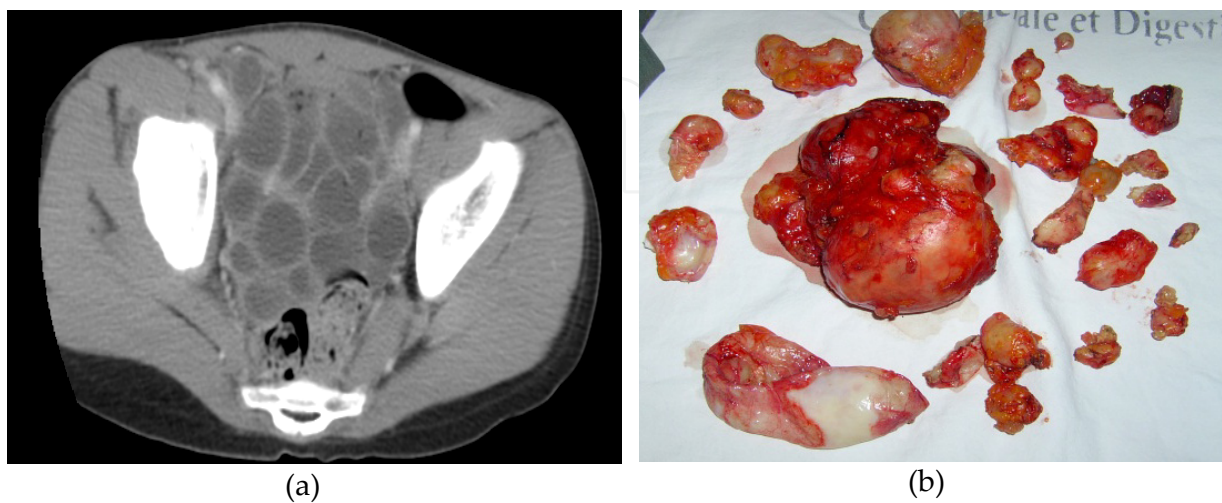
In some cases, if the hydatid cyst contains bile due to associated rupture in the biliary tree, the patient will present peritonitis or even of hydatid choleperitonitis.

If the rupture is insidious, the release of brood capsules, scolices and even daughter cysts from a ruptured hydatid cyst into the peritoneal cavity leads to multiple cysts in the peritoneal cavity. This phenomenon is called secondary echinococcosis [15-16]. (Figure 9-13)

The diagnosis of this complication is mainly performed with the abdominal CT-scan that shows the hydatid cyst of the liver generally collapsed and peritoneal effusion or daughter cysts. In secondary echinococcosis, the CT –scan shows the hydatid cysts and many peritoneal cysts.

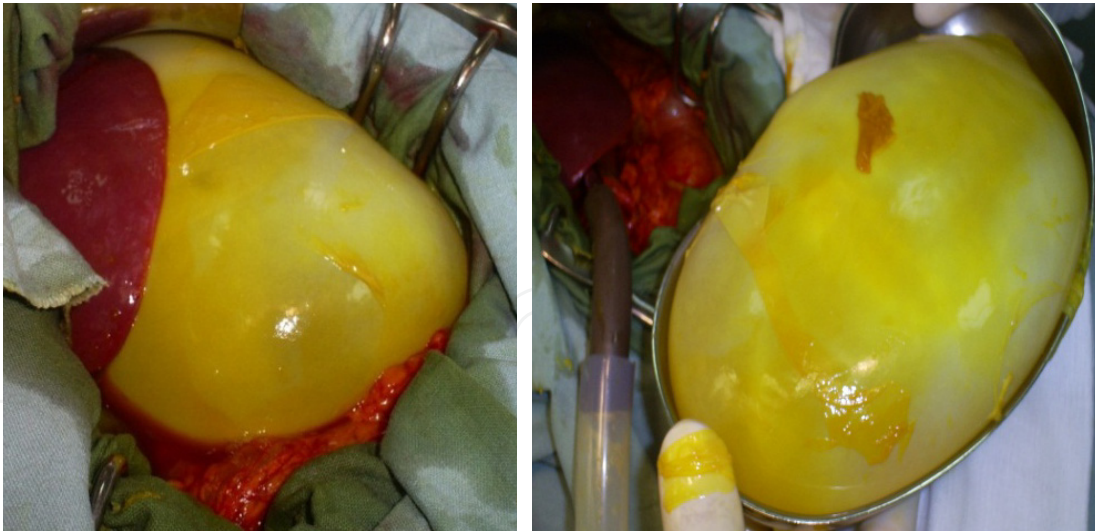

**Figure 9.** CT scan showing a rupture hydatid cyst of the liver in the peritoneum

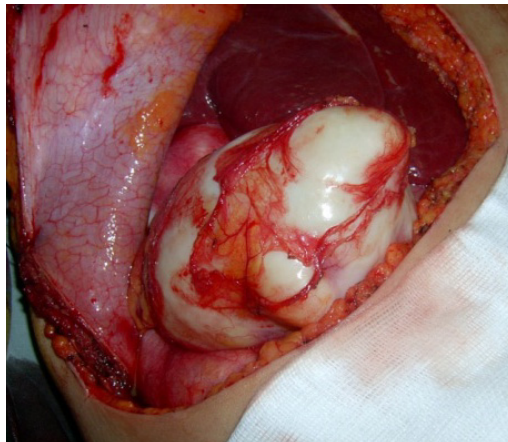


**Figure 10.** CT-scan of the abdomen showing multiple hydatid cysts in the peritoneal cavity due to rupture of hepatic hydatid cyst (secondary echinococcosis)(A). Multiple peritoneal cysts(B)

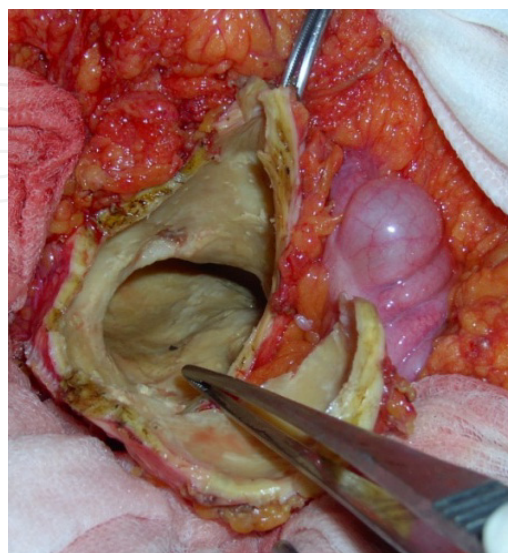




**Figure 11.** An operative view in a 12 years old male showing a hydatid cyst of the liver with spontaneous rupture in peritoneum



**Figure 12.** Operative view showing a hydatid cyst of the peritoneum



**Figure 13.** Operative view showing a peritoneal echinococcosis

### 5.5. Other complications

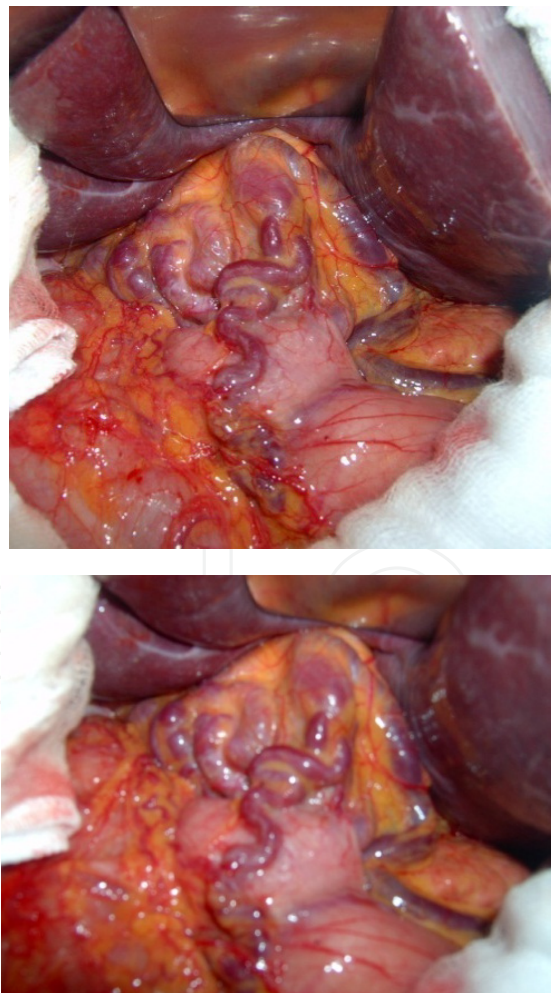
Some complications of the hydatid cyst of the liver are very rare.

About fistulization to the skin, It occurs most often by a cutaneous orifice leaving pus welling and sometimes hydatid membranes [17-18].

Portal hypertension (pre-hepatic, hepatic, post-hepatic) is a very rare complication of hydatid cyst of liver. The compression of the hepatic veins can be responsible for Budd-Chiari syndrome and portal hypertension [19-20]. (fig 14-15)

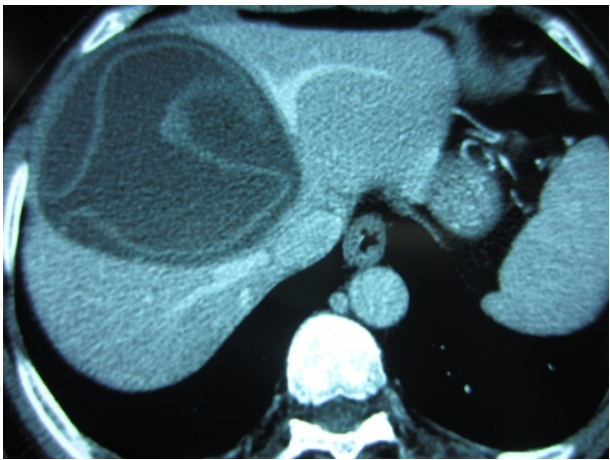
Vascular erosions are very rare complications of the hydatid cysts of the liver. The vessels could be either the hepatic vein or the vena cava. Some spontaneous ruptures into the vena cava have been described [19].

Acute abdominal pains with a sudden decrease in the volume of cyst and release of daughter vesicles during vomiting (hydatimesis) or in stool (hydatidentery) are highly suggestive of the opening of the cyst in the digestive tract. (fig 16-17)

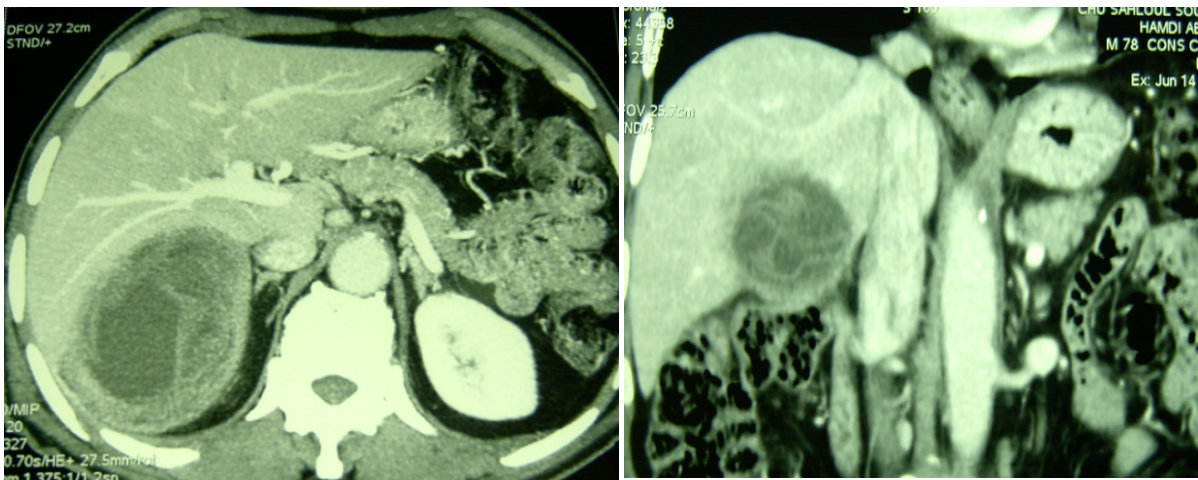


**Figure 14.** Operative view showing a hydatid cyst of the liver with portal hypertension

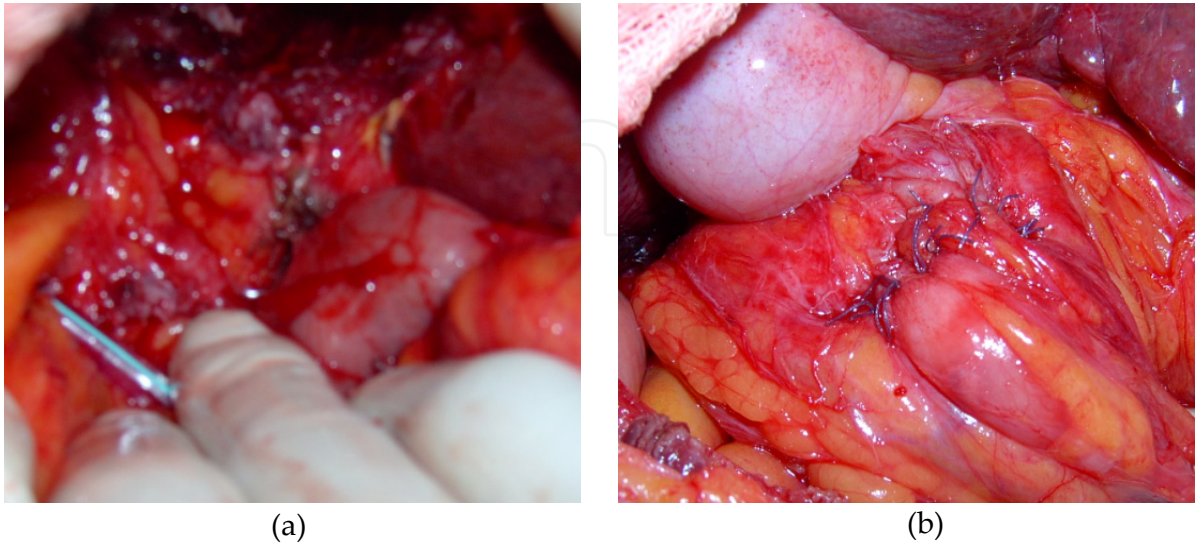




**Figure 15.** CT scan showing a central hepatic cyst with vascular compression



**Figure 16.** CT-scan : hydatid cyst of the segment V showing a large fistula between the cyst and the right colon



**Figure 17.** Operative view showing the colonic fistula (A) and the suture of the fistula after cysto-colonic deconnexion(B)

## 6. Diagnosis

### 6.1. Clinical feature

After infection with *Echinococcus granulosus*, humans are usually asymptomatic for a long time. The growth of the cyst in the liver is variable, ranging from 1 mm to 5 mm in diameter per year. Most primary infections consist of a single cyst, but up to 20%-40% of infected people have multiple cysts. The symptoms depend not only on the size and number of cysts, but also on the mass effect within the organ and upon surrounding structures.[21]

#### 6.1.1. Non complicated cysts

Hydatid cyst of the liver is frequently silent and only diagnosed incidentally during abdominal investigation for other pathology. The clinical signs appear gradually with the increase volume of the cyst. The most common symptom, when it occurs, is right upper quadrant or epigastric pain and the most common findings on examination are an enlarged liver and a palpable mass. Pressure effects are initially vague. They may include non-specific pain, cough, low-grade fever, and the sensation of abdominal fullness. As the mass grows, the symptoms become more specific because the mass impinges on or obstructs specific organs.

#### 6.1.2. Complicated cysts

Patients may also present with complications of the cyst such as biliary communication, intraperitoneal rupture (spontaneous or post-traumatic) and, rarely, intrathoracic or intrapericardial rupture.

Cyst rupture can be associated with anaphylaxis secondary to the highly antigenic content of the cyst fluid or may be silent and present with multiple intraperitoneal cysts.

With secondary infection, tender hepatomegaly, chills, and spiking temperatures occurs. Urticaria and erythema occur in cases of generalized anaphylactic reaction. With biliary rupture the classic triad of jaundice, biliary colic and urticaria occurs.

The diagnosis is most easily set by ultrasound or other imaging techniques such as CT-scan or MRI, combined with case history. Serology tests such as ELISA or immunoblotting can be used in addition, being 80-100% sensitive for liver cysts but only 50-56% for lungs and other organs [21]. False positive reactions may occur in persons with other tapeworm infections, cancer, or chronic immune disorders. Whether the patient has detectable antibodies depend on the physical location, integrity and viability of the cyst. Patients with senescent, calcified or dead cysts usually are sero-negative. Patients with alveolar echinococcosis have most of the time detectable antibodies. Fine needle biopsy should be avoided if dealing with *E. granulosus* since

there is a great danger of leakage with subsequent allergic reactions and secondary recurrence.

A great part of the patients treated for hydatid disease get their diagnosis incidentally, seeking medical care for other reasons.

The time at when a previously silent cyst gives rise to pathology depends both on the size of the cyst, but also on its location, making presenting symptoms of cystic echinococcosis highly variable. Most presenting features are caused by the pressure that the enlarged cyst expels on its surroundings, but may also appear if there is a rupture of a cyst.

Symptoms leading to diagnosis mostly include abdominal pain, jaundice (caused by biliary duct obstruction) or a palpable mass in the hepatic area. Cysts in the liver may also cause cirrhosis.

If the cyst is damaged, there may be a leakage of fluid from inside. This fluid contains antigens that are highly toxic, causing allergic reactions like fever, asthma, urticaria, and eosinophilia and in some cases anaphylactic shock.

## 6.2. Investigations

Considering that the early stages of infection are usually asymptomatic, the diagnosis of liver hydatid cyst may often be incidental, associated with an abdominal ultrasonography performed for other clinical reasons. In endemic areas, the presence of symptoms suggestive of hydatid liver cyst in a person with a history of exposure to sheep and dogs supports the suspicion of hydatidosis.

The definitive diagnosis of liver echinococcosis requires a combination of imaging, serologic, and immunologic studies.

Routine laboratory tests are rarely abnormal occasionally eosinophilia may be present in the presence of cyst leakage, or may be normal. Serum alkaline phosphatase levels are raised in one third of patients

### 6.2.1. Serology and immunological tests.

Serological tests detect specific antibodies to the parasite and are the most commonly employed tools to diagnose past and recent infection with *E. granulosus*. Detection of IgG antibodies implies exposure to the parasite, while in active infection high titers of specific IgM and IgA antibodies are observed. Detection of circulating hydatid antigen in the serum is of use in monitoring after surgery and pharmacotherapy and in prognosis. ELISA is used most commonly, but alternate techniques are counter-immuno-electrophoresis and bacterial co-agglutination.

Elisa techniques have a high sensitivity above 90% and are useful in mass scale screening. The counter-immuno-electrophoresis has the highest specificity (100%) and high sensitivity

(80 – 90%). CASONI TEST has been used most frequently in the past but is at present considered only of historical importance and has largely been abandoned because of low sensitivity.

Tests of humoral immunity are still widely used to confirm the diagnosis. The sensitivity and specificity of any humoral test depends largely on the quality of the antigens utilised.

Antigens can be derived from the whole parasites or organelles, or soluble antigens from cyst fluid. Indirect immunofluorescence assay (IFA) is the most sensitive test (95%) in patients with hepatic CHD.

The sensitivity and specificity of enzyme-linked immunosorbent assay (ELISA) is highly dependent on the method of antigen preparation, and cross-reactions with other helminthic diseases occur if crude antigens are used. Purified fractions may yield high sensitivities (95%) and specificity (100%).[1,3,21]

### 6.2.2. *Imaging techniques*

Imaging modalities range from simple to complex and invasive. Ultrasonography (US) is the screening method of choice.

CT scan is an important preoperative diagnostic tool to determine vascular, biliary or extra hepatic extension, to recognize complications, such as rupture and infections, and therefore to assess respectability[22-28]

However, diagnostic tests such as CT and MRI are mandatory in liver hydatidosis because they allow thorough knowledge regarding lesion size, location, and relations to intrahepatic vascular and biliary structures, providing useful information for effective treatment and decrease in post-operative morbidity

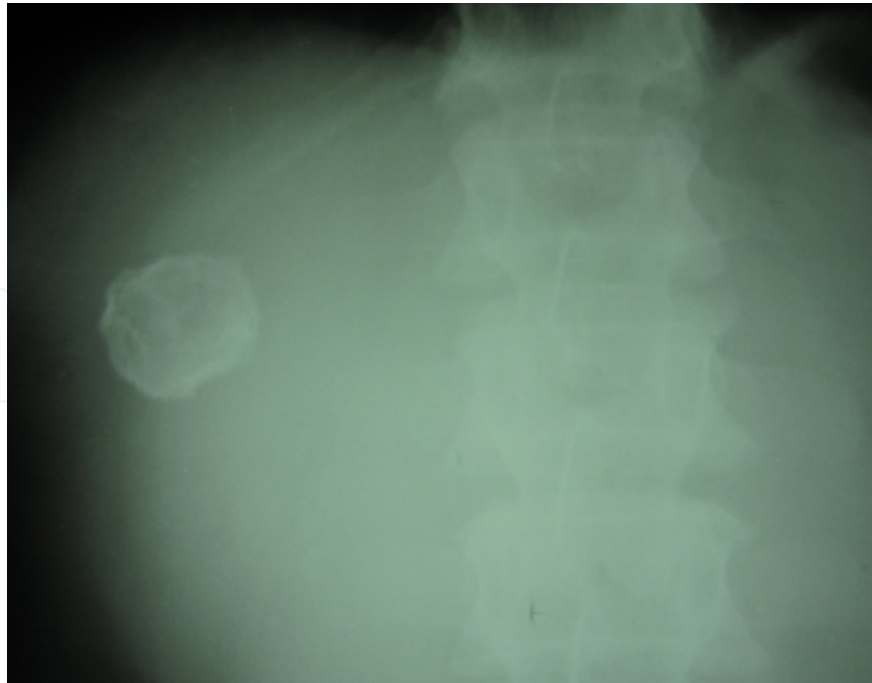The right lobe is the most frequently involved portion of the liver. Imaging findings in hepatic hydatid disease depend on the stage of cyst growth (whether the cyst is unilocular, contains daughter vesicles, contains daughter cysts, is partially calcified, or is completely calcified).

#### *Plain Radiographs*

Plain radiographs of the abdomen and chest may reveal a thin rim of calcification delineating a cyst, or an elevated hemi diaphragm. Both signs are non-specific.

Calcification is seen at radiography in 20%–30% of hydatid cysts and usually manifests with a curvilinear or ringlike pattern representing calcification of the pericyst. During the natural evolution toward healing, dense calcification of all components of the cyst takes place. Although the death of the parasite is not necessarily indicated by calcification of the pericyst, it is implied by a complete calcification (Figure 18)





**Figure 18.** Plain radiograph of the abdomen showing a complete calcification of the cyst

### *Ultrasonography (US)*

Ultrasonography is the screening method of choice. It is currently the primary diagnostic technique and has diagnostic accuracy of 90%. Findings usually seen are:

**Solitary Cyst** – anechoic univesicular cyst with well defined borders and enhancement of back wall echoes in a manner similar to simple or congenital cysts. Features are suggesting hydatid aetiology include dependent debris (hydatid sand) moving freely with change in position; presence of wall calcification or localized thickening in the wall corresponding to early daughter cysts.

Separation of membranes (ultrasonic water lily sign) due to collapse of germinal layer seen as an undulating linear collection of echoes.

**Daughter cysts** - probably the most characteristic sign with cysts within a cyst, producing a cartwheel or honeycomb cyst.

**Multiple cysts** with normal intervening parenchyma (differential diagnosis are necrotic secondaries, Polycystic liver disease, abscess, chronic hematoma and biliary cysts).

**Complications** may be evident such as echogenic cyst in infection or signs of biliary obstruction (dilated bile ducts with some images corresponding to hyperechoic vesicles or hydatid membranes within the biliary tract) usually implying a biliary communication.

Doppler ultrasonography is indicated to show the reports of hydatid cyst with vascular axes (portal vein, hepatic veins, and inferior vena cava).

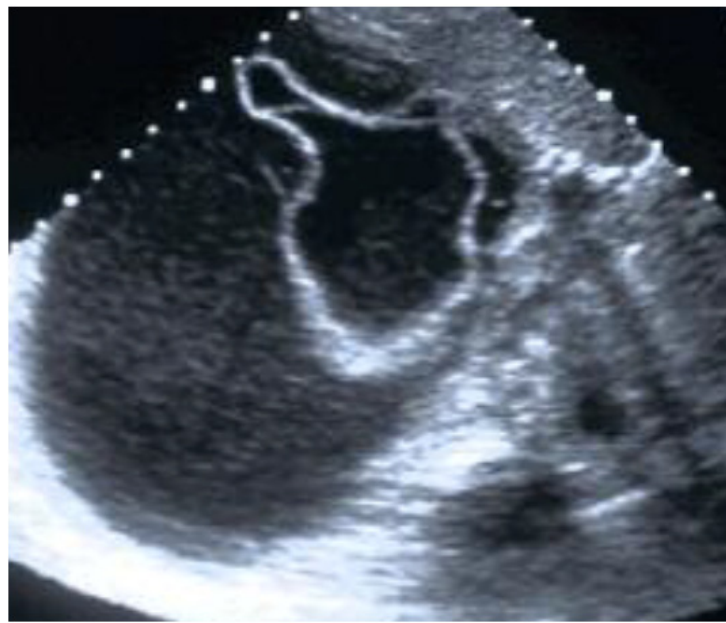However, in the types I and IV, we have to consider differential diagnosis.

Gharbi Classification on Ultrasonography features of Hydatid Cyst [23] ,( Figure 19-20)

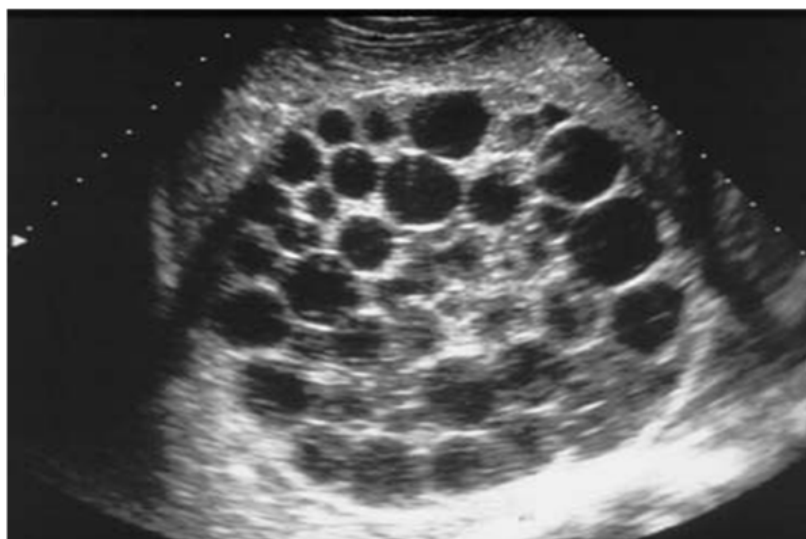
Type	Ultrasound Appearance
I	Pure fluid Collection
II	Fluid collection with a split wall ( <b>detached membrane</b> )
III	Fluid collection with septa <b>and/or daughter cysts</b>
IV	Heterogeneous echo pattern ( <b>Hyperechoic with high internal echoes</b> )
V	Reflecting walls (Cyst with reflecting calcified thick wall)

Type V cysts determined by ultrasound to be calcified and have been assumed to be dead cysts and do not require surgery.

Intra-operative Ultrasonography is an important investigation during surgery for hydatid cyst of the liver.



**Figure 19.** Ultrasonography of Hydatid cyst of the liver type II ( Gharbi)



**Figure 20.** Ultrasonography of Hydatid cyst of the liver Type III ( Gharbi)

Different classifications of Ultrasonography have been described in the literature [24-25].

WHO introduced a standardized classification of Ultrasonography images of cystic echinococcosis, to obtain comparable results in patients worldwide and to link disease status with each morphological type of Hydatid cysts (Table 1).

<b>CL Active;</b> <i>Single cysts. Cysts are developing and are fertile. Cyst wall not visible.</i>
<b>CE1 Active;</b> <i>simple cyst often full of hydatid sand (snow flake sign). Visible cyst wall. Fertile.</i>
<b>CE2 Active;</b> <i>multiple, or multi loculated cysts. May appear honeycomb like with daughter cysts. Fertile.</i>
<b>CE3 Transition;</b> <i>degenerating cysts but still contain viable protoscoleces. Often see floating membranes in fluid filled cysts</i>
<b>CE4 Inactive;</b> <i>degeneration is advanced. Cysts may be calcified. Not likely to be fertile. Heterogeneous appearance with few or no daughter cysts.</i>
<b>CE5 Inactive. Often calcified. Usually infertile.</b>

(Modified from the WHO classification). Ref [www.who.int/emc-documents/zoonoses/docs/whocdscsgraph20016.pdf](http://www.who.int/emc-documents/zoonoses/docs/whocdscsgraph20016.pdf).

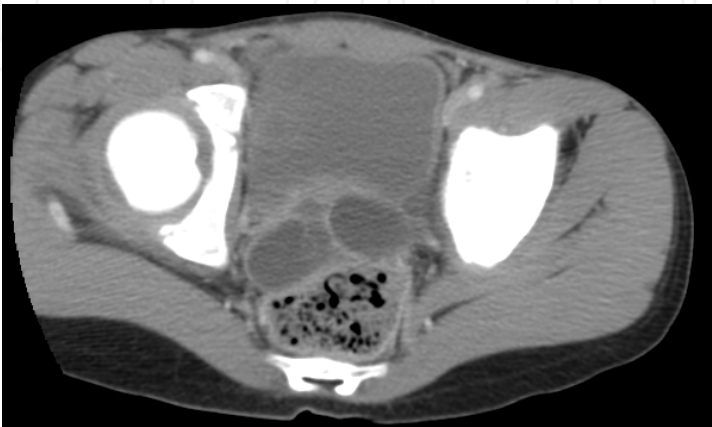
**Table 1.** Classification of hydatid cysts based on the ultrasound appearance.[in 24]

*Computed Tomographic scan*

Multi detector row computed tomography has the highest sensitivity of imaging of the cyst (100%). It is the best mode to detect the number, size, and location, of the cysts. It may provide clues to presence of complications such as infection, and intrabiliary ruptures. CT features include sharply margined single or multiple rounded cysts of fluid density (3 – 30 Hounsfield units) with a thin dense rim. [26-28]

It is also helpful in identifying exogenous cysts, and the volume of the cyst can be estimated. CT is an important investigation when there is a diagnostic uncertainty on ultrasound (Type I and IV of Gharbi), when planning surgical intervention or when recurrent disease is diagnosed. In case of peritoneal hydatidosis, CT scan is indicated before surgery to assess the number and the exact localisations of the cysts. (Figure 21-24)

In case of ruptures in the thorax, the CT-scan allows a better study of the lung parenchyma and ensures a percutaneous drainage of the pleural collection.



**Figure 21.** Scan showing a peritoneal hydatidosis



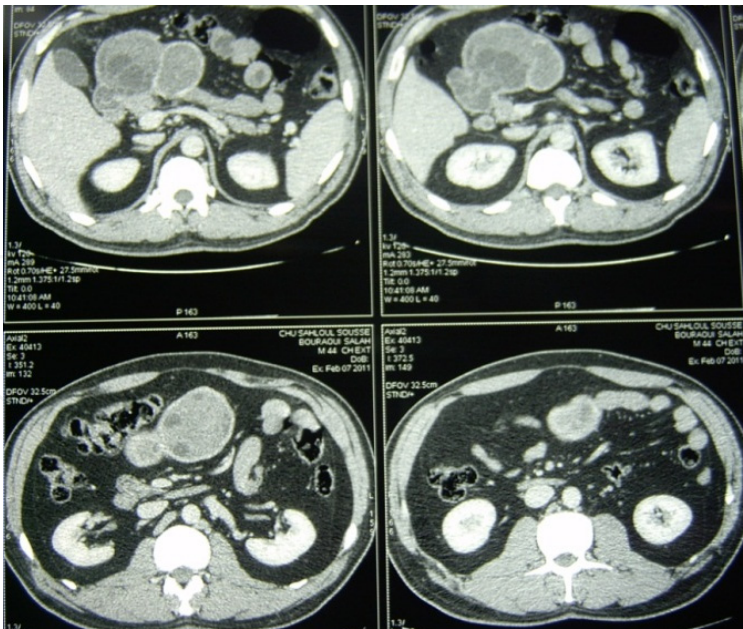


Figure 22. CT- scan of the abdomen showing multiple intra peritoneal hydatid cysts

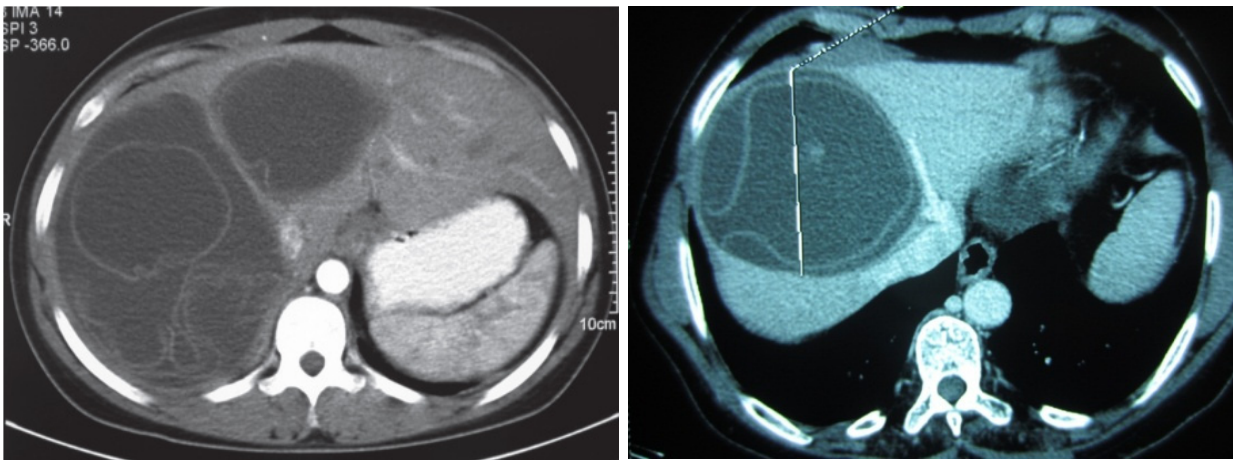


Figure 23. Scan showing typical type II cyst in right lobe of liver.

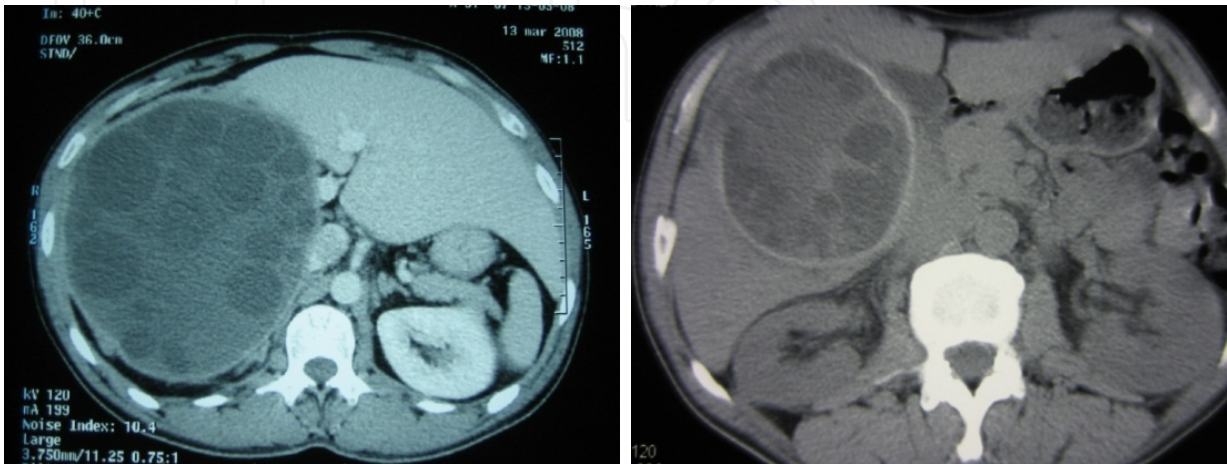


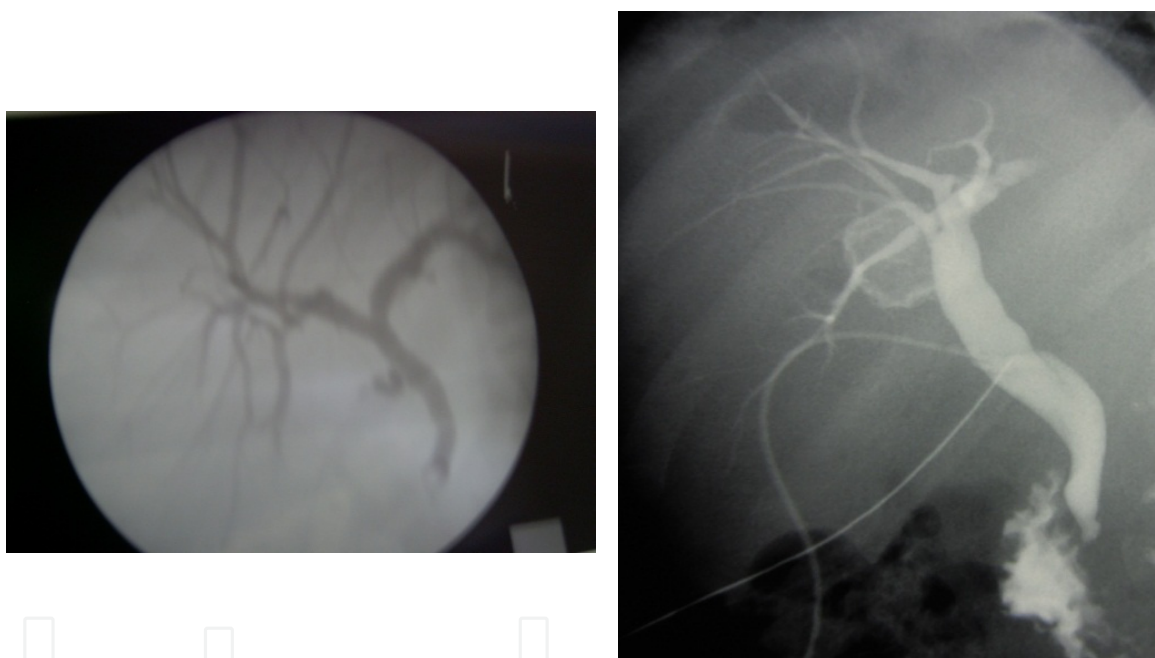
Figure 24. CT scan showing typical type III cyst in right lobe of liver.



**Magnetic resonance Imaging (MRI scan)** - MRI delineates the cyst capsule better than CT scan, as a low intensity on both T1 and T2 weighted images. However, CT scan is better in demonstrating mural calcifications, cysts less than 3 cm may not show any specific features and small peritoneal cysts may be missed. Magnetic resonance imaging (MRI) adds little to CT scanning. In the routine, this investigation is rarely required as a diagnostic tool for liver hydatidosis.[22,30, 32]

**Endoscopic retrograde cholangiopancreatography (ERCP)** remains an important tool in cases where a rupture into the biliary tree has occurred, allowing both the diagnosis of major biliary communication and clearance of the common bile duct (CBD) prior to surgery or intervention by the means of sphincterotomy [34]

**Direct cholangiography:** intra-operative cholangiography is performed through a cystic drain or a T-Tube in a suspected intrabiliary rupture and bile duct obstruction. This method is used to detect post-operative complications following surgery. (**Figure 25**)



**Figure 25.** Intra-operative cholangiography showing a daughter cyst in the CBD (A)- post - operative cholangiography (B)

## 7. Treatment

### 7.1. General considerations

Surgery remains the gold standard treatment for hydatid liver disease. The aim of surgical intervention is to inactivate the parasite, to evacuate the cyst along with resection of the germinal layer, to prevent peritoneal spillage of scolices and to obliterate the residual cavity. It can be performed successfully in up to 90% of patients if a cyst does not have a risky localisation. However, surgery may be impractical in patients with multiple cysts localised in several organs and if surgical facilities are inadequate. The introduction of chemotherapy and of the PAIR

technique (puncture - aspiration - injection - respiration) offers an alternative treatment, especially in inoperable patients and for cases with a high surgical risk. Cysts with homogeneously calcified cyst walls need, probably, no surgery but only a 'wait and observe' approach.

The choice of an optimal treatment should be carefully assessed in each case.[33-34]

The principles of hydatid surgery are

Total removal of all infective components of the cysts;  
the avoidance of spillage of cyst contents at time of surgery;  
management of communication between cyst and adjacent structures;  
management of the residual cavity;  
Minimize risks of operation.

All the surgical procedures can be divided into two large groups, a conservative group and a radical one. The conservative technique communication between cyst and adjacent structures;

## 7.2. The conservative technique

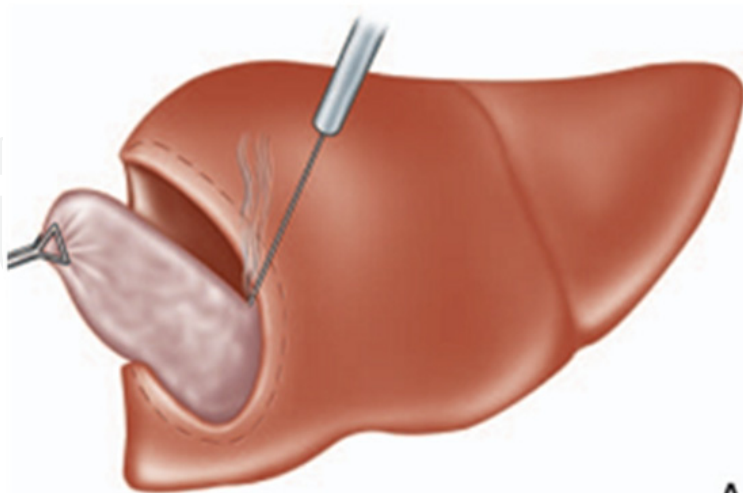
Conservative procedures are safe and technically simple, and are useful in the management of uncomplicated hydatid cysts. Marsupialization was the most common used procedure because it is quick and safe. However, their main disadvantage is the high frequency of postoperative complications, the most common being bile leak from a cyst-biliary communication, bilomas and bile peritonitis (4%-28%).

## 7.3. Radical surgical procedures

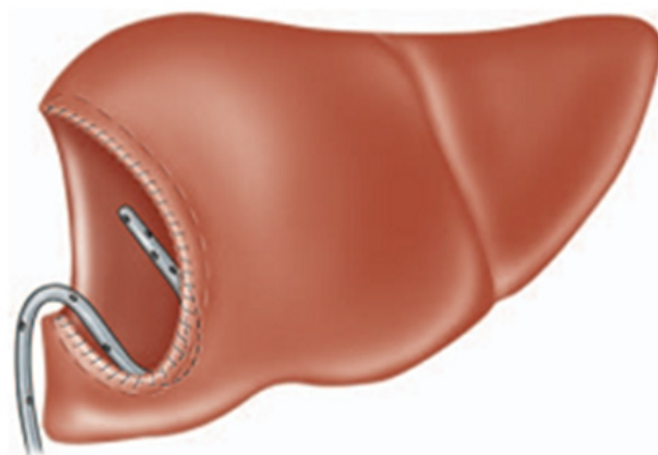
Radical surgical procedures include cystectomy, pericystectomy, lobectomy and hepatectomy. Radical procedures have lower rate of complications and recurrences but many authors consider them inappropriate, claiming that intraoperative risks are too high for a benign disease. [35-39]

- a. **Cystectomy** –. The procedure involves removal of hydatid cyst, comprising laminar layer, germinal layer and cyst contents (daughter cysts and brood capsules). The procedure is simple to perform and has low recurrence rates.( Figure 26-29)  
The management of the residual cavity is a challenging problem especially in patients with giant hydatid Cysts. Various techniques have been described for the management of residual cavities, such as; external drainage, Capitonnage and omentoplasty
- b. **Pericystectomy** – this procedure involves a non-anatomical resection of cyst and surrounding compressed liver tissue. This is technically a more difficult procedure than cystectomy and can be associated with considerable blood loss; it can also be hazardous in the case of large and complicated cysts when the cyst distorts vital anatomical structures such as; hepatic veins or biliary ducts. (Figure.30-31)
- c. **Hepatic resections** – The arguments against hepatic resection as a primary modality of treatment are :firstly, outside of the dedicated liver units there is considerable

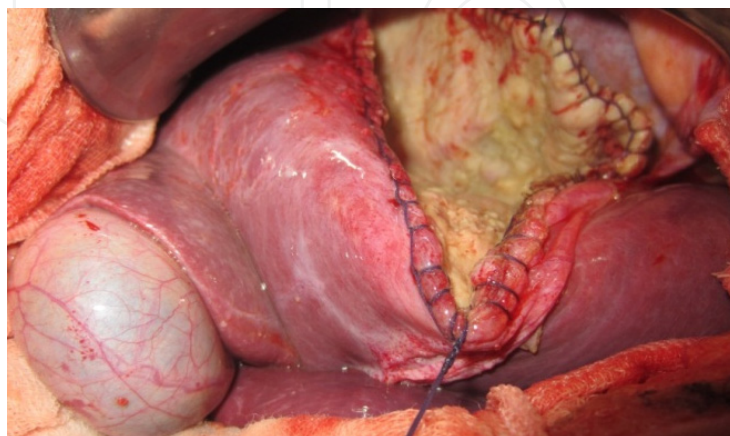
morbidity and mortality from resection of what is essentially a benign condition .What is more, the distortion of the anatomy makes surgery harder.



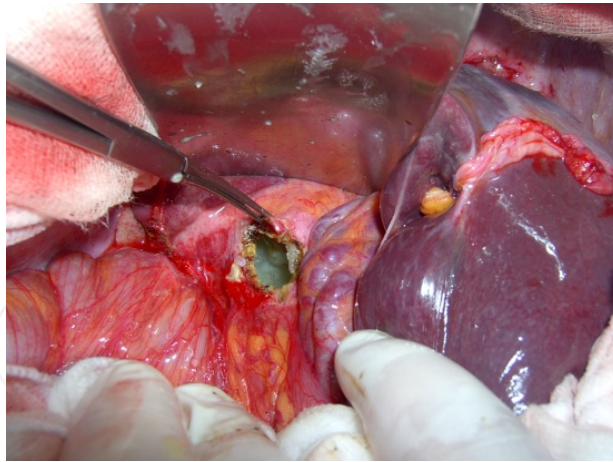
**Figure 26.** Radical surgery: partial cystectomy [in 55]



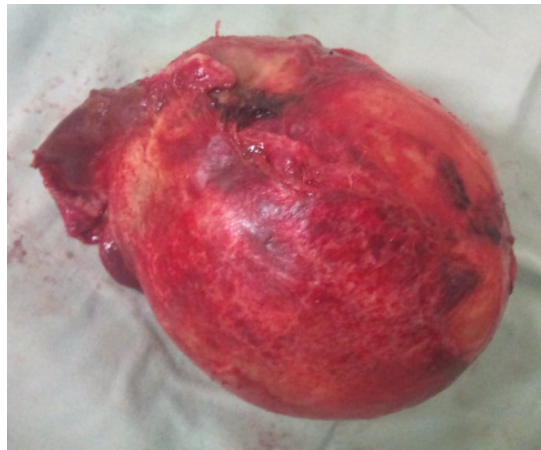
**Figure 27.** Drainage of the residual cavity after partial cystectomy [in 55]



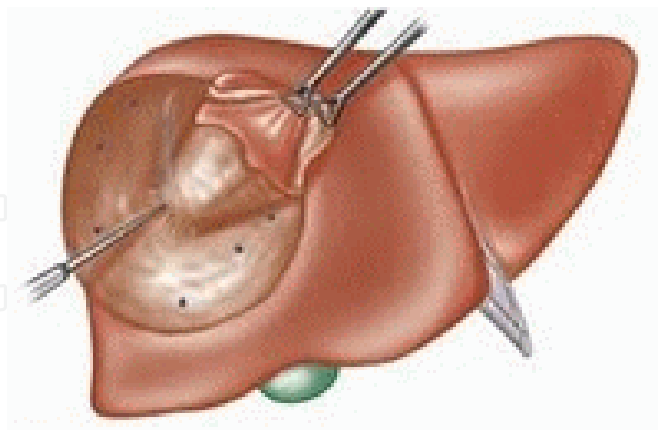
**Figure 28.** A 34- year- old patient operated for hydatid cyst of segment VIII. Partial cystectomy and capitonnage



**Figure 29.** Hydatid cyst of liver with portal hypertension: partial cystectomy



**Figure 30.** Total pericystectomy for a hydatid cyst the lower surface of the right hepatic lobe.



**Figure 31.** Technique of the pericystectomy in [34]

#### 7.4. Laparoscopic management of hydatid cysts

The rapid development of laparoscopic techniques has encouraged surgeons to replicate principles of conventional hydatid surgery using a minimally invasive approach. Several reports have confirmed the feasibility of laparoscopic hepatic hydatid surgery [40-42]



A special instrument has been developed for the removal of the hydatid cyst with the laparoscope called the perforator-grinder-aspirator apparatus. Different instruments have been described to try to avoid leakage of daughter cysts and scolices.

Laparoscopic has some advantages compared to open surgery. In fact this approach to liver hydatid cyst offers a lower morbidity outcome and a shorter hospital stay and it is also associated with a faster surgery. In addition to that advantage, Laparoscopic procedure gives a better visual control of the cyst cavity under magnification which allows a better detection of biliary fistula. This approach is possible only in selected cases.

The Criteria to exclude laparoscopic treatment of hydatid cyst of liver are

Rupture of the cyst in biliary tract

Central localization of the cyst

Cysts dimension > 15 cm

Number of cysts > 3

Thickened or calcified walls

opening of bile ducts that leak bile

Nevertheless, a disadvantage of laparoscopy is the lack of precautionary measures to prevent spillage under the high intraabdominal pressures caused by pneumoperitoneum, allergic reactions are more common in laparoscopic interventions due to peritoneal spillage, though the length of stay is generally shorter and morbidity rates are lower in comparison with open procedures. [40]

Laparoscopic experience has shown that spillage of scolices-rich cyst fluid or daughter cysts is common, and it is difficult to evacuate the cysts without spillage in the absence of the proven techniques available to open surgery [41-42 ].

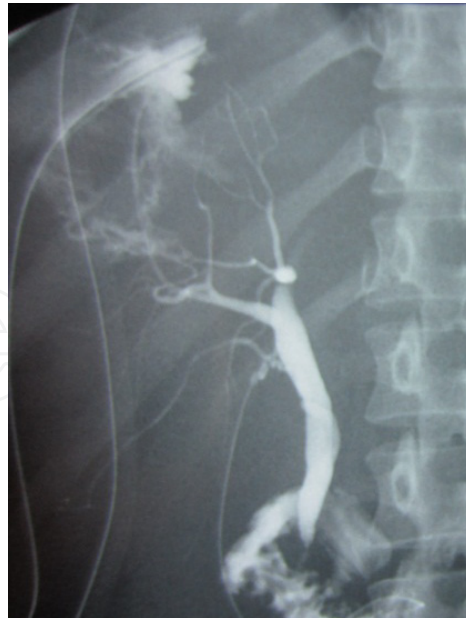Spillage may lead to peritoneal hydatidosis

## 7.5. Complications of surgery

1. Morbidity: Biliary leakage is the most frequent postoperative complication following surgery for hydatid cysts of liver. The rate varies between 6% and 28%. Although most of the external biliary fistulas close spontaneously, they may be persistent in 4%-27.5% of the cases.(figure 32)

Endoscopic sphincterotomy is performed after a 3-week waiting period in patients with low-flow fistulas or can be performed earlier in patients with high-flow fistulas [43-45]

Some other complications can occur in the post-operative period such as; infection of the residual cavity; which is mainly true for big hydatid cysts, in the hepatic dome and treated by partial cystectomy. This complication is more frequent when the pericyst is thick and calcified. This complication needs in some cases reoperation or percutaneous drainage under CT-scan guidance. For this reason, some authors recommend this type of cysts, a total pericystectomy.



**Figure 32.** Post-operative cholangiography showing a cysto-biliary fistula

2. Mortality: The surgical management of hydatid disease of liver carries a mortality rate of 0.9 to 3.6 %.
3. Recurrence rate varies with type of surgery; it is estimated up to 11.3 % within 5 years.

### 7.6. Percutaneous treatment of hydatid cyst

PAIR (puncture, aspiration, injection, and reaspiration) is a percutaneous treatment technique for hydatid disease. This technique was proposed in 1986 by the Tunisian team that first used it in a prospective study [48]. In this minimally invasive method, a needle is introduced into the cyst under ultrasound guidance.

Since that time, its use in the treatment of hydatid cysts has been somewhat controversial [46-50]. However, as this technique has become more common and its safety and efficacy have been reported in the literature [51-56], it has been increasingly accepted as a treatment option for hydatid disease. The World Health Organization currently supports PAIR as an effective alternative to surgery, although its use is limited.

The World Health Organization guidelines for indications and contraindications of PAIR are as follows:[54]

#### 1. Indications for PAIR

- Nonechoic lesion greater than or equal to 5 cm in diameter
- Cysts with daughter cysts and/or with membrane detachment
- Multiple cysts if accessible to puncture
- Infected cysts
- Patients who refuse surgery.
- Patients who relapse after surgery.
- Patients in whom surgery is contraindicated

Patients who fail to respond to chemotherapy alone

Children over 3 years.

Pregnant women

## 2. Contraindications for PAIR

Non cooperative patients

Inaccessible or risky location of the liver cyst

Cyst in spine, brain, and/or heart

Inactive or calcified lesion

Cyst communicating with the biliary tree

Patients should be followed clinically after PAIR treatment. Recurrence is increased in more complicated cysts, including those with multiple daughter cysts.

PAIR should only be performed in highly specialized centers with appropriately trained and experienced staff. In addition, an anaesthesiologist should be present for monitoring and treatment in case of anaphylactic shock. Surgeons should be notified immediately in case of complication.[46-57]

Punctures of hydatid cysts have been discouraged in the past due to the potential risk of Anaphylactic shock and peritoneal dissemination. However, in the recent years percutaneous drainage has been used successfully to treat the hepatic hydatid cysts. Khuroo et al [50] reported 88% disappearance of cysts with percutaneous drainage which was preceded by Albendazole therapy (10 mg/kg body weight) for 8 weeks. In his study, he showed that the efficacy of percutaneous drainage is similar to that of standard treatment with cystectomy, in terms of reducing the size of the cyst and causing its disappearance over a period of up to two years. The advantages of percutaneous drainage include a shorter hospital stay and a lower complication rate.

## 7.7. Endoscopic management of hydatid cyst

The ERCP is effective in diagnosing biliary tree involvement from the cyst.

The Endoscopic management is useful in presence of intrabiliary rupture, which requires exploration and drainage of the biliary tract and also after surgery in presence of residual hydatid material (membranes and daughter cyst) left in biliary tree. During the endoscopic exploration the biliary tree is cleared of any hydatid material with a balloon catheter or a dormia basket. The endoscopic sphincterotomy is also performed to facilitate drainage of the common bile duct. [44-45]

## 7.8. Chemotherapy for hydatid disease of liver

Medical treatment of hydatid liver cysts, primarily induced in the 1970's, is based on benzoimidazole carbamates, such as mebendazole and albendazole. It has been proposed that these agents contribute to clinical improvement of the disease by diminishing the size of the cyst. The factors for success seem to be the ability of the drug to penetrate the cyst wall

and the persistence of adequate levels of the active metabolites. Albendazole seems to be more effective owing to better penetration and absorption.[58] These agents have actually been used in several studies as a conservative treatment, leading to some decrease or stabilization of the cyst size, especially in cases with small cysts.[58-59] However, their clinical efficacy still remains doubtful. They are used mainly for disseminated systemic disease, inoperable cases, and—combined with surgery—to prevent postoperative recurrence. Side effects of Albendazole therapy are: mild abdominal pain, nausea, vomiting, pruritis, dizziness, alopecia, rash and headaches. Occasionally, leucopenia, eosinophilia, icterus, and mild elevation in transaminase levels are seen.

The different schedules for the treatment are:

1. Inoperable cases - as primary treatment - 3 cycles
2. Pre-operatively – to reduce the risk of recurrence 6 weeks continuous treatment
3. Post-operatively to prevent recurrence in cases of intraoperative cyst spillage 3 cycles.

In a review by Dziri et al. [60], the authors sought to provide evidence-based answers to the following questions:

- Should chemotherapy be used alone or in association with surgery?
- What is the best surgical technique?
- When are the percutaneous aspiration, injection, and reaspiration technique indicated?

The results showed that chemotherapy is not the ideal treatment for uncomplicated hydatid liver cyst when used alone, and the level of evidence was too low to help in choosing between radical or conservative treatment. Percutaneous drainage plus albendazole proved to be safe and effective in selected patients [38].

## 7.9. Treatment of hydatid cysts rupture into the biliary tracts

There are two different clinical settings associated with intrabiliary rupture: frank intrabiliary rupture and simple communication. In the former, the cyst content drains to biliary tract and causes cholestatic jaundice. In the latter simple communications are frequently overlooked and could cause post-operative biliary fistulae [37-39]. If the cystobiliary opening was less than 5 mm, spontaneous drainage of the cystic content was uncommon and could be treated by suturing under the direct vision. If the CBD diameter was larger than 5 mm, cystic content migration into the biliary tract would occur in 65% of the cases. Vesicles, debris and purulent materials may be found in the biliary ducts. Surgery must be done early. Delay can cause suppurative cholangitis, septicemia and liver abscess formation. The orifice of bile leakage could be seen in 11.7-17.07% of the cases during the operation while this was difficult in posteriorly localized cysts. In these cases, cholangiography could be done by a catheter pushed into the ductus cysticus or the cystobiliary fistula<sup>1</sup>. The injection of radioopaque solution or methylene blue is helpful to diagnose intrabiliary rupture or to see the orifice

Once the Intraoperative cholangiography is performed, biliary communications with the cyst are identified and meticulously sutured. A supraduodenal choledochostomy is made

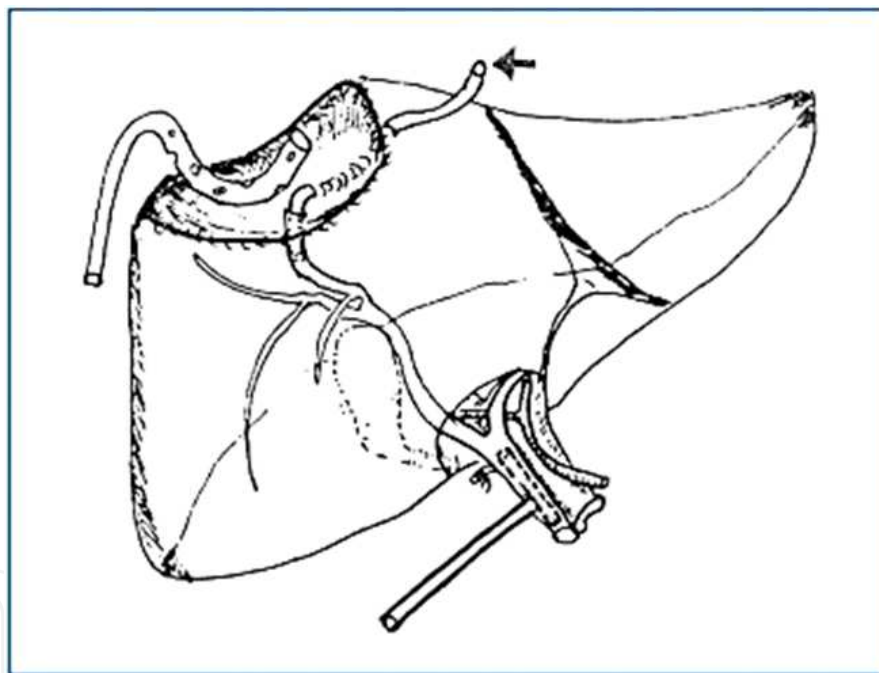


and bile duct cleared by all membranes and debris with the help of choledoscope. The choledochostomy is closed over a T-tube.

The treatment of the cysto-biliary communication is based on several techniques [5,6, 34, 38].

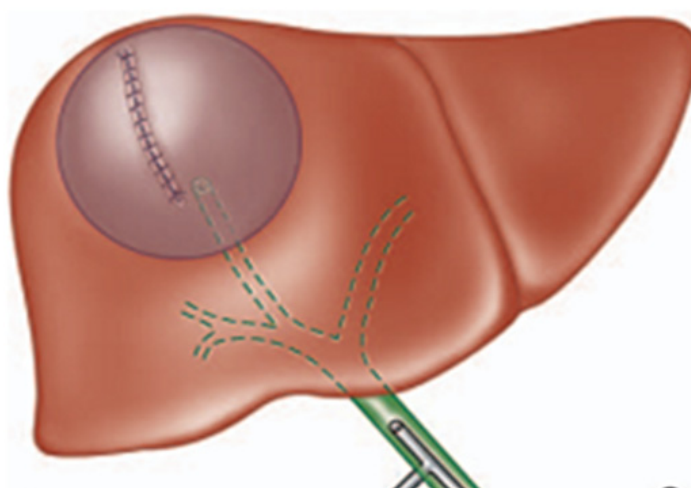
- a. **Direct suture:** small cysto-biliary fistula could be sutured using a resorbable material. This technique could be performed when it is a small fistula
- b. **Repair using a T-Tube:** This method allows to restore canal continuity and to drain the hepatic territory of upstream. The T-Tube is kept 4 at 6 weeks and is withdrawn only after cholangiography.
- c. **Other techniques:** When a complete pericystectomy is not realizable under good conditions, 2 other techniques of treatment of cysto-biliary communication could be performed:

The transparieto-hepatic fistulization described by Perdromo *et al* [39] which use of a T-tube of which one of the branches is intra-biliary and the other intra-cystic. The T-tube should be kept between 4 and 6 weeks. It could be withdrawn after a cholangiography. (figure 33)

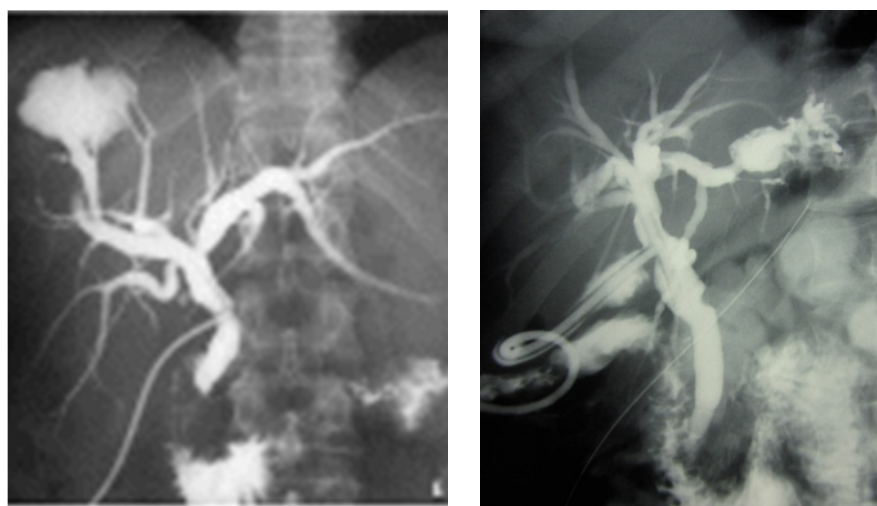

**Figure 33.** Transparieto-hepatic fistulization (perdromo)

The internal drainage technique described by Goinard (figure 34-35). This technique should be performed for central cyst with a large bilio-cystic fistula. In case of a big hydatid cyst, we should perform a partial pericystectomy to reduce the size of the residual cavity. The pericyst is then sutured and a T-tube is inserted in the common bile duct. This drain should be kept between 5 and 8 weeks, and its withdrawal should be performed after a cholangiography. This technique gives good results in case of central cyst with large cysto-biliary fistula in the right and/or left biliary canal. [6,38,39]



**Figure 34.** Internal drainage technique [in 34]



**Figure 35.** Post-operative cholangiography in a patient treated for hydatid cyst with large bilio-cystic fistula treated with partial cystectomy and internal drainage

## 8. Conclusion

Hydatid disease remains a continuous public health problem in endemic countries. The liver is the most common site for hydatid disease (75% of cases), followed by the lungs (15%), the spleen (5%), and other organs (5%).

Diagnosis of liver hydatid disease is made with Ultrasonography and computed tomography. Surgery combined with medical treatment by albendazole is effective in the eradication of hepatic hydatid disease and in the prevention of local recurrences.

Although surgery is the recommended treatment for liver hydatid disease, percutaneous treatment has been introduced as an alternative to surgery. PAIR is a valuable alternative to surgery. It is safe and efficient in selected patients

## Author details

Fethi Derbel, Mohamed Ben Mabrouk, Mehdi Ben Hadj Hamida, Jaafar Mazhoud, Sabri Youssef, Ali Ben Ali and Ridha Ben Hadj Hamida

*Department of Surgery, Sahloul Hospital, Sousse, Tunisia*

Hela Jemni, Nadia Mama, Hasni Ibtissem, Arifa Nadia and Chedia El Ouni

*Department of Medical Imaging, Sahloul Hospital, Sousse, Tunisia*

Walid Naija

*Department of Anesthesiology and Intensive Care, Sahloul Hospital, Sousse, Tunisia*

Moncef Mokni

*Department of Pathology, Farhat Hached Hospital, Sousse, Tunisia*

## Acknowledgement

We thank Professor Jemni Hela, Ibtissem Hasni and Kalthoum Graiess Tlili for their help in the selection and interpretation of the CT-scan and ultrasound and Dr Jaafar Mazhoud and Dr Mohamed Ben Mabrouk for their great help in collecting the operations view.

A special thank to Mr Bouraoui Chelly for his great help in the critical reading of the manuscript.

## 9. References

- [1] Moro P., Schantz PM. - Echinococcosis: a review- International Journal of Infectious Diseases (2009) 13, 125–133
- [2] Nunnari G., Pinzone M R., Gruttadauria S., et al. Hepatic echinococcosis: Clinical and therapeutic aspects. *World J Gastroenterol* 2012; 18(13): 1448-1458
- [3] Khanfar N. Hydatid disease: a review and update. *Current Anaesthesia & Critical Care* (2004) 15, 173–183
- [4] Eckert J., Deplazes P. Biological, Epidemiological, and Clinical Aspects of Echinococcosis, a Zoonosis of Increasing Concern. *Clin Microbiol Rev.* 2004; 17(1): 107–135.
- [5] Paksoy M, Karahasanoglu T, Carkman S, Giray S, Senturk H, Ozcelik F, et al. Rupture of the hydatid disease of the liver into the biliary tracts. *Dig Surg* 1998;15:25–9.
- [6] A Zaouche, K Haouet . Management of liver hydatid cysts with a large biliocystic fistula: multicenter retrospective study. *Tunisian Surgical Association. World J Surg* 2001 Janv, 25(1): 28-39.
- [7] Gharbi HA., Mnif J., Ben Abdallah M., Abdelmoula M., Hammou-Jeddi A. Epidemiology of hydatid cyst in Tunisia. Results of investigation by abdominal echography on 3116 inhabitants of Menzel Bourguiba area. *Médecine et Maladies Infectieuses*- 1986; 16(3): 151–156

- [8] Sakhri J., Ben Ali A., Letaief R., Derbel F., Dahmen Y., Ben Hadj Hmida R. Les kystes hydatiques du foie rompus dans le thorax: Aspects diagnostiques et thérapeutiques. *J Chir (Paris)* 1996;133:437-441
- [9] Kilani T., Daoues A., Horchani H., Sellami M. Place de la thoracotomie dans les complications thoraciques des Kystes hydatiques du foie. *Ann Chir Thorac Cardiovasc.* 1991 ;45 :705-710.
- [10] Caporale A., Frittelli P., Della Casa U., et al. Surgical treatment of hydatid cysts of the hepatic dome ruptured into the thoracic cavity. *G Chir* 1990;11:23-28
- [11] Bel Haj Salah R. , Triki W., Bourguiba MB., Ben Moussa M., Zaouche A. Rupture aiguë d'un kyste hydatique foie dans la plèvre droite À propos de deux observations. *Chirurgie thoracique et cardiovasculaire* - 2011 ; 15(3) : 182-184
- [12] Sakhri J, Letaief R, Ben ali A, Derbel F, Ben Hadj Hmida R. Les kystes hydatiques du foie rompus dans le thorax : Quelle voie d'abord choisir ? *Ann Chir* 1996;50: 284.
- [13] Larbi N, Hedfi S, Selmi M, Ben Salah K. La rupture aigue du kyste hydatique du foie dans le péritoine. *Ann Chir* 2002 ;127:487-488
- [14] Kemal Karakaya. Spontaneous rupture of a hepatic hydatid cyst into the peritoneum causing only mild abdominal pain: A case report. *World J Gastroenterol* February 7, 2007; 13( 5)
- [15] Anadi Nath Acharya, Shahana Gupta. Peritoneal hydatidosis: A review of seven cases. *Tropical Gastroenterology* 2009;30(1):32–34
- [16] İlhan Çiftçi, Hüseyin Yılmaz. Hepatic Hydatid Cyst and Intraperitoneal Free Hydatid Cyst. *Eur J Gen Med* 2012;9 (Suppl 1):50-52
- [17] Khila M, Allegue M, Abdesslam M et al. Fistule cutanéokysto-bronchique spontanée d'origine hydatique. *Tunisie Med* 1987; 65:267-270.
- [18] H. Bedioui et al. *Kyste hydatique du foie rompu dans la paroi abdominale : A propos d'une observation rare. Med Trop* 2006; 66 : 488-490
- [19] Khila M, Said R, Katar S et al. La rupture peropératoire spontanée de la veine cave inférieure dans un kyste hydatique du foie. *Tunisie Med* 1985;63:399-402.
- [20] Ali Emre, Orhan Arioğul, Aydin Alper, Attilâ Ökten, Ali Uras, and Süleyman Yalçın . Hydatid Cysts of Liver and Portal Hypertension- HPB Surgery 1990; 2: 129-133
- [21] Wenbao Zhang, Jun Li, Donald P.Mc Manus. Concepts in Immunology and Diagnosis of Hydatid Disease. *Clinical Microbiology Reviews*, 2003,16(1) :18-36,
- [22] Marrone G., Crino F., Caruso S., Mamone G, et al Multidisciplinary imaging of liver hydatidosis. *World J Gastroenterol* 2012; 18(13): 1438-1447
- [23] Gharbi H.A., Hassine W., Brauner M.W., Dupuch K. Ultrasound examination of the hydatid liver. *Radiology*, 1981, 139, 459-463
- [24] WHO Inform working group on Echinococcosis. International classification of ultrasound images in cystic echinococcosis for application in clinical and field epidemiological settings. *Acta Trop* 2003; 85(2): 253–61.
- [25] Caremani M, Lapini L, Caremani D, Occhini U. Sonographic diagnosis of hydatidosis: the sign of the cyst wall. *Eur J Ultrasound* 2003;16(3):217–23.



- [26] Torricelli P, Martinelli C, Biagini R, Ruggieri P, De Cristofaro R. Radiographic and computed tomographic findings in hydatid disease of bone. *Skelet Radiol* 1990;19(6): 435–9.
- [27] Richter J, Hatz C, Haussinger D. Ultrasound in tropical and parasitic diseases. *Lancet* 2003;362(9387):900–2
- [28] Kalinova K. Imaging (ultrasonography, computed tomography) of patients with hydatid liver disease. *Bulgarian Journal of Veterinary Medicine* (2007), 10, No 1, 45–51
- [29] Filippou D, Tselepis D, Filippou G, Papadopoulos V. Advances in liver echinococcosis: diagnosis and treatment. *Clin Gastroenterol Hepatol* 2007; 5: 152-159
- [30] Mortelé KJ, Ros PR. Cystic focal liver lesions in the adult: differential CT and MR imaging features. *Radiographics* 2001; 21: 895-910
- [31] Pedrosa I, Saíz A, Arrazola J, Ferreirós J, Pedrosa CS. Hydatid disease: radiologic and pathologic features and complications. *Radiographics* 2000; 20: 795-817
- [32] Lim JH. Parasitic diseases in the abdomen: imaging findings. *Abdom Imaging* 2008; 33: 130-132
- [33] Magistrelli P, Masetti r, Coppola R, Messia A. Surgical treatment of hydatid disease of liver: a 20 year experience. *Arch Surg* 1991; 126:518–523.
- [34] Zaouche A, Haouet K. Traitement chirurgical des kystes hydatiques du foie. EMC, Techniques chirurgicales, Appareil digestif. Elsevier Masson ; 40-775.
- [35] Balik A. *et al.* Surgical Treatment of Hydatid Disease of the Liver Review of 304 Cases. *Arch Surg.* 1999;134:166-169.
- [36] Giordano G, Angrisano A, Palazzo P. *et al.* Surgical treatment of hydatid cyst of the liver: pericystectomy or resection. Personal experience. *Int J Surg Sci.* 1999;6: 113-7
- [37] M.A. Silva D.F. Mirza S.R. Bramhall A.D. Mayer P. McMaster J.A.C. Buckels. Treatment of Hydatid Disease of the Liver .Evaluation of a UK Experience *Dig Surg* 2004;21:227–234
- [38] Orhan Elbir *et al.* Surgical Treatment of Intrabiliary Rupture of Hydatid Cysts of Liver: Comparison of Choledochoduodenostomy with T-Tube Drainage. *Dig Surg* 2001;18:289–293
- [39] Perdromo R, Morelli R, Carrquiry L, Chifflet J, Berragalli L. Cholédocostomie transhépatocystique en cas de kyste hydatique ouvert dans les voies biliaires. *Presse Med* 1977; 6:747-749.
- [40] Saglam A. Laparoscopic treatment of liver hydatid cysts. *Surg Lap Endosc* 1996; 6:16–21.
- [41] Metin Ertem, Tayfun Karahasanoglu, Nihat Yavuz, Sabri Erguney, Laparoscopically Treated Liver Hydatid Cysts *Arch Surg.* 2002;137:1170-1173
- [42] Hesham Maged Hasan , Osama Mahmoud El-Sayed. Laproscopic treatment of liver hydatid cyst. *Journal of Medicine and Biomedical Sciences*, ISSN: 2078-0273, May, 2010

- [43] Skroubis G, Vagianos C, Polydorou A. *et al.* Significance of bile leaks complicating conservative surgery for liver hydatidosis. *World J Surg.*2002;26:704-8
- [44] Ersan O, Yusuf B. Endoscopic therapy in the management of hepatobiliary hydatid disease. *J Clin Gastrienterol* 2002;35:160-174.
- [45] Saritas U, Parlak E, Akoglu E, Sahin B. Effectiveness of endoscopic treatment modalities in complicated hepatic hydatid disease after surgical intervention. *Endoscopy* 2001;33: 858-863.
- [46] Palez V, Kugler C, Correa D, Carpio MD. PAIR as percutaneous treatment of hydatid liver cysts. *Acta Tropica* 2000; 75:197–202.
- [47] Yaghan R, Heis H, Bani-Hani K, et al. Is fear of anaphylactic shock discouraging surgeons from more widely adopting percutaneous and laparoscopic techniques in the treatment of liver hydatid cyst? *Am J Surg* 2004; 187:533–537
- [48] Ben Amor N, Gargouri M, Gharbi HA, Golvan YJ, Ayachi K, Kchouck H. Trial therapy of inoperable abdominal hydatid cysts by puncture. *Ann Parasitol Hum Comp* 1986; 61:689–692
- [49] Giorgio A, Tarantino L, Francica G, et al. Unilocular hydatid liver cysts: treatment with US guided, double percutaneous aspiration and alcohol injection. *Radiology* 1992; 184:705–710
- [50] Khuroo MS, Wani NA, Javid G, et al. Percutaneous drainage compared with surgery for hepatic hydatid cysts. *N Engl J Med* 1997; 337:881–887
- [51] Kabaalioglu A, Ceken K, Alimoglu E, Apaydin A. Percutaneous imaging-guided treatment of hydatid liver cysts: do long-term results make it a first choice? *Eur J Radiol* 2006; 59:65–73
- [52] Antonio Giorgio, Antonella Di Sarno, Giorgio de Stefano, Giulia Liorre Nunzia, Farella Umberto Scognamiglio, Valentina Giorgio. Sonography and Clinical Outcome of Viable Hydatid Liver Cysts Treated With Double Percutaneous Aspiration and Ethanol Injection as First-Line Therapy: Efficacy and Long-Term Follow-Up- *AJR* 2009; 193:186–192
- [53] V. Pelaez , C. Kugler, D. Correa, M. Del Carpio, M. Guangirolì, J. Molina, B. Marcos, E. Lopez. PAIR as percutaneous treatment of hydatid liver cysts. *Acta Tropica* 75 (2000) 197–202
- [54] PAIR: Puncture, Aspiration, Injection, Re-Aspiration- An option for the treatment of Cystic Echinococcosis World Health Organization. WHO/CDS/CSR/APH/2001.6
- [55] Sakhri J., Ben Ali A. Le kyste hydatique du foie. *J. Chir* 2004,141(6 ), 381-9
- [56] Ben Amor N, Gargouri M, Gharbi HA, Golvan YJ, Ayachi K, Kchouk KH.. Essai de traitement par ponction des kystes hydatiques abdominaux inopérables. *Ann Parasitol Hum Comp*, 1986; 61: 689-692.
- [57] Ben Amor N, Gargouri M, Gharbi HA, Golvan YJ, Ayachi K, Kcouck H. Percutaneous treatment of hydatid cysts under sonographic guidance. *Digestive Diseases and Sciences*, 1994; 39: 1576-1580.
- [58] Aktan AO, Yalin R. Preoperative albendazole treatment for liver hydatid disease decreases the viability of the cyst. *Eur J Gastroenterol Hepatol.* 1996;8:877-879.

- [59] Blanton RE, Wachira TM, Zeyhle EE, Njoroge EM, Magambo JK, Schantz PM. Oxfendazole treatment for cystic hydatid disease in naturally infected animals. *Antimicrob Agents Chemother*. 1998;42:601-605.
- [60] Dziri C, Haouet K, Fingerhut A. Treatment of hydatid cyst of the liver: where is the evidence? *World J Surg* 2004; 28:731-736

IntechOpen

IntechOpen