

We are IntechOpen, the world's leading publisher of Open Access books Built by scientists, for scientists

6,900

Open access books available

185,000

International authors and editors

200M

Downloads

Our authors are among the

154

Countries delivered to

TOP 1%

most cited scientists

12.2%

Contributors from top 500 universities



WEB OF SCIENCE™

Selection of our books indexed in the Book Citation Index
in Web of Science™ Core Collection (BKCI)

Interested in publishing with us?
Contact book.department@intechopen.com

Numbers displayed above are based on latest data collected.
For more information visit www.intechopen.com



Utility of Pediatric Flexible Bronchoscopy in the Diagnosis and Treatment of Congenital Airway Malformations in Children

Yong Yin, Shuhua Yuan, Wenwei Zhong and Yu Ding

Department of Respiratory, Shanghai Children's Medical Center

*Affiliated to Shanghai Jiaotong University School of Medicine, Shanghai
China*

1. Introduction

Bronchoscopy is an indispensable tool in the clinical evaluation and management of pediatric airway and lung disease. Common indications for pediatric bronchoscopy are varied and extend over a spectrum of congenital, infectious, structural conditions and diagnostic applications. Indications for flexible bronchoscopy in children include the evaluation of stridor, persistent or recurrent wheezing, chronic cough, hemoptysis, atelectasis, suspected airway foreign body, suspected airway anomaly, tracheoesophageal fistula, vascular ring and pneumonia/lower respiratory tract infection. Of note, congenital airway malformations are of specific clinical concern in children with the potential to present as an acute emergency. Airway malformations can cause recurrent wheezing, respiratory distress with, repeated pneumonia by poor drainage of lung segments or aspiration, and life-threatening airway obstruction. Flexible bronchoscopy plays an important role in the diagnosis, evaluation and management of such congenital lung malformations.

The major advantages of flexible bronchoscopy as compared to rigid bronchoscopy, include smaller external diameter of the new pediatric flexible scopes, the ability to change direction (flex and extend within the airway), fine illumination with fiberoptic technology and airway dynamics evaluation. Bronchoscopy is a minimally invasive and superior technique for directly visualizing and evaluating airway anatomy and mucosa compared with chest radiography, high resolution CT scan and bronchogram. Advances in technology leads to more and more sophisticated interventions and therapeutic options in the field of adult bronchoscopy including airway stenting, balloon dilatation, cryotherapy and endobronchial laser therapy. As the development of experience and expertise in the field of pediatric flexible bronchoscopy in clinic, we hope that the versatility of the flexible bronchoscopy can extend the range of diagnostic and therapeutic interventions in children.

2. Choice of pediatric flexible bronchoscope for neonates and children

The pediatric bronchoscopist should be experienced with expertise in maneuvering the bronchoscope deftly and safely in the pediatric airway. The bronchoscopist should also have a thorough understanding of bronchoscope structure, functions, and reprocessing protocols

and adherence to strict infection control precaution both during the procedure, reprocessing and storage of the equipment. This is essential as fiberoptic bronchoscopes are fragile instruments that need careful handling at each step. The pediatric bronchoscopist should also work closely with the anesthesiologist in deciding and developing an appropriate sedation protocol according to the age, underlying medical condition and respiratory status of each child.

Airway size can be largely determined by the age of the patient and the appropriate sized bronchoscope chosen accordingly. Table 1 depicts the different sizes of bronchoscope that can be selected according to the age of the patient.

Particularly in neonates, infants and young children, the smallest sized bronchoscope available should be used, in order to reduce obstruction of the airway lumen by the bronchoscope during the procedure (which would impair ventilation) and to minimize local mucosal trauma.

The flexible bronchoscope with a 3.6 mm external diameter is useful for infants and young children; the bronchoscope with a 4.8mm external diameter can be used in older children. Both bronchoscopes posses a working/suction channel of 1.2 mm diameter sufficient for suctioning and obtaining a diagnostic bronchoalveolar lavage. The smaller bronchoscope with a 2.8 mm external channel is useful to evaluate neonates and small infants in whom congenital airway malformations and abnormal airway anatomy is suspected. The neonatal bronchoscope with 2.2mm external diameter without a suction channel, and can be used for visualization of the airway in neonates, particularly low birth weight infants, and those intubated with endotracheal tubes of 3.0 diameter or less. The quality of images obtained and visualization increases with the increase in diameter (and hence the number of fiberoptic cables) of the flexible bronchoscope.

O.D. mm	Pt/wt (age)	Suction Channel mm	Biopsy	Brush	Picture Clarity	Tool durability	Pass through tube No.	Extra features
2.2	>700g	No	No	-	Fair	Very delicate	>3	Limited use in very small airway
2.8	>1.5kg	1.2	Small	+	Good	Delicate	>4	Useful as has suction channel
3.6	>3kg	1.2	Small	+	Very good	Good	>5	In major use
4.0	>10 kg	2.0	Good	+	Very good	Very good	>5.5	Working channel good for laser and for biopsy

Table 1. Types flexible bronchoscopes in children and characteristic features.

3. Sedation and anesthesia for bronchoscopy in children

Appropriate sedation is important for a well-tolerated bronchoscopic procedure particularly for pediatric patients. Pre-procedure assessment of the child is essential in order to evaluate safety and tolerability of bronchoscopy in addition to anticipating potential difficulties and procedure and anesthesia related complications. Individual pre-

anesthetic assessment should include a comprehensive evaluation of baseline respiratory status and underlying medical conditions. Flexible bronchoscopy can be performed using either conscious sedation or general anesthesia .Various protocols for anesthesia may be used during flexible bronchoscopy in pediatric patients entailing administration of either intravenous drug combination (e.g. midazolam, meperidine, propofol, ketamine, remifentanyl), or inhalational agents (premixed nitrous oxide, sevoflurane). Regardless of the choice of sedation, and it is essential to ensure adequate delivery of oxygen (either by nasal prongs, face mask, laryngeal mask airway or endotracheal intubation). Ideally, allowing the patient to maintain spontaneous ventilation will provide valuable information on airway dynamics which is an advantage as compared to deep anesthesia and paralysis with controlled ventilation as used during rigid bronchoscopy. The most frequent complication of sedation during flexible bronchoscopy is hypoxaemia, either alone or in association with larygospasm and/or bronchospasm. Hypoxemia should be monitored for continuously before, during and after the procedure; and can be secondary to partial or total airway obstruction by the bronchoscope and/or central respiratory depression due to sedation. Pre-operative identification of high-risk patients, administration of appropriate anesthesia individually tailored for each patient and close monitoring are essential for minimizing potential complications and successful completion of the procedure.

4. Applications in the diagnosis of congenital airway malformations

Flexible bronchoscopy enables internal visualization of a child’s airways starting from the external nares, via the pharynx, larynx, trachea and large central airways down to the bronchi limited only by the relative size of the child’s airways and the external diameter of the bronchoscope. Flexible bronchoscopy in a lightly sedated child who is breathing spontaneously, allows assessment of airway dynamics (not provided by rigid bronchoscopy which requires deep sedation and paralysis) which is critical in diagnosing certain airway abnormalities (Table 2). A detailed inspection of dynamics and movements of the glottis, vocal cords and the trachea is invaluable in the systematically evaluating pediatric airway conditions, such as airway collapse caused by tracheomalacia or external compression. Furthermore, bronchoscopy allows direct examination of the internal surface of the airways, their diameter, and characteristics of the tracheal and bronchial mucosa, and respiratory tract secretions.

Laryngomalacia	Tracheal Cartilaginous Sleeve
Vocal Cord Paralysis	Complete Tracheal Rings
Posterior Laryngeal Cleft	Tracheal Diverticulum
Laryngeal web	Tracheal Bronchus
Subglottic Stenosis	Tracheomalacia and Bronchomalacia
Subglottic Hemangioma	Tracheoesophageal Fistula
Subglottic Cyst	Bronchial Atresia/Agenesis
Tracheal Stenosis	Bronchial Stenosis
Tracheal Web	External Compression by a Vascular Ring

Table 2. Common airway anomalies that can be visualized during bronchoscope

4.1 Laryngomalacia

Laryngomalacia is a usually benign, self-limited disorder; it is the most common congenital laryngeal anomaly (50-75%) and the most common cause of stridor in infants (approx.60%) [1]. The term 'laryngomalacia' suggests that the cartilage of the larynx is abnormally soft, but there is no definitive evidence supporting this hypothesis; studies have reported dominance of submucosal edema and lymphatic dilation in the histopathology of tissue excised during supraglottoplasty for the treatment of severe laryngomalacia [2]. Thus, whether laryngomalacia is primarily an anatomical abnormality or whether it is due to delayed neuromuscular development remains under debate. Laryngomalacia is frequently associated with gastro-esophageal reflux, and infants with laryngomalacia may have episodes of micro-aspiration as well [3-5]. The natural history of laryngomalacia is characterized by an onset of inspiratory stridor usually within the first 4-6 weeks of life; the infant's voice and cry are normal. The stridor varies considerably with posture and airflow, is loudest with increased turbulence in airflow such as with crying, agitation and increased respiratory efforts with feeding. The stridor is also louder and appears worse during intercurrent respiratory tract infections. Some patients will have increasing symptoms during the first few months of life but thereafter stridor tends to resolve with time during the latter half of infancy into the second year of life as the supportive tissues mature and the diameter of the airway increases with somatic growth. In some instances, depending on the severity and structural anatomy, stridor may persist beyond the first year of life or even up to several years. Surgical treatment (i.e. supraglottoplasty) may be indicated in severe cases with prolapse of the supraglottic structures into the laryngeal inlet, feeding difficulties with failure to thrive and respiratory distress.

Flexible bronchoscopy demonstrates supraglottic collapse, i.e. prolapse of the epiglottic and/or the aryepiglottic folds and/or arytenoidis during inspiration into the glottis (Fig.1). The state of consciousness and respiratory efforts of the patient may be critical in the examination of the dynamics of the larynx and laryngeal structures during spontaneous breathing; some children may be stridulous only when crying, others only when they are asleep. Topical anesthesia can potentially exaggerate the findings associated with laryngomalacia; thus, the larynx should be examined before applying topical anesthesia [6].

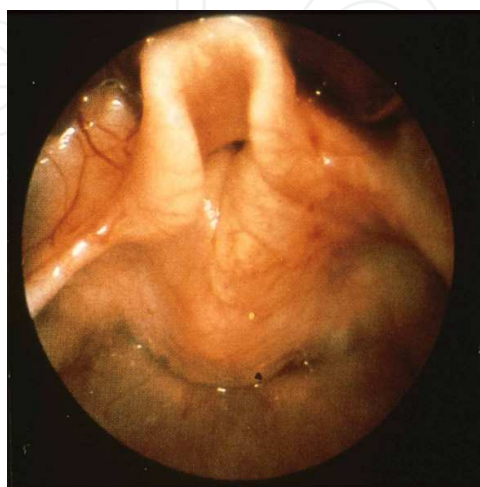


Fig. 1. The epiglottis and the aryepiglottic folds prolapse during inspiration into the glottis.

4.2 Vocal cord paralysis

In the pediatric population, vocal cord paralysis is the second most common congenital laryngeal anomaly (Fig.2). Central nervous system aetiologies of congenital disorders resulting in bilateral vocal cord paralysis include myelomeningocele, Arnold-Chiari malformation, hypoxic ischemic encephalopathy, cerebral hemorrhage and hydrocephalus. Other causes are traumatic and idiopathic factors which can cause vocal cord paralysis^[7,8]. Most frequent causes of unilateral vocal cord paralysis are linked to cardiovascular surgery for correction of heart defects that may cause injury to the recurrent laryngeal nerve and esophageal surgery for esophageal atresia with tracheo-oesophageal fistula^[9].

Bilateral vocal cord paralysis is characterized by a high-pitched inspiratory stridor along with a normal or near normal cry with the vocal cords assuming a midline or paramedian position. Unilateral vocal cord paralysis is characterized by a mild, position-dependent inspiratory stridor with a hoarse, breathy cry and potential risk for feeding difficulties and aspiration ^[10].

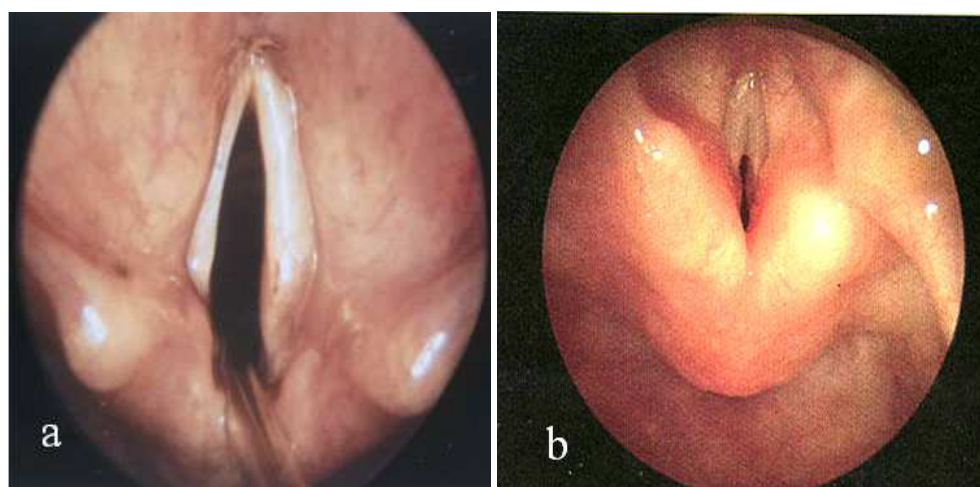


Fig. 2. (a)Left vocal cord paralysis (b) Bilateral vocal cord paralysis

4.3 Posterior laryngeal cleft

Posterior laryngeal clefts are rare congenital anomalies characterized by a failure of fusion of the posterior cricoid lamina that creates an abnormal communication between the larynx and hypopharynx (Fig.3). The anatomic severity of the cleft can range from the absence of interarytenoid muscle above the superior margin of the cricoid cartilage to the absence of the tracheoesophageal septum. Clinical symptoms include combined feeding-respiratory difficulties, such as coughing, choking and cyanotic attacks during feeding, aspiration, recurrent pneumonia, atelectasis, and even death. Other anomalies like cleft lip and palate and congenital cardiovascular anomalies may accompany the laryngeal cleft.

A high index of suspicion is required and bronchoscopy and microlaryngoscopy are needed to make a definitive diagnosis. Posterior laryngeal clefts can be either treated conservatively with medical management to prevent gastroesophageal reflux and aspiration, or surgical repair by endoscopy^[11]. Early medical management may prevent complications, surgery is needed when conservative measures fail. Depending on the severity of the comorbidities and the respiratory condition, some patients with mild symptoms don't need special treatments, while severe patients may require feeding through a nasogastric tube.

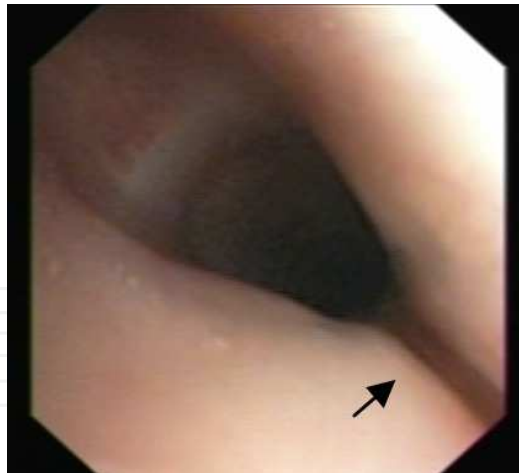


Fig. 3. Laryngeal cleft extending inferiorly to - but not through - the cricoid cartilage;

4.4 Laryngeal web

A congenital laryngeal web is a malformation in which abnormal tissue forms between two structures within the larynx. All patients present with some degree of dysphonia, ranging from mild hoarseness to aphonia. Airway obstructive symptoms increase with the extent of the web compromising or occluding the airway, with the most severe cases warranting a tracheotomy to secure the airway^[12]. Anterior glottic webs less than 2- to 3-mm thickness are often asymptomatic and do not require treatment. Larger webs can cause symptoms which range from dysphonia and decreased exercise tolerance to severe airway obstruction^[13-14].

Laryngoscopy is used to assess precisely the subglottic extension of the web and the size of the residual airway lumen. Webs of the glottis are classified as anterior, posterior, or complete; and may be located at the glottic, supraglottic or infraglottic level. Most commonly found are webs in the anterior portion of the glottis^[15].

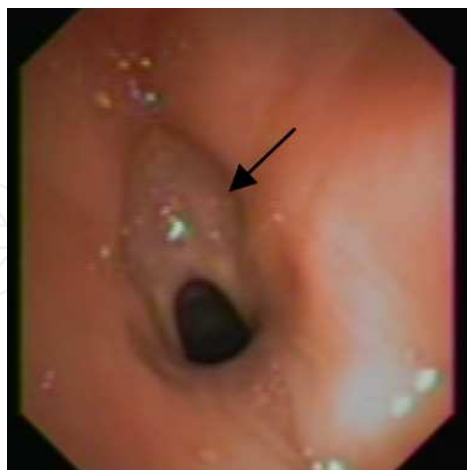


Fig. 4. Anterior Laryngeal web

4.5 Subglottic stenosis

Subglottic stenosis is narrowing of the subglottic airway, which is housed in the cricoid cartilage. It is the third most common congenital anomaly of the larynx ^[16] after

laryngomalacia and vocal cord paralysis. The subglottic airway is the narrowest area of the airway because it is enclosed by the complete cartilaginous ring of the cricoid, unlike the trachea, which has a posterior membranous section, and the larynx, which has a posterior muscular section. Subglottic stenosis is characterized by recurrent episodes of croup or prolonged croup with a barking cough. Acquired subglottic stenosis is related to a variety of causes, including prolonged endotracheal intubation^[17], gastroesophageal reflux, infection, autoimmune disorders, and iatrogenic disorders. The Myer-Cotton grading system for subglottic stenosis (SGS) is widely used in the pediatric community^[18]. It classifies SGS into four grades of luminal obstruction (Fig.5).

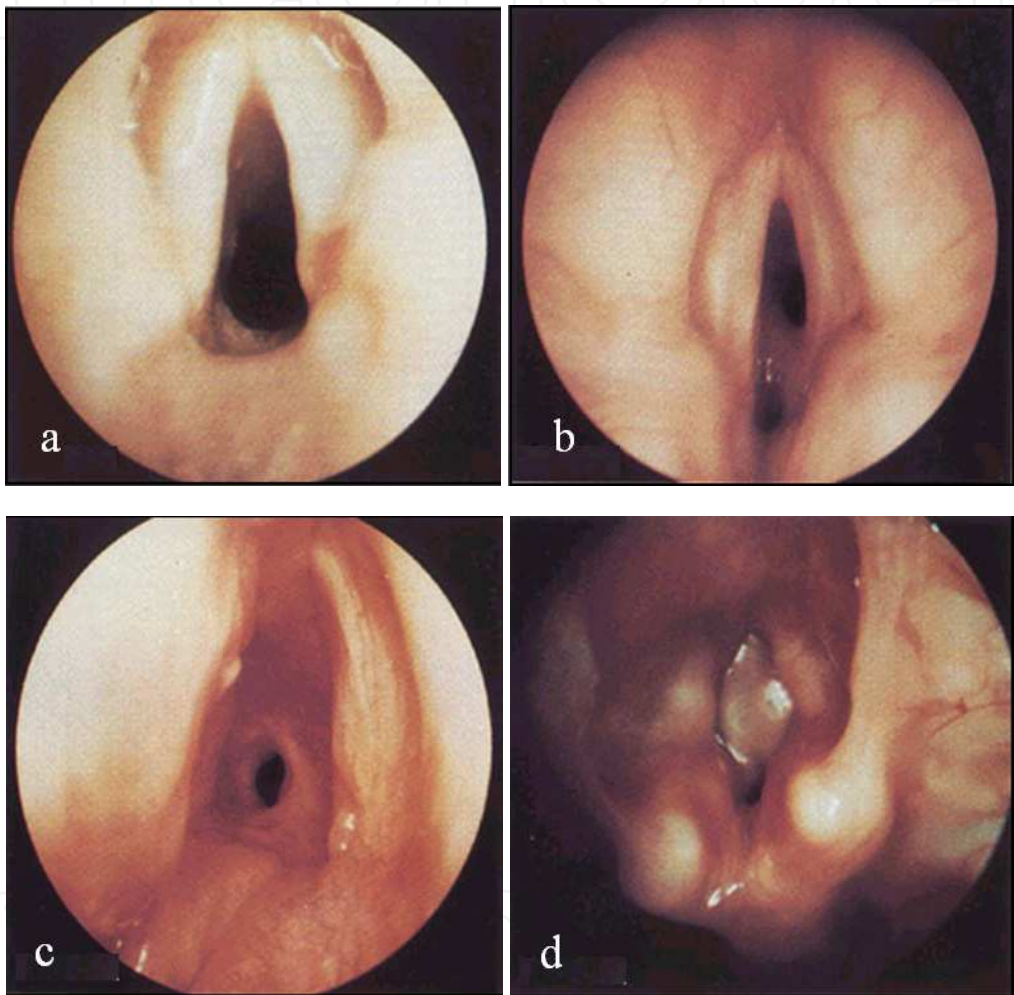


Fig. 5. The Myer-Cotton grading system for subglottic stenosis. (a)Grade 1: $\leq 50\%$ obstruction. (b)Grade 2: 51-70% obstruction. (c)Grade 3: 71-99% obstruction. (d)Grade 4: no detectable lumen.

4.6 Subglottic hemangioma

Congenital subglottic hemangioma is the most common neoplasm of the airway in children (Fig.6). It is a benign tumor associated with hyperplasia of the endothelial cells, mast cells, pericytes, fibroblasts and macrophages. In the absence of treatment, it's potentially life-threatening during the proliferative phase (occurring below the age of 6-12 months) causing airway obstruction which necessitates medical or surgical intervention^[19].

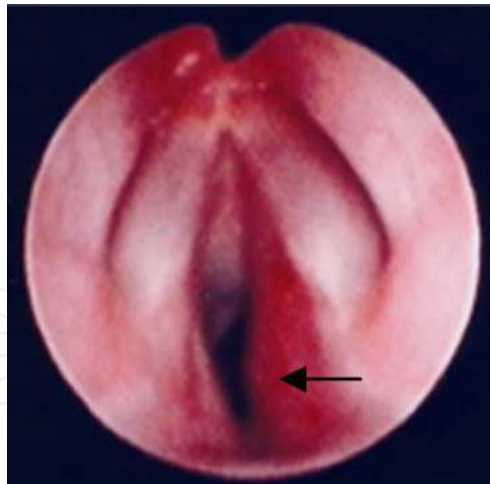

Fig. 6. Right-sided subglottic haemangioma

During the first weeks of life, the infant may be asymptomatic. Usually, symptoms of inspiratory stridor followed by biphasic stridor with barking cough and slight hoarseness start at around the age of 2-4 months. Symptoms of respiratory distress with suprasternal and chest retractions, feeding difficulties and failure to thrive depend on the severity of the airway obstruction. If symptoms worsen, then early intervention is indicated.

This may consist of a tracheotomy, general or local treatment with steroids, interferon, propranolol or vincristine therapy, LASER treatment, or open surgery with laryngo-tracheal reconstruction. Spontaneous regression typically occurs after 18-24 months of age [20].

4.7 Tracheal web

Congenital tracheal web is a rare congenital anomaly. It consists of a thin layer of tissue draped across the tracheal lumen. The web is not complete, and the degree of ventilatory symptoms that may occur is directly related to the size of the remaining functional tracheal lumen. Symptoms consist of stridor, dyspnea and respiratory failure resulting in death in severe cases. Tracheal web may often be misdiagnosed as refractory asthma as symptoms may include recurrent respiratory infections, dyspnea or wheezing. Postintubation tracheal

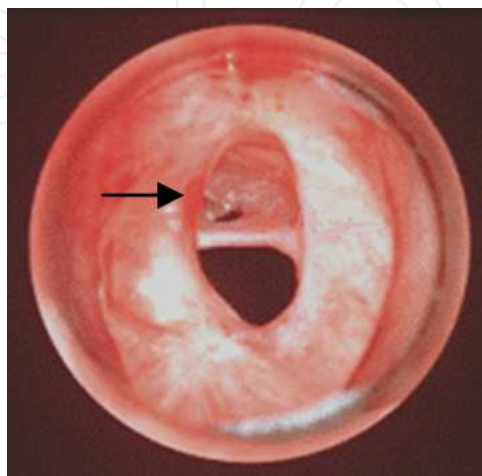


Fig. 7. Tracheal stenosis caused by a tracheal web

web may result as a complication of airway mucosal injury following endotracheal intubation. Although some patients may remain asymptomatic until detected incidentally, most present with symptoms of acute airway obstruction.

Treatment consists of rupturing the web. The first case was reported by Miller et al.^[21] in 1978, as an 8-year-old girl presenting with a six year history of frequent colds, wheezing, and dyspnea in whom the tracheal web was successfully excised after failure of bronchoscopic dilation. In 2004, Alan et al. ^[22] removed a 9-year-old girl's web by endoscopic argon laser treatment.

4.8 Complete tracheal rings

Congenital complete tracheal rings are a rare anomaly, reported by Scheid et al. in 1938 at the first time. They usually present in the first year of life with respiratory distress^[23], and often associated with vascular slings^[24], or other malformations such as tracheoesophageal fistula and esophageal atresia. In complete tracheal rings, the normally C-shaped cartilaginous tracheal rings are fused posteriorly replacing the membranous posterior part of the trachea, becoming O shaped(Fig.8). As a consequence, the trachea is often narrower than normal. The complete rings may be localized to the region where the sling passes around the trachea, or may extend to a certain length of the trachea, creating a long-segment tracheal stenosis, causing recurrent wheezing, breathing difficulties, cyanosis, and is potentially life-threatening.

It is very important to observe and examine the contours of tracheal cartilages during the passage of the bronchoscope through the trachea during diagnostic bronchoscopy, which is considered as the gold standard. CT scan may be used to aid the diagnosis and assess the degree of involvement, a single tracheal ring or short or long segment involvement. Definitive treatment is surgical with primary resection of a single ring or short segment with end-to end anastomosis; longer length involvement will require tracheal reconstructive surgery. In cases of associated pulmonary vascular sling anomaly, reimplantation of the anomalous left pulmonary artery is performed. Laser division of complete tracheal rings has

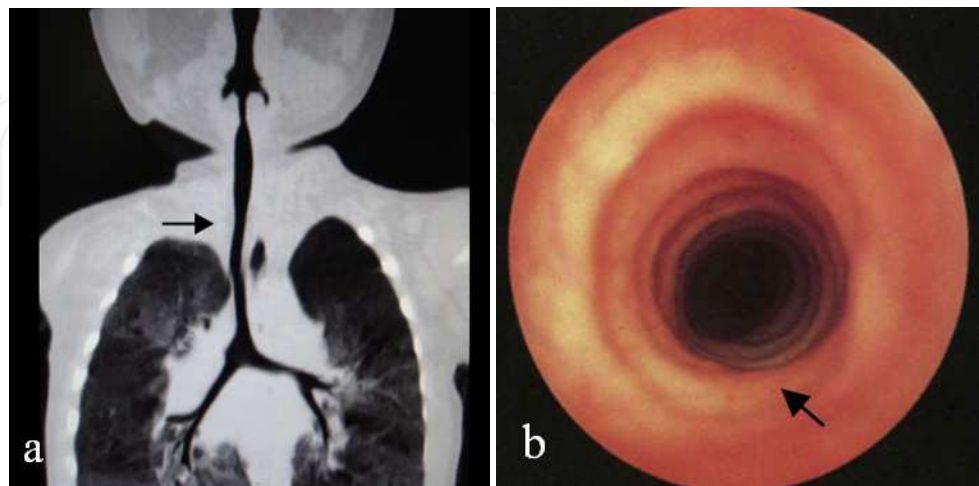


Fig. 8. (a) Coronal projection of the CT scan showing the associated long-segment tracheal stenosis with severe distal deviation and obstruction (Pulmonary artery sling). (b) Complete cartilaginous tracheal rings, the posterior membranous component of the trachea is absent.

only been described in a small number of cases and may provide an alternative approach in patients who are not able to undergo an open procedure or in an emergency situation [25].

4.9 Tracheal diverticulum

Tracheal diverticulum was firstly described by Rokintansky in 1938[26]. It is a rarely encountered entity. The frequency of the tracheal diverticulum found in some autopsy series has been estimated to be about 1% [27], and in children older than 10 yr it is reported as 0.3% [28]. The tracheal diverticulum is usually located approximately 4-5 cm below vocal cords or just above the carina. It projects posteriorly where the cartilage rings are deficient and usually lies towards the right where there is no esophagus supporting the paratracheal tissue (Fig.9). Tracheal diverticulum may be congenital or acquired. Congenital diverticulum is not normally detected in infancy unless it is suggested by recurrent episodes of tracheobronchial infection or in association with other congenital malformations[29-30]. The acquired form is thought to be due to prolonged increase in intraluminal pressures as occurs with a chronic cough. Although usually asymptomatic, the tracheal diverticulum may accumulate respiratory secretions that become infected and lead to cough or tracheobronchitis.

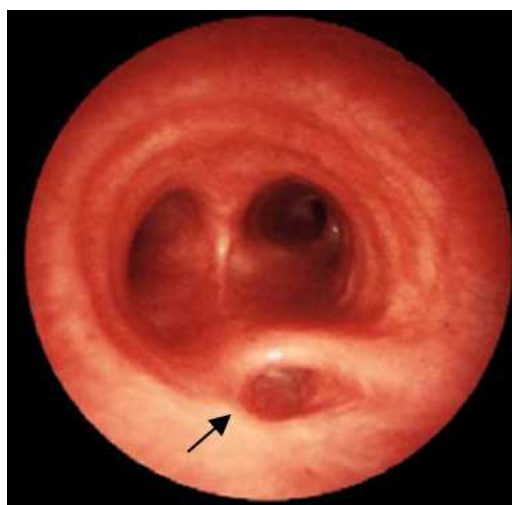


Fig. 9. Tracheal diverticulum in the membranous posterior part of the trachea above the carina.

4.10 Tracheal bronchus

A tracheal bronchus originates from the right lateral wall of the trachea above the level of the main carina and courses to the right (Fig. 10). It was firstly described by Sandifort in 1785. The frequency of the tracheal bronchus is approximately from 0.1% to 3%. In most cases, the tracheal bronchus supplies the apical segment of the right upper lobe. In such case, there is usually an additional orifice proximal to the bifurcation of the trachea, and the usually positioned right upper lobe bronchus has only 2 visible segmental branches (instead of three). Less frequently, the tracheal bronchus is associated with other anomalies, such as stenosis of the right main stem bronchus or it may supply additional, dysplastic pulmonary tissue. Patients in whom the tracheal bronchus is undetected, may undergo atelectasis of the right upper lobe when undergoing endotracheal intubation as the endotracheal tube will

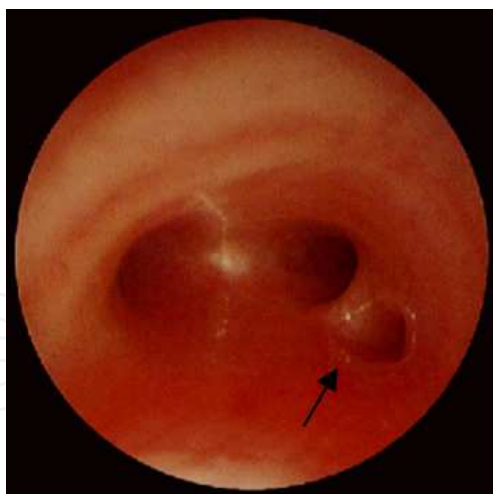


Fig. 10. A tracheal bronchus originates from the right lateral wall of the trachea above the level of the main carina and courses to the right.

obstruct the orifice. In a series of 35 patients with tracheal bronchus, 28 originated from the right wall and 7 from the left wall of the trachea as reported by Ghayel^[31]. Other research by Bertrand suggests that the frequency of the tracheal bronchus in children with Down syndrome is up to 20.8%^[32].

4.11 Tracheomalacia and bronchomalacia

Tracheobronchomalacia can be divided into two different types: congenital (or primary) and secondary tracheobronchomalacia ^[33]. The cause of congenital tracheobronchomalacia is abnormal cartilaginous ring formation with small, malformed or excessively pliable rings and sometimes absent or defective cartilage affecting the trachea partially or completely. Secondary tracheobronchomalacia may occur due to airway compression by vascular structures, tumor, enlarged lymph nodes, thymus, and even excessive fat. Complicated cardiac abnormalities associated with tracheobronchomalacia may result in a higher mortality.

Congenital tracheobronchomalacia is usually caused by abnormal cartilage formation of the trachea and bronchi during the embryonic period. Several changes in cartilage can be found on histopathologic examination, including reduced volume, thinned depth, piecemeal shape of cartilage and even its absence. Acquired tracheobronchomalacia may occur in patients with tracheal cannulation as with prolonged endotracheal intubation, tracheotomy, abnormal left pulmonary artery or vascular ring or sling anomalies, space occupying lesion that compress the airway (for example, goiter), following tracheoesophageal fistula repair, cardiac dilatation and post lung transplantation ^[34-38]. Secondary tracheobronchomalacia may be related to recurrent bronchitis and infections causing chronic inflammation of airway mucosa. In tracheomalacia, the trachea and bronchi lose their normal horseshoe-shape and this leads to the narrowness in airway and limitation of airflow, turbulent or eddied flow and wheezing.

Bronchoscopy has been considered the gold standard in diagnosis of tracheobronchomalacia with direct visualization of dynamic airway collapse with respiration.(Fig.11, Fig.12). Pulsation may be noted at the site of vascular compression as well. These bronchoscopic

findings help differentiate tracheomalacia from tracheostenosis in which there is a fixed and narrowed airway lumen.

Congenital (primary) tracheobronchomalacia is not uncommon, with an incidence of 1/2100 in some estimates^[39]. Most patients will often outgrow their symptoms at the age of 1-2 years with growth and development. Secondary tracheobronchomalacia occurring in association with cardiac and vascular abnormalities, in which the trachea and bronchi are extrinsically compressed by the enlarged heart chambers or anomalous vascular structures. Most children with tracheobronchomalacia may only need conservative treatment to manage respiratory infections, timely anti-infective agents, physical therapy for clearance of airway secretions and good nutrition for lung and body growth. Continuous positive airway pressure (CPAP) or mechanical ventilator support through a tracheostomy tube may be required in children with severe tracheobronchomalacia.. In some cases, surgical intervention with aortopexy or airway stents may be indicated.

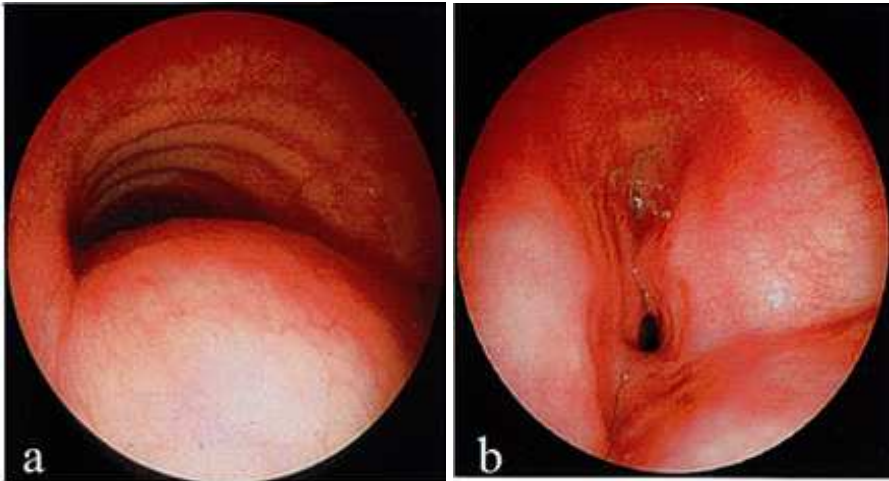


Fig. 11. Two characteristic features of tracheobronchomalacia on bronchoscopy. (a) Dynamic collapse of at least 50% of the airway lumen diameter, during expiration, cough or spontaneous breathing.(b) A ratio of cartilage to membranous wall area of < 3:1

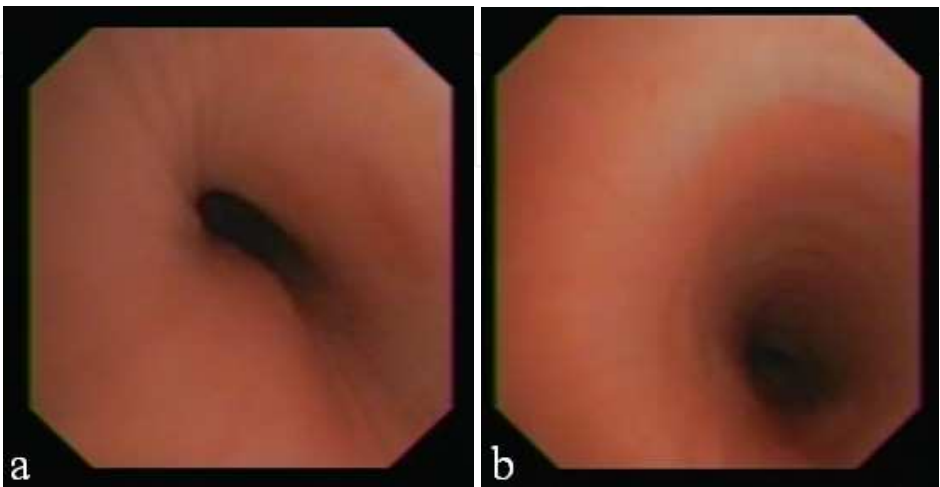


Fig. 12. Dynamic changes of trachea during respiratory period under bronchoscopy. (a) Airway collapse during expiration. (b) Airway dilation during inspiration.

4.12 Tracheo-esophageal fistula

Congenital tracheo-esophageal fistula (TEF) with esophageal atresia occurs with an incidence of approximately 1 in 3500 live births. TEF is potentially lifethreatening in the neonatal period requiring surgical correction. Gibson reported the first case of esophageal atresia with TEF in 1697. Since the report by Ladd and Levin in successful multistage correction of 2 cases of TEF patients in 1939; and technological and clinical advances in neonatal management there has been significant reduction in mortality due to TEF . Surgical correction is well established and survival rates of over 90% can be expected^[40]. Survival has been reported to be lower in infants with TEF weighing less than 1500g and with associated cardiac abnormalities.

Tracheoesophageal fistula results from failure of the primitive gut to separate and recanalize during early embryonic development resulting in an abnormal fistulous connection between the trachea and esophagus^[41]. Five types of TEF with esophageal atresia are described: Type 1: esophageal atresia, in which both the proximal (upper) and distal (lower) segments of the esophagus end in blind pouches. Neither segment is connected to the trachea; Type 2: Esophageal atresia with tracheoesophageal fistula in which the proximal (upper) segment of the esophagus forms a fistula (TEF) to the trachea. The distal (lower) segment of the esophagus ends in a blind pouch; Type 3: Esophageal atresia with tracheoesophageal fistula, in which the proximal (upper) segment of the esophagus ends in a blind pouch and the distal (lower) segment of the esophagus is attached to the trachea (TEF). Type 4: Esophageal atresia with tracheoesophageal fistula, in which both segments (proximal and distal) of the esophagus are attached to the trachea. Type 5: Tracheoesophageal fistula in which there is no esophageal atresia. An H-type fistula is present between the esophagus and the trachea. The most common type of TEF is type 3, with an incidence around 85%-93% (Fig.14). Type 5 (H type TEF) which is not associated with esophageal atresia potentially display the mildest symptoms, and occur at an incidence of around 4%. Secondary TEF usually results from injury to the esophagus as occurs with swallowing of corrosive agents, erosion by mediastinal granuloma or tumors or accidental perforation during tracheo-esophageal

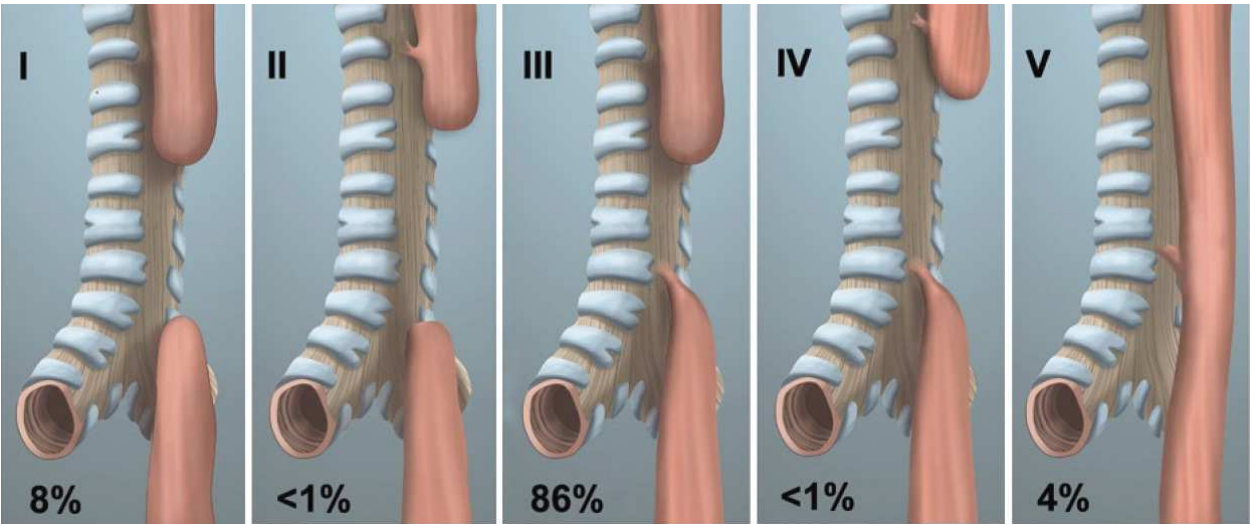


Fig. 13. Types of tracheo-oesophageal fistula and esophageal atresia malformations: The type III with a blind proximal esophageal pouch and a distal TE fistula is by far the most common (Reproduced from Holinger ^[42]. With permission)

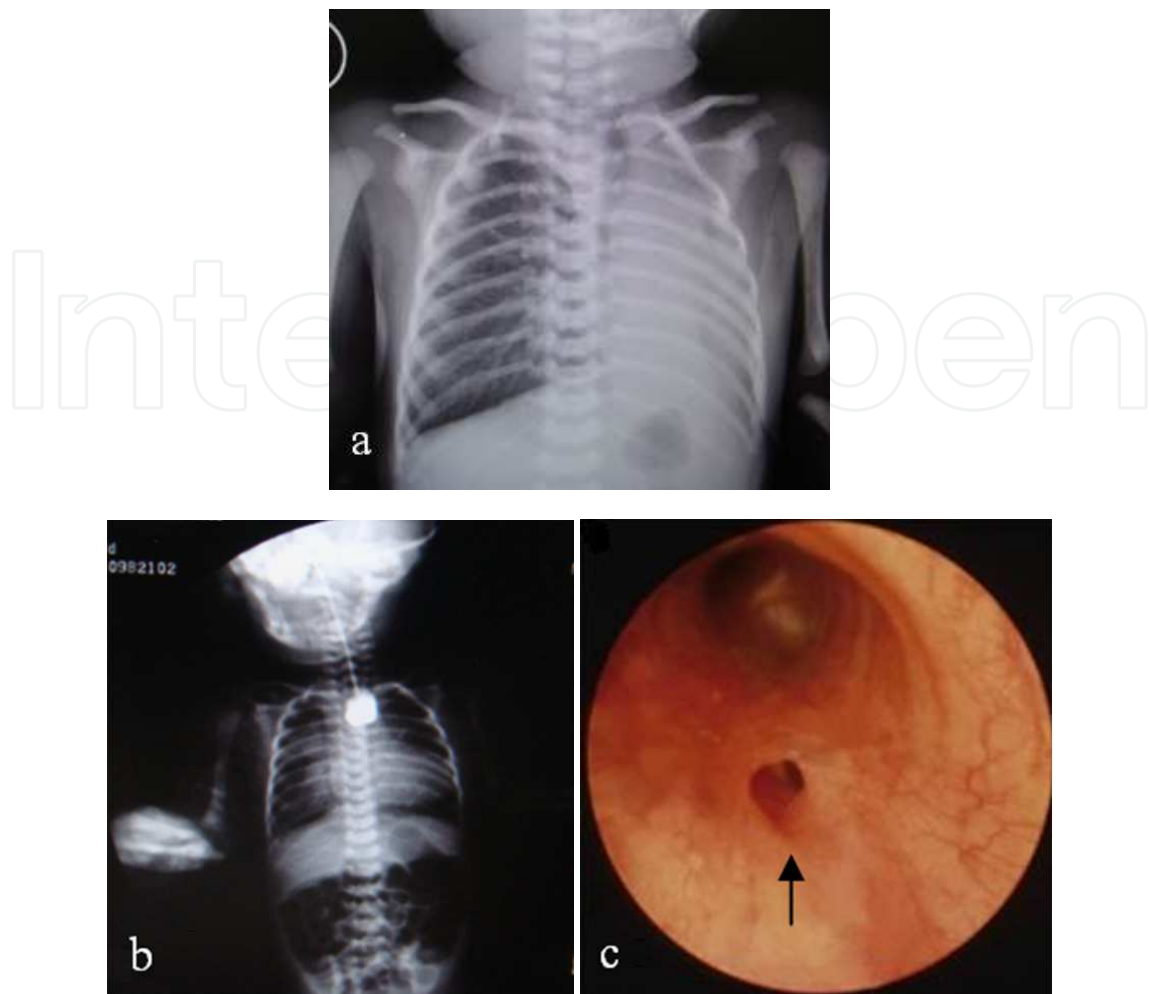


Fig. 14. (a) Chest radiograph shows a gastric tube coiled in blind esophageal pouch (b) Chest radiograph shows round or pocket-like blind esophageal pouch after meglumine diatrizoate injection via gastric tube. (c) Bronchoscopy demonstrates fistulous opening at the posterior aspect of the trachea just 1cm above the carina.

surgery. Complications of primary TEF surgical repair include development of an anastomotic fistula, recurrent laryngeal nerve paralysis, vocal cord paralysis, esophageal stenosis and recurrence of TEF. Recurrent TEF can result from compromise of blood supply and circulation of the area around the original fistula leading to tissue breakdown and fistula recurrence.

4.13 Tracheobronchial absence and agenesis

Agenesis of the trachea is a rare congenital malformation with an incidence below 1 in 50000. The entire trachea is usually absent and air reaches the bronchi through a fistulous connection with the esophagus; the lungs are normally formed. About half the infants are born premature, and a male predominance has been reported. It was first described by Payne in 1900 when he was dissection an infant died from disease^[43]. Those patient didn't cry when was born, and with progressive severe dyspnea, cyanosis and even dead. It is usually combination with other severe malformation and can barely survive under current technique.

Floyd classified tracheal agenesis into 3 types of malformation according to the anatomical location [44] (Fig.15). In Type I, accounting for approximately 20% of the malformations, there is atresia of part of the trachea with a normal but short distal trachea, normal bronchi and a tracheo-esophageal fistula (TEF). Sixty percent of the reported cases are of Type II, where there is complete tracheal atresia, the bronchi communicate at the carina (as the TEF) with normal distal bifurcation and bronchi (Fig.15-17). Type III, accounting for 20% of cases, comprises no trachea or carinal development and both mainstem bronchi arise directly from the esophagus.

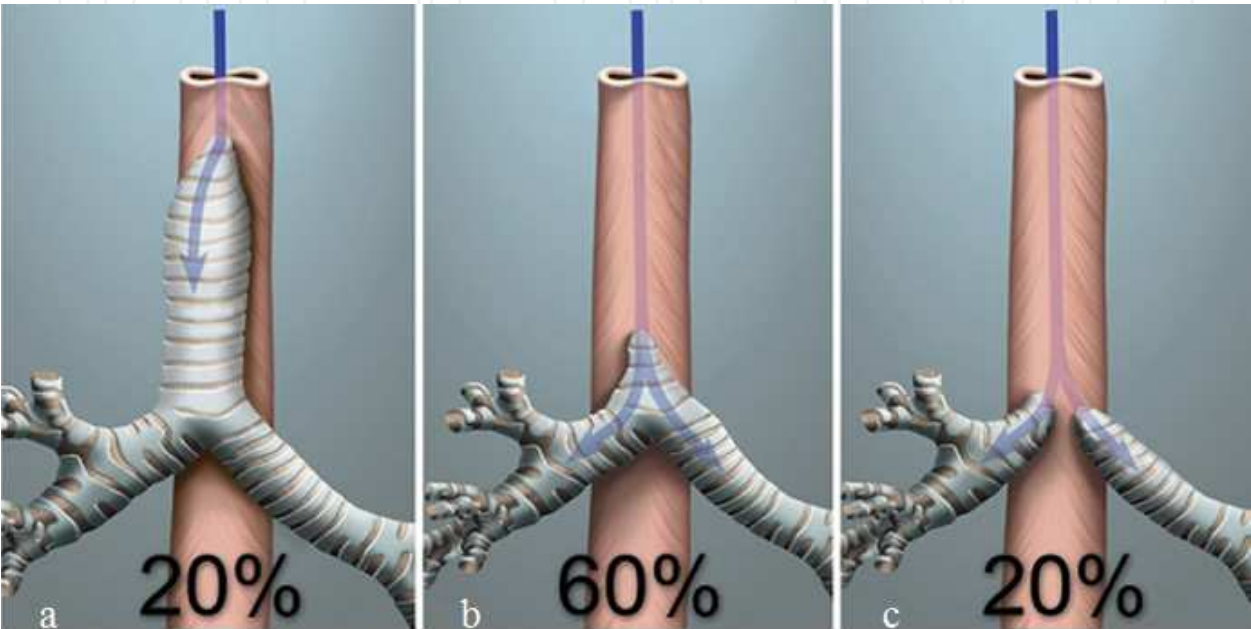


Fig. 15. Illustration of agenesis of trachea. (Reproduced from Monnier^[45]. With permission)

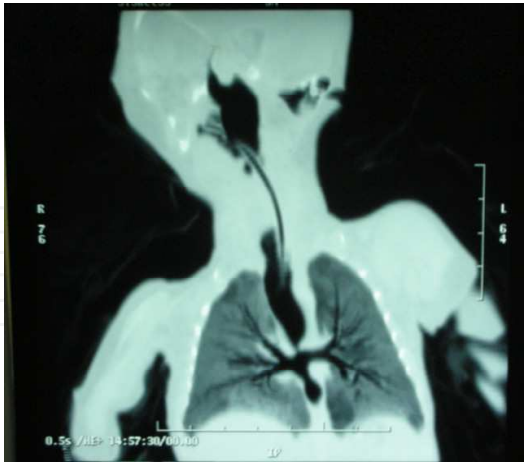

Fig. 16. CT airway reconstruction in coronal view: show left and right main bronchi arising directly from the mid-esophagus. No trachea is present, actually, the endotracheal tube goes though the esophagus.

Hiyama et al. described their surgical experience with 2 neonates; one of which had complex cardiac malformations, and died of cardiac failure 1 week after birth. The second with tracheal agenesis with a proximal TEF was managed successfully with multiple surgical

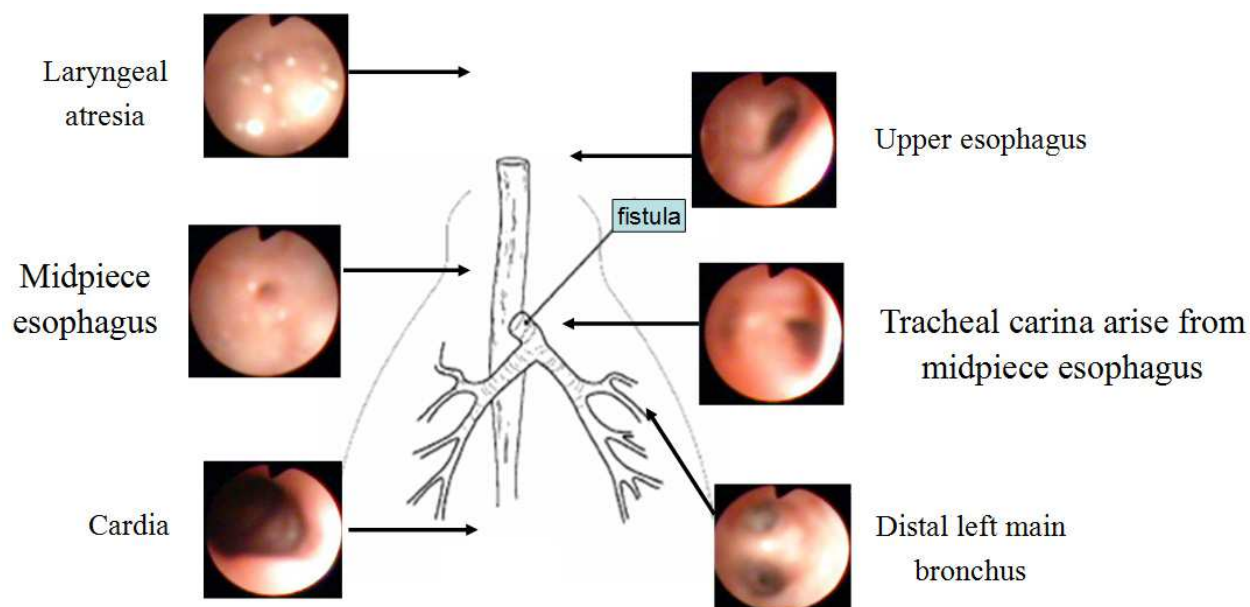


Fig. 17. Bronchoscopic findings in tracheal agenesis

procedures, including tracheotomy, with a long T-tube to maintain airway patency beyond the proximal TEF and esophageal reconstruction with a colonic interposition graft.^[46] It is essential to suspect this malformation and diagnose at birth, maintain airway patency with initial palliative surgical procedures which are lifesaving until reconstructive surgery can be performed for successful outcomes. We hypothesize that tracheal transplantation could be a promising therapy in the future; with advances in tissue engineering, there is potential for the prognosis of this disease to be largely improved.

5. The therapeutic benefit of bronchoscopy in children with congenital airway malformation

5.1 Assisting identification and localization of the tracheoesophageal fistulae prior to and during surgery

It is necessarily important but also understandably technically difficult to locate the distal communicating ends of the tracheoesophageal fistula precisely prior to surgical correction of H-type TE fistulae. Precise dissection is required during the surgical procedure to avoid injury of surrounding and adjacent tissue. This is particularly true for patients who require secondary surgical correction; as it is a surgical challenge as there significant post-operative adhesions may have formed. Flexible bronchoscopy assists in locating the fistula precisely using transillumination of the airway by the inserted bronchoscope. This technique can shorten surgical time spent in searching and locating the communicating ends of the TE fistula. Blanco-Rodriguez et al reported their experience with 3 neonates utilizing preoperative catheterization of H-type tracheoesophageal fistula with either a rigid bronchoscope or a nasolaryngoscope. to facilitate identification, plan the surgical approach, and to reduce operating times and the extent of surgery. ^[47] Several surgeons recommend locating the TE fistula by insertion of a catheter into the visualized orifice during bronchoscopy, however, with little success because of migration of catheter during operation. Garcia et al used bronchoscopy and oesophagoscopy performed simultaneously to

establish a guide wire loop between the tracheoesophageal fistulae in 6 cases of isolated tracheoesophageal fistula (Fig.18) Their success in locating and separating the TE fistula without recurrence in all cases, was the basis for their suggestion that this method be used in H-type TEF^[48] .

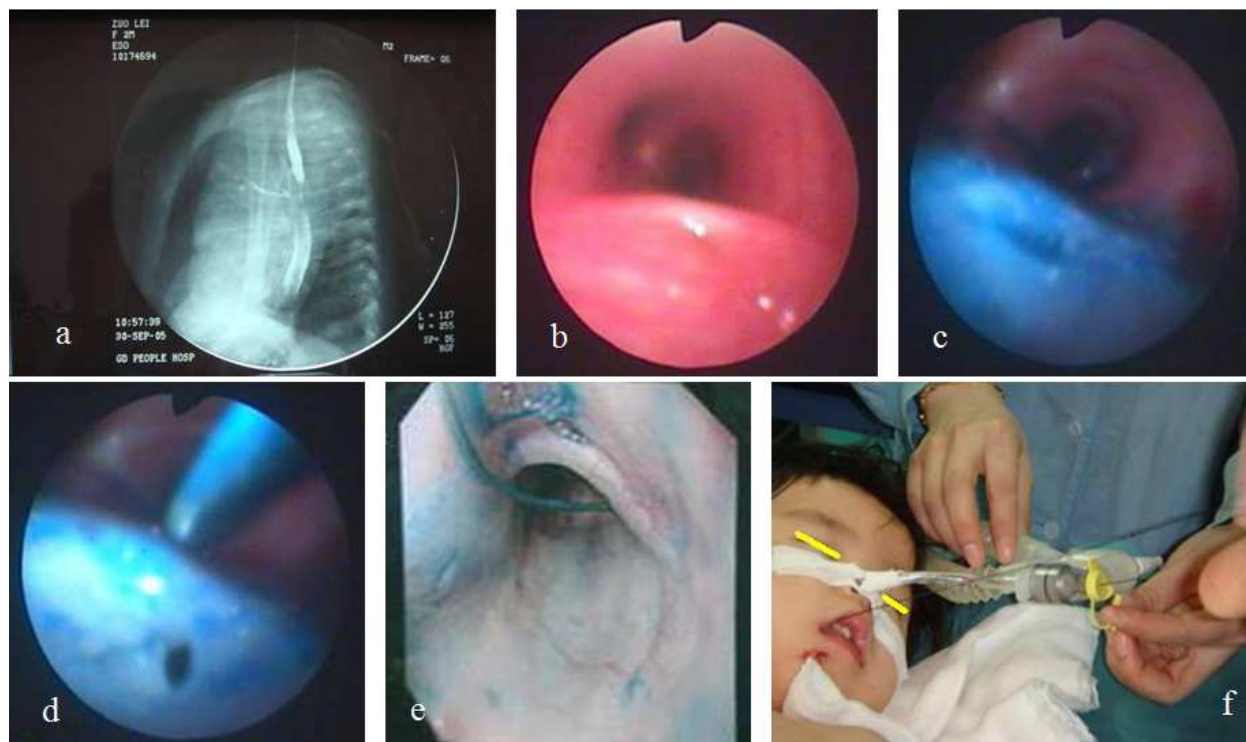


Fig. 18. (a) Shows contrast media passing through abnormal fistulous connection in the mid-esophagus during injection of meglumine diatrizoate via gastric tube. (b) Shows fistula located at the posterior tracheal wall visualized during bronchoscopy. (c) Shows color staining of the tracheal fistula after injection of methylene blue via gastroscopy. (d) Shows insertion of a guide wire towards the esophagus via bronchoscopy. (e) Shows the guide wire entering the esophagus. (f) Shows the guide wire loop between trachea and esophagus.

5.2 Laser treatment in laryngomalacia

With super-pulse or ultra-pulse technology, the CO₂ laser is more precise than microscissors in resecting the desired amount of tissue without causing much bleeding. Further, depending on each individual child and clinical situation, the CO₂ laser allows for additional vaporisation of tissue to achieve a tailored resection (Fig.19). If appropriate CO₂ laser parameters are used, then a char-free resection with less than 50 μ (four to five cells) depth of coagulation necrosis is achieved . This technique offers more versatility and precision than a microscissors resection.

Holinger et al ^[49] performed supraglottoplasty using CO₂ laser which provided 6~9W of power with approximately 0.5mm diameter spot. The CO₂ laser can relieve upper airway obstruction caused by laryngomalacia with less bleeding and higher accuracy. McClurg FL ^[50] summarized indications for supraglottoplasty using CO₂ laser in 1994 to include the following: collapse of the glottis during inspiration, arrest of development, obstructive apnea, cor pulmonale, severe reflux and asphyxia in awake patients. Andrew et al reported

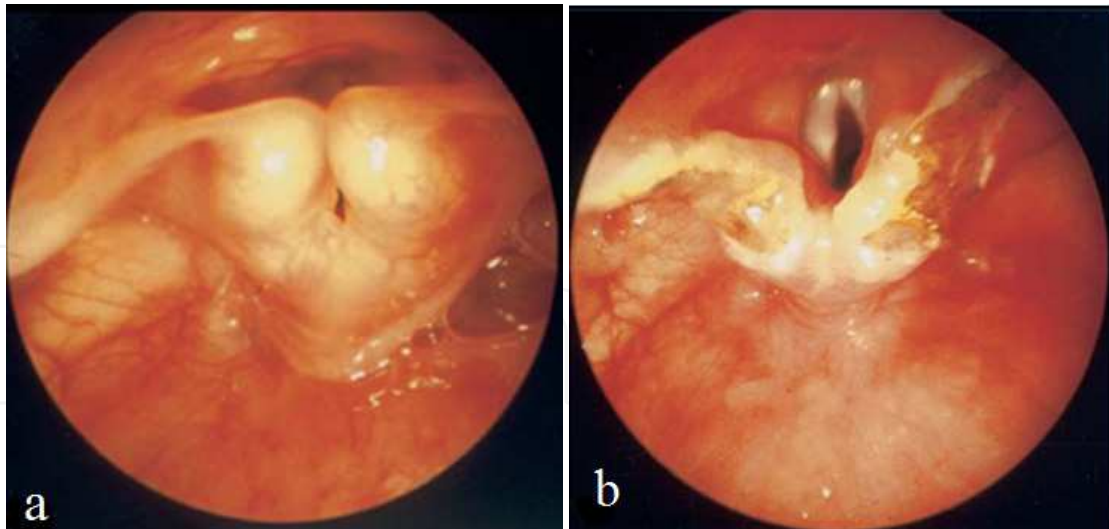


Fig. 19. (a) Inward collapse of the aryepiglottic folds. (b) CO₂ laser resection of the excessive mucosa with preservation of the pharyngo-epiglottic folds.

on 76 cases of laryngomalacia over a 10 year period; CO₂ laser supraglottoplasty resulted in a resolution of symptoms in 80% of the cases.

5.3 Stent insertion for tracheobronchomalacia

Tracheobronchomalacia, results in airflow limitation due to dynamic airway collapse and can be either a primary developmental abnormality of cartilage, or secondary to external compression (such as abnormal vasculature, cysts or tumor). Theoretically, insertion of an airway stent can maintain airway lumen and diameter, preventing collapse and thereby improving symptoms (Fig.1). Tracheobronchomalacia occurs fairly commonly in patients with congenital cardiovascular abnormalities with an incidence of 20-58%. Mortality may be high in patients with severe tracheobronchomalacia^[51]. Bronchomalacia usually occurs in the left mainstem bronchus because of its proximity to the left atrium and left pulmonary artery, abnormal enlargement of which and pulsatility could compress the left main bronchus leading to bronchomalacia.

There are two methods to place airway stents, one surgical and the other non surgical. Fayon^[51] treated 14 patients with left bronchomalacia using silicone stents with success in 6 patients (43%) ; one patient died of stent obstruction .With the development of newer types of stents and delivery devices, non surgical insertion and deployment is utilized, most often using special stent delivery device to place the stent precisely at the required location under bronchoscopic visualization.

However, it must be noted that in the pediatric age group, airway stents are infrequently used given the potential complications and limitations including formation of granulation tissue, potential for stent migration and penetration of adjacent structures. Other problems include technically difficult removal of the stent, potential for stent obstruction and death, stent fracture, the need for a larger stent placement or need to dilate the stent as the child grows and the airway diameter increases with growth and development. Currently, stents are used only in limited situations in children and when conventional therapy has failed.

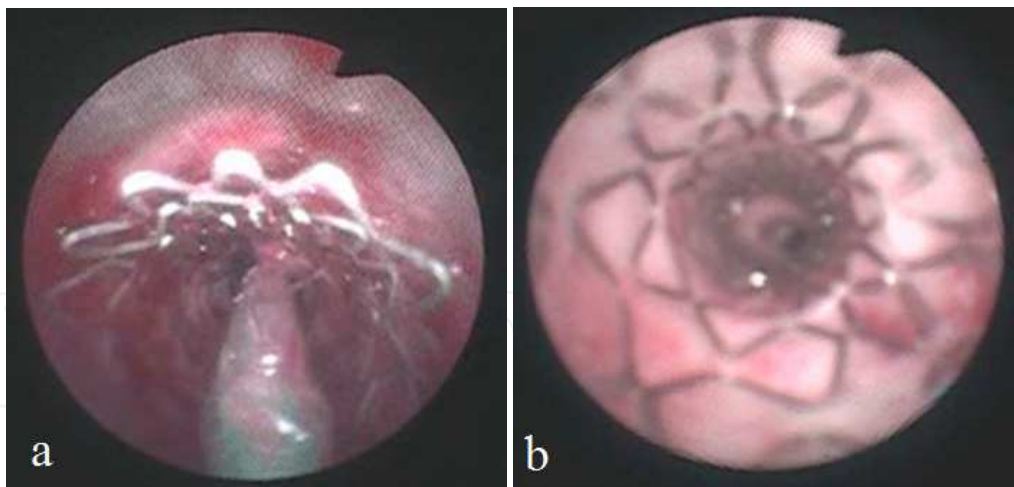


Fig. 20. (a) Expanding of a metal stent in airway carried by delivery device. (b) Full reopening of the collapsed airway with the expansion of the placed stent.

5.4 Balloon dilation for airway stenosis

The mechanism of balloon dilation of the airway relies on expanding the narrowed airway by creating longitudinal splits in the airway mucosa and tissues when the placed balloon is inflated by a pressure syringe device. The longitudinal splits around narrowed tracheal wall will be eventually filled with healing and fibrous tissue enlarging the narrowed airway (Fig.21). Balloon catheters that impart radially directed forces and can be precisely placed under bronchoscopic visualization and guidance are gradually inflated and utilized.

Cohen ^[52]reported a case of a 28 month old patient with congenital tracheobronchial stenosis who encountered restenosis after surgical tracheobronchoplasty which manifested as progressive dyspnea. The patient was anesthetized and tracheal and bilateral bronchial balloon dilatation was performed under fluoroscopic visualization. Andre et al^[53] described balloon tracheoplasty cases in children over a 15 year period; 37 patients underwent 158 procedures for airway balloon dilation performed under bronchoscopic visualization ; with 90% of short-term efficacy and 54% long-term efficacy.

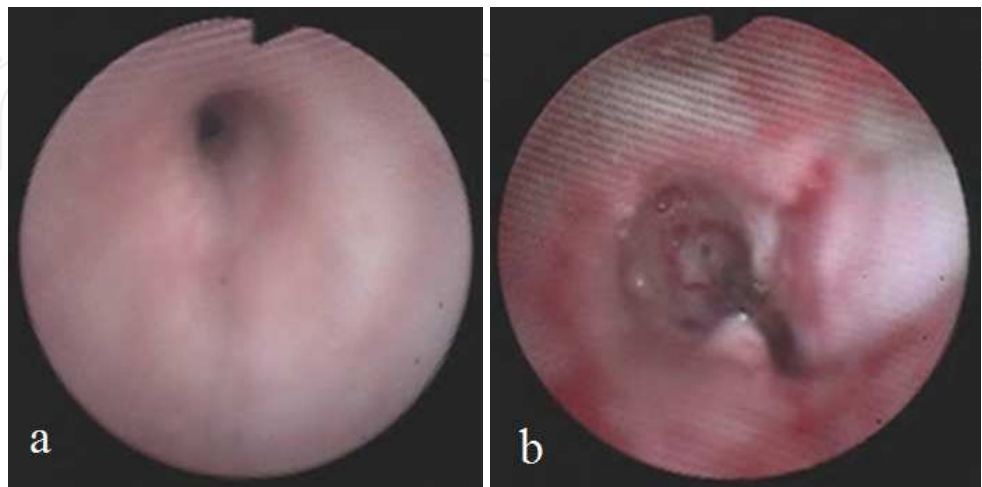


Fig. 21. (a) Narrowed mid part of trachea. (b) Narrowed tracheal segment that has been enlarged after balloon dilatation.

6. Future trends

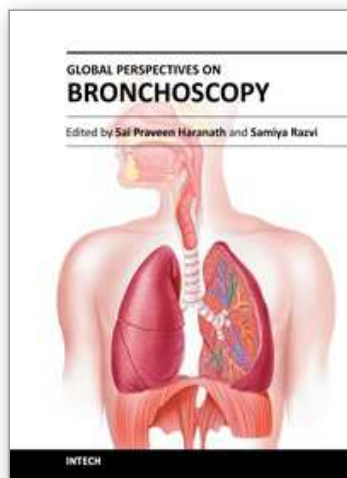
During the past 30 years, flexible bronchoscopy has become an indispensable and useful tool in the diagnosis and management of pediatric respiratory disease. The use of the flexible bronchoscope provides significant insight into the pathogenesis of clinical pulmonary symptoms and assistance to the therapy and surgical interventions in children.

7. References

- [1] Holinger LD, Congenital laryngeal anomalies; in Holinger LD, Lusk RP, Greene CG(eds): *Pediatric Laryngology and Bronchoesophagology*. Philadelphia, Lippincott-Raven, 1997; 137-164.
- [2] Chandra RK, Gerber ME, Holinger LD. Histological insight into the pathogenesis of severe laryngomalacia. *Int Pediatr Otorhinolaryngol*, 2001; 61:31-38.
- [3] Bibi H, Khvliis E, Shoseyov D, et al. The prevalence of gastroesophageal reflux in children with tracheomalacia and laryngomalacia. *Chest*, 2001; 119:409-413.
- [4] Midulla F, Guidi R, Tancredi G, et al. Microaspiration in infants with laryngomalacia. *Laryngoscope*, 2004; 114:1592-1596.
- [5] Dickson JM, Richter GT, Meinzen-Derr J, et al. Secondary airway lesions in infants with laryngomalacia. *Ann Otol Rhinol Laryngol*, 2009; 118:37-43.
- [6] Nielson DW, Ku PL, Egger M. Topical lidocaine exaggerates laryngomalacia during flexible bronchoscope. *Am Respir Crit Care Med*, 2000; 161:147-151.
- [7] Miyamoto, R.C., Parikh, S.R., Gellad, W., et al. Bilateral congenital vocal cord paralysis: a 16-year institutional review. *Otolaryngol. Head Neck Surg*, 2005; 133:241-245.
- [8] Daya, H., Hosni, A., Bejar-Solar, I., et al. Pediatric vocal fold paralysis: a long-term retrospective study. *Arch. Otolaryngol. Head Neck Surg*, 2000; 126:21-25.
- [9] Oestreicher-Kedem, Y., DeRowe, A., Nagar, H., et al. Vocal fold paralysis in infants with tracheoesophageal fistula. *Ann.Otol. Rhinol. Laryngol*, 2008; 117:896-901.
- [10] Smith, M.E. Vocal fold paralysis in children. In: Sulica, L., Blitzler, A. (eds.) *Vocal Fold Paralysis*, Springer, Berlin/Heidelberg, 2006; 225-235.
- [11] Sivi Bakthavachalam, James W Schroeder Jr, Lauren D Holinger. Diagnosis and Management of Type I Posterior Laryngeal, *The Annals of Otology, Rhinology & Laryngology*, 2010; 119:239-10.
- [12] S.R. Cohen, J.W. Thompson, Ventral cleft of the larynx: a rare congenital laryngeal defect, *Ann. Otol. Rhinol. Laryngol*, 1990; 99:281-285.
- [13] B.W. Rotenberg and R.G. Berkowitz, Delayed failure of open repair of an anterior glottic web in the neonatal time period, *Int J Pediatr Otorhinolaryngol Extra*, 2006; 1(3):204-206.
- [14] J. Edwards, N. Tanna and S.A. Bielałowicz, Endoscopic lysis of anterior glottic webs and silicon keel placement, *Ann Otol Rhinol Laryngol*, 2007; 116:211-216.
- [15] S. Men, A.O. Ikiz, I. Topcu, H. Cakmakci and C. Ecevit, CT and virtual endoscopy findings in congenital laryngeal web, *Int J Pediatr Otorhinolaryngol*, 2006; 70:1125-1127.
- [16] Narcy, P., Bobin, S., Contencin, P., et al. Laryngeal anomalies in newborn infants. A propos of 687 cases. *Ann. Otolaryngol. Chir. Cervicofac*, 1984; 101:363-373.

- [17] M. L. G. Duynstee, R. R. de Krijger, Ph. Monnier, et al. Subglottic stenosis after endolaryngeal intubation in infants and children: result of wound healing processes, *International Journal of Pediatric Otorhinolaryngology*, 2002; 62(1):1-9.
- [18] C.M. Myer, D.M. O'Connor, R.T. Cotton, Proposed grading system for subglottic stenosis based on endotracheal tube sizes, *Ann. Otol. Rhinol. Laryngol*, 1994; 103:319-323.
- [19] Catherine Blancheta, Richard Nicollasb, Michèle Bigorrec, et al. Management of Hemangiomas and Other Vascular Tumors. *Clinics in Plastic Surgery*, 2011; 38:45-63.
- [20] Catherine Blancheta, Richard Nicollasb, Michèle Bigorrec, et al. Management of infantile subglottic hemangioma: Acebutolol or propranolol? *Clinics in Plastic Surgery*, 2011; 38:45-63.
- [21] Miller BJ, Morrison MD. Congenital tracheal web - a case report. *J Otolaryngol*, 1978; 7:218-222.
- [22] Alan C. Legasto, Jack O. Haller, Robert J. Giusti. Tracheal web. *Pediatr Radiol*, 2004; 34: 256-258.
- [23] L.D. Hollinger, Congenital abnormalities of the larynx. In: R.E. Bchrman and R.M. Kliegman, Editors, *Nelson Textbook of Pediatrics* (17th ed.), Elsevier Science, Philidelphia, 2004:. 1409-1413.
- [24] M.I. Ali, C.D. Brunson, J.F. Mayhew, Failed intubation secondary to complete tracheal rings: a case report and literature review, *Pediatr. Anaesth*, 2005; 15:890-892.
- [25] W.A. Clement, N.K. Geddes, C. Best, Endoscopic carbon dioxide laser division of congenital complete tracheal rings: a new operative technique, *Ann. Thorac. Surg*, 2005; 76:687-689.
- [26] Frenkiel S, Assimes IK, Rosales JK. Congenital tracheal diverticulum. A case report. *Ann Otol Rhinol Laryngol*, 1980; 89:406-408.
- [27] MacKinnon D .Tracheal diverticula. *J Pathol Bacteriol*, 1953; 65:513-517.
- [28] Caversaccio MD, Becker M, Zbaren P .Tracheal diverticulum presenting with recurrent laryngeal nerve paralysis. *Ann Otol Rhinol Laryngol* , 1998; 107:362-364.
- [29] Hernandez JM, Pe´rez L, Batista JJ, et al. Intratracheal diverticulum. *J Bronchol*, 2005; 12:104-105.
- [30] Restrepo S, Villamil MA, Rojas IC, et al. Association of two respiratory congenital anomalies: tracheal diverticulum and cystic adenomatoid malformation of the lung. *Pediatr Radiol*, 2004; 34:263-266.
- [31] Ghaye B, Szapiro D, Fanchamps J-M, et al. Congenital bronchial abnormalities revisited. *Radiographics*, 2001; 21(1):105-119.
- [32] Bertrand P, Navarro H, Caussade S, et al. Airway anomalies in children with Down syndrome: endoscopic findings. *Pediatr Pulmonol*, 2003 Aug; 36(2):137-41.
- [33] Carden K, Boisselle PM, Waltz D, et al. Tracheomalacia and tracheobronchomalacia in children and adults: an in-depth review of a common disorder. *Chest*, 2005; 127:984-1005.
- [34] Mair EA, Parsons DS. Pediatric tracheobronchomalacia and major airway collapse. *Ann Otol Rhinol Laryngol*, 1992; 101:300-309.
- [35] Blair GK, Cohen R, Filler RM. Treatment of tracheomalacia: eight years' experience. *J Pediatr Surg*, 1986; 21:781-785.

- [36] Andrews TM, Myers CMI, Gray SP. Abnormalities of the bony thorax causing tracheobronchial compression. *Int J Pediatr Otorhinolaryngol*, 1990; 19:139-144.
- [37] Jacobs IN, Wetmore RF, Tom LW, et al. Tracheobronchomalacia in children. *Arch Otolaryngol Head Neck Surg*, 1994; 120:154-158.
- [38] Shaha AR, Alfonso AE, Jaffe BM. Operative treatment of substernal goiters. *Head Neck Surg*, 1989; 11:325-330.
- [39] Boogaard R, Huijsmans SH, Pijnenburg MWH, et al. Tracheomalacia and bronchomalacia in children: Incidence and patients characteristics. *Chest*, 2005; 128:3391-3397.
- [40] Houben CH, Curry JI. Current status of prenatal diagnosis, operative management and outcome of esophageal atresia/tracheo-esophageal fistula. *Prenatal Diagnosis*, 2008; 28(7):667-675.
- [41] Kluth D, Fiegel H. The Embryology of the Foregut. *Semin Pediatr Surg*, 2003; 12:3-9.
- [42] Holinger, L.D., Green, C.G., Benjamin, B., et al. Tracheobronchial tree. *Pediatric Laryngology and Bronchoesophagology*, 1997; 187-214.
- [43] Das, B.B., Nagaraj, A., Rao, A.H., et al. Tracheal agenesis: report of three cases and review of the literature. *Am. J. Perinatol*, 2002; 19:395-400.
- [44] Floyd, J., Campbell Jr., D.C., Dominy, D.E.. Agensis of the trachea. *Am. Rev. Respir. Dis*, 1962; 86: 557-560.
- [45] Monnier Philippe (Ed.), *Congenital Tracheal Anomalies. Pediatric Airway Surgery: Management of Laryngotracheal Stenosis in Infants and Children*, 2011; 157-179.
- [46] Hiyama, E., Yokoyama, T., Ichikawa, T., et al. Surgical management of tracheal agenesis. *J. Thorac. Cardiovasc. Surg*, 1994; 108: 830-833.
- [47] G. Blanco-Rodríguez, J. Penchyna-Grub, A. Trujillo-Ponce, et al. Preoperative Catheterization of H-Type Tracheoesophageal Fistula to Facilitate its Localization and Surgical Correction. *Eur J Pediatr Surg*, 2006; 16:14-17.
- [48] N.M. Garcia, J.W. Thompson, D.B. Shaul. Definitive Localisation of Isolated Tracheoesophageal Fistula Using Bronchoscopy and Esophagoscopy for Guide Wire Placement. *Pediatric Surgery*, 1998; 33:1645-1647.
- [49] Holinger LD, Konior RJ. Surgical management of severe laryngomalacia. *Laryngoscope*, 1989; 99(2):136-42.
- [50] McClurg FL, Evans DA. Laser laryngoplasty for laryngomalacia. *Laryngoscope*, 1994; 104:247-52.
- [51] Fayon M, Donato L, de Blic J. French experience of silicone tracheobronchial stenting in children. *Pediatr Pulmonol*, 2005; 39(1): 21-27.
- [52] Cohen MD, Weber TR, Rao CC. Balloon dilatation of tracheal and bronchial stenosis. *AJR Am J Roentgenol*, 1984; 142(3):477-8.
- [53] Andre Hebra, David D.Powell, Charles D. Smith, et al. Balloon traceoplasty in children: results of a 15-year experience. *Journal of Pediatric Surgery*, 1991; 26(8):957-961.



Global Perspectives on Bronchoscopy

Edited by Dr. Sai P. Haranath

ISBN 978-953-51-0642-5

Hard cover, 240 pages

Publisher InTech

Published online 13, June, 2012

Published in print edition June, 2012

Bronchoscopy has become an essential part of modern medicine . Recent advances in technology have allowed integration of ultrasound with this tool. The use of lasers along with bronchoscopes has increased the therapeutic utility of this device. Globally an increasing number of pulmonary specialists, anaesthesiologists and thoracic surgeons are using the bronchoscope to expedite diagnosis and treatment. The current volume on bronchoscopy adds to the vast body of knowledge on this topic. The democratic online access to this body of knowledge will greatly increase the ease with which both trainees and expert bronchoscopists can learn more .The contributions from around the world cover the breadth of this field and includes cutting edge uses as well as a section on pediatric bronchoscopy . The book has been an effort by excellent authors and editors and will surely be a often reviewed addition to your digital bookshelf. . In summary, this book is a great testament to the power of collaboration and is a superb resource for doctors in training, ancillary team members as well as practicing healthcare providers who have to perform or arrange for bronchoscopy or the associated procedures.

How to reference

In order to correctly reference this scholarly work, feel free to copy and paste the following:

Yong Yin, Shuhua Yuan, Wenwei Zhong and Yu Ding (2012). Utility of Pediatric Flexible Bronchoscopy in the Diagnosis and Treatment of Congenital Airway Malformations in Children, Global Perspectives on Bronchoscopy, Dr. Sai P. Haranath (Ed.), ISBN: 978-953-51-0642-5, InTech, Available from: <http://www.intechopen.com/books/global-perspectives-on-bronchoscopy/utility-of-pediatric-flexible-bronchoscopy-in-the-diagnosis-and-treatment-of-congenital-airway-m>

INTeCH
open science | open minds

InTech Europe

University Campus STeP Ri
Slavka Krautzeka 83/A
51000 Rijeka, Croatia
Phone: +385 (51) 770 447
Fax: +385 (51) 686 166
www.intechopen.com

InTech China

Unit 405, Office Block, Hotel Equatorial Shanghai
No.65, Yan An Road (West), Shanghai, 200040, China
中国上海市延安西路65号上海国际贵都大饭店办公楼405单元
Phone: +86-21-62489820
Fax: +86-21-62489821

© 2012 The Author(s). Licensee IntechOpen. This is an open access article distributed under the terms of the [Creative Commons Attribution 3.0 License](https://creativecommons.org/licenses/by/3.0/), which permits unrestricted use, distribution, and reproduction in any medium, provided the original work is properly cited.

IntechOpen

IntechOpen