

# We are IntechOpen, the world's leading publisher of Open Access books Built by scientists, for scientists

6,900

Open access books available

185,000

International authors and editors

200M

Downloads

Our authors are among the

154

Countries delivered to

TOP 1%

most cited scientists

12.2%

Contributors from top 500 universities



WEB OF SCIENCE™

Selection of our books indexed in the Book Citation Index  
in Web of Science™ Core Collection (BKCI)

Interested in publishing with us?  
Contact [book.department@intechopen.com](mailto:book.department@intechopen.com)

Numbers displayed above are based on latest data collected.  
For more information visit [www.intechopen.com](http://www.intechopen.com)



# Endotracheal Intubation with Flexible Fiberoptic Bronchoscope (FFB) in Cases of Difficult Airway

Francisco Navarro, Raúl Cicero and Andrea Colli

*Departament of Thoracic Endoscopy, Pneumology and Thoracic Surgery Service  
General Hospital of México OD, Faculty of Medicine,  
National Autonomous University of Mexico  
México*

## 1. Introduction

Endotracheal intubation is a procedure whereby a tube is inserted into the trachea to warrant and maintain adequate ventilation with good respiratory gas exchange in patients who undergo anesthesia for surgery or require invasive mechanical ventilation. Since 1967 the flexible fiberoptic bronchoscope was considered as an advanced device to intubate patients with difficult airway having surgery, "fiberoptic assisted tracheal intubation".<sup>1</sup>

In most cases, tracheal intubation is done by oral laryngoscopy performed with a rigid laryngoscope,<sup>2</sup> but there are cases in which the intubation attempt fails due to the presence of difficult airway. This problem occurs in 1/22,000 cases of general anesthesia and is the most frequent serious airway complication.<sup>3</sup> Among 37,482 intubation attempts by direct laryngoscopy for general anaesthesia, 161 (0.43%) cases could not be intubated because of being overly difficult as mentioned by Burke.<sup>4</sup> Other authors report 6/13,380 cases but in obstetric patients it has been reported to be 1/300 cases.<sup>5</sup>

The definition of difficult airway according to the American Society of Anesthesiologists Task Force on Management of the Difficult Airway is "a clinical situation in which a conventionally trained anesthesiologist experiences difficulty with face mask ventilation of the upper airway, difficulty with tracheal intubation or both."<sup>6</sup> Under these conditions, intubation must be attempted with another technique or must be postponed because a life-threatening situation may arise if the anesthesiologist is unable to intubate and cannot ventilate. Use of FFB is then indicated for tracheal intubation as an emergency measure.

## 2. General considerations

### Evaluation of the patient's airway

A difficult intubation can be predicted and avoided with a proper and careful preoperative evaluation of the airway by a skilled anesthesiologist. The clinical record and history of previous episodes of failed intubation during anesthesia for surgical interventions are important.<sup>7</sup> A first question must be answered: Are the larynx and vocal cords visible? If

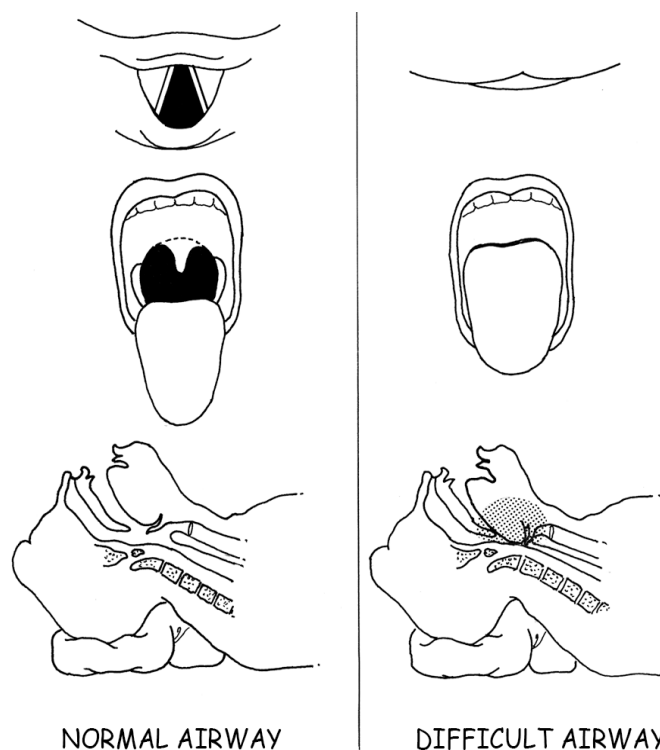


Fig. 1. Normal airway and difficult airway, Cormack-Lehane and Mallampati. The visualization or not of retropharynx and vocal cords is important to predict difficult airway. (Ref 14) Failure of intubation with rigid laryngoscope due to impossible visualization of the larynx is indication for FFB endotracheal intubation.

not, the possibility of difficult tracheal intubation may be identified during the pre-anesthetic evaluation.<sup>8</sup> However, a difficult tracheal intubation is sometimes unpredictable whether occurring in the operating room, the intensive care unit (ICU) or in the emergency department.<sup>9</sup> This is certainly true in cases of an oropharyngeal condition that does not allow epiglottis and vocal cord visualization. These cases were previously classified as difficult airway according to the original Mallampati<sup>10</sup> classification or the modified classification.<sup>11</sup> In cases with limited mouth opening or restricted mobility of the head and neck, evaluation of anatomic conditions is also mandatory. A more accurate evaluation may be done by computerized facial analysis in challenging intubations.<sup>12</sup> If a difficult airway is present, use of FFB may be anticipated.

### 3. Airway assessment

Anatomic conditions and mobility of the head and neck are important<sup>13</sup> as well as imaging with X-ray. Airway exploration must be made in all cases according to ASA recommendations, with particular attention to mouth opening, Mallampati classification, Cormack-Lehane, thyromental distance or other methods.<sup>14</sup> Patency of the nose is important, but under emergency situations it may be impossible to perform this assessment.

### 4. Common indications for endotracheal intubation with FFB

FFB intubation is indicated and appropriately scheduled in cases diagnosed as difficult airway or as an emergency procedure. Patients in whom previous evaluation of the airway

suggests a difficult intubation are the primary candidates for scheduling FFB intubation. Some examples are morbid obesity, trismus, facial trauma, pharynx and larynx injury, limited flexion and extension of the neck, craniofacial disorders, jaw malformations, temporomandibular joint ankylosis, macroglossia, larynx tumors, laryngo-tracheobronchitis, glottic edema and epiglottitis along with other unexpected conditions. An emergency intubation carried out in the ICU or in the emergency department lacks proper previous evaluation of the airway.

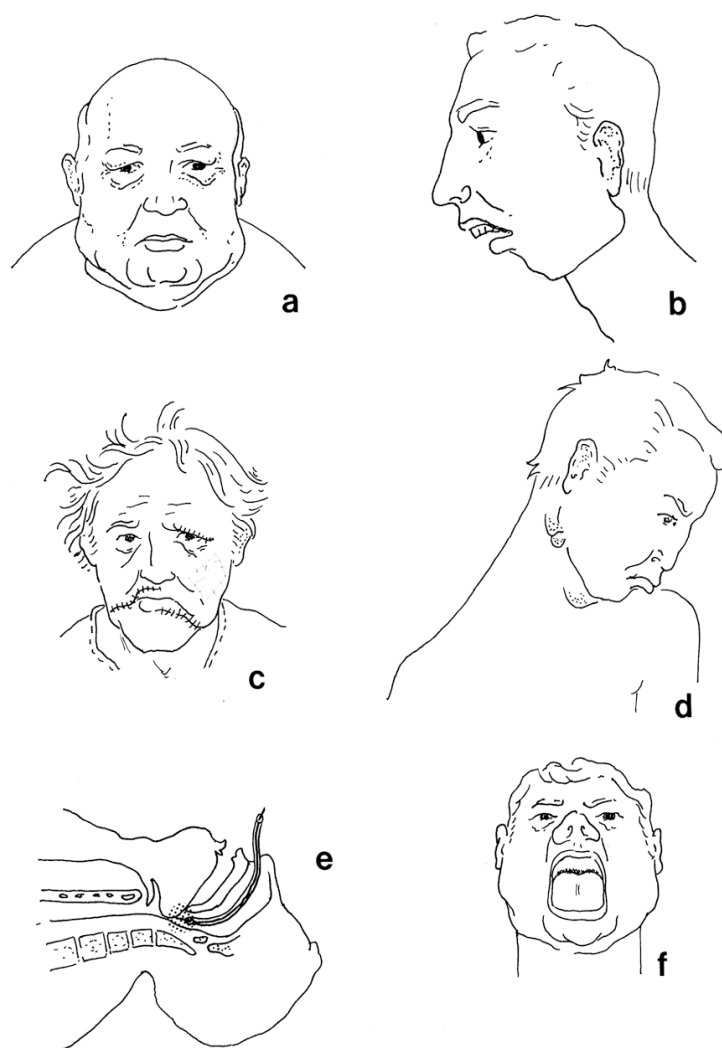


Fig. 2. Some examples of candidates for FFB endotracheal intubation. a) morbid obesity with short neck, b) prominent incisors teeth and micrognathia, c) facial trauma, d) cervical ankylosis, e) macroglossia, f) Mallampati IV (Ref 13)

FFB intubation is better performed with the assistance of a video magnification screen in the operating room.<sup>15</sup> In the ICU it is not always possible and must be done by direct vision in the FFB with a second observer device for the assistant. Proper monitoring of electrocardiogram, oximetry, arterial pressure and capnography is always required.

In every case of intubation with FFB, the bronchoscopist must work in complete coordination and communication with anesthesiologists and intensive care physicians.

5. Awake intubation and anticipated intubation with the FFB

Awake intubation with FFB requires informed consent about the procedure and the risks along with complete cooperation of the individual during the procedure. Confidence between the operator and the patient is also essential.

In predicting difficult intubation,scheduled cases may be better subjected to the procedure in the supine position as a safer and more comfortable measure, with the use of supplemental oxygen.<sup>16</sup> Local anesthesia is easily applied with 2% lidocaine spray. In difficult cases, previous instillation of 3 to 5 mL of 2% lidocaine solution through the nose may be useful. Phenylephrine as vasoconstrictor is advisable to apply in the nose. A sedative such as midazolam or diazepam may be employed. If the mouth opening is limited or restricted, transnasal approach would be the appropriate choice. Gentle manipulation from the operator is required in patients with spontaneous breathing. Before initiating the procedure, the FFB is previously inserted into the selected endotracheal tube as recommended by Stubb and McDougal,<sup>17</sup> then is introduced through the mouth or nose .Instillation of lidocaine solution in the working channel is useful to avoid cough and nausea. Once the FFB is in the trachea the tube is slided over the endoscope. The FFB is removed and the tube is left in the trachea. Manipulation and transport of the patient must be done with extreme care to prevent an unexpected extubation. The approach with a nasopharyngeal trumpet to the glottis followed by the insertion of the FFB and the tube in the trachea may also be used.<sup>18</sup> Basic endoscopic equipment must always be available (Table 1).

1. Every operating room or intensive care unit must have the facilities for intubation under bronchoscopic visualization: FFB of different lengths and diameters should be available. FFB Olympus P60 and 1T60 with 6.0 mm outer diameter or MP60 4.4 mm are suitable in the majority of cases. Ultraslim 3C40 of 3,6 mm and N20 with 2.2 mm are used in cases with major grade of glottic stenoses. All endoscopic instruments must be tested to verify their good conditions.
2. Portable light source of halogen or xenon.
3. Tracheal tubes of different diameters must be available (4.0 mm to 10 mm) (Rush-Magill). Also, armored PVC spiral tubes must be considered.
4. Lidocaine solution 2%-4%. Lubricating the FFB with with lidocaine 2% gel warrants the sliding of the endoscope inside the tube.
5. Neuromuscular relaxants and sedatives.
6. Suction devices: A Yankauer cannula connected to a suction power source.
7. Tracheostomy cannulae, may be percutaneous, with proper equipment for its insertion in cases of impossible intubation.
8. Cardiac arrest equipment is always important

Table 1. Portable airway trolley: Basic equipment

6. Intubation with the patient under general anesthesia

Intubation under general anesthesia always requires 100% oxygen supply with an adaptor or jet injection device. It must be done carefully and quickly. Careful head and neck immobilization is necessary, preferably through oral access if there are no contraindications.

7. Emergency intubation after failure to intubate by direct laryngoscopy

This event occurs in the operating room. The patient must be oxygenated as quickly as possible. Monitoring by oximetry and capnography must be maintained. The head must be immobilized with a pillow placed under the neck. The bronchoscopist immediately introduces the FFB by mouth or nose, previously inserted in the selected tracheal tube and well lubricated. The FFB must be introduced until the glottis can be seen and the instrument inserted and the tracheal lumen visualized. The tube is slide gently and introduced into the trachea until reaching the distal tip of the FFB. Together these are pushed into the tracheal lumen, reaching the middle third of the trachea. The tube should be fixed firmly at the face of the patient before the FFB can be withdrawn (Table 2).

1.	Selecting FFB and endotracheal tube
2.	Insertion of the FFB into the lumen of the tracheal tube (lubrication is essential).
3.	Introduction of the FFB through the nose or oral cavity with a mouthguard.
4.	Advance of the FFB until the glottis is visible.
5.	Introduction of the FFB into the trachea.
6.	Slide the tube until reaching the distal tip of the FFB.
7.	Introduction of the FFB and the tube until reaching the middle third of the trachea.
8.	Extraction of the FFB, retaining the tube within the trachea.
9.	Fixation of the tube to the face, avoiding unplanned extubation.
10.	Finally, tracheal tube is immediately connected to the oxygen source.

Note: All steps must be done gently and quickly to recover efficient ventilation of the patient.

Table 2. Technique for tracheal intubation with FFB

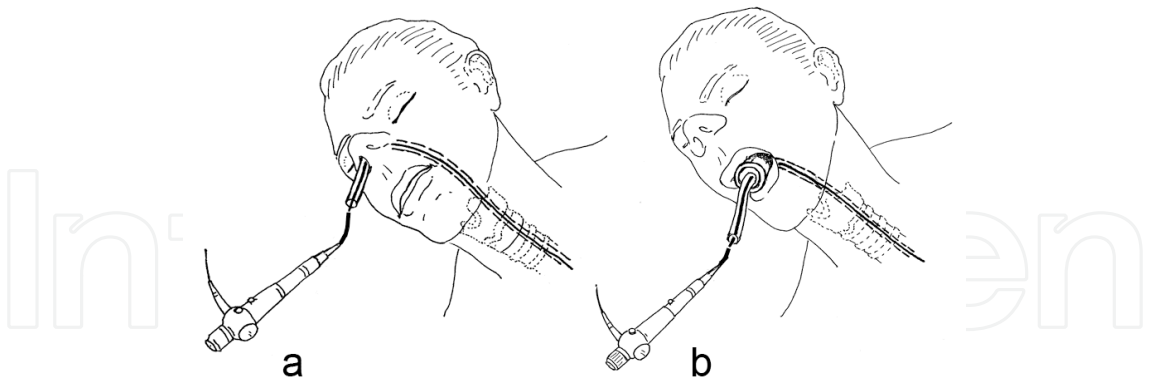


Fig. 3. Introduction of the FFB and the tracheal tube through the nose a) or mouth b) for FFB endotracheal intubation. The FFB is inserted in the tube.

8. Intubation in the ICU and emergency department

Failure to intubate occurred in 0.07% to 3.4% of all intubation attempts in the ICU.<sup>19</sup> Critically ill patients are unstable, cannot cooperate, and have no prior airway assessment. Some difficulties arise because the patient is surrounded by monitoring and mechanical respiration devices. The bronchoscopist may be in a cumbersome bedside situation at the



time of the maneuver with the FFB. Use of neuromuscular blocking agents, induction drugs as etomidate, lidocaine and scopolamine are recommended.<sup>20</sup> An assistant must hold the endotracheal tube to prevent unplanned extubation. Despite these difficulties, the FFB can be easily introduced in the majority of cases. The FFB must be removed immediately after a successful tracheal intubation to prevent oxygen desaturation and increase of partial pressure of carbon dioxide (PaCO<sub>2</sub>) because the presence of the endoscope within the endotracheal tube may obstruct proper ventilation.<sup>21,22,23</sup>

## **9. Oral or transnasal bronchoscopy?**

Oral access has the advantage of introducing tubes with wider diameters. Transnasal approach requires the use of more thin tubes. These procedures are well tolerated and comfortable for the patient.

## **10. Patient recovery**

Tracheal tubes cannot be removed until the patient is completely recovered with an effective cough reflex. If the patient must remain intubated, a bronchoscopic examination for testing the patency of the tube is indicated.

## **11. Complications**

Use of FFB in tracheal intubation is generally safe. Epistaxis is a relatively common problem in transnasal insertion. Injury of the retropharyngeal wall, epiglottis or vocal cords may occur. Rarely, the working channel may be obstructed by thick secretions or clots. Laryngospasm, bronchospasm, nausea, vomiting, tachycardia and bradycardia due to vagal reflex may also be present.

Endoscopes can be damaged with improper manipulation.

## **12. Contraindications**

If it is not possible to introduce the FFB in laryngeal and tracheal stenosis it is contraindicated to attempt FFB intubation. If a narrow tracheal channel persists, thin catheters may be introduced with the aid of an ultrathin FFB.

## **13. Removing the tracheal tube**

Before removing a tracheal tube, a bronchoscopic examination may be required in order to identify complications related to intubation. It is advisable to remove the tube with the FFB inside to allow visualization of the complete tracheal lumen. Reintubation is a risk that must be taken into consideration in extremely difficult cases. Chest X-ray is advisable after extubation.

## **14. Advantages of using the FFB**

FOB intubation is a nontraumatic procedure. Injury is a rare complication during careful introduction of the FFB and tracheal tube. Manipulation by a trained bronchoscopist generally is rapid and safe.

## 15. Conclusions

All patients classified as having a difficult airway must be considered as potential candidates for endotracheal intubation with FFB as well as patients with failed intubation in anesthesia, intensive care unit and the emergency department. Bronchoscopy must be performed by an experienced and skilled endoscopist. There is a high rate of success using this technique.

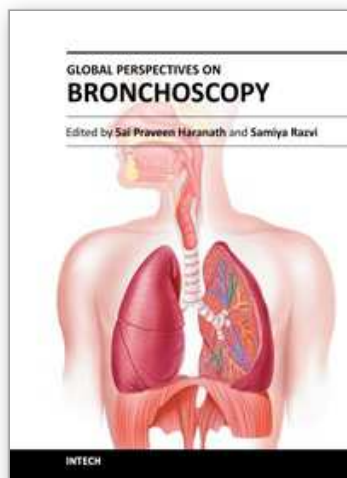
## 16. References

- [1] Jabob AK, Kopp SL, Bacon DR, Smith HM. History of Anesthesia. In "Clinical Anesthesia" 6<sup>th</sup> ed. Barash PG, Cullen BK, Stoelting RK, Cahalan MK, Stock MG Editors. Philadelphia. Lippincott, William & Wilkins. Wolter Kluwer Business. 2009; pp. 3-26
- [2] Brendan T, Finucane T, Santora AH. Principles of airway management. 3<sup>rd</sup> ed. New York, Springer Verlag; 2003. pp. 214-254
- [3] Cook TM, Woodall N, Frerk C. Major complications of airway management in the UK. Results of the Fourth National Audit Project of the Royal College of Anaesthetists and the Difficult Airway Society. Part 1: Anaesthesia. Br J Anaesth 2011;106:617-631.
- [4] Burke C, Walsh MT, Harrison BA, Curry TB, Rose BH. Airway management after failure to intubate by direct laryngoscopy: outcomes in a large teaching hospital. Can J Anesth 2006;52:634-640.
- [5] Cormack RS, Lehane J. Difficult tracheal intubation in obstetrics. Anaesthesia 1984;39:1105-1111.
- [6] American Society of Anesthesiologists. Practice guidelines for management of the difficult airway. An updated report by the American Society of Anesthesiologist Task Force on Management of the Difficult Airway. Anesthesiology (Special article) 2003;98:1269-1277.
- [7] Samsoon GLT, Young JRB. Difficult tracheal intubation: a retrospective study. Anesth Analg 1987; 42:487-490.
- [8] Wilson MF, Spiegelhalter D, Robertson JA, Lesser P. Predicting difficult intubation. Br J Anaesth 1988;61:211-216.
- [9] Bair AE, Caravelli R, Tyler K. Feasibility of the preoperative Mallampati airway assessment in emergency department patients. J Emerg Med 2011;38:677-680.
- [10] Mallampati SR, Gatt SP, Guggino LD, Desair S, Waraska B, Freiburger D. A clinical sign to predict difficult tracheal intubation. A prospective study. Can Anaesth Soc J 1985;32:429-434.
- [11] Lee A, Fan LTY, Gin T, Karmakar MK, Kee WDN. A systematic review (meta-analysis) of the accuracy of the Mallampati tests to predict the difficult airway. Anesth Analg 2006;102:1867-1878.
- [12] Connor C, Segal S. Accurate classification of difficult intubation by computerized facial analysis. Anesth Analg 2011;112:84-93.
- [13] Elizondo E, Navarro F, Pérez-Romo A, Ortega C, Muñoz H, Cicero R. Endotracheal intubation with flexible fiberoptic bronchoscopy in patients with abnormal anatomic conditions of the head and neck. Ear Nose Throat J 2007;86:682-684.



- [14] Orozco-Díaz E, Álvares-Ríos JJ, Arceo-Díaz JL, Ornelas-Aguirre JM. Predictive factors of difficult airway with known assessment scales. *Cir Cir* 2010;78:393-399.
- [15] Serocki G, Bein B, Scholz J, Dörge V. Management of the predicted difficult airway: a comparison of conventional blade laryngoscopy with video-assisted blade laryngoscopy and the GlideScope. *Eur J Anaesthesiol* 2010;27:24-30.
- [16] van Zwan JP, Kapteijns EFG, Lahey S, Smit HJM. Flexible bronchoscopy in supine or sitting position. A randomized prospective analysis of safety and patient comfort. *J Bronchol Intervent Pulmonol* 2010;17:29-32.
- [17] Stubb SE, McDougall. Preparation of the patient for bronchoscopy. In *Bronchoscopy*. Ed. UBS Prakash. New York. Raven Press; 1995. p. 109.
- [18] Heir JS, Kupferman ME. A simple approach to facilitating fiberoptic intubation in the difficult airway. *Laryngoscope* 2011;121:310-312.
- [19] Fragoso Guerreiro da Cunha E, Rosal Gonçalves JM. Role of fiber optic bronchoscopy in intensive care unit: current practice. *J Bronchol Intervent Pulmonol* 2011;18:68-69.
- [20] Reynolds SF, Heffner J. Airway management of the critically ill patient. *Chest* 2005;127:1397-1412.
- [21] Cook TM, Woodall N, Benjer J. Major complications of airway management in the UK. Results of the Fourth National Audit Project of the Royal College of Anaesthetist and the Difficult Airway Society. Part 2: Intensive care and emergency departments. *Br J Anaesth* 2011;106:632-642.
- [22] Tai DYH. Bronchoscopy in the intensive care unit. *Ann Acad Med* 1998;27:552-558.
- [23] Phua GC, Wahif MM. ICU procedures in the critically ill. *Respirology* 2009;14:1092-1097.

IntechOpen



## **Global Perspectives on Bronchoscopy**

Edited by Dr. Sai P. Haranath

ISBN 978-953-51-0642-5

Hard cover, 240 pages

**Publisher** InTech

**Published online** 13, June, 2012

**Published in print edition** June, 2012

Bronchoscopy has become an essential part of modern medicine . Recent advances in technology have allowed integration of ultrasound with this tool. The use of lasers along with bronchoscopes has increased the therapeutic utility of this device. Globally an increasing number of pulmonary specialists, anaesthesiologists and thoracic surgeons are using the bronchoscope to expedite diagnosis and treatment. The current volume on bronchoscopy adds to the vast body of knowledge on this topic. The democratic online access to this body of knowledge will greatly increase the ease with which both trainees and expert bronchoscopists can learn more .The contributions from around the world cover the breadth of this field and includes cutting edge uses as well as a section on pediatric bronchoscopy . The book has been an effort by excellent authors and editors and will surely be a often reviewed addition to your digital bookshelf. . In summary, this book is a great testament to the power of collaboration and is a superb resource for doctors in training, ancillary team members as well as practicing healthcare providers who have to perform or arrange for bronchoscopy or the associated procedures.

### **How to reference**

In order to correctly reference this scholarly work, feel free to copy and paste the following:

Francisco Navarro, Raúl Cicero and Andrea Colli (2012). Endotracheal Intubation with Flexible Fiberoptic Bronchoscope (FFB) in Cases of Difficult Airway, Global Perspectives on Bronchoscopy, Dr. Sai P. Haranath (Ed.), ISBN: 978-953-51-0642-5, InTech, Available from: <http://www.intechopen.com/books/global-perspectives-on-bronchoscopy/endotracheal-intubation-with-flexible-fiberoptic-bronchoscope-ffb-in-cases-of-difficult-airway>

**INTech**  
open science | open minds

### **InTech Europe**

University Campus STeP Ri  
Slavka Krautzeka 83/A  
51000 Rijeka, Croatia  
Phone: +385 (51) 770 447  
Fax: +385 (51) 686 166  
[www.intechopen.com](http://www.intechopen.com)

### **InTech China**

Unit 405, Office Block, Hotel Equatorial Shanghai  
No.65, Yan An Road (West), Shanghai, 200040, China  
中国上海市延安西路65号上海国际贵都大饭店办公楼405单元  
Phone: +86-21-62489820  
Fax: +86-21-62489821

© 2012 The Author(s). Licensee IntechOpen. This is an open access article distributed under the terms of the [Creative Commons Attribution 3.0 License](https://creativecommons.org/licenses/by/3.0/), which permits unrestricted use, distribution, and reproduction in any medium, provided the original work is properly cited.

IntechOpen

IntechOpen