

We are IntechOpen, the world's leading publisher of Open Access books Built by scientists, for scientists

6,900

Open access books available

185,000

International authors and editors

200M

Downloads

Our authors are among the

154

Countries delivered to

TOP 1%

most cited scientists

12.2%

Contributors from top 500 universities



WEB OF SCIENCE™

Selection of our books indexed in the Book Citation Index
in Web of Science™ Core Collection (BKCI)

Interested in publishing with us?
Contact book.department@intechopen.com

Numbers displayed above are based on latest data collected.
For more information visit www.intechopen.com



Anatomical and Surgical Perspective to Approach Degenerative Disc Hernias

H. Selim Karabekir¹, Nuket Gocmen-Mas² and Mete Edizer³

¹*Department of Neurosurgery, Kocatepe University School of Medicine, Afyonkarahisar,*

²*Department of Anatomy, Faculty of Medicine, Kocatepe University, Afyonkarahisar,*

³*Department of Anatomy, Faculty of Medicine, Dokuz Eylul University, Izmir, Turkey*

1. Introduction

The anatomy of the vertebral column is very important for neurosurgeons, orthopedists, traumatologists, neurologists, radiologists, anesthesiologists and pathologists to aid in diagnosis, treatment, planning surgery, and the application of anesthesia or surgery (Winn, 2004).

Intervertebral discs are placed on between adjacent surfaces of vertebral bodies from axis to sacrum. There is no intervertebral disc between atlas and axis. The lowest functional intervertebral disc is located between fifth lumbar (L5) and sacrum. Thicknesses of the discs show variations in different regions and part of the same disc. They are thicker anteriorly and the anterior convexity is obvious in lumbar and cervical regions, but they are nearly uniform and the anterior concavity is large due to vertebral bodies in the thoracic region. In the upper thoracic region, discs are thinnest, but they thickest in the lumbar region. Intervertebral discs are avascular. They supplied by diffusion through the trabecular bone of nearby vertebrae. In brief, discs supplied from neighborhood blood vessels, except for their periphers. Vascular and avascular parts of discs show different reaction to injury.

Radicular damages related with degenerative disc hernias negatively affect innervation area of the spinal nerves, sensibility and ability of the patients to translate patterns of altered nerves activity into meaningful motor behaviors. The sensory or motor alterations can be attributed to functional or anatomical changes within the nerve roots after resolution of inflammation and edema and also surrounding of the nerves (Chaichana et al., 2011; Van Zundert et al., 2010; Lipetz, 2002).

2. Anatomy of vertebral column

2.1 Embriology

Vertebrae develop from the sclerotome parts of the somites, which are undergone, a change from the paraaxial mesoderm. A typical vertebra forms a vertebral arch and foramen, a body, transverse process, and usually a spinous process. Sclerotome cells move around the spinal cord and notochord to merge with cells from the opposing somite on the

opposite side of the neural tube during the fourth week. As development continues, the sclerotome part of each somite also transposes a resegmentation. Resegmentation means as growing and blending of the caudal half of each sclerotome with the cephalic half of each subjacent sclerotome. So, each vertebra is combined between the caudal half of one somite and the cranial half of its neighbor. Modeling of the shapes of the different vertebrae is modulated by HOX genes (Sadler, 2006). Hox genes were defined to be involved in the manufacture of vertebrae with individual properties (Krumlauf 1994; Wellik 2007; Mallo et al., 2009). Mesenchymal cells which placed between two caudal parts of the sclerotome segment and fill the space between two precartilaginous vertebral bodies. In this way, they form the intervertebral discs. Although the notochord regresses entirely in the region of the vertebral bodies, it asserts and expands in the disc space. It supports the nucleus pulposus, which is covered loop shaped fibers of the annulus fibrosus. These two structures compose the intervertebral disc together (Sadler, 2006; Moore, 1992; Williams et al, 1995; Snell, 1997; April, 1990)

Resegmentation of sclerotomes into descriptive vertebrae cause the myotomes to bridge the intervertebral discs. This differentiation gains the discs spine motion capacity. Due to this development, intersegmental arteries, at first placed between the sclerotomes, to come to pass midway over the vertebral bodies (Sadler, 2006). Spinal nerves go to near the intervertebral discs and exit from the intervertebral foramina to leave vertebral column at that level (Moore, 1992; Williams et al, 1995; Snell, 1997; April, 1990).

2.2 Vertebral morphology

The vertebral column compose 33-34 number of vertebrae which are seven cervical, twelve thoracic, five lumbar vertebrae, a sacrum and three to five coccygeal vertebrae (Standrings et al, 2005; Williams et al, 1995). Each typical vertebra has a ventral body (except atlas) and dorsal vertebral arch, together enclosing a vertebral foramen. The adjacent bodies are attached together by intervertebral discs. The foramina form a vertebral canal for spinal cord. Intervertebral foramina which are located between adjoining vertebral arches, allow transmit spinal nerves, blood and lymphatic vessels. The vertebral body varies in size according to its level on vertebral column. The vertebral arch has one each side anteriorly the *pedicle*, and posteriorly the *lamina*. It also has paired transverse, superior and inferior articular processes and posteriorly a median spinous process. The pedicles are thick, short vertically narrower parts. Adjacent vertebral notches assist to an intervertebral foramen when vertebrae are articulated by the intervertebral discs. The laminae which directly continuous with pedicles are vertically broader flattened parts. The articular processes which are named as zygoapophyses joint compose paired superior and inferior articular processes. The superior ones locate on cranially, and the inferior ones caudally. Articular processes of adjoining vertebrae thus form synovial zygoapophyses joints together. These joints permit limited movement between vertebrae. The transverse processes project laterally. Only the thoracic transverse processes articulate with the ribs via their articular faces. The spinous process projects posteriorly and often caudally from the laminal junction. The spines vary in size, shape and directions according to vertebral level.

There are some regional features and differences of vertebrae. Vertebrae in different regions of the vertebral column show some modified characteristics from the typical pattern. There are conspicuous varieties in the size of the vertebral foramina in the same regions of

different persons. There are also differences in the size and shape of the vertebral canal. These variations occur because of the spinal cord enlargements in the cervical and lumbosacral regions for the innervations of the limbs via plexuses (Moore, 1992).

Distinctive characterization of the cervical vertebrae is the oval shaped foramen transversarium. The vertebral arteries pass through the foramina in the transverse process, except those in prominent vertebra (C7) which lie only small accessory vertebral veins. Each of the processes has anterior and posterior tubercles on their upper surfaces. The groove for the spinal nerves locates between the tubercles from third cervical vertebra (C3) to C7 vertebrae, bilaterally. The anterior tubercle of sixth cervical vertebra (C6) which is named as carotic tubercle is bigger than the others. Due to large size of the tubercle, it may compress the common carotic artery. The spinous processes of C3 to C6 vertebrae are short and bifid. The spinous process of C7 is very long, so it is also important as an anatomical landmark for clinicians.

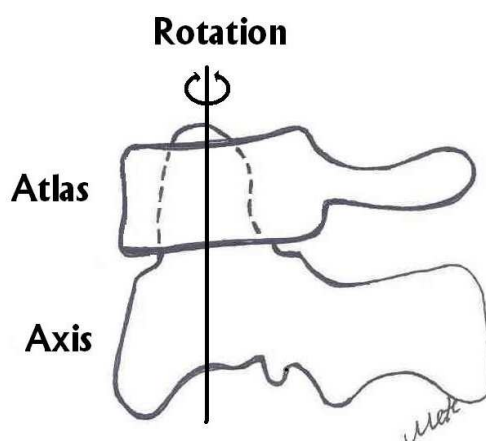


Fig. 1. The relationship between atlas and axis were shown while rotation (Illustrated by Edizer).

Atlas (C1) and axis (C2) are atypical vertebrae. C1 is a ring-shaped bone. The kidney-shaped, concave superior articular surfaces of C1 have the occipital condyles. The atlas has no spinous process or body; it has anterior and posterior arches. Each of the arch consists a tubercle and a lateral mass which is named as massa lateralis atlantis. C2 is named as axis and the skull rotates on it. The axis consists two large flat bearing the superior articular facets upon which the atlas rotates (Figure 1). Its distinguishing characteristic, however, is the blunt tooth-like dens which are called as odontoid process; place on superiorly from its body. The transverse ligament of the atlas supports dens for its position and prevents horizontal displacement of the atlas (Moore, 1992).

Distinctive features of the thoracic vertebrae are existence of the fovea costalis to articulate with the ribs (Figure 2). Adjoining upper and lower costal fovea and also intervertebral disc together articulate with fovea costalis of a rib. The thoracic vertebra has a small nearly oval foramen vertebra. The spinous processes of the thoracic vertebrae are long and slender. The middle ones are directed inferiorly over the vertebral arches of the inferior vertebrae to them. But the laminae are short, broad and thick. The spinous process is long and oblique shaped and lies inferiorly. The transverse processes which are large, strong and club-like, project from the vertebral arch at pediculolaminar junctions. They point dorsolaterally, near

their apex, ventral oval facets articulating with tubercles of corresponding ribs. The eleventh and the twelfth thoracic vertebrae have not the costal tubercles.

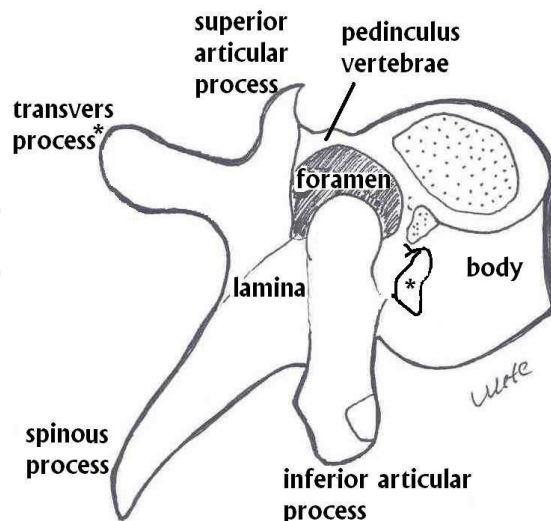


Fig. 2. Typical thoracic vertebra was shown (Illustrated by Edizer)

Differences of the lumbar vertebrae are their large size, absence of costal facets and transverse foramina (Moore, 1992). The body is big, thick and kidney shaped. The vertebral foramen is triangular shaped. The pedicles are short and the spinous process is nearly horizontal, quadrangular shaped and thick. L5 is distinct to its stout transverse processes. It is mostly amenable for the lumbosacral angle between the lumbar region and sacrum.

The sacrum which is fused by five vertebrae is a large, triangular shaped bone. It locates behind the pelvis and between two of the coxae. Its blunted, caudal tip articulates with the coccyx and its upper wide base articulates with the fifth lumbar vertebra. It consists dorsal, pelvic and lateral surfaces and a sacral canal between the apex and the base. Anterior projecting edge of the base is the sacral promontory. Four pairs of anterior sacral foramina place on the pelvic (anterior) surface. The ventral rami of the upper four sacral spinal nerves transmit through intervertebral foramina with the sacral canal via the pelvic sacral foramina. Similarly, four pairs of dorsal sacral foramina locate on the dorsal surface. The lateral surface projects as a broad articular part. Its upper parts have auricular surfaces, bilaterally. The sacral canal forms by sacral vertebral foramina. Its caudal opening is called as sacral hiatus. The canal contains the cauda equina including its flum terminale and spinal meninges. The coccyx is a small triangle bone. It usually consists of three to five fused rudimentary vertebrae (Williams et al, 1995; Moore, 1992).

As a conclusion the vertebral architecture is significant as it combine stability, load-bearing capacity and motor function and also covers contained neurovascular structures such as vessels, spinal nerves, irrespective of its position (Williams et al, 1995). Regional variants can see in mobility of the verterbrae on the geometry, position, placement and properties of both zygoapophysial joints and related ligaments around the column. The ligament flava, interspinous, supraspinous and posterior longitudinal ligaments and posterior margin of intervertebral disc are tensed, interlaminar intervals wider, inferior facet glide on superior facet of subjacent vertebrae and their capsules become taut.

2.3 Intervertebral disc morphology

The discs are composed of circular anuli fibrosi covering gelatinous nuclei pulposi. The anuli fibrosi insert into compact bony edges on articular face of the vertebral bodies. It has a narrow outer collagen zone and a wider inner fibrocartilaginous zone. The annulus fibrosus consists of concentric lamellae of collagenous fibers which lie obliquely from one vertebra to the other (Figure 3). The lamellae are less numerous posteriorly and thinner than they are anteriorly and laterally. The nuclei pulposi contact the hyaline articular cartilages, which are attached to endplates of the bodies. It is large, soft and gelatinous and mucoid materials with a multinucleated notochordal cell at birth. The cells disappear in the first decade followed by gradual replacement of mucoid material by fibrocartilage derived principally from the annulus fibrosus and the hyaline cartilaginous plates adjoining vertebral bodies. The nucleus pulposus is better developed in cervical and lumbar regions. It behaves toward like shock absorber for axial forces and like water bed bearing during flexion, extension and lateral bending of the vertebral column. The water content of nucleus pulposus is about 88% and its turgor and also fullness is great in the young adults. Discs are more often damaged by twisting and flexing the vertebral column. The intervertebral discs are so strong that violence first damages the neighborhood bone in young adults. It is possible to damage a healthy disc by forcible flexion as well as extension. Degenerative changes on discs may result in necrosis, sequestration of the nucleus pulposus, weakening or softening of annulus fibrosus after second decade. Then minor strains may cause internal disharmony with eccentric displacement of the nucleus pulposus. The minor strains may also cause external disharmony. In this case, the nucleus pulposus than bulges through annulus fibrosus may occur usually posterolaterally. The discs are also show pathological changes that may result in protrusion of nucleus pulposus through the annulus fibrosus known as a herniated or prolapsed disc. As people getting older, the nuclei pulposi lose their turgor and become thinner due to degeneration and dehydration. Symptom producing disc herniations happen in the cervical region almost as in the lumbar region. In geriatric ages, degenerative changes may occur in the discs because of relatively minor stress.

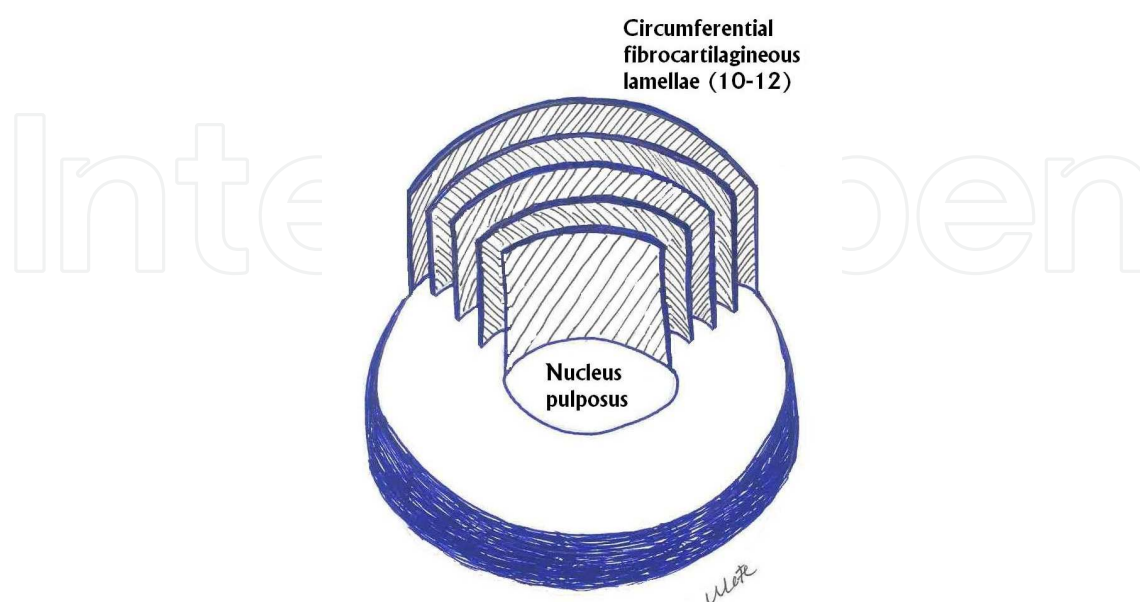


Fig. 3. Structural demonstration of an intervertebral disc (Illustrated by Edizer).

The discs support by anterior and posterior longitudinal ligaments. These ligaments lie throughout vertebral column. The anterior longitudinal ligament holds on the vertebral bodies strongly, but it adheres to the intervertebral disc tenderly. It originates from occipital bone and lies to sacral canal. Despite to anterior longitudinal ligament, the posterior longitudinal ligament which is the principal, but narrow ligament of intervertebral discs to each other adheres to the intervertebral discs strongly. The posterior surface of the vertebral bodies have a little concave shape, so while the posterior longitudinal ligament lies from one body to the other adhere with loose connective tissue in the canal (Figure 4) (Moore, 1992; Williams et al,1995 ; Snell, 1997; April, 1990).

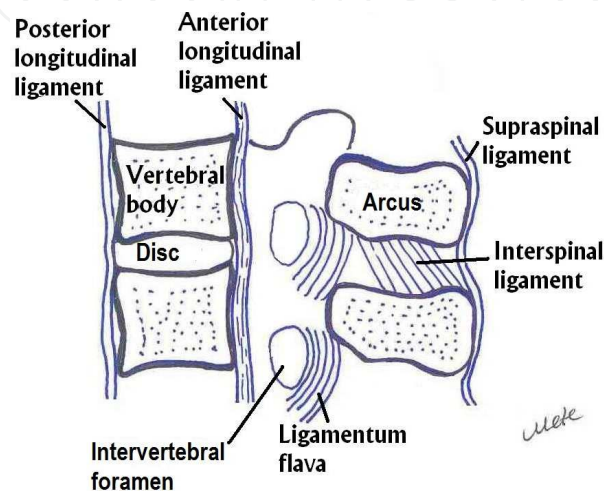


Fig. 4. Vertebral column and related ligaments were shown (Illustrated by Edizer).

2.4 Spinal nerve morphology

There are 31 pairs of the spinal nerves as eight cervical, twelve thoracic, five lumbar, five sacral and a coccygeal, bilaterally. They originate through intervertebral foramina for each level. However, the first spinal nerve leaves the vertebral canal between atlas and the occipital bone, bilaterally. So, the nerve is named as the suboccipital nerve. Each of the nerve is continuous with the spinal cord by the anterior (ventral) and posterior (dorsal) roots, the latter each bearing a spinal ganglion (Taner D, 2004; Van de Graaf, 1998; Williams et al, 1995; Moore, 1992). The anterior roots compose axons of neurons in the anterior and lateral spinal grey columns. The posterior roots also contain centripetal process of neurons sited in the spinal ganglia. The spinal nerves have clinically significant relations in the vertebral foramina. The relations are anteriorly, with the intervertebral discs and adjacent vertebral bodies. Posterior are the zygapophysial joints. Superior and inferior are vertebral notches of the pedicles of adjoining vertebrae. Each of the spinal nerve accompanied by a spinal artery, a small venous plexus and its meningeal branch or branches together traverse a foramen (Williams et al, 1995). Dorsal (posterior) rami of spinal nerves, usually smaller than the ventral (anterior) and directed posteriorly divide into medial and lateral branches (except for the first cervical, fourth and fifth sacral and coccygeal nerves) to innervate the muscles and skin of the posterior regions of the neck and trunk. The ventral rami of spinal nerves innervate the limbs and the anterolateral aspect of the trunk, they are mostly larger than the dorsal rami. The thoracic nerves are independent and retain, like all dorsal rami, mostly segmental distribution. The cervical, lumbar and sacral spinal nerves connect near their

origins to form plexuses like cervical plexus in cervical region, brachial plexus in lower cervical and thoracic region and lumbosacral plexus in lumbosacral region, which are called as the peripheric nerves. Dorsal rami do not join these plexuses (Williams et al, 1995).

The spinal nerves might be compressed by herniated discs. Because of the protrusion and compression, the patients suffer from chronic pain symptom. All symptoms and signs occur usually on the same side as the herniation but sometimes the cases have contralateral side pain symptom, which leads to the fact that operators are in doubt about the decision to perform disc surgery. In the literature the possible mechanism of contralateral pain symptoms may occur due to hypertrophy of ligamenta flava (Karabekir et al 2010). So, surgeons should take care for anatomical landmarks related with ligamentous complex during surgery.

3. Degenerative disc hernias

3.1 Description and scope

Degenerative disc disease (DDD) occurs when the outer ring, annulus fibrosus, is damaged or worn. The contents of the disc may then protrude or impinge on a spinal root. This will cause pain in the lower back and that radiates to the hips and down the back of the legs. Backpain is an unpleasant and noxious sensation of varying severity localized in different regions of the back. The simplified etiologic or pathogenetic classification of back pain includes myofascial, articular (including degenerative disc changes), and neurogenic components. Because of increased incidence of low back pain (LBP) or lumbosacral radicular syndrome, low back pain becomes a serious problem for healthy and active individuals between the ages 30-50.

If a degenerative disc hernia is obtained then simple discectomy is offered to the individuals. Nevertheless there are some problems followed by degenerative disc disease operations such as recurrence, loss of height and instability. The most effective treatment of discogenic pain to unresponsive to conservative care is interbody fusion in the literature (Karabekir et al, 2008).

The development of molecular biology enabled a better understanding of the processes that caused the degenerative disease of intervertebral discs. Many studies aiming to clarify the causes and risk factors for this degenerative disorder have been performed (Patel et al, 2007). It is now known that degenerative disc disease is strongly correlated to genetic factors, investigations indicating that heredity has a major role for degeneration of disc and implies approximately 74% in adult populations, as a variation. Since 1998 there were many genes associated with degenerative disc hernias declared such as MMP-3, VDR, collagen I, collagen IX (COL9A2 and COL9A3), collagen XI (COL11A2), vitamin D receptor, IL-1, IL-6, CILP, and aggrecan (Cevei et al 2011).

When the outer ring, annulus fibrosus, is damaged because of aging and/or degeneration, the degenerative disc disease occurs (Figure 5). Then, the contents of the disc may protrude or impinge on a spinal root, unilaterally or sometimes bilaterally. This process will cause pain in the lower back and that radiates to the hips and down the back of the legs. At the same time degenerative disc disease may cause segmental instability due to following ligamentous laxity, fall in the amount of the nucleus pulposus, and loss of disc height.

Segmental instability which appears as aberrant vertebral motion may be accountable for the pain. Low back pain may arise from the facet joints, but various clinical outcomes have not verified this theory (Marks et al, 1992; Schwarzerger et al, 1994; 1994).

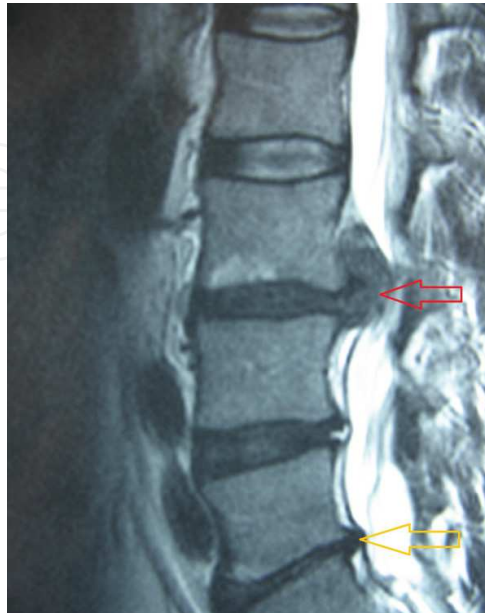

Fig. 5. An extrude disc hernia was shown by the red arrow and degenerative disc hernia was shown by the yellow one

Low back pain can unpleasantly appear in different regions of the back. The pathogenetic classification of low back pain divides into three types as myofascial, articular (including degenerative disc changes), and neurogenic. Back pain can cause several problems. It can effect healthy, active individuals between 30 and 50 years old. Invasive treatment options for chronic LBP are mostly tried after conservative cures have failed to obtain the desired results (Buric et al, 2011). Fusion and total disc arthroplasty are the most frequent surgical procedure to treat LBP caused by DDD with or without segmental instability. Nonetheless, the clinical achievement of fusion varies widely (16–95%) and to relate principally with the indication value being used (Turner et al, 1992; 1993; Waddel et al, 2000). Cases who undergo spinal fusions or total disc replacement mostly have more complications, longer stay in hospital and higher charges from hospital than cases undergoing other types of operation. LBP is usually resulting from mechanical reasons like load, which may initiate internal disc degeneration and trigger loss of water from the nucleus pulposus. The consecutive step of degenerative episode gives rise to a decline in disc height, narrowing of the intervertebral space, and non-organized facet joints. These episodes disturb anatomical and physiological motion between two neighborhood vertebrae and increase instability due to laxity of the ligaments and the annulus fibrosus (Buric et al, 2011).

Modic firstly delineated classifications of lumbar spine degeneration via imaging technique (Hutton et al, 2011). The author classified the cases as grade I, II or III using MRI. According to his follow up results, MRI changes compose of vertebral bodies parallel with the vertebral plateau of degenerated disc which indicates hyposignal on the slices in T1 and hyperintensity in T2 for Type I. The changes of MRI composed of risen intensity of the signal on the images in T1 and an isointense signal or lightly hyperintense in T2 and

represent the imagistic expression of disc lesions consisting of annular protrusion and comparatively recent initial beginning disc hernia for Type II. Both Type I and II have not a radiological correspondent. MRI investigations revealing type III changes, represent decreasing intensity of the signal on the slices both in T1 and T2, being related on regular planar radiographic slices with extensive bone sclerosis. Those changes are related with disc extrusion, disc hernia, free disc fragment, problems of the posterior vertebral ligament (Gocmen-Mas, 2010; Karabekir et al, 2010). The composition of the disc changes during development, growth, ageing and degeneration and this impress the response of the disc to changes in mechanical stress (Cevei et al 2011; Modic, 2007).

Diagnosis of degenerative disc disease is confirmed by MRI scans (West et al, 2010). Direct x-rays, especially planar flexion-extension radiographies may help to recognize instability which develops because of degenerative disc disease. Discography is also important for diagnostic survey of the degenerative disc disease.

4. Treatment modalities of degenerative disc hernias

4.1 Surgical procedures

In biomechanical respect posterior lumbar interbody fusion (PLIF), introduced by Dr.Ralph Cloward in the 1940.s, is an optimal fusion. A succesful PLIF carries the advantages of immobilizing the unstable degenerated intervertebral disc area, decompressing the dural sac and nerve roots, restoring disc height and load bearing to anterior structures. In spite of a lot of fusion techniques, such as autologous iliac crest bone graft, allograft bone, dowelshaped graft, key stone graft, tricortical graft, and bone chips, interbody cages preferred. There is various types of cages, carbon-titanium-polyetherether keton etc., are used for interbody fusion (Figure 2-5). In our daily practice we prefered polyetherether keton (PEEK) cages because of their safety usage and wide graft space contains (Karabekir et al, 2009).




Fig. 6. Samples of expandable PEEK cages; A. Cervical, B. Lumbal




Fig. 7. Samples of the intervertebral cages; A. B-twin, B. B-D PEEK cages, E-F. Cylendiric titanium cages.

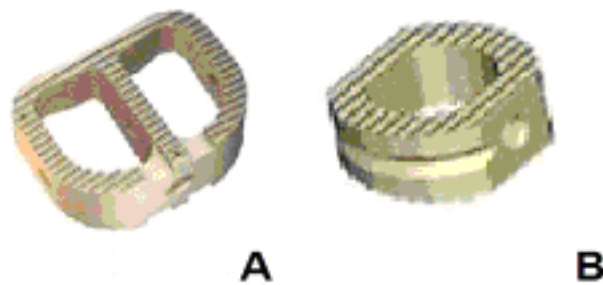


Fig. 8. Samples of the cervical PEEK cages (A and B)




Fig. 9. A sample of the carbon intervertebral cage

PLIF usually has been accomplished with implantation of two threaded cages (Bagby, 1988). The rate of fusion of bone grafts alone have ranged from 46% to 90% at the literature. Because of difficulty in maintaining spinal stabilization and achieving fusion, spinal instrumentation has become an important and popular adjunct to bone grafting in lumbar arthrodesis, further increasing the fusion rates, 80-90% (Karabekir et al, 2009).

More recently, interbody fusion techniques have also shown high fusion rates with distinct advantages (Lin et al, 1983; Ray, 1997). Some of these advantages include immediate anterior column load sharing, a large surface area for fusion, bone graft subjected to compressive loads that is advantageous in achieving fusion and the ability to restore normal sagittal contour while indirectly decompressing the intervertebral foramen (Lin et al, 1983). Interbody fusion technique also appear to be the most effective cure of discogenic back pain unresponsive to conservative care (Weatherly et al, 1986).

Blume, in 1981, described a unilateral approach for posterior lumbar interbody fusion to address some of the potential complications of the standard PLIF such as spinal nerves' roots injuries, and instabilization. The unilateral posterior lumbar interbody fusion (UPLIF) popularized by Harms et al (1997) is a surgical technique in which bilateral anterior column support can be achieved through a unilateral posterior approach.

Weatherly et al (1986) reported on five cases during a 10-year period who had solid posterolateral fusions, but still had positive discography under the fusion and had their back pain relieved by anterior interbody fusion.

Recently, Derby et al (1999) noted that cases with highly sensitive discs as determined by pressure controlled discography achieved significantly better long-term outcomes with combined anterior and posterior fusion.

Nevertheless, there are some problems followed by degenerative disc disease operations such as recurrence, lost of height and instability. Many authors develop some different surgical approaches for preventing the recurrence of disc herniation and to protect the disc height. Of these modified techniques, we prefer, in our daily practice consists of unilateral and bilateral polyetheretherketon (PEEK) posterior lumbar cages by using demineralized bone matrix (DBM) putty graft (Karabekir et al, 2008).

UPLIF is indicated for chronic mechanical pain associated with degenerative disc disease, recurrent disc herniation. With this concept recurrence of disc and the possibility of foraminal narrowing and loss of height can also be reduced. The most advantage of the PEEK cage is to preserve the disc space height and prevent the recurrence. Unilateral posterior PEEK cage application and fusion is a safe and reproducible technique to provide unilateral posterior column support (Karabekir et al, 2009). With this method, recurrence of the disc and the possibility of foraminal narrowing and loss of height can also be reduced (Karabekir et al 2008).

Although PLIF has shown satisfactory clinical outcomes in treatment of degenerative disc diseases, many studies have reported that accelerated adjacent segment degeneration (ASD) may occur after PLIF management, particularly at the rostral level (Kumar et al., 2001; Okuda et al., 2008; Park et al., 2004; Zencica et al., 2010; Chen et al., 2011).

There is controversial relationship between fusion surgery and adjacent segment degeneration. Battie et al (2004) declared that adjacent segment degeneration after fusion was a natural status that was not associated to the fusion surgery. However, some other investigators implied in vitro mechanical studies and found that lumbar fusion may increase abnormal intradiscal pressure and too much movement at the adjacent spinal levels, resulting in adjacent segment degeneration (Lee et al, 2009). Therefore, it appears that adjacent segment disease may be especially caused by the abnormal discal stresses distribution that occurred by lumbar fusion and fixation. The other serious complication of posterior fixation and fusion operations is damaging of the nerve roots because of the placement of pedicular implants from the posterior (Ebrahim et al, 1997). And also neuropathic pain associated with implant placement is not rare in literature. In the implantology literature, complications related to nerve are mentioned as 'sensory disturbances', focusing on the occurrence of paresthesia and dysesthesia, eventually accompanied by transitory pain sensations during implant placement (Ebrahim et al, 1997; Butt et al, 2007).

DDD and its related symptoms have classically been cured with spinal fusion where the affected vertebrae are immobilized with mechanical fasteners or cages. This method stabilizes the impressed segments and achieved pain recipe (Balsano et al, 2011; Gornet et al, 2011).

A modified PLIF method named as transforaminal lumbar interbody fusion (TLIF), was first defined in 1982. Because the bone graft can be inserted far laterally, the TLIF technique can be safely indicated for interbody fusion of the upper lumbar spine. Moreover, TLIF can be performed at any lumbar level below first lumbar vertebra (L1), because it avoids significant retraction of the dura and conus medullaris (Hioki et al, 2011).

The minimally invasive lateral transpsoas method to the lumbar spine such as extreme lateral interbody fusion (XLIF) and direct lateral interbody fusion (DLIF) occurs as an

alternative to interbody placement at levels L1 to L5 in the setting of spondylolisthesis, degenerative disc disease, and scoliotic or kyphotic anomalies (Benglis et al, 2008; Bergey et al, 2004; Cox et al, 2008; Dezawa et al, 2000; Mayer, 1997; Mc Afee et al 1998; Benglis et al, 2009).

But all of these approaches are not without complications. Outcomes of spinal fusion in a decreased range of movement and might caused a degenerative series in adjacent vertebral segments (Rahms, 1996). There have been many efforts to substitute the disc via various equipments for avoiding this and treating cases leaving its usual anatomic and physiologic movement (Balsano et al, 2011).

Recently, spinal movement preservation has so important in spine surgery as a potential planning to arrange a more normal spinal motion and providing against the biomechanical stress and a kinematic strain on nearby segments (Junjie et al, 2011). For protecting spinal motion an alternative to spinal fusion, total disc replacement (TDR) intervention is more and more becoming an adopted alternative for cases with degenerative disc disease. Theorically, the surgery carries on various benefits over spinal fusion, as it is desired to preserve mobilization and may diminish adjacent level degeneration. But, failures can make revision surgery a necessity for all kind of implant surgeries. McAfee et al (2009) report 8.8% revision procedures at the index level. Retrifcation of artificial discs is candidate to complications, because of revision surgery carries individual major risks for cases. McAfee et al (2009) claimed that a 3.6% incidence of vascular injury in primary TDR and 16.7% in anterior revision surgery. Revision surgery is usually applied to the cases with persistent severe low back pain or leg pain. This pain may relate with implant as malpositioning, prosthesis migration, subluxation, subsidence, and breakage of the metal ring of the core or wear.

Owing to adhesions, vascular structures are more vulnerable and adherent to the spine. Major vascular structures are placed on front to the discs at levels above L5 to S1. The vena cava and the aortic bifurcation mainly lie superior to the L5 to S1 disc levels, so the vascular complications give rise to anxiety. Other potential various complications are ureteral damage of the neural prevertebral plexus.

However, no definite proof of its biomechanical and clinical efficacy has yet been provided stand-alone devices are threaded cages designed for anterior lumbar interbody fusion (ALIF). Therefore all the instrument sets are designed for a wide approach to the disc. Moreover, additional space is required for to keep a regular distance between the vertebral endplates throughout the entire procedure by the working tube. The outer diameter of the smallest cage is 12 millimeters; the additional 2–3 mm of the working tube diameter would require about 15 mm of minimal working space on either side (Costa et al, 2011). Using these stand-alone cages is limited because they can be used only for discs which do not exceed 10 mm in height. Furthermore, these cages are suitable for any interbody fusion associated with pedicle screw fixation.

Nuclear replacement began with implantation of devices into the intervertebral disc space following discectomy. Pioneer prostheses contain stainless steel balls, self-curing silicone, silicone-Dacron composite, and polymethylmethacrylate. Other unsuccessful mechanical implants including springs and pistons have been developed. Most of these implants have been unsuccessful because of some complications such as extrusion, subsidence, and reactive endplate changes. Edeland (1981) implied that a nuclear implant should have

viscoelastic features and permit influx and egress of water, thereby mimicking normal disc behaviors. The prosthetic disc nucleus (PDN) prosthesis consist a capsule of woven polyethylene enclosing a hydroscopic thixotropic gel. Various similar products, which have including sheaths with elastic elements, have been tested but none are accepted. Another concept has been to directly inject hydrogel polymers such as polyvinyl alcohol into the intervertebral disc space. Water absorption and subsequent material expansion prevent protrusion. Nuclear replacement theoretically restores degenerative disc biomechanics by changing height and at the same time effect the anular tension.

Symptomatic cases with soft disc hernia or moderate degenerative disc disease may be reckoned for TDR. Few investigations on the intervention of TDR in cervical spondylosis have been declared in literature (Byran VE, 2002; Lafuente et al, 2005; Pimenta et al, 2007; Sekhon LHS 2004), but concern remains on reasonable, efficacy, suitable and safety of disc prostheses in cases with multilevel spondylotic status of the cervical spine, due to accompanied facet joints differency and segmental bony degenerative alterations. The anterior cervical discectomy and fusion (ACDF) is the most largely accepted intervention for the cases with single or double level spondylotic disease. It has acceptable clinical outcomes and radiological fusion ranging from 90 to 100% are frequently cured either by anterior decompression and fusion (Matz et al, 2007), with (Mummaneni et al, 2007; Kaiser et al, 2002) cases with multilevel, symptomatic, spondylotic myeloradiculopathy or without plating (Ashkenazi et al, 2005) or by posterior decompression with or without lateral mass screw fixation (Wiggins et al, 2007). ACDF, a suitable and reliable method, is accepted as the gold standard intervention for single or multilevel cervical spondylosis to cause radiculopathy or myelopathy. It is not absolute whether or not anterior cervical discectomy is due to the physiological senescence of the spine or changes on the ground that previous fusion (Hilibrand et al, 2004). Fusion may be related with other causes such as pseudoarthrosis (Albert et al, 2004), donor site complications and factors of the neighborhood motion segments' biomechanics. The hybrid, single stage, fusion-nonfusion technique appears to be a promising and viable alternation in the treatment of symptomatic multilevel cervical DDD with prevalent anterior myeloradicular compression and different severity per single level, particularly in younger patients. It allows protecting or healing motion in some segments without defining iatrogenic spine instability or painful secondary to severely degenerated levels. Long-term follow-up on larger series of cases are need to approve all of the results (Barbagallo et al, 2009).

Presently there are two types of disc prosthesis as total disc and nucleus disc equipments (Bao et al, 2002; Bao et al, 2007; Bertaglioni et al, 2003, Hedman et al 1991). Contrary to total disc replacement, nucleus disc prosthesis protects the existing constitutions, where include the ligaments, annulus, and endplates (Enker et al, 1993; Fernstrom 1966; Kostuik 1997). Nowadays, there are several types and designs of nucleus disc equipments, and surgical applications such as Nubactm which is the first articulating nucleus disc. Given that the mainly avascular intervertebral disc bears some of the highest loads in the human body and it is not surprising that DDD is a common phenomenon in middle age and a universal condition of the inevitable consequences of aging (Rothman et al 1982). The broad majority of cases achieve acceptable clinical outcomes without surgery (Weinstein, 1992). However, some cases do not respond to nonsurgical treatments. Chronically malformed cases population surgery may be useful. DDD and its related signs have classically been cured with spinal fusion. This method results in a diminished range of movement and may caused

a degenerative process in adjacent vertebral segments (Lee CK, 1998; Ray, 1997; Lee CK et al, 1991; Nachemson, 1992; Kuslisch et al 1998). For a long time, fusion was reckoned as the gold standard of surgical procedure. However, clinical outcomes have yielded the acceptance of disc arthroplasty as the cure option (Balsano et al, 2011).

Several types of prosthesis have been planned with frequent improvements. The polyethylene core of the Charite' prosthesis is sensitive to wear and hurts with breakage of the metal wire marker whether or not associated with impingement. This polyethylene wear gives rise to third-body debris in the intervertebral space near the spinal canal, which may lead to vertebral osteolysis. Retrieval surgery of Charite' TDRs is convenient and relatively reliable, it has major risks due to adjacent vessels and scar tissue. Removal of keeled TDRs like Prodisc and Maverick implants is more hard and more bone removal is a necessity when above L5-S1 levels so, a lateral approach is preferred to avoid damage the major vascular structures (Gerardus et al, 2009). In our series we generally used porous coated motion (PCM) type cervical prosthesis and recently M-6 cervical disc prosthesis at cervical levels, and Nubac at lumbar regions.

The significant cause of recurrent low back pain after TDR may be facet degeneration or adjacent degeneration. The features of intervertebral disc prosthesis with articulating properties like long endurance are so important (Gerardus et al, 2009). The artificial disc or prosthesis is composed of critical importance to prevent premature disintegration; the artificial disc should generate a normal or near-normal movement compared with the pattern of healthy human spinal motion segment, so that corresponding facet joints and adjacent level or levels are not overloaded; and long-term fixation is necessary to avoid subsidence or migration. It seems almost impossible to provide a disc prosthesis that possesses all these features.

Disc arthroplasty provides a new concept not only in the cure of DDD but also in researching its biomechanics on anatomical changes and pathologies of the spine. Disc arthroplasty may fill the gap between simple discectomy and fusion concepts (Fekete et al, 2010).

A less invasive procedure, which is nowadays proposed for the management of chronic lumbar pain due to degenerative discopathy, involves the implantation of dynamic interspinous fixation devices (Bono et al 2007).

Lumbar interspinous spacers (ISPs) have recently become popular as an alternative treatment for lumbar DDD. Several spacers X-STOP, Coflex, Wallis, and DIAM are currently available and there have been various proposed indications (Figure 6). In the literature largest number of studies has been with the X-STOP device. The biomechanical studies with all the devices showed that ISPs have a beneficial effect on the kinematics of the degenerative spine. Apart from two randomized controlled trials, the other studies with the X-STOP device were not of high methodological quality (Kabir et al, 2011). Nevertheless, analysis of those studies showed that X-STOP may improve outcome when compared to non-operative cure in selected cases whose aged 50 or over, with radiologically confirmed lumbar canal stenosis and neurogenic claudication, who have improvement of their symptoms in flexion. Studies on the other interspinous devices show satisfactory outcome to varying degrees. However, due to small number and poor design of the studies, it is difficult to clearly define indications for ISP's use in lumbar degenerative disease. Lumbar ISPs may

have a potential beneficial effect in selective cases with degenerative disease of the lumbar spine. However, further evidence based and good quality trials are needed to clearly outline the indications for ISP's use.

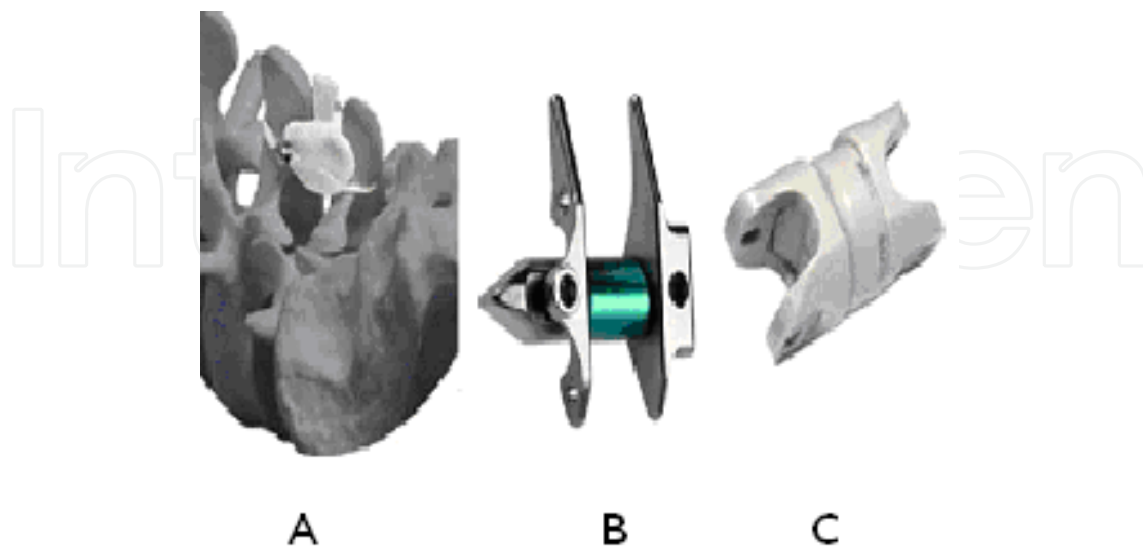


Fig. 10. Samples of the interspinous devices; A.Diam, B.X-Stop, C.PEEK interspinous devices

Nowadays advances in minimally invasive spine surgery (MISS) have allowed spinal surgeons to treat a broader range of degenerative spinal disorders. This is due to the development of advanced technology and new ways of approaching the spine. Some of the many factors that have driven these developments are the request of patients and spinal surgeons to lessen the morbidity and improve the outcome associated. Percutaneous axial anterior lumbar spine surgery is a possible and safe technique (Aryan et al, 2008). This technique is made feasible by a union of established spine surgery principles and the new technology of minimally invasive spinal surgery. The technique is important because it permits the implantation of biomechanically sound implants without the morbidity encountered in open surgery or other types of minimally invasive posterolateral spinal surgery (Aryan et al, 2007). The access orientation makes disc surgery with minimally invasive instruments more intuitive and accomplish. This technique will permit a routine percutaneous fusion from a single access site without paraspinal dissection and will lend itself to the development of new minimally invasive implant. This annulus fibrosus preserving and muscle-sparing approach will moderate postoperative pain, avoid postoperative scarring, speed healing, and eliminate problems encountered with annulus removal. This technique lends itself to spicing biomechanical solutions for motion preservation. Also, therapeutic interbody implants that can be replaced, expanded and revised easily will satisfy the patient and spine surgeon with a novel range of treatment options. The percutaneous paracoccygeal approach to the L5-S1 and L4-L5 interspaces provide a minimally invasive corridor through which discectomy and interbody fusion can safely be actualized. This approach can be used alone or in combination with minimally invasive or classical open fusion procedures. The technique may provide a disjunctive route of access to the L5-S1 or L4-L5 interspaces or both in those patients who may have aberrant anatomy for or contraindications to classical open anterior approach to this level (Aryan et al, 2008). Still this study does not provide Class 1 data, and is subject to the bias of any

retrospective series, and further investigation beyond retrospective analysis is warranted before recommending the routine use of this technique.

Another technique can use after simple discectomy for preventing disc height. It also provides to replace a new injectable synthetic nucleus pulposus material instead of degenerative nucleus pulposus. Nucleus pulposus replacement is a non-fusion technique currently being investigated to treat painful disc degeneration. Replacement of nucleus pulposus with an injectable implant or tissue engineered construct, in patients with healthy annulus fibrosus, may reduce pain while simultaneously restoring spinal mobility and delaying disc degeneration (Boyd et al, 2006; Di Martino et al, 2005; Joshi et al, 2005; Klara et al, 2002; Larson et al, 2006; Cloyd et al, 2007). The challenge for any synthetic nucleus replacement material is to mimic the function of native nucleus pulposus. This bio-adhesive hydrogel material is one of the samples of these kinds of surgical materials (Cloyd et al, 2007; Gloria et al, 2010). After using these materials there's adhesions around the application site could observed. And a question related with application of these materials is the amount of these materials. This can be measured as weight at the operating room after discectomy by measuring the weight of the excising disc material.

Surgeons can measure the cages dimension preoperatively, but there's an easy and unbiased method that can be used before surgery. With this simple volume analysis technique surgeons can calculate how many cc disc material take place at intervertebral space and after discectomy the surgeons can calculate how many cc graft or biogluue substance can be necessary to put this space and what will be the dimensions of the cage or cages to put intervertebral disc space (Karabekir et al, 2011).

The stereological volume analysis is simple, reliable, unbiased and inexpensive. Intervertebral space volumes can evaluate using stereological method. A uniform point-grid with a point-associated area of 0.156 cm² is randomly superimposed on each MRI using the "Grid". Points hitting the lumbar intervertebral space are manually counted for area estimation of the profiles. Automated area estimation by manual perimeter tracing is generally take too much time and hence, more rapid point counting method is preferred. Volume estimation is accomplished by the Cavalieri's principle as described previously using the formula given below:

$$V = t \times [((SU \times d) / SL)^2 \times \sum P]$$

where t is the section thickness, SU is the scale unit, d is the distance between two points in the point grid, SL is the scale length and $\sum P$ is the number of points counted. SU and SL are used to include the linear magnification in the final estimate. All data have been entered to a previously prepared Microsoft Excel spread sheet for automatic calculation of both the results of the above formula and the statistical evaluation parameters including the nugget variance and the coefficient of error (CE). All measurements are performed blinded to subject details and the results of any other measurements, and are done three times in each trial for inter-observer analysis by different researchers.

The surgeons can calculate the intervertebral space volume and discectomy material amount before surgery using this unbiased and inexpensive method (Karabekir et al, 2011). So while operating the cases the surgeons can use the correct amounts of materials and the materials which have correct dimensions.

4.2 Illustrative cases

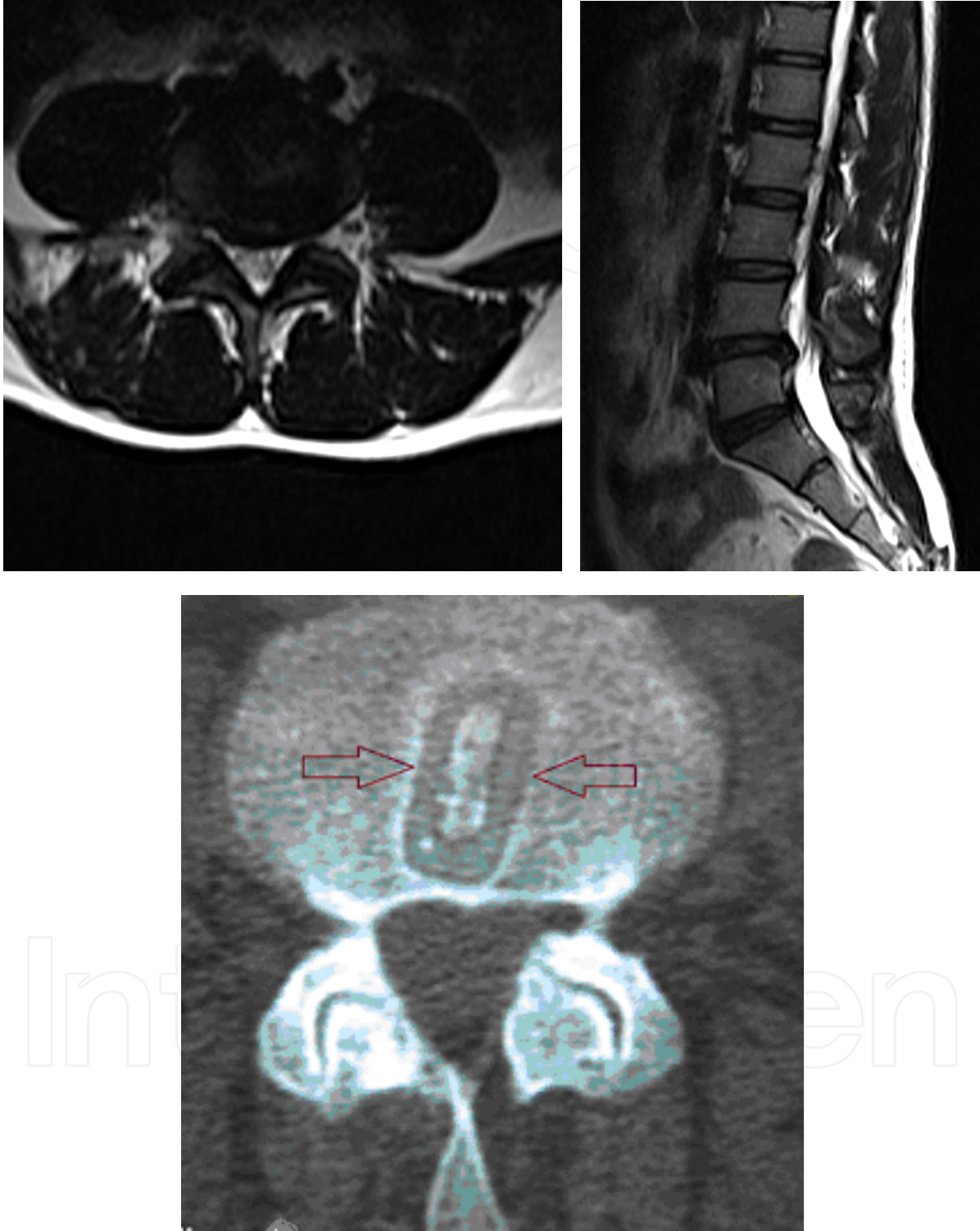


Fig. 11. Preoperative MRI and postoperative CT of 52-year old female case with degenerative disc disease were shown: The patient was admitted with left radicular leg pain and numbness. At physical examination loss of left L5 sensation and left dorsoflexion deficit were obtained. She was operated from left side and after discectomy unilateral PEEK cage was placed on L4-L5 levels (Karabekir, 2006). She had no complaint at 5 years follow-up.

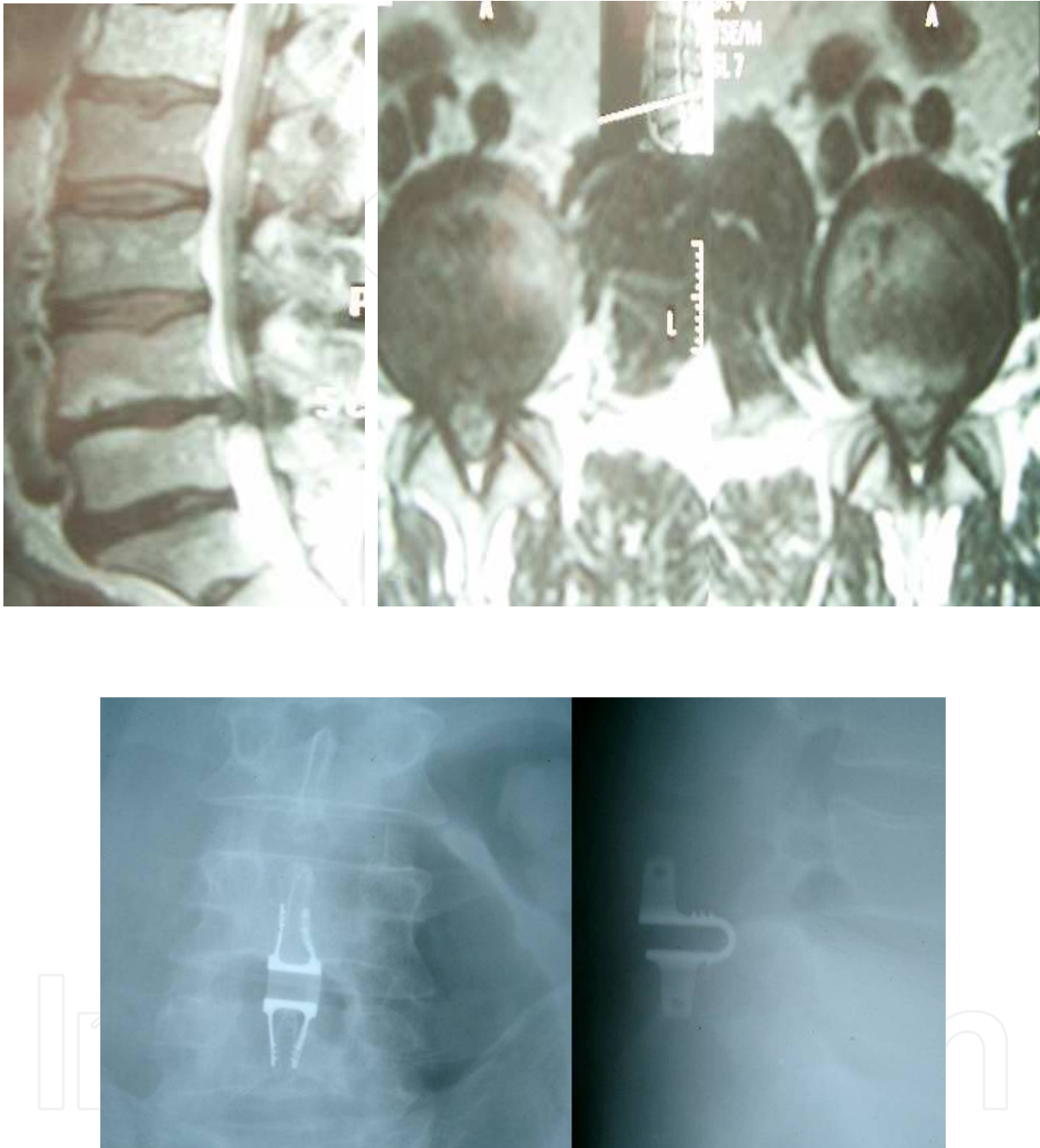

Fig. 12. L4-L5 diffuse protrusion and bilateral foraminal stenosis on preoperative MRI of a 55 year old men, whom had low back and bilateral leg pain which dominate at right side with numbness and causalgia during last 6 months, was shown. At physical examination bilateral muscle weakness at ankle dorsiflexion and L4-S1 hypoesthesia were obtained. Postoperative anteroposterior and lateral X-rays of the case was shown. The interspinous device (Coflex) was applied at L4-L5 level after discectomy posteriorly to preserve the height of the interspinous foramina (Karabekir, 2005).

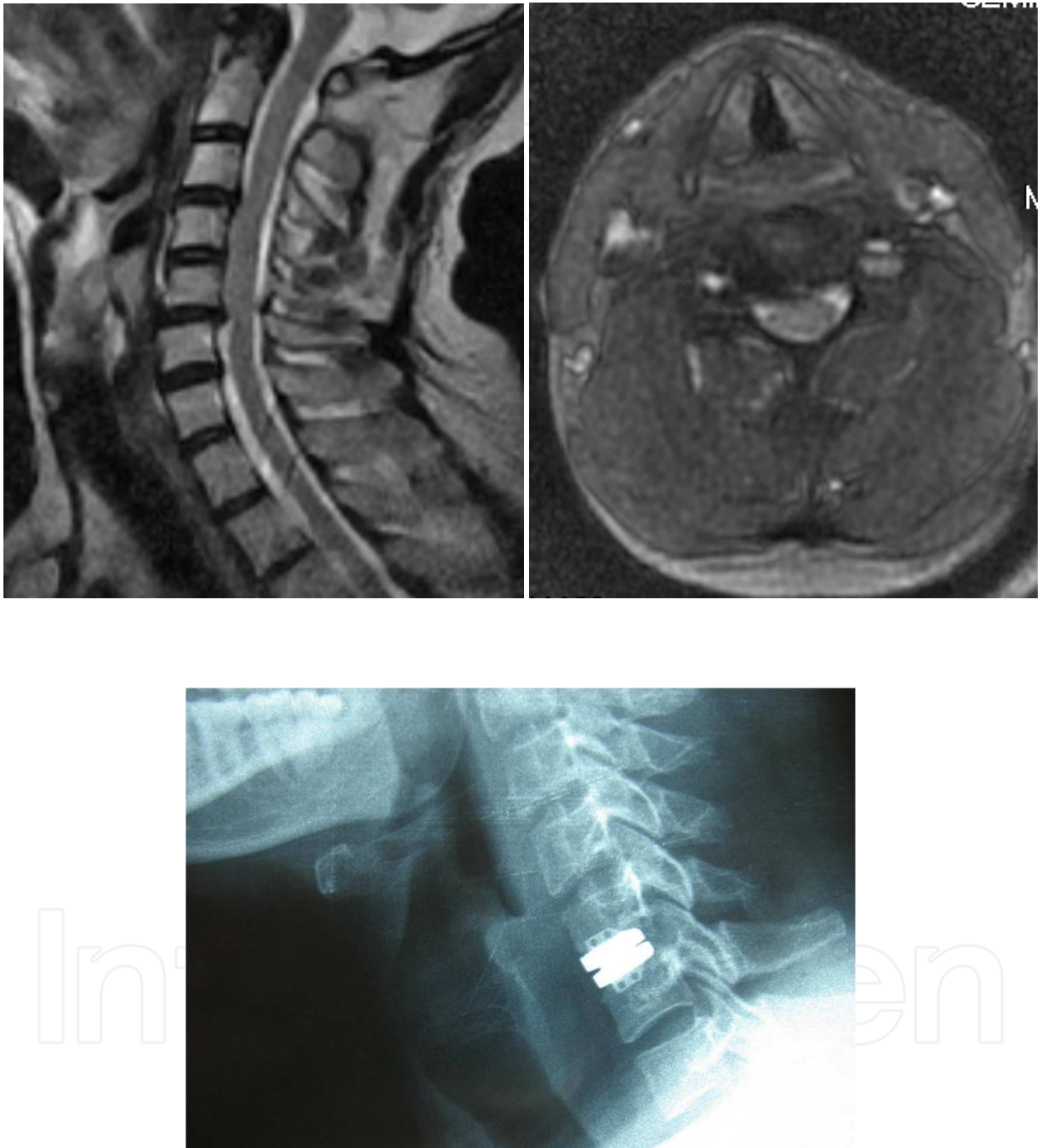


Fig. 13. Preoperative servical MRI was shown with C5-C6 servical degenerative disc hernia. 39 year-old male subject was admitted with right arm pain and numbness for three months period. At physical examination left C5-6-7 sensation lost, muscle weakness and biceps reflex hipoactivity were observed. Patient was operated and applicated Maverick artificial disc prosthesis at C5-C6 level (Karabekir, 2010). Artificial disk was shown at postoperative direct x-ray.

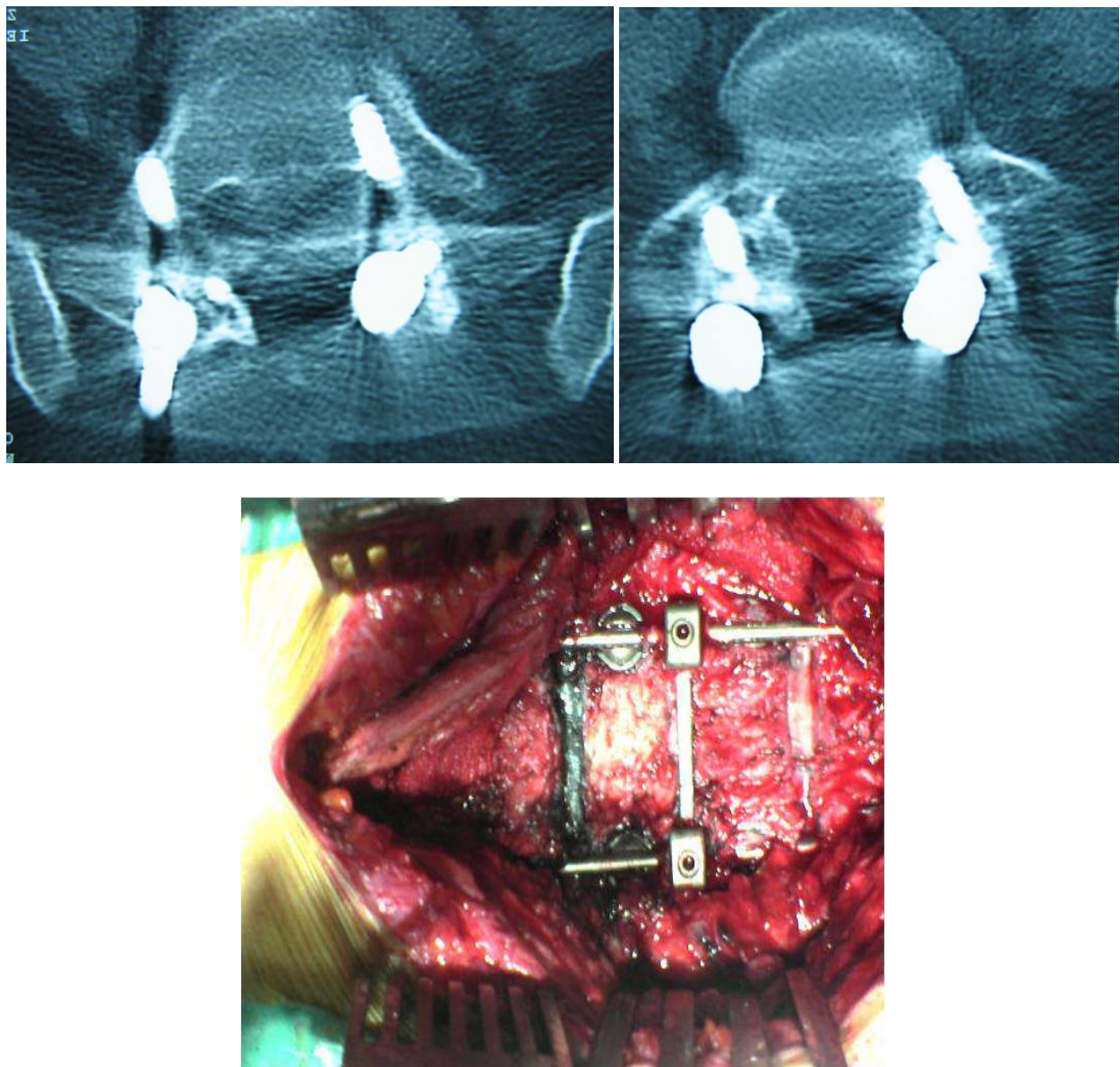


Fig. 14. Peroperative image of 64-year old female revision case; 3rd operation of the case, first simple discectomy and interbody fusion, the second posterior pedicle screws implantation because of chronic lowback pain and the third was performed because of broken screws. Broken screws were shown at W-B pictures (Karabekir, 2008).

5. Expert suggestions

The cases of degenerative disc disease should be evaluated carefully preoperatively and at operative period. The surgeon should know topographic and clinic anatomical knowledge of the region in detailed. Critical important anatomical landmarks should be defined before surgical approach such as lateral border of ligamentum flava and posterior longitudinal ligament, medial margin of superior articular process (superior facet). At the time of preoperative planning and during surgery; surgeon should aim to perform limited invasive procedure for preserving neighbourhood tissue and neurovascular structures of the region. Meticulous dissection should be performed and minimally invasive techniques must be

selected to avoid major complications such as bleeding, iatrogenic neurovascular damage etc. Particularly, resection of the posterior longitudinal ligament must be a little wider than standard discectomy procedure for placing intervertebral implants or grafts. During this procedure, retraction of the dura and roots must be gentle and care. While replacing the implant, surgeon should use scopy for right and exact position and level of it.

6. Conclusion

As a conclusion, anatomical knowledge of the vertebral column and/or spinal cord and also careful preoperative evaluation of the cases as both clinically and radiologically are of importance for realizing successful approach on the degenerative disc diseases.

7. References

- Albert T.J., Eichenbaum M.D. (2004) Goals of cervical disc replacement. *Spine J* 4:292S–293S
- Aldskogius, H., Arvidsson, J. & Grant, G. (1985) The reaction of primary sensory neurons to peripheral nerve injury with particular emphasis on transganglionic changes. *Brain Res* 357(1): 27-46.
- April, E.W. (1990) Clinical anatomy. *The National Medical Series for Independent Study*. 2nd ed. Harwal Publishing Company, USA.
- Aryan H.E., Newman C.B., Gold J.J., Acosta Jr F.L., Coover C, Ames C.P. (2008) Percutaneous Axial Lumbar Interbody Fusion (AxiaLIF) of the L5-S1 Segment: Initial Clinical and Radiographic Experience. *Minim Invas Neurosurg* 51: 225– 230)
- Ashkenazi E., Smorgick Y., Rand N., Millgram M.A., Mirovsky Y., Floman Y. (2005) Anterior decompression combined with corpectomies and discectomies in the management of multilevel cervical myelopathy: a hybrid decompression and fixation technique. *J Neurosurg Spine* 3: 205–209
- Bao Q.B., Yuan H.A. (2002) New technologies in spine: nucleus replacement. *Spine* 27: 1245–1247
- Bao Q.B., Yuan H.A. (2002) Prosthetic disc replacement: the future? *Clin Orthop* 394:139–145
- Bao Q.B., Songer M., Pimenta L., Werner D., Reyes-Sanchez A., Balsano M., Agrillo U., Coric D., Davenport K., Yuan H. (2007) Nubac disc arthroplasty: preclinical studies and preliminary safety and efficacy evaluations. *SAS J* 1: 36–45
- Battie M.G., Videman T., Parent E. (2004) Lumbar disc degeneration: epidemiology and genetics influences. *Spine* 29: 2679–2690
- Benglis D.M., Vanni S., Levi A.D. (2009) An anatomical study of the lumbosacral plexus as related to the minimally invasive transpsoas approach to the lumbar spine. *Neurosurg Spine*. 10(2):139-44.
- Benglis D., Elhammady S., Levi A., Vanni S. (2008) Minimally invasive anterolateral approaches for the treatment of back pain and adult degenerative deformity. *Neurosurgery* 68: 191–196
- Bergey D.L., Villavicencio A.T., Goldstein T., Regan J.J. (2004) Endoscopic lateral transpsoas approach to the lumbar spine. *Spine* 29: 1681–1688
- Bertagnoli R., Vazquez R.J. (2003) The anterolateral transpsoatic approach (ALPA). A new technique for implanting prosthetic disc nucleus devices. *J Spinal Disord* 16: 398–404
- Blume H.G., Rojas C.H. (1981) Unilateral lumbar interbody fusion (posterior approach) utilizing dowel graft. *J Neurol Orthop Surg* 2: 171-175.


- Bono C.M., Vaccaro A.R. (2007) Interspinous process devices in the lumbar spine. *J Spinal Disord Tech.* 20(3): 255-261
- Boyd L.M., Carter A.J. (2006) Injectable biomaterials and vertebral endplate treatment for repair and regeneration of the intervertebral disc. *Eur Spine J* 15(Suppl 3): 414-421
- Bryan V.E. (2002) Cervical motion segment replacement. *Eur Spine J* 11(Suppl 2): 92-97
- Buric J., Pulidori M. (2011) Long-term reduction in pain and disability after surgery with the interspinous device for intervertebral assisted motion (DIAM) spinal stabilization system in patients with low back pain: 4-year follow-up from a longitudinal prospective case series. Josip Buric *Eur Spine J* DOI 10.1007/s00586-011-1697-6)
- Butt M.F., Farooq M., Dhar S.A., Mir M.R., Mir B.A., Kangoo K.A. (2007) Retrospective analysis of the occurrence of radiologically detectable surgical error in cases of failed pedicle screw implants. *Acta Orthop Belg.* 73(4): 500-6.
- Chaichana K.L., Mukherjee D., Adogwa O., Cheng J.S., McGirt M.J. (2011) Correlation of preoperative depression and somatic perception scales with postoperative disability and quality of life after lumbar discectomy. *J Neurosurg Spine.* Feb;14(2): 261-7.
- Chen B.L., Wei F.X., Ueyama K., Xie D.H., Sannohe A., Liu S.Y. (2011) Adjacent segment degeneration after single-segment PLIF: the risk factor for degeneration and its impact on clinical outcomes. *Eur Spine J* DOI 10.1007/s00586-011-1888-1
- Cevei M., Roșca E., Liviu L., Mușiu G., Stoicănescu D., Vasile L. (2011) Imagistic and histopathologic concordances in degenerative lesions of intervertebral disks. *Rom J Morphol Embryol.* 52(1 Suppl):327-32.
- Cloward R.B. (1953) The treatment of ruptured lumbar intervertebral discs by vertebral body fusion: indications, operating technique, after care. *J Neurosurg* 10: 154-168.
- Cloyd J.M., Malhotra N.R., Weng L., Chen W., Mauck R.L., Elliott D.M. (2007) Material properties in unconfined compression of human nucleus pulposus, injectable hyaluronic acid-base hydrogels and tissue engineering scaffolds. *Eur Spine J* 16(11):1892-8. Epub 2007 Jul 28.
- Costa F., Sassi M., Ortolina A., Cardia A., Assietti R., Zerbi A., Lorenzetti M., Galbusera F., Fornari M. (2011) Stand-alone cage for posterior lumbar interbody fusion in the treatment of high-degree degenerative disc disease: design of a new device for an "old" technique. A prospective study on a series of 116 patients. *Eur Spine J* (2011) 20 (Suppl 1):S46-S56
- Cox C.S., Rodgers W.B., Gerber E.J. (2008) XLIF in the treatment of single-level lumbar spondylolisthesis: 6 month and 1 year follow up. *J Neurosurg* 108:A853, 2008 (Abstract)
- Cummings, C.W., Fredrickson, J.M., Harker, L.A., Krause, C.J., & Schuller, D.E. (1993). *Otolaryngology-Head and Neck Surgery*. 2nd ed. Vol I, Mosby Year Book.
- de Maat G., Punt I.M., van Rhijn L.W., Schurink G.H., van Ooij A. (2009) Removal of the Charité Lumbar Artificial Disc Prosthesis Surgical Technique. *J Spinal Disord Tech* 22; 5:334-339
- Derby R., Howard M.W., Grant J.M., Lettice J.J., Van Peteghem P.K., Ryan D.P. (1999) The ability of pressurecontrolled discography to predict surgical and nonsurgical outcomes. *Spine* 24: 364-372.
- Dezawa A., Yamane T., Mikami H., Miki H. (2000) Retroperitoneal laparoscopic lateral approach to the lumbar spine. *J Spinal Disord* 13: 138-143

- Di Martino A., Vaccaro A.R., Lee J.Y., Denaro V., Lim M.R. (2005) Nucleus pulposus replacement: basic science and indications for clinical use. *Spine* 30: 16– 22
- Ebraheim N.A., Xu R., Darwich M., Yeasting R.A. (1997) Anatomic relations between the lumbar pedicle and the adjacent neural structures. *Spine* (Phila Pa 1976). 15; 22(20):2338-41.
- Edelard H.G. (1981) Suggestions for a total elasto-dynamic intervertebral disc prosthesis. *Biomater Med Devices Artif Organs*. 9(1):65-72.
- Enker P., Steffee A., Mcmillan C., Keppler L., Biscup R., Miller S. (1993) Artificial disc replacement. Preliminary report with a 3-year minimum follow-up. *Spine* 18:1061–1070
- Fekete T.F., Porchet F. (2010) Overview of disc arthroplasty-past, present and future. *Acta Neurochir (Wien)*. 152(3):393-404. Review.
- Fernstrom U. (1966) Arthroplasty with intercorporal endoprosthesis in herniated disc and in painful disc. *Acta Chir Scand (Suppl)* 357:154–159
- Ferrera, P.C., & Chandler, R. (1994) Anesthesia in the emergency setting: Part II. Head and neck, eye and rib injuries. *Am Fam Physician* 15; 50(4):797-800.
- Gloria A., Borzacchiello A., Causa F., Ambrosio L. (2010) Rheological Characterization of Hyaluronic Acid Derivatives as Injectable Materials Toward Nucleus Pulposus Regeneration. *J Biomater Appl*. [Epub ahead of print]
- Gocmen-Mas N., Karabekir H., Ertekin T., Senan S., Edizer M., Yazici C., Duyar I. (2010) Evaluation of Lumbar Vertebral Body and Disc: A Stereological Morphometric Study. *Int. J. Morphol.*, 28(3):841-847.
- Gornet M.F., Burkus J.K., Dryer R.F., Pelozo J.H. (2011) Lumbar Disc Arthroplasty with MAVERICK™ Disc Versus Stand-Alone Interbody Fusion: A Prospective, Randomized, Controlled, Multicenter Investigational Device Exemption Trial. *Spine (Phila Pa 1976)*. [Epub ahead of print]
- Haghighat, K. (2007). "Bone augmentation techniques." *J Periodontol* 78(3): 377-96.
- Harms J. (1997) True spondylolisthesis reduction and more segmental fusion in spondylolisthesis. In: Bridwell KH, DeWald RL (Eds.). *The Textbook of Spinal Surgery*. 2nd Ed. Philadelphia, Lippincott-Raven.
- Hedman T.P., Kostuik J.P., Fernie G.R., Hellier W.G. (1991) Design of an intervertebral disc prosthesis. *Spine* 16(Suppl 6):256–260
- Hilibrand A.S., Robbins M. (2004) Adjacent segment degeneration and adjacent segment disease: the consequences of spinal fusion? *Spine J* 4: 190–194
- Hioki A., Miyamoto K., Hosoe H., Sugiyama S., Suzuki N., Shimizu K. (2011) Cantilever transforaminal lumbar interbody fusion for upper lumbar degenerative diseases (minimum 2 years follow up). *Yonsei Med J*. 52(2): 314-21.
- Hutton M.J., Bayer J.H., Powell J., Sharp D.J. (2011) Modic vertebral body changes: The natural history as assessed by consecutive magnetic resonance imaging. *Spine* (Phila Pa 1976). Feb 25. [Epub ahead of print]
- Joshi A., Mehta S., Vresilovic E., Karduna A., Marcolongo M. (2005) Nucleus implant parameters significantly change the compressive stiffness of the human lumbar intervertebral disc. *J Biomech Eng* 127: 536–540
- Junjie D., Mo L., Hao L., Hao M., Qizhen H., Zhuojing L. (2011) Early follow-up outcomes after treatment of degenerative disc disease with the discover cervical disc prosthesis *The Spine Journal* 11: 281–289

- Kabir S.M., Gupta S.R., Casey A.T. (2010) Lumbar interspinous spacers: a systematic review of clinical and biomechanical evidence. *Spine* (Phila Pa 1976). 1; 35(25): 1499-506.
- Kaiser M.G., Haid R.W.Jr., Subach B.R., Barnes B., Rodts G.E.Jr. (2002) Anterior cervical plating enhances arthrodesis after discectomy and fusion with cortical allograft. *Neurosurgery* 50: 229-238
- Karabekir H.S., Atar E.K., Yaycioglu S., Yildizhan A.(2008) Comparison of unilateral posterior lumbar interbody fusion and bilateral posterior lumbar interbody fusion with simple discectomy at degenerative disc herniations. *Neurosciences* 13 (3): 248-252
- Karabekir H.S., Korkmaz S., Ozturk U. (2009) Comparison of unilateral posterior lumbar interbody fusion with simple discectomy at degenerative disc disease. *The J Turkish Spinal Surgery* 20 (1): 47- 52.
- Karabekir H.S., Yildizhan A.,Atar K.E., Yaycioglu S., Gocmen-Mas N., Yazici C. (2010) Effect of ligamenta flava hypertrophy on lumbar disc herniation with contralateral symptoms and signs: a clinical and morphometric study. *Arch Med Sci* 6(4): 617-622
- Karabekir H.S.,Mas N.G., Edizer M.,Ertekin T., Yazici C, Atamturk D (2011). Lumbar Vertebra Morphometry and Stereological Assesment of Intervertebral Space Volumetry: A Methodological Study *Ann Anatomy* 193(3): 231-6. Epub 2011 Apr 2.
- Klara P.M., Ray C.D. (2002) Artificial nucleus replacement: clinical experience. *Spine* 27:1374-1377
- Kostuik J.P. (1997) Intervertebral disc replacement. In: Bridwell KH, DeWald RL (eds) *The textbook of spinal surgery*, 2nd edn. Lippincott-Raven, Philadelphia.
- Krumlauf R. (1994) Hox genes in vertebrate development. *Cell*. 29; 78(2): 191-201. Review.
- Kumar M.N., Jacquot F., Hall H. (2001) Long-term follow-up of functional outcomes and radiographic changes at adjacent levels following lumbar spine fusion for degenerative disc disease. *Eur Spine J* 10: 309-313
- Kuslich S.D., Ulstrom C.L., Griffith S.L., Ahern J.W., Dowdle J.D. (1998) The Bagby and Kuslich method of lumbar interbody fusion. History, techniques, and 2-year follow-up results of a United States prospective, multicenter trial. *Spine* 23: 1267-1279
- Lafuente J., Casey A.T., Petzold A., Brew S. (2005) The Bryan cervical disc prosthesis a san alternative to arthrodesis in the treatment of cervical spondylosis. *J Bone Joint Surg Br* 87(4): 508-512
- Larson J.W., Chadderon R.C., Georgescu H., Lee D., Hubert M., Werkmeister-Lewis L., Irrang J.,Gilbertson L.G., Kang J.D. (2006) Prevention of intervertebral disc degeneration after surgical discectomy using an injectable nucleus pulposus prosthesis. In: *Proceedings of the 52nd annual meeting of the orthopaedic research society, Chicago, USA*.
- Lee C.K. (1988) Accelerated degeneration of the segment adjacent to a lumbar fusion. *Spine* 13: 375-377
- Lee C.K., Langrana N.A., Parsons J.R., Zimmerman M.C. (1991) Development of a prosthetic intervertebral disc. *Spine* 16(Suppl 6): 253-255
- Lee C.S., Hwang C.J., Lee S.W., Ahn Y.J., Kim Y.T., Lee D.H., Lee M.Y. (2009) Risk factors for adjacent segment disease after lumbar fusion. *Eur Spine J* 11: 1637-1643
- Lin P., Cautilli R., Joyce M. (1983) Posterior lumbar interbody fusion. *Clin Orthop* 180: 154-167.
- Lipetz J.S. (2002) Pathophysiology of inflammatory, degenerative, and compressive radiculopathies. *Phys Med Rehabil Clin N Am*. 13(3): 439-49. Review.

- Lundborg, G. (1988) Intraneural microcirculation. *Orthop Clin North Am* 19(1): 1-12.Review.
- Mallo M., Vinagre T., Carapuço M. (2009) The road to the vertebral formula. *Int J Dev Biol.* 53(8-10): 1469-81. Review.
- Marks R.C., Houston T., Thulbourne T. (1992) Facet joint injection and facet nerve block: a randomised comparison in 86 patients with chronic low back pain. *Pain* 49: 325-328
- Matz P.G., Pritchard P.R., Hadley M.N. (2007) Anterior cervical approach for the treatment of cervical myelopathy. *Neurosurgery* 60(Suppl): 64-70
- Mayer H.M. (1997) A new microsurgical technique for minimally invasive anterior lumbar interbody fusion. *Spine* 22: 691-699
- McAfee P.C., Regan J.J., Geis W.P., Fedder I.L. (1998) Minimally invasive anterior retroperitoneal approach to the lumbar spine Emphasis on the lateral BAK. *Spine* 23: 1476-1484
- McAfee P.C., Phillips F.M., Allen T.R., Regan J.J., Albert T.J., Cappuccino A., Devine J.G., Ahrens J.E., Hipp J.A. (2009) Cervical disc replacement in patients with and without previous adjacent level fusion surgery: a prospective study. *Spine (Phila Pa 1976)*. 15; 34(6): 556-65.
- Moore, K.L. (1992) *Clinically oriented anatomy*. The Williams and Wilkind Company USA.
- Mummaneni P.V., Burkus J.K., Haid R.W., Traynelis V.C., Zdeblick T.A. (2007) Clinical and radiographic analysis of cervical disc arthroplasty compared with allograft fusion: a randomized controlled clinical trial. *J Neurosurg Spine* 6(3): 198-209
- Nachemson A.L. (1992) Challenge of the artificial disc. In: Weinstein JN (ed) *Clinical efficacy and outcome in the diagnosis and treatment of low back pain*. Raven Press, New York, USA
- Okuda S., Oda T., Miyauchi A., Tamura S., Hashimoto Y., Yamasaki S., Haku T., Kanematsu F., Ariga K., Ohwada T., Aono H., Hosono N., Fuji T., Iwasaki M. (2008) Lamina horizontalization and facet tropism as the risk factors for adjacent segment degeneration after PLIF. *Spine* 33: 2754-2758
- Park P., Garton H.J., Gala V.C., Hoff J.T., McGillicuddy J.E. (2004) Adjacent segment disease after lumbar or lumbosacral fusion: review of the literature. *Spine* 29: 1938-1944
- Patel K.P., Sandy J.D., Akeda K., Miyamoto K., Chujo T., An H.S., Masuda K. (2007) Aggrecanases and aggrecanasegenerated fragments in the human intervertebral disc at early and advanced stages of disc degeneration, *Spine (Phil Pa 1976)* 32 (23) : 2596-2603.
- Pimenta L., McAfee .PC., Cappuccino A., Bellera F.P., Link H.D. (2007) Superiority of multilevel cervical arthroplasty outcomes versus single-level outcomes: 229 consecutive PCM prostheses. *Spine* 32(12): 1337-1344
- Ray C.D. (1997) Threaded titanium cages for lumbar intebody fusions. *Spine* 22(6): 67-80.
- Rahm M.D., Hall B.H. (1996) Adjacent-segment degeneration after lumbar fusion with instrumentation: a retrospective study. *J Spinal Disord* 9: 392-400
- Rothman R.H., Simeone F.A., Bernini P.M. (1982) Lumbar disc disease. In: Rothman RH, Simeone FA (eds) *The spine*, 2nd edn. WB Saunders, Philadelphia, USA
- Schwarzer A.C., Aprill C.N., Derby R., Fortin J., Kine G., Bogduk N. (1994) Clinical features of patients with pain stemming from the lumbar zygapophysial joints. Is the lumbar facet syndrome a clinical entity? *Spine (Phila Pa 1976)* 19:1132-1137

- Schwarzer A.C., Aprill C.N., Derby R., Fortin J., Kine G., Bogduk N. (1994) The false-positive rate of uncontrolled diagnostic blocks of the lumbar zygapophysial joints. *Pain* 58:195-200
- Sekhon L.H.S. (2004) Cervical arthroplasty in the management of spondylotic myelopathy: 18-month results. *Neurosurg Focus* 17(3): 55-61
- Sekhon L.H.S. (2004) Two-level artificial disc placement for spondylotic cervical myelopathy. *J Clin Neurosci* 11(4): 412-415
- Snell R.S. (2011) *Clinical Anatomy*. Williams and Wilkins 8th ed. Walters Kluwer, USA.
- Standring S., Ellis H., Healy J.C., Johnson D., Williams A., Collins P. (2005) *Gray's Anatomy* (ed 39). London, Churchill Livingstone.
- Steffee A., Sitkowski D. (1988) Posterior lumbar interbody fusion and plates. *Clin Orthop* 227: 99-102.
- Sunderland S., (1951) A Classification of Peripheral Nerve Injuries Producing Loss of Function *Brain* 74(4): 491-516.
- Taner D. (2004) *Functional Neuroanatomy*. 4th ed. ODTU Press, Ankara, Turkey.
- Turner J.A., Ersek M., Herron L., Haselkorn J., Kent D., Ciol M.A., Deyo R. (1992) Patient outcomes after lumbar spinal fusions. *JAMA* 268: 907-911.
- Turner J.A., Herron L., Deyo R.A. (1993) Meta-analysis of the results of lumbar spine fusion. *Acta Orthop Scand Suppl* 251: 120-122
- Van de Graaff. (1998). *Human Anatomy* 5th ed. WBC McGraw-Hill Companies, USA.
- Van Zundert J., Huntoon M., Patijn J., Lataster A., Mekhail N., van Kleef M. (2010) Cervical radicular pain. *Pain Practice. Pain Pract.* 10(1): 1-17. Review.
- Waddell G., Gibson J.N.A., Grant I. (2000) Surgical treatment of lumbar disc prolapse and degenerative lumbar disc disease. In: Nachemson AL, Jonsson E (eds) *Neck and back pain*. Lippincott Williams & Wilkins, Philadelphia.
- Weatherly C.R., Prickett C.F., O'Brien J.P. (1986) Discogenic pain persisting despite solid posterior fusion. *J Bone Joint Surg* 68-B:142-143.
- Weinstein J.N. (ed) (1992) *Clinical efficacy and outcome in the diagnosis and treatment of low back pain*. Raven Press, New York
- Wellik D.M. (2007) Hox patterning of the vertebrate axial skeleton. *Dev Dyn.* 236(9): 2454-2463 Review.
- West W., West K.P., Younger E.N., Cornwall D. (2010) Degenerative disc disease of the lumbar spine on MRI. *West Indian Med J.* 59(2): 192-5.
- Wiggins G.C., Shaffrey C.I. (2007) Dorsal surgery for myelopathy and myeloradiculopathy. *Neurosurgery* 60(Suppl): 71-81
- Williams P.L., Bannister L.H., Berry M.M., Patricia C., Dyson M., Dussek J.E., Ferguson M.W.J. (1995) *Gray's Anatomy*. 38th ed. Churchill-Livingstone, UK.
- Winn H.R. (2004) *Youmans Neurological Surgery*. 5th ed. Saunders, Philadelphia, PA., USA.
- Woodburne R.T., Burkel W.E. (1994) *Essentials of Human Anatomy* 9th ed New York, Oxford University Press.
- Zencica P., Chaloupka R., Hladíková J., Krbec M. (2010) Adjacent segment degeneration after lumbosacral fusion in spondylolisthesis: a retrospective radiological and clinical analysis. *Acta Chir Orthop Traumatol Cech* 77: 124-130



Explicative Cases of Controversial Issues in Neurosurgery

Edited by Dr. Francesco Signorelli

ISBN 978-953-51-0623-4

Hard cover, 534 pages

Publisher InTech

Published online 23, May, 2012

Published in print edition May, 2012

Neurosurgery is a rapidly developing field of medicine. Therefore, staying keeping track of the advancements in the field is paramount for trainees as well as fully trained neurosurgeons. This book, fully available online, is a part of our effort of improving availability of medical information for anyone who needs to keep up-to-date.

How to reference

In order to correctly reference this scholarly work, feel free to copy and paste the following:

H. Selim Karabekir, Nuket Gocmen-Mas and Mete Edizer (2012). Anatomical and Surgical Perspective to Approach Degenerative Disc Hernias, Explicative Cases of Controversial Issues in Neurosurgery, Dr. Francesco Signorelli (Ed.), ISBN: 978-953-51-0623-4, InTech, Available from:
<http://www.intechopen.com/books/explicative-cases-of-controversial-issues-in-neurosurgery/anatomical-and-surgical-perspective-to-approach-degenerative-disc-hernias>

INTECH
open science | open minds

InTech Europe

University Campus STeP Ri
Slavka Krautzeka 83/A
51000 Rijeka, Croatia
Phone: +385 (51) 770 447
Fax: +385 (51) 686 166
www.intechopen.com

InTech China

Unit 405, Office Block, Hotel Equatorial Shanghai
No.65, Yan An Road (West), Shanghai, 200040, China
中国上海市延安西路65号上海国际贵都大饭店办公楼405单元
Phone: +86-21-62489820
Fax: +86-21-62489821

© 2012 The Author(s). Licensee IntechOpen. This is an open access article distributed under the terms of the [Creative Commons Attribution 3.0 License](https://creativecommons.org/licenses/by/3.0/), which permits unrestricted use, distribution, and reproduction in any medium, provided the original work is properly cited.

IntechOpen

IntechOpen