

We are IntechOpen, the world's leading publisher of Open Access books Built by scientists, for scientists

6,900

Open access books available

185,000

International authors and editors

200M

Downloads

Our authors are among the

154

Countries delivered to

TOP 1%

most cited scientists

12.2%

Contributors from top 500 universities



WEB OF SCIENCE™

Selection of our books indexed in the Book Citation Index
in Web of Science™ Core Collection (BKCI)

Interested in publishing with us?
Contact book.department@intechopen.com

Numbers displayed above are based on latest data collected.
For more information visit www.intechopen.com



Suboccipital Concentric Craniotomy as Variant for Posterior Cranial Fossa Surgery

Abraham Ibarra-de la Torre¹, Fernando Rueda-Franco²
and Alfonso Marhx-Bracho²

¹*Hospital Central Sur de Alta Especialidad, PEMEX and*

²*Instituto Nacional de Pediatría
Mexico*

1. Introduction

In the early development of neurosurgery, a common procedure was the posterior cranial fossa surgery exposition using craniectomy.

The approaches to the posterior fossa were directed largely via the occipital squama; with figure of some authors that proposed suboccipital craniectomy and/or craniotomy. The suboccipital concentric craniotomy it's a variant for posterior cranial fossa surgery which considers the principle of fronto-orbital approach, use the concentric craniotomy technique by Laligam N Sekhar, Fotios N Tzortzidis and Jair L Raso in 1997.

2. Alternative procedures

As told, in the early development of neurosurgery, the posterior cranial fossa surgery exposition using craniectomy and/or craniotomy was a common procedure and several authors had described this approach, including combined approaches. Including midline suboccipital craniotomy, superior or inferior, for lesions such tumors of the culmen, pineal tumors, medulloblastoma, cerebellar hemisphere astrocytoma, ependimoma of the IV ventricle, foramen magnum tumors, respectively. The lateral suboccipital craniotomy or paramedian and the lateral suboccipital retrosigmoid approach opening is placed entirely within the squamous portion (immediately inferior to transverse sinus and posteromedial to jugular bulb) out in a retromastoid fashion, the access it offers to the lateral surface of the cerebellar hemisphere is excellent. It is the flap that permits one to work effectively in the pontocerebellar angle, the jugular foramen, or along the lateral surface of the medulla oblongata and pons. Neurinomas, meningiomas, epidermoids, dermoids, chordomas, chondromas, metastases, and cysts constitute the majority of tumors in this region. These techniques had risk of iatrogenic injury to venous sinuses and causing profuse venous bleeding or air emboli. We recently described the suboccipital concentric craniotomy as a variant for posterior cranial fossa surgery, as a variant that have advantage for minor risk of injuries on the venous sinuses, in midline or lateral suboccipital approaches. This paper is dedicated for the latest technique.

3. Indications and contraindications

Injuries of the posterior fossa are varied and different neurosurgical diseases. The indications in this case series were medulloblastoma 5 cases, midline suboccipital craniotomy; pineal germinoma 4 cases, using midline (superior) suboccipital craniotomy; pilocytic astrocytoma in 2 cases, one midline suboccipital craniotomy and the other lateral suboccipital craniotomy; each one case for arteriovenous malformation and aneurysm associated, cerebellar metastases, neurinoma, trigeminal neuralgia. We consider that the suboccipital concentric craniotomy may be used in the different neurosurgical lesions in the posterior fossa, including cerebellar, pineal and the pontocerebellar angle tumors, cerebellar metastasis, vascular lesions and vascular decompression in cranial nerves. This technique has application in children and/or adults. Without contraindications in these cases. Maybe using this craniotomy with combined approach for petroclival meningiomas, supra-infratentorial pre-sigmoid sinus aneurysm, such previous reports for Al-Mefty et al. and Samii and Ammirati, in 1988 or Miller et al, in 1993.

4. Preoperative planning

4.1 Imaging

Computed tomography (CT) or magnetic resonance Imaging (MRI) can establish the diagnosis (alone or together) of the posterior fossa lesion.

4.2 Preoperative preparation

Most of the patients diagnosed with a posterior fossa lesion can be stabilized by using steroids, this given 8 to 48 hours before tumor resection in hopes of reducing peritumoral edema and lowering ICP administer a histamine blockers as prophylactic are at the clinician's discretion; and cerebrospinal fluid diversion, for treat the hydrocephalus using external ventricular drain (EVD) or shunt insertion; the EVD inserted just before the craniotomy, during the same anesthetic; postoperatively, remove bloody, debris-laden cerebrospinal fluid and avoid the risk of acute postoperative hydrocephalus.

4.3 Position

The anesthetized patient is placed in the sitting position (the prone position, the venous oozing obscured the operative field), and the Mayfield three-point fixation device is used to fix the head and the neck slightly flexed forward, for midline approach and a midline linear skin incision (6-7 centimeters in length) begins 2-3cm above the level of the external occipital protuberance and extends as far as C₂₋₃. Dissection of the underlying soft tissue is completed. For the lateral suboccipital approach the skin incision begins approximately 3 cm above and slightly lateral to the external occipital protuberance and extends linearly down 6-8 cm toward the base of the occiput, but may vary. The transesophageal echography was use only in the cases of pineal tumors.

The position and size of major dural sinus were identified for using neuroimaging (see Fig. 2-J). In the midline superior suboccipital craniotomy, lesions such pineal tumor, we don't open the foramen magnum.

4.4 Anatomic landmarks in the posterior cranial fossa

The orientation for any neurosurgical approach begins with consideration of surface anatomic landmarks; the relationships of surface structures to the internal anatomy, and the proper placement of the bony opening (strategic or initial burr-hole). The transverse and sigmoid sinuses are the natural limits of these exposures, the knowledge of the cranial topography constitutes the main factor in the planning of these posterior approaches and reliable landmarks would therefore guide the surgeon in order to reduce the risk of iatrogenic injuries.

Theinion and superior nuchal line, the sagittal, lamboid, occipitomastoid, and parietomastoid sutures are recognizable structures on the external cranial surface and their relationships with the transverse and sigmoid sinuses and torcular herophili or superior sagittal sinus; the asterion, the junction of the lamboid, parietomastoid, and occipitomastoid sutures, has been used in posterior fossa surgery to locate the transverse-sigmoid sinus transition complex.

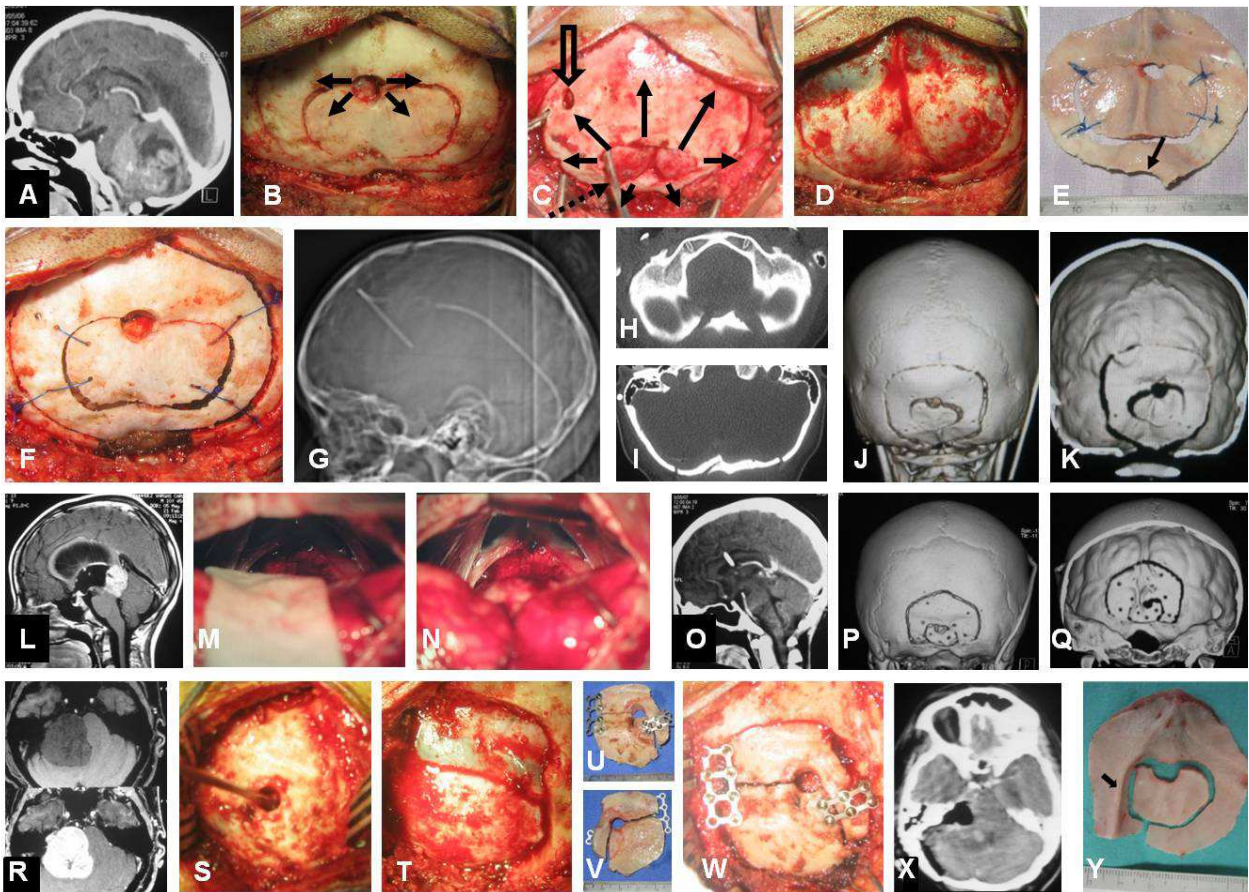


Fig. 1. Surgical technique. Cases 3 (A,B, D to G), 11 (C), 6 (H to K), 10 (L to Q), 16 (R to X) and 4 (Y); the patient with a medulloblastoma by cranial computed tomography (CT) (A) suboccipital concentric craniotomy, medial approach, initial burr-hole inferior to inion and epidural dissection (arrows) for initial craniotomy (B), follow with new epidural-venous sinus dissection (black arrows), look the venous sinus separating (open arrow) with use of dissector through the initial craniotomy (dotted arrow) (C), and cut the complete craniotomy (D) without venous sinus injury; internal cranial view of bone flap with foramen magnum opening (arrow) (E), fixed the bone flap (F), in neuroimaging using CT with reconstruction

suboccipital, (G), foramen magnum (H), occipital squama (I), tridimensional reconstruction (J,K). Suboccipital concentric craniotomy, medial approach, the patient with germinal tumor in pineal region, neuroimaging using magnetic resonance imaging (MRI) T1 weighted with gadolinium (L), infratentorial-supracerebellar approach with the tentorium *in situ* (M) and after retraction gentle (N); CT in the post-surgical (O) and tridimensional reconstruction without foramen magnum opening (P,Q). Suboccipital concentric craniotomy, lateral approach, the patient with right pontocerebellar angle neurinoma in MRI T-1 weighted simple and with gadolinium (R), and in the surgical approach the initial burr-hole inferior and medial to the asterion, dissector in the epidural level (S) and exposure de venous sinus – transverse sinus (TS) with junction to sigmoid sinus (SS) and right infra- and supratentorial dura mater (T), the bone flap with two craniotomies fixed to the cranium (U-W), CT post-surgical; and a case with bone “keel-like” projection intracranially, *arrow* (Y).

5. Key steps of the procedure

5.1 Surgical technique

Patient place in prone and/or sitting position, the Mayfield three-point fixation device is used to fix the head. Midline or lateral linear incision and dissection of the underlying soft tissue is completed. The bone flap of concentric craniotomy, using high velocity drill, in midline or lateral suboccipital craniotomy; initial burr hole inferior to inion, 1cm inferior and medial to asterion, for midline and lateral approach, respectively; and epidural dissection of internal occipital through the burr hole, cut a small-initial bone flap, after this, it's necessary to make an epidural-venous sinuses dissection from internal occipital trying separating it, cut de bone flap for a complete approach requiring with preservation of venous sinuses. Dural open and microsurgical approach is made. Close dural and the two bone flap are fixed; follow with close standard form in the level muscular and skin (Fig. 1).

6. Postoperative care

For the first days after posterior fossa craniotomy, we must attend postoperative pain; intravenous morphine is the standard for analgesia in the intensive care unit. Synthetic opioids such as fentanyl are also available. Ketorolac and other nonsteroidal anti-inflammatory agent would avoid these probably for fear of their antiplatelet effects and increased risk of bleeding. Corticosteroids are given in constant doses in the postoperative, primarily dexamethasone (1-10 mg q6h), are frequently used postoperatively in neurosurgical patients. Complications of delayed wound healing, gastric ulceration, and infection should be monitored; as well as histamine blockers (ranitidine 50mg IV q8h, famotidine 20mg IV q12h) or proton pump inhibitor is reasonable in the immediate postoperative period. Patients receiving prolonged steroid therapy could considered for continued ulcer prophylaxis. Antibiotic prophylaxis for neurosurgical conditions has various antibiotic regimens such gentamicin with vancomycin, cefalozin, piperacillin, or oxacillin, first-generation cephalosporin for minor risk of infection.

We can use external ventricular derivation or shunt in which symptoms of hydrocephalus occur.

Risks of operation include wound infection, ventriculitis/meningitis, cerebrospinal fluid leak, cerebellar signs or the posterior fossa syndrome of mutism or death.

Postoperative scans to determine whether residual lesion and suboccipital anatomical reconstruction.

7. Complications

Using the suboccipital concentric craniotomy in these cases, we none had injuries and/or tear of venous sinuses, in the posterior cranial fossa surgery.

8. Outcome

We reviewed 17 consecutive patients, who underwent surgical resection for posterior cranial fossa lesions at the Departments of Neurosurgery, in the *Hospital Central Sur de Alta Especialidad, PEMEX* and the *Instituto Nacional de Pediatría*, from Mexico City, between March 2005 to February 2008. The charts with the clinical data (age, sex, preoperative symptoms and signs), pre- and postoperative imaging studies, and operative notes (extent of resection, surgical technique) were analyzed.

The seventeen patients who were treated with suboccipital concentric craniotomy and were reported previously, show important data: age from 2 to 64 years old, media 17.23; 9 were male and female 8; 14 children and 3 adults (Table 1).

The diagnosis of the neurosurgical lesions in the posterior fossa were 15 tumors (6 medulloblastomas, 4 pineal tumors, 3 pilocytic astrocytoma, 1 neurinoma, 1 metastasis.), 1 vascular lesion and 1 trigeminal neuralgia.

Additional data: the suboccipital concentric craniotomy shows the surface in the craniotomy measures in children for medial approach was of 37.3 cm² (range 22.5cm² to 47.5cm²) and lateral approach 15.5cm² (range 14.0cm² to 17.1cm²) and in the adults, for medial approach 32.5cm² and lateral approach 15.37cm² (range 10.5cm² to 20.25cm²).

In these cases, we don't have complications for neurosurgical procedure.

9. Expert suggestions

The suboccipital concentric craniotomies for posterior cranial fossa surgery, in the midline and/or lateral, permit access to several infratentorial lesions and with risk reduced for injuries to venous sinuses and avoid profuse bleeding and/or air embolism; useful the external landmarks for initial burr hole and follow the craniotomy.

Too necessary technical aspect, such in the 4 case, that presented a bone "keel-like" projection intracranially (see Fig. 1,Y). With the principle of suboccipital concentric craniotomy, for preservation of dural and/or venous sinuses, too have applications in other cases for incomplete resection as cerebellar abscess and edema (performed a previously craniectomy), for cerebellar hemangioblastoma and edema and/or for sagittal synostectomy in sagittal craniosynostosis (in a patient with multiple synostosis)(Fig. 2).

10. Explicative cases

Case 6. This 6 year old girl was admitted with headache, vomiting, asthenia, with early symptomatic management for gastrointestinal disease without improvement for one month.

Case	Gender (♂/♀) age (years)	Clinical manifestations	Image	Diagnostics	Suboccipital concentric craniotomy						Complications.
					Measure (cm)				Surface (cm ²)		
					Middle		Lateral				
					Initial	Complete.	Initial	Complete	Initial	Complete	
1	♀8	ICH, CerSx.	CT	Medulloblastoma, HCF.	3.0x3.5	4.5x6.0	No.	No.	10.5	27.0	No.
2	♀9	ICH.	CT, MRI	Medulloblastoma, HCF.	2.5x3.0	4.5x5.5	No.	No	7.5	24.7	No.
3	♂5	ICH, CerSx.	CT	Medulloblastoma, HCF.	2.2x3.5	5.2x6.2	No.	No.	7.7	32.2	No.
4	♂15	ICH, ParinaudSx.	CT, MRI	Pineal germinoma ,HCF	2.0x2.5	5.0x6.0	No	No	5.0	30.0	No.
5‡	♀9	ICH, CerSx.	CT, MRI	Medulloblastoma.	No.	No.	1.2x2.3	3.5x4.0	4.2	14.0	No.
6	♀6	ICH.	CT, MRI	Medulloblastoma, HCF.	2.5x3.0	6.6x7.2	No.	No.	7.5	47.5	No.
7*	♂4	Cephalea.	CT, MRI	AVM and aneurysm associate.	2.0x3.2	4.6x5.8	No.	No.	6.4	26.7	No.
8	♂6	ICH, CerSx.	CT, MRI	Medulloblastoma,HCF.	1.4x2.0	4.9x5.4	No.	No.	2.8	26.5	No.
9	♂13	ICH, ParinaudSx.	CT, MRI	Pineal germinoma, HCF	1.8x2.8	4.5x5.0	No.	No.	5.0	22.5	No.
10	♂10	ICH, ParinaudSx.	CT, MRI	Pineal germinoma, HCF	1.7x2.6	4.7x5.8	No.	No.	4.4	27.3	No.
11	♀7	ICH, CerSx.	CT, MRI	Pilocytic astrocytoma.	1.9x3.5	6.1x7.4	No.	No.	6.6	45.1	No.
12	♂2	ICH, CerSx.	CT, MRI	Pilocytic astrocytoma, HCF.	1.8x3.3	5.5x6.5	No.	No.	5.9	35.7	No.
13	♂10	ICH, ParinaudSx.	MRI	Pineal germinoma,HCF	2.0x3.2	5.0x5.5	No.	No.	6.4	27.5	No.
14	♂7	ICH, CerSx.	MRI	Pilocytic astrocytoma.¶	No.	No.	2.0x2.4	3.5x4.9	4.8	17.1	No.
15	♀59	ICH, CerSx.	CT, MRI	Cerebellar metastasis	4.0x3.0	6.5x5.4	No.	No-	12.0	32.5	No.
16	♀59	ICH, CerSx.	CT, MRI	Neurinoma	No.	No.	3.5x3.0	4.5x4.5	10.5	20.25	No.
17	♀64	Facial pain.	MRI	Trigeminal neuralgia	No.	No.	2.5x3.0	3.0x3.5	7.0	10.5	No.
CerSx: cerebelar syndrome (gait abnormality, ataxia, incoordination); HCF: hydrocephalus; ICH: Intracranial hypertension (cephalea, irritability, nausea, vomiting, papilledema); CT: computed tomography; MRI: Magnetic resonante imaging; AVM: arteriovenous malformation; ‡ lateral resection of craniotomy 3.5x1.0cm; * and cerebral diagnostic angiography; ¶ relapse, resection 5 years ago.											

Table 1. Present the consecutive cases and results for use the suboccipital concentric craniotomy.

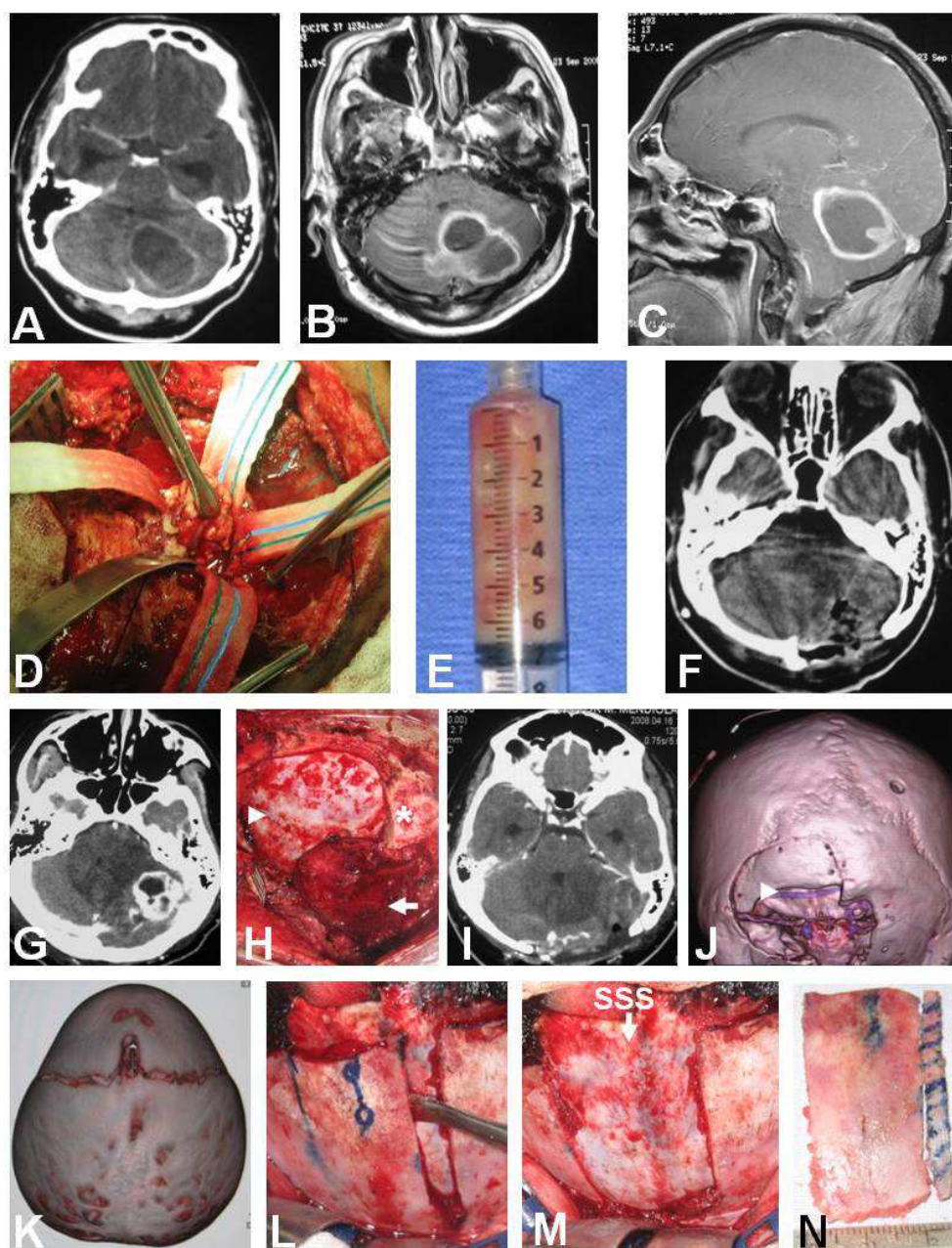


Fig. 2. Other applications with the principle of concentric craniotomy for preservation dural and/or venous sinuses. Such as a case of diabetic patient without take her hypoglycemic treatment, with cerebellar abscess and edema, posterior to drainage for stereotactic approach two weeks early, imaging CT and MRI, annular lesion and mass effect (A, B, C), intraoperative capsular resection (D), the pus (E), CT post/operative (F), in this patient performed shunt previously and craniectomy; too another case had before craniectomy and derivation ventricular external for hydrocephalus and hemangioblastoma (G), that performed re-operation see the cerebellum with congestion and herniated (arrow), preservation dural and transverse sinus (arrowhead) in the left side (H) total resection of tumor (I), duraplasty, concentric craniotomy and left transverse sinus (arrow) by CT tridimensional (J); and other patient with craniosynostosis for oxicephaly (K), with dissection dural and sagittal superior sinus (SSS) with early craniotomy parasagittal longitudinal (L), preservation of SSS (M) and sagittal synostectomy (N). *Inion.

Neurological examination revealed papilledema, horizontal nystagmus towards the left, incoordination and left brachial hypotonic (maneuver's Stewart-Holmes positive). Imaging, in the CT and MRI with obstructive hydrocephalus and tumor in the posterior fossa in the medline probably rising on the cerebellar vermis and quadrigeminal cistern extensions. First was we installed a shunt, with improvement. The operation performed with the patient in the sitting position, midline incision and suboccipital "concentric" craniotomy, without dural tear and/or venous sinuses injuries, following tumor resection (see Fig. 1, H to K). Postoperative course, the patient with improvement and had anatomical suboccipital reconstruction.

Case 17. A 52 year old female with headache, staggering gait with vertigo for one month and lowering of the hearing. Neurological examination revealed papilledema, incoordination and adiadochokinesia on the right side. Imaging, TC and MRI, showed obstructive hydrocephaly and a vestibular schwannoma in the right cerebellopontine angle. Was need performed a shunt and the operation (see Fig. 1, R to X), with total resection for lateral suboccipital craniotomy using the "concentric" form, without dural and/or venous sinuses injury exposed. Postoperative course, the patient had right facial paralysis and hypoesthesia V1, V2; with anatomical suboccipital reconstruction.

11. Acknowledgments


To David Alejandro Díaz Méndez, M.C., and Gloria Angélica Díaz Méndez, M. D., Doria Díaz Ibarra, by preparing this manuscript.

12. References

- A proposal for more informative abstracts of clinical articles. Ad Hoc Working Group for Critical Appraisal of the Medical Literature. *Ann Intern Med* 1987; 106:598-604.
- Abolghassem S, Ulrich K. Osteoplastic lateral suboccipital approach for acoustic neuroma surgery, technical note. *Neurosurgery* 2000;48:229-231.
- Al-Mefty O, Fox JL, Smith RR. Petrosal approach for petroclival meningiomas. *Neurosurgery* 1988; 22:510-517.
- Avci E, Kocaogullar Y, Fossett D, Caputy A. Lateral posterior fossa venous sinus relationships to surface landmarks. *Surg Neurol* 2003; 59: 392-7.
- Bozbuga M, Boran BO, Sahinoglu K. Surface anatomy of the posterolateral cranium regarding the localization of the initial burr-hole for a retrosigmoid approach. *Neurosurg Rev* 2006;29:61-63.
- Bucy PC. Exposure of the posterior or cerebellar fossa. *J Neurosurg* 1966; 24: 820-832.
- Critchley M.: Discussion on the differential diagnosis of lesions of the posterior fossa. *Proc R Soc Med* 1953; 46:719-738.
- Dandy WE. The treatment of trigeminal neuralgia by the cerebellar route. *Ann Surg* 1932; 96:787-795.
- Day JD, Kellogg JX, Tschabitscher M, Fukushima T. Surface and superficial surgical anatomy of the posterolateral cranial base, significance for surgical planning and approach. *Neurosurgery* 1996; 38: 1079-1084.
- Day JD, Tschabitscher M. Anatomic position of the asterion. *Neurosurgery* 1998; 42: 198-199.

- Gharabaghi A, Rosahi SK, Feigl GC, Liebig T, Mirzayan JM, Heckl S, Tatagiba M, Samii M. Image guided lateral suboccipital approach: part 1 individualized landmarks for surgical planning. *Neurosurgery* 2008; 62:S18-S23.
- Haynes RB, Murlow CD, Huth EJ, Altman DG, Gardner MJ. More informative abstracts revisited. *Ann Intern Med* 1990; 113:69-76.
- Ibarra A, Aguilar R. Craneotomía suboccipital concéntrica como variante en cirugía de fosa posterior: nota técnica. *Arch Neurocién (Mex)*, 2009; 14:206-210.
- Ibarra A, Marhx A, Rueda F, Mora I. Craneotomía suboccipital concéntrica para cirugía craneal infratentorial: resultados quirúrgicos en una serie de 14 casos. *Arch Neurocién (Mex)*, 2009; 14:151-156.
- Ibarra A, Marhx A, Rueda F. Suboccipital concentric craniotomy as variant for posterior cranial fossa surgery: outcome in a case series (paper 90). Presented at the 38th Annual Meeting of the International Society for Pediatric Neurosurgery, Jeju, South Korea, October 31 to November 4, 2010. *Childs Nerv Syst* 2010; 26: 1435-1476.
- Jannetta PJ. Hemifacial spasm. In: Samii M, Jannetta PJ (editors), *The cranial nerves, anatomy, pathology, pathophysiology, diagnosis, and treatment*. Springer-Verlag, Berlin, 1981.
- Jannetta PJ. Vascular decompression in trigeminal neuralgia. In: Samii M, Jannetta PJ (editors), *The cranial nerves, anatomy, pathology, pathophysiology, diagnosis, and treatment*. Springer-Verlag, Berlin, 1981.
- Kempe LG. *Operative neurosurgery, posterior fossa, spinal cord, and peripheral nerve disease*. Springer-Verlag, New York, 1970.
- Lang J Jr, Samii A. Retrosigmoid approach to the posterior cranial fossa, an anatomical study. *Acta Neurochir (Wien)* 1991; 111: 147-153.
- Lang J Jr, Samii A. Retrosigmoid approach to the posteriorcranial fossa, an anatomical study. *Acta Neurochir (Wien)* 1991;111:147-153.
- Levy ML, Apuzzo ML.: Supracerebellarinfratentorial approaches to the pineal region. In: Rengachary SS, Wilkins RH (editors), *Neurosurgical operative atlas*. Vol. 4, Park Ridge, Illinois, American Association of Neurological Surgeons, 1995, pp. 29-36.
- Marlin AE, Gaskill SJ. Cerebellar medulloblastoma. In: Rengachary SS, Wilkins RH (editors), *Neurosurgical operative atlas*. Vol. 1, Williams and Wilkins, Baltimore, American Association of Neurological Surgeons 1991, pp 176-83.
- Miller CG, van Loveren HR, Keller JT, Pensak M, El-Kalliny M, Tew JM Jr. Transpetrosal approach: surgical anatomy and technique. *Neurosurgery* 1993; 33:461-469.
- Ogilvy CS, Ojemann RG. Posterior fossa craniotomy for lesions of the cerebellopontine angle. *J Neurosurg* 1993; 78: 508-9. 19.
- Page LK. The infratentorial-supracerebellar exposure of tumors in the pineal area. *Neurosurgery* 1977; 1: 36-40.
- Poppen JL. *An atlas of neurosurgical techniques*. WB. Saunders, Philadelphia, 1960.
- Raimondi AJ. *Pediatric neurosurgery, theoretical principles and surgical techniques*. Springer-Verlag, New York. 1987.
- Rhoton AL Jr. The posterior cranial fossa, microsurgical anatomy and surgical approaches. *Neurosurgery* 2000; 47:S5-S6.
- Ribas GC, Rhoton AL Jr, Cruz OR, Peace D. Suboccipital burrholes and craniectomies. *Neurosurg Focus* 2005; 19: 1-12.

- Samadiana M, Nazparvar B, Haddadian K, Rezaei O, Kormae F. The anatomical relation between the superior sagittal sinus and the sagittal suture with surgical considerations. *Clin Neurol Neurosurg* 2011;113:89-91.
- Samii M, Ammirati M. The combined supra-infratentorialpresigmoidsinus avenue to the petro-clival region.Surgicaltechnique and clinical applications. *Acta Neurochir (Wien)* 1988;95:6-12.
- Sekhar LN, Tzortzidis F, Raso J. Fronto-orbital approach. In: Sekhar LN, De Oliveira E (editors), *Cranial microsurgery, approaches and techniques*, Thieme, New York, 1997: 54-60.
- Stein BM. The infratentorialsupracerebellar approach to pineal lesions. *J Neurosurg*1971; 35: 197-202.
- Stein BM. The infratentorial-supracerebellar exposure of tumors in the pineal area. *Neurosurgery* 1977; 1: 36-40.(Comment).
- Tew JM, van Loveren HR. *Atlas of operative microneurosurgery*.W. B. Saunders Company, Philadelphia, 1994.
- Tubbs RS, Loukas M, Shoja MM, Bellew MP, Cohen-Gadol AA. Surface landmarks for junction between the transverse and sigmoid sinuses: application of the “strategic” burr hole for suboccipital craniotomy. *Neurosurgery* 2009; 65:S37-S41.
- Tubbs RS, Salter G, Elton S, Grabb PA, Oakes WJ. Sagittal suture as an external landmark for the superior sagittal sinus. *J Neurosurg* 2001; 94:985-987.
- Tubbs RS, Salter G, Oakes WJ.Superficial surgical landmarksfor the transverse sinus and torcularherophili. *J Neurosurg* 2000; 93: 279-281.
- Yasargil MG, Fox JL. The microsurgical approach to acousticneurinomas.*SurgNeurol*1974; 2: 393-8.
- Yasargil MG. *Microneurosurgery*. Georg ThiemeVerlag,Stuttgart, 1984; (1):238-244.
- Yasargil MG. *Microneurosurgery*.IVB, Georg ThiemeVerlag,Stuttgart, 1996.



Explicative Cases of Controversial Issues in Neurosurgery

Edited by Dr. Francesco Signorelli

ISBN 978-953-51-0623-4

Hard cover, 534 pages

Publisher InTech

Published online 23, May, 2012

Published in print edition May, 2012

Neurosurgery is a rapidly developing field of medicine. Therefore, staying keeping track of the advancements in the field is paramount for trainees as well as fully trained neurosurgeons. This book, fully available online, is a part of our effort of improving availability of medical information for anyone who needs to keep up-to-date.

How to reference

In order to correctly reference this scholarly work, feel free to copy and paste the following:

Abraham Ibarra-de la Torre, Fernando Rueda-Franco and Alfonso Marhx-Bracho (2012). Suboccipital Concentric Craniotomy as Variant for Posterior Cranial Fossa Surgery, Explicative Cases of Controversial Issues in Neurosurgery, Dr. Francesco Signorelli (Ed.), ISBN: 978-953-51-0623-4, InTech, Available from: <http://www.intechopen.com/books/explicative-cases-of-controversial-issues-in-neurosurgery/suboccipital-concentric-craniotomy-as-variant-for-posterior-cranial-surgery>

INTECH
open science | open minds

InTech Europe

University Campus STeP Ri
Slavka Krautzeka 83/A
51000 Rijeka, Croatia
Phone: +385 (51) 770 447
Fax: +385 (51) 686 166
www.intechopen.com

InTech China

Unit 405, Office Block, Hotel Equatorial Shanghai
No.65, Yan An Road (West), Shanghai, 200040, China
中国上海市延安西路65号上海国际贵都大饭店办公楼405单元
Phone: +86-21-62489820
Fax: +86-21-62489821

© 2012 The Author(s). Licensee IntechOpen. This is an open access article distributed under the terms of the [Creative Commons Attribution 3.0 License](https://creativecommons.org/licenses/by/3.0/), which permits unrestricted use, distribution, and reproduction in any medium, provided the original work is properly cited.

IntechOpen

IntechOpen