

We are IntechOpen, the world's leading publisher of Open Access books Built by scientists, for scientists

6,900

Open access books available

186,000

International authors and editors

200M

Downloads

Our authors are among the

154

Countries delivered to

TOP 1%

most cited scientists

12.2%

Contributors from top 500 universities



WEB OF SCIENCE™

Selection of our books indexed in the Book Citation Index
in Web of Science™ Core Collection (BKCI)

Interested in publishing with us?
Contact book.department@intechopen.com

Numbers displayed above are based on latest data collected.
For more information visit www.intechopen.com



Anesthesiologic Management for Awake Craniotomy

Roberto Zoppellari, Enrico Ferri and Manuela Pellegrini
*Departement of Anesthesia and Intensive Care,
S. Anna University Hospital, Ferrara
Italy*

1. Introduction

The term “awake craniotomy” comprises the entire spectrum of surgical-anesthesiological techniques developed to allow intra-operative brain mapping during surgery in or near eloquent brain areas, in order to minimize the risk of postoperative functional sequelae.

Indeed, when dealing with brain lesions located in functional areas, such as sensorimotor, language or vision, neurosurgeons aim at removing the maximum amount of lesion minimizing the risk of producing neurological deficits so as to avoid impairing patient's quality of life. As a matter of fact, in the span of a few millimetres around the margin of the resection, as well as within the lesion to be removed, one can find eloquent sites whose function is better explored on an awake individual. In fact the collaboration of an awake patient is crucial to guide the surgeon in sparing the function while being as most radical as possible in removing the tumour.

No consensus exists about the optimal anesthetic regimen to follow, among the many proposed that allow intra-operative brain mapping. They range from local anesthesia to conscious sedation or general anesthesia with an “awake” intraoperative phase. The choice is based on the institution past experience and on different surgical needs and is generally tailored on patients characteristics and procedure durations ^{7, 39}.

Independently of the technique chosen, the anaesthesiologist should be able to provide adequate analgesia and comfort during each surgical step and should prevent nausea, vomiting and seizures, while maintaining respiratory, haemodynamic and neurologic homeostasis ⁶. Obviously, preoperative evaluation and patients selection are crucial for the success of this type of surgery ³⁷.

The aim of this chapter is to evaluate the application of different anesthesiological regimens and related intraoperative complications in awake craniotomy for resection of lesions located in eloquent brain areas.

2. Indications and contraindications of specific anesthesiological techniques

Traditionally, awake craniotomy can be performed with 3 different anesthesiological techniques ³⁹. The “Asleep-Awake-Asleep” (AAA) technique ²¹ consists of 3 phases: at first

general anesthesia is induced and the patient is intubated or ventilated through a laryngeal mask (LMA) and kept asleep until the brain is exposed; then anesthesia is discontinued and the tracheal tube or LMA removed and the patient is allowed to fully awake for brain mapping and monitoring of neurological functions to be spared. When brain mapping needs to be alternated with lesion removal, e.g. when subcortical pathways are in or near the lesion, patients are kept awake also during surgical resection; then anesthesia is induced again, the patient re-intubated or the LMA reinserted and surgery is completed. In the so called "Asleep-Awake" (AA) technique ²⁴, after completion of the tumour resection the patient is let awake or just lightly sedated until the end of surgery. The third technique, called "Monitored Anesthesia Care" (MAC) consists of sedation and analgesia, titrated to the different surgical phases, and requires the anaesthesiologist to accurately choose from an armamentarium of different drugs and to combine them and their dosages in order to achieve the desired level of sedation ^{3, 13, 27}. This technique does not require the use of tracheal tube or LMA and is centred on the association between a good loco-regional anesthesia of the scalp and the use of short acting, easy titratable anaesthetics ²⁶.

Hans considers three main reasons for performing awake craniotomy. First, no real benefit is expected from general anesthesia. The second reason is to avoid any interference between anesthetics and the electrical activity of the brain. The last and most important reason is the opportunity to take advantage of the awake state of the patient and of his capacity to co-operate during selected neurosurgical procedures (removal of lesions involving Broca's and Wernicke's speech areas or vascular lesions in or near other eloquent areas) ¹⁷.

Each anesthetic technique requires, beyond respiratory and hemodynamic control, adequate anesthesia/sedation, analgesia, and should not interfere with electrophysiologic mapping and measurements, or cognitive testing.

2.1 The Asleep-Awake-Asleep technique (AAA)

The asleep-awake-asleep technique (AAA), described above, has the advantages of a good airway control, implemented through tracheal intubation or LMA, and a deep sedation that leads the patient to feel less psychological stress and discomfort and not to feel pain. However, the AAA finds its main limitations in the fact that patients have to endure more physical stress associated with intubation, mechanical ventilation and longer hospital stays ³⁵.

During the awake period all airway devices have to be removed to enable verbal communication and patient collaboration. This manoeuvre may induce airway irritation and coughing, leading to patient movement and intracranial pressure increase with brain bulging. Reinsertion of the airway devices at the end of surgery may be cumbersome, especially for the rigid head pin-fixation ⁷. Another major drawback is the residual effect of the anesthetic used in the asleep phase on the cortical functions that are being evaluated during the awake period. Short-acting, easily titratable anesthetics should be used for this purpose ¹³.

2.2 The Asleep-Awake (AA) technique

An evolution of the technique described above, AA consists of avoiding to induce anesthesia again at the end of the procedure, thus bypassing the problems related to reinsertion of the ventilation device ⁷. Of course this entails providing sedation and analgesia for closure, thus it sums the particularities of both AAA and monitored anaesthesia care, described below.

2.3 Monitored anesthesia care

Monitored anesthesia care includes sedation with short-acting anesthetics titrated during the different phases of surgical procedure and local anesthetic infiltration of the scalp. The anesthesiologist thus provides adequate analgesia and full cooperation of the patient, addresses clinical problems and provides psychological support to patients ³⁶.

This method requires proper planning and the ability to convert the planned analgesia and sedation into general anesthesia, if necessary. Maintaining the optimal sedation level and adequate intra-operative management of the airways are the main skills required by this technique. The former is crucial, since over-sedation results in an uncooperative patient and respiratory depression, whereas under-sedation makes the patient extremely uncomfortable, anxious and restless ¹³. Fundamental is the performance of a scalp block to reduce the need for opioids and thus the risks of respiratory depression ^{9, 10}.

The combination of remifentanyl and propofol has been successfully used in spontaneously breathing patients undergoing awake craniotomy ^{17, 23}. Remifentanyl has a very short context-sensitive half life and allows rapid control of the depth of anaesthesia and great haemodynamic stability ³⁹ while propofol is associated with a decreased incidence of convulsions ¹⁹, although both drugs tend to produce respiratory depression with subsequent hypercarbia and hypoxia ^{7, 19, 39}.

Airway instrumentation may be deemed necessary by respiratory depression, uncontrollable seizures or sudden neurological deterioration. This risk is obviously increased by patient's co-morbidities, such as morbid obesity and/or obstructive sleep apnoea syndrome (OSAS) ¹⁷. The latter condition is often associated to cardiovascular disorders, such as arterial hypertension, ischemic heart disease, atrial fibrillation and stroke ³³, and is considered an absolute exclusion criteria by some authors ³⁷. Recently, some experiences have been reported on the use of continuous positive airway pressure in patients with OSAS undergoing awake craniotomy ^{15, 22}.

Obesity, as well as obstructive lung disease, is not an absolute contraindication ³⁷, but a balance between the possible benefits and risks has to be done in each case ³. In a retrospective chart review of 332 propofol-based awake craniotomies for epilepsy surgery using the AAA technique, Skucas found BMI higher than 30 to be a consistent risk factor for haemoglobin desaturation, requiring a secured airway ⁴².

Therefore, predictors of difficult airway management must be thoroughly searched for and anticipated, and are to be taken into serious account when selecting the anesthesiological management.

3. Preoperative planning

A specific and focused clinical assessment is extremely important and must consider the following aspects ^{6, 36}. Preoperative airway evaluation is essential given the difficulty of managing airway complications and the possibility of obstruction during the surgical procedure. Ease of mask airway, Mallampati score, and other predictors of difficulty with laryngoscopy, intubation and any history of past anesthesia must be extensively reviewed. The anesthesiologist must be prepared to emergent laryngoscopy, perhaps in a difficult

position because of surgical drapes or pinions, and ensure all necessary equipment is immediately at hand. As discussed above, the opinion of the authors is that OSAS is to be considered as an absolute exclusion criterion ³⁷. Patients with epilepsy should be carefully evaluated for both type and frequency of seizures, verifying the regimen and serum levels of preoperative therapy. A patient may receive an oral loading dose of phenytoin or other antiepileptic drugs, depending on the frequency of seizures.

Peripheral access sites and the need for an arterial line and urinary catheter placement should be assessed during the preoperative examination.

Obesity, gastroesophageal reflux, dysphagia and chronic cough or wheezing may be relative contraindications depending on severity ³⁶.

Evaluation of brain swelling is also important, because intracranial pressure control during spontaneous breathing is much harder compared to the mechanical ventilation setting.

Steroids, for example dexamethasone, must be considered in these cases, also to prevent nausea and vomiting, in combination with specific anti-emetic drugs, such as metoclopramide or ondansetron ¹⁷.

Other factors including tumour size, haemorrhagic risk and hemodynamic stability are considered in agreement with the surgeon.

A key role in preoperative evaluation is assessment of psychological state of patient and of his level of anxiety. Perks et al found that anxiety was common in neurosurgical patients, the incidence ranging between 60% and 92%, it was higher for female patients and regarded mostly surgical procedure and postoperative neurological deficits ³⁴.

Berkenstadt in his review describes the administration of clonidine at a dose of 2-3 mcg kg⁻¹ orally one hour before entering operating room to induce mild sedation, haemodynamic stability, as well as analgesic and anti-emetic effects with a lower incidence of cognitive deficits³.

An adequate preoperative and explanatory conversation turns out to be essential to gain patients' confidence. Patient must be informed about potential risks, safety measures, stages of procedure, and all that will occur in operating room. In a study on patient perceptions of awake brain tumour surgery, Whittle found that the procedure was well tolerated if fully explained preoperatively ⁴⁵. In this study about 20% of patients did not recall being awake although they were cooperative, 20% had more than minor discomfort, about 30% were anxious, and 15% experienced fear.

The anesthesiologist must not conceal sounds (monitor alarms, cranial drilling, elektroknife, ultrasonic surgical aspirator) or discomforts (unchangeable position, aphasia during cortical mapping) from the patient, who must understand that these discomforts are necessary to the procedure. The anesthesiologist must work in team with the neurosurgeon and speech therapist and motivate the patient, this being one major factor determining how successful the surgical procedure will be.

Selecting a patient who is able to cooperate in an unfamiliar and stressful environment for an extended period of time is crucial. As a matter of fact, it has been claimed that the only absolute contraindication to the awake technique is an uncooperative patient ³⁹.

4. Key steps of the procedure

Every patient scheduled for awake craniotomy has to be referred to the anaesthesiologist some days before surgery, to be evaluated, informed and reassured about the procedure.

Preoperative evaluation concerns mainly the possibility of maintaining airway patency during sedation for the craniotomy. In particular, the risk of obstructive sleep apnoea and criteria for difficult intubation or ventilation are considered respectively absolute and relative exclusion criteria.

On the day of surgery, in the operating room, a peripheral venous line is inserted while ECG, SpO₂ and non invasive blood pressure monitoring is set up. Supplemental oxygen is delivered through nasal prong with end tidal carbon dioxide and respiratory rate monitoring.

4.1 Monitored Anesthesia Care (MAC)

Usually, if pre-anesthesia has not been administered on the ward, midazolam 20 mcg kg⁻¹ and clonidine 1 mcg kg⁻¹ are administered intravenously. Emergency intubation equipment has to be readily available. Under light sedation an arterial line is generally set up in the radial artery, and a Foley urinary catheter may be inserted. Some key points have to be respected for the success of the technique.

1. The patients' position on the surgical table must be adjusted to be comfortable for several hours.
2. It is important to assure a good analgesia and sedation during the positioning of the Mayfield headrest and the craniotomy. Paramount is the combination of an extensive local anesthesia and intravenous sedative and analgesics, to reduce the need for opioids administration, thus minimizing the risk of oversedation. For this purpose the performance of a good scalp block (supraorbital, zygomatic-temporal, auriculotemporal, lesser and greater occipital nerves, see table 1) with ropivacaine or levo-bupivacaine is fundamental. The block must be reinforced with local anesthetic infiltration of the headpin sites and of the surgical incision line. For analgesia and sedation the anesthesiologist will chose short acting drugs, which guarantee proper titration and the rapid shift through the various phases of the procedure and above all the lack of interference with the electro-cortical stimulation and cognitive tests. Sedation depth and analgesia must be systematically assessed using a sedation score and the Visual Analogue Scale or a numeric rating scale respectively. During the head fixation and the craniotomy, sedation is titrated to obtain a Ramsay score between 3 and 4.
3. After the dura opening, sedation has to be terminated at least 15 minutes prior to intraoperative monitoring and patients maintained fully awake and cooperative until the end of brain mapping or tumour removal, depending on the type and purpose of surgery. In case of pain arising during this phase, paracetamol 1g and eventually remifentanyl 0.025-0.05 mcg kg⁻¹ min⁻¹ can be administered.
4. In the end patients are sedated again to obtain a Ramsay score between 2 and 4, as in the first part of the procedure. Sedation is withdrawn after removing the Mayfield headrest.

- 5. Postoperative analgesia can be achieved with a combination of intravenous analgesics and the repetition of the scalp block using a long lasting local anesthetic. Prevention of nausea and vomiting is another key factor in order to accomplish the patients’ comfort and satisfaction.

4.2 Asleep-Awake-Asleep (AAA) and Asleep-Awake (AA)

In the case of AAA or AA techniques, the first part of the intervention is performed under general anesthesia. This guarantees immobility and maximum patient comfort, while assuring adequate oxygenation and ventilation. Airway control is nowadays generally achieved by LMA ^{8, 14, 39}.

The key-points in these techniques are emergence from anesthesia and re-introduction of the ventilation device (AAA only). Emergence must be smooth, considering that the patient has to maintain rigid head fixation. For the same reason the AAA technique is made difficult by reinsertion of LMA. A recent report addresses the advantages of using the LMA-Supreme ³¹.

As discussed below, both techniques may take advantage from the use of short-acting anesthetics, whose fast offset allows rapid neurologic evaluation and reliable brain mapping ^{8,24,39}. This is exceedingly true for the AA technique in which drugs titration is crucial to afford the last part of surgery under sedation without airway control.

4.3 Drugs

Tumour resection, unlike epilepsy surgery, does not require routine intraoperative electrocorticography. This increases the choice of anaesthetic agents use. Anyway, the target controlled infusion (TCI) of propofol, associated to remifentanil-based analgesia, accurately titrated on the surgical stimuli, are a reasonable choice and proved to be feasible and safe. TCI infusion allows brain mapping to be performed earlier after the suspension of sedation ^{3, 17, 23, 24, 26, 39}. Non pharmacologic measures such as frequent reassurance and holding the patient’s hand cannot be overemphasised.

Dexmedetomidine is a selective alpha-2 adrenoreceptor agonist that has been shown to provide sedation and analgesia without significant respiratory depression. It also has a sparing effect on analgesia requirement. Dexmedetomidine has been used successfully in this setting, although some concerns of impaired neurocognitive testing after stopping infusion have been cast. Hypotension and bradycardia are common side effects of the drug ⁴¹.

supraorbital	lesser occipital nerve
zygomatic-temporal	greater occipital nerve
auriculotemporal	

Table 1. Nerves blocked when performing the scalp block

5. Postoperative care

The occurrence, level and duration of acute post operative pain in neurosurgical patients is not precisely known, because of a lack of clinical studies. A lot of analgesics could be used for post-craniotomy pain control, although no one is free from disadvantages. The opiates can cause nausea, vomit and respiratory depression with consequent cerebral blood flow and intracranial pressure increase. Non-steroidal anti-inflammatory drugs are not commonly used as they are associated to an increased intracranial risk of haemorrhage¹⁶.

Scalp infiltration seems to be an effective procedure in the reduction of postoperative pain, caused mainly by the surgical wound⁵. Grossman et al¹⁶ evaluated the efficacy of infiltrating the wound with lidocaine and bupivacaine associated to a single intravenous dose of metamizole for the control of postoperative pain in patients undergoing awake craniotomy. The majority of patients did not ask for extra analgesia during the first 12 postoperative hours, which are reported to be the most painful after craniotomy¹⁶.

Scalp infiltration or surgical wound infiltration with local anesthetics have been successfully associated also with paracetamol for postoperative analgesia^{20, 25, 45}.

When not associated to regional anesthesia, paracetamol alone does not appear sufficient for postoperative analgesia. In this case the addition of tramadol or nalbuphine to paracetamol seems to be necessary, with the drawback of a greater incidence of nausea and vomiting⁴⁴.

Postoperative nausea and vomiting (PONV), in patients submitted to craniotomy, represent indeed another frequent post-operative complication that asks for an indispensable treatment. Manninen indicates a comprehensive incidence of 38% with a predominance in younger compared to adult patients²⁸. The frequency of PONV seems to be lower in patients submitted to awake craniotomy compared to those submitted to craniotomy under general anaesthesia. This fact is likely due to the greater use of opioids, particularly morphine, either pre or post-operatively²⁹. The most used antiemetic is ondansetron 4-8 mg, but metoclopramide (10 mg), droperidol (0.625 mg) or dexamethasone (4-16 mg) have all been used^{18, 29, 39, 45}.

6. Complications and their treatment

Anesthesia for awake craniotomy is challenging. The risk of complications either anesthesia-related or caused by surgical stimulation has been clearly outlined by many authors^{7, 10, 24, 27, 38, 39, 42}. Seizures are reported to be a common intraoperative complication during awake craniotomy for tumour resection^{7, 27} and can be seen both in awake and in asleep patients. As reported by Conte et al, intraoperative seizures' incidence can be as high as 30% in an asleep-awake technique, but those requiring medical intervention are 6-7%⁸. Other authors report an overall incidence of intraoperative seizures lower than 8% in tumour awake surgery^{10, 39} but all patients in these series received prophylactic anticonvulsants. This high variability might also be explained by differences in seizures definition, by different level of intraoperative electrophysiological monitoring, current intensity and stimulator used, by different anesthesia or underlying patients pathology (tumour vs. intractable epilepsy or both), and seizure control^{8, 24}. Usually, seizures occur during mapping or tumour resection and are of short duration and self-limiting²⁷. It can be the case of focal seizures, whose therapy mainly consists of the irrigation of the surgical field with ice cold Ringer's lactate

solution⁴⁰. Generalized seizures not responding to ice cold irrigation can require the administration of benzodiazepines or propofol, which is much safer in an intubated and mechanically ventilated patient⁷. Although its pro- and anti-convulsant properties are still under debate, propofol sedation during epilepsy surgery is popular and does not appear to interfere with electrocorticography, provided it is suspended at least 15 minutes before recording¹⁹. Preoperative prophylaxis with phenytoin or other antiepileptic drugs is advocated by some authors⁸.

Monitored anesthesia care is an approach that does not include airway control, thus it is vulnerable to ventilation impairment, ranging from respiratory depression to airway obstruction. Their common endpoint are hypoxia and hypercarbia, leading to brain swelling. Hypoxia and hypoventilation are commonly related to over-sedation¹³. Nonetheless, Skucas and Artru, analyzing intraoperative complications in 322 patients undergoing awake craniotomy for epilepsy surgery, indicate that only 5 patients (1.5%) showed an oxygen saturation below 90%⁴².

The immediate management of airway obstruction includes decreasing sedation level, jaw thrust or instrumentation of the airways. Emergency airway devices should be immediately available throughout the procedure. Intubation under direct vision, blind nasal intubation, fiberoptic-assisted intubation and different kinds of LMA are among the possible options that have to be planned before the surgical procedure⁴¹.

Hypertension is reported with varying incidence by different authors, although by some of them invasive blood pressure monitoring was used inconsistently⁴² or even never used^{10,39}. It occurs mainly as a consequence of painful stimuli, such as application of the Mayfield headrest^{3,42}, generally without negative sequelae to the patients. Therefore, it seems reasonable to seek for a better anticipation of these stimuli with proper analgesia supplements. Remifentanyl appears the drug of choice for its favourable kinetic profile and it demonstrated to provide good haemodynamic control during particularly noxious portions of craniotomy procedures^{3,11,12,23}. Reluctance to provide sufficient anesthesia that might cause apnoea has been addressed²⁴ and occasionally intravenous antihypertensive agents may be needed⁴¹. Beta-blockers such as labetalol and esmolol are the most commonly used drugs for arterial pressure increase³⁶. Urapidil has also been used successfully for treating hypertension during awake craniotomy³⁸.

Nausea and vomiting are annoying for the patient and can make him/her agitated and uncooperative. Many studies on awake craniotomy with different techniques report an incidence varying from 0 to 9%^{4,10,24,27,39,42}. The use of propofol associated to low dose of opioids has been advocated as the cause of a minor incidence of nausea/vomiting with awake craniotomy compared to general anesthesia²⁹. The use of antiemetics can minimize its incidence, but it is not always successful because this complication is often directly related to surgical manipulation (e.g. during dural opening, mesial temporal and basal frontal lobes or amygdala manipulation, major intracranial vessels handling) or to inadequate analgesia and hypovolemia^{18,46}.

Other anesthesia-related complications are shivering, pain and poor cooperation. Shivering must be prevented by warming the patient. Clonidine, dexmedetomidine, meperidine, tramadol, nefopam, and ondansetron can be used for shivering prevention or treatment¹. Since this type of procedure is very long, forced posture may create pain. The

administration of analgesics such as paracetamol, or the titration of the ongoing analgesia and the possibility of small movements are all useful for intra-operative management. Poor cooperation and agitation may occur at any step of the procedure. They can be related to anxiety, pain, over sedation, seizures, and inadequate intra-operative psychological support ³⁶.

Venous air embolism is a rare but possible adverse event in awake craniotomy ^{2, 43}. Its occurrence must be kept in mind any time there is a pressure gradient between the surgical site and the right atrium. It is a typical complication of neurosurgical cases performed in the sitting position, with a highly variable incidence (10-80%) ³². During awake craniotomy, spontaneous breathing raises even more the pressure gradient between surgical site and right atrium, therefore favouring air suction ³⁶. However, awake craniotomy is typically performed in the lateral or supine positions, and its incidence in this setting has been reported as low as 0.64%². Diagnosis can be made with precordial Doppler ^{2, 30}. Complications can be prevented by reducing the gradient between surgical field and heart and by elevating venous pressure raising the legs above the heart level and hydrating the patient ³⁰. Patients with patent foramen ovale should be carefully evaluated for the risk of paradoxical cerebral air embolism ³⁰.

7. Outcome and prognosis

In a prospective observational study Klimek assumed that awake craniotomy (AC) and craniotomy performed under general anesthesia (GAC) may be associated with different levels of stress and consequently different inflammatory responses and release of plasma interleukins ²⁵. The authors have considered two groups of 20 patients each, undergoing respectively AC and GAC. The results obtained from pre-intra-and post operative determinations of circulating levels of IL-6, IL-8 and IL-10 suggested that awake function-controlled craniotomy does not cause a significantly different inflammatory response than craniotomy performed under general anesthesia. Postoperative pain was significantly lower in the AC group compared to the GAC group at 12 hours ²⁵. Hol et al prospectively evaluated two groups of patients undergoing awake craniotomy with a propofol-remifentanyl based sedation or craniotomy under general anesthesia, to compare the plasma amino acid profiles in the two groups as an index of physical and emotional stress and pain ²⁰. They found a significantly higher phenylalanine/tyrosine ratio, suggesting a greater oxidative stress, in the general anesthesia group, which had also a longer hospitalization and experienced greater pain ²⁰.

Monitored anesthesia care, performed combining regional scalp anesthesia with a propofol-remifentanyl sedation regimen, accomplishes the noteworthy result of obtaining an optimal sedation level throughout the entire surgical procedure, using minimal doses of opioids and propofol. We prospectively studied 70 patients undergoing awake surgery for lesions located near eloquent brain areas. As shown in the picture below, remifentanyl infusion rate, propofol concentration at the effect site and Ramsay sedation score showed a related trend throughout the procedure (fig. 1) when using our technique, pointed out in the paragraph "Expert Suggestions". At the time of the scalp block the mean Ramsay score was 2.4 ± 0.46 , remifentanyl infusion rate was $0.045 \pm 0.03 \text{ mcg kg}^{-1} \text{ min}^{-1}$ and the mean propofol concentration at the effect site was $0.14 \pm 0.12 \text{ mcg ml}^{-1}$. At the time of the bone flap removal the mean infusion rate of remifentanyl was $0.07 \pm 0.03 \text{ mcg kg}^{-1} \text{ min}^{-1}$ and the mean propofol

concentration at the effect site was 0.5 ± 0.28 mcg ml⁻¹ with a mean Ramsay score of 3.5 ± 0.6 . At the starting of intra-operative monitoring (IOM) remifentanyl and propofol had been stopped 10 minutes before: propofol concentration at the effect site was 0.11 ± 0.06 mcg ml⁻¹ and Ramsay score was 2.1 ± 0.24 .

All patients completed successfully the intervention under monitored anaesthesia care. No patient required admission to our ICU. Complications were transient and easily controlled. Hypertension was the most common intraoperative adverse event, occurring in 40% of patients, and it was treated by intravenous labetalol or urapidil boluses. The other three most common intraoperative complications were nausea (18.6%), oxygen desaturation lasting > 30 seconds (15.7%) and short duration seizures (14.3%). All complications were easily handled: nausea was treated with ondansetron 4 mg intravenously, seizures with cold irrigation of the cortex, and oxygen desaturation, being almost constantly the consequence of oversedation, was treated by lowering propofol or remifentanyl infusion. None of these events did affect the course of surgery. Postoperative pain, assessed at 2-6-12-24 hours postoperatively, was ≤ 3 on a Numeric Rating Scale.

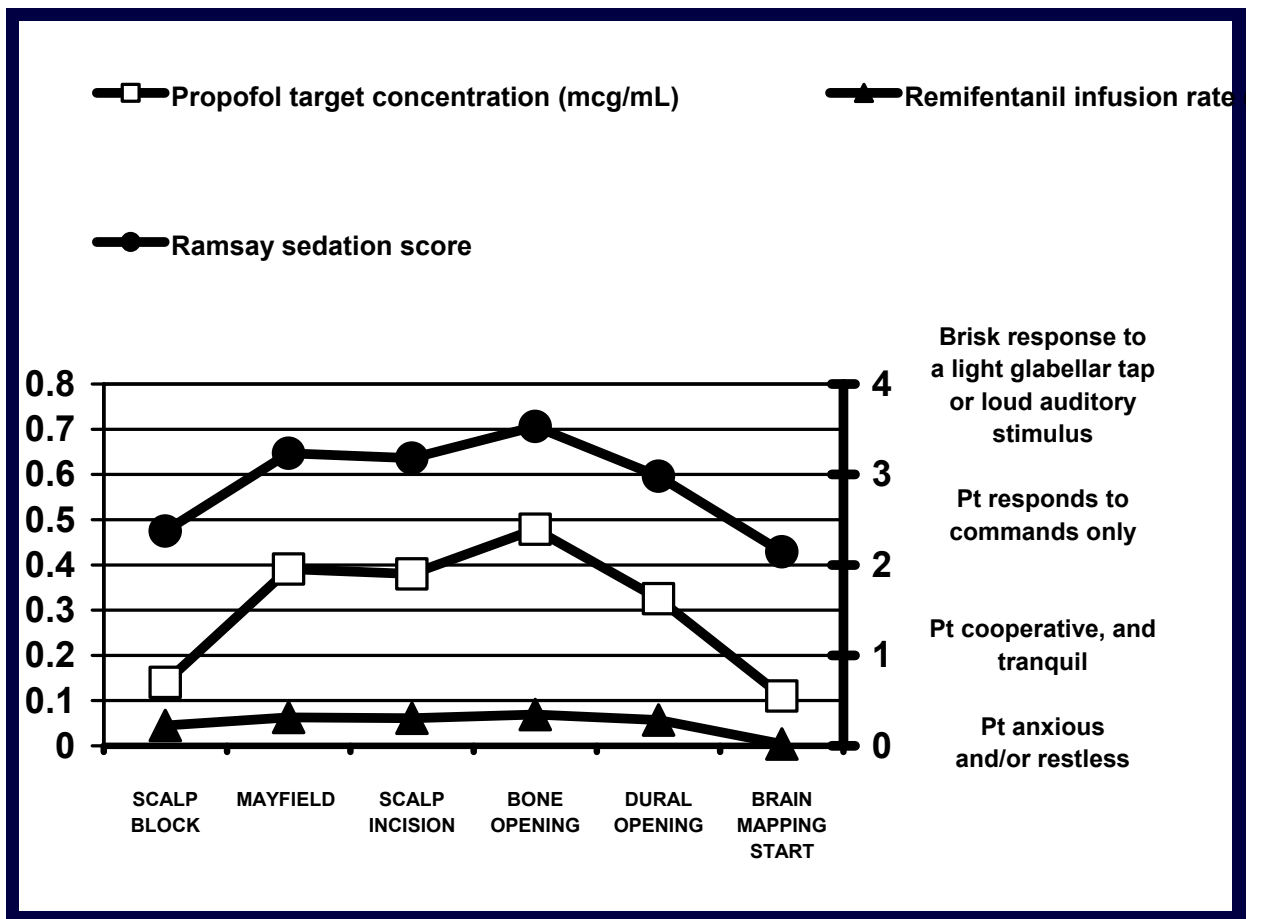


Fig. 1. Remifentanyl infusion rate, propofol concentration at the effect site and Ramsay sedation score on 70 consecutive patients undergoing awake surgery for lesions located near eloquent brain areas.

8. Expert suggestions

Preoperative assessment is the step in which the relationship between patient and anesthesiologist has to be set. Having the same doctor evaluating the patient preoperatively and performing anesthesia the day of surgery contributes to create this relationship, that is crucial for the outcome. Clear explanations, reassurance and constant feedback are the mainstay of psychological assistance that these patients deserve before and during surgery.

Airway is the main concern on the debate on the choice of anesthesia regimen, among monitored anesthesia care and asleep-awake-asleep or asleep-awake. To date, no study definitely demonstrates that one technique is superior to the others. Each institution has to develop its own protocol, as a function of past experience and results. A good rule is that the anesthesiologist should have the skills to shift from a technique to the other in any case that require general anesthesia to be instituted.

Our technique entails intravenous midazolam 20 mcg kg⁻¹ and clonidine 1 mcg kg⁻¹ at the arrival in the operating room, then sedation with propofol TCI and analgesia with remifentanyl starts, while the anesthesiologist blocks the nerves of the scalp with ropivacaine 1 %. The Mayfield headrest is positioned by preventively anaesthetizing the headpin sites with lidocaine and the surgical incision line is infiltrated with mepivacaine 1% with 1:200,000 epinephrine.

Propofol TCI is then set to reach an effect site concentration around 0.5 mcg ml⁻¹ (range 0.2 to 1.5) and remifentanyl between 0.075 and 0.1 mcg Kg⁻¹ min⁻¹. This should provide an adequate sedation without respiratory depression during bone and dura mater opening. This phase is very challenging for the anesthesiologist because haemodynamic and respiratory derangements are very likely to occur during the deepening of sedation. A Ramsay sedation score of 3 to 4 is the goal and accurate titration of propofol and remifentanyl is the key rule to accomplish it.

At the end of dura mater opening, brain mapping starts and no interference by sedation is allowed in order to test patients' neurologic function. Ten minutes in our experience are enough to allow for propofol washout since infusion is stopped. Remifentanyl low context-sensitive half-time (CSHT), independent of infusion time, provides complete washout in about three minutes.

Should patients require supplemental analgesia or light sedation to tolerate the fixed position on the operating table during brain mapping, remifentanyl up to 0.05 mcg Kg⁻¹ min⁻¹ can be administrated without impairing intraoperative neurophysiologic monitoring.

Patients are maintained fully awake and cooperative until the end of tumour removal, especially if it needs to be alternated to brain mapping, and then sedated again with propofol TCI and remifentanyl to obtain a Ramsay score between 2 and 4, as in the first part of the procedure.

9. Explicative cases

Case 1

A 52-year-old man, American Society of Anaesthesiology (ASA) physical status 2, underwent awake craniotomy under monitored anaesthesia care for a left

temporoparietooccipital grade III anaplastic oligodendroglioma placed in the rolandic area. He was on phenytoin for a former epileptic episode. He had no other relevant data on his medical history. Weight was 75 kg and Body Mass Index (BMI) was 25. The day of surgery he was prepared as described above. The procedure went on uneventfully until sedation was resumed for closure. At this time propofol effect-site concentration was 0.6 mcg ml⁻¹ and remifentanyl dosage was 0.15 mcg Kg⁻¹ min⁻¹ and SpO₂ decreased below 90% for a time frame > 30 seconds. Patient's Ramsay score was 4, he was stimulated intensely and allowed to breath deeply pure oxygen through a facial mask for some minutes, regaining rapidly SpO₂ > 95%. This event induced to lower remifentanyl infusion rate to 0.1 mcg Kg⁻¹ min⁻¹, after which no respiratory complications were seen until the end of surgery. Total operating room time was 475 minutes; propofol effect site concentration and remifentanyl infusion rate reached 0.8 mcg ml⁻¹ and 0.2 mcg Kg⁻¹ min⁻¹ respectively during skin incision and bone opening, two among the most painful phases of craniotomy. At that point PaCO₂ was 43.2 mmHg.

Comment: Oversedation occurred because painful stimulation was expected to occur and analgesia and sedation were probably resumed too promptly compared to the onset of surgical stimulation. In fact an even higher dosage of the same drugs did not produce the same effect during the opening phase, when it was adequate to pain. Lowering remifentanyl infusion rate and breathing pure oxygen through a facial mask for a few minutes are simple maneuvers that immediately resolved the complication. Excellent view and access to patient face is crucial to prevent more serious events.

Case 2

A 58-year-old man, ASA physical status 2, weight 70 kg (BMI 23.7) was scheduled to undergo awake craniotomy for a recidivating left frontotemporal astrocytoma. His past medical history revealed gastritis and craniotomy for the same tumour one year before. Surgery was foreseen to last 10 hours, and the patient, although willing to collaborate, was deemed not able to cope with such a long procedure due to anxiety. Therefore he was candidate for the asleep-awake technique. Anesthesia was induced with propofol 100 mg and remifentanyl 0.1 mcg Kg⁻¹ min⁻¹ in neutral supine position, an i-gel® supraglottic airway device # 3 was inserted and lungs were mechanically ventilated to maintain a PaCO₂ around 35 mmHg (Vt 700 ml; RR 13 breaths per min). Mayfield headrest was positioned after performing the scalp block, then he was flipped to right lateral position, and the opening phase took place. Anesthesia was maintained with propofol 2.5-3 mcg ml⁻¹ at the effect site and remifentanyl 0.15-0.2 mcg Kg⁻¹ min⁻¹. Three hours later, upon completion of dura opening, anesthesia was discontinued, the patient was awakened and the LMA removed. Fifteen minutes later brain mapping started. Intraoperative monitoring was carried out without complications for the following 2 hours, then the patient became very anxious and restless, and he claimed to be very tired and not to be able to complete the last part of the procedure in the awake state. A shift to "asleep-awake-asleep" was decided and anaesthesia was induced again. Reinsertion of i-gel® airway device was smooth despite the lateral position. I-gel® was chosen because insertion and tight adherence to the laryngeal framework in a non-supine patient could have been cumbersome using a standard LMA. Four hours later, surgery ended and the patient was successfully awakened.

Comment. This case is described to show how one should be able to modify his standard technique to adapt it to different settings. Airway management is one of the major drawbacks of AAA, and the anesthesiologist should be familiar with a large spectrum of devices to choose from in each particular case.

10. Acknowledgement

We would like to thank Dr. Anna Matina for her precious help.

11. References

- [1] Alfonsi P. Postanesthetic shivering. Epidemiology, pathophysiology and approaches to prevention and management. *Drugs* 2001; 61: 2193-205.
- [2] Balki M, Manninen PH, McGuire GP, El-Beheiry H, Bernstein M. Venous air embolism during awake craniotomy in a supine patient. *Can J Anesth* 2003; 50 (8): 835-8.
- [3] Berkenstadt H, Perel A, Hadani M, Unofrievich I, Ram Z. Monitored anesthesia care using remifentanil and propofol for awake craniotomy. *J Neurosurg Anesthesiol* 2001; 13 (3): 246-9.
- [4] Blanshard HJ, Chung F, Manninen PH, Taylor MD, Bernstein M. Awake craniotomy for removal of intracranial tumor: considerations for early discharge. *Anesth Analg* 2001; 92: 89-94.
- [5] Bloomfield E.L, Schubert A, Secic M, Barnett G, Shutway F, Ebrahim Z.Y. The Influence of scalp infiltration with bupivacaine on hemodynamics and postoperative pain in adult patients undergoing craniotomy. *Anesth Analg* 1998; 87: 579-82.
- [6] Bonhomme V, Born JD, Hans P. Anaesthetic management of awake craniotomy. *Ann Fr Anesth Reanim* 2004; 23: 389-94.
- [7] Conte V, Baratta P, Tomaselli P, Songa V, Magni L, Stocchetti N. Awake neurosurgery: an update. *Minerva Anesthesiol* 2008; 74: 289-92.
- [8] Conte V, Magni L, Songa V, Tomaselli P, Ghisoni L, Magnoni S, Bello L, Stocchetti N. Analysis of propofol/remifentanil infusion protocol for tumour surgery with intraoperative brain mapping. *J Neurosurg Anesthesiol* 2010; 22:119-127.
- [9] Costello TG, Cormack JR. Anaesthesia for awake craniotomy: a modern approach. *J Clin Neurosci.* 2004; 11: 16-9.
- [10] Danks RA, Aglio LS, Gugino LD, Black PM. Craniotomy under local anesthesia and monitored conscious sedation for the resection of tumours involving eloquent cortex. *J Neurooncol* 2000; 49 (2):131-9.
- [11] Egan T, Lemmens HJM, Fiset P, Hermann DJ. Pharm D, Muir K.T, Stanski D.R, Shafer S.L. The pharmacokinetics of the new short-acting opioid remifentanil (GI87084B) in healthy adult male volunteers. *Anesthesiology*: 1993; 79 (5): 881-92.
- [12] Egan, Talmage D. Pharmacokinetics and pharmacodynamics of remifentanil: an update in the year 2000. *Curr Opin Anaesthesiol* 2000; 13 (4): 449-55.
- [13] Frost E, Booij L. Anesthesia in the patient for awake craniotomy. *Curr Opin Anaesthesiol* 2007; 20 (4): 331-5.


- [14] Gadhinglajkar S, Sreedhar R, Abraham M. Anesthesia management of awake craniotomy performed under asleep-awake-asleep technique using laryngeal mask airway: report of two cases. *Neurol India* 2008; 56: 65-7.
- [15] Gonzales J, Lombard FW, Borel CO. Pressure support mode improves ventilation in «asleep-awake-asleep» craniotomy. *J Neurosurg Anesthesiol* 2006; 18 (1): 88.
- [16] Grossman R, Ram Z, Perel A, Yusim Y, Zaslansky R, Berkenstadt H. Control of postoperative pain after awake craniotomy with local intradermal analgesia and metamizol. *Isr Med Assoc J* 2007; 9 (5): 380-2.
- [17] Hans P, Bonhomme V. Anesthetic management for neurosurgery in awake patients. *Minerva Anesthesiol* 2007; 73 (10): 507-12.
- [18] Herrick IA, Craen RA, Gelb AW, Miller LA, Kubu CS, Girvin JP, Parrent AG, Eliasziw M, Kirkby J. Propofol sedation during awake craniotomy for seizures: patient-controlled administration versus neurolept analgesia. *Anesth Analg* 1997; 84 (6): 1285-91.
- [19] Herrick IA, Craen RA, Gelb AW, McLachlan RS, Girvin JP, Parrent AG, Eliasziw M, Kirkby J. Propofol sedation during awake craniotomy for seizures: electrocorticographic and epileptogenic effects. *Anesth Analg* 1997; 84 (6): 1280-4.
- [20] Hol JW, Klimek M, van der Heide-Mulder M, Stronks D, Vincent AJ, Klein J, Zijlstra FJ, Fekkes D. Awake craniotomy induces fewer changes in the plasma amino acid profile than craniotomy under general anesthesia. *J Neurosurg Anesthesiol* 2009; 21: 98-107.
- [21] Huncke K, Van de Wiele B, Fried I, Rubinstein E. The Asleep-Awake-Asleep anesthetic technique for intraoperative language mapping. *Neurosurgery* 1998; 42 (6): 1312-6.
- [22] Huncke T, Chan J, Doyle W, Kim J, Bekker A. The use of continuous positive airway pressure during an awake craniotomy in a patient with obstructive sleep apnea. *J Clin Anesth* 2008; 20 (4): 297-9.
- [23] Johnson KB, Egan TD. Remifentanyl and propofol combination for awake craniotomy: case report with pharmacokinetic simulations. *J Neurosurg Anesthesiol* 1998; 10 (1): 25-9.
- [24] Keifer JC, Dentchev D, Little K, Warner DS, Friedman AH, Borel CO. A retrospective analysis of a remifentanyl/propofol general anesthetic for craniotomy before awake functional brain mapping. *Anesth Analg*. 2005; 101 (2): 502-8.
- [25] Klimek M, Hol JW, Wens S, Heijmans-Antonissen C, Niehoff S, Vincent AJ, Klein J, Zijlstra FJ. Inflammatory profile of awake function-controlled craniotomy and craniotomy under general anesthesia. 2009; 2009: 670480.
- [26] Lobo, Francisco MD; Beiras, Aldara MD. Propofol and remifentanyl effect-site concentrations estimated by pharmacokinetic simulation and bispectral index monitoring during craniotomy with intraoperative awakening for brain tumour resection. *J Neurosurg Anesthesiol* 2007, 19 (3): 183-9.
- [27] Manninen PH, Balki M, Lukitto K. Bernstein M. Patient satisfaction with awake craniotomy for tumour surgery: a comparison of remifentanyl and fentanyl in conjunction with propofol. *Anesth Analg* 2006; 102: 237-42.

- [28] Manninen PH, Raman SK, Boyle K, El-Beheiry H. Reports of Investigation. Early postoperative complications following neurosurgical procedures. *Can J Anesth* 1999; 46 (1): 7-14.
- [29] Manninen PH, Tan TK. Postoperative nausea and vomiting after craniotomy for tumour surgery: a comparison between awake craniotomy and general anesthesia. *J Clin Anesth* 2002; 14 (4): 279-83.
- [30] Mirski MA, Lele AV, Fitzsimmons L, Toung T. Diagnosis and treatment of vascular air embolism. *Anesthesiology* 2007; 106 (1) : 164-77.
- [31] Murata H, Nagaishi C, Tsuda A, Sumikawa K. Laryngeal mask airway Supreme for asleep-awake-asleep craniotomy. *Br. J. Anesth.* 2010; 104 (3): 389-90.
- [32] Palmon SC, Moore LE, Lundberg J, Toung T. Venous Air Embolism: A Review. *J Clin Anesth* 1997; 9 (3): 251-7. Parati G, Lombardi C, Narkiewicz K. Sleep apnea: epidemiology, pathophysiology and relation to cardiovascular risk. *Am J Physiol Regul Integr Comp Physiol* 2007; 293 (4): R1671-83.
- [34] Perks A, Chakravarti S, Manninen P. Preoperative Anxiety in Neurosurgical Patients. *J Neurosurg Anesthesiol* 2009; 21 (2): 127-30.
- [35] Peruzzi P, Bergese SD, Vilorio A, Puente EG, Abdel-Rasoul M, Chiocca EA. A retrospective cohort-matched comparison of conscious sedation versus general anesthesia for supratentorial glioma resection. *J Neurosurg* 2011; 114 (3): 633-9.
- [36] Piccioni F, Fanzio M. Management of anesthesia in awake craniotomy. *Minerva Anesthesiol* 2008; 74 (7-8): 393-408.
- [37] Picht T, Kombos, HJ, Brock M, Suess O. Multimodal protocol for awake craniotomy in language cortex tumour surgery. *Acta Neurochir* 2006; 148: 127-38.
- [38] Saltarini M, Zorzi F. Awake craniotomy. *Minerva Anesthesiol* 2005; 71 (suppl 1, n 10): 183-5.
- [39] Sarang A, Dinsmore J. Anaesthesia for awake craniotomy-evolution of a technique that facilitates awake neurological testing. *Br J Anaesth* 2003; 90 (2): 161-5.
- [40] Sartorius CJ, Berger MS. Rapid termination of intraoperative stimulation-evoked seizures with application of cold Ringer's lactate to the cortex. Technical note. *J. Neurosurg* 1998; 88: 349-51.
- [41] See JJ, Lew TW, Kwek TK, Chin KJ, Wong MF, Liew QY, Lim SH, Ho HS, Chan Y, Loke GP, Yeo VS. Anaesthetic management of awake craniotomy for tumour resection. *Ann Acad Med Singapore* 2007; 36 (5): 319-25.
- [42] Skucas AP, Artru AA. Anesthetic complications of awake craniotomies for epilepsy surgery. *Anesth Analg* 2006; 102: 882-7.
- [43] Suarez S, Ornaque I, Fábregas N, Valero R, Carrero E. Venous Air Embolism During Parkinson Surgery in Patients with Spontaneous Ventilation. *Anesth Analg* 2010; 110: 1138-45.
- [44] Verchère E, Grenier B, Abdelghani M, Siao D, Mussa S, Maurette P. Postoperative Pain Management After Supratentorial Craniotomy. *J Neurosurg Anesthesiol* 2002; 14 (2): 96-101.
- [45] Whittle IR, Midgley S, Georges H, et al. Patient perceptions of "awake" brain tumour surgery. *Acta Neurochir* 2005; 147: 275-7.

- [46] Zorzi F, Saltarini M, Bonassin P, Vecil M, De Angelis P, De Monte A. Anesthetic management in awake craniotomy. *Signa Vitae* 2008; 3 (1) S: 28 – 32.

IntechOpen

IntechOpen



Explicative Cases of Controversial Issues in Neurosurgery

Edited by Dr. Francesco Signorelli

ISBN 978-953-51-0623-4

Hard cover, 534 pages

Publisher InTech

Published online 23, May, 2012

Published in print edition May, 2012

Neurosurgery is a rapidly developing field of medicine. Therefore, staying keeping track of the advancements in the field is paramount for trainees as well as fully trained neurosurgeons. This book, fully available online, is a part of our effort of improving availability of medical information for anyone who needs to keep up-to-date.

How to reference

In order to correctly reference this scholarly work, feel free to copy and paste the following:

Roberto Zoppellari, Enrico Ferri and Manuela Pellegrini (2012). Anesthesiologic Management for Awake Craniotomy, Explicative Cases of Controversial Issues in Neurosurgery, Dr. Francesco Signorelli (Ed.), ISBN: 978-953-51-0623-4, InTech, Available from: <http://www.intechopen.com/books/explicative-cases-of-controversial-issues-in-neurosurgery/anesthesiologic-management-for-awake-craniotomy>

INTECH
open science | open minds

InTech Europe

University Campus STeP Ri
Slavka Krautzeka 83/A
51000 Rijeka, Croatia
Phone: +385 (51) 770 447
Fax: +385 (51) 686 166
www.intechopen.com

InTech China

Unit 405, Office Block, Hotel Equatorial Shanghai
No.65, Yan An Road (West), Shanghai, 200040, China
中国上海市延安西路65号上海国际贵都大饭店办公楼405单元
Phone: +86-21-62489820
Fax: +86-21-62489821

© 2012 The Author(s). Licensee IntechOpen. This is an open access article distributed under the terms of the [Creative Commons Attribution 3.0 License](https://creativecommons.org/licenses/by/3.0/), which permits unrestricted use, distribution, and reproduction in any medium, provided the original work is properly cited.

IntechOpen

IntechOpen