

# We are IntechOpen, the world's leading publisher of Open Access books Built by scientists, for scientists

6,900

Open access books available

185,000

International authors and editors

200M

Downloads

Our authors are among the

154

Countries delivered to

TOP 1%

most cited scientists

12.2%

Contributors from top 500 universities



WEB OF SCIENCE™

Selection of our books indexed in the Book Citation Index  
in Web of Science™ Core Collection (BKCI)

Interested in publishing with us?  
Contact [book.department@intechopen.com](mailto:book.department@intechopen.com)

Numbers displayed above are based on latest data collected.  
For more information visit [www.intechopen.com](http://www.intechopen.com)



# Trigemino-cardiac Reflex in Neurosurgery – Current Knowledge and Prospects

Amr Abdulazim<sup>1</sup>, Martin N. Stienen<sup>1</sup>, Pooyan Sadr-Eshkevari<sup>2</sup>,  
Nora Prochnow<sup>1</sup>, Nora Sandu<sup>4</sup>, Benham Bohluli<sup>3</sup> and Bernhard Schaller<sup>4</sup>

<sup>1</sup>*Department of Neuroanatomy and Molecular Brain Research,  
Ruhr-University Bochum, Bochum,*

<sup>2</sup>*Farzan Clinical Research Institute, Tehran,*

<sup>3</sup>*Department of Oral and Maxillofacial Surgery,  
Tehran Azad School of Dental Medicine, Tehran,*

<sup>4</sup>*Department of Neurosurgery, University of Paris, Paris,*

<sup>1</sup>*Germany*

<sup>2,3</sup>*Iran*

<sup>4</sup>*France*

## 1. Introduction

Sudden development of cardiac arrhythmia as far as cardiac arrest, arterial hypotension, apnea and gastric hypermobility as manifestations of the trigeminocardiac reflex (TCR) were initially described in 1870 by Kratschmer *et al.* (Kratschmer, 1870) after nasal mucosa manipulation in cats and rabbits. In 1908, Aschner and Dagnini presented the oculocardiac reflex (OCR) - nowadays considered as initial description of a peripheral subtype of TCR - which gained broad attention by ophthalmologist (Blanc, *et al.*, 1983). In 1977 Kumada *et al.* (Kumada, *et al.*, 1977) described similar autonomic “trigeminal depressor” responses after low frequency electrical stimulation within portions of the trigeminal complex in anaesthetized or decerebrated rabbits, indicating that not only peripheral but also central stimulation of parts of the trigeminal pathway results in autonomic reflex responses. In 1988 the term “trigemino-cardiac reflex” was introduced by the anaesthetists Shelly and Church (Shelly and Church, 1988). In 1999, Schaller *et al.* (Schaller, *et al.*, 1999) initially described the occurrence of central TCR in human after stimulation of central parts of the trigeminal nerve during cerebellopontine angle and brain stem surgery. It was then Schaller who merged the two entities of peripheral and central TCR to a common concept, which is now generally accepted.

This chapter introduces the TCR, which has gained broad attention in the field of neurosurgery. In the past years, TCR has been reported to occur during several other neurosurgical procedures such as transsphenoidal surgery (Schaller, 2005a), Jannetta microvascular decompression (Schaller, 2005b), percutaneous radiofrequency thermocoagulation and percutaneous microcompression of the trigeminal ganglion (Meng, *et al.*, 2008), neuroendovascular approaches in neurosurgery (Amiridze, *et al.*, 2009, Lv, *et al.*,

2010, Lv, et al., 2007, Ong, et al., 2010), and during aneurysm clipping (Spiriev, et al., 2011a). As the TCR may have decisive impact on the surgical course as well as the postoperative functional outcome of neurosurgical patients with skull-base pathologies, the awareness of the TCR is essential for everyone involved in the treatment of those patients. Therefore, in the following chapter we provide the current knowledge on TCR with respect to its risk and predisposing factors, its clinical implementation in neurosurgery, preventive and therapeutical means and its influence on functional outcome. Above that, we delineate the role of the TCR as an oxygen-conserving reflex and present future aspects on TCR research.

## 2. Definition

The trigeminocardiac reflex is considered to be a brainstem reflex, and has currently been defined as a decrease in heart rate (HR) and mean arterial blood pressure (MABP) of more than 20% as compared with baseline values before application of the stimulus and coinciding with the surgical manipulation at or around any branches of the trigeminal nerve (Schaller, 2005a, Schaller, et al., 2007). However, this definition seems to be problematic as the 20% benchmark is somewhat arbitrary and implies that alterations of less than this value are not defined as TCR, which blurs the true incidence and leads to an underestimation of TCR in daily operative clinical practice. Anyway, from a statistical point of view, such a definition makes sense and therefore should be used for large series having in mind that the incidence might be underestimated by this definition. Thus, it seems more reasonable to define the TCR as any cardiac reflex triggered upon stimulation of the trigeminal nerve anywhere throughout its course. Clinically, however, TCR might be best described as sudden onset of relative bradycardia upon the stimulation of the trigeminal nerve, anywhere throughout its course. This seems to be a rather inclusive and simplified definition for TCR. Any abrupt autonomic reflex response, additional to or without a cardiac response, upon stimulation of the trigeminal nerve anywhere throughout its course may be subsumed as trigeminovagal reflex (TVR). As for the further classification, subtypes of TCR may be defined based on triggerpoints at the proximity of the central nervous system or at peripheral nerve branches. Central (proximal) TCR is triggered upon stimulation of the intracranial course of the trigeminal nerve, namely from the Gasserian ganglion to the brainstem. Peripheral (distal) TCR is elicited upon stimulation of the trigeminal nerve anywhere throughout its course outside the cranium to the Gasserian ganglion. Peripheral TCR is further subdivided based on the branch of the affected trigeminal nerve distinguishing ophthalmocardiac reflex (OCR) and maxillomandibulocardiac reflex (MCR).

## 3. Etiology and pathophysiology

Stimulation of any of the trigeminal branches or nerve endings is suggested to send the afferent signal via the Gasserian ganglion to the sensory nucleus of the trigeminal nerve within the vicinity of the floor of the fourth ventricle. Small internuncial nerve fibers of the reticular formation connect the afferent to the efferent pathway, originating from the motor nucleus of the vagal nerve. The efferent pathway sends depressor fibers to the myocardium, thus complementing the reflex arc (Figure 1) (Lang, et al., 1991, Schaller, 2004). As cardiac responses to TCR are still maintained in decerebrated animals, its circuitry is considered to be located in the brainstem (Elsner and Gooden, 1983, Schaller, 2004). Experimental results

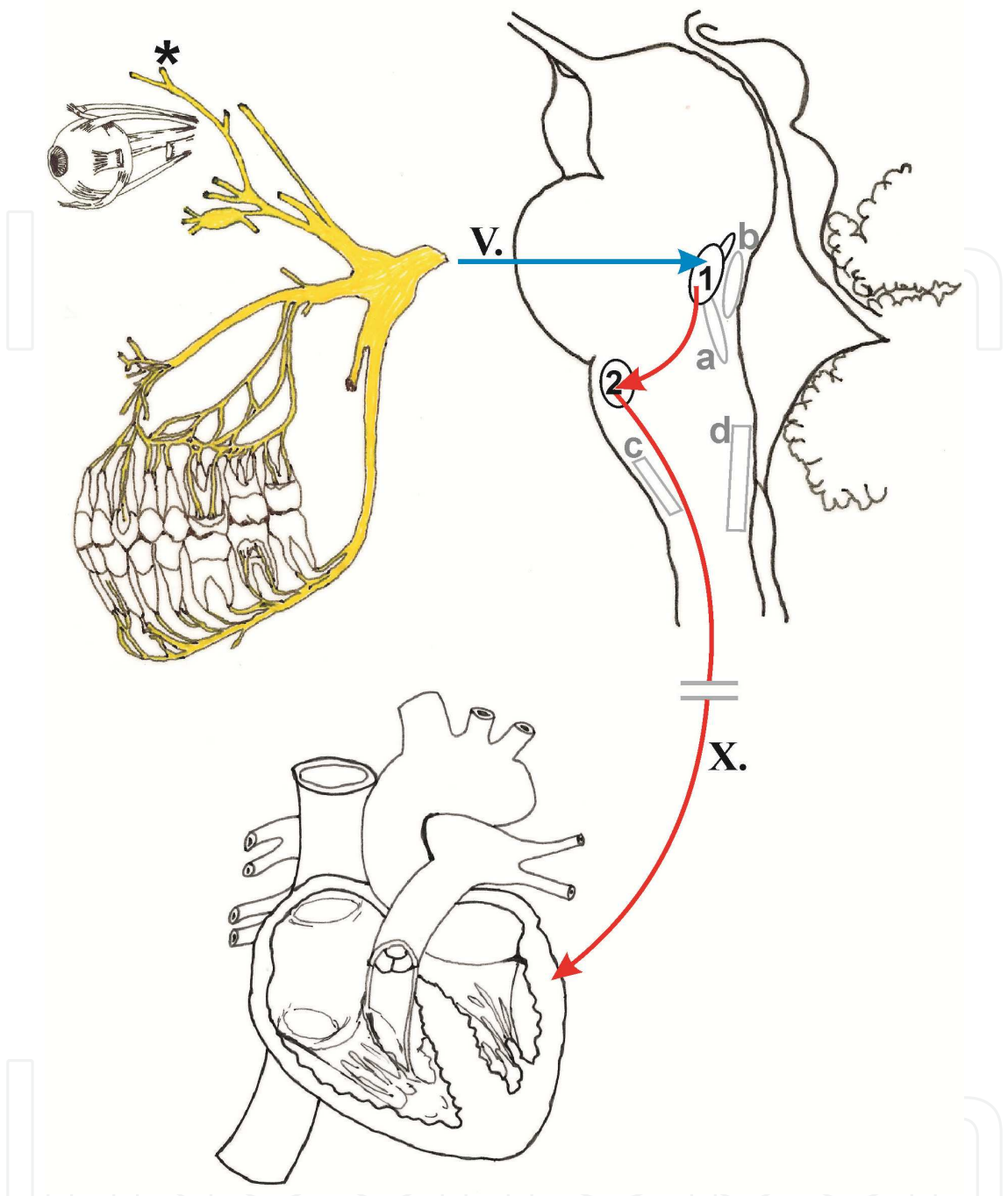


Fig. 1. The anatomy of trigeminocardiac reflex arc representing the three branches of the trigeminal nerve namely ophthalmic nerve (CN V1) responsible for OCR mediation, maxillary (CN V2) and mandibular (CN V3) nerves responsible for what the authors of the present review intend to call maxillomandibulocardiac reflex (MCR). The asterisk shows the origin of anterior ethmoidal nerve, a branch of the ophthalmic nerve, which descends into and innervates the nasal mucosa and is suggested to be responsible for the diving reflex (DR). The Gasserian ganglion, CN V root (blue arrow), the main sensory nucleus of CN V (1), internuncial fibers (upper red arrow), motor nucleus of CN X (2), and vagal myocardial depressor fibers (lower red arrow) complement the reflex arc. Further, the parabrachial nucleus (a), trigeminal nucleus caudalis (b), dorsal medullary reticular field (c), and rostral ventrolateral medulla (d) are shown for they are putatively involved in the reflex circuitry.

suggest that the TCR response is initially mediated from the trigeminal nucleus caudalis, with subsequent inclusion of the parabrachial nucleus, the rostral ventrolateral medulla oblongata, the dorsal medullary reticular field, and the paratrigeminal nucleus (Ohshita, et al., 2004, Schaller, B., et al., 2009a, Schaller and Buchfelder, 2006). However, regarding the afferent pathway, there are marked differences between subtypes of TCR, which also lead to different reflex arcs. Whereas the peripherally stimulated TCR is relayed via the spinal nucleus of the trigeminal nerve to the Kölliker-Fuse nucleus, the centrally stimulated TCR is conveyed via the nucleus of the solitary tract to the lateral parabrachial nucleus (Schaller, B., et al., 2009a). Previous studies have revealed that peripheral stimulation (anterior ethmoidal nerve in the nasal mucosa) co-activates vagal and sympathetic nerves, resulting in both sympathetically mediated peripheral vasoconstriction (hypertension) and parasympathetically mediated bradycardia (Dutschmann and Herbert, 1996, McCulloch, et al., 1999). This is in contrast to central stimulation of TCR where profound activation of the cardiac vagal branch and distinct inhibition of the inferior cardiac sympathetic nerve is observed (Nalivaiko, et al., 2003, Schaller, B., et al., 2009a).

### 3.1 Subtypes of TCR

Based on the common definition of the TCR, Schaller has included different peripherally and centrally stimulated subtypes into the TCR concept (**Table 1**) (Cornelius, et al., 2010).

#### 3.1.1 Oculocardiac Reflex (OCR)

OCR has frequently been the substrate of case series reporting severe bradycardia or asystole caused by ocular surgery (Blanc, et al., 1983). Most commonly OCR occurs in strabismus surgery, resulting from traction on the extraocular muscles. However, it can also be observed during other operations and manipulations of ocular and periocular structures innervated by the ophthalmic division of the trigeminal nerve (Anderson, 1978, Blanc, et al., 1983, Chesley and Shapiro, 1989, Kerr and Vance, 1983, Robideaux, 1978, Schaller, 2004, Stott, 1989).

#### 3.1.2 Maxillomandibulocardiac Reflex (MCR)

As thoroughly reviewed by Lang *et al.* (Lang, et al., 1991) and Bohluli *et al.* (Bohluli, et al., 2009), bradycardic reflex responses have also been observed and described for the maxillary and mandibular divisions of the trigeminal nerve during maxillofacial surgery.

#### 3.1.3 Diving Reflex (DR)

DR constitutes an intrinsic brain stem reflex that is characterized by breath-holding, slowing of the HR, reduction of limb blood flow and gradually rises of the MABP. It is elicited by the combination of water touching the face and the either voluntary or involuntary (reflex) arrest of breathing (Gooden, 1994). Functionally, the DR has been demonstrated to be a mechanism for conserving oxygen (Gooden, 1993, 1994).

#### 3.1.4 Central vs. peripheral

Both OCR and MCR are considered to represent peripheral physiological subtypes of TCR. The literature supports the hypothesis of differentially induced peripheral and central TCR (Schaller, 2004, 2005a, Schaller, B., et al., 2009a, Schaller, et al., 1999, Schaller, et al., 2007).



OCR for example is well associated with bradycardia but, in contrast to central TCR, not with hypotension (Blanc, et al., 1983, Schaller, et al., 1999). Likewise, MCR has mainly been observed without accompanying hypotension, even though this understanding has been challenged by a recent study indicating decent decrease of MABP in MCR (Bohluli, et al., 2009, Bohluli, et al., 2010). From a physiologic point of view, TCR and DR seem to be closely linked, for they both underlie similar brainstem reflex arcs. The bradycardic efferent responses of both reflexes are attributed to centers located in the medulla oblongata and are mediated by parasympathetic pathways. Equally, peripheral vasoconstriction is conducted via efferent sympathetic pathways (Cornelius, et al., 2010, Khurana, et al., 1980, Schaller, B., et al., 2009a, Schaller, et al., 1999). However, in TCR the MABP decreases, whereas it gradually increases in DR as similarly observed for peripheral TCR (Schaller, B., et al., 2009a, Schaller, et al., 2008a). These findings suggest that DR might constitute a further peripheral subform of TCR and is a phylogenetic old reflex that is only present in aberrant form in adults (Cornelius, et al., 2010, Schaller, B., et al., 2009a, Schaller, et al., 2008a).

	Peripheral TCR			Central TCR
	Ophthalmocardiac Reflex	Maxillomandibulo-cardiac Reflex	Diving Reflex	
Triggered by	pressure on ocular bulb, traction on extrinsic muscles of the eye, intraorbital injections or haematomas, acute glaucoma, stretching of the eyelid's muscles	maxillary and mandibulary branches and innervated tissues	stimulation of anterior ethmoidal nerve in the nasal mucosa	stimulation of central divisions of the trigeminal nerve including Gasserian ganglion
Afferent path	LCN/SCN -> CG -> O -> GG -> MSN V <sup>th</sup> -> SIF	VII/VIII -> GG -> MSN V <sup>th</sup> -> SIF	AEN -> GG -> Sp5C -> KF -> SIF	TN -> GG -> NTS -> LPBN -> SIF
Efferent path	MN X <sup>th</sup> -> CDN	MN X <sup>th</sup> -> CDN	MN X <sup>th</sup> -> CDN	MN X <sup>th</sup> -> CDN
Heart Rate	Bradycardia	Bradycardia	Bradycardia	Bradycardia
Respiration	Apnea	Apnea	Apnea <sup>(Gooden, 1993, 1994)</sup>	Apnea
Mean arterial blood pressure	Normotension	Normotension/ Hypotension	Hypertension	Hypotension

LCN long ciliary nerves; SCN short ciliary nerves; CG ciliary ganglion; O ophthalmic branch of the V<sup>th</sup> cranial nerve; GG Gasserian ganglion; MSN V<sup>th</sup> main sensory nucleus of the V<sup>th</sup> nerve; SIF short internuncial fibres; MN X<sup>th</sup> motor nucleus of the X<sup>th</sup> nerve; CDN cardiac depressor nerve; AEN anterior ethmoidal nerve; Sp5C spinal trigeminal nucleus, pars caudalis; KF Kölliker-Fuse nucleus; TN trigeminal nerve; NTS nucleus tractus solitarii; LPBN lateral parabrachial nucleus

Table 1. Summary of the trigeminocardiac reflex subtypes according to points of elicitation, afferent and efferent paths, heart rate, respiratory alterations, and mean arterial blood pressure changes.

### 3.2 TCR as an oxygen-conserving reflex

Beside the clinical implementation, the TCR must be seen as a physiological and phylogenetically-inherited oxygen conserving reflex as it induces an increased cerebral blood flow (CBF) without changing cerebral metabolic rates of oxygen and glucose (Sandu, et al., 2010, Schaller, B.J., et al., 2009). An increase in CBF without change of cerebral metabolic rates provides the brain with oxygen rapidly and efficiently. Cerebrovascular vasodilatation may therefore possibly be a secondary response to amend hypoxia and trigeminovagally induced hypotension. Carbon dioxide (CO<sub>2</sub>) which is increased in hypno/apneic states might be a main contributor in inducing the TCR and the subsequent protective cerebral vasodilatation, as described for oxygen conserving reflexes (Wolf, 1966). Previous studies in the anatomical circuitry of the TCR and oxygen conserving reflexes revealed the activation of brainstem areas which overlap with those described for hypoxic vasodilatation (Schaller, 2004). The latter was initially supposed to be elicited by direct effect of hypoxia on blood vessels and stimulation of arterial chemoreceptors (Schaller, 2004). TCR therefore needs to be reconsidered in terms of brain hypoxia prevention. That would, theoretically, open the door for TCR as a treatment option – for example in inducing tolerance for hypoxemia during stroke and similar ischemic conditions.

## 4. Epidemiology

As the TCR has been demonstrated to be triggered at any point throughout the course of the trigeminal nerve it can be observed during several different surgical approaches in the fields of craniofacial- and neurological surgery which involve manipulation of structures innervated by the trigeminal nerve or the trigeminal nerve itself.

### 4.1 Risk factors and predisposition

Generally accepted predisposing factors for the occurrence of intraoperative TCR constitute hypercapnia, hypoxemia, light general anaesthesia, young age (higher resting vagal tone in children), as well as strong and/or long-lasting provoking stimulus. Interestingly, bilateral stimulation of trigeminally innervated structures or of trigeminal nerve fibers results in a more profound reflex than observed in unilateral stimulation (Bauer, et al., 2005). Even though the previously mentioned risk factors are based on research done nearly 30 years ago, they could again be identified in our recent publications on this topic. In addition, Spiriev *et al.* (Spiriev, et al., 2010, Spiriev, et al., 2011b) observed perioperative TCR on the basis of a subdural empyema or exposure to H<sub>2</sub>O<sub>2</sub>, indicating that chemical or inflammatory stimuli may constitute predisposing factors. Even antecedent transient ischemic attacks less than six weeks before an operation represent a significant risk factor for subsequent intraoperative occurrence of the TCR (Nothen, et al., 2010). Furthermore drugs, including potent narcotic agents like sufentanil and alfentanil, beta-blockers and calcium channel blockers, have been reported to predispose for TCR as they inhibit the sympathetic nervous system (potent narcotics), decrease the sympathetic response of the heart (beta-blockers) and cause peripheral arterial vasodilatation resulting in reduced HR and MABP (Arasho, et al., 2009, Blanc, et al., 1983, Bohluli, et al., 2009, Campbell, et al., 1994, Lang, et al., 1991, Lubbers, et al., 2010, Schaller, et al., 1999). However, evidence for impact of those drugs is low, as effects could not be confirmed in newer literature.

Based on these findings, we have developed the concept that most risk factors lead to a sensitization of the trigeminal nerve and make it more prone to trigger TCR during intraoperative stimulation (Schaller, B., et al., 2009a, Spiriev, et al., 2011b). However, as predisposing drugs actively influence the balance of the autonomic outflow, we believe, that their effect is rather exerted via modulation of the efferent reflex pathway than in the reduction of the reception threshold of the afferent pathway.

## 5. Clinical presentation

Clinically, TCR has gained enormous attention and importance due to its potentially life-threatening complication which may include sudden onset of bradycardia culminating in asystole, asystole without preceding bradycardia or apnea (Campbell, et al., 1994, Schaller, 2004). During several different surgical procedures, including ocular- and orbital cavity surgery, maxillofacial surgery and various neurosurgical procedures, TCR has been observed subsequently to manipulation of either peripheral or central parts of the trigeminal nerve, thus affecting the ongoing operation and requiring immediate and appropriate intervention to serve the patient from devastating cardiovascular deterioration. In the following section the neurosurgical procedures in which TCR has been described and thus in which TCR needs to be attended are introduced.

### 5.1 Cerebellopontine angle surgery

In 1999, Schaller *et al.* (Schaller, et al., 1999) for the first time reported TCR after stimulation of central parts of the trigeminal nerve during surgery in the cerebellopontine angle, and thus introduced TCR to the neurosurgical community. A total of 125 patients who underwent surgery in the cerebellopontine angle due to neoplasms were monitored with respect to the occurrence of autonomic cardiovascular responses consistent with TCR. Indeed, 11% of the patients showed responses most likely attributable to TCR. While dissecting the tumor near the trigeminal nerve at the brainstem, the patient's HR and MABP decreased significantly. The mean HR fell 38% from a mean of 76 beats/minute before manipulation to a mean of 47 beats/minute during the procedure, and returned to a mean of 77 beats/minute after manipulation. The MABP fell 48% from a mean of 84 mmHg before manipulation to 44 mmHg during the procedure, and returned to 82 mmHg after manipulation. Both HR and MABP returned to normal (pre-manipulative) values after the dissection. In three cases, there was an asystole, with duration of 30 to 70 seconds and a return to a normal cardiac rhythm within 90 to 180 seconds after termination of the surgical manipulation (Schaller, et al., 1999). In each of the 14 cases, the surgical manipulation of the trigeminal nerve near the brainstem elicited a specific and unequivocal effect (sudden bradycardia and arterial hypotension). Elimination of the inducing stimulus, such as manipulations near or at the trigeminal nerve, resolved the effect and repetition of the stimulus lead to the same effect each time (Schaller, et al., 1999).

### 5.2 Transsphenoidal surgery

To determine the nature and the extent of TCR during transsphenoidal surgery, Schaller *et al.* (Schaller, 2005a) reviewed a consecutive series of 117 patients with immunohistochemically and/or electronmicroscopically diagnosed and transsphenoidally operated pituitary adenomas with special emphasize on incidence and risk factors of TCR.



The incidence for TCR in this series was 10% with lacking statistical difference between TCR- and non-TCR subgroups for the parameters age, gender, tumor histology, or the duration and distribution of preoperative symptoms. During the preparation of the nasal septum none of the patients revealed TCR. However, a significant decrease in HR and MABP was observed during lateral tumor resection near the cavernous sinus. The mean HR decrease was 43% from a mean of  $78 \pm 13$  beats/minute before manipulation to a mean of  $45 \pm 13$  beats/minute. The mean MABP decrease was 54% from a mean of  $86 \pm 8$  mmHg before to  $40 \pm 13$  mmHg during the manipulation. Within ten minutes after cessation of the stimulus and without administration of anticholinergics HR and MABP values returned to  $77 \pm 9$  beats/minute and  $82 \pm 8$  mmHg. The post-procedural values were not significantly different from preoperative baseline values. Two patients revealed asystole lasting 25-63 sec and a sinus rhythm resumed within 75-135 sec after the end of the surgical manipulation. The follow-up of these two patients was uneventful. Interestingly, TCR occurred significantly more often in patients with invasive adenomas grade III/IV, according to Hardy's classification as modified by Wilson (83% versus 22%;  $p < 0.001$ ) (Hardy, 1969, Wilson, 1983). On the basis that TCR occurred during preparation near the cavernous sinus and was associated with more invasive adenomas, which potentially invade or compress the cavernous sinus, Schaller *et al.* (Schaller, 2005a) concluded that TCR has to be elicited by structures passing the cavernous sinus. In the absence of parasympathetic fibers and with the first and second branch of the trigeminal nerve running through the cavernous sinus (branches of the trigeminal nerve innervate the cavernous sinus wall), it seems most likely that the observed autonomic response was due to TCR. This has been underlined by Abou-Zeid *et al.* (Abou-Zeid, et al., 2009), who reported the case of a patient who needed to be reoperated due to a residual pituitary adenoma adjacent to the left cavernous sinus wall. During the dissection of a small amount of tumor that was noted to be extending through the left cavernous sinus wall the patient became profoundly bradycardic and developed a 30 sec period of asystole, which rapidly reversed on the application of atropine. The bradycardia and the transient asystole also in this patient are most likely related to manifestation of TCR.

### 5.3 Microvascular trigeminal decompression (Jannetta procedure)

After TCR had been demonstrated to occur during surgery in the cerebellopontine angle and in the pituitary region, the question about the relevancy of TCR in other neurosurgical approaches necessitating preparation and manipulation of and around the trigeminal nerve remained. Thus, Schaller (Schaller, 2005b) reviewed the consecutive case histories of 28 patients who received microvascular trigeminal decompression for trigeminal neuralgia. 18% of the patients in this study displayed TCR during the course of surgery. In the time of preparation around the trigeminal nerve, the patient's HR and MABP decreased significantly. The mean HR fell 46% from a mean of 72 beats/minute before manipulation to a mean of 39 beats/minute during the procedure, returning to a mean of 75 beats/minute after manipulation. The MABP fell 57% from a mean of 81 mmHg before manipulation to 35 mmHg during the procedure, returning to 84 mmHg after manipulation. One patient developed a 33 sec lasting asystole which returned to normal cardiac rhythm within 83 sec after completion of surgical manipulation. All cases of TCR occurred while separating microvascular structures from the sensoria radix of the trigeminal nerve (Schaller, 2005b). This emphasizes that the trigeminal nerve route forms the afferent pathway of the observed autonomic responses in this study.

#### 5.4 Aneurysmal clipping

Most recently, Spiriev *et al.* (Spiriev, et al., 2011a) have reported a patient who presented with subarachnoid hemorrhage (SAH) (Hunt and Hess 2, Fischer III) following the rupture of an aneurysm of the posterior communicating artery-internal carotid artery junction (PcomA-ICA). After the sylvian fissure had been opened, the carotid and optic cisterns were approached and a careful dissection around the supraclinoid portion of the ICA with target to ambient cistern was performed. During the latter maneuver the aneurysm ruptured demanding temporary clipping of the parent vessel. After placing clips on the ICA, the patient experienced a 30 sec lasting sudden heart arrest (Spiriev, et al., 2011a). Taking into consideration that trigeminal terminals are found on all vessels of the circle of Willis and their distal branches throughout the adventitia and that the cell bodies of the supratentorial meningeal and cortical vessels lie within the ophthalmic division of the trigeminal ganglion it is possible that the observed response on the manipulation represents TCR (Simons and Ruskell, 1988). Spiriev *et al.* (Spiriev, et al., 2011a) reviewed the literature with reference to the occurrence of underlying TCR in aneurysm clipping procedures and found three further cases where cardiovascular responses are also most likely on the basis of TCR (Ganjoo, et al., 2010, Murakawa, et al., 2002, Takenaka, et al., 2006). Still, it has to be emphasized, that cardiac dysfunction including myocardial infarction is observed in up to 30% of SAH patients and has been discussed to result from excessive activity of the autonomous nervous system of unknown origin (Seule, et al., 2010). Since onset of the asystole was clearly associated with clip placement and not with the rebleeding in this patient however, the case presented by Spiriev *et al.* rather presents TCR than cardiac dysfunction associated with SAH.

#### 6. Diagnosis

Generally, there may be several different reasons for miscellaneous intraoperative cardiovascular alterations. As for declaring the occurrence of TCR one have to consider its current definition which presumes an abrupt drop of HR and MABP of more than 20% compared to baseline values and coinciding with manipulation at or around the trigeminal nerve itself or structures innervated by it. Additionally, cessation of traction needs to result in a spontaneous increase of HR and MABP values and the phenomenon has to recur when traction is repeated. Another means to prove TCR and to exclude other causes of cardiovascular alterations is blocking the nerves that conduct the afferent path of the reflex, which needs to result in alleviation of the reflex response.

#### 7. Prevention and treatment options

The risk of TCR always needs to be considered if an intervention in the territory of the trigeminal nerve is performed. The surgeon should notify the anaesthesiologist if he directly approaches the nerve or any of its branches. Direct trauma to nervous tissue should be reduced to a minimum as smooth and gentle manipulations are less likely to evoke TCR. Intraoperative factors such as light anaesthesia, hypercapnia, hypoxia and acidosis should be corrected before the beginning of the surgical manipulation as they potentiate TCR (Schaller, B., et al., 2009a). A thorough and constant monitoring of the HR and MABP during the surgical procedure allows the surgeon to immediately interrupt his surgical maneuvers once hemodynamic deteriorations from TCR occur. This has mostly been shown to be

sufficient in causing a cessation of the reflex and in restoring normal HR and blood pressure levels, without the need to administer anticholinergics (Arasho, et al., 2009, Bohluli, et al., 2009, Schaller, B., et al., 2009a). However, if bradycardia and hypotension appear to be refractory to immediate pause of the manipulation, intravenous administration of anticholinergics (atropine and/or glycopyrrolate) should be initiated (Bohluli, et al., 2009, Matturri, et al., 2005, Prabhakar, et al., 2006, Schaller, B., et al., 2009a, Schaller, B., et al., 2009b). Notably, bradycardia and hypotension in TCR may not only result from excessive vagal stimulation but also from reduction of the sympathetic tone. In these cases, the patient will not respond to vagolytics and application of epinephrine has been shown to be efficacious, also stressing that the TCR contains a sympathetically mediated component (Arasho, et al., 2009, Prabhakar, et al., 2008). Refractory TCR requiring immediate cardiac life support have been reported previously but seem to be rare (Campbell, et al., 1994, Prabhakar, et al., 2008). Recent studies have shown that local anaesthetic infiltration or block of the nerve(s) which constitute the afferent path, may accomplish a prophylaxis of the peripheral TCR (Gupta, et al., 2007, Misurya, et al., 1990, Shende, et al., 2000). Peribulbar block using bupivacaine in patients operated for retinal detachment significantly reduced the incidence and attenuated the severity of the reflex (Shende, et al., 2000). In comparison to topical local anaesthetic application in children undergoing strabismus surgery, peribulbar block was efficacious in reflex prophylaxis (Gupta, et al., 2007). Misurya *et al.* studied the effectiveness of peripheral cardiac muscarinic receptor blockade using intravenous atropine sulphate and the conduction of the afferent limb at the ciliary ganglion with retrobulbar xylocaine hydrochloride. They found, that each method was capable of reducing the rate of the OCR to 10%-20% and that the reflex was completely suppressed when both methods were combined (Misurya, et al., 1990). Still, what seems to be feasible and effective for peripheral TCR is not applicable to central TCR. This might be attributable to the fact that central TCR is elicited by central divisions near the brainstem and that, unlike peripheral TCR, its reflex circuitry is located nearly completely intrinsic to the latter (Schaller, B., et al., 2009a, Schaller, et al., 1999). From a mechanistic perspective, central manipulation of the trigeminal nerve may cause a radiated traction of the brainstem itself or of the nerve's outlet resulting in the activation of the intrinsic central reflex arc. Thus, a peripheral block of the trigeminal nerve or any of its branches would be obsolete and inefficacious in preventing the central TCR.

## 8. Outcome and prognosis

The occurrence of the TCR during a surgical procedure may significantly influence the course of the operation and threaten the patient. But despite its abrupt onset and drastic deteriorations of HR and MABP, intraoperative TCR can sufficiently be kept under control when considered adequately and managed appropriately. However, TCR does not only have significant impact on the intraoperative course but it has moreover been shown to influence the postoperative functional outcome. For example, occurrence of intraoperative TCR is correlated with postoperative ipsilateral tinnitus and decline of auditory function (Gharabaghi, et al., 2006, Schaller, et al., 2008b). Gharabaghi *et al.* (Gharabaghi, et al., 2006) have prospectively studied 100 patients scheduled for vestibular schwannoma surgery for their postoperative auditory function in correlation to the occurrence of TCR. TCR occurred in 11% of the patients and hearing function could be preserved in 47% of all patients. However, only 11.1% of the patients in the TCR group *vs.* 51.4% in the non-TCR group

experienced a preserved auditory function postoperatively (Gharabaghi, et al., 2006). On the basis of these results, Acioly *et al.* (Acioly, et al., 2010) studied if intraoperatively monitored deteriorations of the brain auditory evoked potentials (BAEP) during surgery of the cerebellopontine angle were directly connected to the occurrence of TCR. The authors were able to identify distinct BAEP alterations as predictive parameters for the risk of postoperative hearing impairment. While a definite causality of BAEP deteriorations to TCR could not be substantiated by this study, they were at least likely to result from TCR as BAEP changes in this study were not associated with previously described eliciting factors (Acioly, et al., 2010). Likewise, Schaller *et al.* (Schaller, et al., 2008b) reported the impact of TCR on postoperative ipsilateral tinnitus in patients undergoing vestibular schwannoma surgery. This retrospective study included 36 patients, with TCR occurring in a total of 17% of the patients. Overall, 22% of the investigated patients experienced postoperative ipsilateral tinnitus, whereas its incidence was up to 60% among the TCR group and just 17% among the non-TCR group (Schaller, et al., 2008b). These studies outline the putative role of TCR in affecting postoperative functional outcome, while the question regarding the pathophysiological mechanism remains unanswered. Possible explanations include changes in the vascular supply of the auditory apparatus. It is hypothesized, that in schwannoma patients an already impaired vascular supply of the medullo-pontine brainstem region due to tumor compression may be critically exaggerated by the sudden TCR-induced hypotension (Gharabaghi, et al., 2006). Substantiation for this hypothesis derives from the observation of BAEP deteriorations after TCR that are thought to be of vascular origin as they occur minutes after the eliciting reflex (Acioly, et al., 2010). Therefore, postoperative consequences are currently believed to derive from deterioration of the vascular supply.

## 9. Expert suggestions

Recently, TCR has been appreciated in the field of clinical neuroscience as its appearance may fundamentally affect patient's surgical and clinical courses. As a consequence, there are many reports and studies on TCR dealing with its clinical implementation and influence on functional outcome. These reports emphasize that knowledge on TCR, its clinical and surgical consideration and recognition, and its appropriate management is essential for neurosurgical patient care. Furthermore, the role of TCR as physiological reflex besides its detrimental role in skull base surgery has largely remained unappreciated. It seemingly plays an important yet not fully understood physiological role with respect to saving the brain from ischemic states and providing oxygen. Besides, TCR has found to be a putatively oxygen-conserving, neuroprotective reflex and is considered to be a valuable tool in prevention of brain hypoxia, for example in inducing intraintraischemic tolerance for hypoxemia during stroke. This very aspect underlines the great importance of the TCR for practice in clinical neurology and cardiovascular therapy as it might open the door for putative future treatment options.

## 10. References

- Abou-Zeid, A.H., Davis, J.R., Kearney, T. & Gnanalingham, K.K. (2009). Transient asystole during endoscopic transsphenoidal surgery for acromegaly: an example of trigeminocardiac reflex. *Pituitary*, 12, 4, 373-4, 1573-7403 (Electronic) 1386-341X (Linking)



- Acioly, M.A., Carvalho, C.H., Koerbel, A., Lowenheim, H., Tatagiba, M. & Gharabaghi, A. (2010). Intraoperative brainstem auditory evoked potential observations after trigeminocardiac reflex during cerebellopontine angle surgery. *J Neurosurg Anesthesiol*, 22, 4, (Oct), 347-53, 1537-1921 (Electronic) 0898-4921 (Linking)
- Amiridze, N., Zoarski, G., Darwish, R., Obuchowski, A. & Solovevchic, N. (2009). Embolization of a Cavernous Sinus Dural Arteriovenous Fistula with Onyx via Direct Puncture of the Cavernous Sinus through the Superior Orbital Fissure: Asystole Resulting from the Trigemino-cardiac Reflex. A Case Report. *Interv Neuroradiol*, 15, 2, (Jul 29), 179-84, 1591-0199 (Print) 1591-0199 (Linking)
- Anderson, R.L. (1978). The blepharocardiac reflex. *Arch Ophthalmol*, 96, 8, (Aug), 1418-20, 0003-9950 (Print) 0003-9950 (Linking)
- Arasho, B., Sandu, N., Spiriev, T., Prabhakar, H. & Schaller, B. (2009). Management of the trigeminocardiac reflex: facts and own experience. *Neurol India*, 57, 4, (Jul-Aug), 375-80, 0028-3886 (Print) 0028-3886 (Linking)
- Bauer, D.F., Youkilis, A., Schenck, C., Turner, C.R. & Thompson, B.G. (2005). The falcine trigeminocardiac reflex: case report and review of the literature. *Surg Neurol*, 63, 2, (Feb), 143-8, 0090-3019 (Print) 0090-3019 (Linking)
- Blanc, V.F., Hardy, J.F., Milot, J. & Jacob, J.L. (1983). The oculocardiac reflex: a graphic and statistical analysis in infants and children. *Can Anaesth Soc J*, 30, 4, (Jul), 360-9, 0008-2856 (Print) 0008-2856 (Linking)
- Bohluli, B., Ashtiani, A.K., Khayampoor, A. & Sadr-Eshkevari, P. (2009). Trigemino-cardiac reflex: a MaxFax literature review. *Oral Surg Oral Med Oral Pathol Oral Radiol Endod*, 108, 2, (Aug), 184-8, 1528-395X (Electronic) 1079-2104 (Linking)
- Bohluli, B., Bayat, M., Sarkarat, F., Moradi, B., Tabrizi, M.H. & Sadr-Eshkevari, P. (2010). Trigemino-cardiac reflex during Le Fort I osteotomy: a case-crossover study. *Oral Surg Oral Med Oral Pathol Oral Radiol Endod*, 110, 2, (Aug), 178-81, 1528-395X (Electronic) 1079-2104 (Linking)
- Campbell, R., Rodrigo, D. & Cheung, L. (1994). Asystole and bradycardia during maxillofacial surgery. *Anesth Prog*, 41, 1, 13-6, 0003-3006 (Print) 0003-3006 (Linking)
- Chesley, L.D. & Shapiro, R.D. (1989). Oculocardiac reflex during treatment of an orbital blowout fracture. *J Oral Maxillofac Surg*, 47, 5, (May), 522-3, 0278-2391 (Print) 0278-2391 (Linking)
- Cornelius, J.F., Sadr-Eshkevari, P., Arasho, B.D., Sandu, N., Spiriev, T., Lemaitre, F. & Schaller, B. (2010). The trigemino-cardiac reflex in adults: own experience. *Expert Rev Cardiovasc Ther*, 8, 7, (Jul), 895-8, 1744-8344 (Electronic) 1477-9072 (Linking)
- Dutschmann, M. & Herbert, H. (1996). The Kolliker-Fuse nucleus mediates the trigeminally induced apnoea in the rat. *Neuroreport*, 7, 8, (May 31), 1432-6, 0959-4965 (Print) 0959-4965 (Linking)
- Elsner, R. & Gooden, B. (1983). Diving and asphyxia. A comparative study of animals and man. *Monogr Physiol Soc*, 40, 1-168, 0079-2020 (Print) 0079-2020 (Linking)
- Ganjoo, P., Navkar, D.V. & Tandon, M.S. (2010). Complete heart block complicating intracranial aneurysm surgery in a pregnant patient. *Neurol India*, 58, 1, (Jan-Feb), 146, 0028-3886 (Print) 0028-3886 (Linking)
- Gharabaghi, A., Koerbel, A., Samii, A., Kaminsky, J., von Goesseln, H., Tatagiba, M. & Samii, M. (2006). The impact of hypotension due to the trigeminocardiac reflex on




- auditory function in vestibular schwannoma surgery. *J Neurosurg*, 104, 3, (Mar), 369-75, 0022-3085 (Print) 0022-3085 (Linking)
- Gooden, B.A. (1993). The evolution of asphyxial defense. *Integr Physiol Behav Sci*, 28, 4, (Oct-Dec), 317-30, 1053-881X (Print) 1053-881X (Linking)
- Gooden, B.A. (1994). Mechanism of the human diving response. *Integr Physiol Behav Sci*, 29, 1, (Jan-Mar), 6-16, 1053-881X (Print) 1053-881X (Linking)
- Gupta, N., Kumar, R., Kumar, S., Sehgal, R. & Sharma, K.R. (2007). A prospective randomised double blind study to evaluate the effect of peribulbar block or topical application of local anaesthesia combined with general anaesthesia on intra-operative and postoperative complications during paediatric strabismus surgery. *Anaesthesia*, 62, 11, (Nov), 1110-3, 0003-2409 (Print) 0003-2409 (Linking)
- Hardy, J. (1969). Transsphenoidal microsurgery of the normal and pathological pituitary. *Clin Neurosurg*, 16, 185-217,
- Kerr, W.J. & Vance, J.P. (1983). Oculocardiac reflex from the empty orbit. *Anaesthesia*, 38, 9, (Sep), 883-5, 0003-2409 (Print) 0003-2409 (Linking)
- Khurana, R.K., Watabiki, S., Hebel, J.R., Toro, R. & Nelson, E. (1980). Cold face test in the assessment of trigeminal-brainstem-vagal function in humans. *Ann Neurol*, 7, 2, (Feb), 144-9, 0364-5134 (Print) 0364-5134 (Linking)
- Kratschmer, F. (1870). Influence of reflexes of the nasal mucosa on breathing and circulatory. *Sber Akad Wis Wien*, 62, 147 - 170,
- Kumada, M., Dampney, R.A. & Reis, D.J. (1977). The trigeminal depressor response: a novel vasodepressor response originating from the trigeminal system. *Brain Res*, 119, 2, (Jan 7), 305-26, 0006-8993 (Print) 0006-8993 (Linking)
- Lang, S., Lanigan, D.T. & van der Wal, M. (1991). Trigemino-cardiac reflexes: maxillary and mandibular variants of the oculocardiac reflex. *Can J Anaesth*, 38, 6, (Sep), 757-60, 0832-610X (Print) 0832-610X (Linking)
- Lubbers, H.T., Zweifel, D., Gratz, K.W. & Kruse, A. (2010). Classification of potential risk factors for trigeminocardiac reflex in craniomaxillofacial surgery. *J Oral Maxillofac Surg*, 68, 6, (Jun), 1317-21, 1531-5053 (Electronic) 0278-2391 (Linking)
- Lv, X., Li, Y., Jiang, C. & Wu, Z. (2010). The incidence of trigeminocardiac reflex in endovascular treatment of dural arteriovenous fistula with onyx. *Inter Neuroradiol*, 16, 1, (Mar), 59-63, 1591-0199 (Print) 1591-0199 (Linking)
- Lv, X., Li, Y., Lv, M., Liu, A., Zhang, J. & Wu, Z. (2007). Trigemino-cardiac reflex in embolization of intracranial dural arteriovenous fistula. *AJNR Am J Neuroradiol*, 28, 9, (Oct), 1769-70, 0195-6108 (Print) 0195-6108 (Linking)
- Matturri, L., Ottaviani, G. & Lavezzi, A.M. (2005). Sudden infant death triggered by dive reflex. *J Clin Pathol*, 58, 1, (Jan), 77-80, 0021-9746 (Print) 0021-9746 (Linking)
- McCulloch, P.F., Faber, K.M. & Panneton, W.M. (1999). Electrical stimulation of the anterior ethmoidal nerve produces the diving response. *Brain Res*, 830, 1, (May 29), 24-31, 0006-8993 (Print) 0006-8993 (Linking)
- Meng, Q., Zhang, W., Yang, Y., Zhou, M. & Li, X. (2008). Cardiovascular responses during percutaneous radiofrequency thermocoagulation therapy in primary trigeminal neuralgia. *J Neurosurg Anesthesiol*, 20, 2, (Apr), 131-5, 1537-1921 (Electronic) 0898-4921 (Linking)

- Misurya, V.K., Singh, S.P. & Kulshrestha, V.K. (1990). Prevention of oculocardiac reflex (O.C.R) during extraocular muscle surgery. *Indian J Ophthalmol*, 38, 2, (Apr-Jun), 85-7, 0301-4738 (Print) 0301-4738 (Linking)
- Murakawa, T., Jin, T. & Matsuki, A. (2002). [A case of ventricular fibrillation during emergency clipping operation for cerebral aneurysm]. *Masui*, 51, 2, (Feb), 203-5, 0021-4892 (Print) 0021-4892 (Linking)
- Nalivaiko, E., De Pasquale, C.G. & Blessing, W.W. (2003). Electrocardiographic changes associated with the nasopharyngeal reflex in conscious rabbits: vago-sympathetic co-activation. *Auton Neurosci*, 105, 2, (May 30), 101-4, 1566-0702 (Print) 1566-0702 (Linking)
- Nothen, C., Sandu, N., Prabhakar, H., Filis, A., Arasho, B.D., Buchfelder, M. & Schaller, B.J. (2010). Trigemino-cardiac reflex and antecedent transient ischemic attacks. *Expert Rev Cardiovasc Ther*, 8, 4, (Apr), 509-12, 1744-8344 (Electronic) 1477-9072 (Linking)
- Ohshita, N., Nakajo, N. & Takemura, M. (2004). Characteristics of the trigeminal depressor response in cats. *J Neurosci Res*, 76, 6, (Jun 15), 891-901, 0360-4012 (Print) 0360-4012 (Linking)
- Ong, C.K., Ong, M.T., Le, K., Power, M.A., Wang, L.L., Lam, D.V., Parkinson, R.J. & Wenderoth, J.D. (2010). The trigeminocardiac reflex in Onyx embolisation of intracranial dural arteriovenous fistula. *J Clin Neurosci*, 17, 10, (Oct), 1267-70, 1532-2653 (Electronic) 0967-5868 (Linking)
- Prabhakar, H., Ali, Z. & Rath, G.P. (2008). Trigemino-cardiac reflex may be refractory to conventional management in adults. *Acta Neurochir (Wien)*, 150, 5, (May), 509-10, 0942-0940 (Electronic) 0001-6268 (Linking)
- Prabhakar, H., Anand, N., Chouhan, R.S. & Bithal, P.K. (2006). Sudden asystole during surgery in the cerebellopontine angle. *Acta Neurochir (Wien)*, 148, 6, (Jun), 699-700; discussion 700, 0001-6268 (Print) 0001-6268 (Linking)
- Robideaux, V. (1978). Oculocardiac reflex caused by midface disimpaction. *Anesthesiology*, 49, 6, (Dec), 433, 0003-3022 (Print) 0003-3022 (Linking)
- Sandu, N., Spiriev, T., Lemaitre, F., Filis, A. & Schaller, B. (2010). New molecular knowledge towards the trigemino-cardiac reflex as a cerebral oxygen-conserving reflex. *ScientificWorldJournal*, 10, 811-7, 1537-744X (Electronic) 1537-744X (Linking)
- Schaller, B. (2004). Trigemino-cardiac reflex. A clinical phenomenon or a new physiological entity? *J Neurol*, 251, 6, (Jun), 658-65, 0340-5354 (Print) 0340-5354 (Linking)
- Schaller, B. (2005a). Trigemino-cardiac reflex during transsphenoidal surgery for pituitary adenomas. *Clin Neurol Neurosurg*, 107, 6, (Oct), 468-74, 0303-8467 (Print) 0303-8467 (Linking)
- Schaller, B. (2005b). Trigemino-cardiac reflex during microvascular trigeminal decompression in cases of trigeminal neuralgia. *J Neurosurg Anesthesiol*, 17, 1, (Jan), 45-8, 0898-4921 (Print) 0898-4921 (Linking)
- Schaller, B., Cornelius, J.F., Prabhakar, H., Koerbel, A., Gnanalingham, K., Sandu, N., Ottaviani, G., Filis, A. & Buchfelder, M. (2009a). The trigemino-cardiac reflex: an update of the current knowledge. *J Neurosurg Anesthesiol*, 21, 3, (Jul), 187-95, 1537-1921 (Electronic) 0898-4921 (Linking)
- Schaller, B., Probst, R., Strebel, S. & Gratzl, O. (1999). Trigemino-cardiac reflex during surgery in the cerebellopontine angle. *J Neurosurg*, 90, 2, (Feb), 215-20, 0022-3085 (Print) 0022-3085 (Linking)

- Schaller, B., Sandu, N., Filis, A., Ottaviani, G., Rasper, J., Noethen, C. & Buchfelder, M. (2009b). Trigemino-cardiac reflex: the trigeminal depressor responses during skull base surgery. *Clin Neurol Neurosurg*, 111, 2, (Feb), 220, 1872-6968 (Electronic) 0303-8467 (Linking)
- Schaller, B.J. & Buchfelder, M. (2006). Trigemino-cardiac reflex in skull base surgery: from a better understanding to a better outcome? *Acta Neurochir (Wien)*, 148, 10, (Oct), 1029-31; discussion 1031, 0001-6268 (Print) 0001-6268 (Linking)
- Schaller, B.J., Filis, A. & Buchfelder, M. (2008a). Trigemino-cardiac reflex in humans initiated by peripheral stimulation during neurosurgical skull-base operations. Its first description. *Acta Neurochir (Wien)*, 150, 7, (Jul), 715-7; discussion 717-8, 0942-0940 (Electronic) 0001-6268 (Linking)
- Schaller, B.J., Rasper, J., Filis, A. & Buchfelder, M. (2008b). Difference in functional outcome of ipsilateral tinnitus after intraoperative occurrence of the trigemino-cardiac reflex in surgery for vestibular schwannomas. *Acta Neurochir (Wien)*, 150, 2, (Feb), 157-60, 0942-0940 (Electronic) 0001-6268 (Linking)
- Schaller, B.J., Sandu, N., Cornelius, J.F., Filis, A. & Perez-Pinzon, M.A. (2009). Oxygen-conserving implications of the trigemino-cardiac reflex in the brain: the molecular basis of neuroprotection? *Mol Med*, 15, 5-6, (May-Jun), 125-6, 1528-3658 (Electronic) 1076-1551 (Linking)
- Schaller, B.J., Weigel, D., Filis, A. & Buchfelder, M. (2007). Trigemino-cardiac reflex during transsphenoidal surgery for pituitary adenomas: methodological description of a prospective skull base study protocol. *Brain Res*, 1149, (May 29), 69-75, 0006-8993 (Print) 0006-8993 (Linking)
- Seule, M.A., Stienen, M.N., Cadosch, D., Fournier, J.Y., Lussmann, R., Hildebrandt, G. & Gautschi, O.P. (2010). [Aneurysmal subarachnoid hemorrhage - therapy and complications]. *Anesthesiol Intensivmed Notfallmed Schmerzther*, 45, 1, (Jan), 8-17, 1439-1074 (Electronic) 0939-2661 (Linking)
- Shelly, M.P. & Church, J.J. (1988). Bradycardia and facial surgery. *Anaesthesia*, 43, 422,
- Shende, D., Sadhasivam, S. & Madan, R. (2000). Effects of peribulbar bupivacaine as an adjunct to general anaesthesia on peri-operative outcome following retinal detachment surgery. *Anaesthesia*, 55, 10, (Oct), 970-5, 0003-2409 (Print) 0003-2409 (Linking)
- Simons, T. & Ruskell, G.L. (1988). Distribution and termination of trigeminal nerves to the cerebral arteries in monkeys. *J Anat*, 159, (Aug), 57-71, 0021-8782 (Print) 0021-8782 (Linking)
- Spiriev, T., Kondoff, S. & Schaller, B. (2011a). Trigemino-cardiac reflex during temporary clipping in aneurysmal surgery: first description. *J Neurosurg Anesthesiol*, 23, 3, (Jul), 271-2, 1537-1921 (Electronic) 0898-4921 (Linking)
- Spiriev, T., Sandu, N., Arasho, B., Kondoff, S., Tzekov, C. & Schaller, B. (2010). A new predisposing factor for trigemino-cardiac reflex during subdural empyema drainage: a case report. *J Med Case Reports*, 4, 391, 1752-1947 (Electronic) 1752-1947 (Linking)
- Spiriev, T., Tzekov, C., Kondoff, S., Laleva, L., Sandu, N., Arasho, B. & Schaller, B. (2011b). Trigemino-cardiac reflex during chronic subdural haematoma removal: report of chemical initiation of dural sensitization. *JRSM Short Rep*, 2, 4, 27, 2042-5333 (Electronic)

- Stott, D.G. (1989). Reflex bradycardia in facial surgery. *Br J Plast Surg*, 42, 5, (Sep), 595-7, 0007-1226 (Print) 0007-1226 (Linking)
- Takenaka, I., Aoyama, K., Iwagaki, T., Ishimura, H. & Kadoya, T. (2006). Development of torsade de pointes caused by exacerbation of QT prolongation during clipping of cerebral artery aneurysm in a patient with subarachnoid haemorrhage. *Br J Anaesth*, 97, 4, (Oct), 533-5, 0007-0912 (Print) 0007-0912 (Linking)
- Wilson, C. (1983). Surgical management of endocrine-active pituitary adenomas, *Oncology of the nervous system*, M. Walker, 117-150 Martinus Nijhoff, Boston
- Wolf, S. (1966). Sudden death and the oxygen-conserving reflex. *Am Heart J*, 71, 6, (Jun), 840-1, 0002-8703 (Print) 0002-8703 (Linking)



## **Explicative Cases of Controversial Issues in Neurosurgery**

Edited by Dr. Francesco Signorelli

ISBN 978-953-51-0623-4

Hard cover, 534 pages

**Publisher** InTech

**Published online** 23, May, 2012

**Published in print edition** May, 2012

Neurosurgery is a rapidly developing field of medicine. Therefore, staying keeping track of the advancements in the field is paramount for trainees as well as fully trained neurosurgeons. This book, fully available online, is a part of our effort of improving availability of medical information for anyone who needs to keep up-to-date.

### **How to reference**

In order to correctly reference this scholarly work, feel free to copy and paste the following:

Amr Abdulazim, Martin N. Stienen, Pooyan Sadr-Eshkevari, Nora Prochnow, Nora Sandu, Benham Bohluli and Bernhard Schaller (2012). Trigemino-cardiac Reflex in Neurosurgery - Current Knowledge and Prospects, Explicative Cases of Controversial Issues in Neurosurgery, Dr. Francesco Signorelli (Ed.), ISBN: 978-953-51-0623-4, InTech, Available from: <http://www.intechopen.com/books/explicative-cases-of-controversial-issues-in-neurosurgery/the-trigemino-cardiac-reflex-in-neurosurgery-current-knowledge-and-prospects>

**INTech**  
open science | open minds

### **InTech Europe**

University Campus STeP Ri  
Slavka Krautzeka 83/A  
51000 Rijeka, Croatia  
Phone: +385 (51) 770 447  
Fax: +385 (51) 686 166  
[www.intechopen.com](http://www.intechopen.com)

### **InTech China**

Unit 405, Office Block, Hotel Equatorial Shanghai  
No.65, Yan An Road (West), Shanghai, 200040, China  
中国上海市延安西路65号上海国际贵都大饭店办公楼405单元  
Phone: +86-21-62489820  
Fax: +86-21-62489821



© 2012 The Author(s). Licensee IntechOpen. This is an open access article distributed under the terms of the [Creative Commons Attribution 3.0 License](https://creativecommons.org/licenses/by/3.0/), which permits unrestricted use, distribution, and reproduction in any medium, provided the original work is properly cited.

IntechOpen

IntechOpen