

# We are IntechOpen, the world's leading publisher of Open Access books Built by scientists, for scientists

6,900

Open access books available

186,000

International authors and editors

200M

Downloads

Our authors are among the

154

Countries delivered to

TOP 1%

most cited scientists

12.2%

Contributors from top 500 universities



WEB OF SCIENCE™

Selection of our books indexed in the Book Citation Index  
in Web of Science™ Core Collection (BKCI)

Interested in publishing with us?  
Contact [book.department@intechopen.com](mailto:book.department@intechopen.com)

Numbers displayed above are based on latest data collected.  
For more information visit [www.intechopen.com](http://www.intechopen.com)



# Emerging Technology and Analytical Techniques for the Clinical Assessment of Scoliosis

Karl F. Zabjek and Reinhard Zeller

*Department of Physical Therapy, University of Toronto  
The Hospital for Sick Children  
Canada*

## 1. Introduction

Paediatric spinal deformities are the most prevalent musculoskeletal conditions observed in children and youth. Idiopathic Scoliosis (IS), a sub-class of these spinal deformities is commonly recognized by a lateral curvature of the spine that is of unknown cause and has the greatest risk of progression during periods of rapid growth and development.[1,2,3] The emergence of our contemporary perspective that this lateral curvature and axial rotation of the spine [4] is also accompanied by significant spatial disorientation of the spine and thoracic cage, [5,6] has motivated clinicians and scientists to develop new models of assessment for the purpose of guiding clinical decisions, orthopaedic interventions, and the evaluation of clinical outcomes.

Historically, the clinical management of IS has posed a significant challenge to the orthopaedic community. In part, this challenge arises from the complex inter-relationship between skeletal growth, deformity, vertebral spatial orientation, mechanical loading, and the neuromuscular mechanisms that control stability of the spine.[8,9] The advent of modern day clinical and diagnostic imaging tools has provided an opportunity to describe, and characterize the breadth of deformity and spatial disorganisation of the spine across children and youth who are living with IS. In particular, three-dimensional imaging techniques have provided unique insight into the complexity and severity of vertebral deformity, and the complex translation and rotation of individual vertebral elements and the spine.[5,6,9,10,11] In parallel, clinical observational tools [12,13] and optoelectronic techniques [14,15,16] have enhanced our knowledge related to the extent of trunk surface deformity and spatial disorientation of the pelvis, thoracic cage, and shoulders[12-16]. Emerging technological developments have provided a unique opportunity to enhance our contemporary understanding of IS, and provide information that may compliment current models of clinical assessment.

The overall aim of this chapter is to provide an overview of current clinical models of assessment for scoliosis, and bring to attention new approaches that may provide opportunity to enhance fundamental knowledge and compliment clinical models of assessment. The specific aims are: 1) review the theoretical construct of posture; 2) identify

the clinical terms and frames of reference that are commonly adopted to describe the posture of children and youth with IS; 3) identify and discuss the potential of emerging techniques that may enhance current clinical models of assessment.

## 2. Contemporary models of assessment for Idiopathic Scoliosis

The standard clinical model of assessment for children and youth who are evaluated for IS typically involves a review of family history, a neuromuscular exam, observation of posture and mobility and a radiological evaluation of the spine. This clinical model founds the diagnosis for IS, and guides the clinical decisions that are fundamental to the clinical management of the spinal deformity.

Although a subtle curvature of the spine and spatial disorientation of the pelvis, thorax and shoulders are observed quite frequently in children and youth (2-38 %) [17,18], a clinical diagnosis of IS is not communicated until there is of unknown cause, an emergence of axial and lateral deviation of the spine that exceeds  $10^\circ$  [4]. The frontal plane radiograph has historically served as the primary diagnostic clinical tool. The severity of spinal curvature may be measured using the technique often referred to as the angle of Cobb [19]. This angle is the angle between two-end vertebrae that define the limits of a spinal curve [20]. The estimation of the amplitude of vertebral rotation has been performed using a variety of techniques [21,22]. The most common is the approach developed by Perdriolle & Vidal (1985) that utilises the Torsion meter [22]. When placed on a Posterior-Anterior radiograph this meter utilises the outer edges of the vertebra, and the longitudinal axis of the pedicles to measure vertebral rotation [22]. The Risser sign, is an additional measure that may be obtained from a frontal plane radiograph and is an index of maturity rated on a scale of 0-5. This index refers to the amount of ossification of the iliac epiphyses that is closely synchronized with the development of the vertebral growth plates [23]. This process of ossification may take 2-3 years, with completion around 14 years for girls, and 16 years for boys.

The risk of progression of the curvature of the spine is associated with a number of factors. These factors include the severity of the initial curve [1,24], age [24], menarche [1,24], skeletal maturity [1,24,25] and gender of the patient [24,25]. The risk of progression has been found to be greatest in children and youth who have a moderate or severe curvature of the spine and significant potential to grow. Lonstein & Carlson 1984, found that with a spinal curvature between  $20-29^\circ$ , and a Risser sign of 0, 1 or an age of 12 years, the risk of progression is 68% and 61% respectively. Whereas a patient with a Risser sign of 2, 3 or 4, or an age of 15 years, the risk of progression decreased considerably and was estimated to be 1.6% and 4% respectively [1].

Evidence from computational [26] and animal models [8] have supported the hypothesis that asymmetric loading of the spinal elements influences the development of vertebral deformities, and consequently progression of the spinal curve [7]. These models are in agreement with emerging evidence from biomechanical and neurophysiologic measures that suggest dysfunction of the neuromuscular system may be an additional factor and indicator of progression risk in IS. This evidence is drawn from studies that have demonstrated increased asymmetry in paraspinal muscle activity [27,28,29], altered sensory weighting [30], and postural control [31]. Of these studies, only a few have focused on

identifying the predictive ability of neuromuscular measures [27,28,29]. For example, in patients who have IS, the presence of asymmetrical activation of the paraspinal muscles when standing quietly upright has been found to have a 68 % probability of progression, which increases to 80 % when combined with growth velocity [28]. Further work by this group also related paraspinal muscle activity with radiological measures of the spine in progressive and non-progressive IS, revealing an association with increased kyphosis and axial rotation of the spine prior to onset of progression [29]. This body of work has provided initial empirical evidence that associates altered paraspinal muscle activity with the progression of the spinal curvature. Our own studies have revealed that dysfunction in postural control may be evident in children with a spinal curvature as small as 15°, and that asymmetric positioning of the Centre of Mass (COM) in relation to the spine and sacrum may predispose children and youth to progression of their spinal curvature [32]. The findings from this recent work aligns itself with emergent hypothesis that have related neuromuscular dysfunction/dyscontrol, vertebral loading, vertebral deformity and further progression of the curvature of the spine [7]. This conceptual and empirical foundation provides rational for the development of complimentary approaches to the clinical assessment of *Posture* and *Mobility* in a clinical setting.

### **3. Conceptual construct, terms of reference and measurement of Posture and Mobility**

#### **3.1 Conceptual constructs of Posture and Mobility**

The conceptual constructs of *Posture* and *Mobility* are central to the clinical evaluation of a child or youth diagnosed with IS. The former concept relates to the position and orientation of individual body segments (Postural Alignment) and the central nervous system control of these segments for the purpose of stability and orientation (Postural Control) [33]. The latter, is a broader term that introduces an element of movement that is afforded by individual joints, multi-articulate structures such as the spine and thorax, and results in relative motion between segments and of the body in relation to the external environment. The application of anatomical frames of reference, terminology and metrics that quantify these constructs are embodied within modern day clinical practice. This is evidenced by the emergence of observational tools, quantitative measurement devices and medical imaging techniques that serve a role in early screening, diagnosis, monitoring and clinical decisions.

#### **3.2 Postural Alignment and Postural Control**

Fundamental to the conceptual construct of *Posture* are the elements of *Postural Alignment* and *Postural Control*. [33] Although in clinical and research environments these elements are most often evaluated independently of one another, they are inherently interdependent, and not exclusive. *Postural alignment* is most accurately defined as the position and orientation of body segments in relation to each other and the external environment [33]. This alignment is a reflection of the overall organisation of the musculoskeletal system, and is influenced by underlying bone morphology, joint composition and structure, muscle length, strength and size. The central nervous system inherently controls the alignment of the body for the primary purpose of stability and orientation against gravity and to perform movement [33]. This is accomplished through

the integration and interpretation of sensory information, the development of muscle tone to counter the mechanical effects of gravity when sitting and standing, and the generation of context appropriate anticipatory and reactive neuromuscular synergies in response to internal and/or external threats to stability [33]. It is this underlying central contribution to the maintenance of the position and orientation of the body that unifies the concepts of *Postural alignment* and *Postural control*.

### 3.3 Anatomical terms, and frames of reference for the description of Postural Alignment

Fundamental to the description of a child's posture who is living with a spinal deformity is the adoption of consistent anatomical terms of reference. These terms of reference found the communication of clinical observations that guide treatment decisions and assist in the evaluation of clinical outcomes. Our contemporary perspective of pediatric spinal deformities recognizes that scoliosis is a three-dimensional curvature of the spine [4-6] and has evolved to include deformity and spatial disorientation of adjacent skeletal structures such as the pelvis, thorax and shoulder's [14,15,34]. (See Figure 1) The complexity and severity of these deformities have necessitated the adoption of terms and frames of reference that are specific to the field of paediatric spinal deformities.

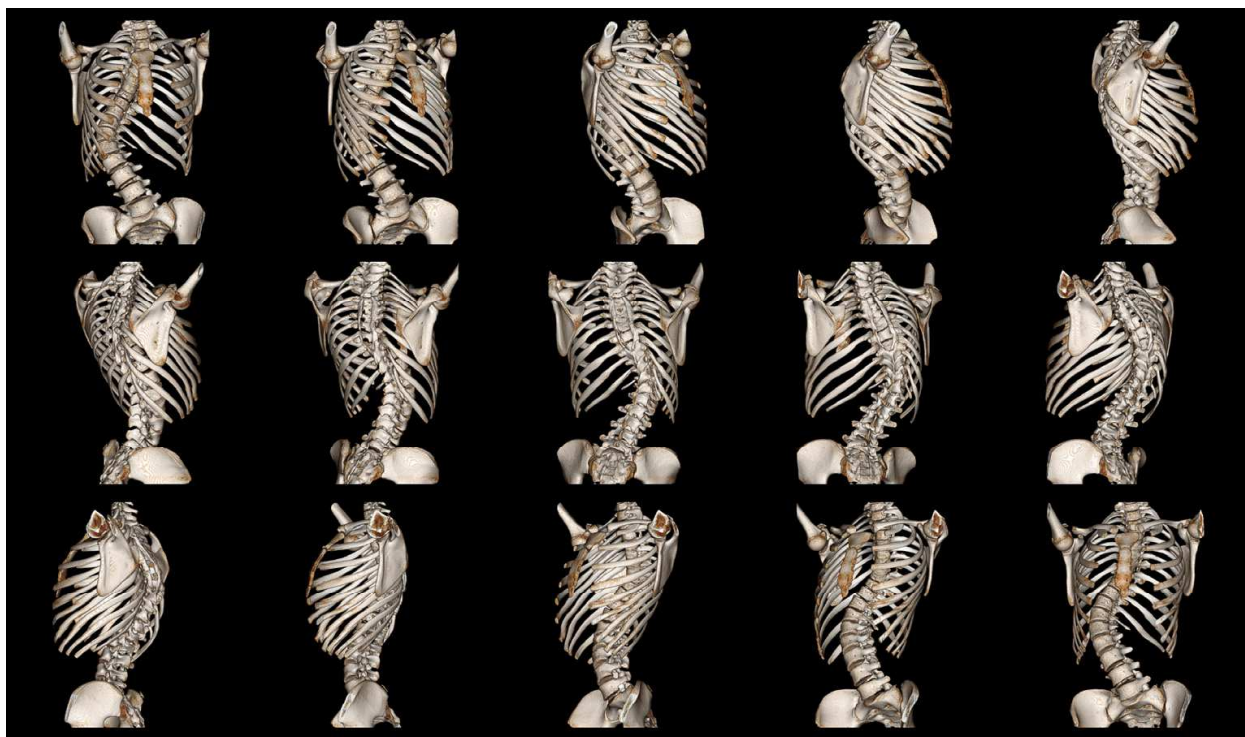


Fig. 1. Three dimensional rendering of scoliosis.

#### 3.3.1 Anatomical terms and frames of reference

The cardinal planes of reference are commonly adopted by clinicians and scientists within the fields of orthopaedics, anatomy, biomechanics and rehabilitation. The three cardinal planes of reference include the Sagittal, Frontal (Coronal) and Transverse (Axial) planes and axis. The Sagittal plane is a vertical plane that passes through the body from front to back,



the Frontal plane is a vertical plane that passes through the body from right to left, and the transverse plane is a horizontal plane that divides the body in an upper and lower section. Each of these planes has an axis which lies perpendicular to this plane. The position, orientation and motion of the body within a cardinal plane, or about an axis may then be described. The terms of flexion, extension, abduction, adduction, rotation, tilt, circumduction, protraction, retraction, elevation, depression, inversion, eversion, are universally accepted descriptors of segment position and motion [35]. In clinical settings, these terms are often used to effectively describe the posture and gait of a wide spectrum of orthopaedic, and neurological conditions.

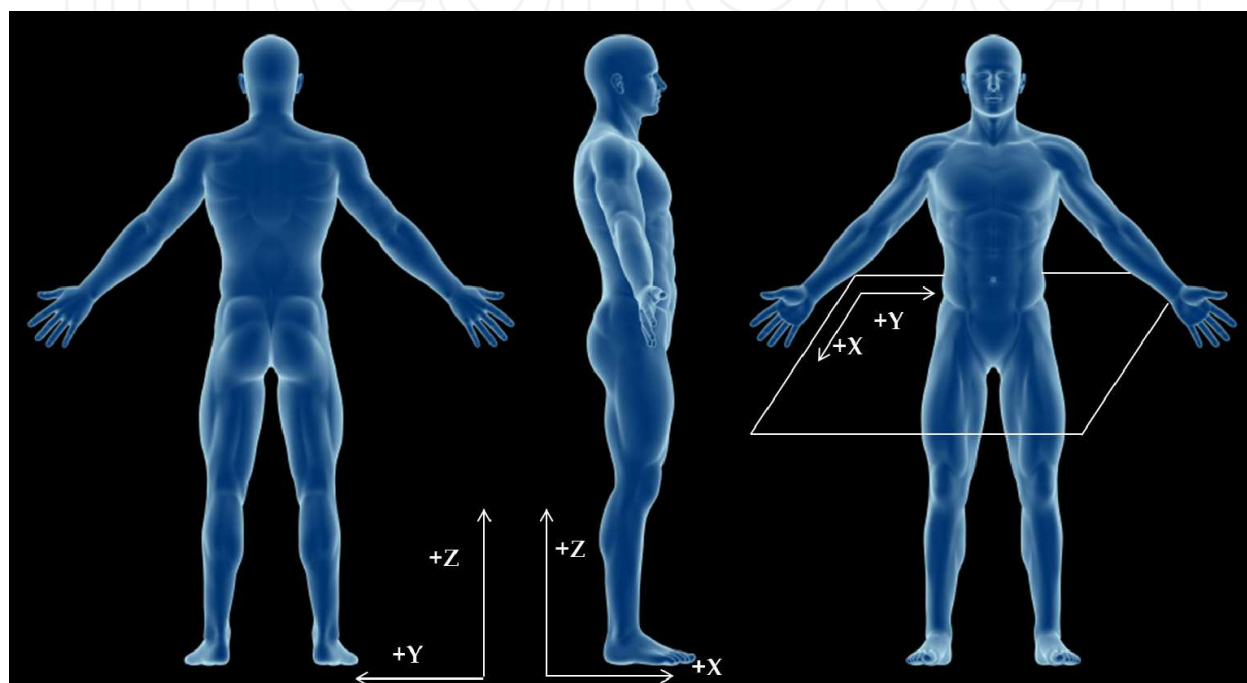


Fig. 2. Anatomical planes of reference, and cartesian co-ordinate system.

### 3.3.2 Cartesian co-ordinate systems

The cartesian co-ordinate system provides the basis to quantify the position and orientation of the pelvis, thorax, scapula and spine. This 3-Dimensional co-ordinate system consists of an origin (0,0,0) and three perpendicular axis (x,y,z) projecting from this origin and defines three planes (x,y; y,z; x,z). (See Figure 2) The position of a point in this co-ordinate system may then be described in relation to these three axis (x,y,z). The location of this co-ordinate system in relation to the body, and individual skeletal structures will provide a frame of reference to describe and quantify posture. A global co-ordinate system is commonly adopted to describe the position and orientation of the body in relation to the external environment. This system is defined by alignment of the cartesian co-ordinate system with the cardinal planes of reference, where the x-axis lies within the sagittal plane and perpendicular to the frontal plane, the y-axis lies within the frontal plane and perpendicular to the sagittal plane, and the z-axis lies within both the frontal/sagittal planes and is aligned with the gravity. The appropriate alignment of this axis system with the cardinal planes of reference, and in particular with gravity is critical. In contrast to a global co-ordinate system, a local co-ordinate system will align the cartesian co-ordinates in relation to individual

skeletal structures. The SRS 3D Terminology work group has proposed that a local reference system may be adopted to describe a) vertebral deformity; b) regional curvatures of the spine; c) the spine. This approach will then provide the capacity to quantify deformity and spatial orientation of the individual vertebra, the spine and the adjacent skeletal structures [20]. The adoption of a cartesian co-ordinate system that is in alignment with the global cardinal planes of reference, and the local frames of reference has served as the basis for a number of tools to quantify the 3 dimensional alignment and spatial orientation of the spine and adjacent skeletal structures.

### **3.3.3 Terms of reference for the clinical description of Idiopathic Scoliosis**

In recognition that a comprehensive description of the complex deformity and disorientation of the spine and adjacent skeletal structures extends beyond the scope of these standard anatomical terms, collective work has assembled detailed terminology to describe spinal deformity [20,36,37]. These work groups have provided terms of reference that describes deformity, alignment and shape of the spine, and the alignment (position/orientation) of individual vertebra and adjacent skeletal structures such as the pelvis, thorax and scapula. Interested readers are further directed to the Scoliosis Research Society documentation related to 3-D Terminology, Biomechanics Documentation, and Revised Glossary of Terms, and in addition to the 6<sup>th</sup> SOSORT consensus paper, and recent review of trunk surface metrics [20,36,-38].

#### **Shape and alignment of the Spine**

With the emergence of modern day diagnostic imaging techniques our understanding of the complexity of the three dimensional curvature of the spine, and the inherent variability observed across children and youth with scoliosis has grown extensively [39]. The development of terms of reference to describe these complex spinal curves has also occurred in parallel.[20,37,38] The Scoliosis Research Society Working group proposed three dimensional terminology to describe scoliosis [20], and has recently been updated by the Working Group on 3D Classification [38]. The terminology proposed by this working group has historically been applied in reference to a bi-planar radiograph (frontal, and lateral) and more recently 3D reconstructions of the spine. Within this context, spine alignment is generally described in relation to the central sacral line, which is defined as a vertical line that traverses the centre of the sacrum [38]. This line of reference provides a reference to identify the most laterally positioned vertebrae, or apical vertebrae. In relation to the apical vertebra, the first vertebra with the greatest tilt of the superior surface towards the concavity of the curve is termed the 'Cephalad end vertebra', and the first vertebra with the inferior surface tilted maximally towards the concavity of the curve is termed the 'Caudad end vertebra'. [20,38] The definition of the apical, cephalada and caudad vertebra define curvature, with the term 'major' commonly referring to the largest curvature, and the term 'minor' refers to the curve with the smallest curvature. Under certain circumstances the terms 'compensatory curve' implies a non-structural minor curve that is located above or below the major curve.[20,38] The location and side of the apical vertebra then provides the basis to define the general class of curvature as either Cervical, Cervical-Thoracic, Thoracic, Thoracolumbar, Lumbar, and Lumbar, Thoracolumbar, Lumbar and Lumbar Sacral (See Table 2).[20,38] This terminology has founded clinical decisions related to the prescription of conservative treatment approaches and surgical intervention, and the evaluation of clinical outcomes.

Scoliosis Type	Location of Apical Vertebra
Cervical	C1 vertebra – C6-C7 Disc
Cervical-Thoracic	C7, T1 vertebra or intervening Disc space
Thoracic	T2 vertebra – T11-T12
Thoracolumbar	T12, L1 vertebra – T12-L1 Disc
Lumbar	L1-L2 disc – L4-L5 Disc
LumboSacral	L5 vertebra or below

Table 2. Scoliosis Research Society classification of scoliosis according to level of apex. [38]

This work group has also defined sagittal alignment of the spine [38]. The overall sagittal spinal balance (or alignment) has traditionally referred to the location of the body of the C7 vertebra to the superior posterior aspect of the sacrum. The spine also has four notable curves that correspond to the cervical (C1-C7), thoracic (T1-T12), lumbar (L1-L5), and sacral regions. The curvature associated with each region is commonly described by the concavity or convexity when viewed in the posterior-anterior direction. In an able bodied adult, the former is referred to as Kyphosis typically observed in the Thoracic and Sacral regions, and the later Lordosis typically observed in the Cervical and Lumbar regions [35,38]. Across children and youth diagnosed with scoliosis, it is recognized that there is considerable variability in the amplitude and direction of the spinal curvature observed in the sagittal plane [38,40,41].

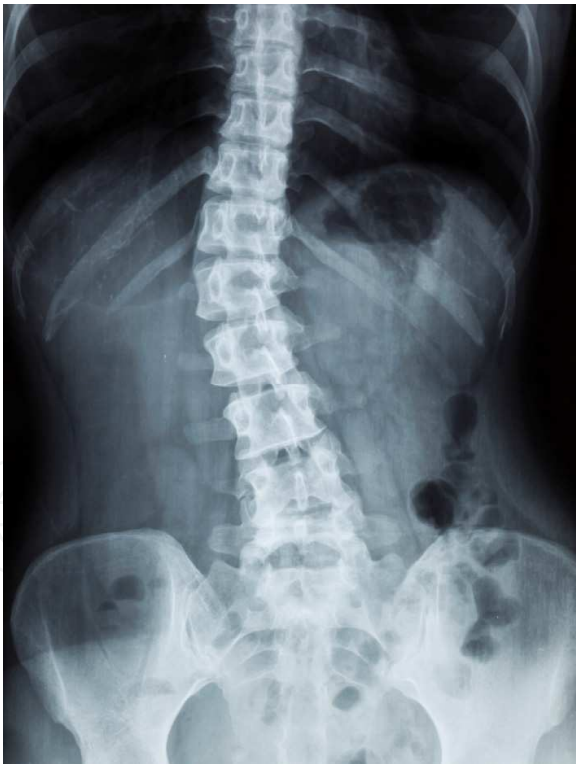

Fig. 3. Frontal plane radiograph of a spine.

**Position and Orientation of Adjacent Skeletal Structures (Pelvis, Thorax, Shoulders)**

The documentation of the position and orientation of the pelvis, thorax and shoulders has often been performed in a clinical setting utilizing observational, quantitative and



radiographic approaches. The position and orientation of these segments have traditionally been referred to in relation to the cardinal planes of reference.

### Pelvis

The terms and measures that have been adopted to describe the position and orientation of the pelvis are quite extensive, and specific to the sacrum, iliac bones and pelvis [34,36,38,42-45]. The anatomical landmarks that provide the point of reference to describe the pelvis include: Anterior-Superior Iliac Spines (ASIS), Posterior-Superior Iliac Spines (PSIS), Superior Lateral Border of the Iliac Crests, and the Sacral Plateau [34,36,38,42-45]. These landmarks have served to measure pelvic position and orientation radiologically [38] and with optoelectronic and digitization techniques [34,42-45]. The premise of this choice of landmarks is founded on the desire to distinguish the spatial disposition of the pelvis from the relative alignment of the right and left iliac bones. Figure 4 provides a perspective of the pelvis from the Frontal, Sagittal, and Transverse planes. The global orientation of the pelvis is generally defined by the angle of a line that is drawn between these landmarks and horizontal [34,42-46]. The angle of the pelvis in the sagittal plane is typically defined by a line between ipsilateral ASIS and PSIS (Figure 4: D3). The rotation of the pelvis in the transverse plane is calculated by a line drawn between the contralateral ASIS, PSIS, and Superior Lateral Border of the Iliac Bones (Figure 4: D4). Adopting the same landmarks, the tilt of the pelvis in the frontal plane is also calculated (Figure 4: D1,D2) [42-46]. These angles provide the basis to define global orientation of the pelvis [42-46], with the difference between angles serving to define the relative orientation between right and left iliac bones [42-43].

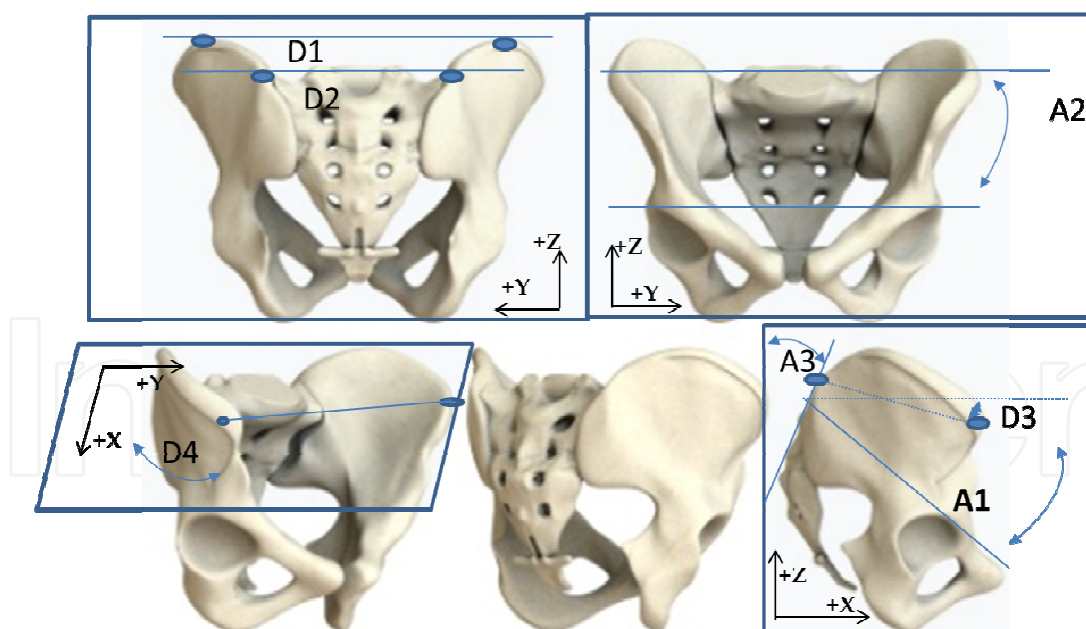


Fig. 4. Frontal, Sagittal and Transverse perspectives of the pelvis.

The Scoliosis Research Society working group, has proposed a standardized list of terms that may describe these angular measures [38]. Specifically, orientation of the sacrum and pelvis in the frontal plane are described as obliquity and orientation in relation to the sagittal plane is referred to as inclination. Pelvic obliquity is suggested by the SRS to be

measured by the angle of a line between the iliac crests in relation to horizontal (Figure 4: D1), and the Sacral obliquity is measured by the angle between a line drawn across the superior border of the sacrum, and the right and left femoral heads (Figure 4: A2) [38]. The posterior surface of the Sacrum serves to define Sacral Inclination in relation to vertical (Figure 4: A3), and pelvic inclination is defined by a line drawn from the superior aspect of the sacrum to the superior aspect of the pubis (Figure 4: A1) [38].

### **Thorax**

The rotation of the thorax has commonly been measured in the transverse plane with the patient in an anteriorly flexed position [12,13]. In this position, the region of the spine with the greatest vertical protrusion, or commonly referred to as prominence is chosen as the location to measure the Angle of Trunk Inclination. The Angle of Trunk Inclination is then measured through the angle defined by the surface of the protruding thorax and the horizontal [12,38].

### **Shoulders and Scapula**

The orientation of the shoulders and scapula have most often been measured through the use of the non-invasive optoelectronic and digitization techniques [34,42-46]. The motivation to measure scapular orientation is founded on the understanding that a rotation of the thoracic cage, will affect scapular orientation due to the positioning of the scapula over the thorax, and the inherent articulation between the scapula, clavicle and sternum [34,42-46]. Within this context, tilt and rotation of the shoulders is defined by a line that is drawn between the right and left scapula and the associated angle in relation to the transverse and frontal planes. The rotation of the scapula has been suggested to include both a measure of the superior rotation (angulation) and inferior rotation (angulation). This is defined by a line that is drawn between the right and left acromions, and/or a line drawn between the inferior border of the right and left scapula and the angulation of these two lines in relation to the transverse (rotation) and frontal planes (tilt). These measures may be expressed in relation to the global reference system, or relative to a pelvis reference system [34,42-46].

## **3.4 Clinical application for terms of reference and metrics**

The anatomical terms, frames of reference and metrics developed by the orthopaedic community has afforded a unique opportunity to characterize the complexity of the 3D deformity of the spinal curvature and evaluate clinical outcomes associated with conservative and surgical management of IS. Although, the extent of application of radiological and non-invasive techniques for these purposes extends beyond the scope of the present chapter, it is notable to briefly discuss the relationships between the underlying skeletal alignment of the spine and the spatial disorientation of the thoracic cage, pelvis and shoulders observed clinically.

Investigation of the clinical utility of the application of metrics to the spatial disorientation of the thoracic cage, pelvis and shoulders has been the focus of numerous studies [12-18,42-47]. Within the context of this work, a significant interest is devoted to quantifying the relationship between surface metrics and the underlying alignment of the spine [12,47]. A weak to strong correlation between back surface metrics has been reported [12,47,58], with evidence of stronger associations through application of advanced analytical techniques

such as neural networks and regression models that are specific to frontal and sagittal spinal alignment [13,54-57]. These observations have founded considerable interest to explore their utility in school screening programs [49-51], and clinically for the purpose of optimizing the number of x-rays [13,54-56]. There is an increased understanding that the limitations that exist with the application of these surface metrics are associated with inherent variability across children that are associated with growth [48], location of the deformity [34] and treatment [52]. Notably, recent work has highlighted a stronger correlation between surface metrics and spinal curvature in older children vs younger children [48]. In addition, significant differences were noted in spatial orientation of the pelvis, and spatial orientation of the shoulders, and shoulder blades when individuals are categorized by the side and location of the apical vertebra [34]. This work revealed that predominant spatial deformity in the frontal plane at the pelvis is greater in curves with an apex in the thoracolumbar region, and conversely in the transverse plane for the shoulders/scapula for the curves with an apex in the thoracic region. This knowledge founds the motivation to expand current models that aim to predict the degree of spinal curvature, and also further explore the clinical utility of surface deformity measures to evaluate the outcomes associated with treatment.

## **4. Emerging and complimentary measures of Posture and Mobility**

### **4.1 What is the motivation to expand current models of Posture and Mobility assessment?**

Historically, the assessment of a child and youth with a spinal deformity has focused on the observation and measurement of skeletal deformity and spatial disorientation of the spine. It is evident, that significant attention has been devoted to the development of imaging techniques, and clinical tools within this regard. It is clear that contemporary models of assessment found the clinical diagnosis and treatment decisions for spinal deformities. With the exception of the Adam's forward bending test [12,13], the upright static standing posture has served as the frame of reference for clinical characterization of spinal deformity. However, there are emerging criticisms that question the relevance of one measure of spinal deformity such as the Cobb angle as one of the primary indicators of surgical outcomes [36]. In part, this criticism is founded on the recognition that the spatial deformity of the spine extends beyond the characterization provided by one summary measure, inconsistencies in surgical decision making [59] and is paralleled by evidence that it does not correlate with perceptions of appearance by parents and patients [60].

Emerging hypothesis related to association between neuromuscular dyscontrol, vertebral deformity, asymmetric vertebral loading, growth, and complimentary empirical evidence has provided a foundation for the expansion of current clinical models of assessment. Our current understanding of the frequency and duration of the actual time that children spend in this position is limited. Furthermore, it is postulated that children and youth spend considerable amounts of time seated either at school or at home. Studies that have investigated the sitting postures of children at school have revealed that children may spend 85 % - 97 % of their time relatively stationary or static, and 28-45 % of the time in forward flexion with only a small proportion of the time dynamically moving their trunk [61-62]. This predisposition to fixed static postures over extended durations may exert unhealthy loads on the passive elements of the spine. These findings are confounded by the

recognition that school furniture design is often mismatched to the anthropometric dimensions of the children, and a change in workstation design ultimately affects muscle activity [63]. The relevance of these studies is appreciated when it is recognized that adolescents with IS adopt different postures in the sitting position when compared to standing [64]. These differences have been noted to favour asymmetric loading of the spine as noted by an increased lateral shift of the thoracic vertebrae in relation to the sacrum [64]. Similarly in adults, sitting postures have been noted to vary from standing and are accompanied by increased loads on the lumbar spine segments [65]. Increased loading of the passive spinal elements has also been observed to occur at smaller angles of flexion during slouched sitting and is attributed to decreased activity of the erector spinae muscles [66].

It is apparent that factors affecting the load distribution on the spine over an extended period of time will affect spinal stability. Common behaviours such as sitting, standing, walking, ascending/descending stairs all vary with respect to the adopted postures and the level of muscle activation that is employed to counter the external accelerations applied on the body. However, there is a limited understanding of the frequency and duration of the asymmetric postures that are assumed on a daily basis, and the nature of the neuromuscular recruitment strategies that are involved. It has been hypothesized that these latter strategies will have the greatest contribution to the loads placed on the spine [7]. It is therefore hypothesized that an augmented understanding of the mechanisms and risk factors associated with the early progression of IS, may be obtained through coupling radiological measures of spinal deformity with measures of neuromuscular function obtained across a range of activities that are representative of the physical demands experienced during everyday life. This body of works brings to light the need to explore new models of assessment that encompass the broader constructs of postural control, and mobility.

#### 4.2 Contemporary perspectives of Postural Control and Idiopathic Scoliosis

The central nervous system regulation of the position and orientation of the body for the purpose of regulating posture and movement is often defined as *Postural Control*. Insights into how the central nervous system controls posture has traditionally focused on the measurement of displacement of the centre of mass (COM) in relation to the base of support. Stability of the body is thus a reflection of how effective the CNS is in maintaining the COM within the base of support under circumstances that destabilize the body.

The COM of the entire body represents a weighted average of COM position of each individual body segment in space, and evidently is affected by the underlying skeletal structure, mass distribution of body segments and the central nervous system strategies that integrate sensory information and regulate muscle tension [67]. It is the tension generated by individual muscles that produce a moment of force (torque) about a joint that is responsible for the stabilization of the body against gravitational loads. Contemporary approaches to understanding how the CNS controls posture have focused on modelling the body in an upright standing position as an inverted pendulum. Fundamental to this model is the recognition that CNS control may be presented by the displacement of the Centre of Pressure (COP). The COP represents the net location of the ground reaction forces located under the base of support (feet), and is a reflection of the net effect of the stabilizing torques generated by the body. Within the concept of the inverted pendulum model, the horizontal acceleration of the COM is strongly correlated with the difference between the COP and



COM (COP-COM) [68]. The application of this model to the study of upright standing balance control has suggested that A/P control of standing is primarily related to the ankle plantar/dorsi flexors, and M/L control is related to the hip abductors/adductors [68-70]. Although this model has informed about fundamental strategies involved in global postural control, there has been limited application of this model to the field of spinal deformities. In particular, relatively few studies have examined how the postural control of children and youth with IS may be compromised, and in particular direct associations with the risk of curve progression.

The overall postural stability of children with IS has been examined through characterization of COP displacement, during quiet standing with the eyes open [71-79] and under altered sensory conditions [72]. Children and youth with IS were found to have a greater displacement of the COP than able bodied children [73,77,78]. However, this is in contrast to other studies that have either found no differences, or decreased sway. Although, the majority of studies examined postural stability in children and youth with a similar amplitude in the spinal curvature, they did not differentiate the type of curve. Gauchard et al., (2001) revealed that overall sway of children and youth with IS was greater in lumbar curvatures, and smallest in double curves [74]. This body of work reveals the complexity of understanding how postural control is affected in children and youth with IS. In part, the current model's of postural control do not differentiate stability of the trunk and spine from overall stability of the body. Traditional measures of standing balance as reflected by the COP under the feet are the net effect of all of the segmental torques generated by the body [67]. Therefore, there is the potential for significant advancements to be made with the enhancement of these models to consider the segmental control of the spine and trunk.

#### 4.3 Emerging approaches for the modelling of the Centre of Mass

Obtaining an accurate estimation of the position and the displacement of the COM has been the focus of numerous studies. These studies have directly measured the position of the COM and moment of inertia in cadavers [80] and on live subjects, through a variety of techniques that includes stereophotogrammetry [81] cross-sectional modelling of body segments [82], and medical imaging techniques [83]. Of these techniques the cadaver studies were principally performed on adults and the remainder on adult subjects with the exception of the cross-sectional elliptical approach employed by Jensen (1989), who studied children and adolescents [84]. The research by Jensen (1989) revealed that during growth and development there is a decrease in the COM proportion of the head and an increase in the COM proportion of the arms and legs. The positions of the COM relative to the proximal joint centres also shifted proximally in the upper legs forearms and arms [84].

Techniques have been proposed to estimate the COM and overcome the difficulties of anatomical landmark detection, and the estimation of anthropometric variables (segment COM and moment of inertia). These techniques involve estimating the position of the COM based on measurements obtained from a force plate. The techniques generally include 1) a filtering technique of the COP [85], 2) Newtonian mechanics based equations [86], 3) filtering technique combined with a mathematical relationship between the COP and COM [87], 4) double integration of the horizontal ground reaction forces [88,89]. These techniques have been developed and initially applied to estimate the displacement of the COM in adult subjects in a quiet standing position [85,87,89]. Recently in a simulation study, Lenzi et al.,



(2003) compared the technique of Caron et al., (1997), Zatsiorsky & King (1998), and Shimba (1984), with a link segment model based on anthropometric parameters obtained from Winter (1990) [67,87,88-91]. Through changing the body segment parameters and evaluating each model in simulated quiet standing, ankle sway, hip sway and the sit to stand task the sensitivity of each technique was tested. The technique by Zatsiorsky & King (1998) was found to be unaffected by changes in body segment parameters, unlike the link segment model which was most sensitive to changes in body segment parameters across conditions [90]. This independence to anthropometric parameters provides a possibility of overcoming the limited source of anthropometric data available for IS patients and healthy adolescents. Recent work that has applied this approach to quantify the position of the COM in children and youth with scoliosis, has revealed notable and significant differences between the two approaches. Importantly, an anthropometric model will overestimate the anterior position of the COM in relation to the Sacrum up to 16 mm, and 3.8 mm in the medial-lateral direction. Similarly, the variability of the COM over time was found to be greater in scoliosis patients than non-scoliosis [32]. The observed differences between models may in part be contributed to the variability in the spatial deformation of the pelvis, trunk and spine often observed in children in youth with scoliosis. It is hypothesized that traditional anthropometric models are not sensitive to these deformities, and thus lack precision in accurately tracking the position and displacement of the COM when standing. This issue is also exhibited when dynamic activities are examined such as lateral trunk bending. Figure 5 presents the COM estimated from a forceplate (COMfp) [32,88] and that estimated from a standard link segment kinematic model [32]. Initial comparison of the COM trajectory using both techniques reveals similar spatial and temporal characteristics. However, importantly, the kinematic model over-estimates COM trajectory at the end range of a movement (ie., full anterior-flexion, full lateral flexion).

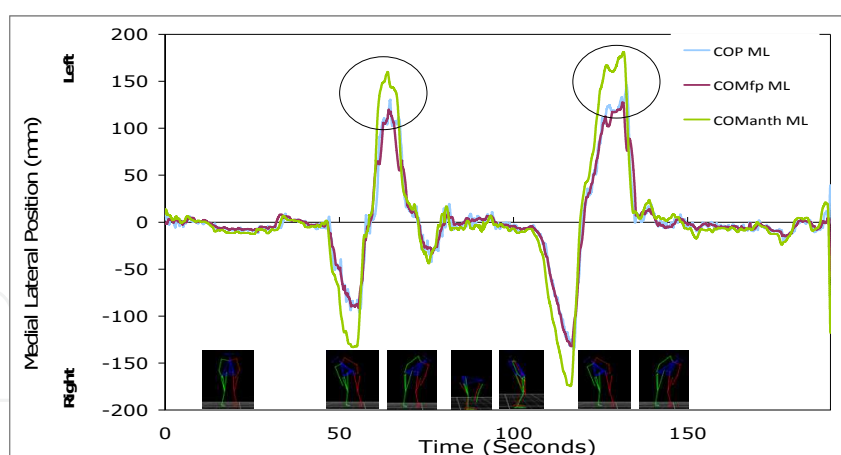


Fig. 5. Medial-Lateral position of the Centre of Pressure, (COP), Centre of Mass, (COM) estimated from a traditional 3D motion capture system and anthropometric model (COMAnth) [32], a forceplate based approach (COMfp)[32,88].

#### 4.4 Emergent technologies that may afford new insight into Posture and Mobility

Recent advancements in portable technology have increased the feasibility of obtaining neuromuscular and quantitative measurements of movement while an individual is engaged in activities of everyday life. The potential of instruments such as an

accelerometer, or a gyroscope to provide indications of the type of activity that is performed has received increasing attention [92-94]. This body of work has focused on the application and evaluation of machine learning techniques [92,93], discrete wavelet transforms [93], and binary decision trees that categorize activities according to rest or activity (falls, walking, transition, postural orientation) [95]. These classification techniques provide the foundation to identify activity patterns, and differentiate both the frequency and duration of each activity throughout the day. Additional research within this area has focused on characterizing in greater detail the nature of the activities, with particular emphasis placed on the extraction of features related to the quality and quantity of walking [96], segmental accelerations [97,98], transitions in positioning and orientation [99], and trunk posture [100-106]. Within this context, there has been a limited focus of the application of this technology for the measurement of trunk postures in children and youth with Scoliosis. Initial work by Bazzarelli et al., 2002 [105], and Lou et al., 2002 demonstrated the potential of an accelerometer based, trunk mounted sensor to measure trunk posture, and provide postural feedback during the performance of daily activities [105,106]. Recent work by Wong & Wong 2008, focused on a three accelerometer system that positioned the sensors on the pelvis (Sacrum), mid-thorax (T12) and high thorax (T1/T2). In comparison to a standard motion capture system, this approach demonstrated a strong correlation, and root mean square differences of less than 3.1° and 2.1° in the sagittal and coronal planes respectively [103]. Further application of this type of device provided an opportunity to quantify the frequency distribution of the range of postures that are assumed on a daily basis [103]. These two studies have clearly demonstrated the potential utility of a trunk mounted sensor network to measure posture during activities of daily life, and the alteration of the postures assumed with the provision of daily feedback [103-106]. It is clear from this body of work that the premise of a body mounted sensor network that integrates tri-axial accelerometers and gyroscopes has the potential to provide information related to the type, frequency and duration of daily activities, as well as specific information related to the segmental body postures and movement. Notably, there is limited work that has focused on the further development and application of this technology to the study of spinal deformities, and the exploration of the clinical potential to inform about treatment outcomes.

## 5. Conclusion

Contemporary perspectives acknowledge that scoliosis is a complex musculoskeletal condition that is characterized by spatial disorientation of the spine and thoracic cage. The emergence of novel three dimensional imaging, optoelectronic, and ambulatory monitoring tools provides clinicians and researchers an unprecedented opportunity to accurately characterize the spatial deformation of the spine and thorax, skeletal deformity, and monitor segment postural alignment in the clinic, at home and in the community. With further development and application, these tools may provide the foundation for the development of new clinical models of assessment and evaluation of outcomes related to treatment.

## 6. References

- [1] Lonstein JE, & Carlson, JM (1984) The prediction of curve progression in untreated idiopathic scoliosis during growth. *J Bone Joint Surg Am.* 66:1061-71.

- [2] Little DG, Song KM, Katz D, & Herring JA (2000) Relationship of peak height velocity to other maturity indicators in idiopathic scoliosis in girls. *J Bone Joint Surg Am.* 82:685-93.
- [3] Risser JC (1958) The Iliac apophysis; an invaluable sign in the management of scoliosis. *Clin Orthop Relat Res.* 4:111-9.
- [4] Kane WJ (1977) Scoliosis prevalence: a call for a statement of terms. *Clin Orthop Relat Res.* 126:43-6.
- [5] Stokes IA, Bigalow LC, Moreland MS (1987) Three-dimensional spinal curvature in idiopathic scoliosis. *J Orthop Res.* 5(1):102-13.
- [6] Stokes IA, Dansereau J, Moreland MS (1989) Rib cage asymmetry in idiopathic scoliosis. *J Orthop Res.* 7(4):599-606.
- [7] Stokes IA, Burwell RG, Dangerfield PH (2006) Biomechanical spinal growth modulation and progressive adolescent scoliosis - a test of the 'vicious cycle' pathogenetic hypothesis: Summary of an electronic focus group debate of the IBSE. *Scoliosis.* 1:16.
- [8] Stokes IA, Spence H, Aronsson DD, Kilmer N (1996) Mechanical modulation of vertebral body growth. Implications for scoliosis progression. *Spine.* 21(10):1162-7.
- [9] Dansereau J, Stokes IA. (1988) Measurements of the three-dimensional shape of the rib cage. *J Biomech.* 21(11):893-901.
- [10] Ilharreborde B, Steffen JS, Nectoux E, Vital JM, Mazda K, Skalli W, Obeid I (2011) Angle measurement reproducibility using EOS three-dimensional reconstructions in adolescent idiopathic scoliosis treated by posterior instrumentation. *Spine.* 36(20):E1306-13.
- [11] Villemure I, Aubin CE, Grimard G, Dansereau J, Labelle H (2002) Evolution of 3D deformities in adolescents with progressive idiopathic scoliosis. *Stud Health Technol Inform.* 91:54-8.
- [12] Cote P, Kreitz BG, Cassidy JD, Dzus AK, Martel J (1998) A study of the diagnostic accuracy and reliability of the Scoliometer and Adam's forward bend test. *Spine.* 23, 796-802.
- [13] Griffet J, Leroux MA, Badeaux J, Coillard C, Zabjek KF, Rivard CH (2000) Relationship between gibbosity and Cobb angle during treatment of idiopathic scoliosis with the SpineCor brace. *Eur Spine J.* 9:516-22.
- [14] Goldberg CJ, Kaliszer M, Moore DP, Fogarty EE, Dowling FE (2001) Surface topography, Cobb angles, and cosmetic change in scoliosis. *Spine.* 26:E55-63.
- [15] Inami K, Suzuki N, Ono T, Yamashita Y, Kohno K, Morisue H (1999) Analysis of Posterior Trunk Symmetry Index (POTSI) in Scoliosis. In: IAF. Stokes (Ed), Part 2. *Research into Spinal Deformities.* 2:85-88.
- [16] Jaremko JL, Poncet P, Ronsky J, Harder J, Dansereau J, Labelle H, Zernicke RF (2002). Indices of torso asymmetry related to spinal deformity in scoliosis. *Clin Biomech.* 17:559-68.
- [17] Vercauteren M, Van Beneden M, Verplaetse R, Croene P, Uyttendaele D, Verdonk R (1982) Trunk asymmetries in a Belgian school population. *Spine.* 7:555-62.
- [18] Nissinen M, Heliovaara M, Tallroth K, Poussa M (1989) Trunk asymmetry and scoliosis. Anthropometric measurements in prepuberal school children. *Acta Paediatrica Scandinavica*, 78:747-53.
- [19] Cobb JR (1948) Outline for the study of scoliosis. *American Academy of Orthopedic Surgeons.* 7:261-75.

- [20] Stokes IAF (1994) Scoliosis Research Society Working Group on 3-d terminology of spinal deformity: Three-dimensional terminology of spinal deformity. *Spine*. 19:236-248.
- [21] Ho EK, Upadhyay SS, Chan FL, Hsu LC, Leong JC (1993) New methods of measuring vertebral rotation from computed tomographic scans. An intraobserver and interobserver study on girls with scoliosis. *Spine*. 18:1173-7.
- [22] Perdriolle R, Vidal J (1985) Thoracic idiopathic scoliosis curve evolution and prognosis. *Spine*. 10:785-91.
- [23] Risser JC (1958) The Iliac apophysis; an invaluable sign in the management of scoliosis. *Clin Orthop Relat Res*. 4:111-9.
- [24] Bunnell WP (1986) The natural history of idiopathic scoliosis before skeletal maturity. *Spine*. 11:773-6.
- [25] Peterson LE, Nachemson AL (1995) Prediction of progression of the curve in girls who have adolescent idiopathic scoliosis of moderate severity. Logistic regression analysis based on data from The Brace Study of the Scoliosis Research Society. *J Bone Joint Surg AM*,77:823-7.
- [26] Stokes I, Gardner-Morse M (2002) The role of muscles and effects of load on growth. *Stud Health Technol Inform*. 91:314-7.
- [27] Cheung J, Halbertsma JP, Veldhuizen AG, Sluiter WJ, Maurits NM, Cool JC, van Horn JR (2005) A preliminary study on electromyographic analysis of the paraspinal musculature in idiopathic scoliosis. *Eur Spine J*. 14(2):130-7.
- [28] Cheung J, Veldhuizen AG, Halbertsma JP, Maurits NM, Sluiter WJ, Cool JC, Van Horn JR (2004) The relation between electromyography and growth velocity of the spine in the evaluation of curve progression in idiopathic scoliosis. *Spine*. 29(9):1011-6.
- [29] Cheung J, Veldhuizen AG, Halbertsma JP, Sluiter WJ, Van Horn JR (2006) Geometric and electromyographic assessments in the evaluation of curve progression in idiopathic scoliosis. *Spine*. 31(3):322-9.
- [30] Simoneau M, Mercier P, Blouin J, Allard P, Teasdale N (2006) Altered sensory-weighting mechanisms is observed in adolescents with idiopathic scoliosis. *BMC Neurosci*. 7:68.
- [31] Nault ML, Allard P, Hinse S, Le Blanc R, Caron O, Labelle H, Sadeghi H (2002) Relations between standing stability and body posture parameters in adolescent idiopathic scoliosis. *Spine*. 27(17):1911-7.
- [32] Zabjek KF, Coillard C, Rivard CH, Prince F (2008) Estimation of the centre of mass for the study of postural control in Idiopathic Scoliosis patients: a comparison of two techniques. *Eur Spine J*. 17(3):355-60.
- [33] Shumway-Cook A, Wollacott MH (2000). *Motor Control: Theory and Practical Applications*. Toronto: Lippincott, Williams & Wilkins.
- [34] Zabjek KF, Leroux MA, Coillard C, Prince F, Rivard CH (2008) Postural characteristics of adolescents with idiopathic scoliosis. *J Pediatr Orthop*. 28(2):218-24.
- [35] Moore KL. (1985) *Clinically Oriented Anatomy* (2nd Edition). Baltimore, Williams & Wilkins.
- [36] Kotwicki T, Negrini S, Grivas TB, Rigo M, Maruyama T, Durmala J, Zaina F (2009) Members of the international Society on Scoliosis Orthopaedic and Rehabilitation Treatment (SOSORT). *Scoliosis*. 4:26.
- [37] Grivas TB, de Mauroy JC, Negrini S, Kotwicki T, Zaina F, Wynne JH, Stokes IA, Knott P, Pizzetti P, Rigo M, Villagrana M, Weiss HR, Maruyama T (2010) SOSORT




- members. Terminology - glossary including acronyms and quotations in use for the conservative spinal deformities treatment: 8th SOSORT consensus paper. *Scoliosis*. 2;5:23.
- [38] Lenke L, & Terminology Committee (2000). Research Society Terminology Committee and Working Group on Spinal Classification Revised Glossary of Terms. [http://www.srs.org/professionals/glossary/SRS\\_revised\\_glossary\\_of\\_terms.htm](http://www.srs.org/professionals/glossary/SRS_revised_glossary_of_terms.htm)
- [39] Carpineta L, Labelle H (2003) Evidence of three-dimensional variability in scoliotic curves. *Clin Orthop Relat Res*. (412):139-48.
- [40] Sangole AP, Aubin CE, Labelle H, Stokes IA, Lenke LG, Jackson R, Newton P (2009) Three-dimensional classification of thoracic scoliotic curves. *Spine*. 34(1):91-9.
- [41] Duong L, Mac-Thiong JM, Cheriet F, Labelle H (2009) Three-dimensional subclassification of Lenke type 1 scoliotic curves. *J Spinal Disord Tech*. 22(2):135-43.
- [42] Zabjek KF, Leroux MA, Coillard C, Martinez X, Griffet J, Simard G, Rivard CH (2001) Acute postural adaptations induced by a shoe lift in idiopathic scoliosis patients. *Eur Spine J*. 10(2):107-13.
- [43] Beaudoin L, Zabjek KF, Leroux MA, Coillard C, Rivard CH (1999) Acute systematic and variable postural adaptations induced by an orthopaedic shoe lift in control subjects. *Eur Spine J*. 8(1):40-5.
- [44] De la Huerta F, Leroux MA, Zabjek KF, Coillard C, Rivard CH (1998) [Stereovideographic evaluation of the postural geometry of healthy and scoliotic patients]. *Ann Chir*. 52(8):776-83.
- [45] Nguyen VH, Leroux MA, Badeaux J, Zabjek K, Coillard C, Rivard CH (1998) Classification of left thoracolumbar scoliosis according to its radiologic morphology and its postural geometry]. *Ann Chir*. 52(8):752-60.
- [46] Zabjek KF, Simard G, Leroux MA, Coillard C, Rivard CH (1999) Comparison of the reliability of two 3D acquisition systems used for the study of anthropometric and postural parameters]. *Ann Chir*. 53(8):751-60.
- [47] Stokes IA, Armstrong JG, Moreland MS (1988) Spinal deformity and back surface asymmetry in idiopathic scoliosis. *J. Orthop. Res*. 6, 129-37.
- [48] Grivas TB, Vasiliadis ES, Mihas C, Savvidou O (2007) The effect of growth on the correlation between the spinal and rib cage deformity: implications on idiopathic scoliosis pathogenesis. *Scoliosis*. 2:11.
- [49] Grivas TB, Vasiliadis E, Savvidou OD, Triantafyllopoulos G (2008) What a school screening program could contribute in clinical research of idiopathic scoliosis aetiology. *Disabil Rehabil*. 30(10):752-62.
- [50] Grivas TB, Wade MH, Negrini S, O'Brien JP, Maruyama T, Hawes MC, Rigo M, Weiss HR, Kotwicki T, Vasiliadis ES, Sulam LN, Neuhaus T (2007) SOSORT consensus paper: school screening for scoliosis. Where are we today? *Scoliosis*. 26;2:17
- [51] Grivas TB, Koukos K, Koukou UI, Mazioutou C, Polyzois BD (2002) The incidence of idiopathic scoliosis in Greece--analysis of domestic school screening programs. *Stud Health Technol Inform* 91:71-5.
- [52] Kotwicki T, Kinel E, Stryla W, Szulc A (2007) Discrepancy in clinical versus radiological parameters describing deformity due to brace treatment for moderate idiopathic scoliosis. *Scoliosis* 2:18.
- [53] Krawczyński A, Kotwicki T, Szulc A, Samborski W (2006) Clinical and radiological assessment of vertebral rotation in idiopathic scoliosis. *Ortop Traumatol Rehabil* 8(6):602-7.



- [54] Leroux MA, Zabjek K, Simard G, Coillard C, Rivard CH (2002) Estimated kyphosis and lordosis changes at follow-up in patients with idiopathic scoliosis. *J Pediatr Orthop.* 22(1):73-9.
- [55] Leroux MA, Zabjek K, Simard G, Badeaux J, Coillard C, Rivard CH (2000) A noninvasive anthropometric technique for measuring kyphosis and lordosis: an application for idiopathic scoliosis. *Spine.* 25(13):1689-94.
- [56] Jaremko JL, Poncet P, Ronsky J, Harder J, Dansereau J, Labelle H, Zernicke RF (2002) Genetic algorithm-neural network estimation of cobb angle from torso asymmetry in scoliosis. *J Biomech Eng.* 124(5):496-503.
- [57] Jaremko J, Delorme S, Dansereau J, Labelle H, Ronsky J, Poncet P, Harder J, Dewar R, Zernicke RF (2000) Use of Neural Networks to Correlate Spine and Rib Deformity in Scoliosis. *Comput Methods Biomech Biomed Engin.* 3(3):203-213.
- [58] Pearsall DJ, Reid JG, Hedden DM (1992) Comparison of three noninvasive methods for measuring scoliosis. *Physical Therapy.* 72:648-57.
- [59] Donaldson S, Stephens D, Howard A, Alman B, Narayanan U, Wright JG (2007) Surgical decision making in adolescent idiopathic scoliosis. *Spine.* 32(14):1526-32.
- [60] Smith PL, Donaldson S, Hedden D, Alman B, Howard A, Stephens D, Wright JG (2006) Parents' and patients' perceptions of postoperative appearance in adolescent idiopathic scoliosis. *Spine.* 2006 31(20):2367-74.
- [61] Cardon G, De Clercq D, De Bourdeaudhuij I, Breithecker D (2004) Sitting habits in elementary schoolchildren: a traditional versus a "Moving school". *Patient Educ Couns.* 54(2):133-42.
- [62] Geldhof E, Cardon G, De Bourdeaudhuij I, De Clercq D (2006) Back posture education in elementary schoolchildren: a 2-year follow-up study. *Eur Spine J.* 16(6):841-50.
- [63] Parcels C, Stommel M, Hubbard RP (1999) Mismatch of classroom furniture and student body dimensions: empirical findings and health implications *J Adolesc Health.* 24(4):265-73.
- [64] Gram MC, Hasan Z (1999) The spinal curve in standing and sitting postures in children with idiopathic scoliosis. *Spine.* 24(2):169-77.
- [65] Callaghan JP, McGill SM (2001) Low back joint loading and kinematics during standing and unsupported sitting. *Ergonomics.* 44(3):280-94.
- [66] Callaghan JP, Dunk NM (2002) Examination of the flexion relaxation phenomenon in erector spinae muscles during short duration slumped sitting. *Clin Biomech.* 17(5):353-60.
- [67] Winter DA (1990) *Biomechanics and motor control of human movement.* 2nd edition. Toronto: Wiley-Interscience Publication.
- [68] Winter DA, Patla AE, Ishac M, Gage WH (2003) Motor mechanisms of balance during quiet standing. *J Electromyogr Kinesiol.* 13(1):49-56.
- [69] Winter DA, Prince F, Stergio P, Powell C (1993) Medial-lateral and anterior-posterior motor responses associated with centre of pressure changes in quiet standing. *Neuroscience Research Communications,* 12:141-148.
- [70] Winter DA, Prince F, Frank JS, Powell C, Zabjek KF (1996) Unified theory regarding A/P and M/L balance in quiet stance. *J Neurophysiol* 75:2334-43.
- [71] Adler N, Bleck EE, Rinsky LA, Young W (1986) Balance reactions and eye-hand coordination in idiopathic scoliosis. *J Orthopaedic Res.* 4:102-7.
- [72] Byl NN, Gray JM (1993) Complex balance reactions in different sensory conditions: adolescents with and without idiopathic scoliosis. *J Orthopaedic R.* 11:215-27.

- [73] Chen PQ, Wang JL, Tsuang YH, Liao TL, Huang PI, Hang YS (1998). The postural stability control and gait pattern of idiopathic scoliosis adolescents. *Clin Biomech*, 13:S52-S58.
- [74] Gauchard GC, Lascombes P, Kuhnast M, Perrin PP (2001) Influence of different types of progressive idiopathic scoliosis on static and dynamic postural control. *Spine*. 26:1052-8.
- [75] Gregoric M, Pecak F, Trontelj JV, Dimitrijevic MR (1981) Postural control in scoliosis. A statokinesimetric study in patients with scoliosis due to neuromuscular disorders and in patients with idiopathic scoliosis. *Acta Orthop Scand*. 52:59-63.
- [76] Lidstrom J, Friberg S, Lindstrom L, Sahlstrand T (1988) Postural control in siblings to scoliosis patients and scoliosis patients. *Spine*. 13:1070-4.
- [77] Nault ML, Allard P, Hinse S, Le Blanc R, Caron O, Labelle H, Sadeghi H (2002) Relations between standing stability and body posture parameters in adolescent idiopathic scoliosis. *Spine*. 27:1911-7.
- [78] Sahlstrand T, Lidstrom J (1980) Equilibrium factors as predictors of the prognosis in adolescent idiopathic scoliosis. *Clin Orthop Relat Res*.152:232-6.
- [79] Sahlstrand T, Ortengren R, Nachemson A (1978) Postural equilibrium in adolescent idiopathic scoliosis. *Acta Orthop Scand*. 49:354-65.
- [80] Dempster WT, Gaughran GRL (1967) Properties of body segments based on size and weight. *Am J Anat*. 120:33-54.
- [81] Zatsiorsky V, Seluyanov V (1983) The mass and Inertia characteristics of the main segments of the human body. In: Matsui H, Kobayashi K (Eds.), *International Series on Biomechanics, Volume 4B. Proceedings of the Eight International Congress of Biomechanics* (pp. 1152-1159). Champaign, Illinois: Human Kinetics Publishers.
- [82] Jensen RK (1986) Body segment mass, radius and radius of gyration proportions of children. *J Biomech*. 19:359-368.
- [83] Pearsall DJ, Reid JG, Livingston LA (1996) Segmental inertial parameters of the human trunk as determined from computed tomography. *Ann Biomed Eng*. 24:198-210.
- [84] Jensen RK (1989) Changes in segment inertia proportions between 4 and 20 years. *J Biomech*. 22:529-536.
- [85] Benda BJ, Riley PO, Krebs DE (1994) Biomechanical relationship between the center of gravity and center of pressure during standing. *IEEE Trans Rehabil Eng*. 2:3-10.
- [86] Morasso PG, Spada G, Capra R (1999) Computing the COM from the COP in postural sway movements. *Hum Mov Sci* 18:759-767.
- [87] Caron O, Faure B, Breniere Y (1997) Estimating the center of gravity of the body on the basis of the center of pressure in standing posture. *J Biomech* 30:1169-71.
- [88] Zatsiorsky VM, King DL (1998) An algorithm for determining gravity line location from posturographic recordings. *J Biomech*. 31:161-4.
- [89] King DL, Zatsiorsky VM (1997) Extracting gravity line displacement from stabilographic recordings. *Gait Posture*. 6:27-38.
- [90] Lenzi D, Cappello A, Chiari L (2003). Influence of body segment parameters and modeling assumptions on the estimate of center of mass trajectory. *J Biomech*. 36:1335-41.
- [91] Shimba T (1984) An estimation of center of gravity from force platform data. *J Biomech*. 17:53:60.

- [92] Allen FR, Ambikairajah E, Lovell NH, Celler BG (2006) Classification of a known sequence of motions and postures from accelerometry data using adapted Gaussian mixture models. *Physiol Meas.* 27:935-51.
- [93] Mannini A, Sabatini AM (2011) Accelerometry-based classification of human activities using Markov modeling. *Comput Intell Neurosci.* 2011:647858.
- [94] Aloqlah M, Lahiji RR, Loparo KA, Mehregany M (2010) A headband for classifying human postures. *Conf Proc IEEE Eng Med Biol Soc.* 2010:382-5.
- [95] Mathie MJ, Celler BG, Lovell NH, Coster AC (2004) Classification of basic daily movements using a triaxial accelerometer. *Med Biol Eng Comput.* 42(5):679-87.
- [96] Prajapati SK, Gage WH, Brooks D, Black SE, McIlroy WE (2011) A novel approach to ambulatory monitoring: investigation into the quantity and control of everyday walking in patients with subacute stroke. *Neurorehabil Neural Repair.* 25(1):6-14.
- [97] Zijlstra W, Hof AL (2003) Assessment of spatio-temporal gait parameters from trunk accelerations during human walking. *Gait Posture.* 18:1-10.
- [98] Murakami N, Okada S, Nakamura T, Saito N (2011) Analysis of pelvic movement in the elderly during walking using a posture monitoring system equipped with a triaxial accelerometer and a gyroscope. *J Biomech.* 44(9):1788-92. Epub 2011 May 4.
- [99] Bidargaddi N, Klingbeil L, Sarela A, Boyle J, Cheung V, Yelland C, Karunanithi M, Gray L (2007) Wavelet based approach for posture transition estimation using a waist worn accelerometer. *Conf Proc IEEE Eng Med Biol Soc.* 2007:1884-7.
- [100] Oliver M, Schofield GM, Badland HM, Shepherd J (2010) Utility of accelerometer thresholds for classifying sitting in office workers. *Prev Med.* 51(5):357-60.
- [101] Ishigaki N, Kimura T, Usui Y, Aoki K, Narita N, Shimizu M, Hara K, Ogihara N, Nakamura K, Kato H, Ohira M, Yokokawa Y, Miyoshi K (2011) Analysis of pelvic movement in the elderly during walking using a posture monitoring system equipped with a triaxial accelerometer and a gyroscope. *J Biomech.* 44(9):1788-92.
- [102] McDonald RL, Wilson GN, Molloy A, Franck LS (2011) Feasibility of three electronic instruments in studying the benefits of adaptive seating. *Disabil Rehabil Assist Technol.* 6(6):483-90.
- [103] Wong WY, Wong MS (2008) Trunk posture monitoring with inertial sensors. *Eur Spine J.* 17(5):743-53.
- [104] Wong WY, Wong MS (2008) Detecting spinal posture change in sitting positions with tri-axial accelerometers. *Gait Posture.* 27(1):168-71.
- [105] Bazzarelli M, Durdle N, Lou E, Raso J, Hill D (2002) A wearable networked embedded system for the treatment of scoliosis. *Stud Health Technol Inform.* 91:383-6.
- [106] Lou E, Raso J, Hill D, Durdle N, Moreau M (2002) Spine-Straight device for the treatment of kyphosis. *Stud Health Technol Inform.* 91:401-4.



## **Recent Advances in Scoliosis**

Edited by Dr Theodoros Grivas

ISBN 978-953-51-0595-4

Hard cover, 344 pages

**Publisher** InTech

**Published online** 09, May, 2012

**Published in print edition** May, 2012

This book contains information on recent advances in aetiology and pathogenesis of idiopathic scoliosis, for the assessment of this condition before treatment and during the follow-up, making a note of emerging technology and analytical techniques like virtual anatomy by 3-D MRI/CT, quantitative MRI and Moire Topography. Some new trends in conservative treatment and the long term outcome and complications of surgical treatment are described. Issues like health related quality of life, psychological aspects of scoliosis treatment and the very important "patient's perspective" are also discussed. Finally two chapters tapping the untreated early onset scoliosis and the congenital kyphoscoliosis due to hemivertebra are included. It must be emphasized that knowledgeable authors with their contributions share their experience and enthusiasm with peers interested in scoliosis.

### **How to reference**

In order to correctly reference this scholarly work, feel free to copy and paste the following:

Karl F. Zabjek and Reinhard Zeller (2012). Emerging Technology and Analytical Techniques for the Clinical Assessment of Scoliosis, Recent Advances in Scoliosis, Dr Theodoros Grivas (Ed.), ISBN: 978-953-51-0595-4, InTech, Available from: <http://www.intechopen.com/books/recent-advances-in-scoliosis/emerging-technology-and-analytical-techniques-for-the-clinical-assessment-of-scoliosis>

**INTECH**  
open science | open minds

### **InTech Europe**

University Campus STeP Ri  
Slavka Krautzeka 83/A  
51000 Rijeka, Croatia  
Phone: +385 (51) 770 447  
Fax: +385 (51) 686 166  
[www.intechopen.com](http://www.intechopen.com)

### **InTech China**

Unit 405, Office Block, Hotel Equatorial Shanghai  
No.65, Yan An Road (West), Shanghai, 200040, China  
中国上海市延安西路65号上海国际贵都大饭店办公楼405单元  
Phone: +86-21-62489820  
Fax: +86-21-62489821

© 2012 The Author(s). Licensee IntechOpen. This is an open access article distributed under the terms of the [Creative Commons Attribution 3.0 License](https://creativecommons.org/licenses/by/3.0/), which permits unrestricted use, distribution, and reproduction in any medium, provided the original work is properly cited.

IntechOpen

IntechOpen