

We are IntechOpen, the world's leading publisher of Open Access books Built by scientists, for scientists

6,900

Open access books available

185,000

International authors and editors

200M

Downloads

Our authors are among the

154

Countries delivered to

TOP 1%

most cited scientists

12.2%

Contributors from top 500 universities



WEB OF SCIENCE™

Selection of our books indexed in the Book Citation Index
in Web of Science™ Core Collection (BKCI)

Interested in publishing with us?
Contact book.department@intechopen.com

Numbers displayed above are based on latest data collected.
For more information visit www.intechopen.com



Three-Dimensional Assessment of the Scoliosis

Jean Legaye
University of Louvain, Mont-Godinne
Belgium

1. Introduction

Scoliosis is a twisting deformation of the spine, including all the related anatomical structures (bones, muscles, ligaments, organs). It is essentially three-dimensional, non reducible and progressive, opposite to “scoliotic attitudes” which are simple compensatory deviation in the frontal plane to lower leg asymmetry, or to secondary deformities corrected after resolving of the cause (infection, prolapsed intervertebral disc, osteoid osteoma, etc.). (Figure 1)

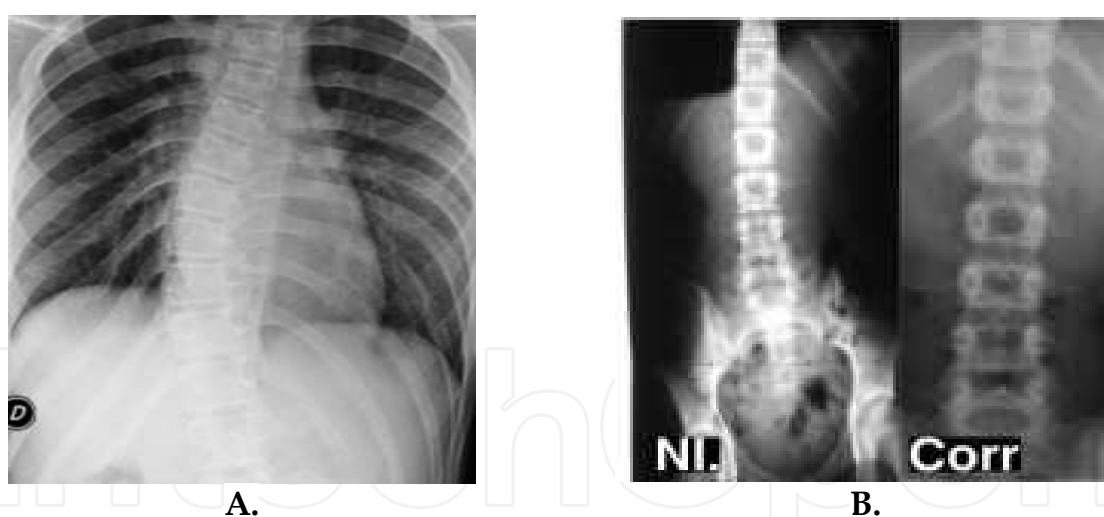


Fig. 1. A. Real scoliotic deviation, with vertebral rotation and costal deformation. B. Scoliotic attitude without vertebral rotation and correction by rectification of the leg length asymmetry.

The spinal 3D distortions and mostly their esthetical repercussions are the main patient's complaints, leading to the diagnosis: the rib hump, the asymmetry of the shoulders or of the flanks. This was well known in the historic medicine (already by Hippocrates in the ancient Greece) (Vasiliadis 2009), and the therapeutics were acting to correct these tree-dimensional distortions by traction and derotating bands. (Figure 2)



Fig. 2. 3D historic corrections of scoliotic deformation by axial traction and derotating maneuvers (A.) or bands (B.).

Nevertheless, this three-dimensional appearance was perverted by the use of the radiographic projections. Considering scoliosis only as a frontal deformation had a negative impact on the therapeutic processes, especially surgery.

The assessment of the spine in 3D through reconstruction models is so of first importance for the diagnosis, the follow-up and the treatment of the scoliosis.

2. The anatomical 3D deformities

3D models of reconstruction of the spine provide a virtual representation of the overall organization of the vertebrae distorted in diverse ways by distinctive distortions affecting the spine, the pelvis, the rib cage, the ligaments and the muscles. Such individual anatomical deformations are not apprehended nor by the imaging techniques nor by the 3D reconstructions. Only the knowledge of the evolution of the vertebral deformities allows an individualized analysis of the global 3D virtual representations and their use for a diagnostic, a prognostic or a therapeutic procedure.

2.1 From the "normal" to the scoliosis

Asymmetry is systematic in all individuals. A common significant trunk asymmetry was described in juveniles, which is changing into the adolescent pattern at a later age for boys than in girls. (Grivas 2006, 2008) Boulay (2006) described a systematic total asymmetry involving the right and the left pelvis. It follows a spiral path always in the same way for all the individuals: in the upper part, the iliac blades rotate clockwise; in the lower part, the pubic symphysis rotates anticlockwise. Nevertheless, such asymmetry is not source of spinal distortions, even if a twist occurs in the pelvis during the walk. (Figure 3)

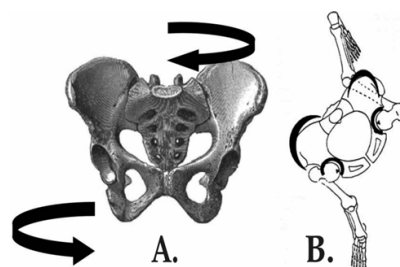


Fig. 3. Systematic morphological asymmetry of the pelvis (A.) and its repercussion on the walk (B.) occurring in all normal subjects.

Moreover, distorted vertebrae in congenital scoliosis, acting as local deforming corners, don't induce surrounding deformities once they are well balanced. (Figure 4 A.) Otherwise, the spinal curvatures of neurological or muscular origin occur in particular area and are typical by their long extension (Figure 4 B.) and often in the contrary side than the "idiopathic" scoliosis or the degenerative scoliosis of the elderly. (Figure 4 C. D.)

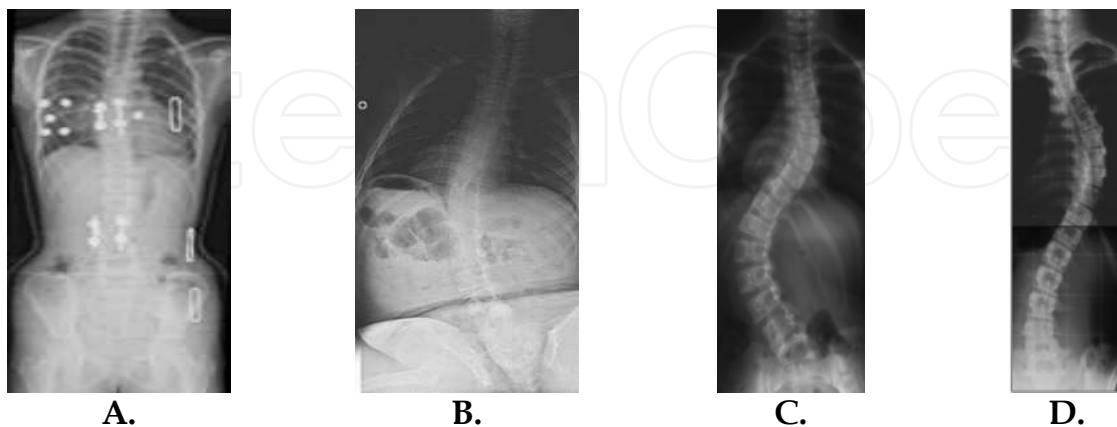


Fig. 4. A. Congenital scoliosis with double asymmetric vertebra stabilised and well balanced, without other associated deformations - B. Long curve of a neuro-muscular scoliosis - Left lumbar (C.) and right thoracic (D.) idiopathic scoliosis.

Such developmental scoliosis are essentially three-dimensional and their progression is so explicable once the distorting process is initialized. In the animals, they occur only in bipedal species, as experimentally by Machida (1994) and Lafortune (2007) in the pinealectomized chicken. (Figure 5)

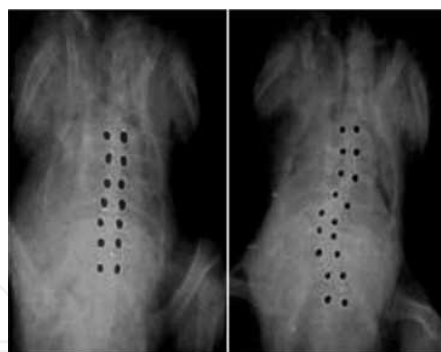


Fig. 5. Radiography of normal and scoliotic pinealectomized chicken.

Some anatomical particularities are encountered in scoliotic cases, as the asymmetric morphology of the facet joints (lumbar at one side, thoracic at the other side) at the lumbo-thoracic level, but they are insufficient to explain the origin of the disease.

Grivas (2002) assumed that the deformity of the thorax develops first and then the deformity of the spine follows. He emphasised the role of the diurnal variation and the asymmetric water distribution in the discs and the subsequent alteration of the mechanical environment of the adjacent vertebral growth plates, especially in the apex of the curve. (Grivas 2006c, 2008c) The deformation of the apical intervertebral disc seems so to be an important contributory factor in the progression of a scoliotic curve. (Will 2009)

2.2 The structural curve and the deformed vertebra

Contrary to other deformations (as the scoliotic attitudes or the curves induced by diseases as infection, tumour or disc protrusion), the true idiopathic scoliosis is characterized by a structured area, i.e. stiff and not reducible, which the vertebrae are gradually irremediably distorted. So, the scoliosis becomes more and more structured.

Vertebral deformity consists in a vertebral body asymmetry, a deformation of the articular processes, a torsion of the entire vertebra involving the discs, the ligaments and the other related structures as the ribs. (Figure 6)

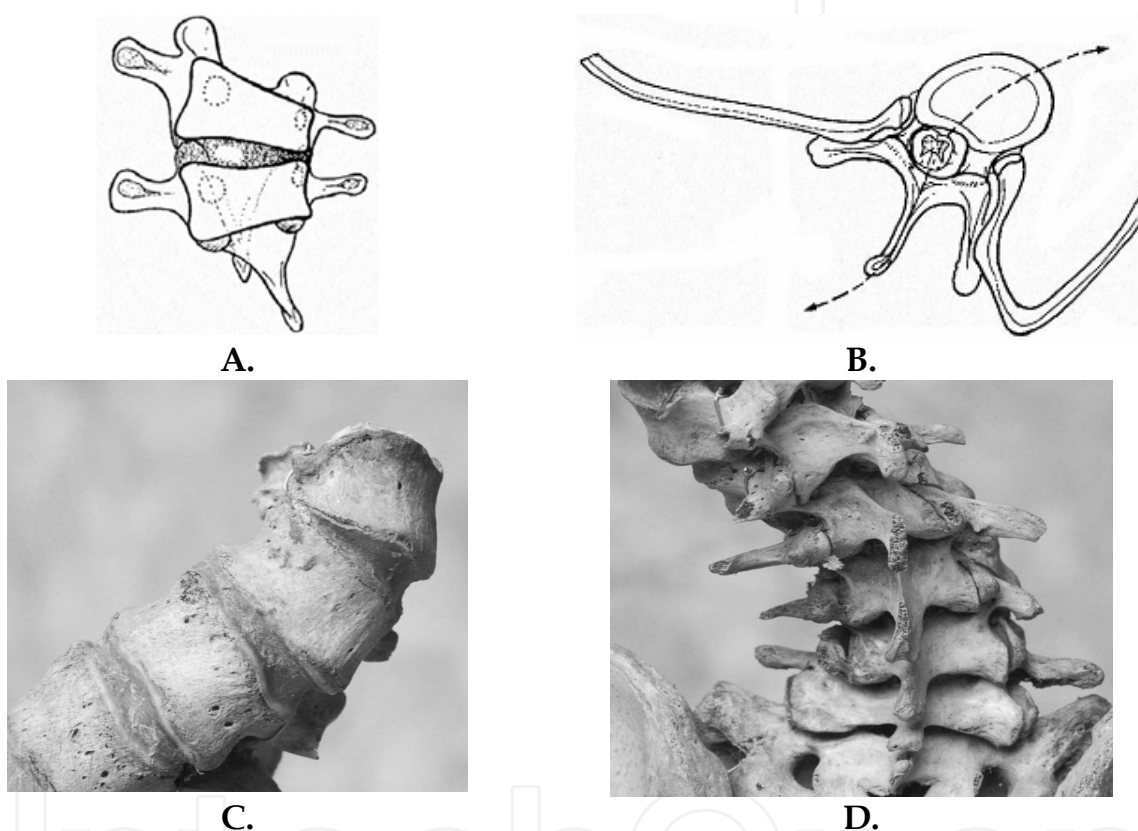


Fig. 6. Structural deformation of the scoliotic vertebrae. A. Cuneiform deformation of the vertebral body. B. Transversal torsion phenomenon of the entire vertebra involving the ribs. C. Torsion of the vertebral body and discal structures. C. Asymmetric deformation of the posterior articular and arch.

This structured deformation of the vertebra is so three dimensional and irreversible, defining the really structural principal curvature in case of multiple curves. On the contrary, the secondary or compensatory curves do not exhibit this anatomical irreversibility and are correctible, even partially.

It is noticeable that the entire spine is organized to lead ultimately to a horizontal gaze. These patterns of adaptation are three-dimensional and allow understanding the distorting process.

2.3 The key vertebrae

A scoliotic curvature is classically defined by its apical vertebra and its limits, or junctional, vertebra. (Figure 7) The rotation is maximal at the apical vertebra and near insignificant at the ends of curvature.

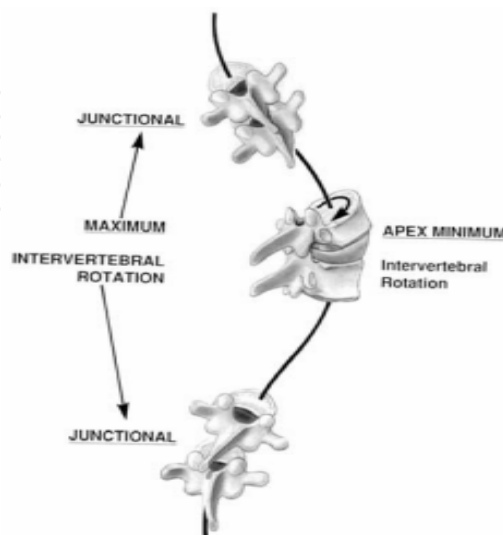


Fig. 7. The junctional and apical vertebrae of a scoliotic curve.

These definitions allow defining the topography of the curves and the classifications of the scoliosis, proposed in the literature to improve in the therapeutics, mostly surgical.

2.4 The classifications of the structural scoliosis

The classical classification simply describes the topography of the structural curve (lumbar, thoraco-lumbar, thoracic, double curve).

King's scoliosis classification is similar and defines 5 types of idiopathic scoliosis, whereby the severity of a case is based on the following parameters:

- Cobb angle on x-ray image
- Determination of "flexibility index" on bending radiographs

King's classification was proposed to establish the limits of the fusion in surgical procedures. (King 1983)

The disadvantages is that it doesn't not included the sagittal plane in the evaluation and don't consider the scoliosis with two or three major curves.

In 2001, Lenke introduced a new classification system for idiopathic scoliosis which is much more complex. It is based on survey spine radiographs in 2 planes, as well as right and left side bending radiographs with the following parameters: localization, degree and flexibility

- The curve apex is defined as follows for localization purposes:
 - Upper thoracic localization: curve apex between T2 and T6
 - Thoracic localization: curve apex between T6 and inter-vertebral disc T11/12
 - Thoraco-lumbar localization: curve apex between T12 and L1

- Lumbar localization: curve apex between inter-vertebral disc L1/2 and L4
- The determination of the flexibility of the curve is assessed either based on the residual curve in the bending radiograph or the extent of kyphosis. A curve is defined as structural if the bending Cobb angle exceeds 25° or the kyphosis angle exceeds 20°.

2.5 The Satagnara's plane of maximal curvature

However, these definitions are based on the radiographic 2D projections of the curves, regardless of their three-dimensional condition. Already in 1965, Stagnara defined the “plane of choice” of the curvatures, or plane of maximal curvature. (Figure 8 A.) Indeed, a curve may remain unchanged but rotating within the body. This will result in a feeling of increase or decrease of the curve in its radiographic lateral and antero-posterior (AP) 2D projection. Moreover, such structural curves are frequently stiffened by vertebral spontaneous fusions. (Figure 8 B)

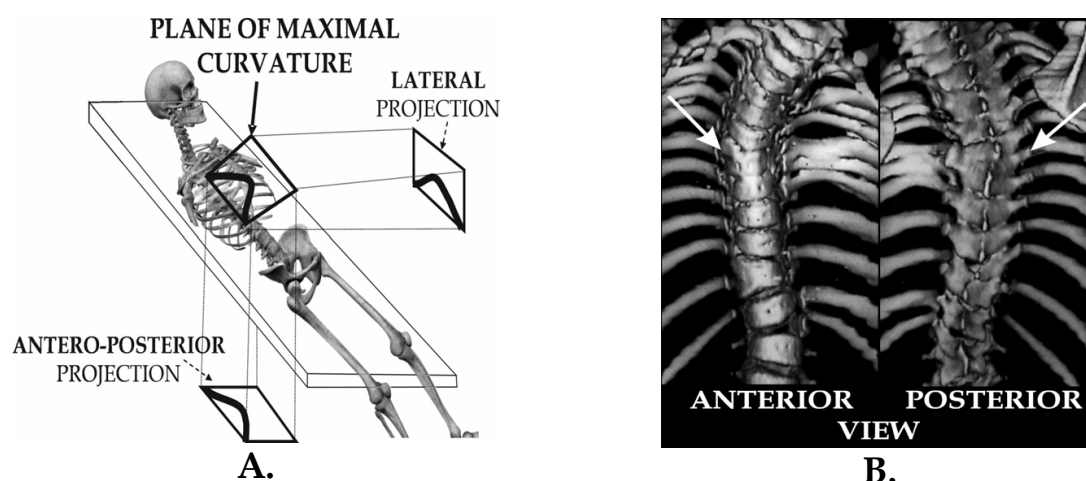


Fig. 8. A. The plane of maximal curvature and its lateral and AP projection. B. The stiff area of a curve by spontaneous fusion of the apical vertebral bodies and posterior arch.

This rotational effect is to be distinguished from a real aggravation. This requires defining three-dimensionally the “plane of choice” of the curvature, the area of stiffness or of suppleness, the inter-vertebral mobility. It emphasizes the necessity of a 3D appraisal of the spine for a real evaluation of the scoliosis. The anatomy of the scoliosis is so to be conceived on two levels: firstly as a mobilization between the vertebrae related to loading forces, secondly as structural deformations of the discs, the ligaments and the bony structures induced by unbalanced loads and corrective compensation. It is the purpose of the three-dimensional reconstruction models of the spine to explain and to quantify these 3D distortions of the scoliosis for a better diagnostic and prognostic evaluation, for an adjustment of the corrective processes by corsets or for the surgical planning.

2.6 The reference system

The reference system is universally used and was proposed by Stoke in the Scoliosis Research Society in 1994. It describes the planes and axis reference systems, for the whole body (global system), for regional (as the spine, the scoliotic curves...) or local structures (as a vertebra). (Figure 9) This reference system was so defined: the X axis follows the gravity

line, the Y- and Z-axes point toward respectively left and cephalad directions. The origins of the axes of global or local systems were defined according to the involved anatomical structures. The orientation of X, Y and Z axis are identical for all axis systems.

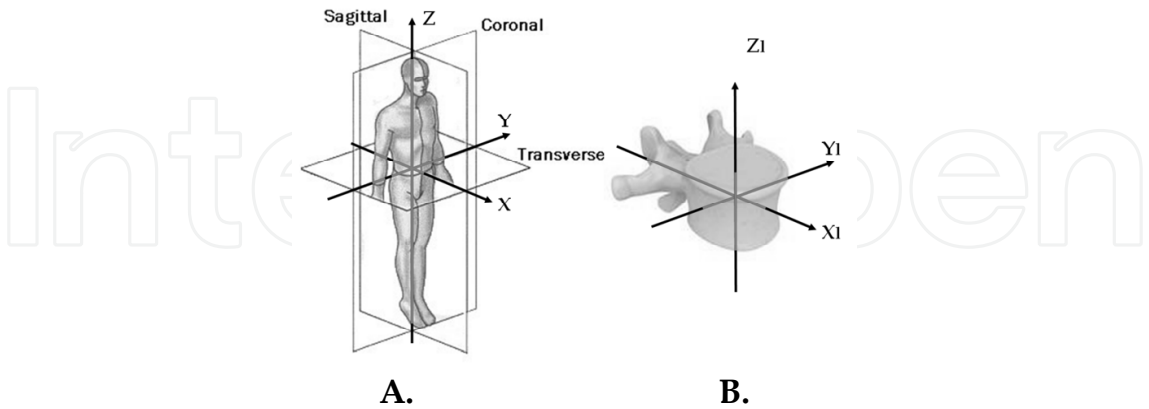


Fig. 9. The referential planes and axes in A. the global referential system (X, Y, Z) and in B. the local vertebral system (Xl, Yl, Zl).

2.7 The vertebral rotation

The vertebral rotation is to be distinguished from intrinsic spinal anatomical torsion, even they are progressively entangled.

2.7.1 The apparent rotation

Several techniques were proposed for the measurement of the vertebral rotation, using the radiographic projections of the spinal structures. It is the “apparent rotation”.

First techniques used the relative projection of the spinous process into the vertebral body shadow. Nevertheless, it involves the structured torsion of the vertebrae.

Most accurate techniques estimate the relationship between the shadows of the pedicles and the edges of the vertebral body. (Nash & Moe 1969) (Figure 10)

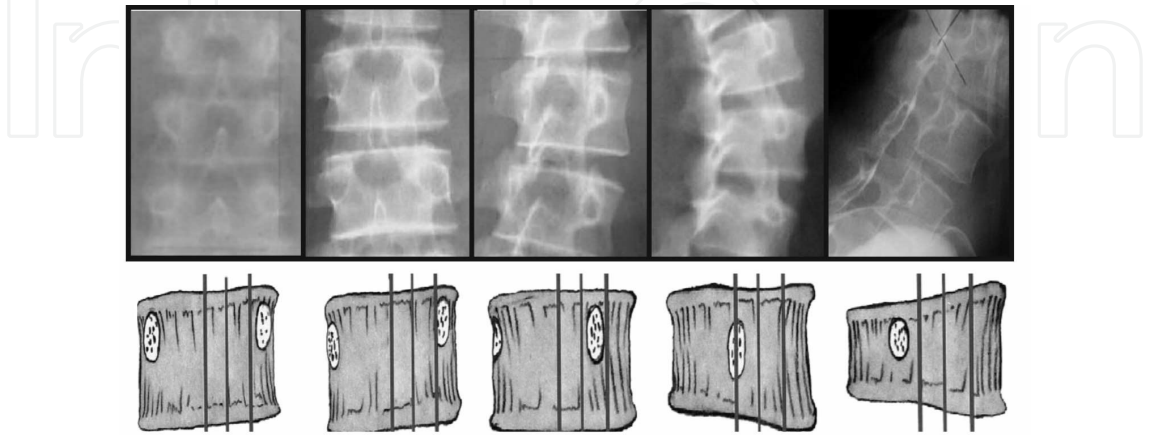


Fig. 10. Projection of the shadows of the pedicles into the vertebral bodies according to the increasing axial rotation.

Several authors proposed a variety of geometrical formulae using diverse anatomical vertebral structures projected in AP radiographs to develop a quantitative measurement of axial rotation, implicitly referred to the global referential system (Drerup 1984). Perdriolle (1987) propose a device named “torsiometer” allowing an easy measurement on AP radiographs. (Figure 11)

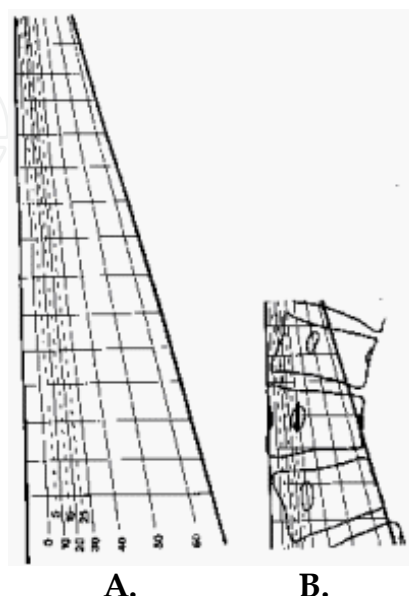


Fig. 11. A. The Perdriolle's torsiometer. B. Measurement of the rotation with the torsiometer using the edges of the vertebral body and the most visible pedicular shadow.

The use of CT scan and MRI was proposed for measurement of rotation, but radiography is still the more commonly used method. (Lam 2008)

2.7.2 The induced rotation

The induced rotation depends of the 3D tilts of vertebra in its local vertebral referential system. Its direction is definite by the order in which these tilts occur: the absolute rotations produced by tilting an object in its sagittal plane and then in its frontal plane, and vice versa, are similar but in opposite directions. (Figure 12 A) A formula describes this rotation:

$$\sin(\text{induced rotation}) = \frac{\sin(\text{frontal tilt}) \times \sin(\text{lateral tilt})}{1 + \cos(\text{frontal tilt}) \times \cos(\text{lateral tilt})}$$

where the lateral and frontal tilts are expressed in the local reference system and the “induced rotation” in the global system. (Hecquet 1998)

The position of each vertebra in a scoliotic curve changes at the same time in both frontal and sagittal planes, thus producing an “induced rotation” which is greater at the junctional (or end) vertebra.

Once more, the orientation of the radiographic rays introduces an artifact on the classical rotation measurement techniques like Perdriolle's one. (Figure 12 B) This figure represents the projected view of the same curvature, but the impact of the X-rays is different: both

intensity and side of the projected curve changes, as well as the apparent rotation. Otherwise, the measurement of the successive induced rotations from the bottom of the curvature does not change. The induced rotation is a really 3D measurement, while the usual radiographic techniques are 2D measurements with artefacts. It allows also explaining the paradox of true scoliosis with rib hump induced by the curvature while the apparent rotation is zero: this is also due to the artefact induced by the incidence of the X-rays on the 2D projection. (Figure 12 C)

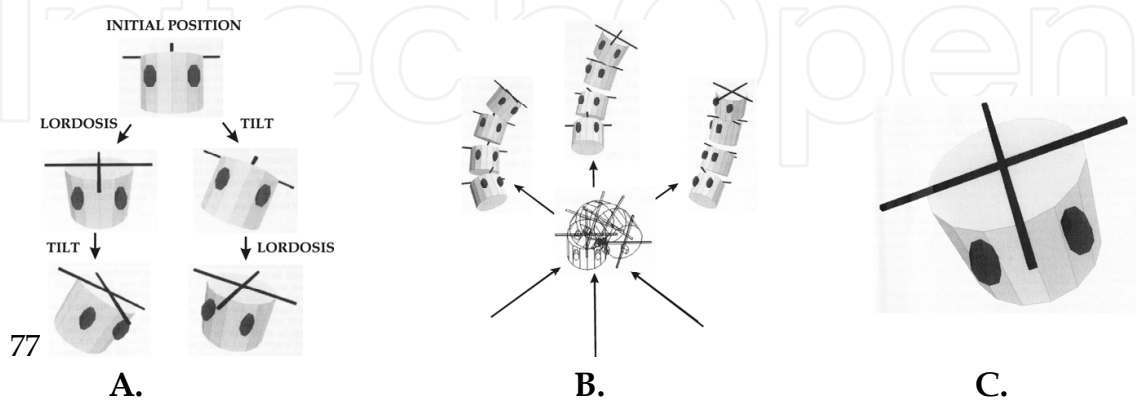


Fig. 12. A. Induced rotation by successive lordotic and lateral tilts of a vertebra depending of the order of local tilts. B. Projections according different impacts of X-Rays showing different 2D parameter of the same curve. C. Real induced rotation for which the apparent rotation is zero using the 2D measurements techniques.

2.8 Rotation and torsion

Rotation is characteristic of the scoliosis. In a normal movement of a disco-vertebral unit, the 3D rotations are associated (flexion-extension, lateral bending and rotation), related to the orientation of the posterior articular processes. The axis of motion is mobile according to the movement but confined at the posterior third of the disc (centrode). The local combination of an antero-posterior with a lateral tilting induces a 3D “induced rotation”. These 3D rotations are reversible according to the disco-ligamentar flexibility. *Torsion* is the intrinsic twisting deformation of the vertebrae induced by the asymmetrical bone growth. These anatomical distortions are irreversible: it characterizes the structural deformation. (Figure 13) Tedious CT measurement methods were described (Doi 2011)

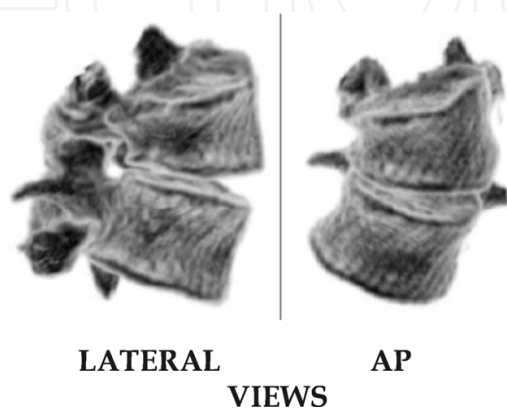


Fig. 13. Irreversible axial torsion of the vertebrae in structural scoliotic curve.

2.9 The 3D bodily scoliosis

Both rotation and torsion have repercussion on the adjacent spinal structures, as well on their own sagittal and lateral displacement inside the body. So are created the 3D deformations characterizing the aesthetic disturbances leading the patient to consult and allowing diagnosing the scoliosis by its 3d repercussions. (Figure 14)

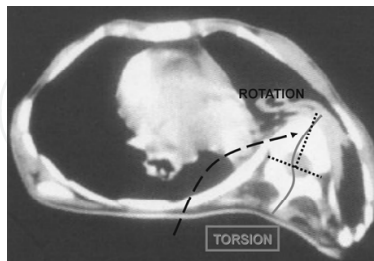


Fig. 14. CT scan of a thoracic curve induced by vertebral torsion, rotation and displacement involving the bony structures (vertebrae, ribs) and the organs (heart, lung, muscles). These 3D phenomena occur all together. The flexible and reversible rotation predominates in the early development of the scoliosis in growing ages. The three-dimensional clinical analysis aims to quantify these events from imaging spinal reconstruction techniques. Assessment of the scoliosis using 3D models has a prognostic value and aims to increase the correction of therapeutic techniques, conferring to the 3D analysis of the spine an essential role.

3. The techniques for 3D reconstructions

3.1 CT Scan and MRI 3D reconstructions

CT scan and MRI could be used to assess the spine in 3D. Nevertheless, they are performed in lying position, not allowing assessing the balance in standing position. CT scan of MRI has only interest for a precise morphological description of malformations, tumours or infection inducing scoliosis. In congenital scoliosis, such 3D technique determine the individual morphology of unsegmented fused area or deformed parts of vertebrae, and the associated malformations, as for the ribs. (Figure 15)

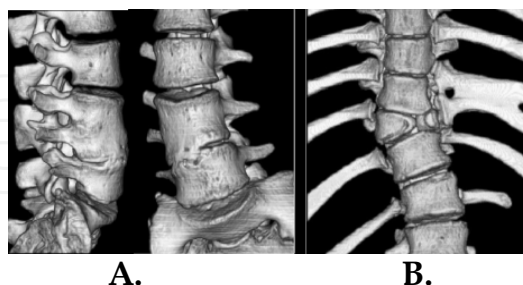


Fig. 15. 3D reconstruction by CT scan of congenital scoliosis: A. Unsegmented area between two vertebrae by loss of segmentation. B. asymmetrical vertebral bodies and fusion of ribs.

3.2 The radiographic techniques

3D reconstruction techniques allow a virtual assessment of the spine. Classically, such 3D reconstructions are performed from multi-planar (usually orthogonal) standing radiographies. (Figure 16)

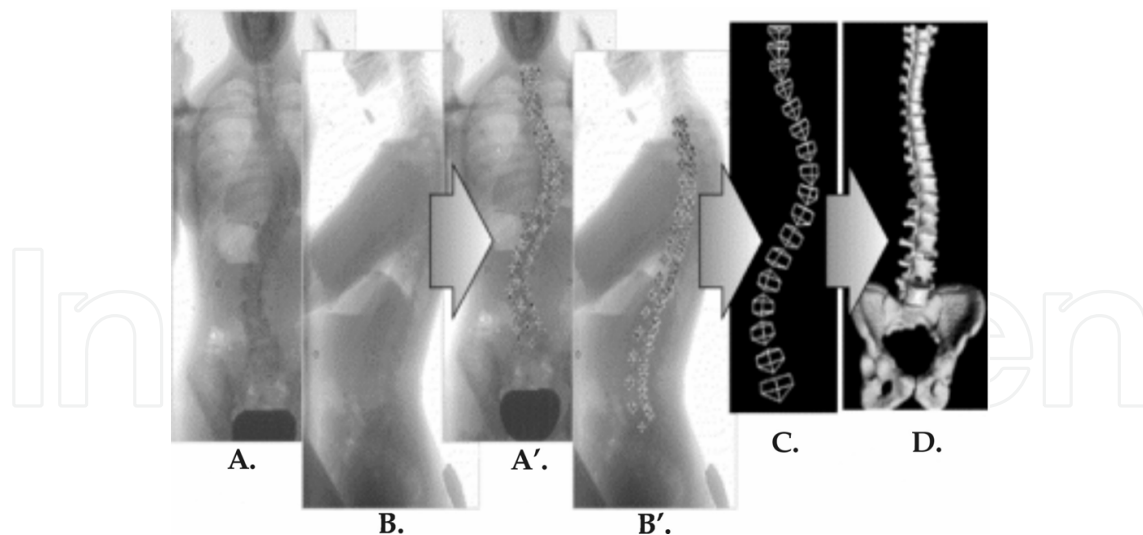


Fig. 16. "Standard" main steps of 3D modelling process of the vertebral structures: (A. B.) radiographic orthogonal AP (A.) and lateral (B.) views
(A'. B'.) manual identification of six anatomical landmarks per vertebra,
(C.) "standard" 3D reconstruction of the anatomical landmarks,
(D.) visualization of the geometric model

Various techniques are proposed:

- *the stereo radiographic techniques*: they use 4 to 25 anatomical points for a vertebra to reconstruct the 3D spinal structures. The *non stereo-corresponding techniques* use algorithms developed from the knowledge a priori of the anatomy. (Mitton 2000, Mitulescu 2001) The anatomical vertebral landmarks are either "corresponding anatomical points" (identifiable both in frontal and lateral views), either "not corresponding points" (identifiable only on one of the radiographic view). (Figure 17)

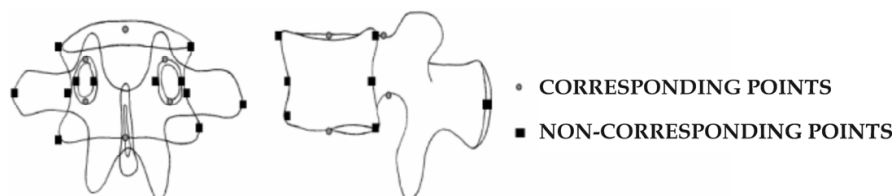

Fig. 17. Corresponding and non corresponding points on an AP and lateral radiographic shadows of a vertebra for a stereo-graphic 3D reconstruction technique.

However, it is relatively long to implement and therefore not used in everyday clinical practice. Moreover, its precision is related to the ability of the observer to identify the anatomical structures on the radiographs (especially difficult in upper thoracic area, or in case of major deformity).

- *The semi-automatic statistical techniques* are faster to use. Reconstructions are performed from some not anatomically corresponding points (the corners of the vertebral bodies) related to a morphological database by interpolation and optimalization. It supposes a priori knowledge of the structure of the objects and of their deformation. (Pomero 2004) The 3D representations can eventually be individually adjusted during handling according to the X-ray imaging for better reliability. (Blanchard 2008, Dumas 2008)

Then, a customization process improves the visual appearance of the bony reconstruction. (Figure 18)

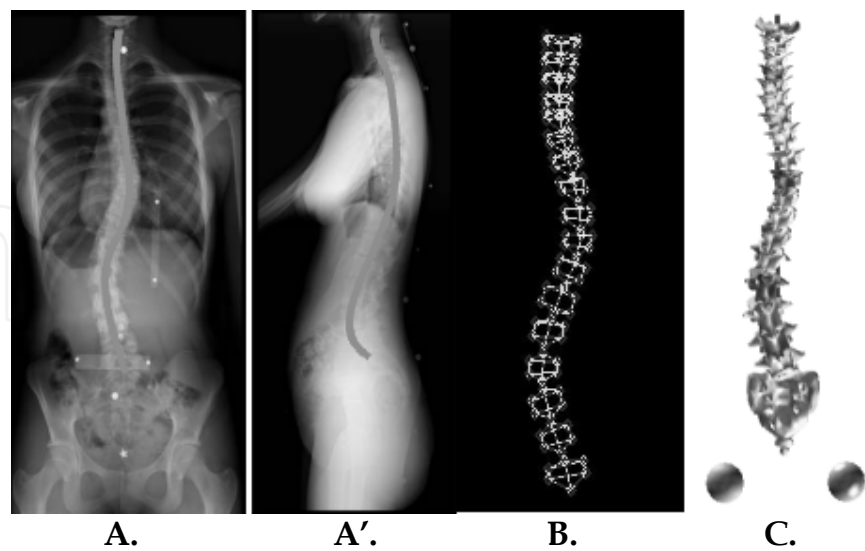


Fig. 18. Statistical method for 3D spine reconstruction: spinal "spline" determined on the AP (A.) and lateral (A'.) radiological view. B. 3D reconstruction linked to a statistical database. C. Customization of the vertebrae.

The accuracy of these techniques, tested on models, was similar to the precision of manual stereo-radiographic techniques: 1 degree for lateral and sagittal tilts and 3 degrees for the axial rotation of each vertebra. (Labelle 1995, Dumas 2004)

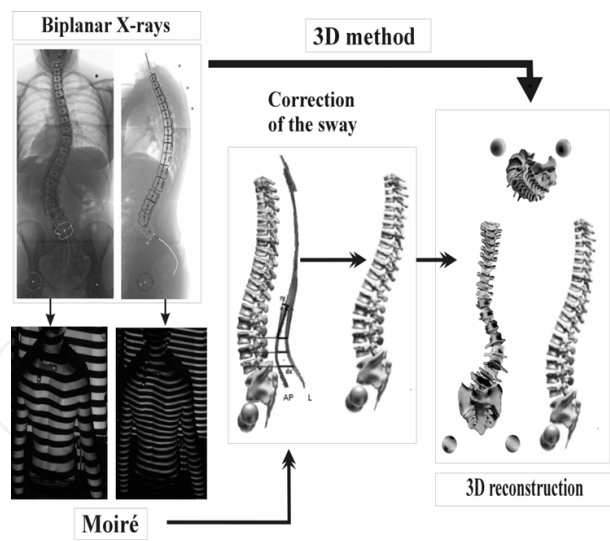


Fig. 19. 3D reconstruction with hybrid X-ray / Moiré imaging for a scoliotic patient: the trunk deformation due to the sway of the subject between the exposures was detected by the Moiré imaging - the correction factors assessed by the Moiré method was then applied to the 3D reconstruction for an optimal accuracy.

However, the mobilization or the sway of the subject between the two X-rays or during their completion is a source of artefact, and so of inaccuracy. Such a tilt of 10 degrees between AP and lateral radiographic exposure is usual. (Bellefleur 2002) To correct this source of lack of

precision, the use of an optical assessment of the skin surface of the back (morphometry by Moiré technique) simultaneously to the X-rays has been proposed. (Legaye 2009) A common calibration tool unifies the two referential systems for automatic corrective procedure. So the precision was 1.3 mm for the 3D location of the vertebrae and 1.5 degrees for the tilts and rotation. For a sway greater than 10 degrees, the improvement persists, but a risk of lack of accuracy exists and is detected by the method. (Figure 19)

A recent imaging system (EOS) allows simultaneous lateral and antero-posterior radiographic views of the whole body in standing position, including the lower limbs and notably reducing the irradiation from 8 to 10 times. (Dubousset 2008) The classical radiographic 3D techniques are usable, but it doesn't avoid the consequence of a moving of the subject during the procedure

3.3 The optical surface topography techniques

3.3.1 Interest of 3D trunk evaluation by non invasive techniques

Although scoliosis is characterized by a 3D deviation of the spine, its results clinically in a deformation responsible for geometric and morphologic changes of the trunk and rib cage which lead to initial complaints. (Nault 2002) The trunk symmetry is what it is seen and praised by the child, not the radiograph itself which is traditionally used by the physician. Moreover, the cosmetic improvement of the trunk after any treatment is of paramount importance for the child under treatment and his family. (Figure 20)

For the medical physician also, trunk analysis can help to document the external asymmetry associated with different types of spinal curves in scoliosis as well as the cosmetic improvement obtained after surgical interventions. (Pazos 2007).

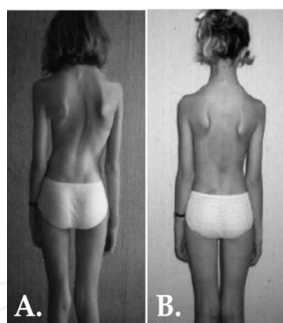


Fig. 20. Pre (A.) and post-operative (B.) back shape of a scoliotic case.

Otherwise, school screening was proposed for an early diagnosis of scoliosis and to improve the results by early treatments. But such screening, and eventual subsequent follow-up, should need multiples X-rays. Unfortunately, cumulative X-rays were reported increasing the risk of future cancers, particularly of the breast in girls. (Denton 1992) Therefore, the use of optical techniques was proposed for such screening.

Such optical techniques for the assessment of the skin surface topography of the back assume that the trunk deformities reflect the underlying bone deformations. Specific parameters were proposed, some specific, some analogous to those measured on radiographs but not similar because both techniques evaluate different structures (the bony spine for the X-ray techniques, the skin surface for the optical techniques).

3.3.2 Optical techniques

Optical systems have been developed as non-invasive imaging techniques. Such systems are the Moiré-fringe mapping, the structured light techniques or Integrated Shape Imaging System (ISIS) (Turner-Smith 1984, 1988, Weisz 1988, Theologis 1997, Berryman 2008), 360° scanning devices (Poncet 2000) and stereo-photogrammetric systems (Frobin 1983). Laser techniques were also developed for corset manufacturing, but not for clinical use.

3.3.3 The “Moiré fringe” technique

Moiré-fringes procedures are most often used for 3D assessment of the back morphology. Moiré is an optical contrast effect changing with the deformation of an object. The moiré is created by dark and light lines resulting from the superposition and interference of two networks of light (generally a set of parallel lines). This can be used to analyze the deformation of an object. (Figure 21)

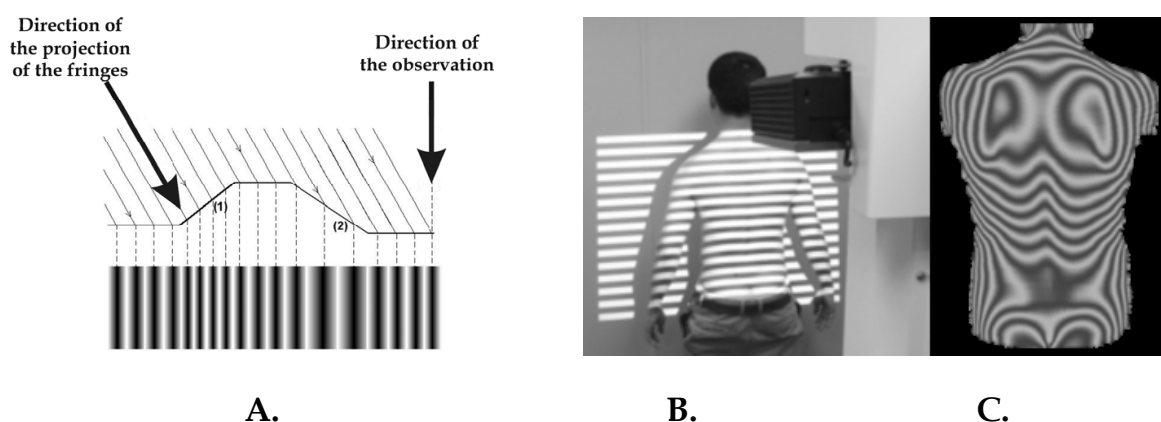


Fig. 21. A. The theoretical principle of the Moiré-fringe. B. Its use for the back surface analysis. C. The imaging of the back surface relief.

The moiré topography was abundantly described for the analysis of the back shape in scoliosis. (Sahlstrand 1986, Breque 2004, Turner-Smith 1984, 1988, Weisz 1988, Theologis 1997, Berryman 2008).

In structural scoliosis, the 3D deformation of the spine is assumed to influence directly and proportionally the morphology of the back. Indeed, back asymmetries are mainly caused by the vertebral rotations. Also, rib hump was reported as the key parameter to detect and to follow the evolution a scoliotic deformation. It has also been reported that patients with double curves have significantly less trunk deformity (both in the transverse and coronal plane) than patients with thoracic and thoraco-lumbar curves of similar Cobb size. Goldberg assumed that assimilation between corresponding optical and radiological parameters is unsuitable because both methods focus on different aspects of the deformity. Nevertheless, the 3D presentation accompanied by numerical data produced by surface topography systems offers a more complete perspective of the deformed back surface and enables a more thorough analysis of the patient's deformity pattern. (Goldberg 2001).

3.3.3.1 3D optical parameters

3D parameters are available for the back shape analysis. Some describe the global deformation of the skin surface, as the rib hump, some appraise the spinous process line (the relief's of the spine between the prominent C7 process at the top, and a point plumb the inter-gluteal fold at the bottom). Sagittal view help to assess the balance and the top view estimates the global spinous process line. (Figure 22)

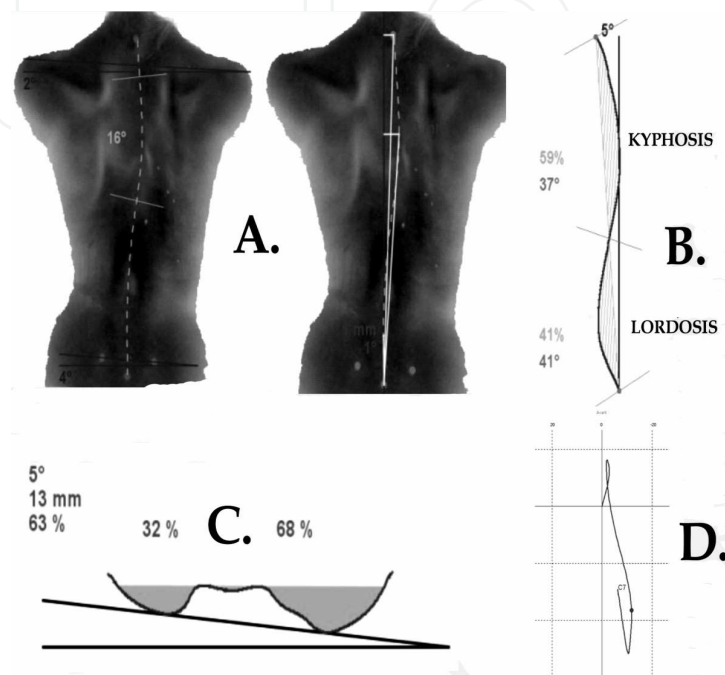


Fig. 22. Some Optical 3D parameters: A. Frontal parameters: spinous line angle and arrows, asymmetry of the shoulders; B. Sagittal parameters: global axis, lordosis, kyphosis; C. Transversal parameters: rib hump in standing position (in mm, degrees and %); D. The top view of the spinous line.

3.3.3.2 Reliability of the optical techniques

It has become apparent from many reports that, although there is a significant correlation between clinical deformity and radiographic measurement, the standard deviation is so high that it is not possible to reliably predict the degree of curvature from only the surface topography in any given patient. (Bunnell 2005)

Nevertheless, 3D Surface topography is mostly useful for scoliosis screening and follow-up in the growth period. Its sensitivity is 90%, its negative predictive value is 90% for curve progression detection. It is reproducible in intra and inter-operators. It can be used to space out and trigger X-ray controls with a mild risk of false negative.

Accurate follow-up is easy, repeatedly, as the technique is absolutely safe, using only the light and not potentially iatrogenic ionizing rays. Imaging is also easily understandable. It raised awareness of the deformation and motivates to the therapeutic process. Moreover, it is closer to the perception of the distortion by the patient, being mainly concerned with the aesthetics 3D deformities induced by the scoliosis rather than the radiological distortion of the spine. (Pazos 2007, Denton 1992, Weisz 1988, Theologis 1997, Sahlstrand 1986)

4. The three-dimensional conception of the spine

Assessing of the scoliosis in its correct 3D reality corrects the artefacts resulting from the two-dimensional X-ray projections. (Graf 1983) By example, the rotation of a rigid vertebral area will be seen on the 2D view as an increase or decrease of the Cobb angle, while the 3D analysis, especially by the top view, will detect the stiffness of this segment and its global rotation. Contrarily, a real correction in a supple area will be better assessed because taking into account the global 3D evolution, especially concerning the inter-vertebral tri-axial rotations.

Similarly, analysis of inter-vertebral rotations will highlight a segmental increasing of instability in the event of a change in the induced rotation. A potential evolution is detected in a forward-looking and therefore treated preventively.

5. The 3D reconstructions parameters

The perception of the spatial position of the vertebrae and their rotations and torsions led to the development of computerized 3D reconstructions of the spine, ideally adjusted of the sway of the patient between the achievements of the AP and lateral imaging.

The standard usual 2D radiographic parameters remain measurable on the 3D reconstructions, including those involving the femoral heads, but upgraded by its specific three-dimensional component. Additional purely 3D parameters have been proposed, particularly the "3D curve area" and the "top view" of the spine.

5.1 The 3D curve area

The spinal curvatures include themselves in flat surfaces. In normal subjects, these areas contain the lordosis and kyphosis, and are essentially sagittal. In case of scoliosis, the areas are disturbed or some are induced by the scoliotic deformation, influenced by the spinal rotations. These plans including the curvatures are easily detected by the 3D reconstruction software. (Figure 23)

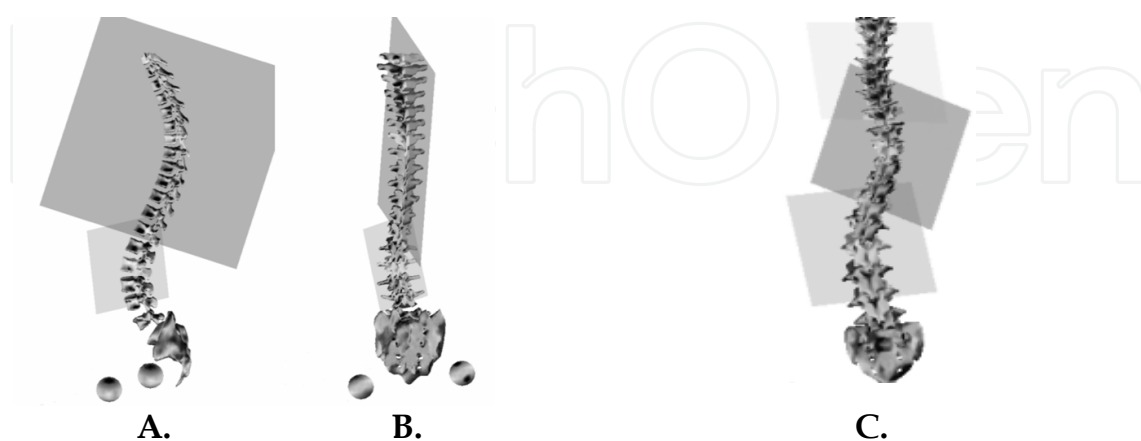


Fig. 23. 3D modification of the lordosis and kyphosis planes (normally strictly sagittal) induced by a lumbar scoliosis in 3D reconstruction lateral (A.) and AP (B.) view. C. Supplementary planes induced by the more marked scoliotic curves.

The extent and 3D orientation of these surface areas including the curves allow assessing worsening or correction of scoliosis, treatment processes, and provide guidance. By comparing successive examinations, a meaningful assessment of the rigidity or flexibility of spinal segments is achievable, as an accurate assessment of its evolution in the 3D conception. The same purpose is available by the optical morphometric technique, using the 3D shape of the spinous process line reflecting the underlying bony spine, the rotation of the body segment (rib hump) reflecting the underlying vertebral rotation.

5.2 The top view

Thanks to computerized spinal analysis, the top view was developed that displays the spine as if the observer were above and looking down on the patient. It is provided by the 3D reconstruction techniques, whatever its origin (X-ray or optical) with more or less sophisticated imaging representations. (Figure 24)

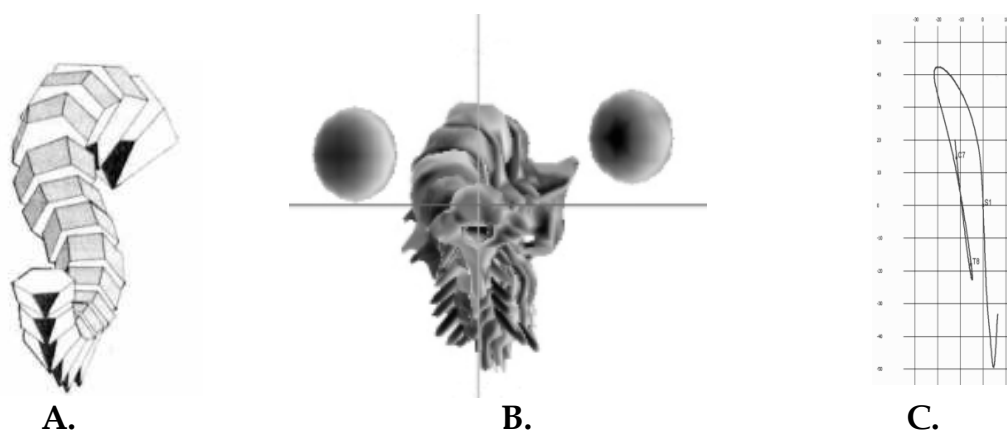


Fig. 24. Top views from radiographs (A. cubic patterns- B. schematized vertebrae) and C. optical acquisitions (3.2.3.1).

Most software allows to "unstuck" the successive vertebrae to access a personalized view of the 3D rotations and positions of each vertebra into the global spine. Nevertheless, the intrinsic vertebral twist is not represented. (Kohashi 1996)

This top view is essentially three-dimensional. It allows to appreciate the scoliotic deformity as a whole: the importance of the deformation by the tilt from the top of the curve, the plane in which it is included (its extension and 3D orientation), the intensity of the vertebral rotation and the overall tilt. Its evolution is determined really three-dimensionally. It results in a moving of the top of curvature relatively to its limit vertebrae, an accentuation of the global rotation of the curvature, an extension to the adjacent levels. (Figure 25)

In addition to the 3D detection of progression or destabilization of a scoliotic curve, the top view makes it possible to understand its mechanism. This better understanding of the individual progression of a scoliosis allows a personalized adaptation of therapeutic action, whether by physical therapy, brace or surgery. The apical vertebra of a lumbar scoliosis moves laterally to the left and backwards with a counter-clockwise rotation (Figure 26 A.), while the apical vertebra of a progressive thoracic scoliosis moves laterally to the right and forwards with a clockwise rotation (Figure 26 B.).

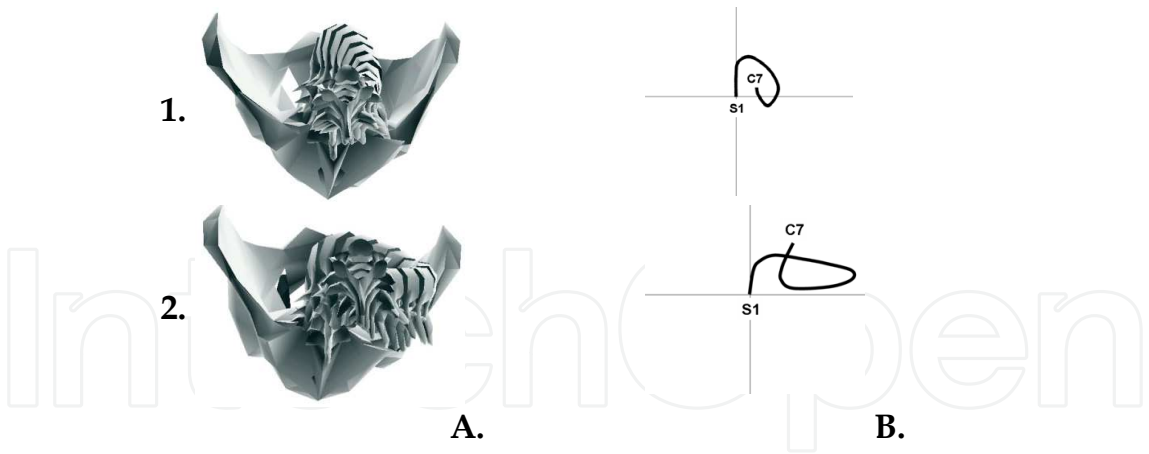


Fig. 25. Top view of a progressive scoliosis (1. Original state. 2. final evolution) in vertebral schematic (A.) and filiform (B) representation: increased frontal diameter of the curve - decreased antero-posterior diameter (traducing the change in the orientation of the plan including the curvature) - increased lateral shift of the top of the curve (expressing the increasing of the curve) - loss of the lordotic area (by extension of the thoracic curve in the lumbar area) - forwards global tilt of C7.



Fig. 26. Transversal moving of the apical vertebra of a lumbar scoliosis (A.) and of a thoracic scoliosis (B.)

6. Functional evaluation

It is important for the physician to assess the balance of a scoliosis, both in the frontal as in the sagittal plane, to assess its potential instability, and how to avoid it. In the frontal plane, the "overhangs" between various levels (mostly from C7 to the sacrum) are easily measurable. (Figure 27 A.) In the sagittal plane, the individualized assessment of the balance of the lumbo-pelvic complex was well defined by Duval-Beaupère (1998). All anatomical (Pelvic Incidence) and positional spinal pelvic parameters as well as the evaluation of the respect of the harmony of their relations between parameters can be automatically calculated. (Figure 27 B.)

Morphological analysis of the pelvi-spinal balance was established from the study of the loads of the gravity at each level of the spine and the pelvis in standing position. Therefore, Duval-Beaupère developed an experimental gamma-ray scanner allowing locating of the gravity, coupled with a 3d reconstruction system: the barycentremetry. (Duval-Beaupère 1992) (Figure 28 A.) It has been observed that the gravity applies in the entire spine into a vertical cylinder of 1 cm diameter, usually located slightly forward of t9, crossing the spine at the thoraco-lumbar junction to place backward the lumbar spine and behind the femoral

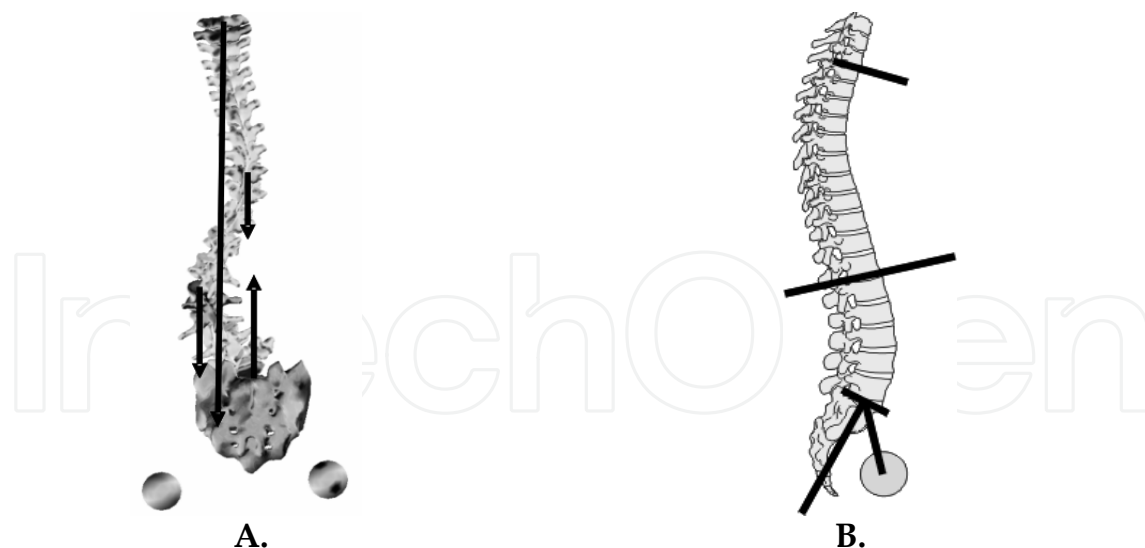

Fig. 27. Frontal (A.) and sagittal (B.) balance analysis.

heads, being centred in the frontal plane. Were thus determined the 3D lever arms of the gravity determining the evolution of spinal deformities. From these several observations, a predictive equation of the position of the gravity loads was established, using morphological, positional and anthropometrical parameters: the simili-barycentremetry. (Legaye 2008) (Figure 28 B.) It allows so a functional personalized 3D evaluation of the balance and a functional assessment of individual. Asymmetries of these solicitations allow defining the 3D mechanical characteristics of a scoliotic deformation and establishing a prognosis of eventual increasing. Such assessment allows also adjusting the therapeutic goals to avoid such predictable accentuation of the curves and deterioration of the balance.

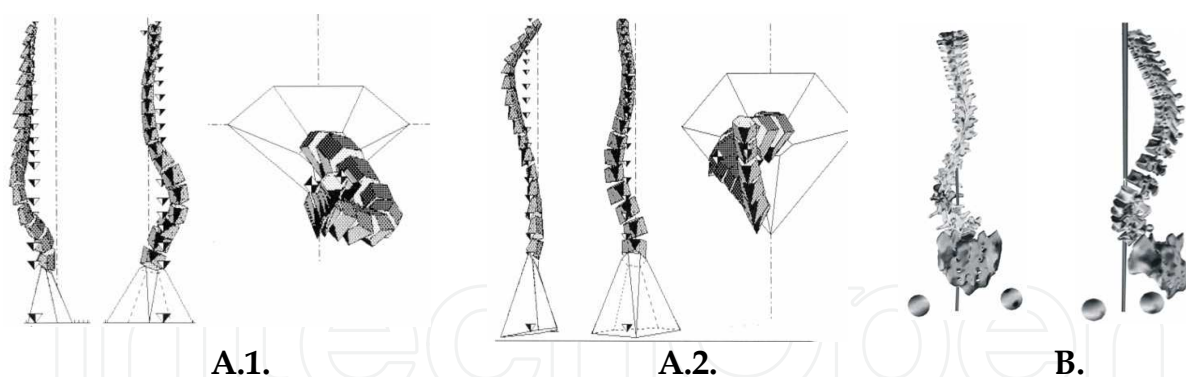


Fig. 28. Functional analysis of the gravity loads: A. Barycentremetry of a lumbar scoliosis (A.1.) and of a thoracic scoliosis (A.2.) – B. Simili-barycentremetry.

7. 3D implications for the treatment of scoliosis

The 3D concept of scoliosis allows, using reconstruction software's, a better diagnosis and an appropriate individual evaluation of potential increasing of the curve(s): anatomical in curve angular progression, extension in adjacent area, 3D mobilization a stiff area thanks to supple levels. It implies a 3D assessment of those areas of rigidity and flexibility, and their 3D orientation. This new knowledge, not accessible by 2D imaging, has also given rise to conceptual treatment, whether medical or surgical.

7.1 Physiotherapy

Physiotherapy techniques are based on stretching in myotensif, or total work. When properly applied and well done, they offer good results. These techniques target mobility of the spine, better muscle flexibility for efficient movement, a reprogramming of neuromuscular postural adjustment. The analytical muscular correction needs to be three-dimensional, as well as the adaptation of sports (including swimming).

7.2 The corsets

Most of the time, the different types of corsets don't take into account the individual biomechanical properties of each patient's spine. Actually, it is essential to better understand the effect of the loads applied on the trunk and on the spine, and a 3D geometrical modelisation of these components is essential. The design and adaptation of individual braces or corsets are to be designed according to a 3D imaging of the spine and the skinny shape. Their effectiveness will be increased for optimal correction of the curves taking into account their three-dimensional component. The balance will also be maintained or restored. Such individual most appropriate corsets will also be better tolerated.

7.2.1 Manufacturing of corsets

Optical methods have been developed to simplify and optimize the manufacturing of corsets. These techniques virtually reproduce the contours of the subject's body, integrated into the 3D reconstruction of the spine. From there, the operator improves the corset by adequate 3D positioning of the pressure points. This also limits the use of body cast, though some consider the body cast as a prerequisite. From custom imaging the spine, corsets have been developed to optimize the correction even by active detorsion, some using the flexibility of some area and elastic traction in stiff area for a 3D correction.

7.3 The surgery

7.3.1 2D surgery

When scoliosis was considered only as a 2D frontal deviation, the correction consisted essentially of an axial vertical tension conducting to "dollar" montages (as Harrington's technique, 1962), leading to almost flat backs, without correction of rotations (nor so of the rib humps).

7.3.2 3D surgery

The rotational misalignment expressed by the rib hump has been the most difficult part of the deformity to correct. Effectively realigning vertebrae that have rotated out of position — a process called derotation — is an area of great interest in scoliosis correction surgery. In recent years, surgeons have sought new ways to maximize curve correction three-dimensionally. This means addressing the curve in all three "planes" of the deformity. Correcting vertebral rotation requires considering the axial aspect of the spine, or the cross-sectional top view.

It is up to Cotrel and Dubousset for using 3D conception of scoliosis to develop a technique also acting in 3D by a rotation effect of a pre-moulded rod, mainly using hooks to act on the

bone structures. (Cotrel 1988, Lee 2004) (Figure 29 A.) The use of pedicle screws allowed a better action on the vertebrae, especially for the derotation, using instrumentation on segments rather than on the entire spine. Techniques of segmental corrections by in situ modelling of the rods have been developed (using hooks, screws or sub-laminar devices). (Figure 29 B.) This allows not only untwisting the vertebrae, but at the same time reducing the rib hump, since the ribs associated to the deformity are attached to the vertebrae being derotated.

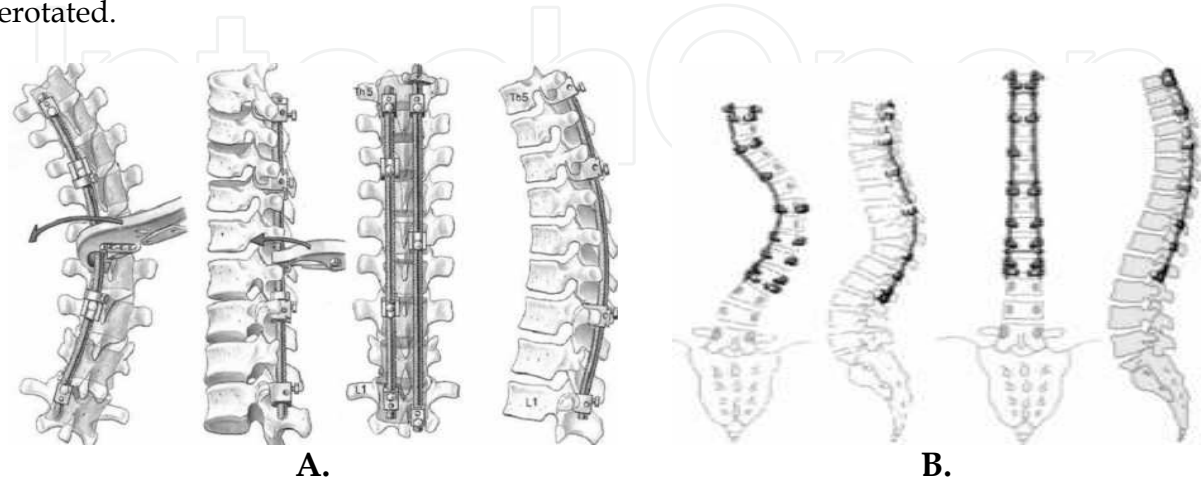


Fig. 29. Surgical techniques. A. Cotrel-Dubousset: rod rotating technique – B. In situ rod modelling technique.

These moving of the fixations points must be adapted according to the 3D position of the vertebra (rotation and translation). (Dumas 2003, Steib 2004) Otherwise, it could lead to a increasing of the rotation rather than a correction. (Figure 30)

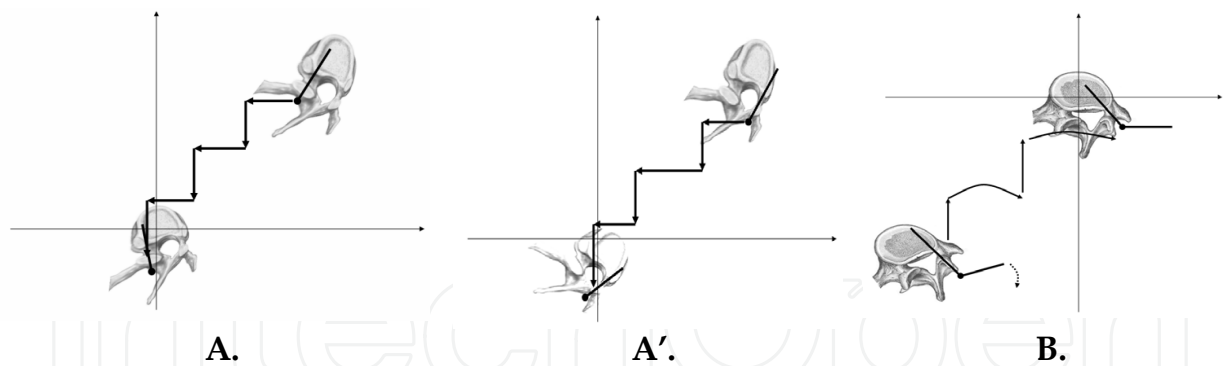


Fig. 30. Derotation technique for thoracic (A.) and lumbar (B.) scoliosis: A. Correct sequence on the screw in the concave side. A'. Accentuation of the rotation if acting on the convex side. B. Correction in the lumbar level by postero-anterior and local axial derotating forces.

So, for surgery, the 3D analysis is essential for planning and achieving the procedures. The 3D corrective principles are essential, distinct in the thoracic and lumbar area. Ignoring these principles can limit the corrections, and even increase the rotations or attempt unnecessary corrections of rigid segments instead of performing an action at their flexible extremities. Using of actual devices allows such 3D corrections, restoring optimal balance.

Nevertheless, the correction of the deformed ribs is not related to the vertebral correction related to the stiffness of the ribs. But this affects the aesthetic result.

7.3.3 The rib hump

If a patient has a significant rib hump that's expected to remain even after fusion surgery, a procedure called “thoraco-plasty” also may be performed, either along with the fusion or at a later date. It consists in sections of the ribs that form the hump which are surgically removed to shorten the ribs and reduce their prominence. (Figure 31) The benefits can include an improved appearance and pain relief.

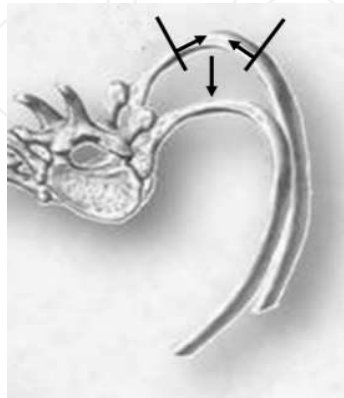


Fig. 31. Thoraco-plasty for correction of the rib-hump.

8. Usefulness of the 3D in diagnosis and treatment of scoliosis

Having a three-dimensional representation of the spine can result in a more accurate diagnosis, a more specific treatment, and less time in scoliosis surgery. The surgeon can improve the treatment of scoliosis by a better understanding of the deformity and perform an appropriate personalized procedure. An advantage of 3D reconstructions is that they identify defects that 2-D images do not. The preoperatively 3D analysis of a scoliotic deformity allows refine the limits for fusion and improve corrections by acting on the flexible zones surrounding stiff areas.

Therefore, 3D corrective techniques, both medical and surgical, are abundantly reported improving the corrections of the curves and restoring the balances. Subjective patient's outcomes are also better. Several studies have demonstrated the better significant relationship between results and 3D clinical parameters than for 2D evaluation.

9. Limits and perspectives

The 3D analysis is still only rarely used in daily practice because of the time required for certain reconstruction techniques. The development of automated and user-friendly methods will help the clinician in performing such procedures.

However, most 3D reconstructions have the disadvantage of not taking into account either the ribs or the rib cage and few of them include the lower limbs (or even the femurs), so essential for the analysis of the sagittal balance. Simultaneous use of optical morphometry allows already connecting the bony spine to the back shape.

The future aim is to access to individual inter-vertebral motilities for a more precise preoperative planning and also correction using dynamic systems to maintain spine mobility and avoid destabilisation of the adjacent levels occurring in case of fusion.

Moreover, the combined use of various 3D techniques (reconstructions of the bony spine, back shape morphology, dynamic tests, gravity loads on the spine, ...) will provide an individualized functional assessment of the spine and of the balances. (Figure 32)



Fig. 32. 3D reconstruction of the bony structures from optical analysis of the back shape.

10. References


- Vasiliadis, ES. ; Grivas, TB. & Kaspiris A. (2009). Historical overview of spinal deformities in ancient Greece. *Scoliosis*, Vol. 25, pp. 4:6
- Grivas, TB. et al. (2006). Study of trunk asymmetry in normal children and adolescents. *Scoliosis*, Vol. 1, pp. 19
- Grivas, TB. et al. (2008). Back trunk morphology in 3301 children aged 3-9 years old. *Stud Health Technol Inform.*, Vol. 140:, pp. 29-32
- Boulay, C. et al. (2006). Three-dimensional study of pelvic asymmetry on anatomical specimens and its clinical perspectives. *J Anat*, Vol. 208, Issue 1, pp. 21-33
- Machida, M. et al. (1994). Pathogenesis of idiopathic scoliosis: SEPs in chicken with experimentally induced scoliosis and in patients with idiopathic scoliosis. *J Pediatr Orthop*, Vol. 14, Issue 3, pp. 329-35
- Lafortune, P. et al. (2007). Biomechanical simulations of the scoliotic deformation process in the pinealectomized chicken: a preliminary study. *Scoliosis*, Vol. 2, pp. 16
- Grivas, TB. et al. (2002). The Double Rib Contour Sign (DRCS) in lateral spinal radiographs: aetiologic implications for scoliosis. *Stud Health Technol Inform*, Vol. 88, pp. 38-43
- Grivas, TB. et al. (2006). Intervertebral disc biomechanics in the pathogenesis of idiopathic scoliosis. *Stud Health Technol Inform*, Vol. 123, pp. 80-3
- Grivas, TB. et al. (2008). The role of the intervertebral disc in correction of scoliotic curves. A theoretical model of idiopathic scoliosis pathogenesis. *Stud Health Technol Inform*, Vol. 140, pp. 33-6
- Will, RE. et al. (2009). Cobb angle progression in adolescent scoliosis begins at the intervertebral disc. *Spine*, Vol. 34, Issue 25, pp. 2782-6
- King, HA.; Moe, JH. & Winter, RB. (1983). Adolescent idiopathic scoliosis: a new classification to determine extent of spinal arthrodesis. *J Bone Joint Surg Am* , Vol. 65, Issue 9, pp. 1302-13

- Lenke, LG.; et al. (2001). The selection of fusion levels in thoracic idiopathic scoliosis. *J Bone Joint Surg Am*, Vol. 83-A, Issue 8, pp.1169-81
- Stagnara, P.; Fauchet, R. & du Peloux, J. (1965). The plan of choice for the radiologic examination of kyphoscolioses. *Rev Chir Orthop Reparatrice Appar Mot*, Vol. 51, Issue 6, pp. 517-24
- Nash, CL. & Moe, J H. (1969). A Study of Vertebral Rotation. *J. Bone and Joint Surg. Am .*, Vol. 51-A, pp. 223-9
- Patias, P. et al. (2010). A review of the trunk surface metrics used as Scoliosis and other deformities evaluation indices. *Scoliosis*, Vol. 5, pp. 12
- Stokes, IA. (1994). Three-dimensional terminology of spinal deformities. A report presented to the Scoliosis Research Society by the Scoliosis Research Society Working Group a 3D terminology of spinal deformity. *Spine*, Vol. 19, pp. 236-248
- Drerup, B. (1984). Principles of measurement of vertebral rotation from frontal projections of the pedicles. *J Biomechanics*, Vol. 17, pp. 932-5
- Perdriolle, R. & Vidal J. (1987). Morphology of scoliosis: three-dimensional evolution. *Orthopaedics*, Vol. 10, Issue 6, pp. 909-15
- Lam, GC. et al. (2008). Vertebral rotation measurement: a summary and comparison of common radiographic and CT methods. *Scoliosis*, Vol. 3, pp. 16
- Hecquet, J.; Legaye, J. & Duval-Beaupère, G. (1998). Access to a three-dimensional measure of vertebral axial rotation. *Eur Spine J*, Vol. 7, Issue 3, pp. 206-11
- Doi, T. et al. (2011) A new method for measuring torsional deformity in scoliosis. *Scoliosis*, Vol. 6, pp. 7
- Mitton, D. et al. (2000). 3D reconstruction method from biplanar radiography using non-stereocorresponding points and elastic deformable meshes. *Med Biol Eng Comput*, Vol. 38, pp. 133-9
- Mitulescu, A. et al. (2011). Validation of the non-stereo corresponding points stereoradiographic 3D reconstruction technique. *Med Biol Eng Comput*, Vol. 39, Issue 2, pp. 152-8
- Pomero, V. et l. (2004). Fast accurate stereoradiographic 3D-reconstruction of the spine using a combined geometric and statistic model. *Clin Biomech*, Vol. 19, pp. 240-7
- Blanchard, B. & Elbaroudi, F. (2008). Imaging process for a computerized three-dimensional reconstruction from two-dimensional radiographic images; device implementation. Patent WO 2008/012479 (A1). France: Axs Ingenierie (Fr)
- Dumas, R. et al. (2008). A semi-automated method using interpolation and optimisation for the 3D reconstruction of the spine by bi-planar radiography: a precision and accuracy study. *Med Bio Eng Comput*, Vol. 46, pp. 85-92
- Labelle, H. et al. (1995). Variability of geometric measurements from three-dimensional reconstructions of scoliotic spines and rib cages. *Eur Spine J*, Vol. 4, pp. 88-94
- Dumas, R. et al. (2004). Validation of relative 3D orientation of vertebrae reconstructed by bi-planar radiography. *Medical Engineering and physics*, Vol. 26, pp. 415-22.
- Bellefleur, C. et al. (2002). Evaluation of the efficiency of patient stabilization devices for 3D X-ray reconstruction of the spine and rib cage. *Stud Health Technol Inform (IOS Press)* Vol. 88, pp. 127-31
- Legaye, J. et al. (2009). Correction for patient sway in radiographic biplanar imaging for three-dimensional reconstruction of the spine: in vitro study of a new method. *Acta Radiol*, Vol. 50, Issue 7, pp. 781-90

- Dubousset, J. et al. (2008). Skeletal and spinal imaging with EOS system. *Arch Pediatr.*, Vol. 15, Issue 5, pp. 665-6
- Nault, ML. et al. (2002). Relations between standing stability and body posture parameters in adolescent idiopathic scoliosis. *Spine*, Vol. 27, Issue 17, pp. 1911-17
- Pazos, V. et al. (2007). Reliability of trunk shape measurements based on 3-D surface Reconstructions. *Eur Spine*, Vol. 16, Issue 11, pp. 1882-91
- Denton, T.; Randall, F. & Deinlein, D. (1992) The use of instant Moiré Photographs to reduce exposure from scoliosis radiographs. *Spine*, Vol. 17, Issue 5, pp. 509-12
- Turner-Smith, A. & Harris, JD. (1984). ISIS - An automated shape measurement and analysis System. In *Proc of 3rd Int Symposium on Surface Topography and Spinal Deformity*,. Edited by Harris JD, Turner-Smith AR. Oxford, Gustav Fischer, Verlag;. ISBN 3-437-10962-6 Sept. 27-28, pp. 31-28
- Turner-Smith, A. (1988). A television/computer three-dimensional surface shape measurement system. *J Biomech*, Vol. 21, Issue 6, pp. 515-29
- Weisz, I. et al. (1988). ISIS scanning: a useful assessment technique in the management of scoliosis. *Spine*, Vol. 13, Issue 4, pp. 405-8
- Theologis, T. et al. (1997). Early Detection of Progression in Adolescent Idiopathic Scoliosis by Measurement of Changes in Back Shape With the Integrated Shape Imaging System Scanner. *Spine*, Vol. 22, Issue 11, pp. 1223-7
- Berryman, F. et al. (2008). A new system for measuring 3D back shape in scoliosis. *Eur Spine J*, Vol. 17, pp. 663-72
- Poncet, P. et al. (2000). Reconstruction of laser-scanned 3D torso topography and stereoradiographical spine and rib-cage geometry in scoliosis. *Comp Meth Biomech Biomed Eng*, Vol. 4, pp. 59-75
- Frobin, W. & Hierholzer, E. (1983). Automatic Measurement of body surfaces using rasterstereograph. *Photogrammetric Engineering and Remote Sensing*, Vol. 49, Issue 3, pp. 377-84
- Sahlstrand, T. (1986). The clinical value of Moiré Topography in the management of scoliosis. *Spine*, Vol. 11, Issue 5, pp. 409-417
- Breque, C.; Dupre, JC. & Bremand, F. (2004) Calibration of a system of projection moiré for relief measuring: biomechanical applications. *Optics and Lasers in engineering*, Vol. 41, pp. 241-60
- Goldberg, CJ. et al. (2001). Surface topography, Cobb angles, and cosmetic change in scoliosis. *Spine*, Vol. 26, Issue 4, pp. 55-63
- Bunnell, WP. (2005). Selective screening for scoliosis. *Clin Orthop Relat Res*, Vol. 434, pp. 40-5
- Graf, H.; Hecquet, J. & Dubousset, J. (1983). 3-dimensional approach to spinal deformities: application to the study of the prognosis of pediatric scoliosis. *Rev Chir Orthop*, Vol. 69, pp. 407-16
- Kohashi, Y.; Oga, M. & Sugioka, Y. (1996) A new method using top view of the spine to predict the progression of curves in idiopathic scoliosis during growth. *Spine*, Vol. 21, pp. 212-17
- Duval-Beaupère, G. et al. (1998). Pelvic incidence: a fundamental parameter for three-dimensional regulation of spinal sagittal curves. *Eur Spine J*, Vol. 7, pp. 99-103
- Duval-Beaupère, G.; Schmidt, C. & Cosson, P. (1992). A Barycentremetric study of the sagittal shape of spine and pelvis: the conditions required for an economic standing position. *Ann Biomed Eng*, Vol. 20, Issue 4, pp. 451-62

- Legaye, J. & Duval-Beaupere, G. (2008) Gravitational forces and sagittal shape of the spine. Clinical estimation of their relations. *Int Orthop.*, Vol. 32, Issue 6, pp. 809-16
- Harrington, P. (1962) Treatment of scoliosis. Correction and internal fixation by spine instrumentation. *J Bone Joint Surg*, Vol. 44-A, pp. 591-610
- Cotrel, Y.; Dubousset, J. & Guillaumat, M. (1988) New universal instrumentation in spinal surgery. *Clin Orthop*, Vol. 227, pp. 10-23
- Lee, S.M.; Suk, S.I. & Ching, E.R. (2004). Direct vertebral rotation: a new technique of three-dimensional deformity correction with segmental pedicle screw fixation in adolescent idiopathic scoliosis. *Spine*, Vol. 29, pp. 343-9
- Steib, J.P.; Dumas, R. & Mitton, D. (2004) Surgical correction of scoliosis by in situ contouring: a detorsion analysis. *Spine*, Vol. 29, pp. 193-9
- Dumas, R. et al. (2003) Three-dimensional quantitative segmental analysis of scoliosis corrected by the in situ contouring technique. *Spine*, Vol. 28, pp. 1158-62
- Fassier, A. et al. (2007) Preliminary study of the relation between the external surface of the trunk and the internal structure of the spine in the scoliosis of the child. *Rev Chir Orthop*, Vol 93, pp. 396-7

IntechOpen



Recent Advances in Scoliosis

Edited by Dr Theodoros Grivas

ISBN 978-953-51-0595-4

Hard cover, 344 pages

Publisher InTech

Published online 09, May, 2012

Published in print edition May, 2012

This book contains information on recent advances in aetiology and pathogenesis of idiopathic scoliosis, for the assessment of this condition before treatment and during the follow-up, making a note of emerging technology and analytical techniques like virtual anatomy by 3-D MRI/CT, quantitative MRI and Moire Topography. Some new trends in conservative treatment and the long term outcome and complications of surgical treatment are described. Issues like health related quality of life, psychological aspects of scoliosis treatment and the very important "patient's perspective" are also discussed. Finally two chapters tapping the untreated early onset scoliosis and the congenital kyphoscoliosis due to hemivertebra are included. It must be emphasized that knowledgeable authors with their contributions share their experience and enthusiasm with peers interested in scoliosis.

How to reference

In order to correctly reference this scholarly work, feel free to copy and paste the following:

Jean Legaye (2012). Three-Dimensional Assessment of the Scoliosis, Recent Advances in Scoliosis, Dr Theodoros Grivas (Ed.), ISBN: 978-953-51-0595-4, InTech, Available from:
<http://www.intechopen.com/books/recent-advances-in-scoliosis/three-dimensional-assessment-of-the-spine-in-scoliosis>

INTECH
open science | open minds

InTech Europe

University Campus STeP Ri
Slavka Krautzeka 83/A
51000 Rijeka, Croatia
Phone: +385 (51) 770 447
Fax: +385 (51) 686 166
www.intechopen.com

InTech China

Unit 405, Office Block, Hotel Equatorial Shanghai
No.65, Yan An Road (West), Shanghai, 200040, China
中国上海市延安西路65号上海国际贵都大饭店办公楼405单元
Phone: +86-21-62489820
Fax: +86-21-62489821

© 2012 The Author(s). Licensee IntechOpen. This is an open access article distributed under the terms of the [Creative Commons Attribution 3.0 License](#), which permits unrestricted use, distribution, and reproduction in any medium, provided the original work is properly cited.

IntechOpen

IntechOpen