

We are IntechOpen, the world's leading publisher of Open Access books Built by scientists, for scientists

6,900

Open access books available

185,000

International authors and editors

200M

Downloads

Our authors are among the

154

Countries delivered to

TOP 1%

most cited scientists

12.2%

Contributors from top 500 universities



WEB OF SCIENCE™

Selection of our books indexed in the Book Citation Index
in Web of Science™ Core Collection (BKCI)

Interested in publishing with us?
Contact book.department@intechopen.com

Numbers displayed above are based on latest data collected.
For more information visit www.intechopen.com



Ritscher – Schinzel Syndrome – 3C (Cranio-Cerebello-Cardiac) Syndrome: Case Report

Sibila Nankovic, Sanja Hajnsek, Zeljka Petelin,
Andreja Bujan Kovac and Vlatko Sulentic
*University Department of Neurology, School of Medicine,
Zagreb University Hospital Centre,
Referral Centre for Epilepsy of the Ministry of Health
and Social Welfare of the Republic of Croatia
Croatia*

1. Introduction

Ritscher-Schinzel syndrome was first described 1987, in the case of two sisters of healthy parents who have had posterior fossa malformations, congenital heart defects and craniofacial anomalies (5). It is believed that this is an autosomal recessive hereditary disorder. So far, according to ORD data (Office of Rare Disease of the National Institutes of Health), only about 30 cases are reported all over the world, mostly from North America and Europe, mostly in the age of 6 and the oldest patient was 21 years old. In 2001, Leonardi et al. proposed criteria for the diagnosis of 3C ("Cranio-cerebello-cardiac") syndrome in a chromosomally normal sporadic cases - Table 1 (3). Clinically the disorder consists of: 1. various forms of craniofacial anomalies, as well as skeletal malformations of other parts, including cleft palate, ocular coloboma, prominent forehead or occiput, hypertelorism, depressed nasal bridge, micrognathia, down-slanting palpebral fissurae; 2. cardiac malformations (ventricular or atrial septal defect, tetralogy of Fallot, hypoplastic left heart, aortic or pulmonary stenosis, and other forms of valvular anomalies), 3. anomalies of the central nervous system, including Dandy-Walker malformation, vermis hypoplasia and enlargement or posterior fossa cyst. Criteria to establish certain diagnosis include presence of a cardiac malformation, described malformations of posterior cranial fossa, cleft palate or ocular coloboma or 4 of these other forms of craniofacial anomalies previously mentioned.

2. Case report

We report on a patient E.K. born in 1972, who soon after his birth underwent surgery for cleft soft palate, and in 1996 because of ventricular septal defect. At the age of 20 he was diagnosed with thoracic spine scoliosis and received physical therapy, but no surgery was performed. From year 1989 he has been treated for epilepsy, with clinical phenotype of grand mal seizures and with signs of psychomotor retardation. CT scan of the brain made in 2008 showed a Dandy-Walker malformation. In March 2009 he was hospitalized in University Hospital Centre Zagreb, University Department of Neurology, for frequent seizures despite regular antiepileptic barbiturates therapy (MPB). The clinical examination showed

Craniofacial malformation: Low-set ears Hypertelorism Down-santing palpebral fissures Depressed nasal bridge Prominent occiput Cleft palate Micrognathia Ocular coloboma Cleft lip and palate	 58% 50% 40% 36% 30% 25% 22% 21% 4%
Cardiac malformation: Septal defects Valvular defects Cono-truncal anomalies	 82% 32% 14%
Cerebellar malformation: Dandy-Walker Dandy-Walker Variant Hydrocephalus	 68% 21% 11%
Other malformations noted in less than 10⁰% of the patients: Absent ribs Adrenal hypoplasia Anal atresia Congenital glaucoma Cutis aplasia Hemangioma Hemivertebrae Hypospadias Inguinal hernia Malrotation of the gut Nail hypoplasia Nippler hypoplasia Penis hypoplasia Polydactyly Renal malformations	

Table 1. Summary of possible clinical findings and the frequency in patients with Ritscher-Schinzel (3C) syndrome (3)

craniofacial anomalies in terms of prominent forehead, down-slanting palpeberal fissurae, depressed nasal bridge (Figure 1), with syndactyly of 1st and 2nd finger on his right foot (Figure 2), flexural contractures of distal phalanges of 2nd and 3rd finger of both hands and scoliosis of thoracic spine segment. X-ray imaging study of the whole spine have been performed. Images of the cervical spine show proper bone mineralization. Congenital block of vertebral body and articular processes in C6-C7 segment. Reduced intervertebral space in C2-C3 segment. Alordosis with preserved posterior vertebral line. Uncovertebral arthrosis, and with hypoplasia of 1st rib on the right side. Sinistro-convex scoliosis of the thoracis

spine segment. Normal intervertebral space. Imaging of the thoracolumbar transition and lumbosacral spine show normal intervertebral space and normal height and width of vertebral body. Preserved posterior vertebral line.

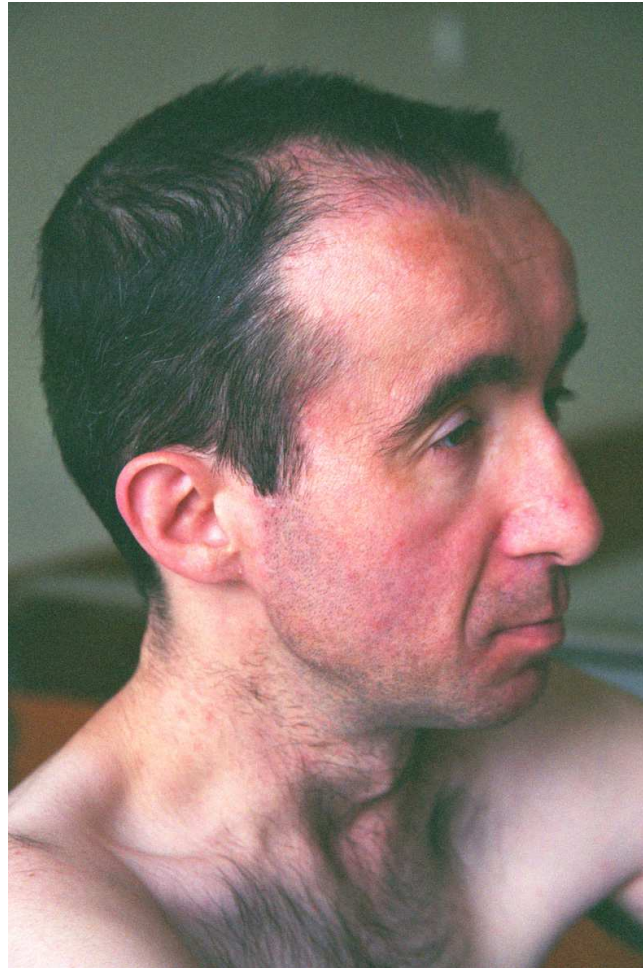


Fig. 1. Craniofacial anomalies: prominent forehead, down-slanting palpebral fissurae, depressed nasal bridge.

MRI of the brain showed Dandy-Walker malformation, enlargement of the cisterna magna because of the posterior fossa cyst and aplasia of the caudal part of the cerebellar vermis, but also bilateral subependymal heterotopia of grey matter (Figure 3-6). EEG showed diffuse dysrhythmic activity with the focus frontotemporobasal left, and with paroxysmic activity and vulnerability on hyperventilation. Visual and auditory evoked potentials were normal. Cardiac ultrasound showed a dilated right heart, with no signs of residual obstruction after resection of the right ventricular ridge, and minor L-D shunt at membranous part of interventricular septum. Abdominal ultrasound displayed in the VI / VII liver segment hyperechogenic zone, 15x9,6 mm in diameter, corresponding liver hemangioma, with other findings were normal. EMNG verified mild chronic lesions in the muscles of the foot. Laboratory analysis was done in terms of multisystem metabolic diseases (lactate /perchlorate in perchloric acid, ammonia, amino acids quantitatively, organic acids, oligosaccharides, mucopolysaccharides excretion, transferrin phenotypes, chitotriosidase) and all findings were proper. Chromosomal analysis showed normal male karyotype.

During hospitalization we have observed two epileptic seizures of a new clinical phenotype, the type of complex partial seizure of the parietal origin (giratory crisis). Antiepileptic therapy was changed and Oxcarbazepine (OXC) was introduced, on which the epileptic manifestations were completely ckupirale. The patient was presented at neurosurgical-neuroradiologic-neurological meeting which concluded that there is no indication for neurosurgical treatment.

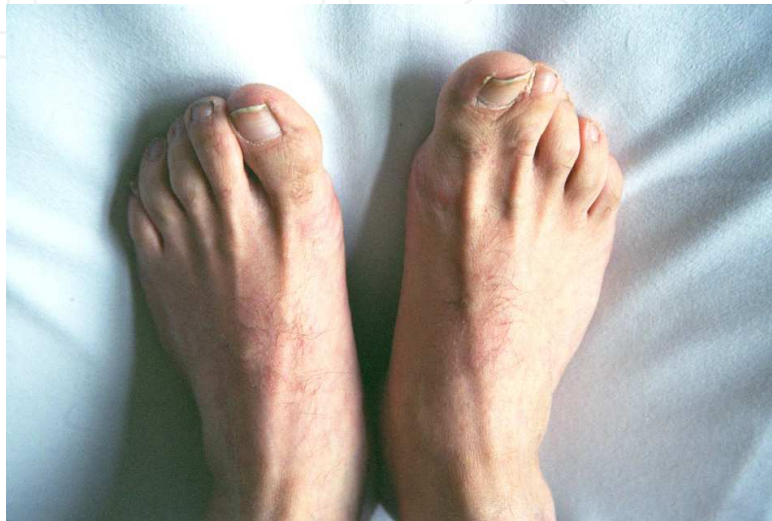

Fig. 2. Complete syndactyly of 1st and 2nd finger of right foot.

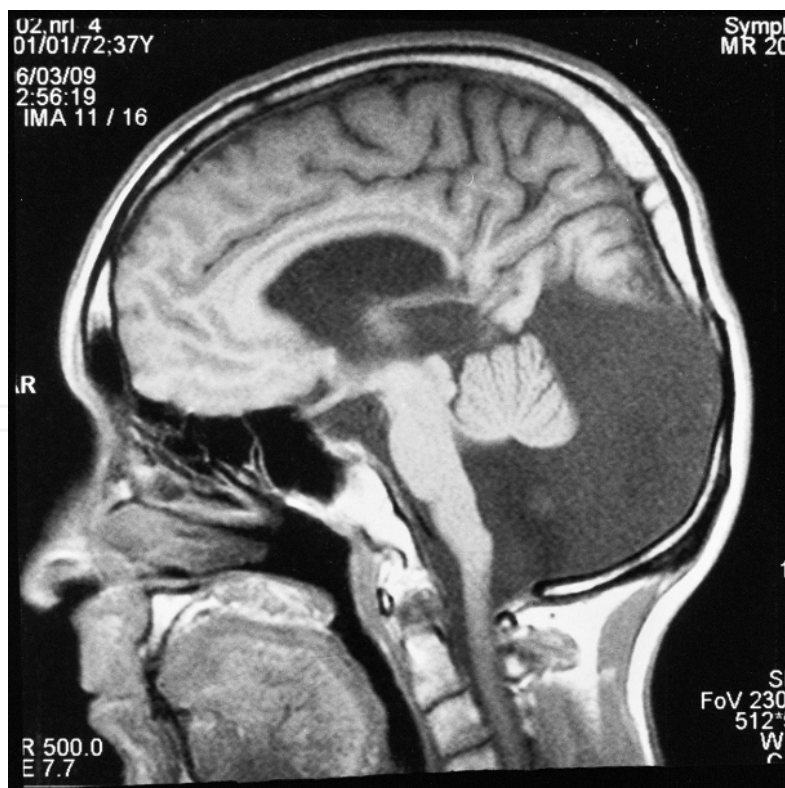


Fig. 3. MRI of the brain: T1-weighted sagittal view shows Dandy-Walker malformation with enlarged posterior fossa because of the cyst, aplasia of the caudal part of the cerebellar vermis, and extensive IV ventricle communication with the cyst.

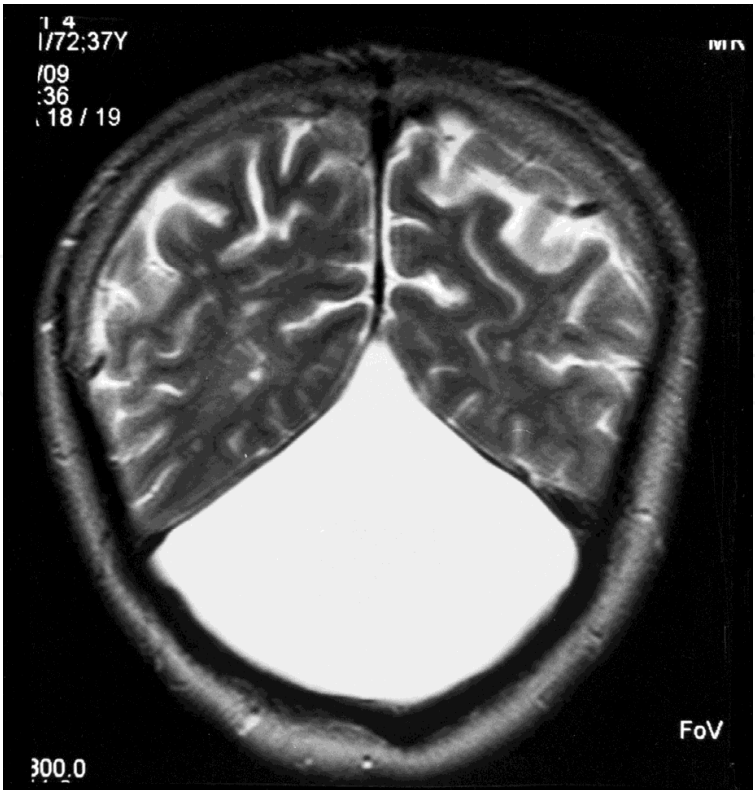

Fig. 4. MRI of the brain: Axial T2-weighted image shows large cystic formation.

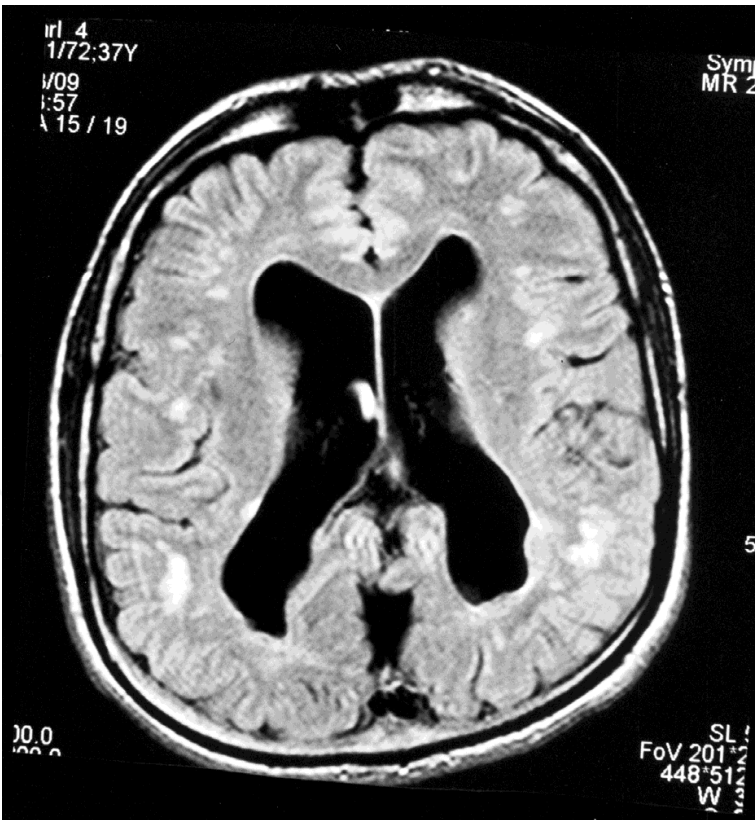


Fig. 5. MRI of the brain: Axial T1-weighted image shows multiple bilateral subependymal heterotopia of grey matter.

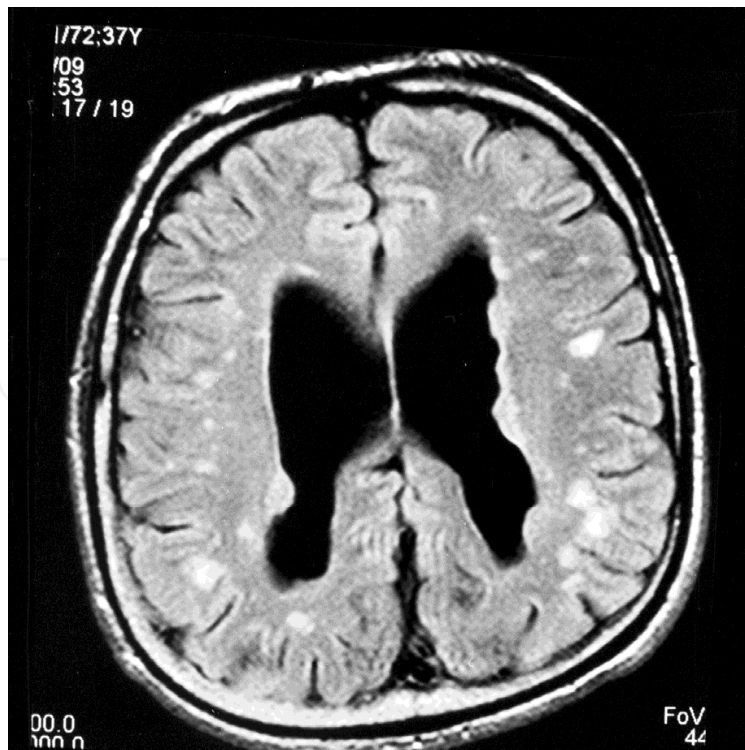


Fig. 6. MRI of the brain: Axial T1-weighted image shows multiple bilateral subependymal heterotopia of grey matter.

3. Discussion

In addition to clinical criteria set by Leonardi et al. (3) other authors present patients associated with other types of malformations. Kosak et al. describe two cases with hypotonia and hypospadias, one had intestinal malrotation with gastroesophageal reflux, and hypoplastic 5th finger of right hand with a cavernous hemangioma on dorsal side and other had scrotal cleft (2). Orstavik et al. describe two patients with anal malformations, in one case there was atresia of the anus with perianal fistula, while the other had anteriorly placed anus. In the third patient there was verified bilateral hydronephrosis (4). Zankl et al. describe a patient with secondary hypogammaglobulinemia due to loss through the gastrointestinal tract and with amelogenesis imperfecta (8). Wheeler et al. in his case describe a patient with deficiency of growth factors and consecutive growth failure at the age of 2, and also the unilateral hearing loss at the age of 6 (7). Several other authors describe presence of malformations of the skeletal muscle system in terms of syndactyly, brachydactyly, hypoplastic ribs, short neck, hemivertebrae and nail hypoplasia (1, 2, 3, 7). DeScipio et al., following a molecular and cytogenetic analysis in three families, verified subtelomeric deletion of chromosome 6p, and in one family also a duplication of chromosome 16q23, and as the three major genes that could be responsible for the disease stated FOXF1 and FOXQ1 and FOXC1 gene (1). Expression of these genes could result in different clinically presentation including malformations of the musculoskeletal system such as hemivertebrae, but no cases of scoliosis in patient with „3C“ Syndrome has yet been reported.

Our patients was clinically presented with the following findings:

- a. from the cranial malformations: down-slanting palpebral fissurae, depressed nasal bridge, prominent forehead, operated cleft palate;
- b. from the heart malformations: operated ventricular septal defect with a small residual shunt at membranous part of interventricular septum;
- c. from the cerebellar malformations: verified Dandy-Walker malformation with bilateral subependymal heterotopia of grey matter;
- d. from other less frequent associated malformations we mention a complete syndactyly of 1st and 2nd finger on his right foot, congenital block of C6-C7 (body and articular processes), sinistro-convex scoliosis of thoracic spine segment, hypoplasia of 1st rib, liver hemangioma and also, what is often described, a mental retardation.

The patient is under regular control of cardiologists and neurologists of the Referral Centre for epilepsy with continuous cardiac and antiepileptic therapy on which is his clinical condition fully satisfactory. Comparing the findings of our patients with the cases described in the literature we believe that all findings necessary for the diagnosis of Ritscher-Schinzel Syndrome (3C) manifested, noting that our patient had additional clinical features, presence subependymal heterotopia of grey matter, complex partial and generalized tonic-clonic epileptic seizures and scoliosis, all clinical presentations that have so far not been described accompanying Ritscher-Schinzel Syndrome.

4. Conclusion

Based on clinical examination, radiological and neuroradiological diagnostic procedures we believe that our patient meets all necessary criteria for the diagnosis of Ritscher-Schinzel syndrome. He is also the first patient who has, apart from criteria, gray matter heterotopia on MRI and epilepsy, and is also the first case described in Croatia, and so far the oldest patient described in the literature.


5. References

- [1] DeScipio C., Schneider L., Young T.L. et al. Subtelomeric deletions of Chromosome 6p: Molecular and Cytogenetic Characterization of Three New Cases With Phenotypic Overlap With Ritscher-Schinzel (3C) Syndrome. *Am J Med Genet* 2005; 134A:3-11.
- [2] Kosaki K, Curry C, Roeder E, Jones K. Ritscher-Schinzel (3C) syndrome: documentation of the phenotype. *Am J Med Genet* 1997;68:421-427.
- [3] Leonardi M, Pai G, Wilkes B, Lebel R. Ritscher-Schinzel cranio-cerebello-cardiac (3C) syndrome: report of four new cases and review. *Am J Med Genet* 2001;102:237-242.
- [4] Orstavik K, Bechensteen A, Fugelseth D, Orderud W. Sibs with Ritscher-Schinzel (3C) syndrome and anal malformations. *Am J Med Genet* 1998;75:300-303.
- [5] Ritscher D, Schinzel A, Boltshauser E et al. Dandy-Walker (like) malformation, atrio-ventricular septal defect and a similar pattern of minor anomalies in 2 sisters: a new syndrome? *Am J Med Genet* 1987;26:481-491.
- [6] Rusnak AJ, Hadfield MJ, Chudley AE et al. Increased nuchal translucency thickness: a potential indicator for Ritscher-Schinzel syndrome. *Fetal Diagn Ther* 2008;24:395-399.

- [7] Wheeler PG, Sadeghi-Nejad A, Elias ER. The 3C syndrome: evolution of the phenotype and growth hormone deficiency. *Am J Med Genet* 1999;87:61-64.
- [8] Zankl A, Gungor T, Schinzel A. Cranio-cerebello-cardiac (3C) syndrome: Follow-up study of the original patient. *Am J Med Genet* 2003;118:55-59.

IntechOpen

IntechOpen



Recent Advances in Scoliosis

Edited by Dr Theodoros Grivas

ISBN 978-953-51-0595-4

Hard cover, 344 pages

Publisher InTech

Published online 09, May, 2012

Published in print edition May, 2012

This book contains information on recent advances in aetiology and pathogenesis of idiopathic scoliosis, for the assessment of this condition before treatment and during the follow-up, making a note of emerging technology and analytical techniques like virtual anatomy by 3-D MRI/CT, quantitative MRI and Moire Topography. Some new trends in conservative treatment and the long term outcome and complications of surgical treatment are described. Issues like health related quality of life, psychological aspects of scoliosis treatment and the very important "patient's perspective" are also discussed. Finally two chapters tapping the untreated early onset scoliosis and the congenital kyphoscoliosis due to hemivertebra are included. It must be emphasized that knowledgeable authors with their contributions share their experience and enthusiasm with peers interested in scoliosis.

How to reference

In order to correctly reference this scholarly work, feel free to copy and paste the following:

Sibila Nankovic, Sanja Hajsek, Zeljka Petelin, Andreja Bujan Kovac and Vlatko Sulentic (2012). Ritscher - Schinzel Syndrome - 3C (Cranio-Cerebello-Cardiac) Syndrome: Case Report, Recent Advances in Scoliosis, Dr Theodoros Grivas (Ed.), ISBN: 978-953-51-0595-4, InTech, Available from:

<http://www.intechopen.com/books/recent-advances-in-scoliosis/ritscher-schinzel-syndrome-3c-cranio-cerebello-cardiac-syndrome-a-first-case-report-in-croatia>

INTECH
open science | open minds

InTech Europe

University Campus STeP Ri
Slavka Krautzeka 83/A
51000 Rijeka, Croatia
Phone: +385 (51) 770 447
Fax: +385 (51) 686 166
www.intechopen.com

InTech China

Unit 405, Office Block, Hotel Equatorial Shanghai
No.65, Yan An Road (West), Shanghai, 200040, China
中国上海市延安西路65号上海国际贵都大饭店办公楼405单元
Phone: +86-21-62489820
Fax: +86-21-62489821

© 2012 The Author(s). Licensee IntechOpen. This is an open access article distributed under the terms of the [Creative Commons Attribution 3.0 License](https://creativecommons.org/licenses/by/3.0/), which permits unrestricted use, distribution, and reproduction in any medium, provided the original work is properly cited.

IntechOpen

IntechOpen