

We are IntechOpen, the world's leading publisher of Open Access books Built by scientists, for scientists

6,900

Open access books available

185,000

International authors and editors

200M

Downloads

Our authors are among the

154

Countries delivered to

TOP 1%

most cited scientists

12.2%

Contributors from top 500 universities



WEB OF SCIENCE™

Selection of our books indexed in the Book Citation Index
in Web of Science™ Core Collection (BKCI)

Interested in publishing with us?
Contact book.department@intechopen.com

Numbers displayed above are based on latest data collected.
For more information visit www.intechopen.com



GISTs: From the History to the Tailored Therapy

Roberta Zappacosta, Barbara Zappacosta, Serena Capanna,
Chiara D'Angelo, Daniela Gatta and Sandra Rosini
*Oncology and Experimental Medicine Department, Cytopathology Unit,
G. d'Annunzio University of Chieti-Pescara
Italy*

1. Introduction

Gastrointestinal stromal tumours (GISTs) represent the most common non-epithelial mesenchymal tumours of the gastrointestinal tract. The role of the pathologist in the differential diagnosis of GISTs, as well as the correct understanding of these neoplasia by detailed clinicopathologic, biological and genetic studies, are becoming increasingly important in optimizing the management of these tumours and to develop new therapies for the treatment of advanced diseases.

2. Historical overview

At the beginning there were more misunderstandings about GIST. On the basis of light microscopic descriptions and until 1960, Gastrointestinal Stromal Tumors (GISTs) were thought to be neoplasms of smooth muscle origin; so they were classified as leiomyoma, leiomyosarcoma or leiomyoblastoma, in one word STUMP (Smooth-muscle Tumors of Undetermined malignant Potential). In the early 1970s, electron microscopic studies revealed inconsistent evidence of smooth muscle differentiation. During '80s, this data was supported by the application of immunohistochemical studies, which showed that the expression of muscle markers (such as actins and desmins) was far more variable than those observed in smooth muscle tumors arising from the myometrium. Immunohistochemistry also demonstrated the existence of a subset of stromal neoplasia having neural crest immunophenotype (S100- and neuron-specific enolase - NSE-positivity) which has not been found in other smooth muscle neoplasms. These findings switched on a long-standing debate about the real origin and nature of mesenchymal tumors arising within the gut wall. In 1983, Mazur and Clark postulated the derivation of these "stromal tumors" from mesenchymal stem element, considered to be the progenitor of both spindle and epithelioid cells, and showing CD34 positivity. In 90s, it began to refer to "GISTs" to collectively designate a group of mesenchymal tumours with miogenic or neurogenic differentiation, arising from gastrointestinal tract, separate from stromal tumors taking place of other sites (e.g. uterus). The observation of both smooth muscle characteristics and neural features in GISTs, led to the conclusion that these tumour would be related to a little population of spindle cells placed in the gut wall. So, in 1998 Kindblom et al, definitively defined the origin of GISTs from a pluripotential stem cell, programmed to differentiate into either

Interstitial Cajal Cell (ICC) and smooth muscle cells. They represent ICCs as a network of cellular elements, intercalated between nerve fibres and muscle cells, involved in the generation of gut contraction (Figure 1).

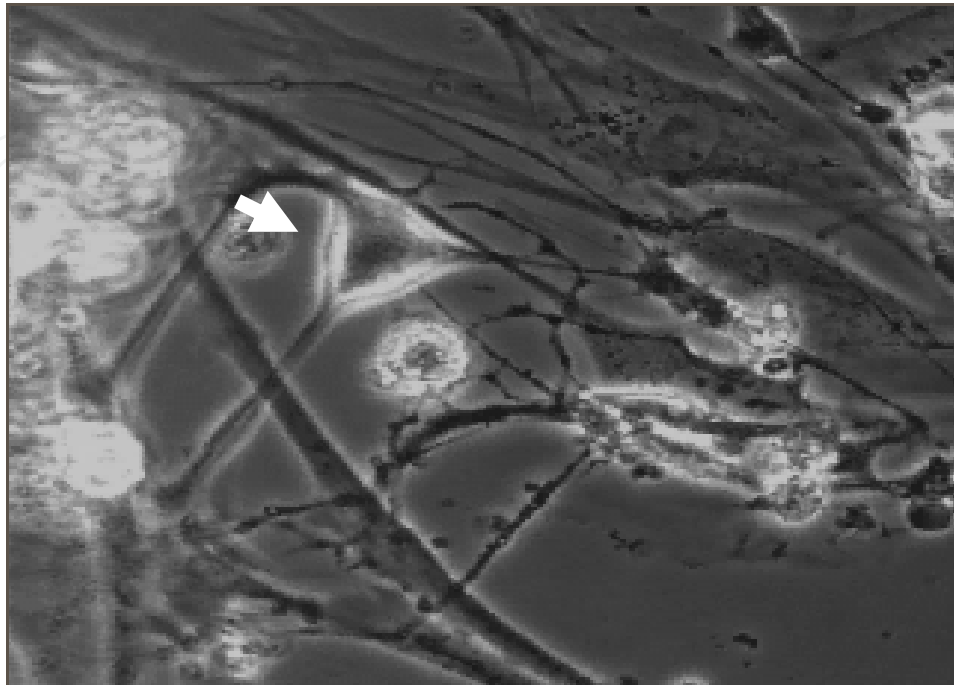


Fig. 1. Cajal cell (arrow) within gastrointestinal wall

Successive studies performed on ICCs demonstrated their growth depending on stem cell factor signalling through KIT tyrosine kinase (CD117) (Isozaki et al., 1995). In 1998, publications by Hirota et al., and Kindblom et al., announced to scientific community the expression of CD117 on GISTs (Kindblom et al., 1998; Miettinen et al., 2005).

Starting from this point, Ogasawara et al. assigned to *c-kit* mutation of ICC an early causal role in GIST tumorigenesis and Agaimy et al. defined GIST as the grossly identifiable counterpart of sporadic ICC hyperplasia.

In subsequent years and to these days, all the previous observations led to the correct classification of GISTs (CD117-positive) as a separate entity from smooth muscle neoplasia (CD117-negative) and to the development of a target-therapy for this disease.

3. *c-kit* gene, KIT receptor and kit mutations

The *c-kit* gene is the cellular homologue of the oncogene *v-kit* of HZ4 feline sarcoma virus, encoding a type III receptor protein-tyrosine kinase (KIT). The type III class of receptors also includes the platelet-derived growth factor receptors, α and β -chain (PDGFR α , PDGFR β), the macrophage colony-stimulating factor (M-CSF) receptor and the Flt3 cytokine receptor (Flt3). All protein-tyrosine kinase receptors share the same topology: an extracellular ligand-binding domain, made up five immunoglobulin-like repeats, a single transmembrane sequence, a juxtamembrane domain, that is considered to be significant for regulation of KIT dimerization and in the inhibition of kinase activity, and a cytoplasmic kinase domain (Figure 2). The structure and amino-acid sequence of KIT is well preserved in humans, mice and rats.

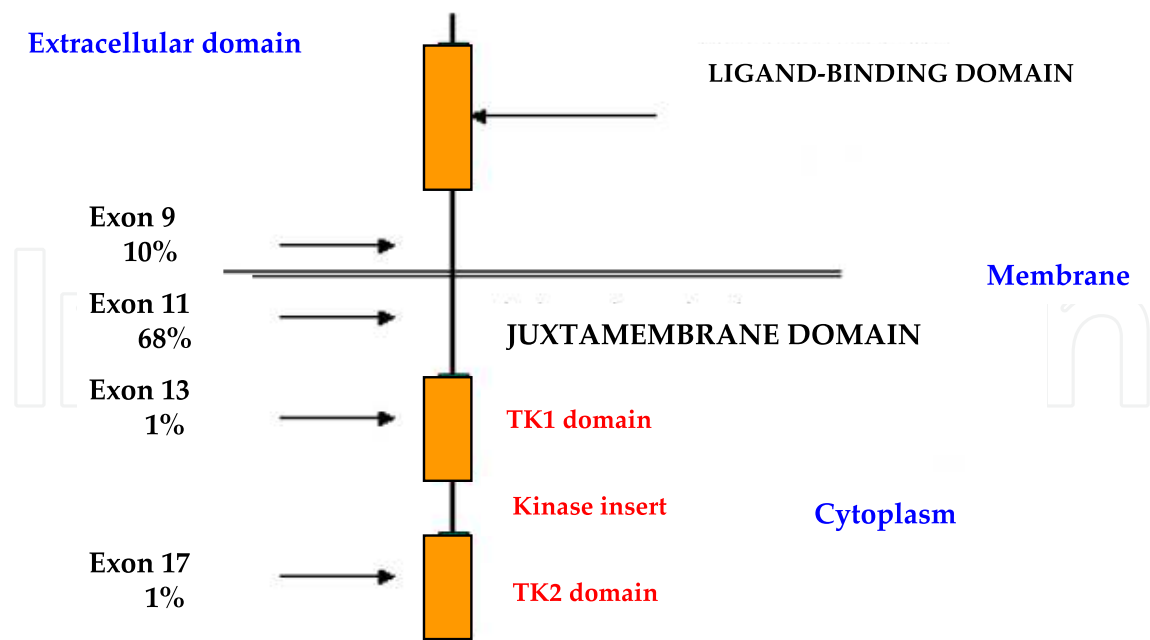


Fig. 2. KIT receptor structure and distribution of KIT mutations

The ligand for KIT is named Stem Cell Factor (SCF); it binds to the second and third immunoglobulin domains, playing the fourth domain a role in receptor dimerization (Zhang et al., 2000). Two molecules of wild-type KIT form a dimer by binding two molecules of SCF; dimerization leads to autophosphorylation of KIT on tyrosine kinase domain and to activation of protein kinase activity through several signal transduction systems, such as phosphatidylinositol 3-kinase (PI3K)/Akt pathway, Ras/mitogen activated protein kinase (MAPK) pathway and jak/STAT pathway (Huizinga et al., 1995; Ullrich et al., 1990). The activation of PI3K/Akt pathway may explain in part how activating mutations of KIT participate in neoplastic transformation.

By the induction of cell proliferation and differentiation, KIT is important in erythropoiesis, lymphopoiesis, mast cell development and functions, megakaryocytopoiesis, gametogenesis and melanogenesis (Rönstrand, 2004).

In the absence of SCF, KIT exists in a monomeric dormant state. The mechanism for the activation of dormant KIT involves binding of the appropriate ligand to the extracellular domain of two receptor monomers; this connection produces a receptor dimer. SCF also exists as a non-covalent dimer, which binds to two KIT monomers, thereby promoting KIT dimer formation (Zhang et al., 2000).

In 1988, c-kit gene was founded at the W locus of mouse chromosome 5. The W locus of mice encodes KIT. Many types of loss-of-function mutants have been reported at the W locus. The W mutant allele is a point mutation at the tyrosine kinase (TK) domain, resulting in a dramatic decreasing of TK activity. Heterozygotic W-wild/W-mutated mice show five abnormalities due to the loss of KIT function: 1) anemia, due to hypoproduction of erythrocytes; 2) white coat colour, due to the lack of melanocytes; 3) sterility, due to the depletion of germ cells; 4) depletion of mast cells; 5) depletion of ICCs.

Molecular analyses of the c-kit gene in W mutants facilitated the understanding of the in vivo function of KIT (Hayashi et al., 1991). In 1992, Maeda et al., analyzing c-kit expression in phenotypically normal mouse tissues, demonstrated c-kit expression in healthy mouse.

Particularly, they showed the presence of KIT-positive cells in GI muscular layers, especially in the myenteric plexus layer. Distribution of KIT-positive cells seemed similar to that of ICC cells.

Subsequently, many types of loss-of-function mutant mice have reported at the W locus. Myenteric plexus ICCs fail to develop in mice which are deficient in expression of the KIT tyrosine kinase receptor or in its ligand SCF, indicating that the KIT-SCF axis is essential for the development of these cells. *W* mutant mice, who had deficiency of KIT-positive cells, also had disturbed GI movements, including bile reflux to stomach. These results unequivocally demonstrated that ICC are KIT-positive and that pacemaker of GI movement is KIT-dependent (Maeda H et al., 1992). Actually, it is well known that loss-of-function mutations of KIT also result in mast cells depletion.

In >80% of GISTs, mutation in the c-kit gene leads to KIT constitutive activation (gain-of-function mutation). Activating KIT mutations occur in the extracellular, in the juxtamembrane and in the proximal and distal protein kinase domains (Table 1), and more often consist in single oligonucleotide substitution in exon 11. The penetrance appears to be high.

Since KIT plays an essential role in development of melanocytes and mast cells, most individuals with exon 11 mutations may also develop mast cell disease, as well as hyperpigmentation of perineal, perioral and digital skin area. This fact does not occur for patients with a KIT exon 13 or 17 mutations, suggesting that there are differences in signalling requirements for mast cells neoplasia as compared with GISTs.

Tumor type	Location of mutation in KIT
GIST	Extracellular domain
Mast cell leukemia	JM segment
Germ-cell tumor	JM segment
Mastocytosis	JM segment
GIST	Proximal kinase domain
Germ-cell tumor, GIST, mastocytosis	Activation loop
Germ-cell tumor, GIST	Activation loop
Seminoma	Activation loop
T-cell lymphomas	Activation loop

Table 1. Oncogenic gain-of-function KIT mutations, in human

The most common mutations in KIT affect the juxtamembrane domain encoding exon 11. Two-third of GISTs harbour an inframe deletion, insertion, substitution or combination of this exon (Figure 1), while approximately 10% of these neoplasia have a mutation in an extracellular domain encoded by exon 9. Rarely, mutations occur in the kinase I (exon 13) and kinase II (exon 17) domains.

In human mast cell leukemia cell line HMC-1, KIT is constitutively phosphorylated in kinase domain, activated and then associated with PI3K without the addition of SCF. c-kit gene of HMC-1 cells is composed of normal-wild-type allele and of mutant allele having point mutations which result in the substitution of Val-560 to Gly in juxtamembrane domain, and Asp-816 to Val in tyrosine kinase domain.

In a transfected cells model, KIT with either mutations is phosphorylated on tyrosine and activates without the addition of SCF. The mechanisms of constitutive activation are different in the cases of Val to Gly and Asp to Val. A substantial fraction of phosphorylated

KIT with Val to Gly mutation dimerizes, whereas phosphorylated KIT with Asp to Val mutation does not (Feritsu et al., 1993).

In general, tumors are heterozygous for a given mutation, but loss of the remaining wild-type KIT allele occurs in about 8-15% of tumors; in these cases, there would be a strict association with a wrong prognosis (Corless & Heinrich, 2008). In a subset of GISTs which are wild-type, a high proportion have mutations in either exon 12 or 18 of the platelet-derived growth factor alpha (PDGF α) gene. PDGF α substitution in exon 18 is only found in GISTs arising in the stomach, mesentery and omentum.

The importance of KIT mutation in GISTs development is sustained by numerous evidences. First, when expressed in transfected cell lines, mutant form of KIT show constitutive kinase activity in the absence of SCF (Hirota et al., 1998). Second, mutant KIT is oncogenic (Hirota et al., 1998). Third, phosphorylated KIT is detectable in GIST. Fourth, patients with hereditary mutations are at high risk for the development of multiple GISTs. Fifth, mice engineered to express mutant KIT shows ICC cell hyperplasia and develops stromal tumors resembling human GISTs (Rubin et al., 2005).

4. Interstitial cells of Cajal (ICC) and GISTs

ICCs were firstly described by Santiago Ramon y Cajal in 1883, as special cells distinct from ordinal neurons, forming a network in the GI wall of the Guinea pigs (Cajal, 1883). ICC act as the “pacemaker” cell of the gut and serve as intermediaries between the GI autonomic nervous system and smooth cells, to regulate GI motility and coordinate peristalsis. Although location and density of ICCs vary in different portion of GI tract, the largest density of these cells occurs around the myenteric plexus, with extension between intramural neurons and smooth muscular cells of the circular and longitudinal layers of the muscularis propria.

ICCs are classified into several subtypes by anatomical localization; moreover, a subset of ICCs are known to mediate neural transmission. In this context, ICCs are considered to play different roles. Cajal et al., estimated that ICCs were primitive neurons. Actually it's well known that ICCs would derive from a common precursor that yields ICC and smooth muscle cells, but not neurons (Torihashi et al., 1997).

As previously described, KIT was reported to be expressed by these cells; in fact, ICC requires the SCF-KIT system for its development. Loss-of-function mutation of KIT results in depletion of ICCs. Conversely, gain-of-function mutation might induce ICCs neoplasms. Normal ICCs as well as ICCs neoplasia express CD117. Since leiomyomas and schwannomas did not express KIT, but most tumors designated as GISTs did express it, it has been postulate the origin of GISTs from ICCs.

Although more than 90% of GISTs harbour a specific *c-kit* gene mutation, and approximately 85% of GISTs have mutations in either KIT or PDGF α receptors, recent molecular studies defined a subset of gastrointestinal stromal tumors which are clearly KIT- and PDGF α -negative (*kit* wild type [*kit*-WT]) (Corless et al., 2002).

About 12% of the stromal gastrointestinal tumors lack a KIT mutation. Heinrich et al., investigating the cause of GISTs without KIT mutation and using Western blotting analysis based on a cocktail of antibodies to epitopes pooled by a broad range of tyrosine kinases receptors, revealed a gain-of-function mutations of PDGF α receptor in about one-third of GISTs (Heinrich et al., 2003). Mutated PDGF α receptor activates not only itself, but also wild-type KIT. Since the signal transduction pathway of PDGF α receptor is similar to that of

KIT, gain-of-function mutation of PDGF α receptor by itself may cause transformation of ICCs.

When compared with kit-positive GISTs, kit-WT tumors are more likely to arise in the omentum/peritoneal surface and stomach whereas GISTs kit-positive occurred predominantly in the small bowel. The presence of KIT mutation in GISTs has been correlated with survival of patients. Survival seems better in patients without KIT mutation than in patients without KIT mutation (Taniguchi et al., 1999). Among mutant GISTs, comparative studies indicated different pharmacological responsiveness to the kinase inhibitor *imatinib*.

It is now widely accepted that mutations of other genes are also necessary for GIST to emerge from a background of ICC hyperplasia. Particularly, some tumor suppressor genes which are closely correlated with tumorigenesis, have been found to harbour abnormalities in GISTs. Recently, functional inactivation of p16^{INK4a} gene transcript on 9p21 locus, via mutation, deletion, or promoter hypermethylation, causing loss or down-regulation of the corresponding protein, has been identified as an independent unfavourable prognostic factor in GISTs (Ricci et al., 2004; Sabah et al., 2004; Schneider et al., 2003; Scheneider-Stock et al., 2005).

p16^{INK4a} is one of the two alternative transcripts of the cyclin-dependent kinase inhibitor 2A (CDKN2A) gene. The other transcript is p14^{ARF}. The CDKN2A gene, with its two transcripts, is an important tumor suppressor gene, with a central role in the control of cell proliferation and apoptosis (Sherr, 2001). Haller et al. examined the relevance of the CDKN2A tumor suppressor pathway in GISTs and found that the low mRNA expression of the CDKN2A transcript p16^{INK4a}, was associated with more aggressive clinical behaviour and adverse prognosis (Haller et al., 2005).

Recently, additional insight on the biology of GISTs has recently been gained through gene microarray studies. These studies identified a number of genes whose expression is relatively increased if compared to that of other soft tissue tumors. Many genes have not been well characterized yet. Among these a GIST-specific gene, encoding for FLJ10261 protein, has been named "Discovered on GIST 1" (DOG1).

DOG1 has been recently identified as a gene on human chromosome 11q13, which is amplified in esophageal cancer, bladder tumors, and breast cancer. Using immunohistochemistry and *in situ* hybridization technology with *DOG1*-specific probes, West et al., (West et al., 2004) showed *DOG1* overexpression in both KIT and PDGFR α GISTs.

Because their biological function is still unknown, it is unclear why *DOG1* is so widely expressed in GISTs. Two possibilities would exist. First, *DOG1* might have a role in receptor kinase signal transduction pathways; second, it may be a fortuitous marker of the GIST phenotype, with no direct connection to the KIT and PDGFR α signaling pathways. The finding that mast cells are also immunoreactive for *DOG1* tends to favour the former possibility (West et al., 2004). In this context, *DOG1* would be considered a potential alternative therapeutic target.

p27 cell cycle inhibitor seems to be downregulated in malignant GISTs; cycle regulatory proteins (cyclins B1, D and E, cdc2, CDK2, CDK4 and CDK6), p53, pRb and cyclinA have been found to be upregulated in high-risk GISTs. The above mentioned molecules have been proposed as immunohistochemical target of high-risk gastrointestinal stromal tumors molecular (Romeo et al., 2009).

In addition to the above mentioned markers, an increasing list of prognostic factors have been reported: Ezrin, Raf kinase inhibitor protein, COX-2, bcl-2, CA II (Romeo et al. 2009). However standardized protocols for interpretation of these markers have not been established yet.

5. GISTs epidemiology and clinical presentation

Mesenchymal tumors of GI tract are divided into two main groups: 1) tumors which are histologically identical to their soft tissue counterpart (e.g., lipomas, leiomyomas etc.); 2) gastrointestinal stromal tumors, which represent approximately 1% of all primitive tumors, 0.1-3% of all gastrointestinal neoplasia and are, at the same time, the most frequent mesenchymal lesions of gastrointestinal tract. GISTs have distinctive histologic and clinical features that vary according to their primary site of origin.

The exact incidence of GIST in USA and in Europe is hard to determine, since GISTs have only been recognized and diagnosed as a separate entity since the late 1990s. Recent population-based studies performed in Sweden (Nilsson et al., 2005), Holland (Goettsch et al., 2005) found incidences of approximately 14.5 and 12.7 cases/million/year, respectively. These findings would translate into an annual incidence in Europe of about 8,000-9,000 cases and in USA of about 5,000 new cases per year. They are frankly malignant in 10-30% of cases and are responsible for cancer mortality in 2% of cases. Sporadic GIST has no clear gender preference; at the time of diagnosis, the majority of patients with GISTs are between 40 and 80 years old, with a median age of 60 years.

GISTs can develop in any part of the digestive system, from the oesophagus to the rectum. They arise predominantly in the stomach (60%), jejunum and ileum (30%), duodenum (5%), and colon-rectum (<5%). Very few cases have been described in the oesophagus and appendix (<5%) (Miettinen et al., 2006). Tumors lacking any association with the bowel wall (omental, retroperitoneal and mesenteric localizations) are known as Extra Gastrointestinal Stromal Tumor (EGIST). Mesentery or omentum lack the ICCs; this fact confirms GIST's origin from these cells.

Most gastrointestinal stromal tumors occur sporadically, and present themselves as solitary lesions.

GISTs have a predominant exophytic growth, along the gastrointestinal tract and frequently protrude into the abdominal cavity. In smaller neoplasia, the mucous membrane is frequently intact, and the muscle layer of the mucosa seems to be coalescent with the muscular layer; in other cases, tumor may compress the muscular layer, from which it is delimited by a thicker collagen band. Ulceration of mucous membrane may occur but in case of large, aggressive tumors.

Commonly, the tumors are well delimited, not encapsulated, firm in consistency, whitish. Macroscopically, GISTs present most often as a well-circumscribed and highly vascular tumors. On gross examination, these tumors appear fleshy pink or tan-white and may show hemorrhagic foci, central cystic degenerative changes, or necrosis. Invasion of the adjacent organs can occur in one-third of cases (Figure 3).

Due to their submucosal or intramural location, small GISTs come often incidentally evident during radiological procedures, surgical intervention for other pathologies or autopsic examination. On the other hand, patients with malignant GIST often present with disseminated disease.

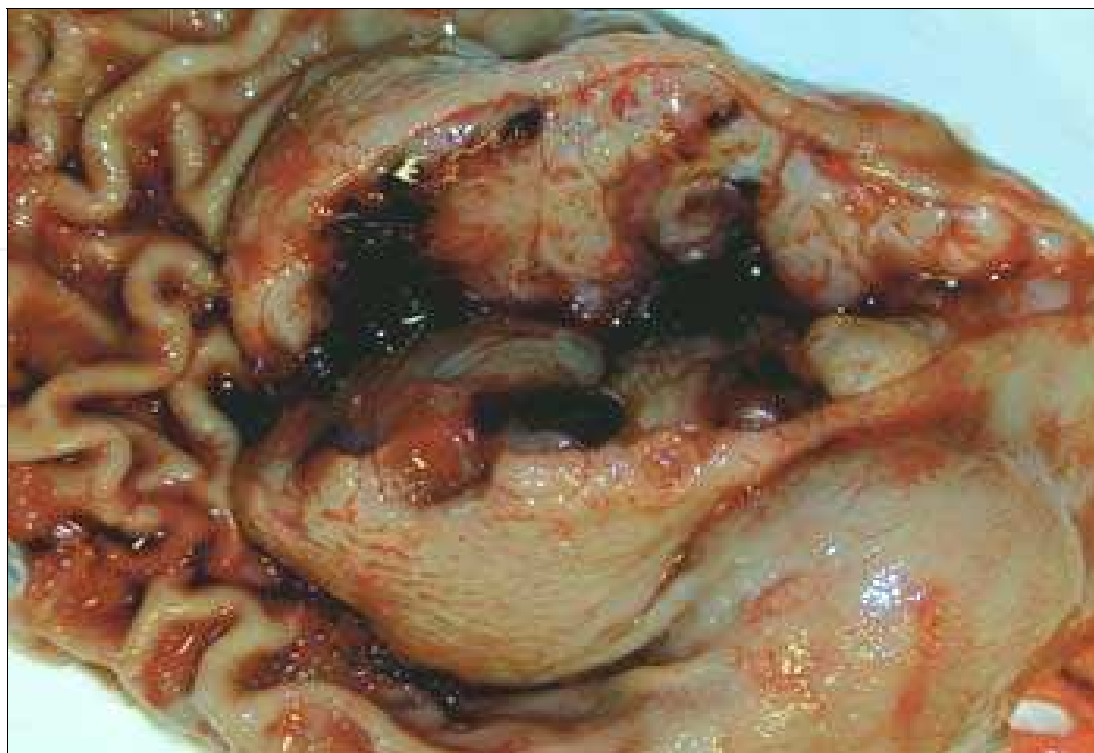

Fig. 3. Commonest macroscopic appearance of gastrointestinal stromal tumor. gelatinous cut surface with focal haemorrhagic foci, central cystic degenerative changes and/or necrosis

The presenting manifestations of gastrointestinal stromal tumors depend on the GI site of origin, the precise portion of the gut wall in which the tumor is located and the size of the neoplasia. A significant number of benign, small tumors are asymptomatic and are accidentally found. In larger tumors, clinical symptoms include abdominal pain, fatigue, dysphagia, satiety and obstruction. Patients may present with chronic acute GI bleeding (causing anemia), acute GI bleeding (caused by erosion through the gastric or the bowel mucosa), or rupture into the abdominal cavity causing intraperitoneal hemorrhage. In general, about 70% of GISTs are associated with clinical symptoms, 20% are not, and 10% are detected at autopsy (Nilsson et al., 2005). The median tumor size in each of the previous categories is 8.9, 2.7 and 3.4 cm, respectively (Nilsson et al., 2005).

In general, tumors infiltrating the mucosa are virtually always malignant. Radiologic imaging studies, including barium contrast, computer tomography and endoscopic ultrasound, are commonly used for the diagnosis and the evaluation of these neoplasms. In addition, some tumors can be diagnosed by cytology, although separation of benign and malignant GISTs is usually not always possible.

GIST metastasis have been reported in 50% of patients. They can quite often occur 10-15 years after initial surgery; therefore, long-term follow-up is required. Metastases develop primarily in the abdominal cavity and liver, exceptionally in lymph nodes or in the lung (De Matteo et al., 2000).

Most of GISTs of omentum, mesenteries, and retroperitoneum are metastatic from the GI-tract (Tsukuda et al., 2007); in these cases, peritoneal involvement with ascites may be the sole presenting features of these tumors.

Histopathologic examination of surgical resection specimens represents the most common method in GIST diagnosis.

6. Familial, paediatric and multiple GISTs

Although the majority of gastrointestinal stromal tumors present as sporadic and solitary gastrointestinal mass in adults aging 50-70 years, with no associated risk factors, a small subset of GISTs (about 5%) occur in the setting of familial or idiopathic multitumor syndrome (neurofibromatosis type 1-NF1-, Carney triad and familial GIST syndrome), in which heritable mutations in KIT or PDGFR α receptors have also been identified (Table 1).

Patients with NF1 have an up to 180-fold increased risk for GISTs, compared with the general population. The majority of NF1 GISTs arise in the small bowel, often in a multifocal appearance. In this context, distinguishing patients with NF1 and multiple GISTs from those having sporadic GISTs with multiple metastasis is often essential. Most of NF1 gastrointestinal stromal tumors are small, cytologically bland, mitotically inactive and follow an indolent course. Then the suspicion for NF1 should be high when multiple, small intestinal GISTs are encountered. Diffuse hyperplasia of ICCs is often seen in the myenteric plexus adjacent to neoplastic masses.

The pathogenesis of NF1 GISTs appears to be different from that of sporadic tumors since it has been demonstrated a very low frequency of associated KIT and PDGFR α mutations (Ponti et al., 2011).

Paediatric GISTs are considered a separate clinicopathologic entity and occur predominantly in the second decade (Juneway et al., 2007). In paediatric and adolescents, gastrointestinal stromal tumors account for 1-2% of all GISTs (Fletcher et al., 2002).

Molecular analyses detect KIT/PDGFR α mutations in a small percentage of cases of paediatric GI stromal neoplasia (10-15%) (Antonescu et al., 2006; Fletcher et al., 2002). Paediatric GISTs are more prevalent in females (female/male ratio: 9:1), occur preferentially in the stomach (88%), display epithelioid or mixed cell morphology (82%), lack of ICC hyperplasia (100%), are slow to progress but can metastasize with a worse prognosis. Unlike adult GISTs, these tumors commonly involve local lymph nodes (Prakash et al., 2005). By contrast, paediatric GISTs with KIT or PDGFR α mutations have very different features: prevalence is greater in males, lesions tend to be unifocal and usually occur in extragastric locations, and spindle-cell morphology is found in all cases (Agaram et al., 2008; Janeway et al., 2007); in other words, they share many of the features of spontaneous adult tumors.

Paediatric gastric GISTs are sometimes associated with pulmonary condromas or paragangliomas, referred to as Carney triad (CT) (Carney, 1999). A number of other lesions have been described in the condition also including pheochromocytomas, oesophageal leiomyomas and adrenocortical adenomas. CT is now considered a novel form of multiple endocrine neoplasia (MEN), a genetic condition with a female predilection. Stratakis et al., recently reported a deletion within the 1p31-q21 region, which harbours the SDHC gene. Another frequent change was the loss of 1p, although GISTs showed more frequent losses of 1p than paragangliomas, the pattern of chromosomal changes was similar in the two tumors, despite their different tissue origin and histology. These findings are consistent with a common genetic aetiology.

Another separate condition in which the dyad GISTs/paragangliomas is inherited is Carney-Stratakis syndrome (CSS); here germline mutation of SDHB, SDHC and SDHD genes (but not KIT or PDGFR α) has been found.

In very rare cases, GISTs may be detected in many organs (multiple GISTs). However, this is not necessarily an indicator of greater aggressiveness. In general, multiple sporadic GISTs are associated to familial GIST syndrome, to Carney triad or Carney-Stratakis syndrome. In

many cases of multiple GISTs, prognosis and treatment differ from those of conventional GISTs. In these circumstances differential diagnosis is mainly based on clinical and genetic studies, rather than on morphological, immunohistochemical or molecular analyses.

7. Pathology

Morphologic evaluation reveals three principal subtypes of GIST, depending on the cytomorphology. Most GISTs (about 70% of cases) are comprised of a fairly uniform population of spindle cells, arranged in a short fascicles or whorls; cytoplasm is sparse, fibrillary, basophilic or rarely eosinophilic, and sometimes contain PAS positive juxtanuclear vacuoles. The nuclei are monomorphous, flattened, have blunt ends and are bullet or cigar shaped; however, they can also be long and pointed. Nuclear pleomorphism is not characteristic for GISTs. The tumor may exhibit a storiform, palisading or herringbone pattern; in this cases GISTs can simulate smooth muscle tumors or tumors of the neural sheet (Figure 4). Larger tumors may present calcification zones.

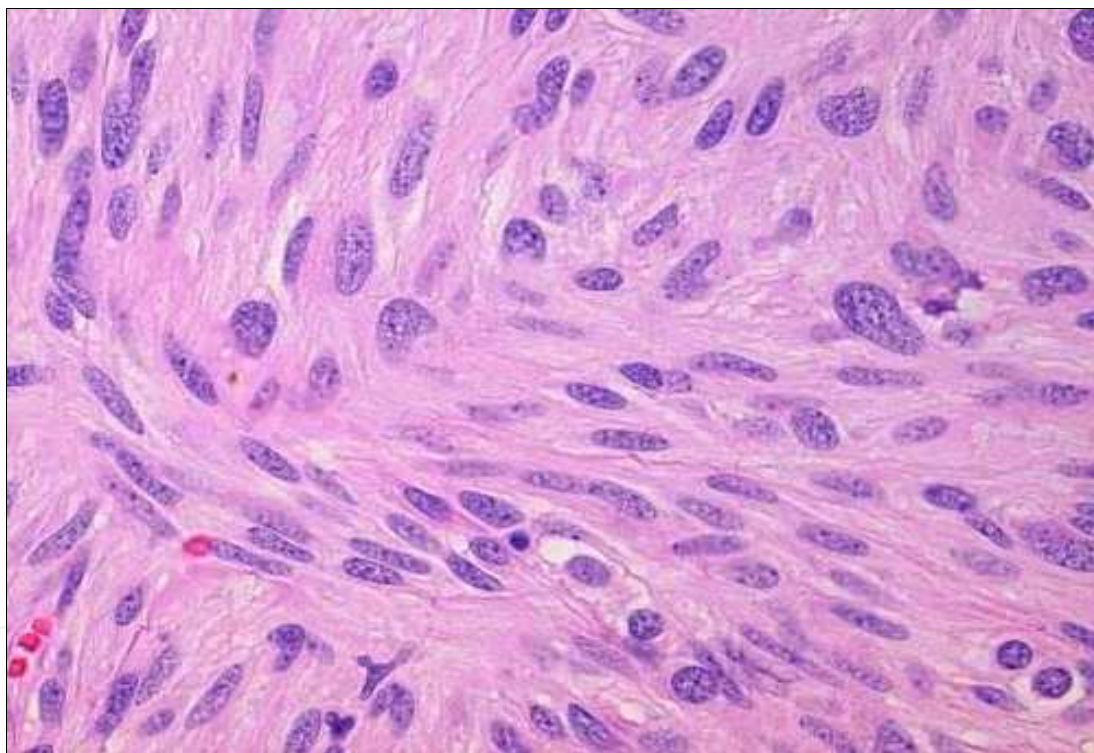


Fig. 4. Spindle cells GIST variant. Hematoxylin-Eosin staining, 20X magnification (from GIST Support International - Pathology Analyses for GIST at www.gistsupport.org).

About 20% of GISTs are dominated by epithelioid round cells, with eosinophilic to clear abundant cytoplasm, and arranged in sheets and nests (Figure 5). This microscopic form can be particularly found in gastric tumors, showing round or eccentric nuclei, with perinuclear vacuolization and small nucleoli. Scattered multinucleated giant cells or cells with bizarre nuclei can be present. Mitotic figures are rare. Collections of extracellular collagen, called skeinoid fibers, may be seen in either spindle and epithelioid variants.

In general, most epithelioid GISTs arising in the stomach are benign, in contrast with those of small intestine, where the prominent epithelioid component is often malignant (Miettinen et al., 2005).

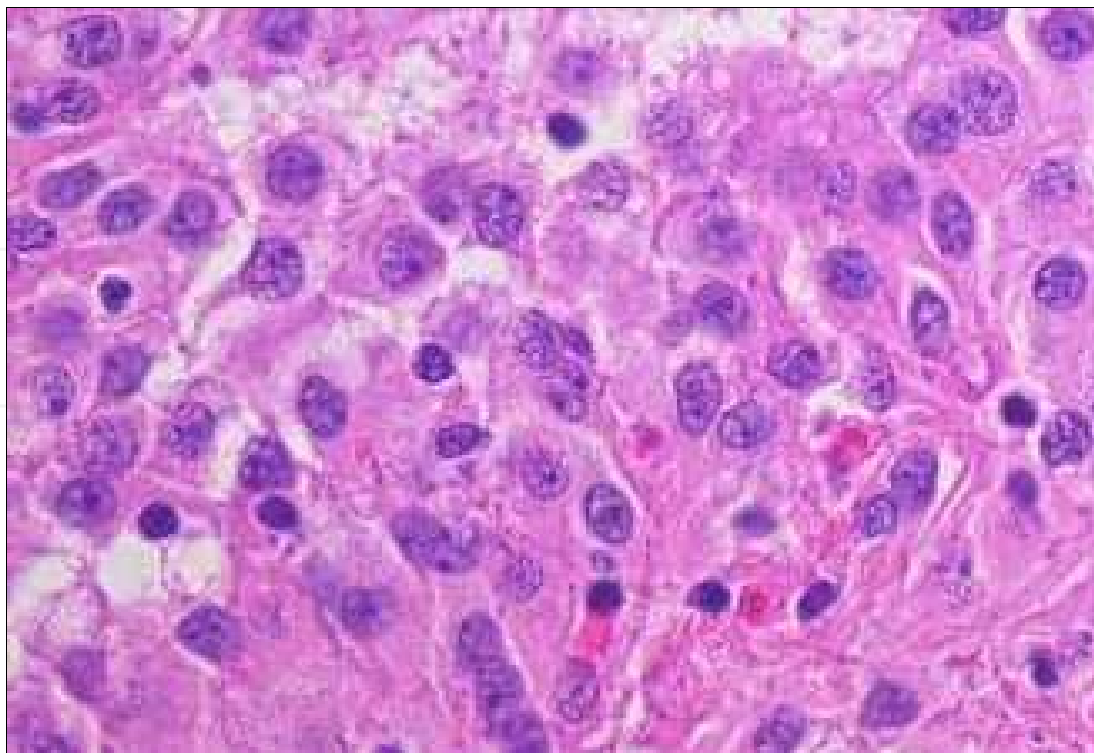


Fig. 5. Epithelioid cells GIST variant. Haematoxylin-Eosin staining, 40X magnification

Approximately 9% of gastrointestinal stromal tumors show mixed morphology, being composed of both spindle and epithelioid cells (biphasic GIST). Variable cellularity as well as sclerotic, collagenous or myxoid stromal changes can be seen. Spindle cells usually can show nuclear palisading or storiform growth pattern, resembling that of peripheral schwannomas; in these cases prominent perinuclear vacuolization is a typical feature.

Overall, GISTs are considered as uniform and monotonous tumors. Pleomorphic and dedifferentiated GISTs are occasionally seen. Mitotic activity is generally low.

Rarely, GISTs may also show signet ring cell features and oncocytic variant. The first variant frequently affect women, and present itself as a small, well circumscribed nodule, histologically characterized by a proliferation of large, round to oval cells containing abundant clear cytoplasm and with nuclear displacement toward the cellular periphery. The second histological variant is characterized by an abundance of mitochondria and by eosinophilic cytoplasm.

Gastrointestinal autonomic nerve tumor (GANT) is also considered a GIST variant. GANT main localization is the small intestine, rarely the stomach, occasionally the large intestine, the oesophagus, the retroperitoneum and the mesentery. It affects mainly the male population aged over 60 years. Tumors occurring in younger person and with gastric localization usually accompany the Carney triad. Microscopically, GANTs are similar to other stromal tumors (epithelial or spindle shape with myxoid stroma). The presence of skeinoid fibers is more frequently observed than in other stromal tumors; lymphoid aggregates can be frequently seen around the tumoral cell nests, but malignant potential is not different from that of GISTs with the same size, histological features and localization.

Although a lot of information has been reported about the histological pattern of GISTs, little is still known about the cytologic appearance of gastrointestinal stromal tumors, particularly in effusions.

In ascitic fluid, GISTs morphologically resemble adenocarcinomas (Figure 6). The most confusing findings are related to cells in a nested pattern and to the occurrence of prominent intracytoplasmic vacuoles (Figure 7). In these case, it would be essential the immunocytochemical study of the neoplasia.

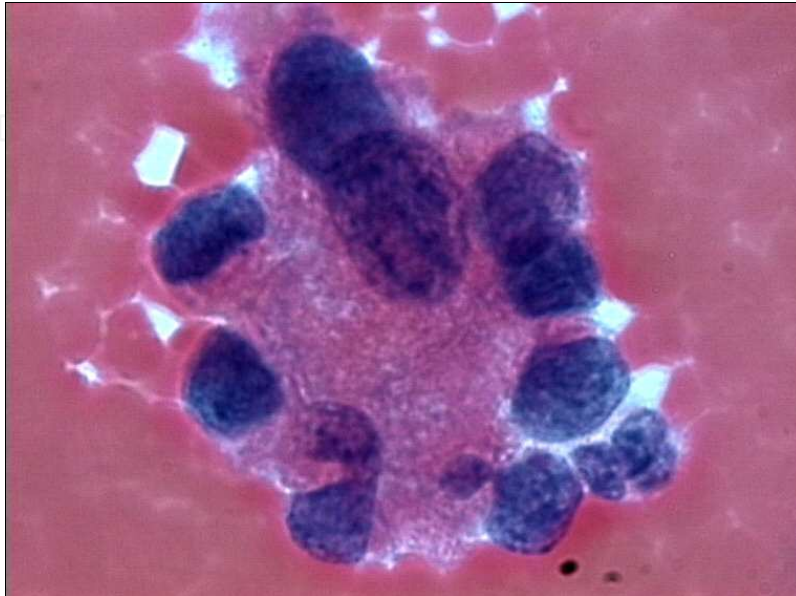

Fig. 6. Morphologic appearance of gastric GIST in ascetic fluid: 3-dimensional sheets of cells with a gland-like prevalent pattern. Papanicolaou stain, 40X magnification

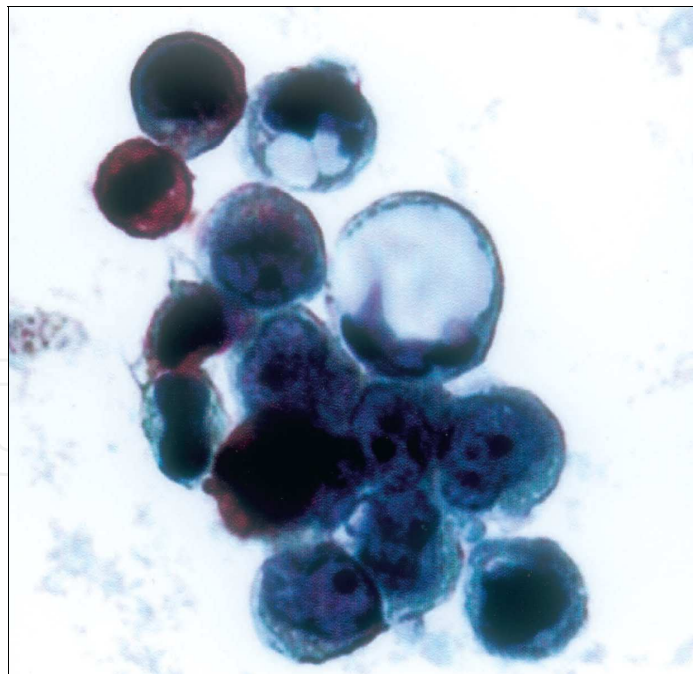


Fig. 7. Gastric GIST in ascetic fluid: tumor cells show epithelioid appearance with high nuclear/cytoplasmic ratio, prominent nucleoli and intracytoplasmic PAS-negative vacuoles, PAS stain, 63X magnification (from Zappacosta et al., (2009) Thin-Layer Cytopathology of a Gastrointestinal Stromal Tumor (GIST) in Effusion: Diagnostic Dilemmas. *Annals of Clinical & Laboratory Science*, 39; 4:367-371)

8. Morphologic risk assessment in GISTs

Although the vast majority of GISTs smaller than 2 cm are clinically benign lesions, occasionally patients will develop metastasis, sometimes 5 years or more after primary excision. Therefore, the older classification that used the terminology “benign” or “malignant” GIST have been replaced by stratification schemes which help in predicting the risk of aggressive clinical behaviour.

The first widely accepted scheme was published in 2002 by Fletcher et al., after a consensus workshop held at the National Institutes of Health (Fletcher et al., 2002). In this scheme, risk assessment is based on tumor size and mitotic activity (per 50 high power fields – HPF). The most important cut-offs as indicator of aggressive clinical behaviour is tumor size of 5 cm and 5 mitoses/50 HPF. According to this 2002 consensus guidelines, all GISTs may have malignant potential. In 2005 and 2006, Miettinen et al., from the AFIP presented two very massive studies of gastric and jejunal/ileal GISTs, providing strong evidence that tumor located in the stomach have a much lower rate of aggressive behaviour that of jejunal and ileal, having similar size and mitotic activity (Miettinen et al., 2006). Basing on these publications, anatomic location is now included as an additional parameter in risk assessment for GIST, together with nodular size and mitotic count (Table 2). To date, tumoral location outside of the stomach seems to be a prognostic factor for survival independent of the mitotic count and tumor size.

Of interest is the prognostic nomogram that could be drawn after the complete surgical resection of primary GISTs; basing on GIST size, mitotic index and site parameters, it would be useful in predicting the probability of 2- and 5-years recurrence free survival (Gold et al, 2009), and in stratifying patients for adjuvant pharmacological treatment.

Mitotic index (number of mitosis/50 HPF)	Size (cm)	Risk of progressive disease in Gastric, duodenal, small intestinal and rectal localization
≤5	≤2	None in all
≤5	>2≤5	Very low, low, low, low
≤5	>5≤10	Low, not reported, moderate, not reported
≤5	>10	Moderate, high, high, high
>5	≤2	None, nor reported, high, high
>5	>2≤5	Moderate, high, high, high
>5	>5≤10	High, nor reported, high, not reported
>5	>10	High in all

Table 2. Risk stratification of primary GIST.

8.1 Gastric GISTs

These neoplasia can be divided into four main types: benign and malignant spindle cell tumors (Figure 3) and benign and malignant epithelioid tumors (Figure 4). These tumor types can usually be distinguished by the assessment of a combination of histologic features (Tables 3 and 4)

ELEMENTS	BENIGN	MALIGNANT
Cellularity	high	high
Mitotic figures	<2/50 HPF	Usually >5/50 HPF
Perinuclear vacuoles	present	usually absent
Nuclear atypia	often absent	Present

*HPF, high power field

Table 3. Histologic characteristics of benign and malignant spindle shape gastric GIST

ELEMENTS	BENIGN	MALIGNANT
Cellularity	low	high
Mitotic figures	<2/50 HPF	Usually >5/50 HPF
Nuclear atypia	often absent	usually present
Necrosis	often absent	usually present

Table 4. Histologic characteristics of benign and malignant epithelioid gastric GIST

8.2 Small bowel GISTs

The small bowel represents the second most common site of gastrointestinal stromal tumors. Unlike GISTs of the stomach, those that occur in the small gut are usually composed of spindle cells. usually, epithelioid variants are rare. The spectrum of histologic feature is completely different from that of gastric localization (Table 5). In general, more small bowel GISTs are malignant than gastric tumors.

ELEMENTS	BENIGN	MALIGNANT
Cellularity	low	high
Mitotic figures	<5/50 HPF	>5/50 HPF
Nuclear atypia	low	high
Necrosis	absent	often present

Table 5. Histologic characteristics of small bowel stromal tumors

8.3 Colonic GISTs

The colon represents the least common site of these neoplasia. Histologically, benign stromal tumors of the colon are rare. Colonic GISTs are more heterogeneous than those of other sites and include highly cellular spindle cell tumors and highly pleomorphic sarcomas. Most patients present metastases at the time of clinical presentation and show poor survival (Miettinen at al., 2009). Tworek et al., showed that an infiltrative growth pattern in the muscularis propria, mucosal invasion and high mitotic counts (>5/50 HPF) correlated significantly with metastasis and deaths Tworek et al., 1999). On the other hand, coagulative necrosis and dense cellularity were found to be minor criteria in the prediction of adverse outcome (Table 6)

ELEMENTS	Low-risk GISTs	High-risk GISTs
Cellularity	low	usually high
Mitotic figures	≤5/50 HPF	>5/50 HPF
necrosis	absent	usually present

Table 6. Histologic characteristics of low-risk and high-risk colonic GISTs

8.4 Anorectal GISTs

The most common mesenchymal tumor of this site is leiomyoma. This lesion is composed of differentiated benign smooth muscular cells derived from the muscularis mucosae and is usually cured by local excision. Apart leiomyoma, most mesenchymal tumors of the anorectum are spindle cell neoplasia, having similar light microscopy, immunohistochemical and molecular genetic alterations of those of GISTs arising in other parts of GI tract. All anorectal GISTs are malignant, regardless their histologic appearance. However, several recent studies have showed the contrary. As with GISTs which develop in other sites, a wide range of features can be used to separate benign from malignant behaviour (Table 7).

ELEMENTS	Low-risk GISTs	High-risk GISTs
Tumor size	<2 cm	>5 cm
Cellularity	low	usually high
Mitotic figures	≤5/50 HPF	>5/50 HPF

Table 7. Histologic characteristics of low-risk and high-risk GISTs

The most common form of anorectal GIST develops in the muscularis propria and is characterized by fascicles of densely cellular, spindle shaped cells with elongated and uniform nuclei, often showing prominent nuclear palisading. Unlike gastric GISTs, anorectal tumors rarely show predominant epithelioid morphology. Malignant tumors tend to be located in the muscularis propria and show mild nuclear atypia and high mitotic counts. Tworek et al., demonstrated that tumor size larger than 5 cm and an infiltrative growth pattern within muscularis propria, correlates with an adverse outcome (Tworek et al., 1999). On the contrary, nuclear plemorphism, necrosis, mitotic counts and intramuscular localization did not correlate with clinical behaviour. This studies also revealed a long latency period before recurrence and metastasis, thus emphasizing the need for long-term follow-up in patients with these tumors

8.5 Oesophageal GISTs

Benign leiomyiomas represents the most common type of mesenchymal tumor also in this site, while oesophageal GISTs are rare. These last usually have a male predilection, more often present with dysphagia, and typically arise in the distal oesophagus, often involving esophagogastric junction. Grossly the have a soft consistency, with a fleshy, variegated cut surface, frequently with central necrosis and cystic changes. histologically, they are typically high cellular spindle shaped neoplasms, composed of mildly atypical nuclei and a wide range of mitotic activity. A variety of morphologic patterns may be seen, including sheets of cells, with or without nuclear palisading, myxoid change, and hyaline-like degeneration. coagulative necrosis and mucosal invasion are rare.

9. Immunohistochemistry of GISTs

9.1 c-kit and PDGFRα antibodies

The key features of GISTs is the positivity for the KIT (CD117) receptor tyrosine kinas (c-kit), observed in more than 95% of the tumors. c-kit is considered a marker with high levels of sensitivity. However, although c-kit positivity is a major defining features for GIST, it

should not be considered an absolute requirement. It is very important to point out that c-kit expression in GIST is a constitutional feature and not a consequence of mutation.

CD117 GIST positivity is often pancytoplasmic. Membrane staining is also observed in epithelioid variants (Figure 8).

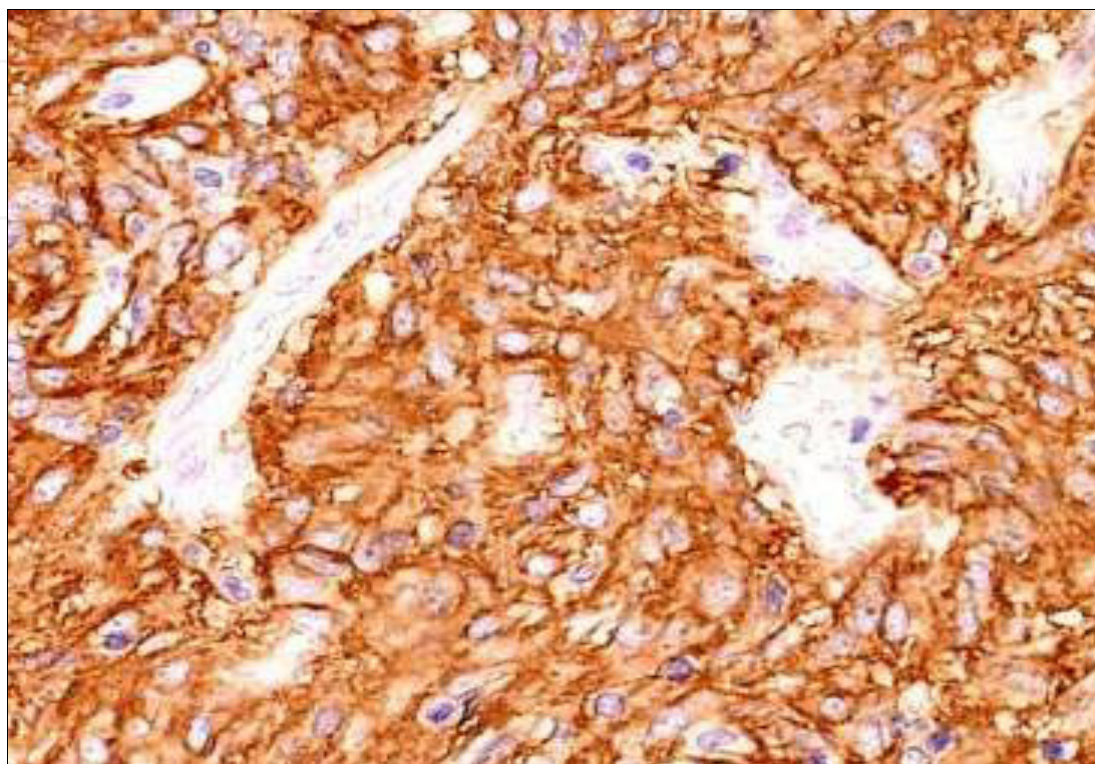


Fig. 8. CD117 GIST positivity. 20X magnification

The intensity of c-kit immunostain is variable. In most cases it is weakly and not homogeneous. In other cases, only a small percentage (10-20%) cells shows CD117 positivity. The minimum percentage of CD117-positive tumoral cells needed to establish GIST diagnosis has been not established yet but if this percentage is below 10% and positive cells are isolated or arranged in small groups it is important to differentiate them from mast cells.

There are some rare cases of negative c-kit GISTs (about 5%). In these cases, diagnosis of GIST should be cautious and should be made only after the elimination of some cases that might determined the marker negativity, such as possible technical errors. Specific kit antibodies should react with normal KIT-positive components, such as mast cells and ICC and not with normal smooth muscle cells or fibroblasts. CD117 could also tested negative in GISTs previously treated with imatinib, and in metastatic or congenital lesions. In these cases, a molecular study o KIT or PDGFR α mutations would be essential.

Basing on the above considerations, it is possible to assert that CD117 is not specific for GISTs. This marker is also expressed, in seminoma, melanoma, follicular thyroid carcinoma, small cells lung carcinoma, thymic carcinoma and thymomas, angiosarcomas, chronic myeloid leukemia, mast- cell tumors, germinal tumors etc. Fortunately, the distinction between GISTs and these other tumors can be easily made with histological observation and with the use of other more specific markers.

PDGFR α strong immunopositivity is often observed in PDGFR α mutated GISTs. However, these finding needs further evaluation.

9.2 CD34 antibody

CD34 is less sensitive than CD117 and is expressed in 60-70% of tumors localized in oesophagus, rectum, and rarely in small bowel. CD34 is a hematopoietic progenitor cell antigen also expressed in endothelial cells, subsets of fibroblasts and in tumors related to these cell types. CD34 expression does not seem to have a significant prognostic factor.

9.3 Muscle cell markers

Approximately 30% of GISTs, more often located in small intestine, are positive for smooth muscle actin (SMA), whose expression is sometimes reciprocal with that of CD34. SMA positivity may be focal or extensive.

Often, when normal smooth muscle fibers infiltrate GIST cells, the result is the presence of SMA (and Desmin) positive spindle cells within stromal stromal neoplasia; this “contamination” should not be confused with GIST SMA-positivity; in fact GIST SMA-positivity has been statistically correlated with favourable prognosis in gastric and intestinal neoplasia (Miettinen et al., 2006).

Desmin positivity is rare in GISTs of all sites, If positive to desmin, GISTs have gastric localization and are of epithelioid variant. It is important to note that imatinib treatment may induce desmin expression.

H-caldesmon it has been recently introduced among the diagnostic immunohistochemical panel for GISTs. It is a protein associated with actin, and is expressed in normal and neoplastic smooth muscle cells such as leiomyomas and leiomyosarcoma. The association of positivity for h-caldesmon, SMA and desmin would guide the diagnosis towards a smooth muscle tumor rather than towards a GIST.

9.4 Neural markers

S100 protein expression is rare in GISTs, but seems to be more common in neoplasia of small bowel than in that of stomach. In this context, S100 protein positivity seems to be an adverse prognostic factor in gastric but not in small intestinal GIST (Miettinen et al., 2006).

GISTs are also positive for nestin, a type VI intermediate filament protein that is typical of many stem cells, including those of nervous and muscular systems. Nestin is also present in GI schwannomas, this suggesting a relative low specificity for GIST diagnosis.

Gastrointestinal stromal tumors are positive for vimentin and negative for glial fibrillary acid protein (GFAP). This negativity helps to distinguish GISTs from GI schwannomas, that test GFAP positive.

Cytokeratin positivity can be also seen in GIST, especially CK18 and CK8, but not CK19 and CK20. Antibodies cocktails such as AE1/AE3 would usually give negative results.

9.5 DOG1

It has been recently realized that DOG1 is the same protein called anoctamin I or TMEM16A, known to act as calcium-activated chloride channel (Gomes-Pinilla et al., 2009).

DOG1 expression has been described in a large series of normal cell types, including ICCs, myoepithelial/basal cells in breast and prostate etc. The pattern of positivity is essentially cytoplasmic and/or membranous. DOG1 is now considered a higher sensitive marker of

GIST than CD117; about one-third of c-kit negative GISTs shows DOG1 positivity (Liegh et al., 2009) even if a small minority (at least, 1%) may be both CD117 and DOG1 negative.

It has been noted that only four GIST mimics potentially express both CD117 and DOG1: angiosarcomas, synovial sarcomas, Ewing's sarcomas and melanomas. In the above mentioned neoplasia, immunostaining for either markers is focal, whereas in GISTs is diffuse. It has been proposed that in histologically suspected GIST and in presence of diffuse c-kit and DOG1 immunopositivity, no other immunohistochemical testing would be required.

It should be take in consideration that: (i) gastrointestinal leiomyomas may shows some DOG1-positive ICCs intermingled with neoplastic smooth cells; the presence of these cells within leiomyomas raises the question if these tumors are effectively true neoplasia or, instead, nodular hyperplasia. (ii) A number of carcinomas may occasionally tested positive for DOG1; some of these neoplasia, especially adenocarcinoma, may also tested CD117-positive (West et al., 2004).

9.6 Immunocytochemical markers

As previously described, in effusions GIST cells may be acquire an epithelioid appearance characterized by nested pattern and prominent intracytoplasmic vacuoles. In order to differentiate GIST from other epithelioid and non-epithelioid neoplasms, the immunocytochemical assessment of the tumor would be imperative. Positive immunoreactivity for vimentin, but not for cytokeratins, within gland-like structures would suggest the mesenchymal nature of the tumor; PAS-negativity demonstrating the lack of mucin within cytoplasmic vacuoles can also supported the diagnosis of GIST.

10. Differential diagnosis

Obviously, differential diagnosis has been very much facilitated by immunohistochemistry, using a complete and specific panel of antibodies for mesenchymal tumors. Neoplasia with smooth muscle differentiation (leiomyomas and leiomyosarcomas, SMA+, desmin+ but CD117- and CD34-negative) will be taken into account. Differential diagnosis also includes tumors with nervous differentiation, such as gastric schwannomas (S100+, CD117-), tumors with fibrous differentiation, such as fibromatosis (CD117-), inflammatory gastric polyps and inflammatory myofibroblastic pseudo-tumor CD117- and CD34-).

Histological pattern would exclude retroperitoneal undifferentiated liposarcomas, as well as two CD117-positive mesenchymal tumors: metastasis of malignant melanomas and angiosarcoma.

In effusion, GIST should be distinguished from mesotheliomas and amelanotic melanomas. Mesotheliomas may display PAS-negative, or rarely PAS-positive, intracytoplasmic vacuoles but, in contrast with GISTs, it shows pancytokeratin positivity. Amelanotic melanomas may show a weak CD117-positivity, as well as vimentin-positivity; however, melanomas cells usually grow as single elements and stain S100-positive, whereas GIST cells aggregate in three-dimensional clusters usually staining S100-negative.

11. GISTs surgical approach

Complete surgical resection with microscopically negative margins represents the standard of care for patients presenting primary resectable GISTs. Particularly, neo-adjuvant therapy

for those with resectable disease is actually not recommended, although preoperative drug administration may be considered for patients with marginally resectable tumors and for those having potentially resectable disease but at increased risk of significant morbidity.

11.1 Lesions smaller than 2 cm

When small oesophageal, gastric or duodenal nodule less than 2 cm in size are detected, endoscopic biopsy may be difficult; in these cases, laparoscopic or laparotomic excision may be elective in order to achieve a histological diagnosis. According to the new guidelines, GISTs smaller than 2 cm must to be regarded as essentially benign. For this reason, the standard approach to these patients relies on endoscopic ultrasound assessment and then follow-up. Excision would then reserved for patients whose tumor increases in size or becomes symptomatic. For rectal tumor, the standard approach is biopsy/excision after ultrasound assessment, regardless of tumor size, because the risk of GIST at this site is high.

11.2 Lesions larger than 2 cm

In this case, the standard approach is biopsy/excision. In presence of larger mass, especially if surgery might imply multivisceral resection, multiple core needle biopsies represent the standard approach. Obviously, accurate assessment of the histotype is essential.

12. Molecular target therapy

Because constitutive activation of KIT and PDGFR α has been demonstrated in GIST development, the inhibition of these activated kinases has been verified to be effective for the treatment of this neoplasia.

Imatinib is an orally bioavailable 2-phenylaminopyrimidine derivative, developed in 1990s as a treatment for myelogenous leukemia. Imatinib shuts off oncogenic signalling from the fusion oncogene Bcr-Abl in chronic myelogenous leukemia cells by occupying the ATP-binding pocket of the Abl kinase domain. Abl shares considerable homology with the type III receptor tyrosine kinase family (Reichardt et al., 2011). In addition to the inhibitory effect of imatinib mesylate on PDGFR α and Bcr-ABL, it has been found an inhibitory effect on wild-type KIT (Reichardt et al., 2011). The first GIST patient successfully treated with imatinib was reported in 2001 (Druker et al., 2001). Subsequently, a multicenter trial on advanced GIST was done in 2002 and significant effect was reported (van Oosterom et al., 2002). Consequently, FDA approved imatinib mesylate as an effective therapeutic agent for patients with metastatic or un-resectable KIT-positive GIST. Obviously, an accurate pathological diagnosis of GIST condition by using immunohistochemistry for KIT is necessary.

Imatinib reliably achieves disease control in 70-85% of patients with advanced GISTs, with a median progression-free survival of 20-24 months. The estimated median overall survival time following imatinib therapy exceeds 36 months (Corless et al., 2008).

As previously described, imatinib is effective in the majority of GIST patients, but tumor regrowth by resistant clones occurs during continuous therapy (secondary resistance) (Joensuu et al., 2008). The main cause of this event seems to be a second mutation in the same genes. For these reasons, several new drugs for GIST including the imatinib-resistant are under development or clinical trials.

12.1 Therapy for localised resectable disease

Estimation of recurrence risk of GIST after resection is very important during the selection of patients for adjuvant imatinib.

Size, mitotic count and anatomic localization have been widely accepted as predictive of outcome, but tumor rupture, incomplete resection and c-kit/PDGFR α mutational status also impact on disease-free survival (Joensuu et al., 2008). Particularly, when compared with exon 11 mutants, the presence of exon 9 mutations and wild-type GIST were the strongest adverse prognostic factors for response, risk of progression and death (Dematteo et al., 2009).

Questions remain regarding post-operative or adjuvant therapy. The American College of Surgeons Oncology Group conducted a randomised, phase III trial of adjuvant imatinib after surgical resection of primary GIST. They randomly assigned 713 adults with a completely resected GIST ≥ 3 cm in size and immunohistochemically positive for KIT to 1 year of adjuvant imatinib or placebo. At a median follow-up of 20 months, 30 patients in the imatinib group had recurred or died, versus 70 given placebo. The 1-year recurrence free-survival was 98% versus 83%, favouring imatinib (Dematteo et al., 2009). basing of these findings, FDA approved the use of imatinib for patients having completely resected GIST ≥ 3 cm in size. However, the optimal duration of therapy for patients remains unclear. Actually two additional European trials have been completed: EORTC 62024 randomized trial assessing the overall survival of patients with intermediate and high-risk GIST after 2 years of imatinib or observation alone; Scandinavian Sarcoma Group trial XVIII, that evaluated recurrence-free survival of patients with high-risk disease after 1-3 years of adjuvant imatinib. Data from there trials are shortly to be published.

12.2 Therapy for un-resectable or metastatic disease

Systemic chemotherapy for advanced GIST is highly ineffective: response rate is less than 10% (Dematteo et al., 2002). Imatinib blocks KIT/PDGFR α signalling by binding to the ATP-binding pocket required for phosphorylation and activation of the receptor. In vitro data demonstrated that imatinib leads to the interruption of cell proliferation through the inhibition of downstream phosphorylation.

12.3 Management of refractory GISTs

The median time to progression on first-line imatinib is about 2-2.5 years. Dose escalation should be considered in patients who had imatinib therapy but shows clear evidence of progression. The efficacy of this approach was demonstrated in the European dose-finding study (Zalcberg et al., 2005).

Sunitinib, nilotinib and dasatinib represent the second generation of multitargeted tyrosine kinase inhibitors. The role of this new pharmacological approach to GIST was established by an international phase III trial performed on patients intolerant to or with imatinib-resistant GIST. this trial revealed highly statistically significant benefits in terms of response rate, time of progression and overall survival.

Sorafenib, is a multitargeted tyrosine kinase inhibitor with potent activity against B-RAF tyrosine kinase, VEGFR, PDGFR, KIT and FLT3. has been investigated in a phase II study

involving patients with imatinib- and sunitinib-resistant GIST. This trial demonstrated an overall progression free survival of about 22 months (Wiebe et al., 2008).

Heat shock proteins (HSP) help to maintain malignant pathway by stabilizing mutated proteins. Inhibition of HSP 90 destroys the activated KIT/ PDGFR α , potentially leading to a therapeutic effect in GIST patients. However, an international phase III trial in patients with metastatic and/or un-resectable neoplasia after failure of imatinib and sunitinib demonstrated higher mortality rate among patients in the treatment arm.

Flavopiridol is an inhibitor of cyclin-dependent kinase (CDK1 and CDK2). In preclinical studies, this molecule induced a high level of apoptosis in GIST cells, at clinical doses.

Although a wide range of studies has been done about GISTs pharmacological therapy, many questions remain controversial. For these reasons, currently sunitinib represents the only standard targeted therapy available in imatinib-refractory GISTs. For this reason, an urgent need for new drugs exist. However, due to the relatively rarity of GIST disease, it is may difficult to accumulate an adequate number of patients for clinical trials. Basing on these considerations, collaborations among medical centers worldwide would be crucial.

13. Mutational analyses to predict GISTs pharmacological response

It has been reported that also the location of KIT and PDGFR α mutations is related to pharmacological response to imatinib (Wardelmann et al., 2007). Then, assessing the presence and the type of GIST mutation can help to predict response to pharmacological therapy. Particularly, GIST with JM domain mutations of the PDGFR α appeared to respond to imatinib but GIST with TK domain mutation of the same gene, as well as GIST without any detectable c-kit or PDGFR α mutations did not. Moreover, pharmacological response to imatinib was higher for GIST with mutations with JM domain of c-kit gene than that of GIST with EC domain mutation of the same gene (Debiec-Rychter et al., 2006)..

The genotype profile associated with primary resistance to sunitinib is just the opposite of that of imatinib: KIT exon 9 mutations and wild-type genotype predict for a better response than exon 11 mutations (Heinrich et al., 2008). Mutations predicting primary resistance to both imatinib and sunitinib, such as PDGFR α exon 18 mutation (D842V), also exist (Corless et al., 2005; Prenen et al., 2006).

In a majority of cases, secondary resistance to imatinib is due to prolonged exposure to the drug, which induces the emergence of GIST cell clones, bearing additional, resistance-mediating mutations (Liegler et al., 2008; Wardelmann et al., 2006). The vast majority of these so-called secondary mutations causing imatinib resistance have been found in KIT exons 13, 14, 17 and 18, and there are some clinical data suggesting that the exon 13 and 14 mutations are still sensitive to sunitinib whereas mutations at exons 17 and 18 are not (Heinrich et al., 2008).

Basing on these considerations mutational analyses are considered to be a needful requirement to predict the effectiveness of pharmacological therapy on GIST patient. For these reasons, it would be of great importance the molecular classification of GISTs, which both emphasizes the molecular context of the tumor as well as provides a quick reference for syndromes with which stromal tumors may be associated (Table 8).

GIST type	Response to pharmacological therapy
KIT mutation	
Exon 11	Excellent response to imatinib
Exon 9	Intermediate response to imatinib
Exon 13	Sensitive to imatinib in vitro
Exon 17	Sensitive to imatinib in vitro
PDGFR α mutation	
Exon 12	Sensitive to imatinib in vitro
Exon 18	D842V: poor response; other mutations are sensitive
Wild type	Poor response to imatinib

Table 8. Molecular classification of GIST (Corless CL et al., 2001, modified)

14. Methodologies to assess GISTs response to therapy

As more GISTs are being resected following down-staging with imatinib therapy, there are increasing published data regarding the pathological changes induced by such therapy, although these data are still evolving.

These changes can be divided into those representing GIST regressing with therapy and into those of GIST resistant to therapy. In the former case, the typical macroscopic appearance is a gelatinous cut surface with focal haemorrhagic and/or necrosis. Histologically, these features correspond with a hypocellular, mixoid and/or fibrotic stroma, containing scattered residual GIST cells with pyknotic nuclei and minimal cytoplasm.

When compared with its pre-treated counterpart, an imatinib regressing GIST will typically shows reduced or absent CD117 immuno-positivity, reduced CD34 positivity and a reduction of mitotic activity and Ki67 labelling index.

There is little documentation of whether GISTs demonstrating primary imatinib resistance show specific histopathological changes; by contrast, the range of pathological features associated with secondary resistance to imatinib has been more widely described.

Radiologically, secondary resistance is often characterized by re-emergence of 2-[18F]fluoro-D-glucose (FDG) uptake on positron emission tomography (PET) scan and/or peripheral thickening or nodule formation in a previously responding tumor on TC scan Mabile et al., 2009; (Mabile et al., 2009; Van den Abbeele et al., 2008). This corresponds macroscopically with one or more solid area showing the above-mentioned regressing changes within the tumor.

Some case reports described secondary resistant GISTs developing a more epithelioid appearance, with large cells containing abundant eosinophilic cytoplasm. However, there are doubts regarding the true significance of this phenomena.

Actually, overall assessment of response to therapy in patients undergoing treatment for GISTs actually relies decrease of tumor density as observed on computed tomography, since tumor progression may present as change in size or density. In this context, it has been proposed a new set of response evaluation criteria in which tumor response is defined as a 10% decreased in unidimensional tumor size or a 15% decrease in tumor density on tomography (Choi et al., 2007).

15. GISTs prognosis

Several clinical factors have been reported to define the prognosis of GISTs. Tumor tumor size, location in the fundus or gastroesophageal junction, coagulative necrosis, ulceration,

mucosal invasion and mitotic count have all been identified as unfavourable factors. In addition, male sex, high age, high Ki67 (or MIB-1) grade, desmin staining and incomplete surgical resection have been also shown to be factors having a wrong impact on the overall survivals (Ozguc et al., 2005). Moreover, it seems that patients with tumor rupture have a very high risk of recurrence, since tumor rupture taking place either spontaneously or at surgery increases the risk of intra-abdominal tumoral implants. Tumor rupture seems to be independent of the size and mitotic count (Rutkowski et al., 2007; Takahashi et al., 2007).

Almost all small GISTs detected incidentally or through serial sectioning of surgical or autoptic specimens display an uniformly spindle cell morphology and are CD117+/CD34+; however, expression of CD34 is often lacking or is focal in the secondary compartment. It has been demonstrated that the secondary localization generally evolved from the corresponding lower-grade primary site through accumulation of additional chromosomal imbalances. This fact suggest that progression from low-grade to high-grade morphology, as well as eventual metastatic behaviour is driven by increasing chromosomal instability (Agaimy et al., 2009). In summary, it seems that sequential chromosomal alterations rather than KIT or PDGFR α mutations would drive the evolution to eventual GIST more aggressive behaviour (Agaimy et al., 2009). However, further studies are needed to clarify these correlations and link them to clinical outcome.

Since additional prognostic factors are continuously proposed in the medical literature, the need of accurate risk stratification becomes increasingly urgent. Accurate risk stratification is crucial for the selection of patients who are most likely to benefit from pharmacological therapy (Demetri et al., 2007).

16. Conclusions

This review provides an overview on gastrointestinal stromal tumor. Pathogenesis, morphologic evaluation, immunohistochemical markers, risk assessment, molecular analyses and therapies, represent the basic elements of the present work, as well as the disquisition regarding the pharmacological approach to this neoplasia and the mechanisms of drug resistance.

At a glance overview emerges how GISTs, from being poorly defined, treatment-resistant neoplasia become a well recognised, well understood and effectively treated neoplasia.

In this context, progresses in understanding of GIST biology laid the foundation for the first model of target therapy. GIST model is now widely adopted in programmes focusing on a variety of other solid tumors.

17. References

- Abulafia, O., Pezzullo, J.C. & Sherer, D.M. (2003). Performance of ThinPrep liquid-based cervical cytology in comparison with conventionally prepared Papanicolaou smears: a quantitative survey. *Gynecol Oncol* 90: 137-144.
- Agaimy, A., Haller, F., Gunawan, B., Wünsch, P.H. & Füzesi, L. (2009). Distinct biphasic histomorphological pattern in gastrointestinal stromal tumours (GISTs) with common primary mutations but divergent molecular cytogenetic progression. *Histopathology* 54: 295-302.

- Agaram, N.P., Laquaglia, M.P., Ustun, B., Guo, T., Wong, G.C. & Socci, N.D. (2008). Molecular characterization of pediatric gastrointestinal stromal tumors. *Clin Cancer Res* 14: 3204-3215.
- Antonescu, C.R., Besmer, P. & Guo, T. (2005). Acquired resistance to imatinib in gastrointestinal stromal tumor occurs through secondary gene mutation. *Clin Cancer Res* 11: 4182-4190.
- Antonescu, C.R. (2006). Gastrointestinal stromal tumor (GIST) pathogenesis, familial GIST, and animal models. *Semin Diagn Pathol* 23: 63-69.
- Cajal, S.R. (1983). Sur les ganglions et plexus nerveux de l'intestin. *CR Soc Biol* 45: 217-23.
- Carney J.A. (1999). Gastric stromal sarcoma, pulmonary chondroma, and extra-adrenal paraganglioma (Carney Triad): natural history, adrenocortical component, and possible familial occurrence. *Mayo Clin. Proc.* 74: 543-52.
- Choi H., Charnsangavej C. & Faria S.C. (2007). Correlation of computed tomography and positron emission tomography in patients with metastatic gastrointestinal stromal tumor treated at a single institution with imatinib mesylate: proposal of new computed tomography response criteria. *J Clin Oncol* 25: 1753-1759.
- Chompret A., Kannengiesser, C., Barrois, M., Terrier, P. & Dahan, P. (2004). PDGFRA germline mutation in a family with multiple cases of gastrointestinal stromal tumor. *Gastroenterology* 126: 318-321.
- Corless, C.L., McGreevey, L., Haley, A., Town, A. & Heinrich, M.C. (2002). KIT mutations are common in incidental gastrointestinal stromal tumors one centimeter or less in size. *Am J Pathol* 160: 1567-1572.
- Corless, C.L., Schroeder, A. & Griffith D. (2005). PDGFRA mutations in gastrointestinal stromal tumors: frequency, spectrum and in vitro sensitivity to imatinib. *J Clin. Oncol* 23; 5357-5364.
- Corless, C.L. & Heinrich, M.C. (2008). Molecular Pathobiology of Gastrointestinal Stromal Sarcomas. *Ann Rev Pathol Mech Dis* 3: 557-586.
- Debiec-Rychter, M., Cools, J. & Dumez, H. (2005). Mechanisms of resistance to imatinib mesylate in gastrointestinal stromal tumors and activity of the PKC412 inhibitor against imatinib resistant mutants. *Gastroenterology* 128: 270-279.
- Debiec-Rychter, M., Sciot, R. & Le, C.A. (2006). KIT mutations and dose selection for imatinib in patients with advanced gastrointestinal stromal tumours. *Eur J Cancer* 42; 1093-1103.
- DeMatteo, R.P., Lewis, J.J. & Leung, D. (2000). Two hundred gastrointestinal stromal tumors: recurrence patterns and prognostic factors for survival. *Ann Surg* 231: 51-58.
- Dematteo, R.P., Heinrich, M.C. & El-Rifai, W.M. (2002). Clinical management of gastrointestinal stromal tumors: before and after STI-571. *Hum Pathol* 33: 466-477.
- Dematteo, R.P., Ballman, K.V. & Antonescu, C.R. (2009). Adjuvant imatinib mesylate after resection of localised, primary gastrointestinal stromal tumour: a randomised, double-blind, placebo-controlled trial. *Lancet* 373: 1097-1104.
- Demetri, G.D., Benjamin, R.S. & Blanke, C.D. (2007). NCCN Task Force report: management of patients with gastrointestinal stromal tumor (GIST)—update of the NCCN clinical practice guidelines. *J Natl Compr Canc Netw* 5(Suppl 2): S1-S29.
- Druker, B.J., Talpaz, M., Resta, D.J., Peng, B., Buchdunger, E., Ford, J.M., Lydon, N.B., Kantarjian, H., Capdeville, R., Ohno-Jones, S. & Sawyers, C.L. (2001). Efficacy and


- safety of a specific inhibitor of the BCR-ABL tyrosine kinase in chronic myeloid leukemia. *N Engl J Med* 5; 344: 1031-1037.
- Fletcher, C.D., Berman, J.J. & Corless, C. (2002). Diagnosis of gastrointestinal stromal tumors: a consensus approach. *Hum Pathol* 33: 459-465.
- Haller, F., Gunawan, B. & von Heydebreck, A. (2005). Prognostic Role of E2F1 and Members of the CDKN2A Network in Gastrointestinal Stromal Tumors. *Clin Cancer Res* 11: 6589-6597.
- Furitsu, T., Tsujimura, T., Tono, T., Ikeda, H., Kitayama, H., Koshimizu, U., Sugahara, H., Butterfield, J.H., Ashman, L.K., Kanayama, Y., Matsuzawa, Y., Kitamura, Y. & Kanakura, Y. (1993). Identification of mutations in the coding sequence of the proto-oncogene c-kit in a human mast cell leukemia cell line causing ligand-independent activation of c-kit product. *J Clin Invest* 92: 1736-1744.
- Goettsch, W.G., Bos, S.D. & Breekveldt-Postma, N. (2005). Incidence of gastrointestinal stromal tumours is underestimated: results of a nationwide study. *Eur J Cancer* 41: 2868-2872.
- Gold, J.S., Gonen, M. & Gutierrez, A. (2009) Development and validation of a prognostic nomogram for recurrence-free survival after complete surgical resection of localised primary gastrointestinal stromal tumour: a retrospective analysis. *Lancet Oncol* 10: 1045-1052.
- Gomez-Pinilla, P.J., Gibbons, S.J. & Bardsley, M.R. (2009). Ano1 is a selective marker of interstitial cells of Cajal in the human and mouse gastrointestinal tract. *Am. J Physiol Gastrointest Liver Physiol* 296: 1370-1381.
- Hayashi, S.I., Kunisada, M., Ogawa, M., Yamaguchi, K. & Nishikawa, S.I. (1991). Exon skipping by mutation of an authentic splice site of c-kit gene in W/W mouse. *Nucleic Acids Res* 19: 1267-1271.
- Heinrich, M.C., Corless, C.L., Duensing, A., McGreevey, L., Chen, C.J., Joseph, N., Singer, S., Griffith, D.J., Haley, A., Town, A., Demetri, G.D., Fletcher, C.D. & Fletcher, J.A. (2003). PDGFRA activating mutations in gastrointestinal stromal tumors. *Science* 299: 708-710.
- Heinrich, M.C., Maki, R.G. & Corless, C.L. (2008). Primary and secondary kinase genotypes correlate with the biological and clinical activity of sunitinib in imatinib-resistant gastrointestinal stromal tumor. *J Clin Oncol* 26; 5352-5359.
- Hirota, S., Isozaki, K., Moriyama, Y., Hashimoto, K. & Nishida, T. (1998). Gain-of-function mutations of c-kit in human gastrointestinal stromal tumors. *Science* 279:577-80
- Rubin BP, Antonescu CR, Scott-Browne JP, Comstock ML, Gu Y, et al. 2005. A knockin mouse model of gastrointestinal stromal tumor harboring kit K641E. *Cancer Res* 65: 6631-6639.
- Huizinga, J.D., Thuneberg, L. & Kluppel, M. (1995). W/kit gene required for interstitial cells of Cajal and for intestinal pacemaker activity. *Nature* 373: 347-349.
- Isozaki, K., Hirota, S., Nakama, A., Miyagawa, J. & Shinomura, Y. (1995). Disturbed intestinal movement, bile reflux to the stomach, and deficiency of c-kit-expressing cells in Ws/Ws mutant rats. *Gastroenterology* 109: 456-464.
- Janeway, K.A., Liegl, B. & Harlow, A. (2007) Pediatric KIT wildtype and platelet-derived growth factor receptor alpha wild-type gastrointestinal stromal tumors share KIT activation but not mechanisms of genetic progression with adult gastrointestinal stromal tumors. *Cancer Res* 67: 9084-9088.

- Joensuu, H. (2008). Risk stratification of patients diagnosed with gastrointestinal stromal tumor. *Hum Pathol* 39: 1411–1419.
- Kang, D.Y., Park, C.K., Choi, J.S., Jin, S.Y. & Kim HJ (2007). Multiple gastrointestinal stromal tumors: clinicopathologic and genetic analysis of 12 patients. *Am J Surg Pathol* 31: 224–232.
- Kindblom, L.G., Remotti, H.E., Aldenborg, F. & Meis-Kindblom, J.M. (1998). Gastrointestinal pacemaker cell tumor (GIPACT): Gastrointestinal stromal tumors show phenotypic characteristics of the interstitial cells of Cajal. *Am J Pathol* 152: 1259–1269.
- Liegl, B., Kepten, I. & Le, C. (2009). Heterogeneity of kinase inhibitor resistance mechanisms in GIST. *J Pathol* 216: 64–74.
- Liegl, B., Hornick, J.L., Corless, C.L. & Fletcher, C.D. Monoclonal antibody DOG1.1 shows higher sensitivity than KIT in the diagnosis of gastrointestinal stromal tumors, including unusual subtypes. *Am J Surg Pathol* 33: 437–446.
- Mabille, M., Vanel, D. & Albitar, M. (2009). Follow-up of hepatic and peritoneal metastases of gastrointestinal tumors (GIST) under imatinib therapy requires different criteria of radiological evaluation (size is not everything!). *Eur J Radiol* 69: 204–208.
- Maeda, H., Yamagata, A. & Nishikawa, S. (1992). Requirement of c-kit for development of intestinal pacemaker system. *Development* 116: 369–375.
- Miettinen, M., El-Rifai, W., Sobin, L.H. & Lasota, J. (2002). Evaluation of malignancy and prognosis of gastrointestinal stromal tumors: a review. *Hum Pathol* 33: 478–483.
- Miettinen, M., Sobin, L.H. & Lasota, J. (2005). Gastrointestinal stromal tumors of the stomach: a clinicopathologic, immunohistochemical, and molecular genetic study of 1765 cases with long-term follow-up. *Am. J Surg Pathol* 29: 52–68.
- Miettinen, M., Makhoul, H. & Sobin, L.H. (2006). Gastrointestinal stromal tumors of the jejunum and ileum: a clinicopathologic, immunohistochemical, and molecular genetic study of 906 cases before imatinib with long-term follow-up. *Am J Surg Pathol* 30: 477–489.
- Miettinen, M., Sobin, L.H. & Lasota, J. (2009). True smooth muscle tumors of the small intestine: a clinicopathologic, immunohistochemical, and molecular genetic study of 25 cases. *Am J Surg Pathol* 33: 430–436.
- Nilsson, B., Bumming, P. & Meis-Kindblom, J.M. (2005). Gastrointestinal stromal tumors: the incidence, prevalence, clinical course, and prognostication in the preimatinib mesylate era—a population-based study in western Sweden. *Cancer* 103: 821–829.
- O’riain, C., Corless, C.L., Heinrich, M.C., Keegan, D. & Vioreanu, M. (2005). Gastrointestinal stromal tumors: insights from a new familial GIST kindred with unusual genetic and pathologic features. *Am. J Surg Pathol* 29: 1680–1683.
- Ozguc, H., Yilmazlar, T., Yerci, O., Soylu, R., Tumay, V & Filiz, G. (2005). Analysis of prognostic and immunohistochemical factors in gastrointestinal stromal tumors with malignant potential. *J Gastrointest Surg* 9: 418–429.
- Ponti, G., Losi, L., Martorana, D., Priola, M., Boni, E., Pollio, A., Neri, T.M. & Seidenari, S. (2011). Clinico-pathological and biomolecular findings in Italian patients with multiple cutaneous neurofibromas. *Hered Cancer Clin Pract* 12: 6–9.
- Prakash, S., Sarraf, L., Socci, N., DeMatteo, R.P. & Eisenstat, J. (2005). Gastrointestinal stromal tumors in children and young adults: a clinicopathologic, molecular, and

- genomic study of 15 cases and review of the literature. *J Pediatr Hematol Oncol* 27: 179–187.
- Prenen, H., Cools, J. & Mentens, N. (2006). Efficacy of the kinase inhibitor SU11248 against gastrointestinal stromal tumor mutants refractory to imatinib mesylate. *Clin Cancer Res* 12: 2622–2627.
- Reichardt, P., Reichardt, A. & Pink, D. (2011). Molecular targeted therapy of gastrointestinal stromal tumors. *Curr Cancer Drug Targets* 11: 688–697.
- Ricci, R., Arena, V. & Castri, F. (2004). Role of p16/INK4a in gastrointestinal stromal tumor progression. *Am J Clin Pathol* 122: 35–43.
- Romeo, S., Debiec-Rychter, M. & Van Glabbeke, M. (2009). Cell cycle/apoptosis molecule expression correlates with imatinib response in patients with advanced gastrointestinal stromal tumors. *Clin Cancer Res* 15: 4191–4198.
- Ronnstrand L. (2004). Signal transduction via the stem cell factor receptor/c-Kit. *Cell Mol Life Sci* 61: 2535–2548.
- Rutkowski, P., Nowecki, Z.I. & Michej, W. (2007). Risk criteria and prognostic factors for predicting recurrences after resection of primary gastrointestinal stromal tumor. *Ann Surg Oncol* 14: 2018–2027.
- Sabah, M., Cummins, R., Leader, M. & Kay, E. (2004). Loss of heterozygosity of chromosome 9p and loss of p16INK4A expression are associated with malignant gastrointestinal stromal tumors. *Mod Pathol* 17: 1364–1371.
- Schneider-Stock, R., Boltze, C. & Lasota, J. (2003). High prognostic value of p16INK4 alterations in gastrointestinal stromal tumors. *J Clin Oncol* 21: 1688–1697.
- Schneider-Stock, R., Boltze, C. & Lasota, J. (2005). Loss of p16 protein defines high-risk patients with gastrointestinal stromal tumors: a tissue microarray study. *Clin Cancer Res* 11: 638–645.
- Sherr, C.J. (2001). The INK4a/ARF network in tumour suppression. *Nat Rev Mol Cell Biol* 2: 731–737.
- Takahashi, T., Nakajima, K. & Nishitani, A. (2007). An enhanced risk-group stratification system for more practical prognostication of clinically malignant gastrointestinal stromal tumors. *Int J Clin Oncol* 12: 369–374.
- Taniguchi, M., Nishida, T., Hirota, S., Isozaki, K., Ito, T., Nomura, T., Matsuda, H. & Kitmura, Y. (1999). Effect of *c-kit* mutation on prognosis of gastrointestinal stromal tumors. *Cancer Res* 59: 4297–4300.
- Torihashi, S., Ward, S.M. & Sanders, K.M. (1997). Development of c-kitpositive cells and the onset of electrical rhythmicity in murine small intestine. *Gastroenterology* 12: 144–155.
- Tsukuda, K., Hirai, R., Miyake, T., Takagi, S., Ikeda, E., Kunitomo, T. & Tsuji, H. (2007) The outcome of gastrointestinal stromal tumors (GISTs) after a surgical resection in our institute. *Surg Today* 37: 953–957.
- Tworek, J.A., Goldblum, J.R., Weiss, S.W., Greenson, J.K. & Appelman, H.D. (1999). Stromal tumors of the abdominal colon: a clinicopathologic study of 20 cases. *Am J Surg Pathol* 23: 937–945.
- Ullrich, A. & Schlessinger, J. (1990). Signal transduction by receptors with tyrosine kinase activity. *Cell* 61: 203–212.
- Van den Abbeele, A.D. (2008). The lessons of GIST-PET and PET / CT: a new paradigm for imaging. *Oncologist* 13: 8–13.

- van Oosterom, A.T., Judson, I.R., Verweij, J., Stroobants, S., Dumez, H., Donato di Paola, E., Sciot, R., Van Glabbeke, M., Dimitrijevic, S. & Nielsen, O.S. (2002). European Organisation for Research and Treatment of Cancer Soft Tissue and Bone Sarcoma Group. Update of phase I study of imatinib (STI571) in advanced soft tissue sarcomas and gastrointestinal stromal tumors: a report of the EORTC Soft Tissue and Bone Sarcoma Group. *Eur J Cancer* 38 Suppl 5: S83-587.
- Wakai, T., Kanda, T., Hirota, S., Ohashi, A., Shirai, Y. & Hatakeyama, K. (2004). Late resistance to imatinib therapy associated with a second KIT mutation in metastatic gastrointestinal stromal tumour. *Br J Cancer* 90: 2059-2061.
- Wardelmann, E., Merkelbach-Bruse, S. & Pauls, K. (2006). Polyclonal evolution of multiple secondary KIT mutations in gastrointestinal stromal tumors under treatment with imatinib mesylate. *Clin Cancer Res* 12: 1743-1749.
- Wardelmann, E., Merkelbach-Bruse, S., Büttner, R. & Schildhaus, H.U. (2007). Activating mutations in receptor tyrosine kinases with relevance for treatment of gastrointestinal stromal tumors. *Verh Dtsch Ges Pathol* 91: 165-168.
- West, R.B., Corless, C.L., Chen, X., Rubin, B.P., Subramanian, S., Montgomery, K., Zhu, S., Ball, C.A., Nielsen, T.O., Patel, R., Goldblum, J.R., Brown, P.O., Heinrich, M.C. & van de Rijn, M. (2004). The novel marker, DOG1, is expressed ubiquitously in gastrointestinal stromal tumors irrespective of KIT or PDGFRA mutation status. *Am J Pathol* 165: 107-113.
- Wiebe, L., Kasza, K.E. & Maki, R.G. (2008). Activity of sorafenib (SOR) in patients (pts) with imatinib (IM) and sunitinib (SU)-resistant (RES) gastrointestinal stromal tumors (GIST): a phase II trial of the University of Chicago Phase II consortium. *J Clin Oncol* 26:553-557.
- Zalcberg, J.R., Verweij, J. & Casali, P.G. (2005). Outcome of patients with advanced gastrointestinal stromal tumours crossing over to a daily imatinib dose of 800 mg after progression on 400 mg. *Eur J Cancer* 41: 1751-1757.
- Zhang, Z., Zhang, R., Joachimiak, A., Schlessinger, J. & Kong, X.P. (2000). Crystal structure of human stem cell factor: implication for stem cell factor receptor dimerization and activation. *Proc Natl Acad Sci USA* 97: 7732-7737.

IntechOpen



Gastrointestinal Stromal Tumor

Edited by Prof. Raimundas Lunevicius

ISBN 978-953-51-0580-0

Hard cover, 120 pages

Publisher InTech

Published online 27, April, 2012

Published in print edition April, 2012

Almost 30 years have gone by since the postulation that GISTs derive from mesenchymal stem elements, and only 15 years have gone by since the definitive detection of origin of GISTs. Research in the last decade was more focused upon the justification of imatinib mezylate therapy in GISTs and clarification why a secondary resistance that occurred during the kinase inhibitors therapy. The era of therapy for GISTs, targeting the primary activating mutations in the KIT proto-oncogene; is being proclaimed as bringing the message of special importance to the pathologist role in multidisciplinary team that are responsible for treating patients with locally advanced or metastatic GIST. This is the first conclusive message forthcoming from this book. On the other hand, the book provides summarised and case-based knowledge on current management of gastrointestinal and extragastrointestinal stromal tumours. We hope that this book may be considered as a worthwhile timely addition to clinical science dissemination, medical education, further basic and clinical research.

How to reference

In order to correctly reference this scholarly work, feel free to copy and paste the following:

Roberta Zappacosta, Barbara Zappacosta, Serena Capanna, Chiara D'Angelo, Daniela Gatta and Sandra Rosini (2012). GISTs: From the History to the Tailored Therapy, Gastrointestinal Stromal Tumor, Prof. Raimundas Lunevicius (Ed.), ISBN: 978-953-51-0580-0, InTech, Available from:
<http://www.intechopen.com/books/gastrointestinal-stromal-tumor/gists-from-the-history-to-the-tailored-therapy>

INTech
open science | open minds

InTech Europe

University Campus STeP Ri
Slavka Krautzeka 83/A
51000 Rijeka, Croatia
Phone: +385 (51) 770 447
Fax: +385 (51) 686 166
www.intechopen.com

InTech China

Unit 405, Office Block, Hotel Equatorial Shanghai
No.65, Yan An Road (West), Shanghai, 200040, China
中国上海市延安西路65号上海国际贵都大饭店办公楼405单元
Phone: +86-21-62489820
Fax: +86-21-62489821

© 2012 The Author(s). Licensee IntechOpen. This is an open access article distributed under the terms of the [Creative Commons Attribution 3.0 License](https://creativecommons.org/licenses/by/3.0/), which permits unrestricted use, distribution, and reproduction in any medium, provided the original work is properly cited.

IntechOpen

IntechOpen