

# We are IntechOpen, the world's leading publisher of Open Access books Built by scientists, for scientists

6,900

Open access books available

185,000

International authors and editors

200M

Downloads

Our authors are among the

154

Countries delivered to

TOP 1%

most cited scientists

12.2%

Contributors from top 500 universities



WEB OF SCIENCE™

Selection of our books indexed in the Book Citation Index  
in Web of Science™ Core Collection (BKCI)

Interested in publishing with us?  
Contact [book.department@intechopen.com](mailto:book.department@intechopen.com)

Numbers displayed above are based on latest data collected.  
For more information visit [www.intechopen.com](http://www.intechopen.com)



# High Dose Rate Endobronchial Brachytherapy in Lung Cancer in Patients with Central Airway Obstruction

Alejandro B. Santini<sup>1</sup>, Benjamín G. Bianchi<sup>1</sup>,  
Dionis D. Isamitt<sup>2</sup>, Claudia C. Carvajal<sup>3</sup> and Gonzalo P. Silva<sup>3</sup>

<sup>1</sup>National Cancer Institute (INC), Santiago,

<sup>2</sup>National Thorax Institute (INT), Santiago,

<sup>3</sup>Los Andes University

<sup>1,2</sup>Chile

<sup>3</sup>Colombia

## 1. Introduction

The term brachytherapy derives from the Greek “brachys”, which means “short” or “close”. It is the branch of radiotherapy in which the radioactive source is located near the therapeutic target. The reported first use of endobronchial brachytherapy (EBBT) done by Yankauer in 1992<sup>1</sup>. He inserted Radon seeds directly into lung tumors through a rigid bronchoscope.

Recent technological development of brachytherapy equipment with small and high dose rate sources, clinical application of EBBT became safe, fast, remote, precise, and less invasive (Fig 1), expanding its indication and feasibility in symptomatic palliation and curative treatment.

One of the major role of EBBT is palliation of symptoms caused by endobronchial cancer ingrowth. Boost EBBT to endobronchial gross tumors combined with external beam radiotherapy (EBRT) provides not only palliative but curative possibilities<sup>2</sup>. In small endobronchial tumors EBBT is used as definitive curative treatment<sup>3</sup>. EBBT is also used for non-oncologic pathologies<sup>4,5</sup>. The majority of non-small cell lung cancer (NSCLC) found at loco-regionally advanced stage and frequently associated with bronchial obstruction. Various endoscopic techniques available today are including cryotherapy, stent, laser, photodynamic, and EBBT<sup>6,7</sup>. Among these EBBT is the only one that provides biologically tumoricidal effect keeping the normal tissue structure as is.

The National Institute for Cancer in Santiago, Chile (Instituto Nacional del Cáncer de Santiago de Chile) has had EBBT HDR since October 2004, and began treating patients in March 2006, along with the Bronchoscopy department in Chest National Institute. The purpose of this work is to analyze of the result obtained in our center in the palliation of symptoms related to the tumor obstruction of the airway, and literature review.

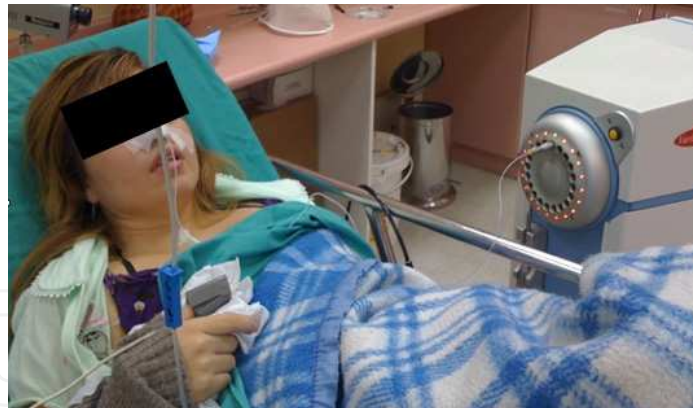

Fig. 1. Varisource Brachytherapy equipment (patient with a catheter in airway during treatment)

## 2. Patients, materials and methods

From March 2006 to November 2009, 27 patients were treated with 82 HDR-EBBT procedures as palliative treatment for advanced cancer.

The indication criteria for included: Being able to tolerate decubitus supine position that allows fiberrbronchoscopy examination(FBC), there were clear evidence of tumors with intraluminal component (with or without extrabronchial component), life expectancy of over 3 months, no immediately life-threatening airway obstruction , and healthy coagulating condition. All patients were clinically assessed and the symptoms were evaluated according to Speiser and Spratling<sup>8</sup>, recommended by American Brachytherapy Society (ABS), (table 1), prior to and one week after the end of the treatment.

Premedication including included sedatives, and local endobronchial anesthesia which were commonly used in usual FBC.

We used two equipment:

- Video bronchoscope Fujinon, model EB-270S working channel of 2.0 mm, flexible tube of 4.9 mm in diameter.
- Fibrobronchoscope Olympus, model BF-TE2 working channel of 2.8mm, flexible tube of 4.9 mm in diameter.

During FBC, the physician evaluated the percentage of luminal obstruction of the air way (table 2), repeating these evaluations after the following FBC.

At the first FBC, the extension of the lesion was measured: the anatomic potion of thee carina was used as reference point to measure lesion extension towards cranium or caudal. After confirmation of the precise target location that was recognized as clearly limited or demarcated, one or two endobronchial brachytherapy applicator catheters (Varian (metal-tipped 4.7, FR-150 cm long (PTFE) R)) were installed ,, with a radiopaque terminal that keeps its position by means of nasal fixing. After insertion of the catheter, or in advance, we used of codeine for managing cough caused by the dwelling catheters in the airway.

The HDR-EBBT planning was simulated on computer associated tomography (CAT) images. using planning computer ( Brachyvision system , Varian Medical Systems), which

was transferred to are mote high loading dose (iridium-192 source) brachytherapy equipment (VariSource iX, Varian Medical Systems). We prescribed 1 to 4 fractions of 7 to 7.5 Gy (range of total, 7 – 30Gy )at 1 cm depth point from the endobronchial surface-covering the macroscopic lesion with a safety margin of additional 1 cm (Figure 2). The fractional interval between brachytherapy session was 1 week. In patients with significant or complete bronchial obstruction, we applied electrofulguration before installing the catheter, or installed the catheter through the tumor stenosis/obstruction into the peripheral end. Both the catheter installation procedure by BFC and HDR-EBBT were performed in an outpatient setting. Patients were followed up and evaluated for effect and complications at next week of the last brachytherapy session and at the second month. .

Grade	Description
Dyspnea	
0	Without dyspnea
1	Dyspnea in moderate effort
2	Dyspnea in normal activity
3	Dyspnea in rest
4	Requires oxygen
Cough	
0	Without cough
1	Intermittent, no medication required
2	Intermittent, no narcotics required
3	Constant, narcotics required
4	Constant, not improved with narcotics
Hemoptysis	
0	Without hemoptisis
1	Less than twice a week
2	More than twice a week, but less an everyday
3	Daily, red bright blood or clot
4	Hemoglobin decreases and/or hematocrit in more than 10% or more than 150 ml. Requires to be admitted in hospital or transfusion of more than 2 U of red blood cells.

Table 1. Sympton's scale of American Brachytherapy Society (Speiser and Spratling)

Grades	Obstruction
G0	Without evidences of obstruction
G1	Equivalent or less than 25% of obstruction
G2	Obstruction between 25-75%
G3	Obstruction more than 75%
G4	Full obstruction

Table 2. Grade of obstruction

3. Results

Patient consisted of 15 men and 12 women and their age ranged 32-85 years old. The most frequent histologic cancer type was NSCLC, with the main subtype being squamous carcinoma (40%). 7 patients (26%) were previously treated with palliative radiotherapy:(5 patients received 40 Gy in 20 fractions, one received 30 Gy in 10 fractions, one 20 Gy in 5 fractions and the other one 8 Gy in 1 fraction.. At the time of EBBT no patients were receiving concomitant chemotherapy, while a few received chemotherapy previously for relapsed tumor. Table 3 summarizes the characteristics of the 27 patients who received HDR-EBBT.

Lesion location, extent and degree of airway obstruction are described in Table 3 and Figure 3. With this treatment, a significant improvement was observed in every evaluated symptom (hemoptysis, cough, dyspnea and obstruction). Table 4 compares symptomatic scores before and 1 week after treatment. One patient did not complete treatment for personal reasons, and another one died secondary to a hemorrhagic complication from the contralateral bronchial tree. Thus 25 patients were evaluable for dyspnea, hemoptysis and cough. 22 patients underwent bronchoscopic reevaluation for degree of obstruction after treatment: One patient with significant clinical improvement refused the reevaluation.

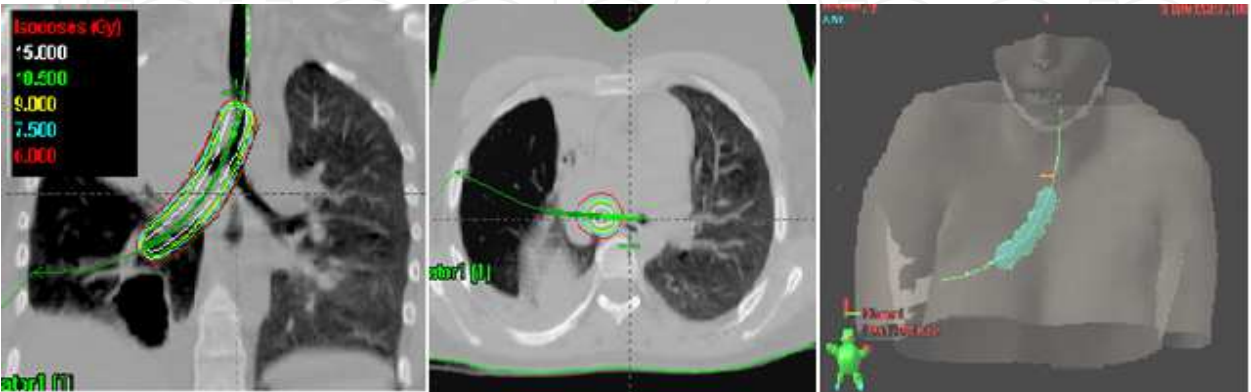


Fig. 2. Dose distribution of a treatment planning to main left bronchus lesion causing left superior lobar atelectasis. Thick green line: catheter in treatment position: Cayn cloured contur between red and yellow indicates 100% of the prescribed dose .

Variables	Number (%)
Age (years)	
Mean ± standard deviation	63,07 ± 12,95
Sex	
Male	15 (56%)
Female	12 (47%)
Diagnosis	
Lung Cancer	21(78%)
Amyloidosis	1 (3%)
Esophageal Cancer	1 (3%)
Renal cancer	3 (12%)
Bronchial carcinoid	1 (3%)
Cancer Histology	
Adenocarcinoma	10 (37%)
Epidermoid	11 (40%)
Undifferentiated NSCLC	1 (3%)
Bronchial carcinoid	1 (3%)
CP large cell	1 (3%)
Small cell CP	1 (3%)
Cancer Stages	
IIIA	1 (4%)
IIIB	7 (28%)
IV	16 (64%)
Relapses	1 (4%)
Location	
Right bronchus	18 (66%)
Left bronchus	11 (40%)
Carina	14 (51%)
Trachea	4 (14%)
Palliative external beam radiotherapy (overprint)	8 (30%)

Total number of staged patinets is 26 because eliminating a patients with benign concurrent disease. Most of the patients had more than one location.

Table 3. This table summarizes the characteristics of the 27 patients who underwent endobronchial brachytherapy high doses (HDR-EBBT)

Variable	Degree of symptoms	Prior to the EBBT n patients (%)	Post to the EBBT n° patients (%)
Dyspnea	G0	3 (11,1%)	10 (37%)
	G1	2 (7,4%)	13 (48,1%)
	G2	13 (48,1%)	2 (7,4%)
	G3	8 (29,6%)	0
	G4	1 (3,7%)	0
Hemoptysis	G0	4 (14,8%)	25 (92,6%)
	G1	3 (11,1)	0
	G2	9 (33,3%)	0
	G3	11 (40,1%)	0
	G4	0	0
Obstruction	G0	1 (3,7%)	9 (33,3%)
	G1	4 (14,8%)	12 (44,4%)
	G2	11 (40,07%)	1 (3,7%)
	G3	8 (29,6%)	0
	G4	3 (11,1%)	0
Cough	G0	3 (11,1%)	9 (33,3%)
	G1	2 (7,4%)	13 (48,1%)
	G2	9 (33,3%)	3 (11,1%)
	G3	13 (48,1%)	0
	G4	0	0

Table 4. Patient symptoms according to the Speiser-Spratling scale before and after HDR-EBBT

Symptomatic improvement was observed in all hemoptysis condition, 40% of dyspnea, and 25% coughing condition after treatment. After treatment, no patient had G3 or G4 symptoms.

The EBBT procedure was well tolerated, with no acute complications registered. Two months after treatment, two patients (7%) had significant hemoptysis and bronchoscopic examination revealed these bleeding were originated from different locations.. One patient discontinued treatment because of personal choice.

The average treated volume (100% isodose) was 38.1 cm<sup>3</sup>(SD ± 15.4)(this shows the smallness of the irradiated tissue volume with this technique)



## 4. Discussion

The HDR-EBBT provides rapid and significant symptomatic improvement of related to main airway obstruction when the selection of patients is adequate. Our results are consistent with that reported previously (Table 5). These excellent results, with the progress in radioisotope security issue and the outpatient treatment possibility owing to recent decade's technological advances, have made EBBT one of the major applications of brachytherapy in several nations<sup>16</sup>.

Currently, EBBT is a part of the therapeutic arsenal in interventional bronchoscopy, being complementary to other techniques such as cryotherapy, laser, photodynamic, stents and argon plasma<sup>17</sup>.

### *EBBT Indications*

There are several comprehensive publications that develop the indications and treatments techniques<sup>6, 18,19</sup>.

According to the recommendations of the ABS (American Brachytherapy Society)<sup>18</sup> and the ESTRO (European Society of Therapeutic Radiology and Oncology)<sup>19</sup> indications could be divided into: Palliative treatment, healing and non-oncologic pathology.

### **1. Palliative treatment**

Patients with large endobronchial tumors which cause symptoms such as dyspnea due to obstruction, cough, bleeding, or post obstructive pneumonia, represent the most common EBBT indication. Contrary, those tumors that cause obstruction mainly due to extrinsic airway compression would not be candidates for this treatment. Patients with critical obstruction and airway compromise are not recommended for exclusive use of this technique, but it can be used after initial treatment with laser, cryotherapy, stents or electrocautery<sup>20, 21</sup> with great results and ostensible improvement in quality of life.

According to Nag<sup>18</sup>, the EBBT might be more effective than a two or three weeks treatment with external beam radiotherapy (EBRT), indicated at first instance, in patients with life expectancy greater than three months that are not candidates for surgery or EBRT due to poor lung function after radiation therapy. Kelly et al, from MD Anderson, discussed their 10 years' experience with EBBT<sup>11</sup>. These authors treated a group of patients with the worst prognosis. Given that, two thirds had already received palliative EBRT. However, they got a 66% improvement of symptoms. Escobar-Sacristán et al, from the Military Hospital of Madrid, reported 85 patients with symptomatic advanced lung cancer who received 288 EBBT applications with 85% partial improvement in symptoms (cough, dyspnea, hemoptysis, and obstruction) and 60% complete responses using endoscopic EBBT<sup>22</sup>.

The treatment schedule, i.e., the dose and the number of applications vary in different sites and authors as shown in Table 5. When treatment is performed exclusively, most publications have suggested dose and fractionation schemes between 15 and 35 Gy in one to five applications, calculated within 1 cm from the source. However, more recent studies recommended not exceeding 30 Gy with EBBT<sup>19</sup>. The ABS recommends 3 fractions of 7.5 Gy, two of 10 Gy or four of 6 Gy. These fractions have the same radiobiological equivalent according to the linear quadratic model<sup>23</sup>, and the results are very similar<sup>7,13,24-26</sup>.



Authors	N° of patients	Dose and fraction	Results
Macha et al <sup>9</sup>	365	5 Gy/3-4f	66% obstructive symptoms improvement
Muto et al <sup>10</sup>	320	GROUP A 10 Gy/1f GROUP B 7 Gy/2f GROUP C 5 Gy/3f	94% hemoptysis and 90% dyspnea reduction, 70% performance status improvement
Kelly et al <sup>11</sup>	175	15 gy/1f	66% symptoms and 85% endoscopic lesions improvement
Petra et al <sup>12</sup>	67	5-7 Gy/1-2f	90% symptoms and 85% endoscopic lesion reduction
Celebioglu et al <sup>13</sup>	95	7-10 Gy/1-3f	Significant reduction of symptoms, hemoptysis, dyspnea and cough
Delclos et al <sup>14</sup>	81	15 Gy/1f	62% symptomatic improvement
Anacak et al <sup>15</sup>	28	7 Gy/3f	43% in cough, 80% in dyspnea and 95% in hemoptysis Improvements
Speicer and Spratling <sup>8</sup>	151	7 Gy/2-3f	99% of hemoptysis, 86% of dyspnea and 85% of cough improvements

Table 5. Published results of HDR endobronchial brachytherapy as palliative treatment

2. Curative treatment

EBBT has been used in curative treatment of lung cancer, both in the exclusive treatment of early tumors with EBRT as overprint (boost or reirradiation)<sup>2 3</sup>. About the first indication, Marsiglia et al, reported a two year survival rate of 78% in 34 patients with small tumors without evidence of spread that were treated only with HDR-EBBT with a 30 Gy dose in 6 fractions<sup>3</sup>.Hennequin et al, in a series of 106 patients with localized tumors that were not candidates for surgery or EBRT, obtained a specific 3 and 5 years survival of 60% and 50% respectively<sup>2</sup>.The ABS recommended a healing (palliative) dose is 3 fractions of 5 to 7.5 Gy (total 15 – 22.5Gy) when the patient already received 60 Gy pretreatment with EBRT, and 5 to 6 fractions of 5 to 7 Gy (total 25 – 42 Gy) if this treatment is exclusively used <sup>17</sup>.

3. Non-oncologic pathology treatment

Several authors have published interesting experiences regarding the use of EBBT in non-malignant pathology. This treatment modality has been used successfully in patients with granulomatous proliferation after metal stent placement because of non-malignant airway stenosis, or pulmonary transplant patients<sup>4,5</sup>.

In patients who have not received EBRT it is feasible to use the combination of EBBT and EBRT in order to improve results. In a randomized study, the combination of those treatments proved to be more effective than single-EBRT in symptomatic improvement<sup>27</sup>. Mantz and colleagues, obtained a significant increase in local control when using a EBBT

boost or overlay to EBRT compared to exclusively use of EBRT (58 versus 32% at 5 years, respectively)<sup>28</sup>.

We understand that the EBRT is preferred as a palliative treatment when the airway compression is extrinsic, when EBBT is not indicated. In patients with tumors, with an intrinsic component in the airway lumen, Kelly and colleagues from MD Anderson, say that one of the advantages of HDR-EBBT would be the shorter treatment time<sup>11</sup>.


## 5. Conclusion

The HDR-EBBT is a useful technique in the symptomatic treatment of ambulatory patients with central airway obstruction. The procedure is well tolerated and effective with low complications rate. Main indications are patients with advanced lung cancer, where the objective is only palliative. It must also be considered in situations of incipient tumors for patients with contraindications for surgery or EBRT, boosted after a first treatment with EBRT or in benign disease with endobronchial or endotracheal scar proliferation.

## 6. References

- [1] Yankauer S. Two cases of lung tumour treated bronchoscopically. *NY Med J* 1922;115:741-742
- [2] Hennequin C, Bleichner O, Trédaniel J y col. Long term results of endobronchial brachytherapy: a Curative treatment? *Int J radiat Oncol Biol Phys* 2007;67(2):425-30.
- [3] Marsiglia H, Baldeyrou P, Larigau E, Brioth E, Haie C, Le chevalier L y col. High Dose Rate Brachytherapy as sole Modality for early stage Endobronchial carcinoma. In *J Radiat Oncol Biol Phys* 2000;47(3):665-672
- [4] Kramer MR, Kats A, Yarmolowsky A y col. Successful use of high dose rate brachytherapy for non-malignant bronchial obstruction. *Thorax* 2001;56:415-416
- [5] Brenner, M. R. Kramer, A. Katz, R. Feinmesser, y col. High Dose Rate Brachytherapy for Nonmalignant Airway Obstruction: New Treatment Option. *Chest*, 2003; 124(4): 1605 - 1610.
- [6] Vergnon JM, Huber RM and Moghissi K. Place of cryotherapy, brachytherapy and photodynamic therapy in therapeutic bronchoscopy of lung cancers. *Eur Eespir J* 2006;28;200-18
- [7] Cavaliere S, Ventura F, Foccoli P y col. Endoscopic treatment of malignant airway obstruction in 2008 patient *CHEST* 1996;110.1536-42
- [8] Speiser BL, Sparring L. Remote afterloading brachytherapy for local control of endobronchial carcinoma. *Int J Radiat Oncol Biol Phys* 1993;25:579-87
- [9] Macha HN, Wahlers B, Reichle C y col. Endobronchial radiation therapy for obstructing malignancies. Ten years experience with IR192 hiagh-Dose-radiation Brach therapy afterloading technique in 365 patients. *Lung* 1999;173:274-80
- [10] Muto P, Ravo V, Pannelli C y col. High-Dose-rate brachytherapy of bronchial cancer: treatment optimization using thee schemes of therapy. *The Oncology* 2000;5:209-14
- [11] Kelly J, Delclos M, Morice R Y col. High-Dose.rate Endobroncial Brachytherapy afterloading palliative symptoms due to airway tumor. The ten years MD Anderson Cancer Center experience *Int J Radiat Oncol Biol Phys* 2000;48(3):697-702

- [12] Petera J, Spasora I, Neumanova R y col. High-Dose-Rate Intraluminal brachytherapy in treatment of malignant airway obstruction. *Neoplasma* 2001;48:148-153
- [13] Celebioglu B, Ural Gurkan O, Erdogan S y col. High dose rate endobronchial brachytherapy effectively palliates symptoms due to inoperable lung cancer. *Jpn J Clin Oncol* 2002;32(11);443-48
- [14] Delclos ME, Komaki R, Morice RC y col. Endobronchial brachytherapy with High-Dose-Rate Remote afterloading for recurrent endobronchial lesion. *Radiology* 1996;201:279-282
- [15] Anacak Y, Mogulkoc N, Ozkok S y col. High dose rate endobronchial brachytherapy in combination with external beam radiotherapy for stage III non-small cell lung cancer. *Lung cancer* 2001;34:253-259
- [16] The Royal College of Radiologists. The Role and development of brachytherapy service in United Kingdom. London : the Royal College of Radiologists, 2007
- [17] Janssen JP, Noppen M and Rabe KF. Place of cryotherapy, brachytherapy and photodynamic therapy in therapeutic bronchoscopy of lung cancer. *Eur Respir J* 2006;28:200-18
- [18] Nag A. Brachytherapy for carcinoma of the lung. *Oncology* 2001;15(3): 371-81
- [19] Van Limbergen E and Pötter R. Bronchus cancer in: Gerbaulet A, Potter R, Van Limbergen E, Mazon JJ and Meertens H: GEC - ESTRO handbook of brachytherapy. ACCO, Belgium 2002
- [20] Freitag L, Emst E, Thomas M y col. Sequential Photodynamic therapy and HDR brachytherapy for endobronchial tumor control in patients with limited bronchogenic carcinoma. *Thorax* 2004;59:790-93
- [21] Wang Jan T, Blackman G, George J. Survival benefits of lung cancer patients undergoing Laser and Brachytherapy. *J Korean Med Sci* 2002;17:341-7
- [22] Escobar-Sacristán JA, Granada-Orive J, Gutierrez T y col. Endobronchial brachytherapy in the treatment of malignant lung tumors. *Eur resp J* 2004;24:348-52
- [23] Mehta M, Petereit D, Ghosy L y col. Sequential comparison of low-dose rate and hyperfractionated high-dose rate endobronchial radiation for malignant airway occlusions. *Int J Radiat Oncol Biol Phys* 1992;23(1):133-39
- [24] Mallick I, Sharma S and Behera D. Endobronchial brachytherapy for symptom palliation in non-small cell lung cancer - Analysis of symptom response, endoscopic improvement and quality of life. *Lung Cancer* 2007;55:313-318
- [25] Bedwinek J, Petty A, Burton C y col. The use of high dose rate endobronchial brachytherapy to palliate symptomatic endobronchial recurrence of previously irradiated bronchogenic carcinoma. *Int J Radiat Oncol Biol Phys* 1992;22:23-30
- [26] Lu JJ, Bains Y, Aaron B y col. High dose rate endobronchial brachytherapy for the management of non-small cell lung cancer with an endobronchial or peribronchial component. *Cancer Therapy* 2004;2:469-74
- [27] Huber RM, Fischer R, Hautman H Y col. Does additional brachytherapy improve the effect of external irradiation? A prospective randomized study in central lung tumors *Int J radiat Oncol Biol Phys* 1997;38:53-540
- [28] Mantz C, Dosoretz E, Rubeinstein H y col. Endobronchial brachytherapy and optimization of local disease control in medically inoperable non-small cell lung carcinoma: A matched-pair analysis. *Brachytherapy* 2004;3:183-190



## **Brachytherapy**

Edited by Dr. Kazushi Kishi

ISBN 978-953-51-0602-9

Hard cover, 128 pages

**Publisher** InTech

**Published online** 25, April, 2012

**Published in print edition** April, 2012

Importance of brachytherapy is currently increasing in cancer therapy. In brachytherapy each treatment is best fitted by physician's hand, and appropriate arrangement and selection of radiation sources facilitates the fitting. This book is full of essences to make a breakthrough in radiation oncology by brachytherapy. I hope this book will encourage all people related. Contents 1: problem of currently popular dosimetric method; 2: Monte Carlo dose simulation of ruthenium-106/rhodium-106 eyes applicators; 3. Progress in Californium-252 neutron brachytherapy; 4. Clinical aspect of endobronchial brachytherapy in central airway tumor obstruction; 5. Review from principle and techniques of Iodine-125 production at nuclear reactor plant to their clinical practice in prostate cancer treatment; 6. Stereotactic Brachytherapy for Brain Tumors using Iodine-125 seed; 7. A brachytherapy procedure with organ-sparing hyaluronate gel injection for safe and eradicated reirradiation.

### **How to reference**

In order to correctly reference this scholarly work, feel free to copy and paste the following:

Alejandro B. Santini, Benjamín G. Bianchi, Dionis D. Isamitt, Claudia C. Carvajal and Gonzalo P. Silva (2012). High Dose Rate Endobronchial Brachytherapy in Lung Cancer in Patients with Central Airway Obstruction, Brachytherapy, Dr. Kazushi Kishi (Ed.), ISBN: 978-953-51-0602-9, InTech, Available from: <http://www.intechopen.com/books/brachytherapy/the-role-of-brachytherapy-in-the-management-of-advanced-lung-cancer>

**INTECH**  
open science | open minds

### **InTech Europe**

University Campus STeP Ri  
Slavka Krautzeka 83/A  
51000 Rijeka, Croatia  
Phone: +385 (51) 770 447  
Fax: +385 (51) 686 166  
[www.intechopen.com](http://www.intechopen.com)

### **InTech China**

Unit 405, Office Block, Hotel Equatorial Shanghai  
No.65, Yan An Road (West), Shanghai, 200040, China  
中国上海市延安西路65号上海国际贵都大饭店办公楼405单元  
Phone: +86-21-62489820  
Fax: +86-21-62489821

© 2012 The Author(s). Licensee IntechOpen. This is an open access article distributed under the terms of the [Creative Commons Attribution 3.0 License](https://creativecommons.org/licenses/by/3.0/), which permits unrestricted use, distribution, and reproduction in any medium, provided the original work is properly cited.

IntechOpen

IntechOpen