

We are IntechOpen, the world's leading publisher of Open Access books Built by scientists, for scientists

6,900

Open access books available

185,000

International authors and editors

200M

Downloads

Our authors are among the

154

Countries delivered to

TOP 1%

most cited scientists

12.2%

Contributors from top 500 universities



WEB OF SCIENCE™

Selection of our books indexed in the Book Citation Index
in Web of Science™ Core Collection (BKCI)

Interested in publishing with us?
Contact book.department@intechopen.com

Numbers displayed above are based on latest data collected.
For more information visit www.intechopen.com



Skills in Minor Surgical Procedures for General Practitioners

Jose María Arribas Blanco and María Hernández Tejero
*Faculty of Medicine, Autonomous University of Madrid, Madrid,
Spain*

1. Introduction

Minor surgery is defined as a set of procedures in which short surgical techniques are applied on superficial tissues. Local anaesthesia is often required for these procedures and their complication-rate as well as the risk involved is low.

Lesions and problems requiring these procedures for diagnostic or therapeutical reasons are frequently seen by general practitioners both in the outpatient setting (excision of skin lesions, for instance) as well as in the emergency care setting (wound suturing, for example). Therefore, for family doctors proficiency in minor surgical procedures is an additional tool for good medical practice and acquiring skills in minor surgical procedures has become a critical part of medical training, and has adjusted their professional profile to the problems and needs arising in the daily practice of family medicine.

Achieving clinical excellence in these procedures depends on the involved practitioner's level of technical training, since surgical training is the best way to learn the correct surgical gestures and proper use of surgical instruments. Trainees must also understand that a sound diagnostic approach plus the observance of basic principles of good medical practice are prerequisites for clinical excellence in their practice of minor surgical procedures

It is shown that the performance of minor surgery in primary care is good for patients, for health care system and for the practitioner; In addition to being fun and rewarding. However, those procedures are not without risks, both during surgery and afterwards. Therefore, any surgical procedure performed by the family physician, is necessary (in addition to proper surgical technique and appropriate therapeutic indications) provide a comprehensive, clear and complete information to the patient, which will be reflected with the Informed Consent signed by the patient before carrying out any minor surgical intervention. The realization of Informed Consent is not a guarantee of exculpate in the event of a judicial proceeding by a complaint from a medical act of minor surgery. The judge will assess good medical practice and clinical experience based on the *lex artis* (proper patient selection and indications for its implementation, use of good surgical technique ..). Therefore, and although the academic programs of the Family Medicine Specialty explicitly enable the family doctor to perform minor surgical procedures, it is recommended that primary care physicians have medical insurance with specific coverage for surgical techniques.

This chapter will try and help general practitioners master minor surgical procedures by answering the following questions:

1. Where should general practitioners perform minor surgical procedures?
Optimal infrastructure and medical furniture for a Minor Surgery operating room and doctor's preparation
2. Which are the instruments and materials involved?
Surgical instruments (plus their handling) and suture materials for basic and advanced surgery.
3. How to perform minor surgical procedures in the primary care setting?
Anaesthesia techniques: local anaesthetic infiltration and regional blocks
Basic and Advanced Surgical Techniques in Minor Surgery
4. Preoperative considerations
Body areas of risk in minor surgery. Basic knowledge of the topographic anatomy of the skin. The most common pathologies in minor surgery: diagnostic criteria
5. Performance of the surgical procedure
Elliptical excision
6. Good clinical practice in minor surgery and complications in minor surgery.

2. The minor surgery room and physician's preparation

2.1 The minor surgery room

Minor surgical procedures do not involve very sophisticated devices. However, some basic requirements in terms of infrastructure and equipment must be met^{1,2}.

Although some minor surgical procedures could be performed in a consulting room or office in the primary care setting, it is recommended that each facility has a specific room for these procedures. This room (Fig 1) must include:

Surgical room: a well-ventilated, square or rectangular, 15-20 square-meter room is necessary, with a suitable temperature and a good source of artificial light. It is imperative that it is clean, but it does not require sterile isolation. The surgical room should be cleaned properly at the end of the surgical session, particularly after contaminated procedures (e.g. abscesses). Having a room exclusively dedicated to surgical procedures is ideal, but a well-equipped treatment room is acceptable. It is advisable to have a sink with a mixer tap control plus an automatic soap applicator for hand washing.

Operating table: it should be located in the centre of the room to allow easy access from both sides. Height-adjustable, articulated tables are preferred. It should be of washable material. In any case, it is essential to have a table that allows the doctor to work in comfort, both standing and sitting. Low beds used for physical examination are not acceptable, since doctors will be forced to work in awkward positions.

Doctor's stool: long procedures are best performed in a sitting position. A height-adjustable stool on wheels is, therefore, necessary.

Side Table: it is used to place the surgical instruments and material used during the surgery. It must have wheels and be height-adjustable, and it should be placed near the

surgical field, facilitating the procedure. Placing surgical material on the patient must be avoided, to prevent it from falling in case the patient moves during the procedure.

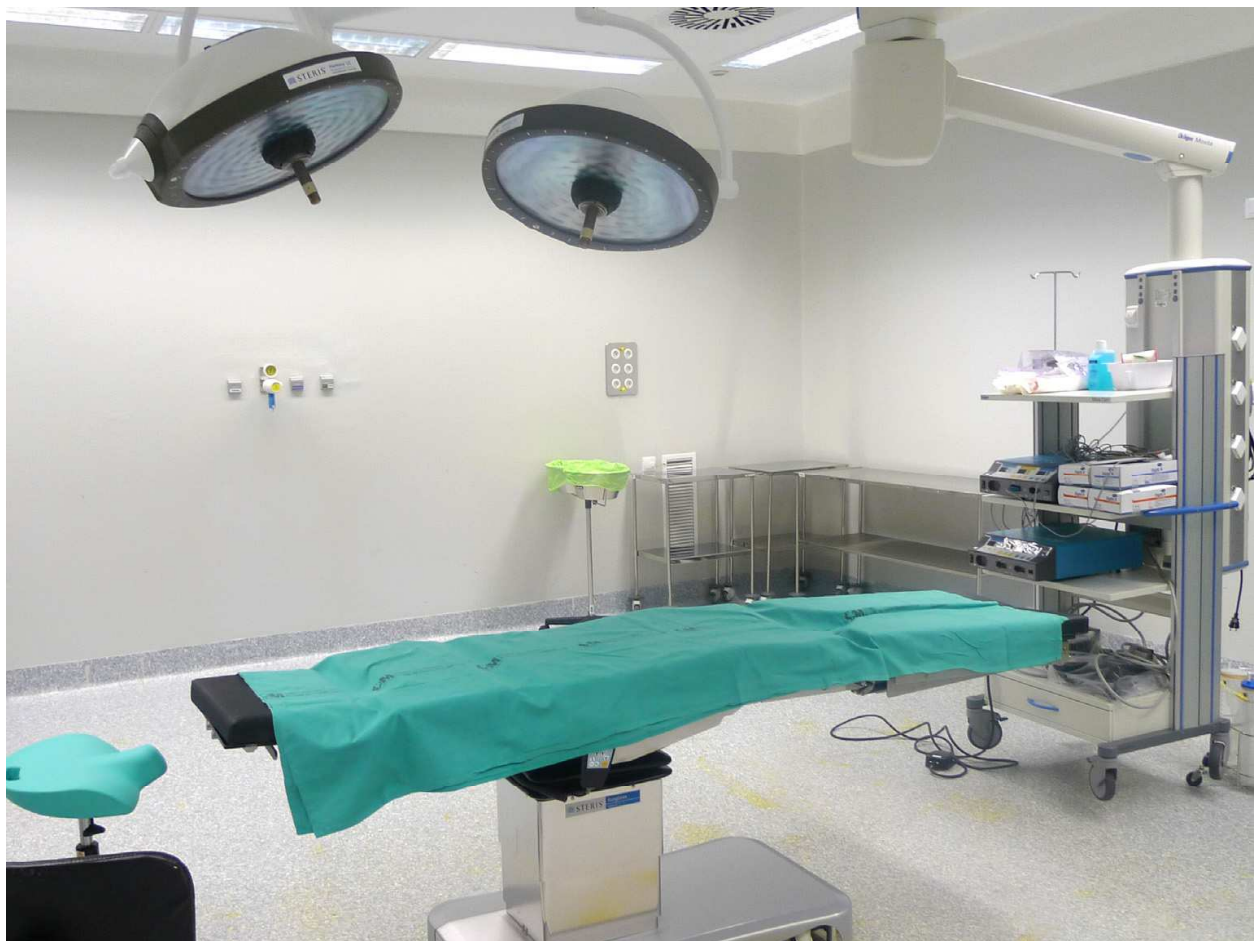

Fig. 1. Well-equipped Room of Minor Surgery.

Lamp: it must provide adequate lighting with, at least, 45,000 lux of illuminance. Lamps may be fixed to the wall or ceiling of the room but portable lamps with wheels are also acceptable. These lamps can be moved in several directions, their light intensity can be modulated and their spotlight can be focused. It is advisable to have another auxiliary lamp with a magnifying glass, which will be useful for removing foreign bodies or working under magnification.

Showcase and containers: some space should also be left for storing consumables and surgical instruments. There should also be properly marked containers for bio contaminated material, and a disposal system in accordance with current health legislation.

Resuscitation equipment: although life-threatening events are extremely rare in minor surgery, it is nonetheless essential to have a crash trolley with cardiopulmonary resuscitation equipment, including material for vascular access, airway intubation, saline, drugs for resuscitation (e.g. epinephrine, atropine, bicarbonate) and a defibrillator.

Sterilization system: any medical facility performing surgical procedures must have an autoclave to sterilize surgical equipment or set up an external circuit to sterilize the material.

2.2 Physician's preparation for minor surgery

Performing minor surgical procedures carries some risk of transmission of infectious diseases (such as HCV and HIV), both from patient to doctor and vice versa. To minimize this risk, universal precautions should be adopted and applied by all physicians performing invasive procedures to any patient regardless of their serological status. These measures include the use of appropriate clothing and accessories and proper hand washing as well as sterile technique for surgical glove placement.

Surgical attire: In minor surgical procedures we consider essential the use of surgical shirts and trousers ("scrubs") or gowns and sterile gloves. The use of surgical masks and eye goggles is considered highly desirable. Disposable gowns are very useful.

Hand washing: There are different methods of surgical scrubbing. Hygienic scrubbing involves using a normal soap solution (no brush) and washing thoroughly all skin folds for at least 20 seconds and is appropriate for all minor surgical procedures. Anatomic scrubbing is left for major surgery.

Time span from scrubbing to glove placement should never exceed 10 minutes.

Sterile glove placement: surgical gloves are sterile and single use and are available in various sizes. Some manufacturers use a numerical sizing (from 6 ½ to 8 ½) while others use an alphanumeric sizing (XS, S, M, L, XL). There are models with and without latex as well as powder-free models.

Glove placement should be completed without contaminating the outer surface of the glove, i.e. the inner or powdered part of the glove can be touched with the hands, while the outer or non-powdered surface should only be touched with the other glove.

Unquestionably, gloves act as a barrier against body fluids from accidental cuts or punctures. In some surgeries with increased risk of glove perforation the use of double gloves is recommended, because it decreases the risk of perforation and, therefore, the risk of patient to doctor contamination.

3. Surgical instruments (handling) and suture material

3.1 surgical instruments for minor surgery

General practitioners should have a thorough knowledge of surgical instruments, including their handling and maintenance. The quality, condition and type of instruments used in any procedure can affect its outcome. Choosing the right instruments for each surgical intervention is, therefore, an important issue¹.

In the following paragraphs we will briefly describe the main features of the instruments recommended for minor surgical procedures.

Scalpel: it allows the surgeon to cut with precision through the skin and other tissues and is also used for non-blunt dissection.

A number 3 handle with number 11 and 15 blades must be available. The scalpel blade is installed on the handle in a unique position, matching the blade guide with the handle guide. The scalpel is handled with the dominant hand like a pencil (fig. 2), allowing small

and precise incisions. The hand should be partially supported on the working surface to increase precision. Using the contralateral hand the skin should be tightened perpendicularly to the direction of the incision. The blade should cut the skin perpendicularly (bevelled incisions should be avoided), except in hairy areas (scalp or eyebrows) where the incision should be parallel to the hairshafts, to avoid damaging the follicles.

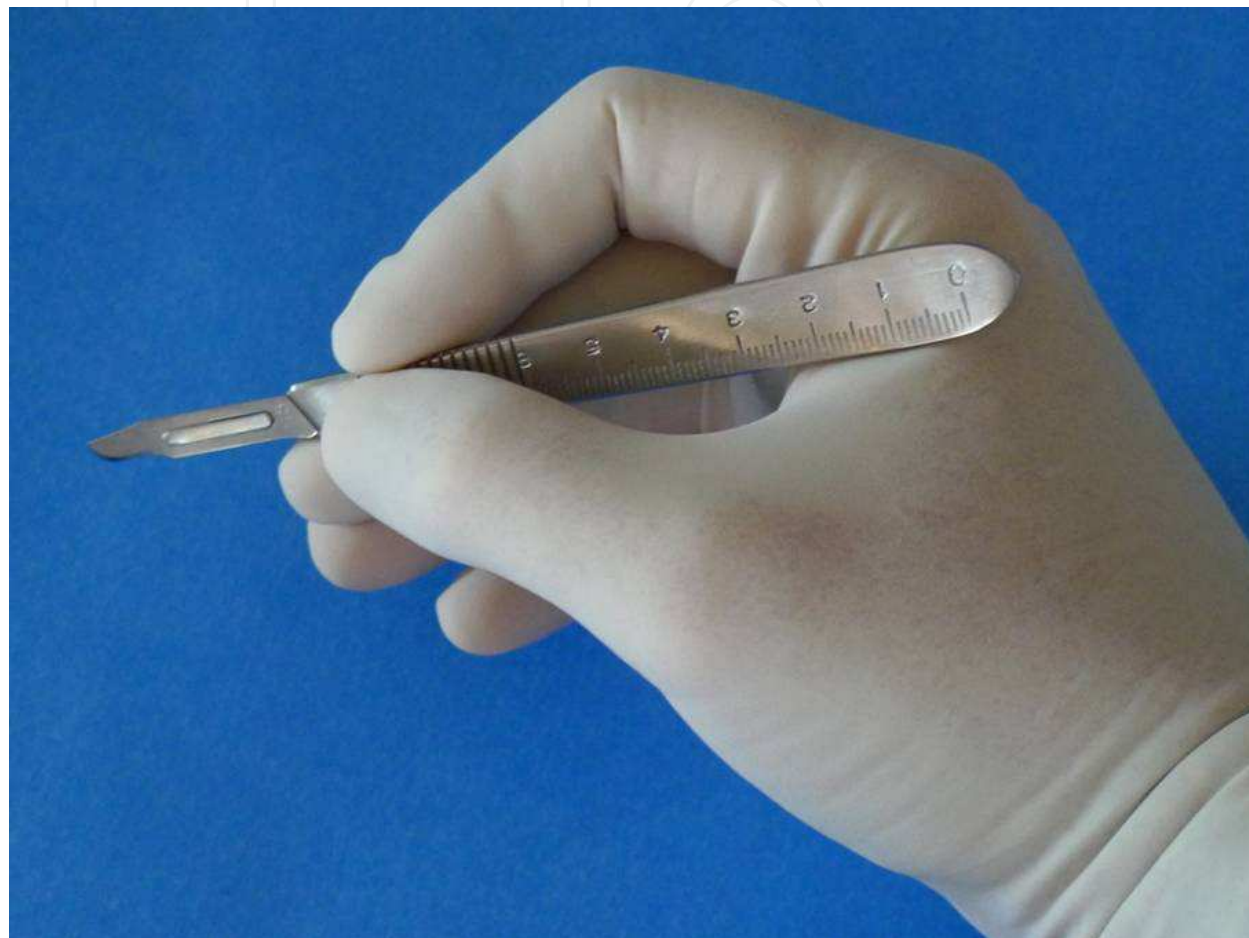


Fig. 2. Correct way of managing of the scalpel

Scissors: they are used both for cutting or sectioning tissues and different materials such as sutures, drains, and bandages, and dissecting through different tissues.

A 14 cm. long curved blunt May scissors (cutting scissors) and an 11.5 cm curved blunt Metzenbaum scissors (dissecting scissors) should be available. The use of dissecting scissors for cutting materials is not recommended.

Scissors are handled by inserting part of the distal phalanges of the thumb and fourth finger into the rings, and then supporting the second finger on the branches of the instrument. For blunt dissection (using Metzenbaum scissors), scissors are inserted with the tip closed and are then opened, separating the tissues in more or less anatomical layers. For sharp dissection scissors are inserted with the tip open and the blades are then closed, cutting the tissue.

Dissection manoeuvres should be performed gently and with a good exposure of the surgical field, never in a blind fashion, to avoid irreversible damage to anatomical structures. To this aim, it is essential to know the topographic anatomy of the operative site.

Needle-holder: needle-holders are meant to hold curved needles while stitching. Their jaws are especially designed to hold needles safely and atraumatically. The needle is held 2/3 of the way back from its point. A small or medium (12 to 15 cm.) standard needle holder with a tip suitable for needles up to 4/0 is recommended. Long needle holders are not recommended for minor surgeries.

Like other instruments with rings, the needle holder is handled by inserting a portion of the distal phalanges of the thumb and fourth finger of the dominant hand into the rings, while the index finger is directed towards the tip of the instrument (Fig 3). When performing the suture, the needle holder should describe a prono-supination movement to facilitate the passage of the needle through the tissues. The angle of entry of the needle into the skin should be 90 ° for a proper edge eversion of the wound. The non-dominant hand holds the skin with a dissecting forceps or a retractor, to oppose the pressure of the needle

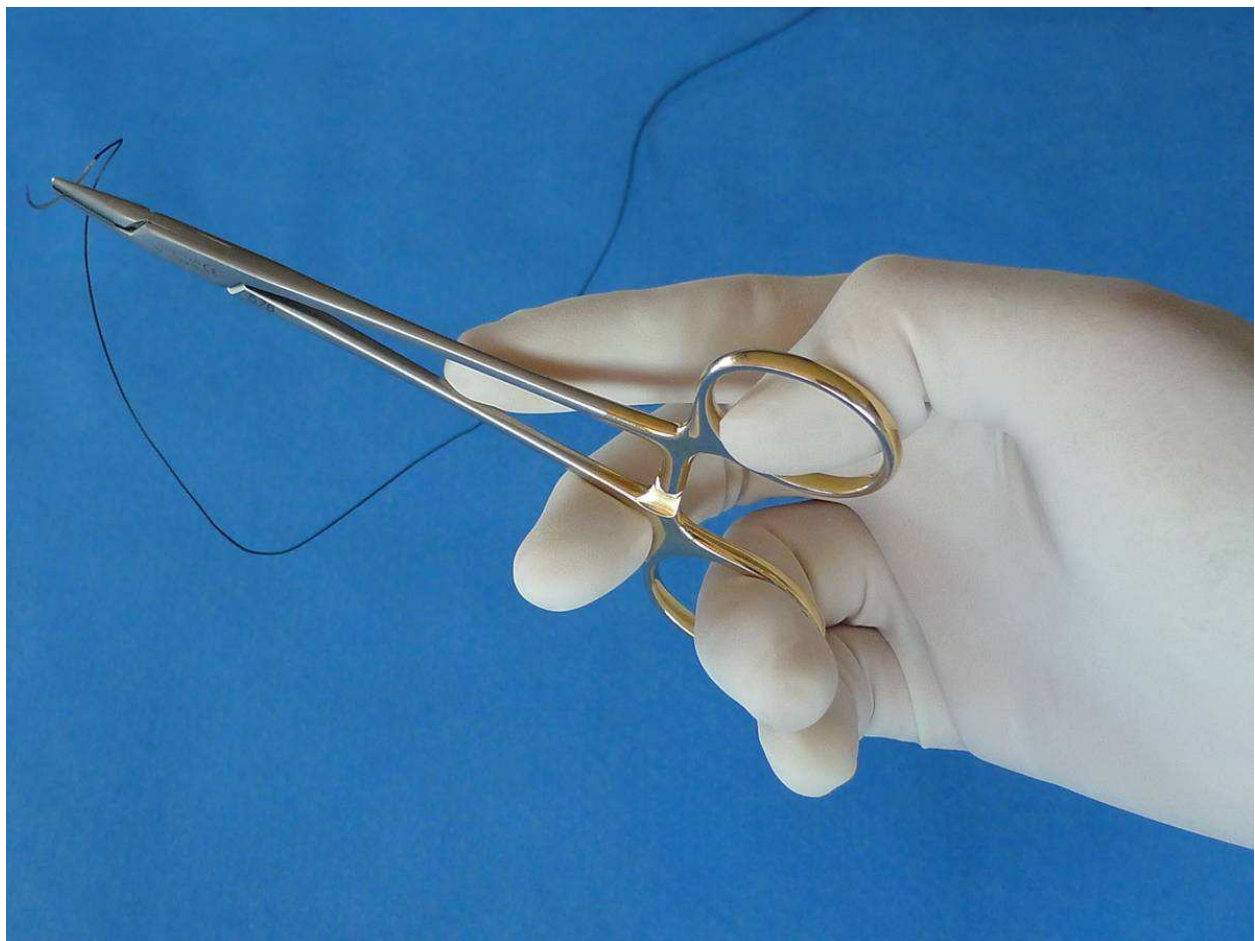


Fig. 3. Correct way of managing of needle-holders

Dissecting Forceps: Use of a 12 cm- long Adson forceps with teeth to handle the skin, plus a toothless Adson forceps for suture removal is recommended. If Adson forceps are not

available, they may be replaced by two standard forceps, one with and one without teeth. It is important not to manipulate the skin using non-toothed forceps.

Used with the nondominant hand, forceps are the most important auxiliary instrument. They allow the surgeon to expose the tissues that are to be incised, dissected and sutured, while the other hand uses the main surgical instrument. Forceps are handled similar to holding a pencil, between the first, second and third fingers.

Haemostats: 2 or 3 12 cm curved non-toothed Mosquito forceps must be available. Haemostats are used to pull tissue, for haemostasis and, in some cases, for blunt dissection in absence of small scissors. Haemostats are handled by inserting the thumb and fourth finger through the rings, while the second finger is directed towards the tip of the instrument.

Although a basic set of surgical instruments (including the previously described instruments [Fig 4]) is enough for most minor surgical interventions, certain surgical procedures require familiarity with the use of especial instruments or equipment such as curettes, punches, the bovie, or surgical retractors.

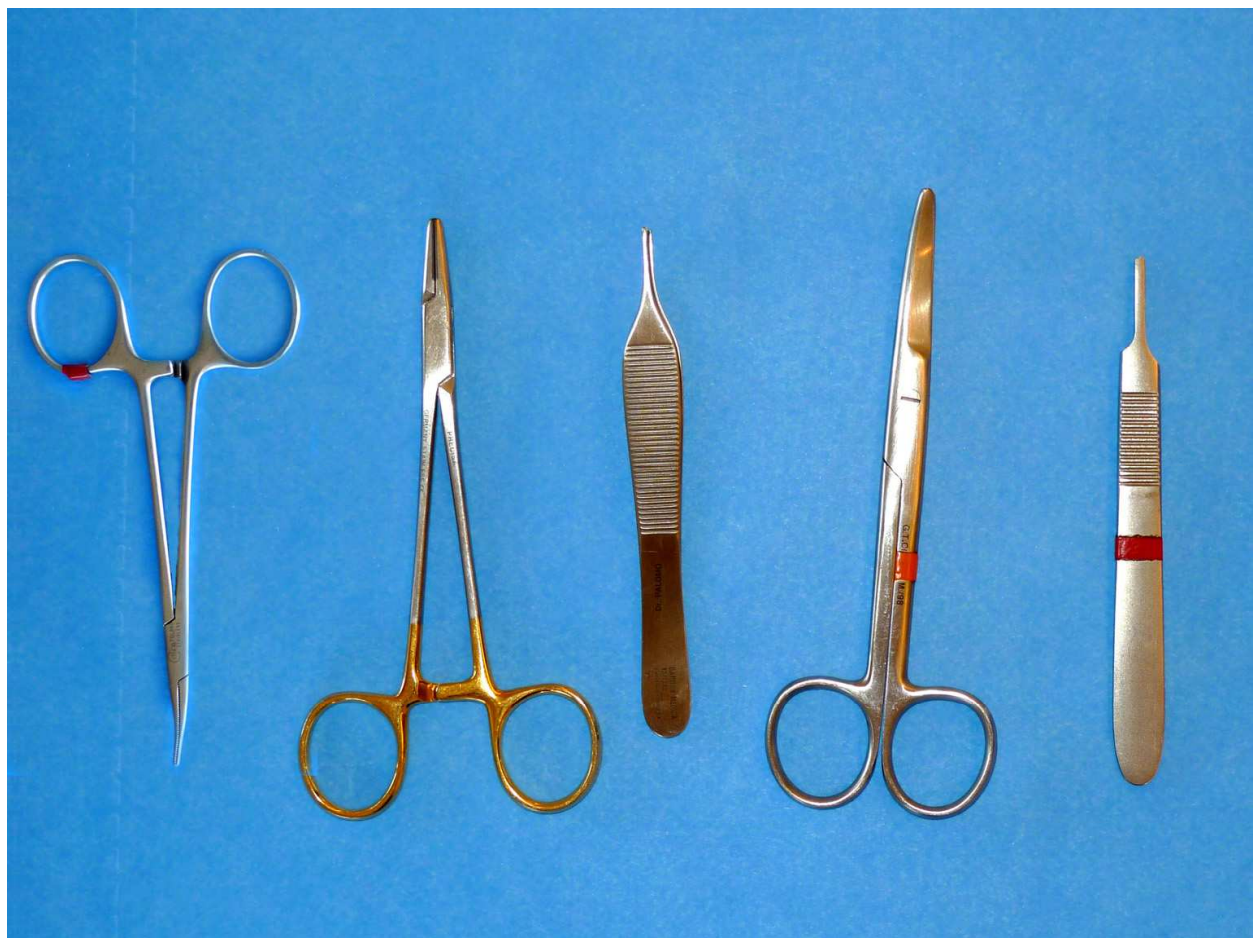

Fig. 4. Basic Set of instruments of minor surgery: scalpel (handle of the number 3 for scalpel number 15), scissors of May, Adson forceps with teeth, needle-holders and Mosquito forceps

Surgical retractors: these instruments are used to expose the surgical field through separation or retraction of the edges of the wound. If an assistant is available, he or she will hold the retractors. Otherwise, the surgeon will hold the retractor in his/her non dominant hand. In minor surgery, it is advisable to have a Senn-Mueller retractor (which is also called double-end retractor, due to its having a wide plate on one side and three sharp hooks on the other). Another useful retractor for delicate surgery is the simple skin hook.

Biopsy punch: it is an instrument consisting of a handle and a cylindrical cutting edge (trephine) for obtaining tissue biopsies. They are usually disposable and are manufactured in different diameters (2 to 8 mm), the most useful in minor surgery being the 4 mm punch. These instruments allow the surgeon to obtain full- thickness samples of the skin. They are handled with the dominant hand, performing rotational movements of the instrument to cut the skin and obtain the sample³.

Curette: it is an instrument consisting of a handle and a spoon-shaped or cutting ring end that allows scraping of lesions on the skin surface. They can be disposable or not, and they are manufactured in different diameters. The curette is handled with the dominant hand using a simple surgical technique that involves "scraping" or enucleating different types of superficial, hyperkeratotic or raised partial-thickness skin lesions.

Cryosurgical equipment: these are devices that spray a cryogen, which is usually liquid nitrogen to treat skin lesions. The cryogen may also be applied by using a swab⁴. The cryogen is stored in tanks or containers to prevent its evaporation (Fig 5). There are mobile units equipped with a nitrogen- spraying mechanism, which are endowed with a range of nozzles and probes that allow the surgeon to control the intensity of the spray, depending on the dimensions and location of the lesion that needs to be treated.

Electrocautery: the electrocautery or bovie is an electrical device consisting of a central unit that applies an electric current through a sterile terminal with capacity to coagulate and cut through different tissues. It also consists of a ground to close the electrical circuit (Fig 6). There are different terminals depending on the type of procedure that is to be performed⁵.

A set of surgical instruments for minor surgical procedures should include:

- One 14-16 cm-long standard needle holder (Webster, Crile-Wood, Hegar)
- Two curved non-toothed Mosquito hemostats
- One 14 cm-long standard dissecting forceps or 1 Adson dissecting forceps with teeth
- One 14 cm-long standard non-toothed dissecting forceps
- One scalpel handle # 3, with No. 15 disposable blades
- One 14 cm-long curved or straight blunt May scissors
- One 14 cm-long curved blunt Metzenbaum scissors

Optional: 1 or 2 double-end retractors (Senn-Muller), and a sterile marker. An optimal allocation should include electrosurgical and cryosurgical equipment

Care of surgical instruments

Surgical instruments are expensive. With proper care, an instrument should last ten years or more. Eventually instruments deteriorate through normal use, but most of the damage is

due to improper cleaning and handling. On the other hand, instruments should always be used in sterile conditions since minor surgical procedures require sterilization of all surgical material. In accordance, the following guidelines should be respected:



Fig. 5. Equipo de criocirugía. Portable unit of cryosurgery for liquid nitrogen. It consists of a thermos of stainless steel, covered with a structure of bronze and stainless steel, with a special system of valves and a great mouth of filling, the pulverization being controlled by means of a trigger. They are light and of easy transport.

- Separate (using gloves) single-use sharps and throw them in the container for biocontaminated material.
- Do not place the instruments in saline, which can deteriorate the instruments and do not allow organic matter to dry on the instruments after use. Instruments should be placed into a container with some disinfecting solution (glutaraldehyde phenolate, disinfecting solution of phenol, sodium tetraborate, glutaraldehyde or 0.05% chlorhexidine solution).
- Sterilize. The most appropriate method is using an autoclave with quality control of the sterilization process

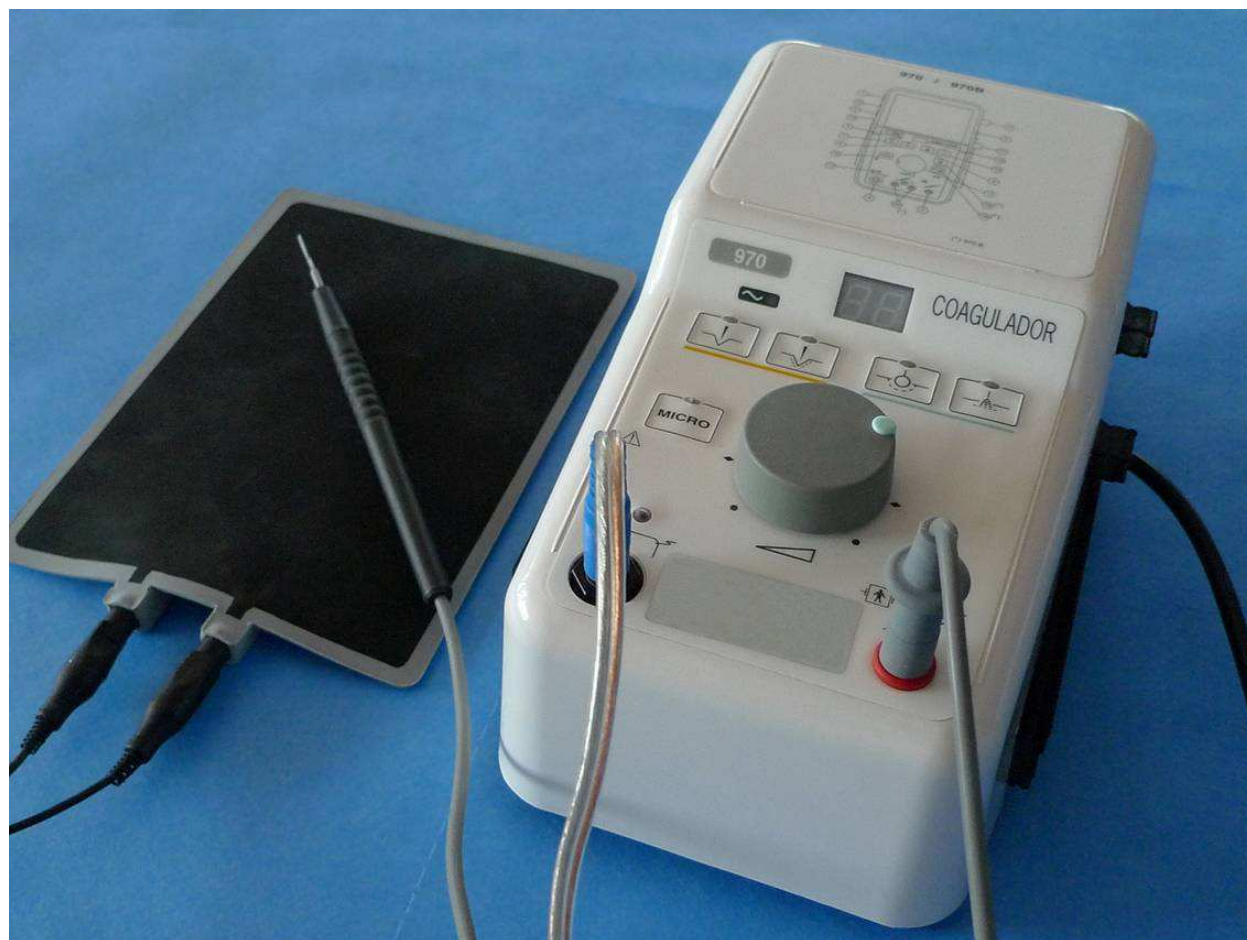


Fig. 6. Unit of electrobisturí, terminal and capture of land.

3.2 Suture materials

Different types of suture materials are available: threads, staples, adhesive sutures and tissue adhesives. The use of a particular suture material or a particular type of needle can make a difference in surgical outcome. Suture choice should be based on scientific criteria, and tempered by good practical experience.

Thread sutures provide a secure wound closure and ensure the strongest wound- support and minimal wound- dehiscence rate compared to other types of closure^{6,7}, but require the use of anesthesia, operating time is increased, tissue is traumatized, foreign bodies are inserted in the wound and the risk of disease transmission by accidental inoculation is increased.

Conventional sutures may be replaced by mechanical sutures, which reduce surgical time or by adhesive tapes, which provide lower reactivity and a lower infection rate, as previously mentioned. Tissue glues or adhesives arise in this context as an alternative to the usual procedures⁸.

Sutures

They are classified according to their origin (natural, such as silk, or synthetic polymers that produce less tissue reaction), their configuration (monofilament or multifilament), their size

(the thickness of the suture is measured using a zero-scale [USP system] with more zeros meaning finer sutures) (fig 7). The most commonly used in minor surgery range from 2 / 0 to 4 / 0 or 5 / 0, the finest sutures are usually attached to smaller needles and require the use of more precise needle holders.



Fig. 7. Information of on of suture: (1) calibre of the thread (system USP and metric), (2) trade name of the suture, (3) composition and physical structure of the thread, (4) length of the thread, (5) color of the thread, (6) model of needle (every manufacturer uses different references), (7) I draw from the needle to scale 1:1, (8) circumference of the needle (expressed in parts of circle), (9) section of the needle, (10) length of the needle, (11) expiry date, (12) indexes of the manufacturer, (13) indicator of sterile packing.

The size and type of suture will be selected depending on the anatomical site, the type of wound and on the patient’s features (Table 1).

Features of main sutures

Nonabsorbable sutures: They are not degraded by the body (or their degradation process is very slowly). They are used for skin wounds in which stitches that are to be removed or for internal structures that must maintain a constant tension (like tendons and ligaments):

- 1. Silk: Suitable for skin suture and for removable sutures in general, although it may cause significant tissue reaction.

- 2. Nylon: Indicated for precise skin sutures and internal structures that must maintain constant tension (e.g. tendons). Nylon is more difficult to handle but it causes minimal tissue reaction
- 3. Polypropylene: Indicated in continuous intradermal skin closure. It is a very soft suture with high package memory and, therefore, it requires more knots for secure tying. Polypropylene causes minimal tissue reaction

Anatomical region	Skin suturing	Subcutaneous suturing (whenever necessary)	Stitch removal	
			Adults	children
scalp	staples 2/0 silk	Vicryl® or Dexon® 3/0	7-9	6-8
eyelids	6/0 monofilament 6/0 silk	-	3-5	3-5
ears	4/0-5/0 monofilament 4/0-5/0 silk	-	4-5	3-5
nose	4/0 monofilament 4/0 silk	Vicryl® or Dexon® 4/0	4-6	3-5
lips	4/0 monofilament 4/0 silk	Vicryl® or Dexon® 4/0	4-6	4-5
Forehead and face neck	4/0-5/0 monofilament 4/0-5/0 silk	Vicryl® or Dexon® 4/0	4-6	3-5
Trunk / abdomen	3/0-4/0 monofilament	Vicryl® or Dexon® 3/0	7-12	7-9
back	3/0-4/0 monofilament	Vicryl® or Dexon® 3/0	12-14	14
Upper limb / hand	4/0 monofilament	Vicryl® or Dexon® 3/0	8-10	7-9
Pulp of fingers	4/0 monofilament	-	10-12	8-10
Lower extremity	3/0 monofilament staples	Vicryl® or Dexon® 3/0	8-12	7-10
foot	4/0 monofilament	Vicryl® or Dexon® 3/0	10-12	8-10
penis	4/0 monofilament	Vicryl® or Dexon® 3/0	7-10	6-8
Mouth and tongue	3/0 Vicryl®	-	-	-

Table 1. Indications of types of sutures and time for stitch removal

Absorbable Sutures: A suture is considered absorbable if, when placed under the skin surface, it loses most of its tensile strength in 60 days. Complete resorption is, thus, not required for a suture to be considered absorbable. These sutures gradually disappear from the body by biological absorption or hydrolysis, causing an inflammatory reaction in the body. Absorbable sutures are use for deep or non-removable suturing.

1. Polyglactin 910: Indicated in dermal suturing, subcutaneous tissue, deep suturing and ligatures of small vessels.
2. Polyglycolic acid: its indications are similar to the previous

Stitch removal

The lapse of time (in days) recommended for the removal of stitches, together with an indication of the type of suture thread is described in the table 1.

On the face, where the scar will be visible, it is important to remove stitches as soon as possible, while Steri-Strip ® is placed for 7 extra days, since during this period there is risk of wound dehiscence after minor trauma. In other anatomical regions, where the cosmetic result is not as important and the healing process is not as fast as in the face, the sutures should be left longer. In particular, in periarticular areas –due to continuous movement, and in the lower extremities, where the healing process is slower, the stitches will be removed later than usual.

Suturing needles

Needles are designed to carry the suture through tissues with minimal damage. Needle selection depends on the type of tissue to be sutured, its accessibility and suture thickness.

There are straight needles which are handled with the fingers, and are not used in minor surgery, and curved needles, which are handled with the needle holder, allowing greater accuracy and accessibility. Curved needles have different arcs, those of 3 / 8 circle or ½ circle being the most useful in minor surgery.

According to their section, needles are classified as triangular, conical or spatulate. Triangular needles have sharp edges that allow suturing through highly-resistant tissues such as skin, subcutaneous tissue and fascia and, therefore, are considered as first choice in minor surgery.

Curved needles are used with the needle holder, since its jaws are especially designed to hold needles safely and atraumatically. Needle holders should be selected in accordance with the size of the needle and the surgical area (shorter needle holders are preferred in minor surgery).

Staples

staples are available in different widths (W: Wide staples, R: normal staples) and are applied by disposable staplers preloaded with a variable number of staples (35 staples for large staplers, 10 for small ones). The use of staples versus conventional sutures has certain advantages such as the speed with which the suture is performed, low resistance and no tissue reaction

Indications: In linear wounds on the scalp, trunk and limbs, and for temporary closure of wounds in patients to be transferred or with other serious injuries.

Contraindications: Wounds on face and hands. Staple use is contraindicated in regions that are going to be studied through CT or MRI.

Staple application and removal: Staples are applied with the dominant hand, while the nondominant hand everts the skin edges using dissecting forceps with teeth. Time for staple

removal parallels time for suture removal in each anatomical region. Staple removal is performed using a staple extractor which is also provided by the stapler distributor.

Adhesive sutures

Adhesive sutures consist of adhesive tapes made of porous paper and capable of approximating the edges of a wound or incision. Sterile presentations are available in various widths and lengths, but can be cut to the proper size as required. Their advantages over conventional sutures are speed and ease of application. Besides, local anesthesia is not necessary and no “suture cross-hatching” is produced.

Indications: linear and superficial wounds with little tension. The regions where they are used most are: the forehead, chin, malar eminence, chest, non-articular surfaces of the limbs and fingertips. They are also a good choice for elderly patients and patients under treatment with corticosteroids, whose skin is thin and fragile and as wound-reinforcement after stitch removal.

Contraindications: irregular wounds, wounds closed under tension, wounds producing continuous oozing or discharge, wounds on the scalp and hairy areas, skin folds and joint surfaces

Application and removal of adhesive sutures: The wound should be dry, free of blood or secretions; substances may be added to increase skin adhesiveness. The suture tape is cut, before removing its protective paper, to the adequate size and is then applied to the wound using dissecting forceps without teeth or fingers, first on one edge of the wound and then the other and along the wound.

Time for adhesive suture removal parallels time for conventional suture removal in each anatomical region. Unlike conventional sutures, any wound closed with adhesive suture should not be wet for the first few days, due to the risk of tape detachment.

Tissue adhesives (glues)

One of the latest advances in the treatment of wounds has been the development of tissue adhesives. These products (cyanoacrylates) act as an adhesive, producing an epidermal plane closure, so they are used as topical agents that bind to the most superficial epithelial layer (stratum corneum) and hold together the wound edges. The product forms a bridge over the edges of wounds, lacerations and incisions, holding them together for 7 to 14 days. During this lapse of time, normal wound reparation takes place under the adhesive. After 7 to 14 days, most of the adhesive is shed along with the stratum corneum before degradation occurs.

In the areas of greatest wound tension or in deeper wounds, cyanoacrylates can be used in conjunction with sutures in the subcutaneous plane.

Application technique

After placing the patient in supine position and once cleaning and hemostasis of the wound have been completed, tissue adhesive will be applied as follows:

- Accurately approximate the wound edges using fingers or dissecting forceps.
- Apply the adhesive on the outer surface of the skin, preventing it from entering the interior of the wound.

- Keep the edges in contact for 30 to 60 seconds. After this time a proper degree of polymerization will have been reached. Final adhesive tension is reached within two minutes of application, and can be checked by gently pulling apart the wound edges. The application process is repeated an average of three times. After polymerization the wound can be inspected through the transparent adhesive film.
- After adhesive application, the wound does not require dressings. The wound should be kept dry 5 days and then it can get wet with caution, avoiding prolonged contact with water (bath). The glue will disappear after 7-10 days

Warnings for correct use

Should the adhesive penetrate within a wound, it will be considered a foreign body and will be eliminated through debridement. Should it contact the eyes, use of an ophthalmic ointment is recommended, since its emollients will facilitate the removal of the adhesive, along with ocular occlusion for twenty-four hours. The adhesive is usually easily detached from the eyelashes, without any need for cutting them. Should the adhesive reach the cornea, it can be extracted as a foreign body or a conservative attitude may be adopted, waiting for spontaneous detachment.

Current indications

Tissue adhesives are a good alternative for closing lacerations that meet the following criteria^{1,8}:

- Require 4 / 0 or finer sutures
- Not associated with multiple trauma
- In patients without peripheral vascular disease, diabetes mellitus, bleeding diathesis, history of keloid formation
- The cause of the wound is not an animal bite, puncture, pressure sore, or crush injury causing stellate lacerations
- Wound should present no visual sign of local or systemic active infection, contamination or visible or devitalized tissue within an active rash
- Not located in lip vermillion, mucous membranes or very hairy areas

4. Surgical procedures and techniques of anesthesia in minor surgery

4.1 Basic surgical maneuvers

Practice of minor surgical procedures requires knowledge of proper technique for handling surgical instruments (described above). Surgical knowledge and technique are also essential for carrying out minor surgical procedures.

The practice of any surgical procedure, however minimal, is not without risks. The possibility of complications during and after surgery must always be kept in mind. A satisfactory outcome of surgery should never be guaranteed, since the results of surgical treatment are not always predictable, and depend on many factors, involving not only the physician's skills, but also the patient.

Surgical incision and dissection

A correct design of the incision is important in any cutting technique, so that enough exposure of the lesion is obtained without damaging any important anatomical structures

and, at the same time, a cosmetically acceptable scar is produced. It is therefore essential to know the anatomy of the area being treated, as well as the basic technique for obtaining optimal cosmetic and functional results.

Dissection is a maneuver that involves detaching layers of tissue similar to others to which they are attached. There are two ways to dissect tissue: a so-called blunt dissection (in which tissue is not sectioned but spread apart and is usually performed using Metzembaun scissors or mosquito forceps) and a cutting dissection, which is done with a scalpel or scissors. In minor surgery, the most common level of dissection should be: for the face and neck, the junction between the dermis and subcutaneous tissue, for the scalp, the subgaleal plane, and for the trunk and extremities, the junction between the superficial and deep fascia

Incisions in minor surgery

To plan a surgical incision certain elements, such as the anatomy of the surgical area, the relaxed skin tension lines and the biology of the lesion to be treated must be taken into consideration.

Surgical incisions or excisions should be oriented so that they result in an acceptable scar, both cosmetically and functionally. To do this, incisions must parallel the minimal tension lines, which match facial expression lines and skin relaxation lines (Fig 8). Diagrams of the relaxed skin tension lines are available for correct incision planning.

Design of the incisions or excisions also must take into account the type of lesion to be treated. For excisional biopsies, it is necessary to leave an adequate margin (1-2 mm) of healthy skin both around the lesion and in depth, depending on each lesion. For partial or incisional biopsies, the incision should be designed so that it can be included in a future excision.

In many cases, marking the planned incision helps the surgeon not to lose reference after draping of the surgical field. The incision can be marked prior to skin antiseptic preparation or a previously sterilized marking pen can be used in the surgical field after skin preparation and draping.

Types of incisions for minor surgery

Incision: Used for surgical exposure of deeper tissues (e.g., lipomas, epidermal cysts, lymph node biopsies) or for drainage of abscesses. Incisions can be straight, angled or curved depending on the anatomic area involved and the type of surgery.

Elliptical excision: Used to remove skin lesions with a margin of healthy skin around the lesion and in depth. As a general rule, the length of the ellipse should be 3 times its width and the ends must form a 30- degree angle (Fig 9). It should be oriented along the lines of minimal tension and not along the axis of the lesion to be excised.

Tangential Excision: Also called "skin shave", it involves the removal by scalpel or scissors of very superficial lesions, eliminating only the most superficial layers of the skin. The defect created is allowed to heal by secondary intention. Shave can only be used to remove certain lesions affecting only the most superficial layers of the skin and for which diagnosis is certain.



Fig. 8. Graphs of the lines of minimal tension (the lines of Langers)

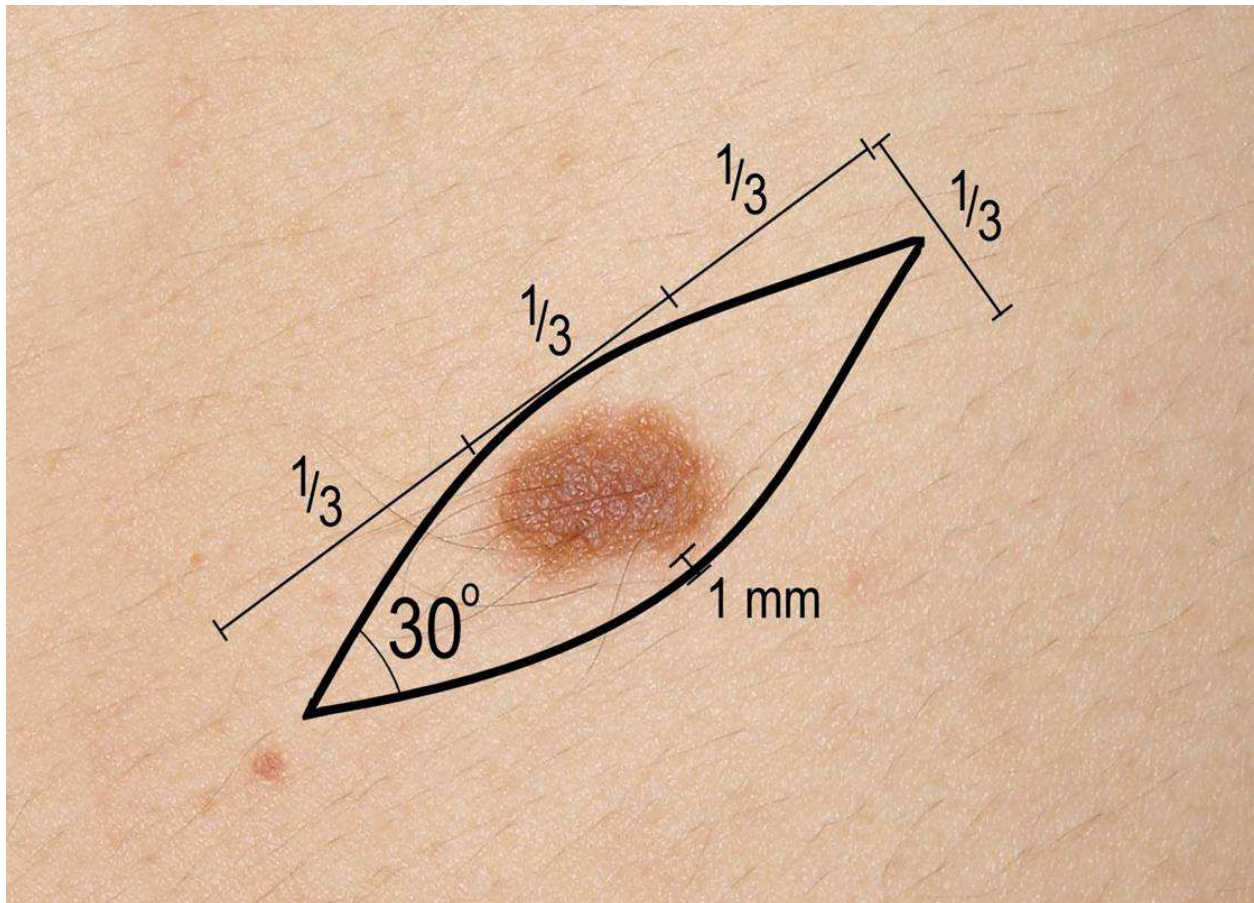


Fig. 9. Characteristics of the Elliptical excision.

Haemostasis

It is a surgical maneuver that not only controls bleeding, but allows clear vision of surgical anatomy. Most episodes of bleeding in minor surgery (where incisions or injuries very rarely involve major blood vessels) are controllable with pressure with a gauze or surgical towel. Moreover, applying a compressive bandage on the wound in the immediate postoperative period reduces the possibility of collecting a hematoma or seroma.

Types of hemostasis

- A *tourniquet* is not a method of hemostasis "per se", but provides temporary control of bleeding, allowing wound exploration and reducing surgical time. Its use in minor surgery is limited to the fingers (nail surgery, etc) and should not exceed 15 minutes.
- *Hemostats*. After identifying a bleeding vessel, the surgeon clamps it with the tip of a toothless-hemostat and checks the interruption of bleeding. Attempts to clamp blindly a bleeding vessel in the depth of a bleeding wound must be avoided at all costs because of the risk of damaging important structures (eg nerves or tendons).
- *Ligatures* are threads that, when tied around a blood vessel, occlude its lumen and prevent bleeding. After identification of the bleeding vessel, it should be fixed using a hemostat. The ligature (a single 3/0 thread) should be passed below the clamp and several knots tied. The ends are left short.

- In hemostasis by *electrocoagulation* the bovie is used in coagulation mode.

Suture techniques

Their goal is to approximate similar tissues so that proper healing of the wound ensues. For an optimal surgical closure the following principles should be remembered:

1. Tension must be avoided: suturing a wound under tension decreases the blood supply to its edges, increasing healing problems and the risk of infection.
2. Eversion of the wound edges: due to the tendency of scars to contract over time, if surgical edges are left slightly elevated above the plane of the skin, they will flatten over time, producing a more cosmetically acceptable result. One of the keys to proper surgical skin edge eversion is to introduce the needle at a 90-degree angle with the plane of the skin so that the suture, once tied, lifts the skin (fig 10).
3. Closure by layers: for most minor surgical interventions a single (cutaneous) layer closure is enough. However, if there is any tension, if the wound is very deep and involves several surgical layers or if there is much dead space, a multi-layer closure may become necessary. A multi-layer wound closure requires thick fascia or dermis for the placement of internal sutures, because fatty tissue lacks consistency to support sutures.
4. Type of suture material: it is a less important factor than the previous principles. If a suture is removed too late it will cause scarring in the areas of entry and exit of the suture ("cross-hatching"). To avoid it, stitches shall be removed as soon points as possible. The choice of suture material and its thickness are also important.

Interrupted sutures

Interrupted sutures are those in which each stitch is independent of the next one. Interrupted suturing is the most appropriate suturing technique for minor surgery, as it helps to distribute stress, promotes the drainage of the wound and stitch removal is easier.

Simple stitch (percutaneous): it is the suture technique of choice for skin suturing in minor procedures and is used alone or in combination with buried stitches in deeper wounds.

Simple stitch with inverted knot (buried): Used to approximate the deep planes, reducing tension, and to obliterate dead spaces before skin suturing. It is not necessary in superficial wounds. Absorbable material is used, leaving the knot in the depth of the wound, thus reducing the chances of suture exposure through the incision. The knot is cut flush to decrease the amount of foreign material within the wound.

Mattress stitch or "U" stitch: vertical mattress stitch: a stitch useful in areas of loose skin (back of the hand, elbow), where the wound edges tend to invaginate. In addition to providing good eversion of wound edges, this suture provides good obliteration of dead space, avoiding the need for buried sutures in shallow wounds.

Horizontal mattress stitch: This stitch also provides a good eversion of wound edges, especially in areas where the dermis is thick (e.g. Palm of the hand and sole of the foot).

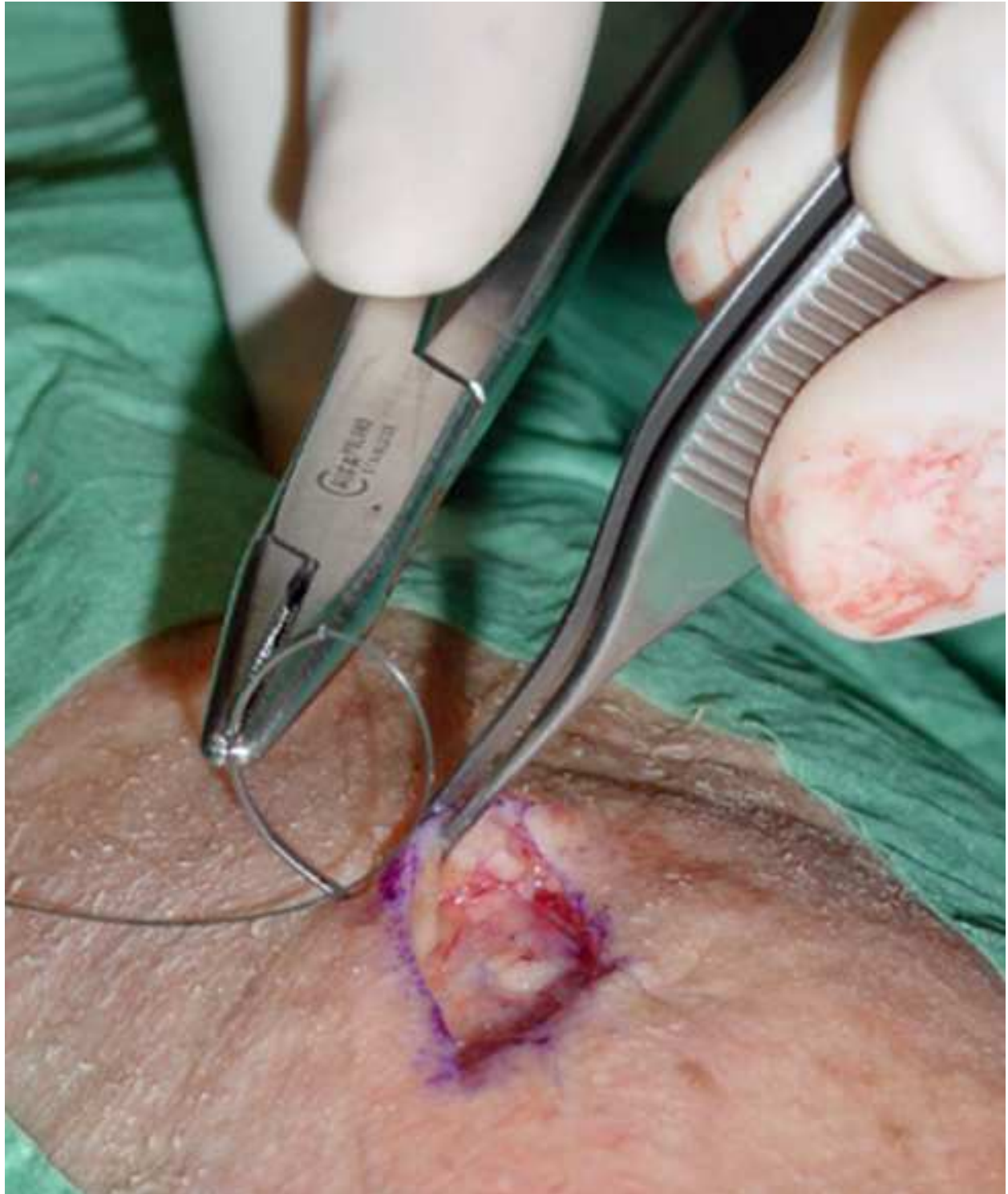

Fig. 10. Correct eversión of the surgical edges, is to introduce the needle forming an angle of 90° with the plane of the skin

Half-buried horizontal mattress stitch: is used to suture wound angles or surgical edges of uneven thickness.

Running sutures

They impede the drainage of the wound, so they are contraindicated if infection is suspected and in heavily contaminated wounds. Suture removal is somewhat more difficult, and there is no chance to remove stitches in several sessions.

Simple running suture: It is a sequence of stitches with an initial and a final knot. It takes short time to perform but it makes difficult to adjust skin tension and does not always provide adequate wound edge eversion. It is seldom used in minor surgery.

Intradermal (subcuticular) running suture: This type of suture allows wound suturing without breaking the skin, prevents “cross-hatching” and provides an optimal cosmetic result. It is performed by passing the suture through the dermis horizontally along the entire wound. At both ends suture can go out through the skin (removable intradermal suture), for which nonabsorbable monofilament suture material is selected or a knot may be tied inside the wound (non-removable intradermal suture) for which absorbable material is used. Use of multifilament suture material as silk for intradermal suturing should be avoided, as it would be very difficult to remove the suture material. Intradermal sutures are used on wounds where it will be necessary to maintain the suture a long time (more than 15 days). There should be no tension on the wound. In minor surgery their usefulness is limited.

Knot-tying

Instrumental knot-tying is performed with a needle holder and a curved needle. In minor surgery, where the surgical area is superficial and accessible to surgical instruments, *instrumental knot-tying* is the preferred technique because it provides more precise suturing and significant savings in suture material, except for suture-ligation of small blood vessels, where *manual tying* is preferred. The recommended technique is the surgeon's knot which consists of a double loop followed by several simple loops. The advantage of this knot is the resistance of its first double loop, which prevents knot untying as the surgeon proceeds with the following loops.

When knot-tying a multifilament thread (e.g. Silk) three loops are usually enough (first a double loop plus two single loops). When knot-tying a monofilament thread (eg. Nylon, polypropylene) an extra loop should be added, to increase knot security.

The knots should be placed to one side of the wound, instead of placing them on top of the incision. This will allow better visualization of the wound, interfere less with the healing and facilitate stitch removal.

4.2 Techniques of local anesthesia in minor surgery

Local anesthetics are drugs that block the transmission of nerve impulses causing, at least, the absence of pain sensation in the area of injection.

According to a small chemical difference, local anesthetics can be classified into two groups:

Esters (procaine, tetracaine, chlorprocaine, benzocaine.... which is obsolete due to its high incidence of sensitization) and amides (lidocaine, mepivacaine, bupivacaine, prilocaine, etidocaine and ropivacaine). For their remarkable safety and efficacy we will only use amides, namely lidocaine and mepivacaine

Available presentations

The concentration of the anesthetic is expressed in%. We must know that a concentration of 1% means that 100 ml of the solution contain 1 g of anesthetic and 10 ml of the solution contain 100 mg of the anesthetic. To calculate the concentration in mg / ml, the concentration percent should be multiplied by 10; thus, a 2 ml ampoule of 2% mepivacaine contains 20 mg of mepivacaine for each ml of the solution, i.e. this 2 ml ampoule contain 40 mg of mepivacaine.

Maximum doses and features

LIDOCAINE.- 10 ml Amp. \diamond 1% (100 mg), 2% (200 mg), 5% (500 mg)

Dose without vasoconstrictor: 3-4 mg / kg \diamond maximum 300 mg (3 amp 10 ml 1%)

Dose with vasoconstrictor: 7 mg / kg \diamond maximum 500 mg (5 amp 10 ml 1%)

Onset of action: 2-4 min. Induces vasodilation.

Duration: 1-2 hours, depending on the dose and breadth of the area.

In adults, concentration should range between 0.5 and 1% and total dose should not exceed 30 ml.

In children, concentration should range between 0.25 and 0.50% and total dose should not exceed 4 mg / kg.

MEPIVACAINE.- 10 ml Amp. 1% (100 mg) and 2 ml Amp. 2% (40 mg)

Dose without vasoconstrictor: 400 mg (4-5 mg / kg)

Dose with vasoconstrictor. 500mg (7mg/Kg)

Onset of action: 2-5 min. Induces less vasodilation.

Duration: 1-1.5 hours, depending on the dose and breadth of the area.

In adults, mepivacaine should be used at a 1% concentration and total dose should not exceed 40 ml.

For children 0.25 to 0.50% mepivacaine should be used and total dose should not exceed 7 mg / kg.

Adverse effects of local anesthetics

- *Local effects:* Pain, hematoma, injury to nerve trunks.
- *Systemic effects:* 1. Due to overdose toxicity. These effects appear when the maximum recommended dose is exceeded or the correct dosage is used but applied intravascularly. From a clinical standpoint, toxicity is associated to the central nervous system (CNS: tinnitus, metallic taste, numbness, dizziness, twitching, etc.) and cardiovascular system (CV: hypotension, arrhythmias, cardiac arrest). 2. Due from an allergic reaction. 3. Due to psychogenic reaction (vasovagal syncope), this is the most common adverse effect.

Use of vasoconstrictors

The association of vasoconstrictors with local anesthetics improves the safety profile of the anesthetic and also allows for better visualization of the surgical field. The most widely used is adrenaline and the maximum dose (as a vasoconstrictor) must not exceed 250 micrograms in adults or 10 micrograms / kg in children.

The recommended concentration is a dilution of 1:100,000 or 1:200,000 (best) which is prepared by mixing 0.1 mg of adrenaline (0.1 ml of 1:1000 adrenaline) in 10 ml of anesthetic to obtain a 1:100,000 dilution, or in 20 ml to obtain a 1:200,000 dilution.

Due to the risk of necrosis and delayed healing, adrenaline should not be used in acral areas (fingers and toes), or in devitalized or traumatized skin. Except in such circumstances, using the anesthetic with vasoconstrictor is highly recommended.

Basic techniques of local anesthesia

Topical anesthesia

In recent years, topical anesthetics have been developed as an alternative to infiltration both for intact skin and for lacerations and mucosae, especially in children. Topical anesthetics used in minor surgical procedures and their characteristics are shown in the table 2:

Anesthetic	Mode of use	characteristics	Indications	Complications	Not indicated
LET® (4 % lidocaine, 0,1 % epinephrine 1:2000, 0,5 % tetracaïne)	1-3 ml applied directly on wound for 15-30 min	Onset 20-30 min after application. Duration of effect has not been clearly established	Can be effective in children for face and scalp lacerations and less effective in limbs	No important adverse effects reported	For mucosae and acral areas
EMLA® lidocaine 25 mg/ml plus prilocaïne 25 mg/ml,	1-2 gr of cream should be applied for each 10 cm2 of intact skin and occluded Or apply in patch Maximum dose is 10 grams	Onset 60-120 min after application. Duration of effect is 30-120 min. not useful on palms of hands and soles of feet	Admitted for procedures on intact skin: scraping and shaving (seborrheic keratosis, Molluscum contagiosum, dermal nevus), cryosurgery (warts, condylomas), electrosurgery (small fibroids and spiders), laser hair removal, pre-anesthesia for infiltration	Local mild irritation, contact dermatitis. There have been reports of Metahemoglo binemia in children aged <6 months	For wounds or deep tissues

Table 2. Topical anesthetics used in minor surgical procedures and their characteristics

Infiltration anesthesia: angular and peri-lesional⁹

1. *Angular infiltration:* From the point of entry, the anesthetic is infiltrated in three or more different directions, like a fan (Fig 11).
2. *Perilesional infiltration:* Starting from each point of entry the anesthetic is infiltrated in a single direction, so that after several injections, the lesion will have been surrounded by anesthetic, and the diferent points of entry will be forming a polyhedral figure (Fig 12).
3. *Linear Infiltration:* If the lesion to be operated on is a skin laceration, the anesthetic should be directly infiltrated into the wound edges in a linear fashion. If the wound is

bruised and has irregular edges, it is preferable to use a perilesional technique from the uninjured area, and follow along the margins of the wound to avoid introducing microbial contamination.

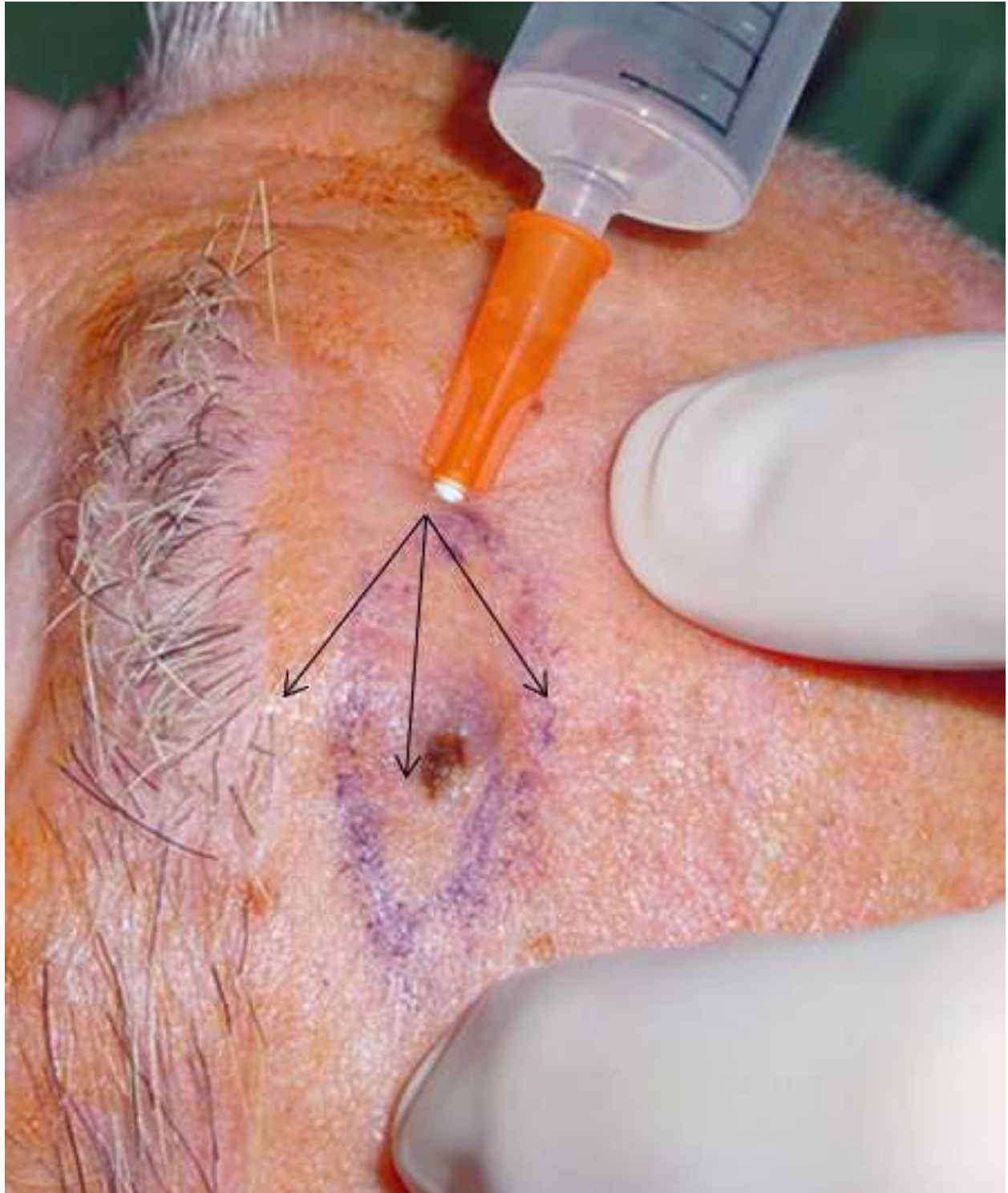


Fig. 11. Anesthetic angular infiltration: it infiltrates following three or more different directions, like a fan

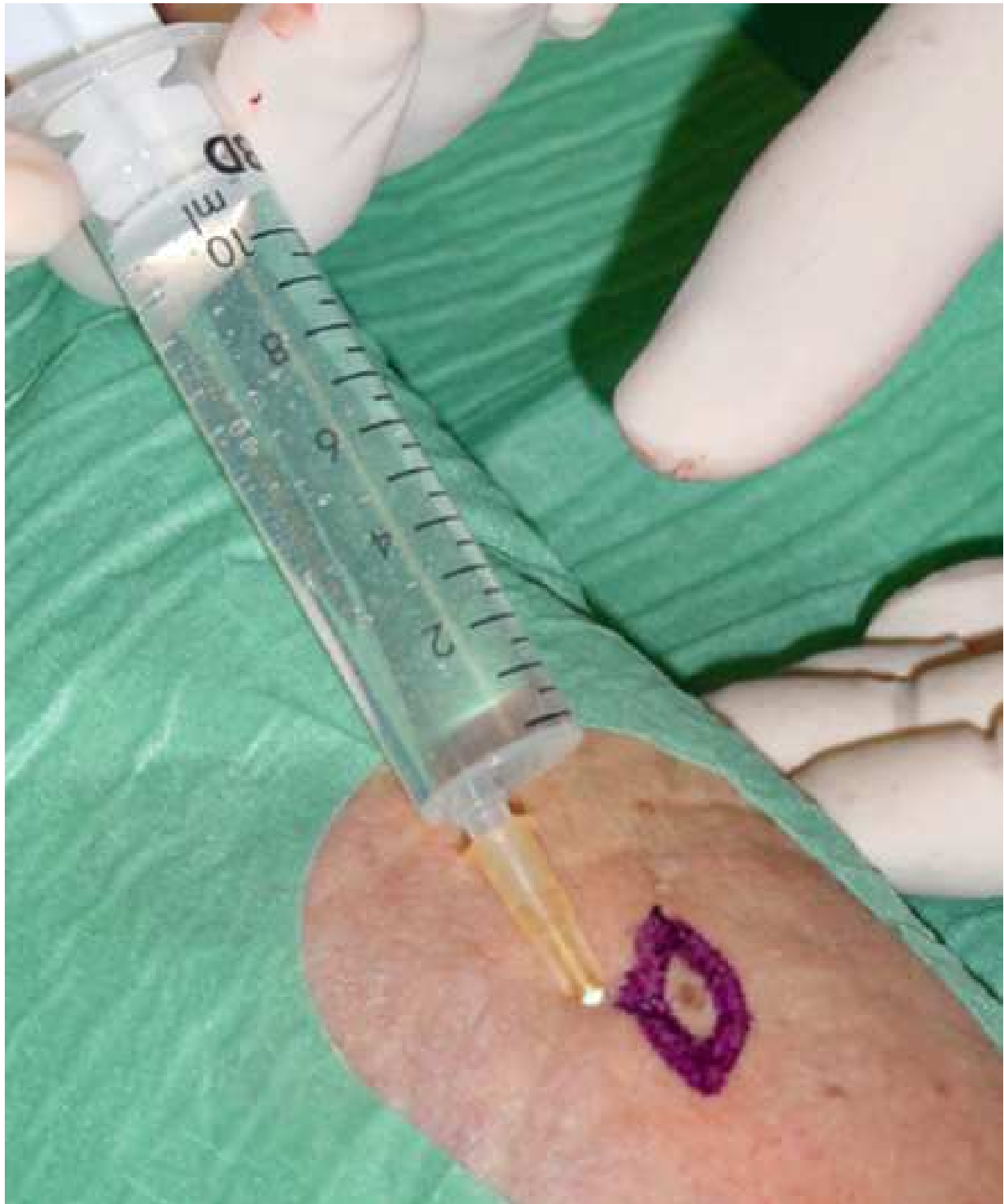

Fig. 12. Infiltration perilesional: the injury surrounds itself by means of different infiltrations

Loco-regional block

There are multiple blocks, digital blocks being the most common minor surgery. The digital block will allow the surgeon to act on all types of fingers injuries (lacerations, wound debridement, soft tissue injuries, foreign body removal, pathology of the nail).

A thin needle is inserted at the base of the proximal phalanx in a dorsal and lateral location. The needle is inserted to the point where the collateral palmar digital nerve should lie and, after aspiration, 0.5-1 mL of local anesthetic is injected. The needle is removed until its tip is just below the skin and, after aspiration, a dose of anesthetic is again infiltrated in a subcutaneous plane along the side of the base of the phalanx.

Then, the needle will be inserted on the opposite side and infiltration will proceed in a similar way.

Before the procedure, the surgeon should wait 10-15 minutes for a complete effect of the block. The total injected volume should not exceed 4 ml, because higher volumes can compress digital vessels and cause ischemia. For the same reason, anesthetics used in digital blocks should contain no vasoconstrictor.

5. Preoperative considerations

5.1 Diagnostic criteria for the most common lesions in minor surgery

The indications for minor surgery are related to the diagnosis of the patient's lesion. A misdiagnosis can cause incorrect treatment and lead to loss of clinical information relevant to the patient's prognosis. It is therefore imperative that general practitioners have an extensive knowledge of the lesions most frequently treated by minor surgery. When in doubt about the nature of any given lesion, preoperative diagnosis should always be confirmed by other specialists¹⁰. For each lesion there is a surgical procedure of choice. Other techniques may also be valid or they may even be contraindicated.

The following paragraphs contain an overview of the most important diagnostic consideration in lesions usually treated with minor surgery.

Seborrheic keratoses

Seborrheic keratoses are benign light brown lesions initially measuring 1-3 mm which after years of growth can turn into more or less pigmented 1-6 cm plaques with a rough or waxy surface. These lesions are easily treated with curettage, electrosurgery or cryosurgery. In case of doubt, an incisional biopsy should be sent for histopathological analysis.

Epidermal cysts

Also known as epithelial cysts, epidermoid cysts or sebaceous cysts, they are firm nodules, measuring from 0.2 to 5 cm in diameter, formed by a layer of stratified squamous epithelium or epithelium of a hair follicle, which are located in the dermis or subcutaneous tissue. They are not adherent to deep tissues and in many instances a central keratin-rich pore can be seen. Keratin is the main component inside the cyst. The most common location is on the face, neck, chest, upper third of back and scrotum. Their treatment is surgical removal for cosmetic reasons or due to recurrent infections.

Warts

They are a form of benign epithelial hyperplasia induced by human papilloma virus (HPV). The clinical presentations of the cutaneous infection by HPV include:

Verruca Vulgaris: The treatment of choice is 15-20% salicylic acid with petroleum jelly, applied topically for 2-3 weeks or liquid nitrogen.

Plantar wart: The treatment of choice is 40% salicylic acid with petroleum jelly, applied topically for 3 weeks followed first by curettage and then by liquid nitrogen. Surgery and electrocoagulation are not indicated

Molluscum

Pearly white papules of 1-5 mm (sometimes even bigger) with central dimpling. They may appear isolated or in groups in the neck, trunk, anogenital area or eyelids. They are very common in children and in patients with HIV / AIDS with extensive lesions which difficult to eradicate.

Their first choice treatment is cryosurgery, curettage or electrodesiccation.

Lipoma

Lipomas are slow-growing benign tumors of mature adipose tissue. They are a frequent cause of consultation due to mechanical or aesthetic reasons. Lipomas appear as soft, elastic, smooth or multilobulated tumors of variable size (from 1 or 2 cm to 15 cm or more) with ill-defined borders, and not adherent to deep planes.

Lipomas are generally asymptomatic and patients usually refer the emergence of a "lump" whose location, size and visibility will determine how urgent such consultation will be. In most cases, a simple physical examination will establish a correct diagnosis of lipoma.

Lipomas are treated by surgical removal. Their removal by either a general practitioner or a surgeon usually depends on the size, location and position of the lipoma in the subcutaneous plane.

Fibroma pendulum, skin tags

These are pedunculated fleshy-looking benign tumours, whose colour is either similar to that of the surrounding skin or darker. Their size varies from a few mm (which usually appear in groups and are located in the neck, armpits, and skin folds) up to 2-5 mm (which usually appear as pedunculated and solitary lesions).

Their treatment is justified for cosmetic reasons, and good surgical results usually ensue. These lesions can be treated by skin shave, electrodesiccation and cryosurgery.

Melanocytic nevi

They are acquired lesions in the form of macules or papules or small nodules (<1 cm) and are constituted by groups of melanocytes located in the epidermis, dermis or both areas and rarely in the subcutaneous tissue. They are very common in Caucasians and family incidence has been clearly established. Sun exposure contributes to the induction of these lesions.

Most appear in early childhood and peak in young adults to regress and disappear gradually and are asymptomatic. By contrast, dysplastic nevi continue to appear as new lesions over a lifetime and do not show signs of involution. The indication for removal will be established when any of the following characteristics is seen:

- Presentation site: scalp, mucous membranes, anogenital area
- Time of evolution: de novo appearance in adulthood
- Color: variegated or modified
- Borders: always have been irregular or have just turned irregular

- Symptoms: If the nevus starts to itch, bleed or hurt
- Epiluminescence microscopy: criteria of dysplasia

Actinic keratoses

These are yellowish brown dry- looking maculopapular lesions, with a rough and scaly texture located in sun-exposed areas of middle-aged patients. Actinic keratoses are more prevalent in males. Most of these lesions are present on the skin for years and 13-25% of them will lead to a squamous cell carcinoma.

The treatment of choice is the topical application of 5% 5-fluorouracil or Imiquimod. If lesions are scarce and localized, they may be treated with liquid nitrogen.

Basal cell carcinoma

Basal cell carcinoma is the most common skin malignancy. Although it can occur at any age, its incidence raises abruptly after the age of 40 with a history of heavy sun exposure. These lesions are more prevalent in the face and scalp followed by the ears and upper chest and back.

Excision should be considered for any slow-growing pale pink, brown or flesh-colored, flat or slightly elevated new skin lesion located in the face, ear, neck, back or scalp with a pearly or waxy appearance, that also meets any of the following criteria:

- Blood vessels visible in the lesion or in the adjacent skin
- Keratin pearls sometimes visible with a loupe
- Appearance of a scar with no history of previous wound in the area
- Non-healing ulcer

Squamous cell Carcinoma

This is a malignant tumor that usually appears on a previous premalignant lesion.

It takes different clinical forms, in this case as a crust-covered superficial ulcer that grows insidiously over months. In other cases it may appear as a hard papule or nodule.

Squamous-cell carcinomas require a multidisciplinary therapeutical approach involving dermatologists, surgeons, radiotherapists, and chemotherapists.

Melanoma

Of all skin malignancies, melanoma has the worst prognosis. There are different clinical presentations and, for their detection, the "ABCDE-rule of melanoma" , which is described in the following table, should never be overlooked (Table 3).

	A-B-C-D-E rule for any lesion clinically suspicious of melanoma
A	Asimetry
B	Border: irregular and scalloped
C	Colour: mottled, irregular shades of brown, black, gray and pink
D	Diameter over 6 mm
E	Subtle or obvious skin elevation (on illuminated sideview) and serial assessment of growth

Table 3. A-B-C-D-E rule for any lesion clinically suspicious of melanoma

Any lesion suspicious of melanoma should be referred to a dermatologist. These lesions should never undergo biopsy by skin shave or curettage, nor should any destructive procedure (cryosurgery or electrosurgery) be used in their diagnosis or therapy.

5.2 Body areas of risk in minor surgery

Certain body areas are considered high-risk areas for minor surgical procedures, due to the superficial location of some anatomical structures, which are likely to be injured during surgery. To avoid injury to these structures, it is necessary to know their theoretical path and keep the surgery, whenever possible, on a superficial plane (superficial subcutaneous tissue). Other areas are also considered high-risk areas due to the potential esthetic impact of poor surgical technique.

High-risk areas for minor surgery include the facial and cervical regions, axillary and supraclavicular regions, wrists, hands and fingers, the groin, the popliteal fossa and the feet (Fig 13 A, B).

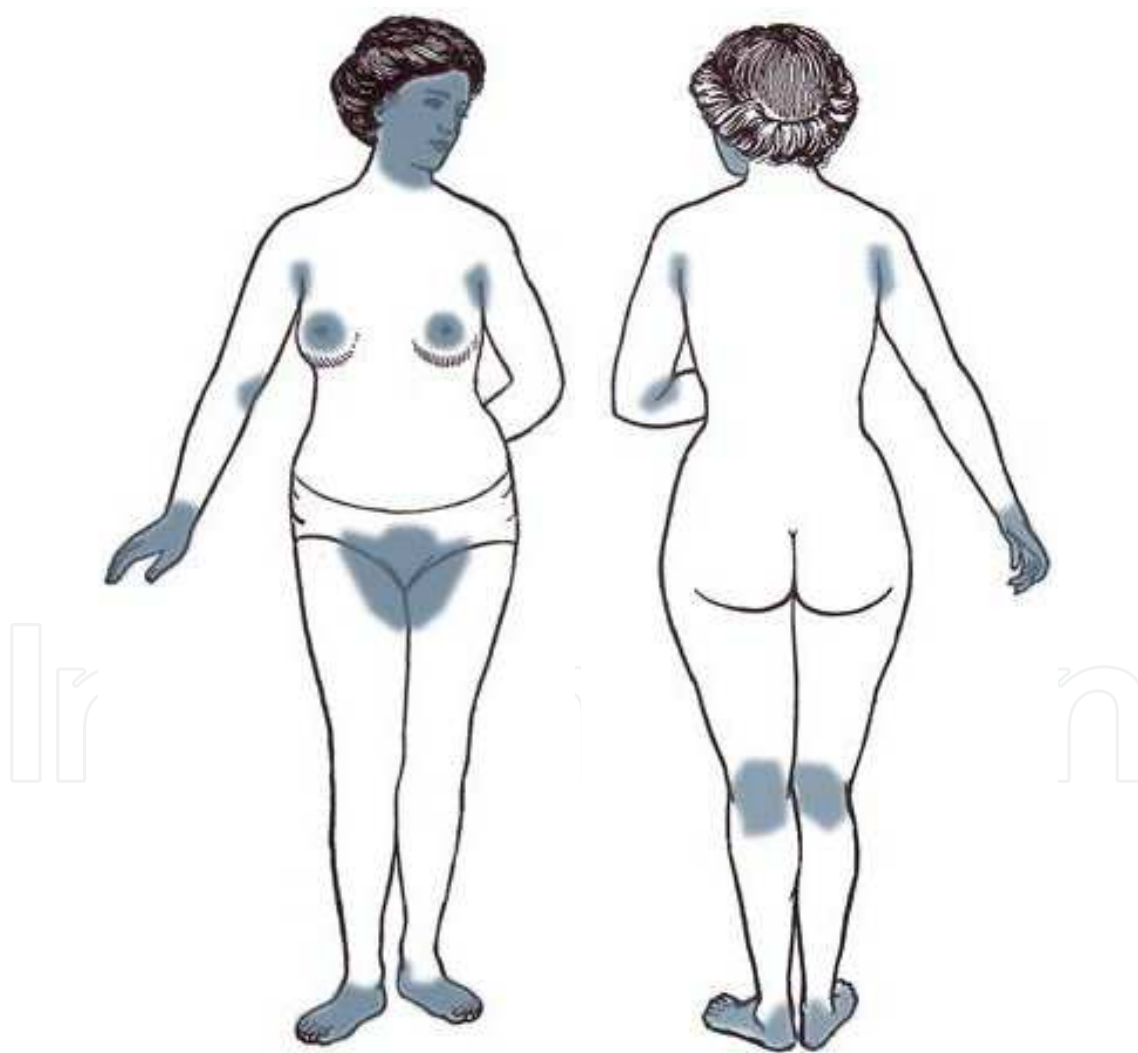


Fig. 13, A, B: The zones of risk in Minor Surgery include the facial and cervical region, the region axilar and supraclavicular, the wrists, hands and fingers, the inguinal region, the hollow poplíteo and the feet

Along with the previously-mentioned areas, we must also consider those regions with a greater tendency to develop pathological scars. The deltoid and shoulder region, the sternal and interscapular region, and the skin of black patients and children are especially prone to hypertrophic scarring and keloids. Thus, before any skin lesion is removed in any of these areas it is important to discuss this possibility with the patient, especially in cases where the excision pursues aesthetic improvement, and is not indicated for diagnostic or therapeutic reasons.

6. How to perform a surgical procedure: Elliptical excision step by step

Elliptical excision is a skin excision technique with a spindle-shaped design. This ellipse should include all skin layers plus some subcutaneous fat, in order to remove skin lesions with a safety margin both around and under them. This technique not only allows for simultaneous diagnosis and treatment, but also facilitates closure producing good cosmetic results. It is, therefore, the ideal technique to remove the majority of skin lesions¹¹⁻¹⁴.

Before surgery the patient should be informed about the procedure and its technical details before asking them to sign the informed consent form.

The procedure involves the following steps:

1. **Design of the incision** which is drawn with a marker using the following parameters: the longitudinal axis of the ellipse will be three times longer than its transverse axis and will be parallel to skin tension lines. Its ends will form a $<30^\circ$ angle to avoid "dog ears". There must be a 1-2 mm margin between the lesion and the incision (some lesions may require more generous margins).
2. **Preparation of the surgical field:** cleaning and antisepsis
3. **Local anesthetic** injection, covering the entire edge of the incision and the tissue to be sectioned and sutured
4. **Superficial skin incision** along the marked ellipse, going through the entire dermis to prevent jagged edges. The incision is made with a clean cut of the scalpel, which is held like a pencil, and any sawing movement should be avoided. Using the nondominant hand, the skin should be stretched or pinched along the previously marked incision line (Fig 14).
5. **En bloc excision of the lesion** using the nondominant hand the skin is stretched with toothed-forceps from one end of the ellipse and, using the edge of the blade, the deep wedge-shaped incision is made (always under direct vision, Fig 15), until fat is reached and the lesion is, thus, removed en bloc.
6. **Haemostasis of the surgical area:** if anesthesia with vasoconstrictor is used bleeding will be scarce and hemostasis will be easily achieved by applying digital pressure with a gauze.
7. **Wound closure** by layers: most minor surgical procedures only require suturing of the skin surface, but if there is any tension, the incision is deep and involves several tissue layers or there is dead space, suturing several surgical planes may be required. The deep-layer suture should be performed with absorbable material using an inverted-knot technique. Then, the superficial closure with nonabsorbable suture will be performed. The number of stitches will depend on the tension of the wound, suture thickness and chosen suture technique (Fig 16).
8. **Sterile dressing** placement after cleaning the surgical area

9. **Submission of the resected specimen to pathology**, in a container with 10% formalin.
10. **Follow-up:** After 48 hours the wound can be washed gently, and the patient should be warned of postoperative risks and taught how to take care of the surgical wound. No surgical procedure is complete until the pathology report has been received and the patient informed of the results and prognosis.

IntechOpen

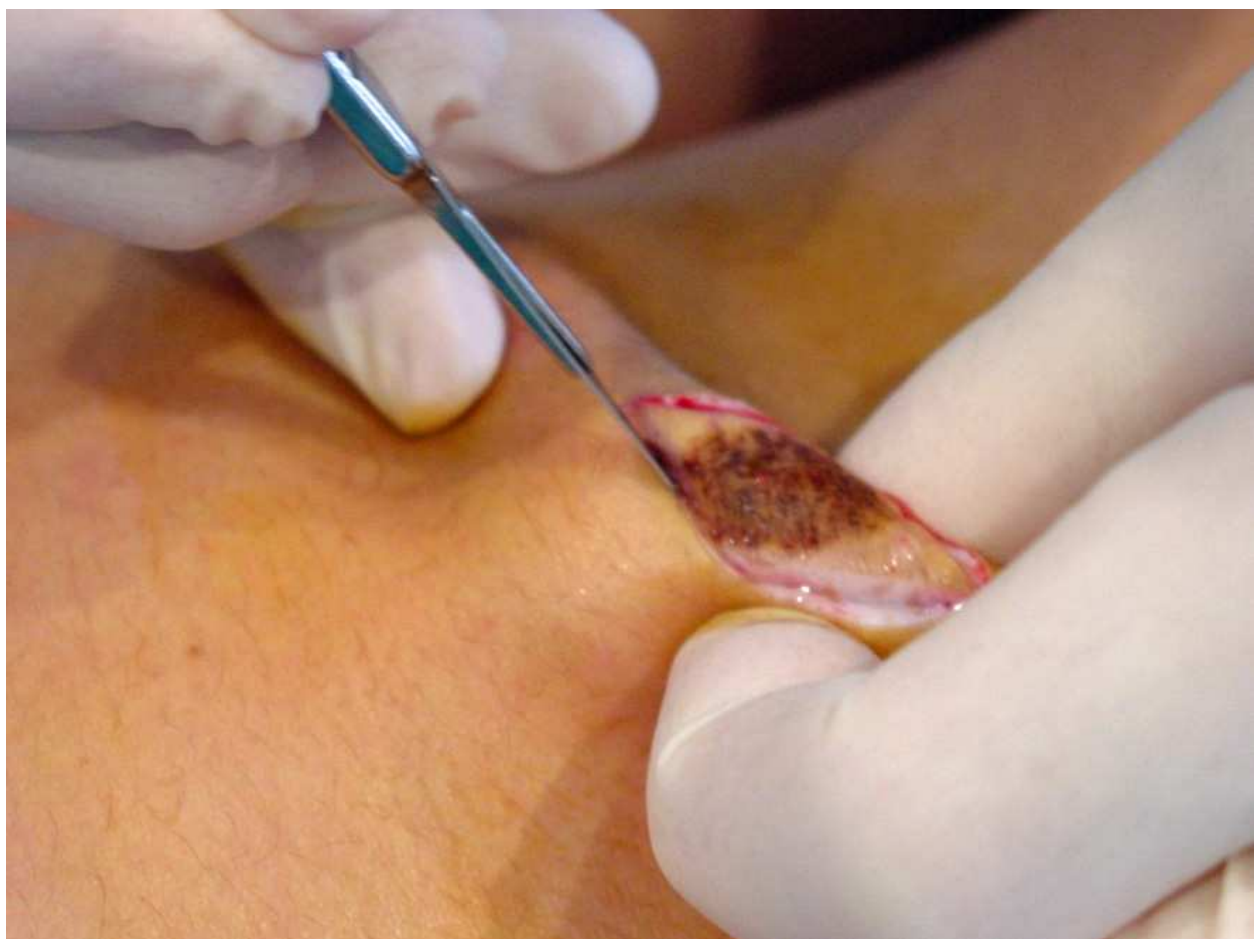

Fig. 14. Incision is done giving a clean cut of the scalpel, not sawing, taking the handle of the scalpel as a pencil, traccionando (or pinching the zone) with the fingers

IntechOpen

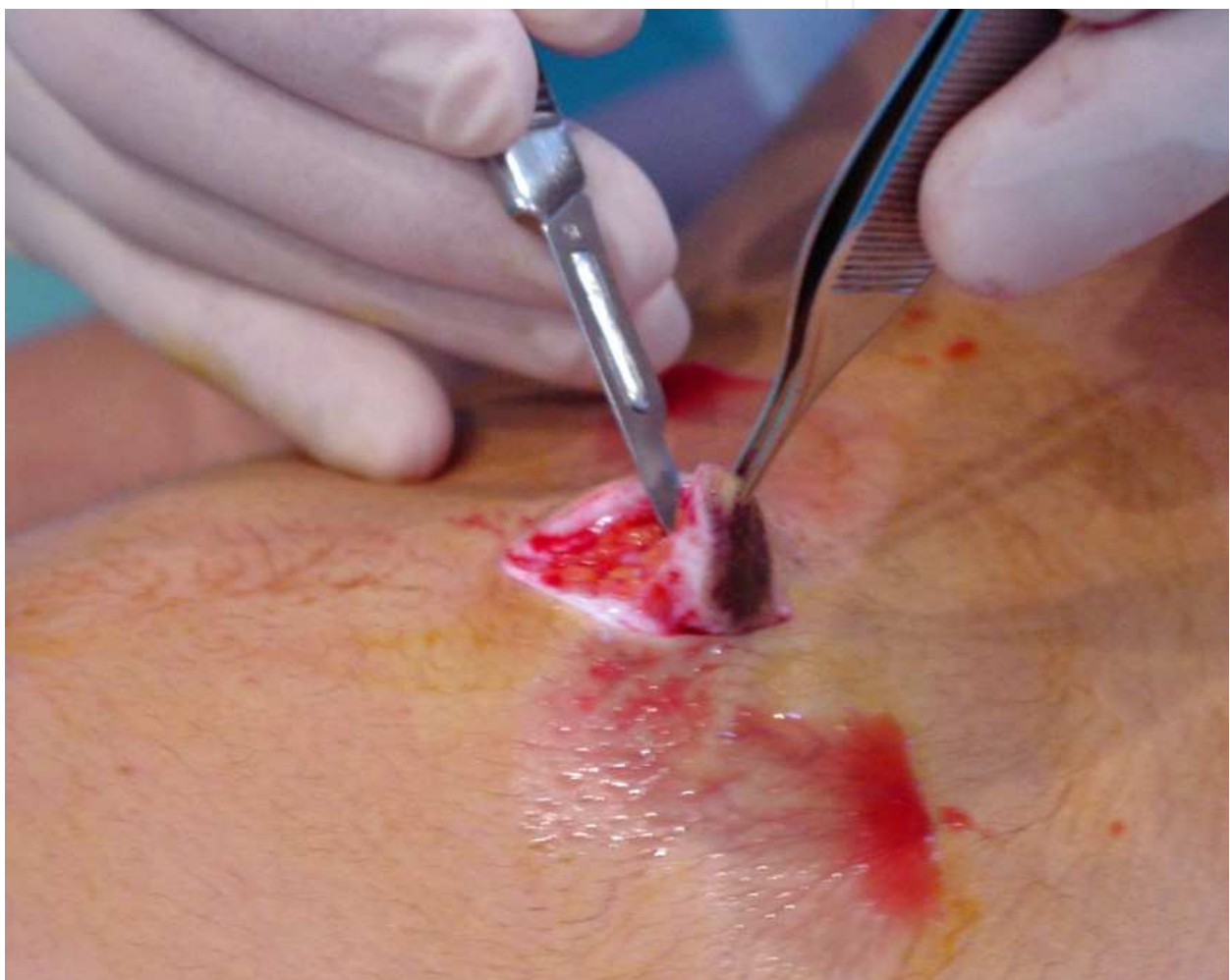

Fig. 15. En bloc excision: traction is realized (with forceps with teeth) from an end of the spindle and with the edge of the scalpel deep incision is realized

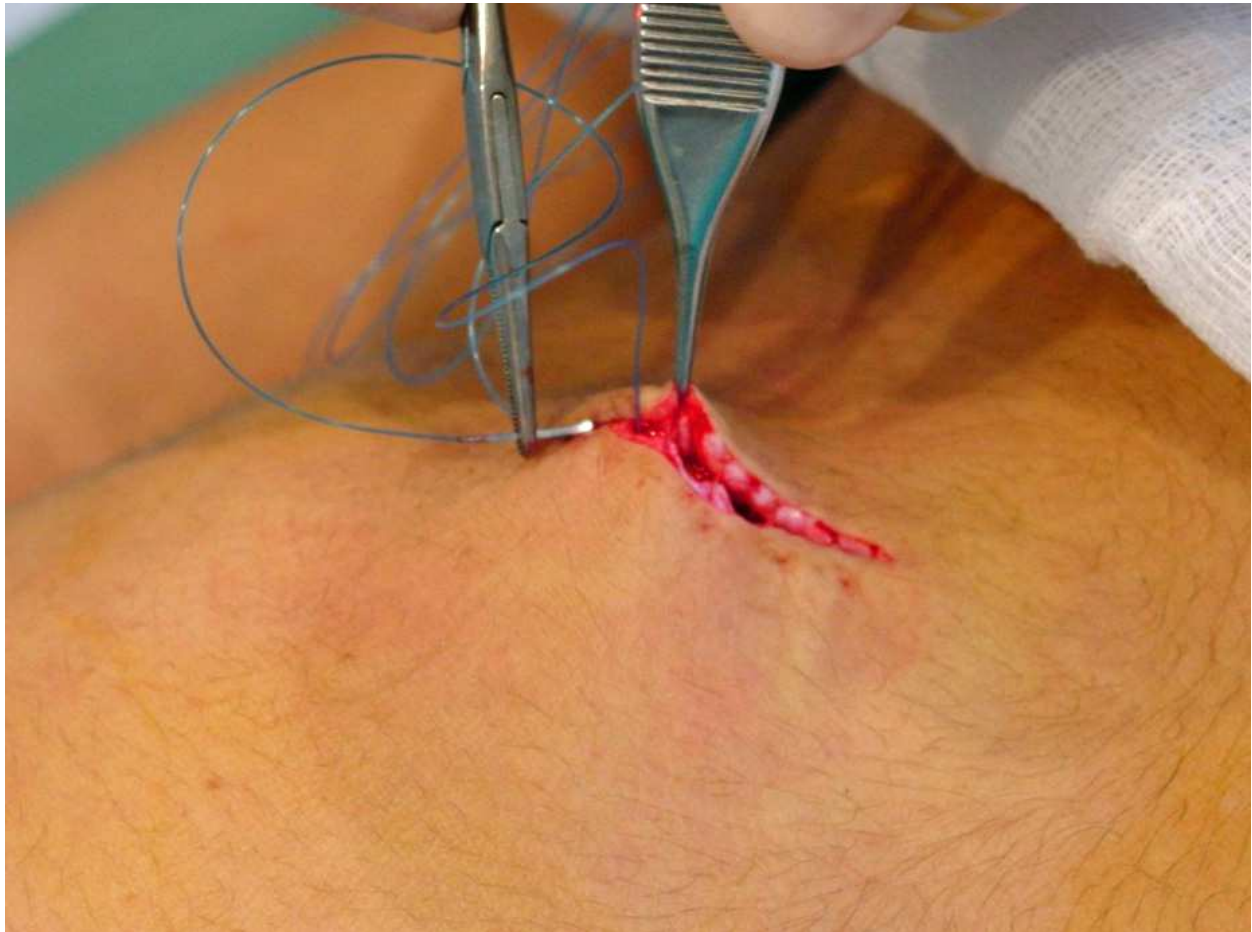

Fig. 16. Suturing of the skin surface

7. Good clinical practice in minor surgery

Preoperative

For most basic minor surgical procedures, no preoperative work-up is needed. However, since we, as general practitioners, operate on our own patients, we have immediate access to their medical history which can be completed with a series of simple questions that will help us detect those patients in whom surgery poses especial risks or is contraindicated. The table 4 summarizes the precautions of minor surgery in primary care:

<ul style="list-style-type: none">- Diabetes Mellitus and peripheral vascular disease when planning surgery in the lower extremities- In patients with chronic use of immunosuppressors (corticosteroids)- Do not add vasoconstrictor to local anesthetic in patients with: arrhythmia, severe hypertension, hyperthyroidism, pheochromocytoma, pregnancy, and in anesthesia of the fingers- Anatomic areas of risk- Use of oral anticoagulants and antiplatelet agents should be sought for. The risk-benefit of their suspension should be studied prior to surgery. <p>In most patients at low risk, minor surgical procedures can be performed without altering the anticoagulation regimen if their INR is within therapeutic range (<i>Antithrombotic and Thrombolytic Therapy: American College of Chest Physicians Evidence-Based Clinical Practice Guidelines (8th Edition)2008</i>)</p> <p><i>Specific precautions with the use of electrocautery</i></p> <ul style="list-style-type: none">- Keep the patient’s skin clear from any metallic object. Metal dentures, implants, prosthesis, IUD are not contraindicated- Do not use alcohol or use the bovie near a source of oxygen.- Use latex gloves for insulation <p><i>Special precautions for cryosurgery</i></p> <ul style="list-style-type: none">- Patients with areas of potential circulatory compromise due to the risk of necrosis.- Hairy areas in which hair loss could ensue.- Hyperpigmented areas (black or dark skin), where the use of cryosurgery can leave areas of hypopigmentation.- Patients with high levels of cryoglobulins.
--

Table 4. Precautions minor surgery

Premedication

In patients with increased anxiety, use of preoperative sedation can be considered. 5-10 mg oral or sublingual diazepam, or 1-5 mg sublingual lorazepam can be administered 30 minutes before surgery.

Contraindications for minor surgery

- With few justified exceptions, no malignant skin lesion should be surgically treated by the general practitioner. Similarly, all lesions labeled as malignant after pathological analysis, should prompt consultation with other specialists.
- Allergy to local anesthetics: If there is doubt about a history of allergic reactions, the patient should see the allergist prior to surgery.
- Pregnancy: If the patient is pregnant, surgery should be deferred until the end of pregnancy, to avoid unnecessary risks. If malignancy is suspected, the patient should be referred to a specialist.

- Acute intercurrent disease: if the patient suffers an acute illness at the time of surgery (heart failure, liver failure, arrhythmia, flu or pneumonia), surgery should be postponed until recovery.
- Doubt about patient's motivations: surgery is contraindicated in patients whose motivation is questionable or in whom there is excessive preoccupation about the aesthetic result
- Patients with psychiatric disorders or uncooperative patients are not eligible for surgery in primary care. In general it is not advisable to involve uncooperative patients.
- Refusal to sign the informed consent form is a contraindication for any minor surgery procedure or technique.

Intraoperative complications

Vasovagal syncope is the most frequent complication and is more common in young men. Warning signs are flushing, pallor, sweating, weakness, nausea (occasionally, vomiting), etc. After these symptoms, some patients may lose consciousness.

Treatment consists of placing the patient in Trendelenburg's position, administering oxygen and i.v. fluids if needed and, in severe cases (long-lasting or associated with bradycardia) use of 0.5-1 mg sc or iv atropine can be considered (maximum dose, 2 mg). Generally, most of patients recover spontaneously over a period of seconds to a few minutes.

All medical premises where minor surgical procedures are performed should have CPR equipment and medication.


Postoperative complications

- Hematoma-seroma: fluid collection under the sutures that occurs whenever cavities or dead space have been left in the surgical site. To prevent their formation, a correct intraoperative hemostasis is paramount plus suturing the wound in layers with no gaps and, finally, applying a compressive bandage.
- Infection can occur in up to 1% of minor surgical patients and it appears as swelling, redness of the wound edges and, sometimes, purulent discharge. Symptoms such as fever and / or chills are only rarely seen. Infections are treated by removing some of the stitches, plus daily cleaning and disinfection of the wound and allowing the wound to close by secondary intention. If necessary, a drain may be inserted into the wound and an oral antibiotic regimen may be initiated.
- Wound dehiscence: The separation of the edges of the wound before proper healing. There are predisposing factors secondary to surgery (excessive tension on the edges of the wound, use of inappropriate suture material or early suture withdrawal) or it may be the final phase of other complications such as hematoma or infection. After wound dehiscence, wound repair will take place by secondary intention, resulting in a poor cosmetic result.
- Hypertrophic scar and keloid scarring are deviations from normal wound-repair process. Hypertrophic scars do not grow beyond the initial limits of the primary wound whereas in a keloid the scar tissue extends beyond the initial boundaries of the scar, forming a permanent bulk of scar tissue. Keloids are very difficult to prevent and their most frequent location is in the chest, shoulders and upper back, in young people and

blacks. Treatment of these scars is difficult and results are often discouraging. Occlusive treatment or steroid injections may be tried.

8. References

- [1] Arribas JM (2006). Cirugía menor y procedimientos en medicina de familia (2ª edición). Madrid: Jarpyo Editores,
- [2] Czarnowski C, Ponka D, Rughani R, Geoffrion P. See one. Do one. Teach one.: Office-based minor surgical procedures. *Can Fam Physician*. 2008 Jun;54(6):893.
- [3] Zuber TJ. Punch biopsy of the skin. *Am Fam Physician*. 2002 Mar 15;65(6):1155-8, 1161-2, 1164.
- [4] Freiman A, Bouganin N. History of cryotherapy. *Dermatol Online J*. Aug 1 2005;11(2):9
- [5] Hainer BL. Electrosurgery for the skin. *Am Fam Physician*. 2002 Oct 1;66(7):1259-66.
- [6] Kudur MH, Pai SB, Sripathi H, Prabhu S. Sutures and suturing techniques in skin closure. *Indian J Dermatol Venereol Leprol*. 2009 Jul-Aug;75(4):425-34.
- [7] Moy RL, Lee A, Zalka A. Commonly used suturing techniques in skin surgery. *Am Fam Physician*. 1991 Nov;44(5):1625-34.
- [8] Singer AJ, Quinn JV, Hollander JE. The cyanoacrylate topical skin adhesives. *Am J Emerg Med*. 2008 May;26(4):490-6.
- [9] Achar S, Kundu S Principles of office anesthesia: part I. Infiltrative anesthesia. *Am Fam Physician*. 2002 Jul 1;66(1):91-4.
- [10] Klaus Wolff y Richard Allen Johnson (2009). Fitzpatrick's Color Atlas and Synopsis of Clinical Dermatology 6th edition. El McGraw-Hill Companies, Inc. New York
- [11] Hussain W, Mortimer NJ, Salmon PJ. Optimizing technique in elliptical excisional surgery: some pearls for practice. *Br J Dermatol*. 2009 Sep;161(3):697-8. Epub 2009 Jun 25.
- [12] Czarnowski C, Ponka D, Rughani R, Geoffrion P. Elliptical excision: minor surgery video series. *Can Fam Physician*. 2008 Aug;54(8):1144
- [13] Zuber TJ. Fusiform excision. *Am Fam Physician*. 2003 Apr 1;67(7):1539-44, 1547-8, 1550.
- [14] Wu T. Plastic surgery made easy - simple techniques for closing skin defects and improving cosmetic results. *Aust Fam Physician*. 2006 Jul;35(7):492-6.



Primary Care at a Glance - Hot Topics and New Insights

Edited by Dr. Oreste Capelli

ISBN 978-953-51-0539-8

Hard cover, 446 pages

Publisher InTech

Published online 27, April, 2012

Published in print edition April, 2012

"Both among scientists and clinical practitioners, some find it easier to rely upon trivial explanations, while others never stop looking for answers". With these surprising words, Augusto Murri, an Italian master in clinical medicine, reminds us that medical practice should be a continuous journey towards knowledge and the quality of care. The book brings together contributions by over 50 authors from many countries, all around the world, from Europe to Africa, from Asia to Australia, from North to South America. Different cultures are presented together, from those with advanced technologies to those of intangible spirituality, but they are all connected by five professional attributes, that in the 1978 the Institute of Medicine (IOM)¹ stated as essentials of practicing good Primary Care: accessibility, comprehensiveness, coordination, continuity and accountability. The content of the book is organized according to these 5 attributes, to give the reader an international overview of hot topics and new insights in Primary Care, all around the world.

How to reference

In order to correctly reference this scholarly work, feel free to copy and paste the following:

Jose Maria Arribas Blanco and Maria Hernandez Tejero (2012). Skills in Minor Surgical Procedures for General Practitioners, Primary Care at a Glance - Hot Topics and New Insights, Dr. Oreste Capelli (Ed.), ISBN: 978-953-51-0539-8, InTech, Available from: <http://www.intechopen.com/books/primary-care-at-a-glance-hot-topics-and-new-insights/skills-in-minor-surgical-procedures-in-family-medicine>

INTECH
open science | open minds

InTech Europe

University Campus STeP Ri
Slavka Krautzeka 83/A
51000 Rijeka, Croatia
Phone: +385 (51) 770 447
Fax: +385 (51) 686 166
www.intechopen.com

InTech China

Unit 405, Office Block, Hotel Equatorial Shanghai
No.65, Yan An Road (West), Shanghai, 200040, China
中国上海市延安西路65号上海国际贵都大饭店办公楼405单元
Phone: +86-21-62489820
Fax: +86-21-62489821

© 2012 The Author(s). Licensee IntechOpen. This is an open access article distributed under the terms of the [Creative Commons Attribution 3.0 License](https://creativecommons.org/licenses/by/3.0/), which permits unrestricted use, distribution, and reproduction in any medium, provided the original work is properly cited.

IntechOpen

IntechOpen