

We are IntechOpen, the world's leading publisher of Open Access books Built by scientists, for scientists

6,900

Open access books available

186,000

International authors and editors

200M

Downloads

Our authors are among the

154

Countries delivered to

TOP 1%

most cited scientists

12.2%

Contributors from top 500 universities



WEB OF SCIENCE™

Selection of our books indexed in the Book Citation Index
in Web of Science™ Core Collection (BKCI)

Interested in publishing with us?
Contact book.department@intechopen.com

Numbers displayed above are based on latest data collected.
For more information visit www.intechopen.com



Corneal Collagen Cross-Linking Using Riboflavin and Ultraviolet-A Irradiation in Keratitis Treatment

Vassilios Kozobolis, Maria Gkika and Georgios Labiris
*Eye Institute of Thrace and Department of Ophthalmology,
Medical School of Democritus University of Thrace
Greece*

1. Introduction

Cross-linking is a common method of tissue stabilization. For example, cross-linking is used for formaldehyde-induced tissue stiffening and fixation in pathologic specimens. Corneal collagen Crosslinking (CXL) is performed with ultraviolet-A (UVA) irradiation at 370 nm and the photosensitizer riboflavin (vitamin B₂). According to Wollensak (Wollensak, 2006), the photosensitizer is excited into its triplet state generating reactive oxygen species (ROS), which are mainly singlet oxygen and to a much lesser degree superoxide anion radicals. ROS can react further with various molecules inducing chemical covalent bonds that form bridges between amino groups of collagen fibrils (type II photochemical reaction). The biomechanical effect occurs immediately after irradiation leading to an increase of the biomechanical rigidity of the cornea of about 300%. The optimal wavelength of the ultraviolet (UV) radiation is 370 nm, at which riboflavin presents maximal absorption. Interestingly, a similar mechanism has been detected in the human crystalline lens (Krishna et al., 1991).

2. Corneal collagen cross-linking therapeutic protocol

All patients who are candidates for CXL treatment need to have maximum keratometric (K) readings less than 60 diopters (D) and a central corneal thickness (CCT) of at least 400 µm. All clinical trials of CXL refer to patients aged between 18 and 30 years. There are as yet no extensive clinical trials in children and this is the reason why great care must be taken when applying the CXL technique in patients younger than 18. In addition, patients with a history of herpetic keratitis, corneal scarring, severe eye dryness, pregnancy or nursing, previous anterior segment surgery, systemic collagen pathology or concomitant autoimmune diseases should be handled with great caution and perhaps better excluded.

In brief, the CXL procedure is conducted under sterile conditions in the operating room, after the patient's eye is anesthetized. According to the Dresden therapeutic protocol, the central 8 mm of the corneal epithelium are removed to allow better diffusion of riboflavin into the stroma. Without epithelial removal, the biomechanical effect is less than 50% of the standard cross-linking procedure. In fact, Botto's et al. (Botto's et al., 2008) conclude in their

study that treatment of the cornea with riboflavin and UVA without previous de-epithelialization did not induce any cross-linking effect. Consequently, to facilitate diffusion of riboflavin throughout the corneal stroma, the epithelium should be removed as an important initial step in the treatment (Botto's et al., 2008). Partial grid-pattern epithelial removal allows some riboflavin penetration, but uptake is limited and non-homogeneous, which may affect the efficacy of the cross-linking process (Samaras et al., 2009). Following de-epithelialization, a 0.1% riboflavin solution (10 mg riboflavin-5-phosphate in 10 ml dextran 20% solution) is instilled to the cornea for 30 min (2 drops every 2 min) prior to the irradiation, until the stroma is completely penetrated and the aqueous humour is stained yellow. Changes in application time and riboflavin concentration have only little influence on stromal depth diffusion (Søndergaard et al., 2010). Generally, the riboflavin film is an integral part of the CXL procedure and important in achieving the correct stromal and endothelial UVA irradiance (Wollensak et al., 2010). The irradiation is performed from 1 cm distance for 30 min using a UVA double diode at 370 nm and an irradiance of 3 mW/cm² (equal to a dose of 5.4 J/cm²). The required irradiance is controlled in each patient directly before the treatment to avoid a potentially dangerous UVA overdose (Wollensak et al., 2003a, 2003b). Instillation of riboflavin drops (1 drop every 2 min) is continued during irradiation as well, in order to sustain the necessary concentration of riboflavin. Moreover, balanced salt solution (BSS) is applied every 6 min to moisten the cornea.

A series of variations of the treatment protocol have been demonstrated. In 2009 Kanelopoulos (Kanellopoulos, 2009) demonstrated that CXL by means of a femtosecond laser facilitated intrastromal 0.1% riboflavin administration, with promising preliminary results. A limited but favourable effect of trans-epithelial CXL was noted on keratoconic eyes, without complications by Leccisotti et al. (Lecciotti and Islam, 2010). The effect appears to be less pronounced than described in the literature after CXL with de-epithelialization. In addition Bakke et al. (Bakke et al., 2009) attempted to compare the severity of postoperative pain and the rate of penetration of riboflavin between eyes treated by CXL using excimer laser superficial epithelial removal and mechanical full-thickness epithelial removal, and concluded that superficial epithelial removal using the excimer laser resulted in more postoperative pain and the need for prolonged application of riboflavin to achieve corneal saturation.

3. Laboratory studies

A series of laboratory studies attempted to explore all aspects of CXL procedure and particularly its biomechanical, thermomechanical, and morphological impact on corneal cells. A series of observations suggest that the CXL effect is maximal on the anterior part of cornea, the collagen fibre diameter is significantly increased only in the anterior half of the stroma, in enucleated porcine eyes CXL led to a significant change in the swelling behaviour of the anterior stroma (Wollensak et al., 2007a) and significant biomechanical and biochemical differences between the anterior and posterior parts were demonstrated in post-CXL corneas (Kohlhaas et al., 2006; Schilde et al. 2008).

Microcomputer-controlled biomaterial testing experiments indicated an impressive increase in corneal rigidity of 71.9% in porcine and 328.9% in human corneas, and an increase in Young's modulus by a factor of 1.8 in porcine and 4.5 in human corneas after CXL. Moreover, clinical observations suggest that riboflavin/UVA-induced collagen cross-linking

leads to an increase in biomechanical rigidity which remains stable over time (Wollensak and Iomdina, 2009; Kling et al., 2010).

However, the cross-linking effect was maximal only in the anterior 300 μm . The greater biomechanical effect in human corneas was attributed to the relatively larger portion of crosslinked stroma because of the lower total corneal thickness of 550 μm in human corneas compared with 850 μm in porcine corneas (Wollensak et al., 2003c). Also, in a patient with acute keratoconus (KC) who underwent CXL, a rapid progress of KC developed 2 years after treatment. This was probably due to the fact that CXL does not effectively treat the posterior corneal layers and Descemet's membrane, which are mainly affected by acute KC. In normal corneas, the anterior stroma is more rigid because it is designed to maintain the anterior corneal curvature. Interestingly, the anterior stroma of these corneas after CXL is found to be more cross-linked and still more rigid than the posterior one. This degree of rigidity is even preserved in the presence of corneal oedema (Muller et al., 2002).

In the anterior stroma of rabbit corneas treated with CXL, the collagen fibre diameter was significantly increased by 12.2% (3.96 nm), but by only 4.6% (1.63 nm) in the posterior stroma (Wollensak et al., 2004c). Similar changes have been reported in the cornea and other tissues due to age-related or diabetes mellitus-related collagen cross-linking. A possible explanation for this observation is that the induced cross-links push the collagen polypeptide chains apart, resulting in increased intermolecular spacing. On scanning electron microscopy, the collagen fibres of cross-linked vitreous humour also appeared markedly thickened and coarse (Faulborn et al., 1998).

Experiments in rabbits treated with riboflavin and variable UVA irradiances ranging from 0.75 to 4 mW/cm^2 indicated a variable apoptosis that was proportional to the irradiance power. The cytotoxic UVA irradiance level for keratocytes was determined to be about 0.5 mW/cm^2 (Wollensak et al., 2004a). The latter was also confirmed by in vitro studies on keratocyte cell cultures (Wollensak et al., 2004b). Cytotoxic apoptosis is followed by repopulation approximately after 4–6 weeks from the irradiation (Wollensak et al., 2007b).

In addition, in cross-linked porcine eyes, a markedly increased resistance to collagenase digestion was described, with a 15 day digestion time in the cross-linked samples compared with 6 days in the controls (Spoerl et al., 2004). This effect is stronger in the anterior half of the cornea.

4. Corneal collagen cross-linking in keratitis

Corneal ocular infections may have a profound and devastating impact on visual function. Ulcerative keratitis, often microbial in origin and presenting as central or peripheral corneal ulceration or infiltration, is a sight-threatening condition. It remains an important cause of blindness that requires skilled management and effective chemotherapy to preserve vision (Bennett et al., 1998). If diagnosis and initiation of appropriate antimicrobial treatment are delayed, it has been estimated that only 50% of eyes will heal with good visual outcome (Jones et al., 1981).

Although the treatment of corneal infections with topical antimicrobial agents has been notably successful, with an expanding array of both focused and broad-spectrum antibiotics, there has been an alarming resistance to antimicrobial agents (Neu, 1992; DeMuri and

Hostetter, 1995; Dever, 1996; Glynn et al., 1998; Levy, 1998). Microbes cleverly develop resistance to antibiotics as a result of chromosomal mutation, inductive expression of a latent chromosomal genes, or exchange of genetic material via transformation, bacteriophage transduction, or plasmid conjugation (Neu, 1992; Bennett et al., 1998). Use of the fluoroquinolones in the management of external infections is the most recent example of how a new class of antibiotics has been instrumental in changing management strategies for the treatment of corneal infections. Also, the antimicrobials currently in use are sometimes problematic because of their toxic effects on the ocular surface (e.g., punctate keratitis, delayed re-epithelialization, hyperemia, chemosis). Nonetheless, emerging patterns of resistance even to these new classes of antimicrobial agents (Daum et al., 1990; Smith et al., 1990; Thomson et al., 1991; Snyder et al. 1992; Maffett et al. 1993; Chin and Marx, 1994; Fass et al., 1995; Knauf et al., 1996; Garg et al., 1999; Goldstein et al., 1999) have stimulated the continuing quest for an agent that provides rapid and complete microbicidal activity with minimal toxic effects and susceptibility to mechanisms of microbial resistance.

The antimicrobial activity of UV irradiation includes sporicidal and virucidal effects. Traditional applications of UV light are disinfection of drinking water and air/surface disinfection. Limitations of the application of UV are mainly the lack of penetration and a strong dependence on the distance from the UV source, which may result in non-homogeneous microbial inactivation.

On the other hand, riboflavin, or vitamin B2, is a naturally occurring compound and an essential human nutrient. Riboflavin products, including lumichrome, are present and consumed in a wide range of foods and natural products in common use. Japanese scientists demonstrated in the 1960s that riboflavin, when exposed to visible or UV light, could be used to inactivate the RNA containing tobacco mosaic virus (Tsugita et al., 1965). Research has been developing since 2000 to use riboflavin as a photosensitizer to inactivate pathogens in plasma, platelet, and red cell products (Goodrich, 2000). The chemistry, toxicity, and ability of riboflavin to interact with nucleic acids after UVA photograph activation have also been extensively studied. Riboflavin and UVA (280-370 nm) may damage nucleic acids by direct electron transfer, production of singlet oxygen, and generation of hydrogen peroxide with formation of hydroxyl radicals. Pathogen DNA/RNA may be affected in the absence of oxygen. This process has proven effective against a wide range of pathogens, including bacteria, intracellular HIV-1, West Nile virus (WNV), and porcine parvovirus in preclinical studies of platelets and plasma. The process also damages leukocyte DNA in a manner that makes repair by normal pathways unlikely. There is a possibility that the riboflavin already present in the cornea serves as a natural antimicrobial mechanism. However, riboflavin concentration in the cornea is not enough to produce antimicrobial effects in overt keratitis. Since the riboflavin is photosensitive, it is more likely that the small content of corneal riboflavin will be depleted when exposed to sunlight UVA/riboflavin therefore may offer high efficacy with low protein damage and little toxicity.

This development leads to propose that it could act as a photosensitizer useful for the inactivation of pathogens found in corneal infections, because of its nucleic acid specificity and its limited tendency toward indiscriminate oxidation. Pitts et al. (Pitts et al., 1977) found corneal damage at the surface UVA dose (365 mV) of 42.5 J/cm², and Wollensak et al. (Wollensak et al., 2004a) described that riboflavin/UVA treatment leads to dose-dependent keratocytes damage in human corneas. The recent clinical use of a riboflavin/UVA

combination for corneal collagen cross-linking and the observations in the laboratory of keratocyte depletion after its application (Wollensak et al., 2003a, 2003b; Labetoulle, 2003; Kaufman, 2004) stimulated the evaluation of its application for corneal infection and the effort ultimately to expand the armamentarium of antimicrobial agents for the management of severe keratitis.

4.1 Corneal collagen cross-linking in infectious keratitis

In 2008, Martins et al. (Martins et al., 2008) demonstrated the antimicrobial properties of CXL against common pathogens. Some of the microbes used in this study were selected from a panel of human clinical ocular isolates from severe cases of bacterial keratitis treated at The Wilmer Ophthalmological Institute and maintained by the Microbiology Laboratory, Johns Hopkins University School of Medicine. The test panel of human clinical isolates maintained by the previously mentioned microbiology laboratory included oxacillin-resistant *Staphylococcus epidermidis* (ORSE), penicillin-resistant *Streptococcus pneumoniae* (PRSP), and pan-resistant *Pseudomonas aeruginosa* (PRPA). The other isolates used were individual cultures of freeze-dried microorganisms used to assist in the quality control of microbiologic media (LyfoCults; PML Microbiologicals, Wilsonville, OR), which included ORSE strain (SE), methicillin-resistant *Staphylococcus aureus* (MRSA), oxacillinsusceptible *Staphylococcus aureus* (SA), and susceptible *Pseudomonas aeruginosa* (PA). *Candida albicans* (CA) strains were selected from human clinical isolates in the Virology Sector and maintained by the Microbiology Laboratory (Johns Hopkins University School of Medicine). Approximately 90% of cases of bacterial keratitis is caused by one of four groups of organisms (1): PA (2) SA and Micrococcaceae, (3) SP, and (4) Enterobacteriaceae (Jones, 1979) *Pseudomonas* keratitis is one of the most serious corneal infections and represents one of the most threatening bacterial infections of the eye. Because of its aggressive behaviour and the frequency and context in which it occurs, PA was chosen as a pathogen in this study. SA was also used because of its frequency of occurrence as a clinical pathogen. SE is an uncommon clinical corneal pathogen; however, its common presence at the ocular surface and its occasional conversion to an opportunist led to its selection as a comparison test organism. SP is commonly associated with keratitis (3%–15% of cases).

They tested the riboflavin/UVA combined treatment against two settings of organisms based on their antibiotic susceptibility. Group 1 comprised non-resistant organisms: SA, PA, and SE. Group 2 was formed by antibiotic-resistant organisms: MRSA, PRPA, PRSP. CA was also tested in the same settings. The assay used was a disc diffusion susceptibility test based on the principle that a standardized inoculum of the organism is swabbed onto the surface of a Mueller-Hinton agar plate, and filter paper discs (Kirby-Bauer discs) impregnated with antimicrobial agents are placed on the agar. In this study, the discs were placed in the culture plates as reference points, to locate the areas where the riboflavin was previously instilled. The discs were also taken as a guide measurement for planimetric assays. Riboflavin drops were placed directly adjacent to the discs, to have an area where the light exposure would be performed. After 20 minutes of diffusion of the drops in the agar media, a beam of UVA light was directed to the selected location for 1 hour, in an attempt to photoactivate the vitamin solution or simply to irradiate the area of bacterial growth with UVA alone. The experiments were performed three times for each microorganism. After UVA irradiation, the agar plates were inverted and incubated for 24 hours at 34°C to 35°C in

an ambient-air incubator Digital images of each disc and the surrounding agar area were captured (AxioVision software; Axiovert 200M; Carl Zeiss Meditec Inc., Thornwood, NY), to measure the area of inhibition zone to the nearest whole millimetre (Herretes et al., 2006). The mean growth inhibition zone (GIZ) in square millimeters is inversely proportional to the minimum inhibitory concentration (MIC) of the organisms.

The results in the present study showed significant in vitro inhibition growth of test isolates using UVA alone and combined riboflavin/UVA treatment compared with the other types of treatment used in the study (B2 alone and B2 previously activated by UVA), for both setting of microorganisms. Seemingly, the results also demonstrate that UVA treatment alone is less effective in killing test isolates when compared with riboflavin/UVA combined treatment in the groups of bacteria tested. Of interest, a very localized response to the area of irradiation was observed, with well-defined margins of bactericidal activity, which may be particularly useful for corneal application. Riboflavin alone did not seem to have any effect as an antibacterial agent, but UVA alone may be effective against all test isolates in this study but resistant PA. The combined riboflavin/UVA treatment did not seem to have any effect on CA at the riboflavin concentrations tested (0.1% and 0.5%). In the non-resistant group, the efficacy of riboflavin/UVA treatment was greater against SA and SE, when compared with the treatment applied against PA. In the resistant group, we found the same effect, with the treatment being more effective against the Gram-positive microorganisms than against PA. Despite those findings, we cannot exclude PA as a potential microorganism to be treated with riboflavin/UVA treatment, as it showed some GIZ in both groups.

In 2010 Sauer et al. (Sauer et al., 2010) demonstrated the antimicrobial properties of riboflavin/UVA (365 nm) against fungal pathogens. The antimicrobial properties of riboflavin/UVA (365nm), with or without previous treatment with amphotericin B, were tested on three groups of fungi selected from severe cases of keratomycosis: *Candida albicans*, *Fusarium* sp, and *Aspergillus fumigatus*. They were tested by using Kirby-Bauer discs with empty disc (control), riboflavin 0.1% alone (R), UVA alone (UVA), riboflavin 0.1% and additional UV-A exposure (R_UVA), amphotericin B alone (A), amphotericin B and riboflavin 0.1% (A_R), amphotericin B and UVA (A_UVA), amphotericin B and riboflavin 0.1%, and additional UVA exposure (A_R_UVA). The mean growth inhibition zone (GIZ) was measured around the discs. *C. albicans*, *Fusarium* sp, and *A. fumigatus* did not show any increased GIZ after treatment without previous amphotericin B medication. However, GIZ was significantly greater after pretreatment with amphotericin B and riboflavin/UVA (A_R_UVA) for *C. albicans* ($P=.0005$), *Fusarium* sp ($P=.0023$) and *A. fumigatus* ($P=.0008$) compared with A, A_R, and A_UV-A. Amphotericin B is believed to interact with fungi membrane sterols to produce aggregates that form transmembrane channels. Given that collagen is one of the principal components of the cornea, it is also probable that amphotericin B may diffuse easily after cross-linking. Previous treatment with amphotericin B allowed riboflavin/UVA effectiveness against *C. albicans*, *Fusarium* sp, and *A. fumigatus*. This schema might be used in the future for the treatment of keratomycosis.

Since these results obtained in vitro do not always correlate with in vivo efficacy, further tissue culture models and animal studies are under way to test the efficacy of this treatment for infectious keratitis. Iseli et al. (Iseli et al., 2008) evaluated the efficacy of CXL for treating infectious melting keratitis. Five patients with infectious keratitis associated with corneal melting were treated with CXL when the infection did not respond to systemic and topical

antibiotic therapy. Follow-up after cross-linking ranged from 1 to 9 months. In all cases, the progression of corneal melting was halted after CXL treatment. Emergency keratoplasty was not necessary in any of the five cases presented. Moreover, Micelli-Ferrari et al. (Micelli-Ferrari et al., 2009) described a case of keratitis caused by the Gram-negative *Escherichia coli* treated with CXL with outstanding outcome. Similar results were also reported by Moren et al. (Moren et al., 2010), who treated an infectious keratitis using CXL.

4.2 Corneal collagen cross-linking in complicated bullous keratopathy with ulcerative keratitis

CXL's antimicrobial and anti-oedematous properties were demonstrated by (Kozobolis et al., 2010) in our report of two patients with combined bullous keratopathy and ulcerative keratitis, resistant to conventional treatments. Former investigators suggested that corneal cross-linking (CXL) might have beneficial impact against corneal melting from bacterial and fungal enzymes, because of the antimicrobial effect of UV-A radiation per se (Spoerl et al., 2004). Moreover, there is evidence that the post-CXL corneal stabilization might prevent the outflow of aqueous humour to the intracorneal space in diseases that manifest with endothelial decompensation. Based on the aforementioned hypothesis and evidence, we reported our experience with 2 patients with bullous keratopathy and corneal infectious keratitis resistant to topical medical treatment who underwent therapeutic CXL.

The first patient was a 78-year-old woman referred to our department because of deteriorating visual acuity (VA) and intense ocular discomfort (pain) in the right eye, whereas her left eye was otherwise healthy. Regarding the ophthalmological history, she had an extracapsular cataract extraction surgery in her right eye 4 years before her referral. According to her medical report, because of high postoperative intraocular pressure, she was administered timolol-dorsolamide, fixed combination (twice a day). The systemic history revealed diabetes and coronary heart disease. Ophthalmological examination revealed the following: A vision-threatening central corneal ulcer accompanied by bullous keratopathy (Figure 1), which resulted in poor visualization of the anterior chamber structures (Figure 2). Despite limited visibility, an anterior chamber intraocular lens could be visualized, in situ. Best-corrected visual acuity (BCVA) was limited to light perception, whereas corneal thickness (thinnest point) measured by ultrasound pachymetry (Pacline Optikon pachymeter, Optikon 2000 SpA; OPTIKON, Rome, Italy) was 641 mm (Table 1). The second patient was a 69-year-old man referred to our department because of deteriorating VA and intense ocular discomfort (pain) in his left eye, whereas his right eye was otherwise healthy. Regarding the ophthalmological history, he had an extracapsular cataract extraction surgery in his left eye, 3 years before his referral. Ever since the cataract operation, the patient was administered dorsolamide-timolol fixed combination because of postoperative ocular hypertension. His systemic history was uneventful. BCVA was 1/20 (Table 1). Slit-lamp biomicroscopy revealed bullous keratopathy accompanied by infectious keratitis (Figure 3). The corneal thickness at the thinnest point was 714 mm (Table 1). Further to antiglaucoma medications, both patients were administered intense local antibiotic treatment (ofloxacin and tobramycin drops). However, their private physicians reported progressive deterioration of the bullous keratopathy and depth of their ulcers. Because of the vision-threatening state of their corneas and the poor beneficial effect of local antibiotics, CXL was suggested as an experimental but potentially vision-saving adjuvant treatment.

The same surgical procedure was applied to both patients, according to the Dresden protocol. Prior antibiotic therapy was resumed after the surgical procedure with the addition of frequent instillation of artificial tears. Patients' progress was monitored in a daily basis for the first postoperative week for thorough evaluation of the reepithelialization process and potential adverse events and then every 15 days for a total of 2-month follow-up period.

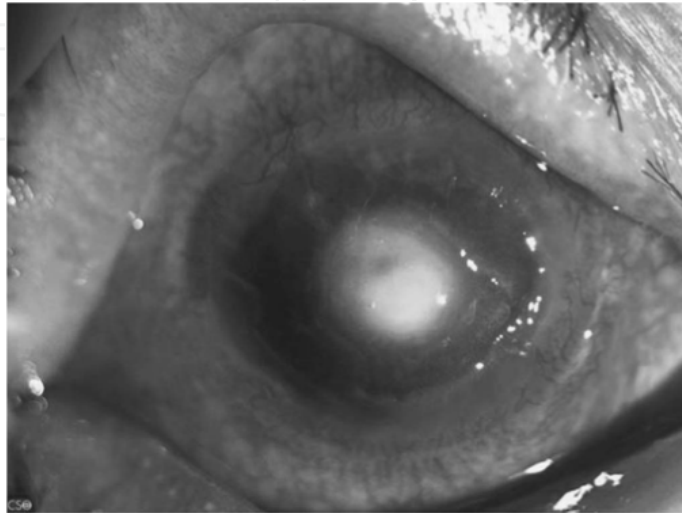


Fig. 1. Preoperative picture (case 1).

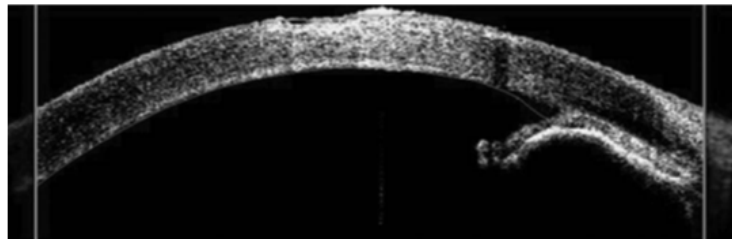


Fig. 2. Preoperative anterior chamber optical coherence tomography (case 1).

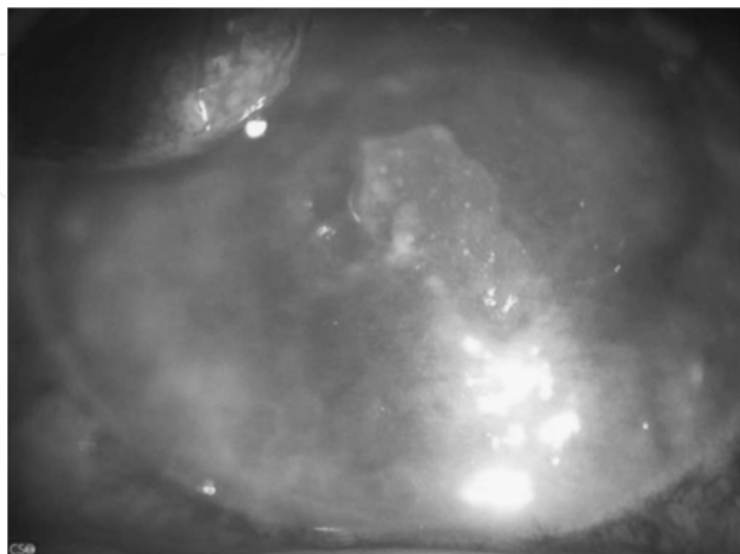


Fig. 3. Preoperative picture (case 2).

Both patients presented a gradual reduction of their corneal edemas associated with improved corneal clarity and VA. Moreover, slit-lamp biomicroscopy revealed significant improvement of the corneal ulcers (Table 1, Figures 4-7). The reepithelialization was completed within a week for both cases. Laboratory analysis of the corneal epithelial smears was negative in the first case, whereas in the case 2, *Streptococcus viridans* was developed. BCVA was improved in both cases within the first month after the treatment and remained stable during the follow-up period of 2 months.

	Preoperative		Postoperative	
	VA (Decimal Scale)	Corneal Thickness (Thinnest Point) (μm)	VA (Decimal Scale)	Corneal Thickness (Thinnest Point) (μm)
Case 1, 78-year-old woman	LP	641	2/10	595
Case 2, 68-year-old man	1/20	714	2/10	635

LP, light perception.

Table 1. Preoperative and Postoperative VA and Corneal Thickness

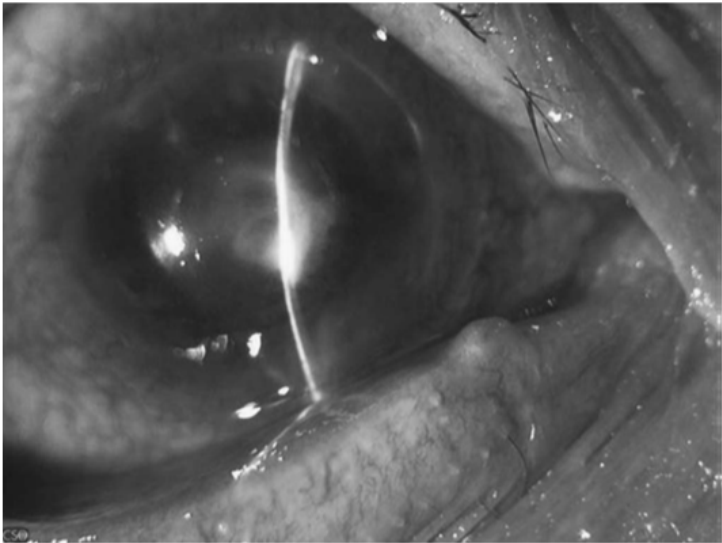


Fig. 4. First postoperative day (case 1).

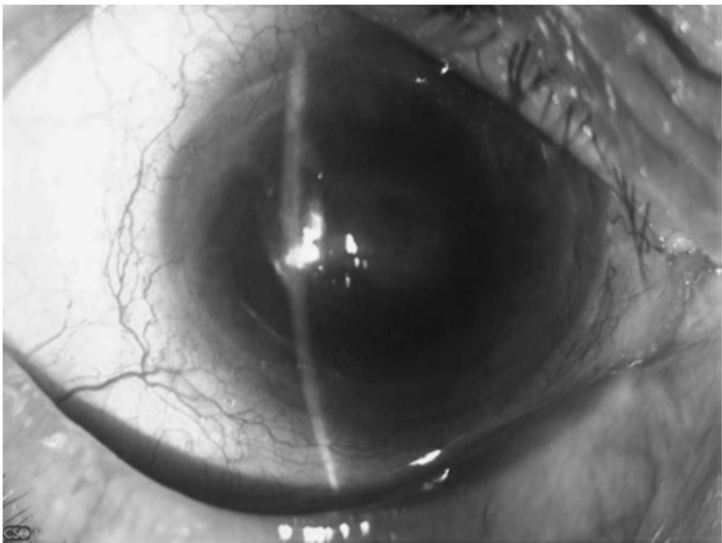


Fig. 5. Final postoperative day (case 1).

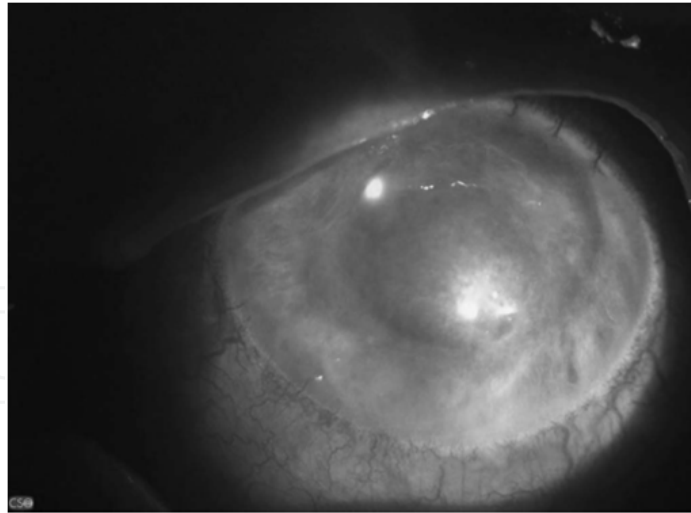


Fig. 6. First postoperative day (case 2).

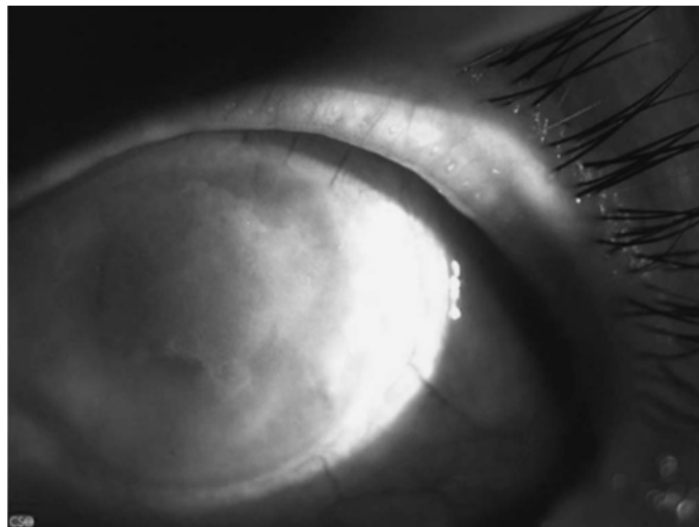


Fig. 7. Final postoperative day (case 2).

Regarding the cases presented above, the induced compactness of the cornea after CXL treatment interfered with the outflow of aqueous humor to the intracorneal space because of the decompensated endothelium. In fact, the impact of riboflavin and UV radiation on endothelial decompensation has been also described by Ehlers et al. (Ehlers et al., 2009). Our results confirm their hypothesis because both patients presented a decrease of their corneal thickness and disappearance of the corneal bullae. Moreover, the beneficial impact of the CXL treatment on corneal edema because of endothelial dysfunction might be inversely related to the extent of dysfunction. Thus, maximal therapeutic results are expected in early stages of endothelial decompensation. These results attempt to contribute to the body of knowledge regarding the potential therapeutic use of CXL with riboflavin in patients with bullous keratopathy and corneal infectious keratitis resistant to topical medical treatment that would otherwise be treated with penetrating keratoplasty. Obviously, more studies are required to explore the potential beneficial impact of the proposed therapeutic procedure and provide the necessary data for the development of a valid therapeutic protocol.

5. Risks and side-effects

Riboflavin is generally regarded as a safe compound since it is a vitamin ingested in normal diets and an omnipresent molecule in biological systems. It is also assumed that any residual riboflavin and any photoproducts produced during the treatment do not present any hazardous risks.

On the other hand, UV represents a potential danger to the human eye. It is well known that UV-induced photochemical damage, like sunburn or photokeratitis, is caused by UVB light, wavelengths of 270 to 315 nm, at power densities ranging from 0.12 to 0.56 J/cm². In the cornea UVB light (290–320 nm) is mainly absorbed by the corneal epithelium (Pitts et al., 1977; Podskochy, 2004). CXL uses a small peak-like sector of the UVA spectrum (370 nm). UVA absorption in the cornea is increased massively during the cross-linking procedure due to the photosensitizer riboflavin, resulting in a UVA transmission of only 7% across the cornea (Wollensak et al., 2003a). Experiments in rabbits indicated that the cytotoxic level for the corneal endothelium was 0.36 mW/cm². The standard CXL procedure cannot provide this cytotoxic level unless the central corneal thickness (CCT) is less than 400 µm (Wollensak et al., 2003d, 2003e). In general, UVA is absorbed mainly by the crystalline lens, which also contains endogenous riboflavin and other photosensitizers leading to cross-linking of crystallines (Krishna et al., 1991). This intrinsic system protects the retina and for this reason a UV absorber is usually incorporated into intraocular lenses. For the development of cataract, various power values have been reported in the literature at wavelengths between 290 and 365 nm. (Pitts et al., 1977; Olsen et al., 1982; Soderberg et al., 2003; Wollensak et al., 2004a; Kumar et al., 2004; Lin et al., 2004;) With the standard CXL procedure, the lens only receives 0.65 J/cm² which is far below the cataractogenous level of 70 J/cm² (Pitts et al., 1977). The retina is damaged by thermal or visible-light-induced photochemical damage in the wavelength range of 400–1400 nm. In the rhesus monkey, retinal damage with complete loss of the photoreceptor layer was reported at a threshold level of 81 mW/cm²; however, such extreme values are incompatible with the standard treatment protocol (Zuclich, 1989).

On the other hand, after CXL, the stroma is depopulated of keratocytes. HRT II-RCM confocal microscopy indicated that the reduction in anterior and intermediate stromal keratocytes is followed by gradual repopulation which will be concluded within 6 months. The UVA induces oxygen radicals which in turn induce covalent cross-linking of all kinds of proteins. The main and almost exclusive protein of the cornea is collagen type I, so that in the cornea the effect is focused on collagen. UVA can induce DNA and RNA lesions, an effect which is used for the disinfection of water etc. and also for the sterilization of aphaeresis blood products, efficiently killing viruses, bacteria and other pathogens. These cytotoxic DNA lesions are also the reason for the cytotoxic effect of the treatment on corneal keratocytes. As long as the cornea treated has a minimum thickness of 400 µm (as recommended), the corneal endothelium will not experience damage, nor will deeper structures such as lens and retina. The light source should provide a homogenous irradiance, avoiding hot spots (Mazzotta et al., 2007a; 70Spöerl et al., 2007; Avitabile et al., 1997; Mencucci et al. 2010; Esquenazi et al., 2010). Nevertheless, Mazzotta et al. (Mazzotta et al., 2007b) presented two cases, studied through in vivo confocal microscopy, with stage III KC that developed stromal haze after the cross-linking treatment, Kymionis et al. (Kymionis et al., 2010) reported the development of posterior linear stromal haze after simultaneous PRK followed by CXL and Raiskup et al. (Raiskup et al., 2009), after an extensive one-year

study of 163 eyes, concluded that advanced KC should be considered at higher risk of haze development after CXL due to low corneal thickness and high corneal curvature. In addition, Koppen et al. (Koppen et al., 2009) reported four cases of keratitis and corneal scarring from a total of 117 eyes treated with CXL and Sharma et al. (Sharma et al., 2010) presented a case report of *Pseudomonas* keratitis after collagen cross-linking for KC. Also, Garcia-Delpech et al. (Garcia-Delpech et al., 2010) reposted a case of *Fusarium* keratitis 3 weeks after healed corneal cross-linking. Apart from the above-mentioned complications, Gokhale et al. (Gokhale and Vemuganti, 2010) presented a case of acute corneal melt with perforation in a patient with KC after collagen cross-linking treatment and the use of topical diclofenac and proparacaine eyedrops. The use of diclofenac sodium and proparacaine eyedrops after surgery was possibly responsible for the corneal melt in this patient, so patients who have undergone cross-linking treatment should be observed closely until the corneal epithelium heals completely. In addition, a case of advancing KC treated with CXL complicated with sterile infiltrates was presented by Mangioris et al. (Mangioris et al., 2010). This complication may be an individual hypersensitivity reaction to the riboflavin or UVA light in the anterior stroma. At this point we should mention that Goldich et al. (Goldich et al., 2010) reported that CXL does not cause damage to the corneal endothelium and central retina and Koller et al. (Koller et al. 2009) made a significant effort to evaluate the complication rate of CXL for primary keratectasia and to develop recommendations for avoiding complications. Their results indicate that changing the inclusion criteria may significantly reduce the complications and failures of CXL. A preoperative maximum K reading of less than 58 D may reduce the failure rate to less than 3%, and restricting patient age to younger than 35 years may reduce the complication rate to 1%.

6. Conclusion

CXL is a promising therapeutic intervention for corneal tissue stabilization in diseases that manifest with progressive keratectasia, like keratoconus. Moreover, CXL's anti-oedematous and antimicrobial properties have been demonstrated in a series of studies, suggesting its therapeutic indications in bullous keratopathy and in infectious keratitis, as an adjuvant treatment to conventional therapeutic modalities. These cases show the positive effects of CXL with a satisfactory final visual outcome. CXL may be a promising new treatment for keratitis, although this remains to be elucidated in detail in future studies. Until more data are available this treatment should only be considered in therapy-refractive keratitis or ulceration and not in the first line of defence, since it may have cytotoxic side-effects.

7. References

- Avitabile, T., Marano, F., Uva, M.G. & Reibaldi, A. (1997). Evaluation of central and peripheral corneal thickness with ultrasound biomicroscopy in normal and keratoconic eyes. *Cornea* Vol. 16, No. 6, (November 1997), pp. 639-644, ISSN: 02773740
- Bakke, E.F., Stojanovic, A., Chen, X. & Drolsum, L. (2009). Penetration of riboflavin and postoperative pain in corneal collagen crosslinking: excimer laser superficial versus mechanical full-thickness epithelial removal. *J Cataract Refract Surg* Vol. 35, No. 8, (August 2009), pp. 1363-1366, ISSN: 08863350

- Bennett, H.G.B., Hay, J., Devonshire, P., Kirkness, C.M. & Seal, D.V. (1998). Antimicrobial management of presumed microbial keratitis: guidelines for treatment of central and peripheral ulcers. *Br J Ophthalmol*. Vol. 82, No. 2, (February 1998), pp. 137-145, ISSN: 00071161
- Botto's, K.M., Dreyfuss, J.L., Regatieri, C.V. et al (2008). Immunofluorescence confocal microscopy of porcine corneas following collagen cross-linking treatment with riboflavin and ultraviolet A. *J Refract Surg* Vol. 24, No. 7, (September 2008), pp. S715-S719, ISSN: 1081597X
- Chin, G.J. & Marx, Je. (1994). Resistance to antibiotics. *Science* Vol. 264, No. 5157, (1994), pp. 359, ISSN 00368075
- Cohen, M.A. & Huband, M.D. (1999). Activity of clinafloxacin, trovafloxacin, quinupristin/dalfopristin, and other antimicrobial agents versus *Staphylococcus aureus* isolates with reduced susceptibility to vancomycin. *Diagn Microbiol Infect Dis*. Vol. 33, No. 1, (January 1999), pp. 43-46, ISSN: 07328893
- Daum, T.E., Schaberg, D.R., Terpenning, M.S., et al. (1990). Increasing resistance of *Staphylococcus aureus* to ciprofloxacin. *Antimicrob Agents Chemother*. Vol. 34, No. 9, (1990), pp. 1862-1863, ISSN: 00664804
- DeMuri, GP & Hostetter, M.K. (1995). Resistance to antifungal agents. *Pediatr Clin North Am*. Vol. 42, No. 3, (1995), pp. 665-685, ISSN: 00313955
- Dever, L.L. & Handwerker, S. (1996). Persistence of vancomycin-resistant *Enterococcus faecium* gastrointestinal tract colonization in antibiotic-treated mice. *Microb Drug Resist*. Vol. 2, No. 4, (1996), pp. 415-421, ISSN: 10766294
- Ehlers, N., Hjortdal, J., Nielsen, K. & Søndergaard, A. (2009). Riboflavin-UVA treatment in the management of edema and nonhealing ulcers of the cornea. *J Refract Surg* Vol. 25, No. 9, (September 2009), pp. S803-S806, ISSN: 1081597X
- Esquenazi, S., He, J., Li, N. & Bazan, HE. (2010). Immunofluorescence of rabbit corneas after collagen cross-linking treatment with riboflavin and ultraviolet A. *Cornea* Vol. 29, No. 4, (April 2010), pp. 412-417 ISSN: 02773740
- Fass, R.J., Barnishan, J. & Ayers, L.W. (1995). Emergence of bacterial resistance to imipenem and ciprofloxacin in a university hospital. *J Antimicrob Chemother*. Vol. 36, No. 2, (1995), pp. 343-353, ISSN: 03057453
- Faulborn, J., Dunker, S. & Bowald, S. (1998). Diabetic vitreopathy: findings using the celloidin embedding technique. *Ophthalmologica* Vol. 212, No. 6, (1998), pp. 369-376, ISSN: 00303755
- Garcia-Delpech, S., Díaz-Llopis, M., Udaondo, P. & Salom, D. (2010). *Fusarium* keratitis 3 weeks after healed corneal cross-linking. *J Refract Surg*. Vol. 26, No. 12, (December 2010), pp. 994-995, ISSN: 1081597X
- Garg, P., Sharma, S. & Rao, G.N. (1999). Ciprofloxacin-resistant *Pseudomonas* keratitis. *Ophthalmology*. Vol. 106, No. 7, (July 1999), pp. 1319-1323, ISSN: 01616420
- Glynn, M.K., Bopp, C., Dewitt, W., et al. (1998). Emergence of multidrug-resistant *Salmonella enterica* serotype typhimurium DT104 infections in the United States. *N Engl J Med*. Vol. 338, No. 19, (May 1998), pp. 1333-1338, ISSN: 00284793
- Gokhale, N.S. & Vemuganti, G.K. (2010). Diclofenac-induced acute corneal melt after collagen crosslinking for keratoconus. *Cornea* Vol. 29, No. 1, (January 2010), pp. 117-119, ISSN: 02773740

- Goldich, Y., Marcovich, A.L., Barkana, Y., Avni, I. & Zadok, D. (2010). Safety of corneal collagen cross-linking with UV-A and riboflavin in progressive keratoconus. *Cornea* Vol. 29, No. 4, (April 2010), pp. 409–411, ISSN: 02773740
- Goldstein, M.H., Kowalski, R.P. & Gordon, Y.J. (1999). Emerging fluoroquinolone resistance in bacterial keratitis: a 5-year review. *Ophthalmology*. Vol. 106, No. 7, (July 1999), pp. 1313–1318, ISSN: 01616420
- Goodrich, R.P. (2000). The use of riboflavin for inactivation of pathogens in blood products. *Vox Sang*. Vol. 78, No. 2, (2000), pp. 211–215, ISSN: 00429007
- Herretes, S., Suwan-Apichon, O., Pirouzmanesh, A., et al. (2006). Use of topical human amniotic fluid in the treatment of acute ocular alkali injuries in mice. *Am J Ophthalmol*. Vol. 142, No. 2, (August 2006), pp. 271–278, ISSN: 00029394
- Iseli, H.P., Thiel, A.M., Hafezi, F. et al (2008). Ultraviolet A/riboflavin corneal cross-linking for infectious keratitis associated with corneal melts. *Cornea* Vol. 27, No. 5, (June 2008), pp. 590–594, ISSN: 02773740
- Jones, D.B. (1979). Initial therapy of suspected microbial corneal ulcers. II. Specific antibiotic therapy based on corneal smears. *Surv Ophthalmol*. Vol. 24, No. 2, (1979), pp. 97–116, ISSN: 00396257
- Jones, D.B. (1981). Decision-making in the management of microbial keratitis. *Ophthalmology*. Vol. 88, No. 8, (1981), pp. 814–820, ISSN: 01616420
- Kanellopoulos, A.J. (2009). Collagen cross-linking in early keratoconus with riboflavin in a femtosecond laser-created pocket: initial clinical results. *J Refract Surg* Vol. 25, No. 11, (November 2009), pp. 1034–1037, ISSN: 1081597X
- Kaufman, H.E. (2004). Strengthening the cornea. *Cornea* Vol. 23, No. 5, (July 2004), pp. 432, ISSN: 02773740
- Kling, S., Remon L., Perez-Escudero, A., Merayo-Llodes, J. & Marcos, S. (2010). Corneal biomechanical changes after collagen cross-linking from porcine eye inflation experiments. *Invest Ophthalmol Vis Sci* Vol. 51, No. 8, (August 2010), pp. 3961–3968, ISSN: 01460404
- Knauf, H.P., Silvany, R., Southern, P.M.J., et al. (1996). Susceptibility of corneal and conjunctival pathogens to ciprofloxacin. *Cornea*. Vol. 15, No.1, (1996), pp. 66–71, ISSN: 02773740
- Kohlhaas, M., Spoerl, E., Schilde, T. et al (2006). Biomechanical evidence of the distribution of cross-links in corneas treated with riboflavin, ultraviolet A light. *J Cataract Refract Surg* Vol. 32, No. 2, (February 2006), pp. 279–283, ISSN: 08863350
- Koller, T., Mrochen, M. & Seiler, T. (2009). Complication and failure rates after corneal crosslinking. *J Cataract Refract Surg* Vol. 35, No. 8, (August 2009), pp. 1358–1362, ISSN: 08863350
- Koppen, C., Vryghem, J.C., Gobin, L. & Tassignon, M.J. (2009). Keratitis and corneal scarring after UVA/riboflavin cross-linking for keratoconus. *J Refract Surg* Vol. 25, No. 9, (September 2009), pp. S819–S823, ISSN: 1081597X
- Kozobolis, V., Labiris, G., Gkika, M., Sideroudi, H., Kaloghianni, E., Papadopoulou, D. & Toufexis, G. (2010). UVA collagen cross linking treatment of bullous keratopathy combined with corneal ulcer. *Cornea* Vol. 29, No. 2, (February 2010), pp. 235–238, ISSN: 02773740

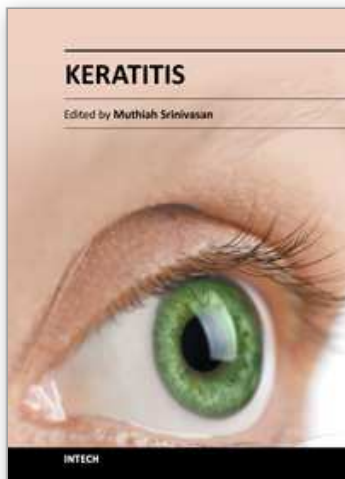
- Krishna, C.M., Uppuluri, S., Riesz, P. et al (1991). A study of the photodynamic efficiencies of some eye lens constituents. *Photochem Photobiol* Vol. 54, No. 1, (July 1991), pp. 51–58, ISSN: 00318655
- Kumar, V., Lockerbie, O., Kell, S.D. et al. (2004). Riboflavin and UV light based pathogen reduction: extend and consequence of DNA damage at molecular level. *Photochem Photobiol*. Vol. 80, No. 1, (July 2004), pp. 15-21, ISSN: 00318655
- Kymionis, G.D., Portaliou, D.M., Diakonis, V.F., Kontadakis, G.A., Krasia, M.S., Papadiamantis, A.G., Coskunseven & E., Pallikaris, A. (2010). Posterior linear stromal haze formation after simultaneous photorefractive keratectomy followed by corneal collagen cross linking. *Invest Ophthalmol Vis Sci* Vol. 51, No. 10, (October 2010), pp. 5030–5033, ISSN: 01460404
- Labetoulle, M. (2003). An alternative to corneal transplantation in keratoconus treatment? *J Fr Ophtalmol* Vol. 26, No. 10, (December 2003), pp. 1097–1098 ISSN: 01815512
- Leccisotti, A. & Islam, T. (2010). Transepithelial corneal collagen cross-linking in keratoconus. *J Refract Surg* Vol. 26, No. 12, (December 2010), pp. 942–948, ISSN: 1081597X
- Levy, S.B. (1998). Multidrug resistance: a sign of the times. *N Engl J Med*. Vol. 338, No. 19, (May 1998), pp. 1376-1377, ISSN: 00284793
- Lin, L., Dikeman, R., Molini, B., et al. (2004). Photochemical treatment of platelet concentrates with amotosalen and long-wavelength ultraviolet light inactivates a broad spectrum of pathogenic bacteria. *Transfusion*. Vol. 44, No. 10, (October 2004), pp. 1496-1504, ISSN: 00411132
- Maffett, M. & O'Day, D.M. (1993). Ciprofloxacin-resistant bacterial keratitis (letter). *Am J Ophthalmol*. Vol. 115, No. 4, (1993), pp. 545-546, ISSN: 00029394
- Mangioris, G.F., Papadopolou, D.N., Balidis, M.O., Poulas, J.L., Papadopoulos, N.T. & Seiler, T. (2010). Corneal infiltrates after corneal collagen cross-linking. *J Refract Surg* Vol. 26, No. 8, (August 2010), pp. 609-611, ISSN: 1081597X
- Martins, S.A., Combs, J.C., Noguera, G. et al (2008). Antimicrobial efficacy of riboflavin/UVA combination (365 nm) in vitro for bacterial and fungal isolates: a potential new treatment for infectious keratitis. *Invest Ophthalmol Vis Sci* Vol. 49, No. 8, (August 2008), pp. 3402–3408, ISSN: 01460404
- Mazzotta, C., Balestrazzi, A., Traversi, C. et al (2007a). Treatment of progressive keratoconus by riboflavin-UVA-induced cross-linking of corneal collagen: ultrastructural analysis by Heidelberg retinal tomograph II in vivo confocal microscopy in humans. *Cornea* Vol. 26, No. 4, (May 2007), pp. 390–397, ISSN: 02773740
- Mazzotta, C., Balestrazzi, A., Baiocchi, S., Traversi, C. & Caporossi, A. (2007b). Stromal haze after combined riboflavin- UVA corneal collagen cross-linking in keratoconus: in vivo confocal microscopic evaluation. *Clin Exp Ophthalmol* Vol. 35, No. 6, (August 2007), pp. 580–582, ISSN: 14426404
- Mencucci, R., Marini, M., Paladini, I., Sarchielli, E., Sgambati, E., Menchini, U. & Vannelli, G.B. (2010). Effects of riboflavin/UVA corneal cross-linking on keratocytes and collagen fibres in human cornea. *Clin Exp Ophthalmol* Vol. 38, No. 1, (January 2010), pp. 49–56, ISSN: 14426404

- Micelli-Ferrari, T., Leozappa, M., Lorusso, M. et al (2009). Escherichia coli keratitis treated with ultraviolet A/riboflavin corneal cross-linking: a case report. *Eur J Ophthalmol* Vol. 19, No. 2, (2009), pp. 295–297, ISSN: 11206721
- More'n, H., Malmsjo, M., Mortensen, J. & Ohrstrom, A. (2010). Riboflavin and ultraviolet a collagen crosslinking of the cornea for the treatment of keratitis. *Cornea* Vol. 29, No. 1, (January 2010), pp. 102–104, ISSN: 02773740
- Muller, L.J., Pels, E. & Vrensen, G. (2002). The specific architecture of the anterior stroma accounts for maintenance of corneal curvature. *Br J Ophthalmol* Vol. 85, (2002), pp. 437–443, ISSN: 00071161
- Neu, H.C. (1992). The crisis in antibiotic resistance. *Science* Vol. 257, No. 5073, (1992), pp. 1064–1073, ISSN: 00368075
- Olsen, E.G. & Ringvold, A. (1982). Human cornea endothelium and ultraviolet radiation. *Acta Ophthalmol (Copenh)*. Vol. 60, No. 1, (1982), pp. 54–56, ISSN: 0001639X
- Pitts, D.G., Cullen, A.P. & Hacker, P.D. (1977). Ocular effects of ultraviolet radiation from 295–365 nm. *Invest Ophthalmol Vis Sci* Vol. 16, No. 10, (1977), pp. 932–939, ISSN: 01460404
- Podskochy, A. (2004). Protective role of corneal epithelium against ultraviolet radiation damage. *Acta Ophthalmol Scand* Vol. 82, No. 6, (December 2004), pp. 714–717, ISSN: 13953907
- Raiskup, F., Hoyer, A. & Spoerl, E. (2009). Permanent corneal haze after riboflavin-UVA-induced cross-linking in keratoconus. *J Refract Surg* Vol. 25, No. 9, (September 2009), pp. S824–S828, ISSN: 1081597X
- Samaras, K., O'brart, D.P., Douth, J. et al (2009). Effect of epithelial retention and removal on riboflavin absorption in porcine corneas. *J Refract Surg* Vol. 25, No. 9, (September 2009), pp. 771–775, ISSN: 1081597X
- Sauer, A., Letscher-Bru, V., Speeg-Schatz, C., Touboul, D., Colin, J., Candolfi, E. & Bourcier, T. (2010). In vitro efficacy of antifungal treatment using riboflavin/UV-A (365 nm) combination and amphotericin B. *Invest Ophthalmol Vis Sci*. Vol. 51, No. 8, (August 2010), pp. 3950–3953, 01460404
- Schilde, T., Kohlhaas, M., Spoerl, E. & Pillunat, L.E. (2008). Enzymatic evidence of the depth dependence of stiffening on riboflavin/UVA treated corneas. *Ophthalmologe* Vol. 105, No. 2, (February 2008), pp. 165–169, ISSN: 0941293X
- Sharma, N., Maharana, P., Singh, G. & Titiyal, J.S. (2010). Pseudomonas keratitis after collagen crosslinking for keratoconus: case report and review of literature. *J Cataract Refract Surg* Vol. 36, No.3, (March 2010), pp. 517–520, ISSN: 08863350
- Smith, S.M., Eng, R.H.K., Bais, P., et al. (1990). Epidemiology of ciprofloxacin resistance among patients with methicillin-resistant Staphylococcus aureus. *J Antimicrob Chemother*. Vol. 26, No. 4, pp. 567–572, ISSN: 03057453
- Snyder, M.E. & Katz, H.R. (1992). Ciprofloxacin-resistant bacterial keratitis. *Am J Ophthalmol*. Vol. 114, No. 3, (1992), pp. 336–338, ISSN: 00029394
- Soderberg, P.G., Michael, R., Merriam, J.C. (2003). Maximum acceptable dose of ultraviolet radiation: a safety limit for cataract. *Acta Ophthalmol Scand*. Vol. 81, No. 2, (April 2003), pp. 165–169, ISSN: 13953907

- Søndergaard, A.P., Hjortdal, J., Breitenbach, T. & Ivarsen, A. (2010). Corneal distribution of riboflavin prior to collagen cross-linking. *Curr Eye Res* Vol. 35, No. 2, (February 2010), pp. 116–121, ISSN: 02713683
- Spoerl, E., Wollensak, G. & Seiler, T. (2004). Increased resistance of crosslinked cornea against enzymatic digestion. *Curr Eye Res* Vol. 29, No. 1, (July 2004), pp. 35–40, ISSN: 02713683
- Spoerl, E., Mrochen, M., Sliney, D. et al (2007). Safety of UVA-riboflavin cross-linking of the cornea. *Cornea* Vol. 26, No. 4, (May 2007), pp. 385–389, ISSN: 02773740
- Thomson, K.S., Sanders, C.C. & Hayden, M.E. (1991). In vitro studies with 5 quinolones: evidence for changes in relative potency as quinolone resistance rises. *Antimicrob Agents Chemother.* Vol. 35, No. 11, (1991), pp. 2329–2334, ISSN: 00664804
- Tsugita, A., Okada, Y. & Uchara, K. (1965). Photosensitized inactivation of ribonucleic acids in the presence of riboflavin. *Biochim Biophys Acta.* Vol. 103, No. 2, (June 1965), pp. 360–363, ISSN: 00052787
- Wollensak, G., Sporl, E. & Seiler, T. (2003a). Treatment of keratoconus by collagen crosslinking. *Ophthalmologe* Vol. 100, No. 1, (January 2003), pp. 44–49, ISSN: 0941293X
- Wollensak, G., Spoerl, E. & Seiler, T. (2003b). Riboflavin/ultraviolet- A-induced collagen crosslinking for the treatment of keratoconus. *Am J Ophthalmol* Vol. 135, No. 5, (May 2003), pp. 620–627, ISSN: 00029394
- Wollensak, G., Spoerl, E. & Seiler, T. (2003c). Stress-strain measurements of human and porcine corneas after riboflavin- ultraviolet-A-induced cross-linking. *J Cat Refr Surg* Vol. 29, No. 9, (September 2003), pp. 1780–1785, ISSN: 08863350
- Wollensak, G., Spoerl, E., Wilsch, M. & Seiler, T. (2003d). Endothelial cell damage after riboflavin-ultraviolet-A treatment in the rabbit. *J Cataract Refract Surg* Vol. 29, No. 9, (September 2003), pp. 1786–1790, ISSN: 08863350
- Wollensak, G., Sporl, E., Reber, F. et al (2003e). Corneal endothelial cytotoxicity of riboflavin/UVA treatment in vitro. *Ophthalmic Res* Vol. 35, No. 6, (2003), pp. 324–328, ISSN: 00303747
- Wollensak, G., Spoerl, E., Wilsch, M. & Seiler, T. (2004a). Keratocyte apoptosis after corneal collagen cross-linking using riboflavin/UVA treatment. *Cornea* Vol. 23, No. 1, (January 2004), pp. 43–49, ISSN: 02773740
- Wollensak, G., Spoerl, E., Reber, F. & Seiler, T. (2004b). Keratocyte cytotoxicity of riboflavin/UVA-treatment in vitro. *Eye* Vol. 18, No. 7, (July 2004), pp. 718–722, ISSN: 0950222X
- Wollensak G, Wilsch M, Spoerl, E. & Seiler, T. (2004c). Collagen fiber diameter in the rabbit cornea after collagen crosslinking by riboflavin/UVA. *Cornea* Vol. 23, No. 5, (July 2004), pp. 503–507, ISSN: 02773740
- Wollensak, G. (2006). Crosslinking treatment of progressive keratoconus: new hope. *Curr Opin Ophthalmol* Vol. 17, No. 4, (August 2006), pp. 356–360, ISSN: 10408738
- Wollensak, G., Aurich, H., Pham, D.T. & Wirbelauer, C. (2007a). Hydration behavior of porcine cornea crosslinked with riboflavin and ultraviolet A. *J Cataract Refract Surg* Vol. 33, No. 3, (March 2007), pp. 516–521, ISSN: 08863350

- Wollensak, G., Iomdina, E., Dittert, D.D. & Herbst, H. (2007b). Wound healing in the rabbit cornea after corneal collagen cross-linking with riboflavin and UVA. *Cornea* Vol. 26, No. 5, (June 2007), pp. 600–605, ISSN: 02773740
- Wollensak, G. & Iomdina, E. (2009). Long-term biomechanical properties of rabbit cornea after photodynamic collagen crosslinking. *Acta Ophthalmol* Vol. 87, No. 1, (February 2009), pp. 48–51, ISSN: 1755375X
- Wollensak, G., Aurich, H., Wirbelauer, C. & Sel, S. (2010). Significance of the riboflavin film in corneal collagen crosslinking. *J Cataract Refract Surg* Vol. 36, No. 1, (January 2010), pp. 114–120, ISSN: 08863350
- Zuclich, J.A. (1989). Ultraviolet-induced photochemical damage in ocular tissues. *Health Phys* Vol. 56, No. 5, (1989), pp. 671–682, ISSN: 00179078

IntechOpen



Keratitis

Edited by Dr. Muthiah Srinivasan

ISBN 978-953-51-0568-8

Hard cover, 62 pages

Publisher InTech

Published online 25, April, 2012

Published in print edition April, 2012

The 4 chapters in this book focus on investigation, basic and advanced clinical aspects and management of frequently encountered corneal disorders. The authors have covered keratitis theory and practice. Onchocerciasis, even though found on one continent, has its impact on population, epidemiologists, ophthalmologists, NGOs, public health planners and care providers. The goal of this book is to provide information on ancient eye diseases; their investigation and management to prevent corneal blindness. I acknowledge the great help rendered by Publishing Process Manager and Editor Relations Consultant.

How to reference

In order to correctly reference this scholarly work, feel free to copy and paste the following:

Vassilios Kozobolis, Maria Gkika and Georgios Labiris (2012). Corneal Collagen Cross-Linking Using Riboflavin and Ultraviolet-A Irradiation in Keratitis Treatment, Keratitis, Dr. Muthiah Srinivasan (Ed.), ISBN: 978-953-51-0568-8, InTech, Available from: <http://www.intechopen.com/books/keratitis/corneal-collagen-cross-linking-using-riboflavin-and-ultraviolet-a-irradiation-in-keratitis-treatment>

INTECH
open science | open minds

InTech Europe

University Campus STeP Ri
Slavka Krautzeka 83/A
51000 Rijeka, Croatia
Phone: +385 (51) 770 447
Fax: +385 (51) 686 166
www.intechopen.com

InTech China

Unit 405, Office Block, Hotel Equatorial Shanghai
No.65, Yan An Road (West), Shanghai, 200040, China
中国上海市延安西路65号上海国际贵都大饭店办公楼405单元
Phone: +86-21-62489820
Fax: +86-21-62489821

© 2012 The Author(s). Licensee IntechOpen. This is an open access article distributed under the terms of the [Creative Commons Attribution 3.0 License](https://creativecommons.org/licenses/by/3.0/), which permits unrestricted use, distribution, and reproduction in any medium, provided the original work is properly cited.

IntechOpen

IntechOpen