

# We are IntechOpen, the world's leading publisher of Open Access books Built by scientists, for scientists

6,900

Open access books available

186,000

International authors and editors

200M

Downloads

Our authors are among the

154

Countries delivered to

TOP 1%

most cited scientists

12.2%

Contributors from top 500 universities



WEB OF SCIENCE™

Selection of our books indexed in the Book Citation Index  
in Web of Science™ Core Collection (BKCI)

Interested in publishing with us?  
Contact [book.department@intechopen.com](mailto:book.department@intechopen.com)

Numbers displayed above are based on latest data collected.  
For more information visit [www.intechopen.com](http://www.intechopen.com)



## Bacterial Keratitis – Causes, Symptoms and Treatment

Hadassah Janumala, Praveen Kumar Sehgal and Asit Baran Mandal  
Central Leather Research Institute  
India

### 1. Introduction

The human eye is a complex organ of vital importance for everyday life. Eyes are the parts of our body that perceive light to see the world and to understand how objects relate to each other. We can distinguish far objects from close ones and determine their color and shape (Figure 1). The cornea is the dome-shaped window in the front of the eye. When looking at a person's eye, one can see the iris and pupil through the normally clear cornea. The cornea bends light rays as a result of its curved shape and accounts for approximately two-thirds of the eye's total optical power, with the lens of the eye contributing the remaining one-third. The cornea is as smooth and clear as glass but is strong and durable (Figure 2). It helps to shield the rest of the eye from germs, dust, and other harmful matter. The cornea shares this protective task with the eyelids, the eye socket, tears, and the sclera, or white part of the eye. A very thin tear film lies between the front of the cornea and our environment. The cornea copes very well with minor injuries or abrasions. If the highly sensitive cornea is scratched, healthy cells slide over quickly and patch the injury before infection occurs and vision is affected.

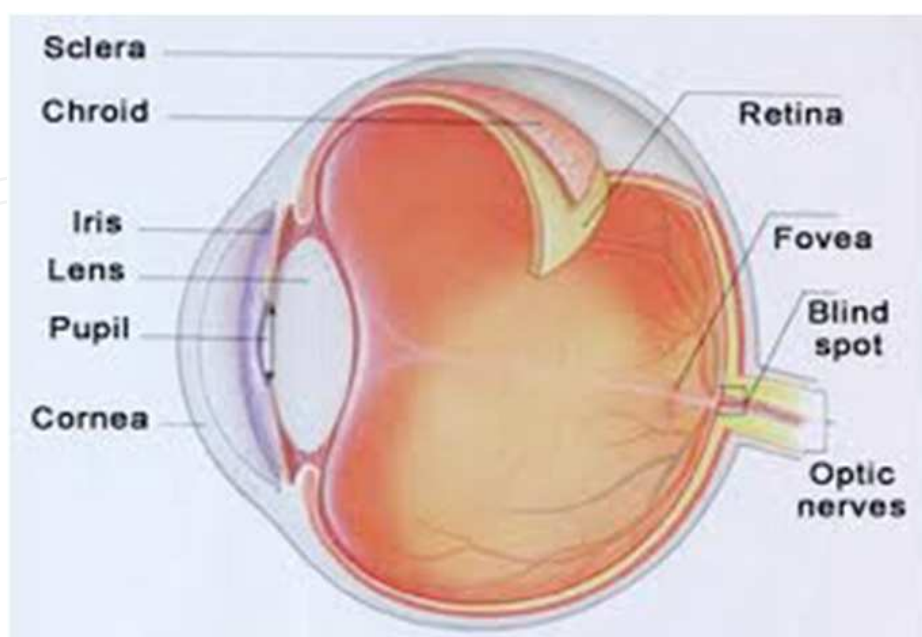


Fig. 1. Structure of the eye

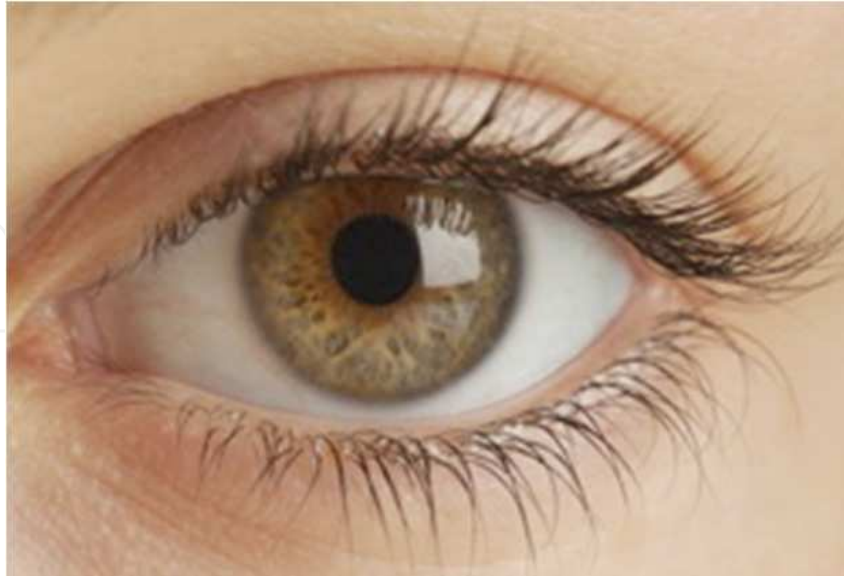

Fig. 2. Cornea is the clear part of the eye that covers the pupil

Bacterial keratitis is an infection and inflammation of the cornea that cause pain, reduced vision, light sensitivity and tearing or discharge from the eye that can, in severe cases cause loss of vision. Bacterial keratitis progresses rapidly and corneal destruction may be complete in 24 - 48 hours with some of the more virulent bacteria. The severity of the corneal infection usually depends on the underlying condition of the cornea and the pathogenicity of the infecting bacteria. It may involve the center of the cornea or the peripheral part of the cornea (that portion closest to the sclera) or both. Keratitis may affect one eye or both eyes. Keratitis may be mild, moderate, or severe and may be associated with inflammation of other parts of the eye (Figure 3). Keratitis can be classified by its location, severity, and cause. If keratitis involves the surface (epithelial) layer of the cornea, it is called superficial keratitis. Kerato-conjunctivitis is inflammation of the cornea and the conjunctiva. Kerato-uveitis is inflammation of the cornea and the uveal tract, which consists of the iris, ciliary body, and choroid. Keratitis may be acute or chronic. It may occur only once or twice in an eye or be recurrent. It may be limited in its effects on the eye or be progressive in its damage. Bacterial keratitis is a sight-threatening process. Many patients have a poor clinical outcome if aggressive and appropriate therapy is not promptly initiated. Some cases of keratitis results from unknown factors. Until recently, most cases of bacterial keratitis were associated with ocular trauma or ocular surface diseases. Various types of infections, dry eyes, injury, and a large variety of underlying medical diseases may all lead to keratitis.

Dry eye syndrome (DES; keratoconjunctivitis sicca) is a disorder of the tear film due to tear deficiency or excessive evaporation, which cause damage to the ocular surface. (Holly et al., 1977; Janumala H et al., 2009, 2010; Lemp et al., 1998; Tsubota et al, 1996) The signs of DES include foreign body sensation, ocular discomfort (scratchy, dry, sore, gritty, burning sensations) and problems with visual acuity. (Stern et al., 1998; Tsubota et al., 1992) Bacterial keratitis accounts for approximately 65% to 90% of all corneal infections. (Marios et al., 2007)

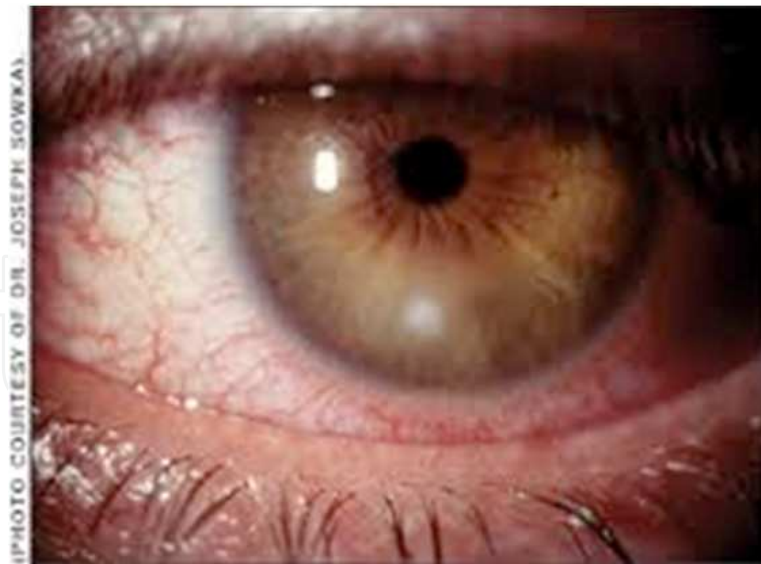

Fig. 3. Human eye with non-ulcerative Bacterial Keratitis

The spectrum of bacterial keratitis can also be influenced by geographic and climatic factors. Many differences in keratitis profile have been noted between populations living in rural or in city areas, in western, or in developing countries. Ulcerations of the cornea may occur, a condition known as ulcerative keratitis. Before the advent of antibiotics, syphilis was a frequent cause of keratitis. Corneal ulceration, stromal abscess formation, surrounding corneal edema, and anterior segment inflammation are characteristic of this disease. There are several types of keratitis, including superficial punctate keratitis, in which the cells on the surface of the cornea die; interstitial keratitis, a condition that can be either the direct result of infection, or more commonly secondary to an immunologic process; herpes simplex viral keratitis, caused by the sexually transmitted herpes virus; and traumatic keratitis, which results when a corneal injury leaves scar tissue. Early diagnosis and treatment is the key to minimizing any visual-threatening sequelae. In addition, close follow-up, attention to laboratory data, and changing antimicrobials if no clinical improvement is evident are important elements for successful outcome. The severity of the corneal infection usually depends on the underlying condition of the cornea and the pathogenicity of the infecting bacteria. Many patients have a poor clinical outcome if aggressive and appropriate therapy is not promptly initiated. (Acharya et al., 2009; Tang et al., 2009)

### 1.1 Epidemiology frequency

The most common predisposing factor for keratitis in southeast Brazil is trauma, especially corneal injury due to vegetation; observation clearly connected with following risk factors. The risk of agricultural predominance and vegetative corneal injury in fungal keratitis and associated ocular diseases in bacterial keratitis increase susceptibility to corneal infection. A hot, windy climate makes fungal keratitis more frequent in tropical zones, whereas bacterial keratitis is independent of seasonal variation and frequent in temperate zones. In tropical countries the incidence of bacterial keratitis is pathogens and show geographical variation in their prevalence. Thus, the spectrum of microbial keratitis varies with geographical location influenced by the local climate and occupational risk factors. In United States Approximately 25,000 Americans develop bacterial keratitis annually. International

incidence of bacterial keratitis varies considerably, with less industrialized countries having a significantly lower number of contact lens users and, therefore, significantly fewer contact lens-related infections. Mortality/Morbidity in cases of severe inflammation, a deep ulcer and a stromal abscess may coalesce, resulting in thinning of the cornea and sloughing of the infected stroma.

## 2. Causes of bacterial keratitis

Keratitis can lead to vision loss from corneal scarring. Physical or chemical trauma is a frequent cause of keratitis. If the cornea is hit and damaged by a foreign body (a finger nail, an arm, a metal splinter or through contact lenses), can cause a scratch to the cornea. Scratches are usually harmless and not very deep, but they give bacteria and viruses the possibility of attacks, which gives the cornea inflammation and should therefore be detected and treated. There are various types of keratitis, but most commonly it occurs after an injury to the cornea, dryness, inflammation of the ocular surface or contact lens wear. A wide variety of conditions can lead to inflammation of the cornea. Among them are viral, bacterial, or fungal infections; exposure to ultraviolet light such as sunlight or sunlamps; exposure to other intense light sources such as welding arcs or snow or water reflections; irritation from excessive use of contact lenses; dry eyes caused by an eyelid disorder or insufficient tear formation; a foreign object in the eye; a vitamin A deficiency; or a reaction to eye drops, eye cosmetics, pollution, or airborne particles such as dust, pollen, mold, or yeast. The condition is also a side effect of certain medications. Bacterial keratitis remains one of the most important potential complications of contact lens use and refractive corneal surgery. "Organisms can infiltrate an intact cornea of a lens-wearer, and a biofilm can form on the contact lens. Interruption of an intact corneal epithelium and/or abnormal tear film permits entrance of microorganisms into the corneal stroma, where they may proliferate and cause ulceration or secondary effect or molecules and cause infection. The epithelium and stroma in the area of injury and infection swell and undergo necrosis. Acute inflammatory cells (mainly neutrophils) surround the beginning ulcer and cause necrosis of the stromal lamellae. The collagen of the corneal stroma is poorly tolerant of the bacterial and leukocytic enzymes, and undergoes degradation, necrosis and thinning. This leads to scarring of the cornea. As thinning advances, the cornea may perforate, thus introducing bacteria into the eye with ensuing endophthalmitis. Corneal infections rarely occur in the normal eye. They are a result of an alteration in the cornea's defense mechanisms that allow bacteria to invade when an epithelial defect is present. The organisms may come from the tear film or as a contaminant from foreign bodies, contact lenses or irrigating solutions. The severity of the disease depends on the strain of the organism, the size of the inoculums, the susceptibility of the host and immune response, the antecedent therapy and the duration of the infection. The process of corneal destruction can take place rapidly (within 24hrs with virulent organisms) so that rapid recognition and initiation of treatment is imperative to prevent visual loss.

Contact lens users are at an increased risk of corneal ulcers (Figure 4, Figure 5). The annual incidence of bacterial keratitis with daily-wear lenses is 3 cases per 10,000. Contact lens is the leading cause of corneal inflammation, and if we as a contact lens user experience the following symptoms should seek medical attention right away. The injury may become secondarily infected or remain noninfectious. Retained corneal foreign bodies are frequent sources of keratitis. (Dart et al., 1988; Liesegang et al 1997; Moriyama et al., 2008; Musch et al 1983; Poggio et al., 1989; Weissman et al., 2002)



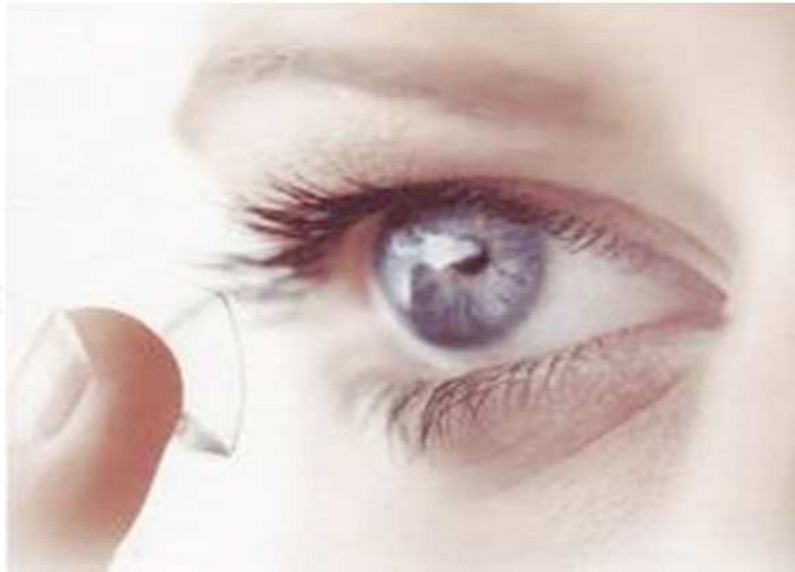

Fig. 4. Contact lens use

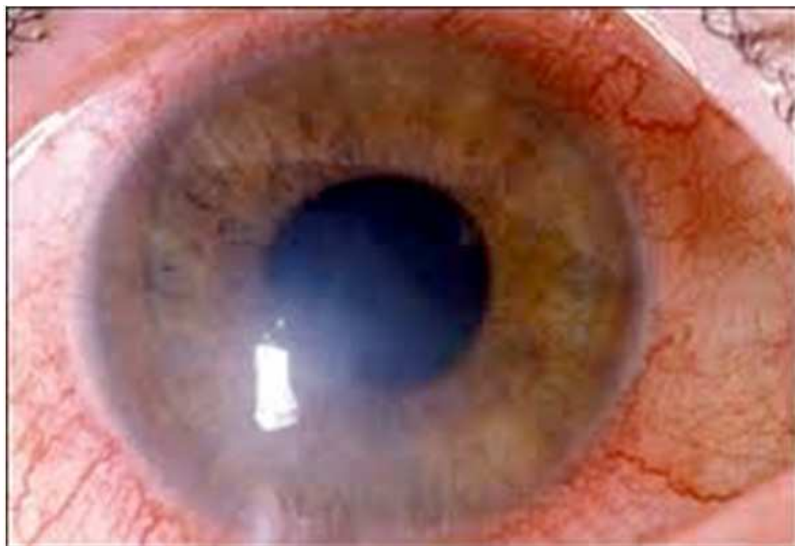


Fig. 5. Eye with keratitis infection due to contact lens use

### 2.1 Other causes for bacterial keratitis are

- Disturbances in the tear film may lead to changes in the corneal surface through drying of the corneal epithelium. This type of keratitis is usually superficial and most commonly is related to dry eyes and is known as keratitis sicca. If the eyes are extremely dry, the surface cells may die and form attached filaments on the corneal surface, a condition known as filamentary keratitis.
- Disorders that cause dry eyes; has no or limited germ fighting protection tears causing ulcers.
- Chemical solution splashes can injure the cornea and lead to corneal ulceration. Ultraviolet light from sunlight (snow blindness), a tanning light or a welder's arc, contact-lens over wear, and chemical agents, either in liquid form splashed into the eye or in gases in the form of fumes can all result in non-infectious superficial punctate keratitis,

- Inability to close the eyelids properly can also lead to cornea drying, including entropion with trichiasis and lagophthalmos a condition termed exposure keratitis.
- Allergies to airborne pollens or bacterial toxins in the tears may also cause a non-infectious type of keratitis. Autoimmune diseases create a similar appearance, often affecting the periphery of the cornea, termed marginal keratitis or limbic keratitis.
- Decreased immunologic defenses secondary to malnutrition, alcoholism, and diabetes (Moraxella).

Corneal ulcers are commonly caused by bacterial or fungal invasions following superficial corneal abrasions; among the common infectious agents are: staphylococcus, streptococcus, herpes (both simplex and zoster), adenovirus, rubeola, rubella, mumps, trachoma, infectious mononucleosis, and pneumococcus; also at fault may be Vitamin A deficiency or broad-spectrum antibiotic drug reactions. Corneal ulcers may also follow trauma, may be associated with other eye infections (e.g., conjunctivitis), may be related to other corneal disorders (e.g., degenerative conditions, or ptosis, which may cause a "dry eye"), or may arise from a variety of systemic disorders (especially those of autoimmune origin). In cases of severe inflammation, a deep ulcer and a stromal abscess may coalesce, resulting in thinning of the cornea and sloughing of the infected stroma. Once the corneal defenses are breached, specifically the epithelial glycocalyx, the cornea is prone to infection. Possible causes include direct corneal trauma, chronic eyelid disease, tear film abnormalities affecting the ocular surface and hypoxic trauma from contact lens wear. Pathogenic bacteria colonize the corneal stroma and immediately become antigenic, both directly and indirectly, by releasing enzymes and toxins. This sets up an antigen-antibody immune reaction that leads to an inflammatory reaction. The body releases polymorphonuclear leukocytes (PMNs) that aggregate at the area of infection, creating an infiltrate. The PMNs phagocytize and digest the bacteria. The collagen stroma is poorly tolerant of the bacterial and leukocytic enzymes and undergoes degradation, necrosis and thinning. This results in scarring of the cornea. With severe thinning the cornea may perforate, creating the possibility for endophthalmitis.

## 2.2 Gender

Males have a 30 to 40 per cent increased risk of developing keratitis compared to females. This gender difference has been reported previously for microbial keratitis. The reason for this association may be related to perceived health risks. Males have different attitudes and perceptions relating to health risks than do females, whereby they perceive risks as much smaller and much more acceptable. For example, males may be more inclined to underestimate the risk of developing corneal infiltrative events (CIE) when sleeping in contact lenses. (Efron et al., 2005a, 2005b, 2006; Morgan et al., 2005a, 2005b)

## 2.3 Smoking

Smoking was found to be associated with a 35 per cent greater risk of developing CIE's and this was increased to two-fold for severe keratitis. Others have reported similar findings. Smoking may be a risk factor for a number of reasons. It is generally considered that smoking is an unhygienic pursuit, which may be linked to a general lack of hygiene with respect to matters relating to contact lens wear and care. Toxins from smoke may either irritate the eyes directly or become absorbed into the contact lens and act as an irritant that

compromises the health of the ocular surface and predisposes the eye to the development of corneal infiltrative events (CIE). Cigarette smoke is known to have an immuno-modulatory effect, which may indirectly predispose a cigarette smoker to develop a CIE.

## 2.4 Ocular and general health

Lens wearers have approximately twice the risk of developing a CIE in the absence of compromised ocular and general health. The protective effect of compromised ocular health in lowering the risk of contact lens associated CIEs may be explained by the precautionary attitude adopted by those with compromised ocular health in that such persons may cease lens wear, reduce wearing time or use self-prescribed topical ocular medications in an attempt to alleviate their condition. Such strategies might have the secondary effect of precluding the development of a CIE. An alternative explanation is that compromised ocular health may be associated with a general up-regulation of the innate defense status of the eye, so that there is an ever-present resistance to extraneous challenges to the ocular surface, which could result in a CIE. These principles can be extended to explain why compromised general health also serves to protect the eye from developing a CIE.

## 2.5 Season

The notion that adverse ocular conditions related to contact lens wear can be influenced by the time of year (seasonal effect) is well established; for example, Begley, Riggle and Tuel reported that the onset of contact lens-associated papillary conjunctivitis was seasonal, in that the incidence of this condition peaked during the allergy seasons in mid-western USA. We found a two to four times increased risk of developing CIEs in late winter (January to March in the northern hemisphere) compared with mid-summer (July in the northern hemisphere). We accessed the number of consultations for influenza-like illness to the United Kingdom National Health Service helpline by people aged 15 to 64 years in England during the same period as the Manchester Keratitis Study. This number peaked around October and November 2003, which is in disaccordance with the peak incidence of CIEs in our study from January to March 2003. Interestingly, this observation is consistent with the finding of a lower incidence of CIEs in association with compromised general health. (Efron et al. 2006)

## 2.6 Risk of keratitis

In the Manchester Keratitis Study (Morgan et al 2005), logistic regression analyses were performed to investigate the association between a range of risk factors and the occurrence of CIEs. Daily wear of rigid lenses was found to be associated with a lower risk of developing CIEs compared with daily wear of hydrogel lenses. The risk of developing CIEs when sleeping in contact lenses is higher than in daily lens wear.

## 3. Symptoms of bacterial keratitis

The symptoms of keratitis usually include pain, tearing, and blurring of vision. The pain may be mild to severe, depending on the cause and extent of the inflammation. Sensitivity to light may also be present. To the observer, the eye may appear red, watery, and if the cornea has extensive keratitis, the normally clear cornea may look grey or have white to grey areas.



### 3.1 Physical

External and biomicroscopic examination of these patients reveal some or all of the following features: Ulceration of the epithelium; corneal infiltrate with no significant tissue loss; dense, suppurative stromal inflammation with indistinct edges; stromal tissue loss; and surrounding stromal edema. Increased anterior chamber reaction with or without hypopyon folds in the descemet membrane. Upper eyelid edema, Posterior synechiae surrounding corneal inflammation is either focal or diffuse, conjunctival hyperemia adherent mucopurulent exudate, endothelial inflammatory plaque.

#### A scratch on the cornea can cause

- Light annoyance.
- Blurred vision.
- Feeling "something in the eye".
- Pain

#### Cornea inflammation with bacteria cause

- Your eye turns red.
- Pain, impaired vision and sensitivity to light as a scratch.
- May be you see a gray-white speck in the eye (the pupil).

The patient will present with a unilateral, acutely painful, photophobic, eye. Visual acuity is usually reduced, and profuse tearing is common. There will be a focal stromal infiltrate with an overlying area of epithelial excavation. There is likely to be thick, ropy, mucopurulent discharge. The cornea will be very edematous. The conjunctival and episcleral vessels will be deeply engorged and inflamed, often greatly out of proportion to the size of the corneal defect. In severe cases, there will be a pronounced anterior chamber reaction, often with hypopyon. Intraocular pressure may be low due to secretory hypotony of the ciliary body, but most often will be elevated due to blockage of the trabecular meshwork by inflammatory cells. Often, the eyelids will also be edematous. Bacterial keratitis is a sight-threatening process. Bacterial keratitis makes the cornea cloudy. It may also cause abscesses to develop in the stroma, which is located beneath the outer layer of the cornea.

Interruption of an intact corneal epithelium and/or abnormal tear film permits entrance of microorganisms into the corneal stroma, where they may proliferate and cause ulceration. Virulence factors may initiate microbial invasion, or secondary effector molecules may assist the infective process. Many bacteria display several adhesions on fimbriated and non-fimbriated structures that may aid in their adherence to host corneal cells. During the initial stages, the epithelium and stroma in the area of injury and infection swell and undergo necrosis. Acute inflammatory cells (mainly neutrophils) surround the beginning ulcer and cause necrosis of the stromal lamellae. Diffusion of inflammatory products (including cytokines) posteriorly elicits an outpouring of inflammatory cells into the anterior chamber and may create a hypopyon. Different bacterial toxins and enzymes (including elastase and alkaline protease) may be produced during corneal infection, contributing to the destruction of corneal substance. The most common groups of bacteria responsible for bacterial keratitis are as follows: *Streptococcus*, *Pseudomonas*, *Enterobacteriaceae* (including *Klebsiella*, *Enterobacter*, *Serratia*, and *Proteus*), and *Staphylococcus* species.

### 3.2 Complications with keratitis

**Irregular astigmatism:** Another possible complication of these infections is uneven healing of the stroma, resulting in irregular astigmatism.

**Corneal perforation:** This is one of the most feared complications of bacterial keratitis that may result in secondary endophthalmitis and possible loss of the eye.

### 3.3 How is keratitis diagnosed?

Keratitis can be diagnosed by an ophthalmologist (a physician who specializes in diseases and surgery of the eye) by physical examination of the eye and history. The history consists of questions documenting a past medical and ocular history and the symptoms specific to the current visit. The eye examination will consist of checking the vision and careful inspection of the corneas using a slit lamp, which is a microscope with excellent illumination and magnification to view the ocular surface and the cornea in detail. In cases in which infection is suspected, a culture may be taken from the surface of the eye for specific identification of the bacteria, virus, fungus, or parasites causing keratitis. Slit lamp examination helps to diagnose the depth of the keratitis eye infection.

- Swab the eye or take samples from the eye to confirm the diagnosis of herpes simplex infection.
- Testing visual sharpness and clearness (visual acuity).
- Testing how well the pupil responds to light.
- Patients' history to know about any recent infection of the upper respiratory tract accompanied by cold sores.
- Blood tests may also be done in certain patients with suspected underlying disease.

### 3.4 What are the risk factors for keratitis?

- Major risk factors for the development of keratitis include any break or disruption of the surface layer (epithelium) of the cornea.
- The use of contact lenses increases the risk for the development of keratitis, especially in poor hygiene, improper solutions, or over wear of the lens.
- A decrease in the quality or quantity of tears predisposes the eye to the development of keratitis due to corneal drying.
- Disturbances of immune function through diseases such as AIDS or the use of medications such as corticosteroids or chemotherapy also increase the risk of developing keratitis.

### 3.5 Precautions and complications of corneal inflammation

If you have a job where you are exposed to metal pieces or similar things, you should wear goggles and visit a doctor when symptoms of a scratch on the cornea appear to prevent inflammation. Inflammation can spread deeper into the cornea and is difficult to treat. Therefore we should seek medical advice by herpes cornea inflammation every time. Bacteria can also produce a severe corneal inflammation, which in the worst case, permanent visual impairment. You must also not wear contact lenses before the eye has healed. If the scratch penetrates the cornea more deeply, however, the healing process will

take longer, at times resulting in greater pain, blurred vision, tearing, redness, and extreme sensitivity to light. These symptoms require professional treatment. Deeper scratches can also cause corneal scarring, resulting in a haze on the cornea that can greatly impair vision. In this case, a corneal transplant may be needed.

#### 4. Treatment of bacterial keratitis

Wound healing of the ocular surface is a special process due to its non-vascularity. It depends on surrounding corneal tissues for nourishment. Healing requires regeneration of the corneal and conjunctival epithelium, reduced scar formation, retention of transparency of cornea and mobility of the conjunctiva. (Janumala H et al., 2009; Reim et al. 1997) The process of corneal wound healing consists of different phases, i.e. latent phase, cell migration, adhesion and

cell proliferation. Another fluoroquinolone, ofloxacin 0.3% (Ocuflox) is also an effective treatment for bacterial keratitis. Both fluoroquinolones are as effective at managing bacterial keratitis as fortified antibiotics, but with significantly fewer side effects. (Marios et al., 2007; Baker et al., 1996) Adjunctive use of cold compresses will also help to reduce inflammation. If there is evidence of secondary inflammatory glaucoma, Rx a topical beta-blocker BID. Have the patient return daily for follow-up visits. Once the infection is controlled, add a topical steroid Q2H to the regimen. Continue the daily follow-up and begin to taper all medications as you see improvement. (McLeod et al., 1995)

##### 4.1 What is the treatment for keratitis?

Medical treatment is absolutely essential - even a delay of a few hours can affect the ultimate visual result. The causative factors must be determined through laboratory analysis of scrapings; medical treatment (i.e., medication) varies according to the cause. As with bacterial conjunctivitis, culturing the infection is the ideal way to determine the infecting organism but is often difficult or impractical. First and foremost, you must halt bacterial proliferation; do not delay treatment while waiting for the culture results. If you have the materials available, scrape the ulcer using a platinum spatula and plate the specimen into blood and chocolate agar culture media. A simpler but less effective method is to use a culturette. (McLeod et al 1996; Miedziak et al., 1999; Schaefer et al., 2001) Regardless, immediately begin therapy with a broad - spectrum antibiotic. A popular initial therapy is the fluoroquinolone ciprofloxacin 0.3% (Ciloxan) two drops every 15 minutes for six hours, followed by two drops every 30 minutes for 18 hours, and then tapered depending on patient response. Infectious keratitis generally requires antibacterial therapy to treat the infection. This treatment can involve prescription eye drops, pills, or even intravenous therapy. Any corneal or conjunctival foreign body should be removed. Wetting drops may be used if disturbance of the tears is suspected to be the cause of the keratitis. Steroid drops may often be prescribed to reduce inflammation and limit scarring. This must be done carefully and judiciously, since some infections can be worsened with their use. Treatment depends largely on the source of the problem. If a common adenoviral virus is causing the keratitis, the condition is likely to clear up on its own, usually in about two to three weeks. Available medications for this form of keratitis include palliative treatment. Contact-lens wearers are typically advised to discontinue contact-lens wear, whether or not the lenses are related to the cause of the keratitis.

#### 4.2 Treatment of scratches on the cornea

- Foreign body should be removed if it sits in the eye.
- Antibiotics-drops to prevent inflammation.
- Possibly putting a small bandage over the eye in order to give it a little calm.

#### 4.3 Keratitis antibiotic treatment

*Staphylococcus aureus* is a major cause of bacterial keratitis. (Alexandrakis et al., 2003; Liesegang et al. 1998) *S. aureus* ocular infections can cause severe inflammation, pain, corneal perforation, scarring, and loss of visual acuity. (Chusid et al., 1979) *S. aureus* has a long history of evolving to more resistant states, and this trend is expected to continue. (Hiramatsu et al., 1997; Peterson, 1999) Therefore, new antibiotics and new antibiotic formulations are needed to manage future cases of *S. aureus*-induced keratitis. Moxifloxacin and gatifloxacin are “fourth generation” fluoroquinolone antibiotics that target bacterial DNA gyrase (topoisomerase II) and topoisomerase IV. (Adams et al., 1992; Dalhoff et al., 1996; Kato et al., 1992; Shen, 1994) These fourth generation fluoroquinolones have in vitro activity similar to that of ciprofloxacin and ofloxacin (extended-spectrum fluoroquinolones) against gram-negative bacteria but enhanced activity against gram-positive bacteria, including *S. aureus*. (Biedenbach et al., 1996; Davis et al. 1994) A broadspectrum antibiotic may prevent secondary bacterial infection. Chronic dendritic keratitis may be effectively treated with vidarabine, long term topical therapy may be necessary. Keratitis due to exposure requires application of moisturizing ointment to the exposed cornea and protects it with eye patch. Severe corneal scarring may be treated by keratoplasty (cornea transplantation). Slit lamp photography can be useful to document the progression of the keratitis, A B-scan ultrasound can also be carried out in severe corneal ulcers with no view of the posterior segment. The fourth-generation ophthalmic fluoroquinolones include moxifloxacin and gatifloxacin and they are now being used for the treatment of bacterial conjunctivitis. Both antibiotics have better in vitro activity against gram-positive bacteria than ciprofloxacin or ofloxacin. Moxifloxacin penetrates better into ocular tissues than gatifloxacin and older fluoroquinolones; in vitro activity of moxifloxacin and gatifloxacin against gram-negative bacteria is similar to that of older fluoroquinolones. Polymicrobial keratitis has been reported in up to 12% of cases and can be difficult to treat. The use of multiple antibiotics simultaneously and with frequent dosing may result in added toxicity and damage to the ocular surface epithelium, thereby impairing recovery. Demonstration of broad-spectrum efficacy, excellent safety profiles in ocular infections, and a distinct mode of resistance acquisition. Moxifloxacin is a fourth-generation fluoroquinolone that exhibits a broad spectrum of bactericidal activity against both Gram-positive and Gram - negative bacterial pathogens, including staphylococci, *S. pneumoniae*, members of the family enterobacteriaceae, *P. aeruginosa*, *H. influenzae*, and *Moraxella* species. Moxifloxacin also has better mutant prevention characteristics than other fluoroquinolones. Moxifloxacin has also been shown to have superior activity compared with ciprofloxacin against quinolone resistant strains of *S. aureus*. Data also shows superior corneal and aqueous penetration of moxifloxacin (Solomon R, Donnenfeld E, et al.) Penetration of topically applied gatifloxacin 0.3%, moxifloxacin 0.5% and ciprofloxacin 0.3% into the aqueous humor.

#### 4.4 Treatment with Succinylated Collagen Bandage lenses (SCBL)

Succinylated Collagen Bandage Lenses SCBL, are prepared with modified collagen (pH7.4) a natural biopolymer with biocompatibility with the human cornea, bioerodability, non-immunogenicity, high oxygen permeability, good water content, optimum thickness and

superior physiological environment compared to hydrogel lenses. When used as a corneal adjunct in various conditions SCBL eliminates side effects such as irritation of the cornea, inflammation, watering, reduced visual acuity etc. SCBL shows promise to treat dry eyes, keratitis and epithelial trauma. (Janumala H et al., 2008, Janumala H et al., 2009)

#### 4.5 Complications of keratitis?

Superficial keratitis involves the superficial layers of the cornea and commonly does not lead to scarring. More extensive keratitis involves deeper layers of the cornea, and a scar may develop upon healing. This will affect the vision if the central portion of the cornea is involved. With severe ulcerative keratitis, the cornea may perforate, which is an extremely serious situation. With proper diagnosis and appropriate treatment including follow-up care, keratitis can usually be managed without causing permanent visual disturbances. (Callegan et al., 1992; Davis et al. 1978) Vision often improves with treatment of the underlying infection. However, there may be some scarring of the cornea after treatment that may or may not affect vision in the long run. If the corneal scarring is in the center of the cornea, where it affects the line of site, a corneal transplant may ultimately be needed to improve the vision.

#### 4.6 Can keratitis be prevented?

The risk of keratitis can be reduced through the use of safety precautions to avoid eye injury, and the prompt treatment of early ocular symptoms.

- Many forms of keratitis can be prevented by good hygiene.
- Protecting the cornea from injury is the first step, since keratitis also results from a corneal injury.
- If you have a cold sore or genital herpes, avoid touching the eyes.
- Have well balanced diet, including vitamin A rich foods such as carrots, squash, mangoes, sweet potatoes and spinach.

##### 4.6.1 Prevention tips for contact lens users

- Contact lens users should always use sterile lens cleanser and disinfection solution.
- Do not over use contact lenses at night and make the eyes red or irritated.
- Never sleep with the contact lenses in the eyes.
- Always store the lenses in disinfecting solutions overnight.
- Regularly clean your contact lens case.
- Careful contact-lens care including proper cleaning of contact lens cases.

##### 4.6.2 Keratitis home remedies

- A sterile, cotton-tipped applicator may be used to gently remove infected tissue and allow the eye to heal more rapidly.
- Can wear an eye patch to protect it from bright light and foreign particles.
- Minor infections are treated with antibacterial or antifungal eye drops.
- If keratitis is caused by dry eye, artificial tears for lubrication are effective.
- Vitamin supplementation such as vitamin A can be used in case deficiency is a suspected cause.



#### 4.7 Clinical pearls

- If a patient presents with a corneal infiltrate but no overlying epithelial staining, the condition is not bacterial keratitis. If there is epithelial breakdown but only minor inflammation and anterior chamber reaction, then it is most likely not infectious bacterial keratitis.
- The inflammatory reaction is as damaging to the cornea as the infective organism. Once you've halted bacterial proliferation, be sure to prescribe a steroid to speed healing and reduce corneal scarring. For steroids to be beneficial, they must be used while the ulcer bed is still open, usually within the first 24 to 48 hours. If you wait until the ulcer re-epithelializes before adding a steroid, the beneficial effects will be lost.

#### 5. Conclusion

- It is extremely important to treat keratitis before corneal tissue is destroyed and scar tissue is formed. Because the pain is so severe in keratitis, the patient usually welcomes medical attention. However, if the cornea loses its sensitivity (as in trauma, surgery, or damage to the trigeminal nerve), ulcers can develop without accompanying pain.
- The implications for personal hygiene are evident, especially with children. Hand washing *during* periods of illness and following toileting is of vital importance as a preventive measure.

#### 6. Acknowledgements

I thank Dr. A. B. MANDAL, Director, CLRI-CSIR for his support to publish this book chapter. I am thankful to my husband Dr. Victor B. Kassey and my loving children Sharon Kassey, Angela Kassey and Daniel Kassey for their unconditional love, support and encouragement. Above all, I thank God for "*He has made everything beautiful in its time*" (Ecclesiastes 3:11).

#### 7. References

- Acharya, N.R., M. Srinivasan, J. Mascarenhas, *et al.* (2009) "The Steroid Controversy in Bacterial Keratitis." *Arch Ophthalmol.*, 127, 1231.
- Adams, D. E., Shekhtman, E. M., Zechiedrich, E. L., Schmidt, M. B., & Cozzarelli, N. R. (1992), The role of topoisomerase IV in partitioning bacterial replicons and the structure of catenated intermediates in DNA replication. *Cell*, 71, 277–288.
- Alexandrakis, G., Alfonso, E. C., & D. Miller. (2000), Shifting trends in bacterial keratitis in south Florida and emerging resistance to fluoroquinolones, *Ophthalmology* 107, 1497–1502.
- Baker, RS, Flowers, Jr. CW, Casey, R, *et al.* (1996) Efficacy of ofloxacin vs. cefazolin and tobramycin in the therapy for bacterial keratitis. *Arch. Ophthalmol*, 114, 632–633.
- Biedenbach, D. J., & Jones, R. N. (1996), The comparative antimicrobial activity of levofloxacin tested against 350 clinical isolates of streptococci. *Diagn. Microbiol. Infect. Dis.* 25, 47–51.

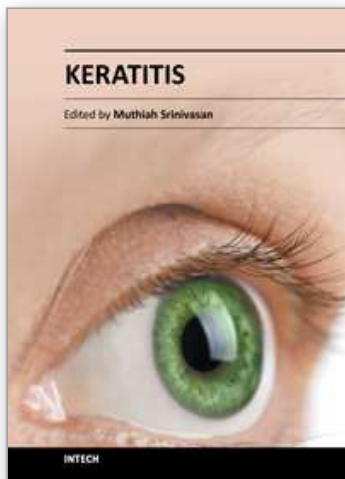
- Callegan, M. C., Hobden, J. A., Hill, J. M., Insler, M. S., & O'Callaghan R. J. (1992), Topical antibiotic therapy for the treatment of experimental *Staphylococcus aureus* keratitis, *Investig. Ophthalmol. Vis. Sci.* 33, 3017–3023.
- Chusid, M. J., & S. D. Davis. (1979). Experimental bacterial keratitis in neutropenic guinea pigs: polymorphonuclear leukocytes in corneal host defense. *Infect. Immun.* 24, 948–952.
- Dalhoff, A., Petersen, U., & Endermann, R. (1996), In vitro activity of BAY 12–8039, a new 8-methoxyquinolone. *Chemotherapy* 42, 410–425.
- Dart, J.K. (1988), Predisposing factors in microbial keratitis: the significance of contact lens wear. *Br. J. Ophthalmol.* 72, 926–930.
- Davis, R., & Bryson H. M. (1994), Levofloxacin. A review of its antibacterial activity, pharmacokinetics and therapeutic efficacy. *Drugs*, 47, 677–700.
- Davis, S.D., Sarf, L.D., & Hyndiuk, R.A. (1978), Topical tobramycin therapy of experimental *Pseudomonas* keratitis: an evaluation of some factors which potentially enhance efficacy. *Archives of Ophthalmology*, 96, 123–125.
- Efron, N, Morgan, P.B, Hill, E.A, Raynor, & MK, Tullo, A.B. (2005a), The size, location and clinical severity of corneal infiltrative events associated with contact lens wear. *Optom Vis. Sci.*, 82: 519–527.
- Efron, N, Morgan, PB, Hill, EA, Raynor, & MK, Tullo. AB. (2005b), Incidence and morbidity of hospital-presenting corneal infiltrative events associated with contact lens wear, *Clin. Exp. Optom.*, 88, 232–239.
- Efron, N., & Morgan, P.B. (2006) Impact of differences in diagnostic criteria when determining the incidence of contact lens associated keratitis, *Optom. Vis. Sci.*, 83, 152–159.
- Hiramatsu, K., Aritaka, N., Hanaki, Kawasaki, H., S., Hosoda, Hori, Y., S., Fukuchi, Y., & Kobayashi, I. (1997), Dissemination in Japanese hospitals of strains of *Staphylococcus aureus* heterogeneously resistant to vancomycin. *Lancet* 350, 1670–1673.
- Holly, F.J., & Lemp, M.A. (1977) Tear physiology and dry eyes, *Surv. Ophthalmol.*, 22, 69–87.
- Janumala, H., Namita, B., Rao, U, & Sehgal, P. K. (2009), Evaluation of Succinylated Collagen Bandage Lenses in Corneal Healing by the Expression of Matrix Metalloproteinases (MMP-2 and MMP-9) in Tear Fluid, *Ophthalmic Res.*, 42, 64–72.
- Janumala, H., Namita, B., Deepti, S., & Sehgal, P.K. (2010) Preparation and Clinical Evaluation of Succinylated Collagen Punctal Plugs in Dry Eye Syndrome - A Pilot Study, *Ophthalmic Res.* 43, 185–192.
- Kato, J., Suzuki, H., & Ikeda, H. (1992), Purification and characterization of DNA topoisomerase IV in *Escherichia coli*, *J. Biol. Chem.* 267, 25676–25684.
- Lemp, M.A. (1998) Epidemiology and classification of dry eye in lacrimal gland tear film and dry eye syndromes 2; in Sullivan D (Ed): Dartt DA, Meneray MA. New York, Plenum Press, pp 791–803.
- Lemp, MA., (2000), Evaluation and differential diagnosis of keratoconjunctivitis sicca. *J. Rheumatol Suppl.*, 61, 11–14.
- Liesegang, T.J. (1997), Contact lens-related microbial keratitis: Part I: Epidemiology, *Cornea*, 16, 125–131.
- Liesegang, T.J. (1998), Bacterial and fungal keratitis, pp 159–219. In H. E. Kaufman (ed.), *The cornea*, 2nd ed. Butterworth-Heinemann, Boston, Mass.

- Marios, C., Mark, D., Grant, R. S., Hien T. Vu, Hugh, R. Taylor, AC, (2007) Clinical Efficacy of Moxifloxacin in the Treatment of Bacterial Keratitis - A Randomized Clinical Trial, *Ophthalmology*, Vol. 114, Issue 9, pp 1622-1629.
- McLeod, SD., LaBree, LD., & Tayyanipour, R., *et al.* (1995), The importance of initial management in the treatment of severe infectious corneal ulcers, *Ophthalmology*, 102, 1943-1948.
- McLeod, S.D., Kolahdouz, I.A., & Rostamian, K., *et al.* (1996), The role of smears, cultures, and antibiotic sensitivity testing in the management of suspected infectious keratitis. *Ophthalmology*, 103, 23-8.
- Miedziak, A.I., Miller, M.R., Rapuano, C.J., *et al.* (1999). Risk factors in microbial keratitis leading to penetrating keratoplasty, *Ophthalmology*, 106, 1166-1171.
- Morgan, P.B, Efron, N, Brennan, NA, Hill, EA, Raynor, MK, Tullo, AB. (2005a) Risk Factors for the Development of Corneal Infiltrative Events Associated With Contact Lens Wear." *Invest Ophthalmol Vis. Sci.* 46, 3136-3143.
- Morgan, PB, Efron, N, Hill, EA, Raynor, MK, Whiting, MA, Tullo, (2005b) AB. Incidence of keratitis of varying severity among contact lens wearers. *Br. J. Ophthalmol.*, 89, 430-436.
- Moriyama, A. S., Hofling, A.L (2008) Contact lens-associated microbial keratitis, *Lima Arquivos Brasileiros de Oftalmologia* 71(6) , Suppl, pp 32-36.
- Musch, DC, Sugar, A, Meyer, R.F. (1983) Demographic and predisposing factors in corneal ulceration. *Arch Ophthalmol*, 101, 1545-1548.
- Peterson, D. L. (1999), Vancomycin-resistant Staphylococcus aureus. *Infect. Med.* 16, 235-238
- Poggio, E.C., Glynn, R.J, & Schein, O.D. (1989), The Incidence of Ulcerative Keratitis Among Users of Daily-Wear and Extended-Wear Soft Contact Lenses, *N. Engl. J. Med.*, 321, 779-783.
- Reim., M, Kottek., A, & Schrage, N. (1997), The cornea surface and wound healing, *Prog. Retinal Eye Res*, 16, 183-225.
- Schaefer, F., Bruttin, O., & Zografos, L., *et al.* (2001) Bacterial keratitis: a prospective clinical and microbiological study. *Br. J. Ophthalmol.*, 85, 842-847.
- Shen, L. L. (1994), Molecular mechanisms of DNA gyrase inhibition by quinolone antibacterials. *Adv. Pharmacol.* 29A, 285-304.
- Stern, M.E., Beuerman, R.W., Fox, R.I., Gao, J., Mircheff, A.K., Plugfelder, S.C. (1998), The pathology of dry eye: the interaction between the ocular surface and lacrimal glands. *Cornea*, 17, 584-589.
- Tang, A., Marquart, M.E., Fratkin, J.D., McCormick, C.C, Caballero, A.R, Gatlin, H.P, O'Callaghan, R.J. (2009). "Properties of PASP: a Pseudomonas protease capable of mediating corneal erosions". *Invest Ophthalmol Vis. Sci.* 50 (8): 3794-801.
- Tsubota, K., Yamada, M. (1992) Tear evaporation from the ocular surface, *Invest. Ophthalmol Vis. Sci.*, 33, 2942-2950.
- Tsubota, K., Hata, S., Okusawa, Y., Egami, F., Oh- tsuki, T., Nakamori K. (1996) Quantitative video- graphic analysis of blinking in normal subjects and patients with dry eye, *Arch Ophthalmol*, 114, 715-720.
- Weissman, B.A, Mondino, B.J. (2002), Risk factors for contact lens associated microbial keratitis, *Contact lens anterior eye the journal of the British Contact Lens Association*, 25(1), pp 3-9.

Zhonghua, Yan. Ke. Za. Zhi. (1992), Keratitis associated with contact lens wear. *Chinese Journal of Ophthalmology*, 28(4), pp 234-235. (24)

IntechOpen

IntechOpen



## **Keratitis**

Edited by Dr. Muthiah Srinivasan

ISBN 978-953-51-0568-8

Hard cover, 62 pages

**Publisher** InTech

**Published online** 25, April, 2012

**Published in print edition** April, 2012

The 4 chapters in this book focus on investigation, basic and advanced clinical aspects and management of frequently encountered corneal disorders. The authors have covered keratitis theory and practice. Onchocerciasis, even though found on one continent, has its impact on population, epidemiologists, ophthalmologists, NGOs, public health planners and care providers. The goal of this book is to provide information on ancient eye diseases; their investigation and management to prevent corneal blindness. I acknowledge the great help rendered by Publishing Process Manager and Editor Relations Consultant.

### **How to reference**

In order to correctly reference this scholarly work, feel free to copy and paste the following:

Hadassah Janumala, Praveen Kumar Sehgal and Asit Baran Mandal (2012). Bacterial Keratitis - Causes, Symptoms and Treatment, Keratitis, Dr. Muthiah Srinivasan (Ed.), ISBN: 978-953-51-0568-8, InTech, Available from: <http://www.intechopen.com/books/keratitis/bacterial-keratitis-causes-symptoms-and-treatment>

**INTech**  
open science | open minds

### **InTech Europe**

University Campus STeP Ri  
Slavka Krautzeka 83/A  
51000 Rijeka, Croatia  
Phone: +385 (51) 770 447  
Fax: +385 (51) 686 166  
[www.intechopen.com](http://www.intechopen.com)

### **InTech China**

Unit 405, Office Block, Hotel Equatorial Shanghai  
No.65, Yan An Road (West), Shanghai, 200040, China  
中国上海市延安西路65号上海国际贵都大饭店办公楼405单元  
Phone: +86-21-62489820  
Fax: +86-21-62489821



© 2012 The Author(s). Licensee IntechOpen. This is an open access article distributed under the terms of the [Creative Commons Attribution 3.0 License](https://creativecommons.org/licenses/by/3.0/), which permits unrestricted use, distribution, and reproduction in any medium, provided the original work is properly cited.

IntechOpen

IntechOpen