

We are IntechOpen, the world's leading publisher of Open Access books Built by scientists, for scientists

6,900

Open access books available

185,000

International authors and editors

200M

Downloads

Our authors are among the

154

Countries delivered to

TOP 1%

most cited scientists

12.2%

Contributors from top 500 universities



WEB OF SCIENCE™

Selection of our books indexed in the Book Citation Index
in Web of Science™ Core Collection (BKCI)

Interested in publishing with us?
Contact book.department@intechopen.com

Numbers displayed above are based on latest data collected.
For more information visit www.intechopen.com



Hepatic Encephalopathy

Jeffrey E. Juneau and Brendan M. McGuire
*University of Alabama at Birmingham, Department of Medicine,
 Division of Gastroenterology and Hepatology
 Birmingham, AL
 USA*

1. Introduction

Hepatic encephalopathy (HE) is a neuropsychiatric condition affecting patients with cirrhosis, acute liver failure and portal-systemic bypass^{1, 2, 3}. The neuropsychiatric abnormalities include changes in levels of consciousness, behavior, intellect, and neurologic exam. The changes in levels of consciousness can range from altered sleep habits to coma. HE is a frequent complication in patients with cirrhosis and is broadly classified as minimal HE and overt HE. Minimal HE is defined as subclinical cognitive dysfunction, only detected by neuropsychiatric testing, and is present in up to 80% of patients with cirrhosis⁴. Overt HE is defined in patients with active HE or a previous episode of HE and is present in 30-45% of patients with cirrhosis⁵.

HE results from the overproduction or impaired metabolism of one or more neurotoxin. The general consensus is that ammonia with inflammation in the serum is believed to be the underlying trigger to developing HE. Normally, ammonia enters the portal system from the gut. When the liver is unable to clear ammonia, secondary to a limited number of viable hepatocytes or portal-systemic shunting, ammonia can enter the systemic circulation and enter brain tissue. Elevated ammonia with inflammation can impair normal neurotransmission and result in a variety of neuropsychiatric abnormalities⁶. The inflammatory component is usually related to bleeding, dehydration or sepsis⁴.

1.1 Classification

The most common classification used for research purposes is the West Haven Criteria (also called Conn Score) (table I-1)⁸. The West Haven Criteria is graded with a range of 0-4. The far ends of the spectrum, grades 0 and 4, have fairly obvious clinical manifestations with no abnormalities and comatose, respectively ^{8, 9}. However, the major criticism of the West Haven Criteria is deciphering the middle categories, 1-3, which can be difficult to reproduce due to the subjectivity involved with the assessment.

The World Congress of Gastroenterology developed a classification system for HE in 1998 based on underlying hepatic abnormalities. The three types are **A**, **B**, and **C** and are associated with Acute liver failure, portal systemic Bypass without intrinsic liver disease, and Cirrhosis, respectively ^{2, 3, 10}. Type C can be subcategorized into persistent, episodic, and

minimal HE depending on symptoms and presentation. Persistent HE is subdivided into mild, severe, and treatment-dependent. Persistent HE presents with cognitive defects that negatively affect social and occupational functioning. The differences between mild and severe persistent HE depend on the West Haven Criteria. Mild persistent HE is present when a patient has met the persistent HE definition as well as having West Haven grade one, whereas severe persistent HE is present with grade two, three, or four of the West Haven Criteria. Treatment-dependent persistent HE implies that overt symptoms develop when treatment stops¹⁰. Episodic HE is subdivided into recurrent, precipitated, and spontaneous. Episodic is essentially viewed as delirium secondary to a general medical condition, with delirium defined as a disturbance of consciousness that is accompanied by a change in cognition that cannot be accounted for by a pre-existing or evolving dementia. Recurrent episodic HE is defined as having had two or more episodes in one year. Precipitated episodic HE is caused by an identifiable precipitant which led to the HE episode. These precipitants are listed in Table P-1. Spontaneous episodic HE is diagnosed only if no precipitant can be identified and all other causes of mental status alteration have been ruled out. Minimal HE is diagnosed by specialized tests due to the subtlety of its presentation. The most commonly used clinical categorization of HE is minimal and overt HE. Overt HE includes both persistent and episodic HE. But neither the World Congress of Gastroenterology nor the minimal and overt HE Classification systems are scientific or precise enough to offer a clear idea of the patient’s clinical condition.

Due to the inconsistencies between HE severity scores, Bajaj and Cordoba created the Spectrum of Neurocognitive Impairment in Cirrhosis (SONIC) to eliminate the phrasing of minimal, overt and normal, as well as the scoring system of West Haven Criteria⁷. In utilizing a spectrum, the physician can follow the patient’s mental status on a day-to-day basis with standardization in place to allow all providers to understand the clinical course of the patient. Although this spectrum was created to eliminate other severity classifications, the use of both West Haven Criteria and minimal/overt HE descriptions is widely practiced. Other scoring systems have been used in small studies such as the HE Scoring Algorithm (HESA)¹¹ and clinical hepatic encephalopathy staging scale (CHESS)¹⁶² but they have not been tested in large, multicenter trials ⁷.

Stage	Consciousness	Intellect/behavior	Neurological findings
0	Normal	Normal	Normal exam
1	Mild lack of awareness	Shortened attention span, impaired addition/subtraction	Mild asterixis or tremor
2	Lethargic	Disoriented; inappropriate behavior	Obvious asterixis; slurred speech
3	Somnolent	Gross disorientation; bizarre behavior	Muscular rigidity, clonus, hyperreflexia
4	Coma	Coma	Decerebrate posturing

Used with permission from *Alimentary Pharmacology and Therapies* “Modern management of Hepatic Encephalopathy” 2010.

Table I-1. West Haven Criteria for Hepatic Encephalopathy

2. Pathophysiology

Due to the various etiologies of the liver dysfunction, the etiology of HE is not completely understood. Nevertheless, several mechanisms are known to be associated with the development of HE and elevated serum ammonia seems to be the spark along with other precipitating factors. Precipitating factors can be found in 80% of cases with overt HE¹². These precipitants work by increasing the underlying inflammatory milieu, or altering the ammonia threshold, or a combination of the above. The precipitants are listed in the table below (Table P-1).

Increased Nitrogen load	Decreased toxin clearance		Altered neurotransmission	Hepatocellular damage
Excess dietary protein	Dehydration	Abdominal paracentesis	Benzodiazepines	Continued alcohol abuse
Constipation		Fluid restriction	Psychoactive drugs	Development of hepatocellular carcinoma
GI bleed		Diuresis		
Blood transfusion		Diarrhea secondary to laxatives		
Azotemia	Hypotension	Bleeding		
		Vasodilation		
Infection	Anemia			
Hypokalemia	Portal-systemic shunts			

Table P-1 Common precipitants of hepatic encephalopathy and the underlying mechanisms

2.1 Ammonia

The pathophysiology is based largely on the five organs involved in the ammonia metabolism – gut, muscles, kidneys, liver, and brain¹³. The gut, kidneys and muscles are involved in the production of ammonia into the blood system. In the gut, ammonia is mainly produced by urease producing gut flora, which cleaves protein enzymatically to ammonia (NH₃), and then absorbed into the portal-system through the colon¹⁴. In addition, enterocytes contain glutaminase, which converts glutamine to glutamate and ammonia¹⁵. The kidneys also express glutaminase and are involved in ammonia production during acid-base balance and dehydration¹⁶. With intense exercise or seizure, ammonia is produced in the skeletal muscles¹⁴.

Normally, ammonia is metabolized to urea in the liver for renal clearance. Eighty to ninety percent of ammonia enters the urea cycle via the liver and is ultimately cleared via the kidneys. Ammonia clearance also occurs within the kidneys, skeletal muscles, and brain. Ten to twenty percent of ammonia is metabolized by the skeletal muscles and brain via glutamine synthetase. Glutamine synthetase is the enzyme responsible for the condensation of glutamate and ammonia to form glutamine. In patients with cirrhosis, muscle wasting is

common, thus limiting the ability of skeletal muscles to clear ammonia. The kidney expresses glutamine synthetase and is capable of increasing ammonia metabolism and excretion¹⁷. The shunting of blood (physiologic or iatrogenic) away from the liver decreases the ammonia metabolism in the liver, and increases systemic circulatory ammonia levels^{16, 17}.

In the brain, astrocytes are the only brain cells that can metabolize ammonia into glutamine via glutamine synthetase¹⁸. Astrocytes have several functions including neurodevelopment, maintaining appropriate ion concentrations in extracellular space, and maintaining the blood brain barrier and synaptic transmission. They also have the power to regenerate, which allows them to aid in repairing neuronal tissue¹⁹. When ammonia levels are elevated in the brain, glutamine levels are elevated which leads to an influx of water and subsequent edema. With chronic exposure to ammonia as well as manganese, astrocytes can undergo a morphologic change to Alzheimer type 2 astrocytosis characterized by cell swelling, large nuclei, prominent nucleoli, margined chromatin, and the inability of cells to function^{20, 21, 22}. The swelling of the astrocytes can cause cerebral edema and intracranial hypertension, which leads to global effects on the brain including agitation to seizures^{14, 23-25}. This cerebral edema has been demonstrated on MRI by reduced magnetization transfer ratios in patients with overt HE²⁶. The dysfunction of the astrocytes can lead to permanent damage of the brain. The permanent neurologic damage was seen in patients who received a liver transplant after recurrent episodes of overt HE. The changes included decreased brain volume seen on MRI, loss of the N-acetylaspartate/Creatine-phosphocreatine neuronal marker, and gross motor dysfunction²⁷. When acute elevation of arterial ammonia to levels greater than 200 $\mu\text{mol/L}$ occurs, cerebral autoregulation is lost and cerebral edema and intracranial hypertension may result in herniation^{24, 25}.

2.2 Inflammation

High levels of ammonia do not cause the symptoms of HE alone; a spark has to be present – inflammation. Inflammatory markers are elevated in patients with HE and they can affect the liver and neurologic functions. Inflammatory markers were present in a number of studies, and they are relevant in the presence of all types of HE. Inflammatory markers including C-reactive protein, white blood cell levels, and interleukin-6 are higher in patients with minimal HE than those without minimal HE²⁸. In overt HE, cytokines are released by the astrocytes in response to ammonia-related injury. Tissue necrosis factor (TNF), which arises during inflammation, stimulates more cytokine production as well as altering the blood brain barrier (BBB). The permeability of the BBB to ammonia increases with increasing severity of liver disease²⁹. Over-active neutrophils have been associated with HE and exhibit excessive degranulation and release of reactive oxygen species (ROS). The cytokines increase permeability of ammonia to the BBB. Ammonia swells the astrocytes with osmotic stress, and oxidative and nitrosative stress may cause apoptosis³⁰. Thus, ammonia and the inflammation alter the environment of the astrocytes and BBB in a synergistic fashion to create a spectrum of neurologic changes³¹.

2.3 Amino acids

An elevation in aromatic amino acids to branched chain amino acids (BCAA) ratio is present in a large portion of patients with cirrhosis and HE. Aromatic amino acids (AAA) are elevated relative to baseline in patients with HE. BCAA are utilized more in the presence of

hyperammonemia to help in detoxification of ammonia by skeletal muscles. Chronic liver disease and portal-systemic shunts are characterized by reduced levels of BCAA³². Aromatic amino acids are associated with an altered BBB, due to the transportation of glutamine out of the astrocytes which brings AAA into the cells. The imbalance may inhibit normal neurotransmitters such as dopamine, serotonin, and norepinephrine^{33, 34} or hinder their synthesis³⁵. This change in concentration has led to treatment options involving BCAA. However, clinical trials of specialized BCAA formulas have yielded mixed results³⁶.

2.4 Neurologic alterations

Because of the uncertainty surrounding all of the events in HE, a great deal of substances have been observed to be elevated or reduced with HE episodes. GABA, translocator protein 18-kDa (TSPO) receptors, endogenous benzodiazepine, glutamate receptors, serotonin, catecholamines, melatonin, and histamine, which all have a role in cognitive function, have been altered during HE.

The GABA-benzodiazepine neurotransmitter system has been implicated in HE pathogenesis on a number of levels. The GABA receptors were once thought to be a major factor in the development of HE; however the receptors have not been shown to be more numerous or active in patients with HE. In the clinical setting, patients with liver failure are more sensitive to the sedative effects of benzodiazepines than those without liver failure. In rat models, ROS and reactive nitrogen species (RNS) are enhanced in the presence of benzodiazepines^{30, 37}. Antagonists to GABA-benzodiazepine receptor complex administered to rats with mild to severe hepatic encephalopathy produced a transient improvement in clinical status³⁸. Neurosteroids, which are metabolites synthesized by cholesterol or steroid precursors, have also been associated with the GABA-A receptors. Neurosteroids are positive allosteric modulators of GABA-A receptor, thus increasing the GABAergic tone. The increased GABAergic tone has been associated with the reduced oxygen requirements and subsequent reduced blood flow and metabolism in the brain³⁹. Endogenous benzodiazepines, which have also been involved with the activation GABA-Aergic neurotransmission, have been identified with contributing to HE. The concentrations of these endogenous benzodiazepines have been directly correlated with the severity of HE in animal models, but the role in humans has not been completely elucidated⁴⁰.

In patients with HE, translocator protein 18-kDa (TSPO) (formerly known as peripheral-type benzodiazepine receptor (PTBR)) is upregulated in microglial cells that are activated by inflammation⁴¹. This receptor is responsible for increasing the neurosteroid concentrations that stimulates the GABAergic tone as described above. The TSPO is activated by increases in ammonia and manganese^{40, 42}. Ammonia's presence as an activator of TSPO seems appropriate. Manganese has a role as well. Serum manganese levels are not elevated in HE, but deposits in the basal ganglia have been seen on MRI. Manganese toxicity has similar clinical manifestations as HE, with the addition of Parkinsonian symptoms, which may or may not be present in HE^{21, 22}.

Glutamate receptors have been implicated mainly through the effects of the glutamate, ROS and RNS. As part of the "Trojan Horse Hypothesis," ammonia is thought to induce oxidation when produced from glutamine within the mitochondria of astrocytes. The RNA oxidation induces N-methyl D-aspartic acid (NMDA) activation⁴³. NMDA receptors are

used in the brain function as a means to compartmentalize glutamine and glutamate. Under normal conditions, astrocytes support adjacent neurons with ATP, glutamine, and cholesterol. The neuron metabolizes glutamine to glutamate, and the NMDA receptors take in the glutamate to be recycled back to glutamine. With excess ammonia being metabolized to glutamine, the compartmentalization of glutamine and glutamate is altered. Glutamate is now in excess, and has been found in the hippocampus and cerebral cortex in patients with acute liver failure. Glutamate is an excitatory neurotransmitter, which could lead to agitation and possible seizure. In patients chronically exposed to ammonia, these receptors are down-regulated, which results in less neuroexcitation from glutamate^{14, 23-25, 44}. Meanwhile, glutamine's concentration increases within the astrocytes and ultimately leads to further release of ROS and RNS and swelling.

Neurochemical alterations have consistently been present in various models of HE. In a study by Yurdaydin, the extent of the neurochemical involvement was dependent on the severity of the HE. Nevertheless, the study proposed an increase in serotonic and noradrenergic neurotransmission in patients with HE⁴⁰.

Serotonin is a neurotransmitter involved in the CNS, and it is also a hormone which interacts with various other organ systems. Serotonin metabolites are increased in patients with HE. In addition, the number of serotonin receptors is altered and catabolizing enzymes are elevated⁴⁰. However, the amount of biologically active serotonin has not been found to be elevated. In some studies, it has been reduced in the synaptic clefts⁴⁵. Despite the alterations in the serotonin cycle, the role of serotonin in HE is not clear.

Catecholamines, particularly altered concentrations of norepinephrine (NE), have been implicated in contributing to HE. Catecholamine concentrations are closely linked to the AAA:BCAA ratio, thus suggesting a role in amino acid production. BCAA are thought to either competitively inhibit catecholamines or hinder their synthesis. NE is typically reduced in the brain of rats in acute or chronic liver failure. This reduction in NE would result in general slowing of cognitive processes most notably seen in minimal HE or overt HE types B and C. The possible cause of reduced levels of NE may also be directly related to hyperammonemia. Elevated levels of ammonia could potentially cause an increase in the noradrenergic transmission⁴⁶.

Melatonin and histamine are both involved in the circadian rhythm, which dictates the sleep-wake cycle. Histamine levels are elevated in the frontal cortex and central histamine concentrations have been linked to the control of arousal in the circadian rhythm⁴⁷. Melatonin levels are altered in patients with liver disease. These changes yield the symptoms of altered sleep patterns and insomnia usually reported early in the disease state⁴⁸.

2.5 Precipitating factors

HE is precipitated by an event that impacts the patient's functioning in the vast majority of cases. This event may be an increase in nitrogen, decreased ability to clear toxins, altered neurotransmission, or further hepatocellular damage⁴⁹. The most common precipitating factors are sepsis, dehydration (secondary to treatment), and variceal bleeding¹². Treating the precipitating factor is a pillar in treatment of HE. In the event that a precipitating factor cannot be identified, the diagnosis of spontaneous HE should be considered. A table of precipitating factors is listed in P-1.

A large nitrogen load can precipitate an episode of HE. Excess dietary protein, constipation, and hypokalemia are all intake/output related, and can be treated with relative ease. Hypokalemia's effects stem from altering the BBB, and allowing more ammonia to cross. GI bleeding can also precipitate an episode of HE. GI bleeding leads to an excess of ammonia in the blood by digesting and absorbing proteins from the breakdown of red blood cells in the intestines. In addition, GI bleeding leads to the production of ammonia from the kidney resulting in hyperammonemia as well as potential hypovolemia^{17, 50}. Blood transfusions can be a less obvious cause, but must be considered as a potential precipitating event in HE, especially after an acute GI bleed.

Infection is a common contributor to HE. Infection or sepsis is usually apparent with a combination of increased temperature, white blood cell count, heart rate and respiratory rate. Cirrhotics are also viewed as functionally immunocompromised, therefore, their risk of infection is increased³¹. Because infection is such a common cause of HE, it is standard of care to evaluate all patients with HE with an infection workup including blood and urine cultures, chest x-ray, skin exam and diagnostic paracentesis⁴.

Decreased toxin clearance is generally associated with hypovolemia (dehydration, hypotension, or anemia) and portal-systemic shunting (either iatrogenic or spontaneous). Shunting of blood away from the liver bypasses hepatic cells and minimizes the clearance of toxins⁵¹. Dehydration and anemia, which are usually associated with hypotension, can lead to ineffective clearance of toxins by the kidneys. On occasion, hypotension can be due to systemic vasodilation which has the same result of ineffective toxin clearance. The lack of clearance in all of these processes leads to increased levels of toxins, most notably ammonia.

As noted in the astrocyte physiology, neurotransmission is vital to neurologic functioning. Altered neurotransmission is known to be a precipitating factor in HE. Patients placed on benzodiazepines or any psychoactive drug may react drastically for separate, yet related reasons. Endogenous benzodiazepines are elevated during HE, and increasing the concentration of these would severely affect the patient⁴⁰. With the hepatocytes damaged from the liver disease, blood shunted away from the liver, and various transporter proteins downregulated as a result of the liver disease, drugs affecting the cognitive function of a patient will have a more pronounced effect including stimulants (caffeine, amphetamines, methylphenidate) and depressants (sedatives, narcotics)⁵².

Although hepatocellular damage is already present, in certain situations it can be worsened. Continued abuse of alcohol may cause worsening hepatic function, which can lead to a spontaneous shunt and a buildup of toxins in the blood and brain. Also, the development of hepatocellular carcinoma in the setting of cirrhosis may worsen the patient's status⁵³.

3. Diagnosis

The diagnosis of overt HE is generally made by the presence of clinical signs and symptoms, elevated ammonia levels, and the absence of other possible causes of altered mental status. The signs and symptoms seen early are alterations in sleeping patterns, which can progress to somnolence and on to obtundation⁴⁸. Some patients may become more agitated usually occurring in Type A HE⁵⁴⁻⁵⁶. Types B and C HE presentations are more associated with neuroinhibitory symptoms⁵⁷⁻⁵⁹. Nevertheless, the approach to anyone suspected of having

HE is to exclude other possible causes of encephalopathy, identify precipitating factor, and empiric treatment for HE.

Clinical features of overt HE include those associated with consciousness, intellect and behavior, and gross neurological findings. In regards to consciousness, the patient can range from no impairment or mild lack of awareness to lethargy, somnolence or coma. Intellect and behavior changes include shortened attention span, disorientation, and inappropriate or bizarre behavior⁶⁰. Neurological findings on exam include impaired psychomotor testing, varying extent of asterixis, slurred speech, rigidity and hyperreflexia, and transient posturing⁶¹. These signs and symptoms are all recognized by the West Haven Criteria and are graded by the severity of HE (Table I-1).

A detailed physical exam must be performed mainly to rule out other causes of altered mental status and to help elucidate possible precipitating factors. The general appearance of jaundice signifies underlying liver dysfunction, and often clues the physician as to the etiology of the altered mental status. Other evidence of liver failure, such as ascites, palmar erythema, edema, spider telangiectasias, muscle wasting and fetor hepaticus, may also be present in patients with overt HE⁶². Monitoring the patient's vital signs may also help with determining the precipitating factor(s) that induced the overt HE. A digital rectal exam should also be performed to assess for constipation and fecal occult blood as precipitating factors for the HE.

The neurologic exam is critical to assess the patient's altered mental status as disorientation and that other etiologies of the encephalopathy can be excluded. The alertness and orientation are aspects of the neurologic exam that usually separates the various grades of HE using the West Haven Criteria, and it is a critical symptom that may determine the need for hospitalization (grades 3 and 4). Mental status evaluations should be assessed to exclude other causes such as Alzheimers and neurovascular disease as well as to grade the encephalopathy according to the West Haven Criteria⁶³. A detailed neurologic exam must be performed to rule out a neurologic cause contributing to the change in mental status⁶⁴. Overt HE typically causes a global process, and any focal findings in the neurologic exam must be further pursued. Focal findings such as hemiplegia is an extremely rare presentation for overt HE. Focal neurologic signs are not prognostic and are usually reversible when associated with HE⁶⁵. Asterixis is a common physical sign associated with overt HE. The presence and severity of asterixis can help grade the HE when using the West Haven Criteria. The assessment of asterixis requires an outstretched arm with extension of the wrist and is positive if a flapping tremor is present⁶⁶. Alternatively, asterixis can be evaluated having the patient grip the evaluator's fingers in steady fashion and is present if the patient's grip tension oscillates. Parkinsonian-like symptoms may be present in the form of rigidity and tremors⁴.

Lab values play a vital role in the diagnosis of HE with the close monitoring of the ammonia levels. The ammonia level is typically elevated to quantities well above the upper normal limits during an episode of HE. The numerical value of the ammonia levels generally correlates to the extent of mental status change. However, there is a delay in the resolution of symptoms after ammonia levels return to normal, and routine ammonia measurements after diagnosis is not recommended^{63, 67}. In the event that ammonia is elevated and no underlying liver disease was present, labs should be collected to rule out inborn errors in

metabolism (IEM) of urea. The IEM that present in adulthood include ornithine transcarbamylase, carbamyl synthetase, and arginosuccinate lyase deficiencies with each having measurable enzyme lab values¹³.

Other labs should be checked to determine the precipitating factor, which may have induced the overt HE. Discovering this factor is vital to the treatment of HE and the ultimate resolution of symptoms. For this reason the serum electrolytes must be checked due to the precipitating factors of hypernatremia, hypokalemia, hyperglycemia, and hypoglycemia⁴⁹. The white and red blood cell counts should also be checked to evaluate for possibility of infection or GI bleed, respectively.

Obtaining pharmacologic levels of potentially toxic medications should be obtained in patients with liver disease receiving multiple drugs and having altered first pass liver metabolism. In addition, a urine drug screen may provide answers to patients with altered mental status.

Cultures should be drawn from the blood, urine, and ascitic fluid to evaluate for infection as precipitating factor of HE⁴. A chest x-ray may be necessary to rule out pneumonia. A lumbar puncture may be necessary to rule out meningitis. Cultures usually take 24 hours for preliminary results and therefore antibiotics should be started empirically if clinical suspicion is high for infection. Although infection may induce overt HE, sepsis may present with altered mental status with an ammonia level within the normal range⁶³. White blood cell count, respiratory rate, heart rate, and temperature should be closely monitored due to differing treatments between overt HE and sepsis.

Radiologic imaging has a minimal role in diagnosing HE. When an unknown patient presents with altered mental status or general somnolence, it is appropriate to rule out an acute intracranial process with a non-contrast CT of the head. Because many patients with liver disease also have coagulopathies and are subject to falls, the head CT is clearly warranted. Imaging must be used in these instances when ruling out an intracranial process that could either be the etiology of the change in mental status or exacerbating HE⁶⁸. However, in the event of diagnosing HE, radiologic images have not been shown to be necessary. Brain MRI's are increasingly being used to identify low-grade cerebral edema in HE, but this is often used for research purposes. As discussed in the sections above, several imaging modalities have identified abnormalities used in deciphering the pathophysiology of HE. For instance, magnetic transfer ratio was reduced in patients with HE, but reverses with liver transplantation. This finding suggests that the metabolic effects of HE maybe reversible⁶⁹. T1-weighted imaging showed manganese in the basal ganglia suggesting a role of manganese in the pathophysiology of HE⁷⁰⁻⁷². Proton spectroscopy (MRS) is mentioned as the evidence of glutamate involvement within the astrocytes during HE⁵⁹.

Although radiologic imaging has a minimal role in diagnosis and treatment, several modalities may be seen in the future for staging liver disease and the severity of HE. MRS changes directly correlate with severity of HE. This correlation could be used in the staging of liver disease as an illustrative way of monitoring the toll the disease is having on the brain. Although its variability and costs prevent it from being used routinely today, future management of chronic liver disease may include MRS⁷³. T1 mapping with partial inversion recovery (TAPIR) is another method that correlates changes with HE severity. This method maps the brain through a series of T1 MRI scans. Unlike MRS, TAPIR offers measurements in short, clinically relevant acquisition times⁷⁴.

Electroencephalography (EEG) is a tool used primarily in the research setting for diagnosis of HE. HE is associated with a decrease in mean frequency of electrical activity in the brain in the spectral EEG. Triphasic waves are noted in advanced HE⁷⁵. However, EEG readings have demonstrated subjectivity, and the test has a low sensitivity. Furthermore, the equipment is expensive and the test has not been validated^{76,77}.

3.1 Specialized tests

Specialized tests have been developed to quantify the degree of HE and also to monitor recovery or progression. Minimal HE is not diagnosed clinically, but it is diagnosed with neuropsychometric (NP) tests. These tests are useful tools in assessing progression of minimal HE as well as the initial diagnosis by identifying impairments in visuospatial functioning, attention, processing speed and response inhibition^{4, 78}. Minimal HE does not have a gold standard for diagnosis or assessment through neuropsychometric testing. Two tests, Psychometric HE Score (PHES) and Repeated Battery for the Assessment of Neuropsychological status (RBANS), are recognized by prominent organizations worldwide, although no single test has gained significant popularity or validation in the US⁶².

Psychometric HE Score (PHES) (also referred to as the PSE Syndrome Test) consists of a battery of five tests; Number connection tests (NCT)-A, NCT-B, line tracing test, serial dotting tests and digit symbol test. The diagnosis of minimal HE is made if any two of the NP tests are impaired beyond two standard deviations from normal⁶⁴. The whole test requires an educated instructor, paper, and pencil. The PHES typically requires 10-20 minutes to complete⁷⁵. The PHES was recognized by the World Congress of Gastroenterology in 1998 and is validated in Germany, Italy, and Spain. The Working Group of Hepatic Encephalopathy has recommended the PHES, but validation of this test has yet to be completed in the United States (US)⁷⁹⁻⁸¹.

The Repeated Battery for the Assessment of Neuropsychological status (RBANS) is a test similar to PHES with the addition of verbal, visual, and working memory domains. The test requires 20-25 minutes to complete, and is administered by paper and pencil. RBANS was created to gauge Alzheimer's Disease, schizophrenia, traumatic brain injury, and in some patients with cirrhosis awaiting liver transplantation. The International Society for the Study of HE and Nitrogen Metabolism (ISHEN) has recommended this test for diagnosis of minimal HE along with PHES. A modified version of RBANS is used in the US for overt HE, and has been proven to be effective in screening patients for minimal HE⁸²⁻⁸⁴. The RBANS recommended by ISHEN is currently being validated in the US in a multicenter trial^{85, 86}.

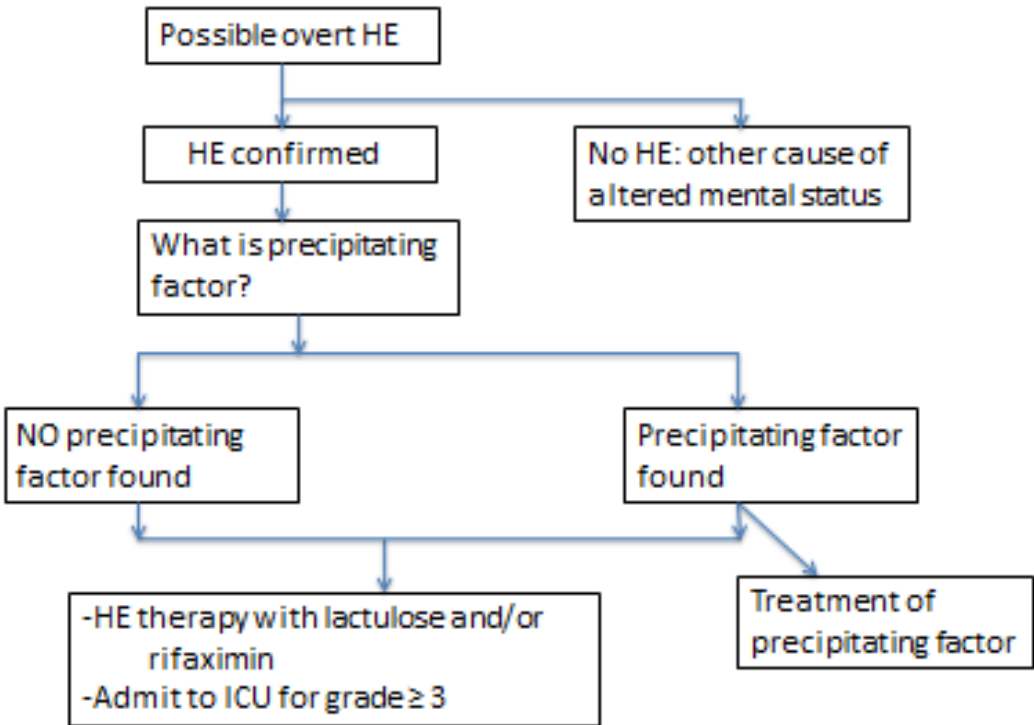
Performing the PHES or the RBANS require supervision by a neurologist, specialized equipment, trained personnel, and time. These tests rely on motor activity, which are often limited in patients with HE by the West Haven Criteria grades 2 to 4. Thus additional testing of HE has been used. The Critical Flicker Frequency (CFF) is a test of functional efficacy of the cortex, and it is a highly objective and sensitive measure of minimal HE. This test consists of a patient indicating the minimum frequency at which a flickering light is still perceived as flickering and not fused. In Spain and India, it has been effective in differentiating minimal HE or early stage HE from no HE^{87, 88}. It positively correlates with NP tests, and it is not influenced by gender, education level, occupation, and only slightly by age. It was validated for assessment of patients with HE in 2002 and for patients with HE who were undergoing TIPS placement in 2009^{66, 89}. For patients with reduced motor skill

function undergoing HE assessment, pressing a button instead of performing a detailed pencil and paper test is more appropriate. Reaction times are directly measured and should increase the accuracy of assessing HE⁸⁵.

Computerized psychometric tests are gaining popularity and could revolutionize the assessment of patients with HE⁷⁸. The inhibitory control test is the most popular in the US. Its focus is primarily on response inhibition and attention. It has shown close correlations with other NP tests, but investigations have been limited to only Wisconsin and Virginia, USA. The inhibitory control test offers promise in that training of the technician is minimal, and the cost of the test may be cheaper than the NP tests. Furthermore, the inhibitory control test can also predict overt HE, and it is associated with driver simulator performance and traffic accidents in the US^{87, 90, 91}. Cognitive Drug Research Ltd computerized assessment system was designed specifically for cirrhosis and minimal HE, and it focuses on power of attention, continuity of attention, quality of episodic memory, quality of continuous memory and speed of memory. This test is popular in the UK and has shown good correlation with PHES⁹².

4. Treatment

Treatment of overt HE is based on a multifaceted approach of reducing the ammonia levels, treating the precipitating factor, and evaluating the patient for liver transplantation. After the overt HE resolves, the focus of therapy shifts to preventing recurrent HE, improving daily functioning and quality of life, and continuing evaluation for liver transplantation. Therapies can be viewed as short-term treatments, long-term treatments, and sometimes they can be used in both circumstances.



Adapted from Bajaj

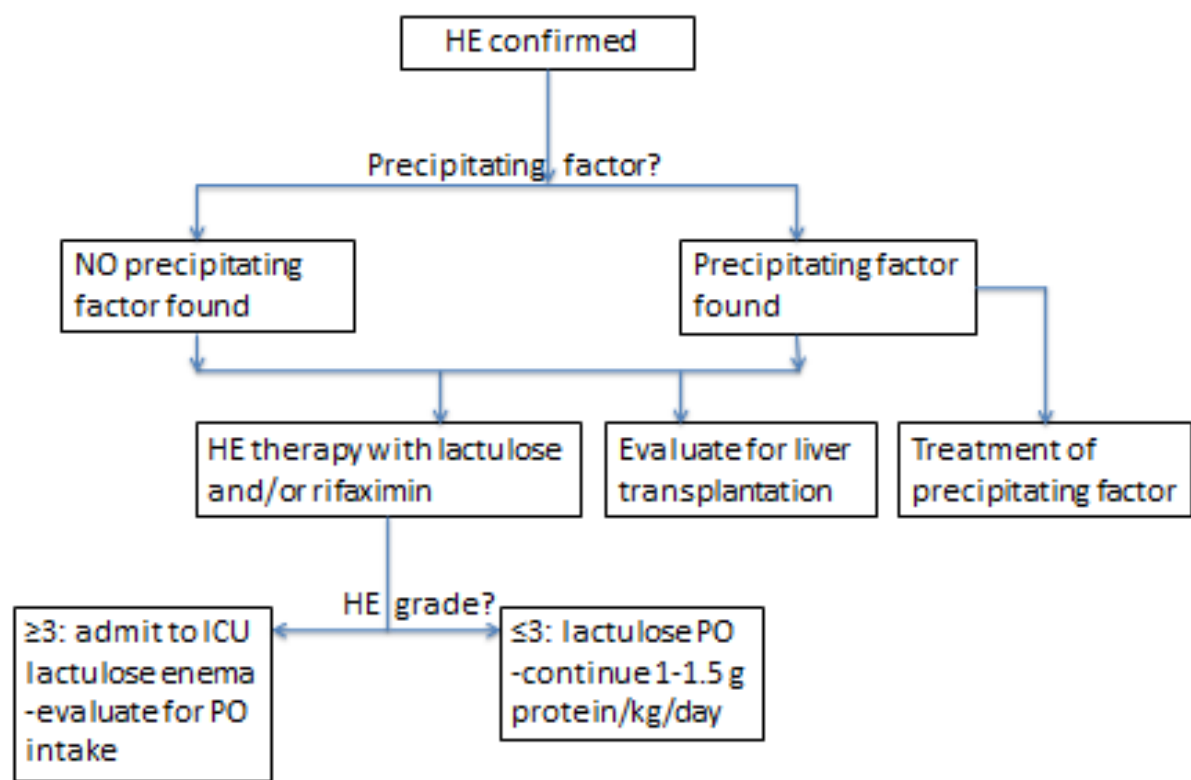


Diagram T-1. Treatment of Hepatic Encephalopathy

Patient safety is another important aspect of therapy. Patients with Type A HE are typically more agitated, and they pose greater risk to hurt themselves, family, and staff. For this reason and because of the possible effects of sedatives, judicious use of restraints is recommended. Haloperidol is a safer sedative than benzodiazepines most likely due to the endogenous benzodiazepines or increased benzodiazepine receptors produced in HE and liver disease. However, there is little evidence to support haloperidol’s use in sedation of patients with HE⁹³.

For patients with minimal HE, treatment is focused on family and patient discussions of potential complications that can develop as patients transition to overt HE and to discuss limitations in activities of daily living. In particular, several studies have shown the effect that minimal HE has on the patient’s driving performance. One study showed patients with cirrhosis and minimal HE were involved in 17% of crashes compared to cirrhosis without minimal HE 0%⁹¹. It should be noted that patients often overestimate their fitness to drive⁹⁴. Patients and their family members must be aware that limiting or revoking the patient’s drivers’ license may be necessary.

Once overt HE has been diagnosed, the clinician must search for precipitating factor(s). Once the precipitating factor(s) has been identified, treatment must be directed to resolve the offending agent. It is also important to identify the precipitating factor to prevent recurrence. While treating the precipitating factor will resolve the primary mechanism responsible for the overt HE, reducing the ammonia will help alleviate the cognitive dysfunction.

4.1 Ammonia treatments

Lactulose is a synthetic non-absorbable disaccharide which is used as a cathartic to help clear ammonia through bowel movements. Lactulose also lowers the pH in the colon by being catabolized to lactic and acetic acid, which reduces ammonia levels in two additional ways. A lower pH will facilitate the conversion of ammonia (NH_3) to ammonium (NH_4^+), which is poorly absorbed across the colon⁹⁵. A lower pH also makes the environment more unfit for urease-positive bacteria, which decreases production of ammonia⁹⁶⁻⁹⁸. Lactulose has been shown in numerous studies to be effective, and when used appropriately it is as effective as any new medications. Dosage and administration depends on grade of HE and goal of therapy. For overt HE (grades 1-2), recommendations is to start lactulose orally with 20 g/30 ml every 1-2 hours until patient has 2-4 soft bowel movements. The dosage should always be titrated so that the patient has 2-4 semisoft bowel movements each day^{2, 61}. If the HE grade is ≥ 3 , lactulose should be administered via enema due to risk of aspiration. The starting enema dosage is 200 gm/300 ml with 700 ml water or saline every 4 hours titrated. Although lactulose has been proven to be more effective than placebo in treating HE, the use of lactulose has not been proven to reduce mortality⁹⁹.

Lactulose can also be used in the long-term treatment of patients with chronic liver diseases to prevent recurrence of HE and in the treatment of minimal HE¹⁰⁰. With proper adherence, lactulose's effectiveness has been proven in multiple studies for long-term prevention of recurrent HE. Being inexpensive and effective makes lactulose a 1st line agent for both short- and long-term therapy^{61, 101}.

Diarrhea, abdominal pains, and fatigue are the most common side effects associated with lactulose. The side effects can be severe enough that patients discontinue using the medication. This discontinuation has been well chronicled in various trials¹⁰². The side effects of diarrhea can be severe enough that the overuse of lactulose itself could lead to hypovolemia or an electrolyte imbalance that induces a new episode of overt HE¹⁰³. In a lactulose adherence trial conducted, nearly half of the patients with recurrent HE were non-adherent or had ≥ 5 bowel movements which contributed to the development of overt HE¹⁰². Adherence has been reported as low as 31% in patients prescribed lactulose¹⁰⁴. Adherence is low due to a lesser quality of life secondary to the side effects of lactulose. Patients on lactulose should be closely monitored, as adherence is affected by presence of adverse events, lack of insight into disease, inability to self-titrate, consequences of non-adherence not fully explained, and absence of close follow-up¹⁰².

Lacitol has a similar mechanism to Lactulose, but it is unavailable in the US. It is frequently used in England with success similar to lactulose and better adherence. The better adherence is due to its superior palatability and less gastrointestinal side effects that are associated with lactulose¹⁰³. Lacitol was also found to have a faster clinical response than lactulose¹⁰⁴.

The US Food and Drug Administration (FDA) approved rifaximin in 2010 for the treatment of HE in liver disease. Over 90% of the patients in the registration trial were also receiving lactulose. While lactulose's effects are limited by the adverse side effects, rifaximin has minimal side effects. Rifaximin is an antibiotic taken orally with minimal systemic absorption¹⁰⁷. Its antibiotic properties are thus limited to the gastrointestinal tract, where antibiotic coverage includes gram-positive and gram-negative bacteria, although it has

minimal effects on gut normal flora¹⁰⁸. A review comparing rifaximin to lactulose concluded that rifaximin is equally effective and in some studies superior to nonabsorbable disaccharides and other antimicrobials in relieving the signs and symptoms observed in cirrhotic patients with mild-to-moderately severe HE¹⁰⁹. However, due to the lack of side effects associated with rifaximin, patient adherence and satisfaction are significantly greater in rifaximin^{110, 111, 112, 113}. When factoring in patient adherence to the comparison of lactulose and rifaximin, rifaximin is superior.

Patient's adherence to rifaximin make it a more practical option for long-term therapy than lactulose, however, the cost of rifaximin is substantially higher (approximately 40 dollars a day) than that of lactulose (approximately 40-100 dollars a month)¹¹⁴. Thus, rifaximin and lactulose compare beyond the medical and physical aspects, they also must be compared in the psychosocial realm. A single center retrospective chart review comparing rifaximin to lactulose found that patients on rifaximin therapy were less likely to be hospitalized for recurrent HE, HE severity was reduced, and hospital stay was shorter than patients on lactulose¹¹⁰. These results suggest that rifaximin may be more cost effective in the long run, due to less expense associated with hospitalizations. However, multi-center prospective studies are lacking to support this claim. Two cost effective analyses reviewing different strategies in HE management, found that initial therapy of lactulose monotherapy with cross over to rifaximin was the best treatment. In other words, if the patient was intolerant to lactulose or responded poorly, then rifaximin was administered^{107, 115}.

Rifaximin administration has been the subject of debate. In Italy, pulse therapies with rifaximin achieved therapeutic effect without developing resistance or clostridium difficile infection¹¹⁶. Currently in the US, continuous therapy of 550 mg bid for HE is most widely accepted. Although rifaximin's effects were suffice to warrant US FDA approval, studies must continue to investigate maximizing the drug's benefits.

Neomycin is another antibiotic that has been approved in the treatment of overt HE. Trials with neomycin have not yielded the same results as rifaximin or lactulose. In fact, in a randomized study, neomycin was shown to be no better than placebo in 39 patients with HE¹¹⁷. In addition, the potential side effects of ototoxicity and nephrotoxicity that can occur with systemic absorption has limited its use clinically for treating HE^{118, 103}.

Metronidazole has been used for the treatment of HE, but has not been approved by the US FDA. Small single center studies suggest it may have some benefit in treating HE¹¹⁹. However, the major long-term side effect of neurotoxicity, limits its routine use for the management of HE¹⁰³.

Ornithine-aspartate is a substrate that is used in the urea cycle to convert ammonia to urea and glutamine in both hepatic and muscular metabolism. It has been shown in several controlled trials to lower ammonia concentrations and provide improvements of mental status and cognitive function in patients with mild to moderate HE^{120 - 122}. In a double-blinded randomized placebo-controlled trial treating patients with acute liver failure, ornithine-aspartate did not lower serum ammonia levels or improved survival¹²³. Fifty percent of patients report side effects of mild gastrointestinal disturbance, but no major side effects have been reported^{121 - 123}. Most trials administered ornithine-aspartate 18-30 g IV daily for 1-2 weeks. Additional studies are required before this agent can be recommended in the treatment of HE.

Sodium benzoate/sodium phenylacetate has been shown to enhance tissue metabolism of ammonia. Benzoate interacts with glycine to form hippurate, which is renally excreted. Phenylacetate conjugates with glutamine to form phenylacetylglutamine, which is renally excreted as well. Both hippurate and phenylacetylglutamine contain nitrogen from ammonia. In a prospective, randomized, double-blind study on 74 patients with overt HE, an oral dose of 5 grams of sodium benzoate twice daily and lactulose were similar in symptomatic improvement as well as adverse effects¹²⁴. Adverse effects included unpleasant taste, nausea, and salt overload. A combination of sodium benzoate and sodium phenylacetate intravenously is US FDA approved for the treatment of hyperammonemia in urea cycle defects, however, it has not been rigorously studied for HE treatment^{125, 126}.

Acarbose is an inhibitor of α -glycosidase, which inhibits the conversion of carbohydrates into monosaccharides for diabetic patients. It also facilitates the reduction of proteolytic bacteria flora that produce ammonia. In a single center randomized control trial comparing acarbose at dosage of 150 to 300 mg/day versus placebo in diabetic patients noted serum ammonia levels were significantly reduced and symptomatic improvement of HE were seen¹²⁷. This drug is not routinely used for the management of HE due to the product information sheet stating acarbose is contraindicated in patients with cirrhosis.

Dietary protein restrictions were once thought to be necessary in the treatment of HE to help resolve hyperammonemia. After many studies were undertaken to examine this belief, it is now recommended that dietary protein should remain constant during an overt HE episode. The prevalence of malnutrition in cirrhotic patients is estimated to be 65-100%^{128, 129}. Muscle wasting is also common in patients with cirrhosis, thus severely limiting ammonia removal from skeletal muscles. Protein intake, therefore, should remain constant during any episode of HE. The suggested protein requirement of 1-1.5 gram/kg per day for patients with liver cirrhosis should be continued during an episode of HE¹³⁰.

Probiotics are thought to work by introducing bacteria that do not produce urease. Probiotics have been associated with reduced serum ammonia concentrations¹¹⁶. Single center studies have demonstrated that probiotics improved cognitive function in patients with minimal HE¹³¹. A meta-analysis of prebiotics, probiotics, and synbiotics in minimal HE showed clinical improvement of minimal HE, but not as great as lactulose¹³². Probiotics and symbiotics were associated with fewer side effects compared to lactulose. While treatment options for HE with prebiotics, probiotics, and symbiotics are still being investigated, many clinicians are reluctant to introduce live bacteria to functionally immunosuppressed patients.

4.2 Neurotransmission

BCAA are decreased and AAA are increased in patients with cirrhosis and HE. As mentioned in the pathophysiology section, this imbalance inhibits production of catecholamines. Restoring balance would seem like a logical treatment, but trials have shown inconsistent results. Perhaps the greatest benefit of BCAA therapy is in the ability to increase protein intake without compromising cerebral function¹³³. It has been associated with increased serum albumin levels as well as improved cellular metabolism in cirrhotic patients¹³⁴.

Timing of BCAA therapy may be a crucial factor in its efficacy. In a small study of 12 patients with cirrhosis, nocturnal administration was associated with increased serum albumin levels at three months while daytime administration was not. It is speculated that these amino acids are used as calories during the day and protein synthesis when infused at night¹³⁵.

Two meta-analyses have produced conflicting results. A meta-analysis of 5 clinical trials suggested that long-term supplementation of oral BCAA was associated with significant improvement in mental recovery from HE and improvement from chronic HE¹³⁶. However, a recent meta-analysis of 11 trials found no convincing evidence that BCAA supplementation is beneficial¹³⁷. Thus, if protein replacement is clinically indicated, BCAA supplementation may help with the patient recovery through the increase in protein synthesis.

Flumazenil is the short-acting benzodiazepine receptor antagonist, and has been studied for treating patients with HE. Most studies have reported limited success with flumazenil in short-term improvement in mental status. In a systematic review, flumazenil was associated with a significant symptomatic improvement in patients with HE when compared to placebo¹³⁸. However, clinical improvements are short-term since flumazenil is given intravenously and has a half-life of less than an hour¹³⁸. In addition, caution is advised in patients with hepatic impairment and side effects are significant (seizure, nausea and agitation) limiting its use clinically⁴⁹.

Because the pathogenesis of HE may involve dopaminergic neurotransmission, bromocriptine has been studied as a possible treatment option. Bromocriptine stimulates dopamine receptors and is approved for Parkinson's disease treatment. In a small randomized study, bromocriptine was no more effective than placebo in resolution of HE. However, when bromocriptine was added to more conventional therapies, improvement of extrapyramidal symptoms was reported¹³⁹. Bromocriptine at 30 mg orally twice daily can be considered in patients who are refractory to other therapies with extrapyramidal symptoms⁶⁴.

Zinc deficiency is common among patients with cirrhosis and HE. Zinc is a cofactor of urea cycle enzymes¹⁴⁰. Zinc supplementation is thought to decrease serum ammonia and GABA and norepinephrine in the brain, but studies have shown conflicting results. In a blinded study of short-term zinc supplementation in patients with HE, no clinically significant benefit was associated with the zinc supplementation¹⁴¹. However, in a study evaluating supplementation for 3 months resulted in an improvement of HE¹⁴². Zinc toxicity is a concern as well as the adverse effects including nausea, vomiting, loss of appetite, abdominal cramps, diarrhea, and headaches⁴⁹.

4.3 Surgery

Shunting of blood away from the liver through a portal-systemic shunt predisposes the patient to recurrent and persistent HE in patients with cirrhosis, surgical shunts, or TIPS placements. Shunting blood away from the liver, limits metabolism of ammonia by the liver. A majority of cirrhotic patients with HE is secondary to portal-systemic shunts and not hepatocellular dysfunction¹⁴³. Obliteration of large spontaneous portal-systemic anastomoses, surgical shunts, or TIPS can be a therapeutic option among persistent HE

patients⁴⁹. As with any surgical procedure in a patient with cirrhosis, the risk of bleeding and hepatic decompensation must be considered when weighing this treatment option.

The ultimate surgical treatment of HE and liver disease is liver transplantation. Liver transplant recipients rarely present with additional HE episodes. HE episodes before liver transplantation has been associated with increased morbidity and worse patient functioning after transplantation⁶⁹. For this reason, a patient experiencing his first overt HE should be referred to a liver transplant center¹. The model for end-stage liver disease (MELD) is the scoring system used to list patients with cirrhosis in the US. The clinical data for calculating the MELD score includes objective data (serum creatinine, serum total bilirubin, and international normalized ratio of prothrombin time), but does not include any subjective data, such as episodes of HE or ascites. It has been shown that overt HE worsens prognosis over and above the MELD score and results in poorer survival rate with higher grades of HE for patients admitted to a hospital¹⁴⁴. This further emphasizes the necessity of beginning the liver transplant workup following the first episode of overt HE.

4.4 Dialysis

Peritoneal dialysis, hemodialysis, continuous venovenous hemofiltration and continuous arteriovenous hemodiafiltration have the ability to remove ammonia directly¹⁴⁶⁻¹⁵¹. These therapies have proven to be effective in children and adults with urea cycle defects. They could serve as a bridge for adults with fulminant hepatic failure while they are awaiting liver transplantation.

4.5 Future/experimental therapies

Hypothermia is a popular treatment modality for patients who are comatose after a cardiac arrest. In patients with HE, the benefits of hypothermia are associated with the reduction of free radical production, astrocyte swelling, and inflammation¹⁵². This improves cerebral blood flow and autoregulation, which reduces potential of intracranial hypertension. It also slows the ammonia production in both the gut from urease-positive bacteria and in the kidney. Hypothermia has also been shown to slow protein catabolism and prevents the neutrophil dysfunction^{153, 154}. Based on all of these mechanisms for clinical improvement, hypothermia could be a valuable tool in liver failure and grade 3-4 HE, but large randomized trials are needed before routine clinical use³¹.

Indomethacin is a nonsteroidal anti-inflammatory drug (NSAID) used in rheumatic disease and other inflammatory processes. The role of indomethacin in HE is to reduce inflammation and reduce cerebral blood flow, thus decreasing intracranial hypertension^{24, 99, 155}. There is excitement surrounding TLR-2, TLR-4, and TLR-9 inhibitors which would down-regulate neutrophil activation and therefore inflammation³¹. The side effect of indomethacin and other NSAIDs causing renal failure in cirrhotic patients may limit its use.

Levocarnitine is a metabolite of lysine degradation and serves as a carrier for short-chain fatty acids across mitochondrial membrane. It has been shown to stimulate the urea cycle and a delayed onset of HE in hyperammonemic mice, which is thought to be protective against ammonia neurotoxicity¹⁵⁶. In the two studies conducted on patients with HE,

levocarnitine reduced ammonia levels and improved mental status in one, while it provided no significant benefit in the other^{157, 158}. Future studies are needed before clinical use.

The glutamatergic neurotransmitter system has been implicated in the pathogenesis of HE in several models. Memantine is an NMDA receptor antagonist, which is hypothesized to help reduce the overactivity of NMDA receptors. It is currently approved for the treatment of Alzheimer's Disease. In rats with hyperammonemia and neurologic symptoms, memantine administration improved HE grade and neurologic symptoms¹⁵⁹. The human studies investigating memantine are pending.

The Molecular Adsorbent Recirculating System (MARS) is an albumin dialysis system that allows the removal of protein-bound and water-soluble toxins. A US multicenter randomized clinical trial in 70 patients with cirrhosis and grade III and IV HE showed significant benefit of MARS versus standard therapy with regard to time to improvement of HE¹⁶⁰. However, there is no extracorporeal albumin dialysis approved by the US FDA for the treatment of HE.

Spherical Carbon Adsorbent (AST-120) when given orally acts as a sink for neurotoxins and hepatotoxins in the gut. AST-120 has been studied in rats with cirrhosis and have shown decreased arterial ammonia levels, normalization of brain water content and normalization of locomotor activity¹⁶¹. Clinical trials are being conducted in humans.

5. Summary

The development of HE is a severely debilitating event for patients. Overt HE is a socially isolating event for patients, preventing them from working, driving a car and performing activities of daily living. Elevated serum ammonia with inflammation in the serum has been implicated as the underlying trigger to developing HE. The diagnosis should be considered in any patient with underlying liver disease who present with mental status changes and asterixis. After a thorough workup to rule out any acute neurologic cause of the patient's condition, a major effort must be made to find the precipitating factor which induced the current overt HE. Knowing the precipitating factor will allow both aspects of the HE to be treated – the cause and the effect. Treatments should start by eliminating the precipitating factor, which will ultimately improve the patient's condition. Standard treatments are focused on the prevention of additional ammonia from entering the blood system. Lactulose is a cheap and effective medication that has been studied extensively and it has been proven to be as effective as any medication on the market. Rifaximin is another effective medication, with minimal side effects. However, these agents do not resolve HE completely, but only minimize the number of severe episodes and partially improve mental function in the persistent cases of overt HE. Other potential treatments have shown some clinical benefits in the treatment of HE and can be considered as third line agents (zinc and sodium benzoate).

Several therapies are currently being studied, and they offer hope to those who currently suffering from recurrent HE. As these therapies become available, the treatment and prevention of HE will become easier to both patients and physicians. Until then, liver transplantation offers resolution of liver failure and HE, improves patient survival, improves quality of life, and decreases healthcare costs.

Line	Agent	Dosage	Side effects
First	lactulose	Acute -- enemas: 300 ml in 1000 ml every 2 hour until clinical improvement .	Abdominal cramps, diarrhea, dehydration
		Acute -- oral: 45 ml each hour until bowel movement and clinical improvement	
		Chronic -- oral: 15-45 ml tid or bid continuous until 2 to 3 bowel movements per day.	
Second	Rifaximin	Chronic -- oral: 400-550 mg po bid	Flatulence
Second	Neomycin	Acute -- oral: 1 g every 6 hours for up to 6 days	Ototoxicity, nephrotoxicity
		Chronic -- oral: 1-2 g/day	
Second	metronidazole	Chronic -- oral: 250 mg bid	Neurotoxicity
Third	Sodium benzoate/sodium phenylacetate	Chronic -- oral: titrate up to clinical improvement or a maximum dose of 5 g bid	Emesis
Third	Zinc acetate, Zinc gluconate, zinc sulfate	Chronic -- oral: 11 mg in adult males and 8 mg in adult females every day	Nausea
Third	bromocriptine	Chronic -- oral: 30 mg bid	Nausea, hypotension, headache, dizziness
Fourth	Surgical	Chronic -- surgical obliteration of large spontaneous portal-systemic anastomoses	Bleeding, infection

Table S-1. Treatment Summary

6. References

[1] Ferenci P. Hepatic encephalopathy. In: Haubrich WS, Schaffner F, Berk JE, eds. *Bockus Gastroenterology*. 5th ed. Philadelphia, Pa: WB Saunders; 1995:1998-2003.

[2] Blei A, Cordoba J. Practice Parameters Committee of the American College of Gastroenterology: Hepatic encephalopathy. *Am J Gastroenterol*. 2001; 96: 1968–1976.

[3] Mendler M, Donovan J, Blei A. Central nervous system and pulmonary complications of end-stage liver diseases. In *Textbook of Gastroenterology*, 4th Ed., Vol 2. Edited by Yamada J, Alpers D, Kaplowitz N, et al. Philadelphia: Lippincott Williams & Wilkins;2003: 2445–2467

[4] Bajaj JS. Review article: the modern management of hepatic encephalopathy. *Aliment Pharmacol Ther* 2010; 31: 537-547.

[5] Poordad FF. Review article: the burden of hepatic encephalopathy. *Aliment Pharmacol Ther* 2007; 25(Suppl 1): 3-9.

- [6] Chatauret N, Butterworth RF. Effects of liver failure on inter-organ trafficking of ammonia: Implications for the treatment of hepatic encephalopathy. *J Gastroenterol Hepatol.* 2004;19: S219-23.
- [7] Bajaj JS, Cordoba J, Mullen KD, Amodio, P, Shawcross DL, Butterworth RF, Morgan MY. Review article: the design of clinical trials in hepatic encephalopathy – an International Society for Hepatic Encephalopathy and Nitrogen Metabolism (ISHEN) consensus statement. *Aliment Pharmacol Ther* 2011; 33: 739-47.
- [8] Conn HO, Leevy CM, Vlahcevic ZR, et al. Comparison of lactulose and neomycin in the treatment of chronic portal-systemic encephalopathy. A double blind controlled trial. *Gastroenterology* 1977; 72: 573-83.
- [9] Parsons-Smith BG, Summerskill WHJ, Dawson AM, Sherlock S. The electroencephalograph in liver disease. *Lancet* 1957; 2: 867-71.
- [10] Ferenci P, Lockwood A, Mullen K, et al. Hepatic encephalopathy—definition, nomenclature, diagnosis, and quantification: final report of the working party at the 11th World Congresses of Gastroenterology, Vienna, 1998. *Hepatology* 2002; 35:716–21.
- [11] Hassanein, TI, Hilsabeck RC, Perry W. Introduction to the Hepatic Encephalopathy Scoring Algorithm (HESA). *Dig. Dis. Sci.* 2008; 53: 529-38.
- [12] Fessel JN, Conn, HO. An analysis of the causes and prevention of hepatic coma. *Gastroenterology.* 1972; 62:191.
- [13] Clay, AS, Hainline BE. Hyperammonemia in the ICU. *Chest* 2007; 132:1368-78.
- [14] Bachmann, C. Mechanisms of hyperammonemia. *Clin Chem Lab Med.* 2002; 40:653-662.
- [15] Vince, A, Dawson, AM, Park, N, et al. Ammonia production by intestinal bacteria. *Gut* 1973;14,171-177.
- [16] Karim, Z, Szutkowska, M, Vernimmen, C, et al Renal handling of NH₃/NH₄⁺: recent concepts. *Nephron Physiol* 2005;101,77-81.
- [17] Olde Damink, SW, Dejong, CH, Deutz, NE, et al Kidney plays a major role in ammonia homeostasis after portasystemic shunting in patients with cirrhosis. *Am J Physiol Gastrointest Liver Physiol* 2006;291,G189.
- [18] Cooper AJ, Plum F. Biochemistry and physiology of brain ammonia. *Physiol. Rev.* 1987; 67, 440-519.
- [19] Waxman SG, "Chapter 2. Development and Cellular Constituents of the Nervous System" (Chapter). Waxman SG: Clinical Neuroanatomy, 26e
- [20] Norenberg M. Hepatic encephalopathy: studies with astrocyte cultures. In: Norenberg M, Hertz L, Schousboe A, eds. *The Biochemical Pathology of Astrocytes*. New York: Alan R. Liss; 1988:451-464.
- [21] Aggarwal A et al. Reversible Parkinsonism and T1W pallidal hyperintensities in acute liver failure. *Mov Disord.* 2006; 21: 1986-1990
- [22] Krieger D et al. Manganese and chronic hepatic encephalopathy. *Lancet* 1995; 346: 270-74.
- [23] Butterworth, RF Effects of hyperammonaemia on brain function. *J Inherit Metab Dis* 1998; 21:6-20.
- [24] Vaquero, J, Chung, C, Cahill, ME, et al Pathogenesis of hepatic encephalopathy in acute liver failure. *Semin Liver Dis* 2003; 23:259-269.
- [25] Shawcross, D, Jalan, R. The pathophysiologic basis of hepatic encephalopathy: central role for ammonia and inflammation. *Cell Mol Life Sci* 2005; 62:2295-2304.

- [26] Cordoba J, Alonso J, Rovira A, Jacas C, Sanpedro F, Castells L, et al. The development of low-grade cerebral oedema in cirrhosis is supported by the evolution of 1H-magnetic resonance abnormalities after liver transplantation. *J Hepatol* 2001; 35:598-604.
- [27] Garcia-Martinez R, Rovira A et al. Hepatic encephalopathy is associated with posttransplant cognitive function and brain volume. *Liver Transpl* 2011; 17:38-46.
- [28] Shawcross DL, Davies NA, Williams R, Jalan R. Systemic inflammatory response exacerbates the neuropsychological effects of induced hyperammonemia in cirrhosis. *J Hepatol* 2004; 40:247-254.
- [29] Lockwood A, Yap E, Wong W. Cerebral ammonia metabolism in patients with severe liver disease and minimal hepatic encephalopathy. *J Cereb Blood Flow Metab* 1991; 11:337-341.
- [30] Murthy CR, Rama Rao KV, Bai G, Norenberg MD. Ammonia-induced production of free radicals in primary cultures of rat astrocytes. *J Neurosci. Res* 2001; 66:282-298.
- [31] Shawcross DL, Shabbir SS, Taylor, NJ, Hughes RD. Ammonia and the neutrophil in the pathogenesis of hepatic encephalopathy in cirrhosis. *Hepatology* 2010; 51:1062-1069.
- [32] Soeters PB, Fischer JE. Insulin, glucagon, aminoacid imbalance, and hepatic encephalopathy. *Lancet* 1976; 2(7991):880-2.
- [33] Ferenci P, Wewalka F. Plasma amino acids in hepatic encephalopathy. *J Neural Transm Suppl.* 1978;14(suppl): 87-94.
- [34] Morgan MY, Milsom JP, Sherlock S. Plasma ratio of valine, leucine and isoleucine to phenylalanine and tyrosine in liver disease. *Gut.* 1978;19: 1068-1073.
- [35] James, JH, Ziparo V, Jeppsson B, Fischer JE. "Hyperammonaemia, plasma aminoacid imbalance, and blood-brain aminoacid transport: a unified theory of portal-systemic encephalopathy." *Lancet* 1979; 2(8146):772.
- [36] Naylor CD, O'Rourke K, Detsky AS, Baker JP. Parenteral nutrition with branched-chain amino acids in hepatic encephalopathy a meta- analysis. *Gastroenterology.* 1989; 97: 1033.
- [37] Schliess F, Gorg B, Haussinger D. Pathogenetic interplay between osmotic and oxidative stress: the hepatic encephalopathy paradigm. *Biol. Chem.* 2006; 387:1363-1370.
- [38] Bassett ML, Mullen KD, Skolnick P, Jones EA. Amelioration of hepatic encephalopathy by pharmacologic antagonism of the GABAA-benzodiazepine receptor complex in a rabbit model of fulminant hepatic failure. *Gastroenterology.* 1987; 93(5):1069.
- [39] Ahboucha S, Butterworth RF. Pathophysiology of hepatic encephalopathy: a new look at GABA from the molecular standpoint. *Metab Brain Dis* 2004; 19:331-343.
- [40] Yurdaydin C, Gu ZQ, Nowak G, Fromm C, Holt AG, Basile AS. Benzodiazepine receptor ligands are elevated in an animal model of hepatic encephalopathy: relationship between brain concentration and severity of encephalopathy. *J Pharmacol Exp Ther.* 1993;265(2):565.
- [41] Cagnin A, Taylor-Robinson SD, Forton DM, Banati RB. In vivo imaging of cerebral "peripheral benzodiazepine binding sites" in patients with hepatic encephalopathy. *Neurochem. Int.* 2008; 52:575-587.
- [42] Ahboucha S, Butterworth RF. The neurosteroid system: an emerging therapeutic target for hepatic encephalopathy. *Metab Brain Dis* 2007; 22:291-308.

- [43] Reinehr R, Becker S, Qvartrkhava N, Bidmon HJ, Selbach O, Haas HL, Schliess F. Hypoosmotic swelling and ammonia increase oxidative stress by NADPH oxidase in cultured astrocytes and vital brain slices. *Glia*. 2007;55(7):758.
- [44] Butterworth RF. Glutamate transporter and receptor function in disorders of ammonia metabolism. *Ment Retard Dev Disabil Res Rev* 2001;7:276-279
- [45] Mousseau DD, Butterworth RF. "The [3H]tryptamine receptor in human brain: kinetics, distribution, and pharmacologic profile." *J Neurochem*. 1994;63(3):1052.
- [46] Yurdaydin C, Hörtnagl H, Steindl P, Zimmermann C, Pifl C, Singer EA, Roth E, Ferenci P. Increased serotonergic and noradrenergic activity in hepatic encephalopathy in rats with thioacetamide-induced acute liver failure. *Hepatology*. 1990;12(4 Pt 1):695.
- [47] Lozeva V, Tuomisto L, Sola D, Plumet C, Hippeläinen M, Butterworth R. Increased density of brain histamine H(1) receptors in rats with portacaval anastomosis and in cirrhotic patients with chronic hepatic encephalopathy. *Hepatology*. 2001;33(6):1370.
- [48] Córdoba J, Cabrera J, Lataif L, Penev P, Zee P, Blei AT. High prevalence of sleep disturbance in cirrhosis. *Hepatology*. 1998;27(2):339.
- [49] Al Sibae MR, McGuire BM. Current trends in the treatment of hepatic encephalopathy. *Ther Clin Risk Manag* 2009; 5: 617-626.
- [50] Olde Damink SW, Dejong CH, Deutz NE, et al. Upper gastrointestinal bleeding: an ammoniagenic and catabolic event due to the total absence of isoleucine in the haemoglobin molecule. *Med Hypotheses* 1999; 52, 515-519.
- [51] Chatauret N, Butterworth RF. Effects of liver failure on inter-organ trafficking of ammonia: Implications for the treatment of hepatic encephalopathy. *J Gastroenterol Hepatol*. 2004;19: S219-223.
- [52] Rodighiero V. "Effects of liver disease on pharmacokinetics. An update." *Clin Pharmacokinet* 2000; 38(6):491.
- [53] Kumar V, Fausto N, Abbas A (editors) (2003). *Robbins & Cotran Pathologic Basis of Disease* (7th ed.). Saunders. pp. 914-7
- [54] Rose C, Kresse W, & Kettenmann H. Acute insult of ammonia leads to calcium-dependent glutamate release from cultured astrocytes, an effect of pH. *J. Biol. Chem*. 2005; 280:20937-20944.
- [55] Rose C. Effect of ammonia on astrocytic glutamate uptake/release mechanisms. *J. Neurochem*. 2006; 97(suppl 1):11-15.
- [56] Hertz L, Murthy CR, Lai JC, Fitzpatrick SM, & Cooper AJ. Some metabolic effects of ammonia on astrocytes and neurons in primary cultures. *Neurochem. Pathol*. 1987; 6:97-129.
- [57] Córdoba J, Sanpedro F, Alonso J, & Rovira A. ¹H Magnetic resonance in the study of hepatic encephalopathy in humans. *Metab. Brain Dis*. 2002; 17:415-416.
- [58] Haussinger D. Low grade cerebral edema and the pathogenesis of hepatic encephalopathy in cirrhosis. *Hepatology* 2006; 43:1187-1190.
- [59] Rovira A, Alnoso J & Córdoba J. MR imaging findings in hepatic encephalopathy. *AJNR Am. J. Neuroradiol*. 2008; 29:1612-1621.
- [60] Mullen K. Hepatic encephalopathy. *Hepatology: A Textbook of Liver Disease*, 5th Ed., Vol. 1. Edited by Zakim D, Boyer TD. Philadelphia, Pa: WB Saunders;2006, 311-331.

- [61] Mullen KD, Amodio P, Morgan MY. Therapeutic studies in hepatic encephalopathy. *Metab. Brain Dis.* 2007; 22:407-23.
- [62] Ferenci P. Clinical Manifestations of Hepatic Encephalopathy. (online) <http://www.uptodate.com> 2010.
- [63] Sotil EU, Gottstein J, Ayala E, Randolph C, Blei AT. Impact of preoperative overt hepatic encephalopathy on neurocognitive function after liver transplantation, *Liver Transpl* 2009; 15: 184-92.
- [64] Ferenci P, Lockwood A, Mullen K, Tarter R, Weissenborn K, Blei AT. Hepatic encephalopathy-definition, nomenclature, diagnosis, and quantification: final report of the working party at the 11th World Congress of Gastroenterology, Vienna, 1998. *Hepatology* 2002; 35: 716-21.
- [65] Cadranet JF, Lebiez E, Di Martino V, Bernard B, El Koury S, Tourbah A, Pidoux B, Valla D, Opolon P. Focal neurological signs in hepatic encephalopathy in cirrhotic patients: an underestimated entity? *Am J Gastroenterol.* 2001;96(2):515.
- [66] Kircheis G, Wettstein M, Timmermann L, Schnitzler A, Haussinger D. Critical flicker frequency for quantification of low-grade hepatic encephalopathy. *Hepatology* 2002; 35: 357-66.
- [67] Bass NM. Review article: the current pharmacological therapies for hepatic encephalopathy. *Aliment Pharmacol Ther* 2007; 25(Suppl 1): 23-31.
- [68] Tsuji H. *et al.* A case of liver cirrhosis associated with chronic subdural hematoma and hepatic encephalopathy (Japanese). *Fukucka Igaku Zasshi* 1991; 82: 528-532.
- [69] Garcia-Martinez R, Rovira A, Alonso J, Jacas C, Simon-Talero M, Chavarria L, Vargas V, Cordoba J. Hepatic Encephalopathy is Associate with Posttransplant Cognitive Function and Brain Volume. *Liver Transpl* 2010; 17: 38-46.
- [70] Mullen KD & Jones EA. Natural benzodiazepines and hepatic encephalopathy. *Semin. Liver Dis.* 1996; 16: 255-264.
- [71] Mullen KD, Cole M & Foley JM. Neurological deficits in "awake" cirrhotic patients on hepatic encephalopathy treatment: missed metabolic or metal disorder? *Gastroenterology* 1996; 111: 256-257.
- [72] Rose C. *et al.* Manganese deposition in basal ganglia structures results form both portal-systemic shunting and liver dysfunction. *Gastroenterology* 1999; 117: 640-644.
- [73] Haseler, LJ, Sibbitt, WL, Mojtahedzadeh, HN, *et al.* Proton MR spectroscopic measurement of neurometabolites in hepatic encephalopathy during oral lactulose therapy. *AJNR Am J Neuroradiol* 1998; 19:1681.
- [74] Shah NJ, Neeb H, Zaitsev M, Steinhoff S, Kircheis G, Amunts K, Häussinger D, Zilles K. "Quantitative T1 mapping of hepatic encephalopathy using magnetic resonance imaging." *Hepatology* 2003;38(5):1219.
- [75] Amodio P, Campagna F, Olinas S, *et al.* Detection of minimal hepatic encephalopathy: normalization and optimization of the Psychometric Hepatic Encephalopathy Score. A neuropsychological and quantified EEG study. *J Hepatol* 2008; 49: 346-53.
- [76] Montagnese S, Jackson C, Morgan MY. Spatio-temporal decomposition of the electroencephalogram in patients with cirrhosis. *J Hepatol* 2007; 46: 447-58.
- [77] Amodio P, Montagnese S, Gatta A & Morgan MY. Characteristics of minimal hepatic encephalopathy. *Metab Brain Dis* 2004; 19: 253-267.
- [78] Prakesh R, & Mullen KD. Mechanisms, diagnosis and management of hepatic encephalopathy. *Nat rev Gastroenterol Hepatol* 2010; 7: 515-525.


- [79] Montagnese S, Amodio P, & Morgan MY. Methods for diagnosing hepatic encephalopathy in patients with cirrhosis: a multidimensional approach. *Metab Brain Dis* 2004; 19: 281-312.
- [80] Weissenborn K, *et al.* Neuropsychological characterization of hepatic encephalopathy. *J Hepatol* 2001; 29: 768-773.
- [81] RED Hepatic Encephalopathy (Spanish). *Spanish normative data for hepatic encephalopathy* (online), <http://www.redeh.org/> 2010.
- [82] Randolph C *et al.* Neuropsychological assessment of hepatic encephalopathy: ISHEN practice guidelines. *Liver Int* 2009; 29: 629-635.
- [83] Meyer T, Eshelman A, & Abouljoud M. Neuropsychological changes in a large sample of liver transplant candidates. *Transplant Proc* 2006; 38: 3559-3560.
- [84] Sorrell JH, Zolnikov BJ, Sharma A, & Jinnai I. Cognitive impairment in people diagnosed with end-stage liver disease evaluated for liver transplantation. *Psychiatry Clin Neurosci* 2006; 60: 174-181.
- [85] Iduru S, Mullen KD. The demise of the pencil? New computer-assisted tests for minimal hepatic encephalopathy. *Gastroenterology* 2008; 135: 1455-1456.
- [86] Randolph C. Randolph, C. (1998). *Repeatable Battery for the Assessment of Neuropsychological Status (RBANS)*. San Antonio: Harcourt, TX: The Psychological Corporation.
- [87] Bajaj JS, Hafeezullah M, Franco J, *et al.* Inhibitory control test for the diagnosis of minimal hepatic encephalopathy. *Gastroenterology* 2008; 135: 1591-1600e1.
- [88] Sharma P, Sharma BC, Puri V, Sarin SK. Critical flicker frequency: diagnostic tool for minimal hepatic encephalopathy. *J Hepatol* 2007; 47: 67-73.
- [89] Kircheis G, Wettstein M, Timmerman L, Schnitzler A, & Haussinger D. Diagnostic and prognostic values of critical flicker frequency determination as new diagnostic tool for objective HE evaluation in patients undergoing TIPS implantation. *Eur J Gastroenterol Hepatol* 2009; 1383-1394.
- [90] Bajaj JS, *et al.* Inhibitory control test is a simple method to diagnose minimal hepatic encephalopathy and predict development of overt hepatic encephalopathy. *Am J Gastroenterol* 2007; 102: 754-760.
- [91] Bajaj JS, Hafeezullah M, Zadvornova Y, *et al.* The effect of fatigue on driving skills in patients with hepatic encephalopathy. *Am J Gastroenterol* 2009; 104: 898-905.
- [92] Mardini H, Saxby BK, & Rcord CO. Computerized psychometric testing in minimal encephalopathy and modulation by nitrogen challenge and liver transplant. *Gastroenterology* 2008; 135: 1582-1590.
- [93] Prabhakar S, Bhatia R. "Management of agitation and convulsions in hepatic encephalopathy." *Indian J Gastroenterol*. 2003;22 Suppl 2:S54.
- [94] Kircheis G, Knoche A, Hilger N, Manhart F, Schnitzler A, Schulze H, Haussinger D. Hepatic encephalopathy and fitness to drive. *Gastroenterology* 2009; 137(5): 1706-1715.
- [95] Eroglu Y, Byrne W. Hepatic encephalopathy. *Emerg Med Clin N Am* 2009; 27: 401-414
- [96] Morgan MY, Blei A, Grungreiff K, *et al.* The treatment of hepatic encephalopathy. *Metab Brain Dis* 2007; 22: 389-405.
- [97] Cordoba J, Blei AT. Treatment of hepatic encephalopathy. *Am J Gastroenterol* 1997; 92(9): 1429-39.

- [98] Clausen MR, Mortensen PB. Lactulose, disaccharides and colonic flora: clinical consequences. *Drugs* 1997; 53(6): 930-942.
- [99] Jalan, R Intracranial hypertension in acute liver failure: pathophysiological basis of rational management. *Semin Liver Dis* 2003;23,271-282.
- [100] Sharma BC, Sharma P, Agrawal A, Sarin SK. Secondary prophylaxis of hepatic encephalopathy: an open label randomized controlled trial of lactulose versus placebo. *Gastroenterology* 2009; 137: 885-91.
- [101] Als-Nielsen B, Gluud LL, Gluud C. Non-absorbable disaccharides for hepatic encephalopathy: systematic review of randomized trials. *BMJ* 2004; 328: 1046.
- [102] Bajaj JS, Sanyal AJ, Bell D, Gilles H, & Heuman DM. Predictors of the recurrence of hepatic encephalopathy in lactulose-treated patients. *Aliment Pharmacol Ther* 2010; 31: 1012-1017.
- [103] Phongsamran PV, Kim JW, Abbott JC, & Rosenblatt A. Pharmacotherapy for Hepatic Encephalopathy. *Drugs* 2010; 70(9): 1131-1148.
- [104] Leevy CB, Phillips JA. Hospitalizations during the use of rifaximin versus lactulose for the treatment of hepatic encephalopathy. *Dig Dis Sci* 2007; 52: 737-741.
- [105] Heredia D, Teres J, Orteu N, *et al.* Lactitol vs. lactulose in the treatment of chronic recurrent portal-systemic encephalopathy. *J Hepatol* 1988; 7: 106-10.
- [106] Morgan MY, Hawley KE. Lactitol vs lactulose in the treatment of acute hepatic encephalopathy in cirrhotic patients: a double-blind, randomized trial. *Hepatology* 1987; 7 (6): 1278-84.
- [107] Huang DB, DuPont HL. Rifaximin: a novel antimicrobial for enteric infections. *J Infect* 2005; 50: 97-106.
- [108] Brigidi P, Swennen E, Rizzello F, *et al.* Effects of rifaximin administration on the intestinal microbiota in patients with ulcerative colitis. *J Chemother* 2002; 14: 290-295.
- [109] Lawrence KR, Klee JA. Rifaximin for the treatment of hepatic encephalopathy. *Pharmacotherapy*. 2008 Aug;28(8):1019-32.
- [110] Leevy CB, Phillips JA. Hospitalizations during the use of rifaximin versus lactulose for the treatment of hepatic encephalopathy. *Dig Dis Sci* 2007; 52: 737-41.
- [111] Jiang Q, Jiang XH, Zheng MH, Jiang LM, Chen YP, Wang L. Rifaximin versus nonabsorbable disaccharides in the management of hepatic encephalopathy: a meta-analysis. *Eur J Gastroenterol Hepatol* 2008; 20: 1064-70.
- [112] Bass NM. The current pharmacological therapies for hepatic encephalopathy. *Aliment Pharmacol Ther* 2007; 25: Suppl 1: 23-31.
- [113] MacLayton DO, Eaton-Maxwell A. Rifaximin for treatment of hepatic encephalopathy. *Ann Pharmacother* 2009; 43: 77-84.
- [114] PRICING – (data from drugstore.com)
- [115] Sama Ca, Morselli-Labate AM, Pianta P, *et al.* Clinical effects of rifaximin in patients with hepatic encephalopathy intolerant or nonresponsive to previous lactulose treatment: an open-label, pilot study. *Clin Ther Res* 2004; 65 (5): 413-420.
- [116] Longuercio C, Federico A, De Girolamo V, Ferrieri A, Del Vecchio, Blanco C. Cyclic treatment of chornic hepatic encephalopathy with rifaximin. Results of a double-blind clinical study. *Minerva Gastroenterol Dietol* 2003; 49: 53-62.

- [117] Strauss E, Tramote R, Silva EP, Caly WR. Double-blind randomized clinical trial comparing neomycin and placebo in the treatment of exogenous hepatic encephalopathy. *Hepatogastroenterology*. 1992;39: 542.
- [118] Greenberg LH, Momary H. Audiotoxicity and nephrotoxicity due to orally administered neomycin. *JAMA* 1965; 194: 237-238.
- [119] Tarao K, Ikeda T, Hayashi K, *et al.* Successful use of vancomycin hydrochloride in the treatment of lactulose resistant chronic hepatic encephalopathy. *Gut* 1990; 31: 702-706.
- [120] Staedt U, Leweling H, Gladisch R, *et al.* Effects of ornithine aspartate on plasma ammonia and plasma amino acids in patients with cirrhosis: a double-blind, randomized study using a four-fold crossover design. *J Hepatol* 1993; 19: 424-430.
- [121] Kircheis G, Nilius R, Held C, *et al.* Therapeutic efficacy of L-ornithine-L-aspartate infusions in patients with cirrhosis and hepatic encephalopathy: results of a placebo-controlled, double-blind study. *Hepatol* 1998; 25: 1351-1360.
- [122] Stauch S, Kircheis G, Adler G, *et al.* Oral L-ornithine L-aspartate therapy of chronic hepatic encephalopathy: results of a placebo-controlled double-blind study. *J Hepatol* 1998; 28: 856-64.
- [123] Acharya SK, Bhatia V, Sreenivas V, *et al.* Efficacy of L-ornithine L-aspartate in acute liver failure: a double-blind, randomized, placebo-controlled study. *Gastroenterol* 2009; 136: 2159-2168.
- [124] Sushma S, Dasarathy S, Tandon RK, *et al.* Sodium benzoate in the treatment of acute hepatic encephalopathy: a double-blind randomized trial. *Hepatology* 1992; 16: 138-144.
- [125] Mendenhall CL, Rouster S, Marshall L, *et al.*: A new therapy for portal systemic encephalopathy. *Am J Gastroenterol* 1986, 81:540-543.
- [126] Batshaw ML, MacArthur RB, Tuchman M. Alternative pathway therapy for urea cycle disorders: twenty years later. *J Pediatr*. Jan 2001;138(1 Suppl):S46-54; discussion S54-5.
- [127] Gentile S, Guarino G, Romano M, *et al.* A randomized controlled trial of acarbose in hepatic encephalopathy. *Clin Gastroenterol Hepatol* 2005; 3: 184-91.
- [128] Mendenhall C, Roselle GA, Gartside P, and Moritz T. Relationship of protein calorie malnutrition to alcoholic liver disease: a reexamination of data from two Veteran Administration Cooperative Studies. *Alcoholism: Clinical and Experimental Research* 1995; 19 (3): 602-609.
- [129] Campillo B, Richardet JP, Scherman E, & Bories PN. Evaluation of nutritional practice in hospitalized cirrhotic patients: results of a prospective study. *Nutrition* 2003; 19 (6): 515-564.
- [130] Plauth M, Cabre E, Riggio O, *et al.* ESPEN Guidelines on Enteral Nutrition: liver disease. *Clinical Nutrition* 2006; 25 (2): 285-294.
- [131] Liu Q, Duan ZP, Ha da K, *et al.* Synbiotic modulation of gut flora: Effect on minimal hepatic encephalopathy in patients with cirrhosis. *Hepatology*. 2004;39: 1441.
- [132] Shukla S, Shukla A, Mehboob S, & Guha S. Meta-analysis: the effects of gut flora modulation using probiotics, probiotics and synbiotics on minimal hepatic encephalopathy. *Aliment Pharmacol Ther* 2011; 33: 662-671.

- [133] Marchesini G, Dioguardi FS, Bianchi GP, *et al.* Long-term branched chain amino acid treatment in chronic hepatic encephalopathy. *J Hepatol* 1991; 11: 92-101.
- [134] Nakaya Y, Okita K, Suzuki K, *et al.* BCAA-enriched snack improves nutritional state of cirrhosis. *Nutrition* 2007; 23 (2): 113-120.
- [135] Fukushima H, Miwa Y, Ida E, *et al.* Nocturnal branched-chain amino acid administration improves protein metabolism in patients with liver cirrhosis: comparison with daytime administration. *Journal of Parenteral and Enteral Nutrition* 2003; 27 (5): 315-322.
- [136] Naylor CD, O'Rourke K, Detsky As, *et al.* Parenteral nutrition with branched-chain amino acids in hepatic encephalopathy: a meta-analysis. *Gastroenterology* 1989; 97: 1033-42.
- [137] Als-Nielsen B, Koretz RL, Kjaergard LL, *et al.* Branched-chain amino acids for hepatic encephalopathy. *Cochrane Database Syst Rev* 2003; (2): CD001939.
- [138] Als-Nielsen B, Kjaergard LL, Gluud C. Benzodiazepine receptor antagonists for acute and chronic hepatic encephalopathy. *Cochrane Database Syst Rev* 2004; (2): CD 002798.
- [139] Uribe M, Farca A, Marquez MA, Garcia-Ramos G, Guevara L. Treatment of chronic portal systemic encephalopathy with bromocriptine: A double-blind controlled trial. *Gastroenterology*. 1979;76: 1347-1351.
- [140] Loomba V, Pawar G, Khar KL, *et al.* Serum zinc levels in hepatic encephalopathy. *Indian Gastroenterol* 1995; 14: 51-53.
- [141] Riggio O, Ariosto F, Merli M, *et al.* Short-term oral zinc supplementation does not improve chronic hepatic encephalopathy: results of a double-blind crossover trial. *Dig Dis Sci* 1991; 36: 1204-1208.
- [142] Marchesini G, Fabbri A, Bianchi G, *et al.* Zinc supplementation and amino acid-nitrogen metabolism in patients with advanced cirrhosis. *Hepatology* 1996; 23: 1084-1092.
- [143] Riggio O, Efrati C, Catalano C, *et al.* High prevalence of spontaneous portal-systemic shunts in persistent hepatic encephalopathy: a case-control study. *Hepatology* 2005; 42: 1158-1165.
- [144] Stewart CA, Malinchoc M, Kim WR, Kamath PS. Hepatic encephalopathy as a predictor of survival in patients with end-stage liver disease. *Liver Transpl* 2007; 13: 1366-71.
- [145] Chang MY, Fang JT, Chen YC, *et al.* Continuous venovenous haemofiltration in hyperammonaemic coma of an adult with non-diagnosed partial ornithine transcarbamylase deficiency. *Nephrol Dial Transplant* 1999; 14, 1282-1284.
- [146] Donn SM, Swartz RD, Thoene JG. Comparison of exchange transfusion, peritoneal dialysis, and hemodialysis for the treatment of hyperammonemia in an anuric newborn infant. *J Pediatr* 1979; 95, 67-70.
- [147] Treem WR. Inherited and acquired syndromes of hyperammonemia and encephalopathy in children. *Semin Liver Dis* 1994; 14, 236-258.
- [148] Rutledge SL, Havens PL, Haymond MW, *et al.* Neonatal hemodialysis: effective therapy for the encephalopathy of inborn errors of metabolism. *J Pediatr* 1990; 116, 125-128.
- [149] Falk MC, Knight JF, Roy LP, *et al.* Continuous venovenous haemofiltration in the acute treatment of inborn errors of metabolism. *Pediatr Nephrol* 1994; 8, 330-333.

- [150] Mathias RS, Kostiner D, Packman S. Hyperammonemia in urea cycle disorders: role of the nephrologist. *Am J Kidney Dis* 2001; 37, 1069-1080.
- [151] Summar M, Pietsch J, Deshpande J, *et al.* Effective hemodialysis and hemofiltration driven by an extracorporeal membrane oxygenation pump in infants with hyperammonemia. *J Pediatr* 1996; 128, 379-382.
- [152] Stahl J. Studies of the blood ammonia in liver disease: Its diagnostic, prognostic, and therapeutic significance. *Ann Intern Med.* Jan 1963; 58: 1-24.
- [153] Shawcross D, Davies N, Hodges S, Wright G, Jalan R. Hypothermia abolishes ammonia-induced neutrophil spontaneous oxidative burst. *Hepatology* 2006; 44 (Suppl 1): 363A.
- [154] Jalan R, Olde Damink SW, Deutz NE, Hayes PC, Lee A. Moderate hypothermia in patients with acute liver failure and uncontrolled intracranial hypertension. *Gastroenterology* 2004; 127: 1338-1346.
- [155] Clemmesen J, Hansen B, Larsen FS. Indomethacin normalizes intracranial pressure in acute liver failure: a twenty-three year old woman treated with indomethacin. *Hepatology* 1997; 26, 1423-1425.
- [156] Therrien G, Rose C, Butterworth J, Butterworth RF. Protective effect of L-carnitine in ammonia-precipitated encephalopathy in the portacaval shunted rat. *Hepatology.* 1997;25: 551.
- [157] Malaguarnera M, Pistone G, Elvira R, *et al.* Effects of L-carnitine in patients with hepatic encephalopathy. *World J Gastroenterol* 2005; 11: 7197-7202.
- [158] del Olmo JA, Castillo M, Rodrigo JM, *et al.* Effects of L-carnitine upon ammonia tolerance test in cirrhotic patients. *Adv Exp Med Biol* 1990; 272: 197-208.
- [159] Vogels BA, Maas MA, Daalhuisen J, *et al.* Memantine: A noncompetitive NMDA receptor antagonist improves hyperammonemia-induced encephalopathy and acute hepatic encephalopathy in rats. *Hepatology.* 1997; 25: 820.
- [160] Hassanein TI, Tofteng F, Brown RS Jr, McGuire B, Lynch P, Mehta R, Larsen FS, *et al.* Randomized controlled study of extracorporeal albumin dialysis for hepatic encephalopathy in advanced cirrhosis. *Hepatology* 2007;46:1853-62.
- [161] Bosoi CR, Rarent-Robitaille C, Anderson K, Tremblay M, Rose FR. AST-120 (spherical carbon adsorbent) lowers ammonia levels and attenuates brain edema in bile duct-ligated rats. *Hepatology* 2011;53:1995-2002.
- [162] Ortiz M, Cordoba J, Doval E, *et al.* Development of a clinical hepatic encephalopathy staging scale. *Aliment Pharmacol Ther* 2007; 26:859-67.



Miscellanea on Encephalopathies - A Second Look

Edited by Dr. Radu Tanasescu

ISBN 978-953-51-0558-9

Hard cover, 390 pages

Publisher InTech

Published online 25, April, 2012

Published in print edition April, 2012

The book project “Miscellanea on Encephalopathies-a second look” aims to cover some of the important aspects regarding metabolic, hypoxic, neoplasm- and drug-related encephalopathies, by transmitting valuable information filtered through the real life clinical and research experience of the authors.

How to reference

In order to correctly reference this scholarly work, feel free to copy and paste the following:

Jeffrey E. Juneau and Brendan M. McGuire (2012). Hepatic Encephalopathy, Miscellanea on Encephalopathies - A Second Look, Dr. Radu Tanasescu (Ed.), ISBN: 978-953-51-0558-9, InTech, Available from: <http://www.intechopen.com/books/miscellanea-on-encephalopathies-a-second-look/hepatic-encephalopathy1>

INTECH
open science | open minds

InTech Europe

University Campus STeP Ri
Slavka Krautzeka 83/A
51000 Rijeka, Croatia
Phone: +385 (51) 770 447
Fax: +385 (51) 686 166
www.intechopen.com

InTech China

Unit 405, Office Block, Hotel Equatorial Shanghai
No.65, Yan An Road (West), Shanghai, 200040, China
中国上海市延安西路65号上海国际贵都大饭店办公楼405单元
Phone: +86-21-62489820
Fax: +86-21-62489821

© 2012 The Author(s). Licensee IntechOpen. This is an open access article distributed under the terms of the [Creative Commons Attribution 3.0 License](https://creativecommons.org/licenses/by/3.0/), which permits unrestricted use, distribution, and reproduction in any medium, provided the original work is properly cited.

IntechOpen

IntechOpen