

# We are IntechOpen, the world's leading publisher of Open Access books Built by scientists, for scientists

6,900

Open access books available

186,000

International authors and editors

200M

Downloads

Our authors are among the

154

Countries delivered to

TOP 1%

most cited scientists

12.2%

Contributors from top 500 universities



WEB OF SCIENCE™

Selection of our books indexed in the Book Citation Index  
in Web of Science™ Core Collection (BKCI)

Interested in publishing with us?  
Contact [book.department@intechopen.com](mailto:book.department@intechopen.com)

Numbers displayed above are based on latest data collected.  
For more information visit [www.intechopen.com](http://www.intechopen.com)



# Macular Edema Surgical Treatment

Jin Ma

*Eye Center of Second Associated Hospital,  
Zhejiang University College of Medicine  
China*

## 1. Introduction

Macular edema (ME) represents a common final pathway of many intraocular and systemic diseases, which characterized by the accumulation of extracellular fluid in Henle's layer and the inner nuclear layer of the retina. ME can cause severe visual disturbances and be considered to be multifactorial and difficult to treat. It may be most commonly seen following diabetic retinopathy, retinal vascular occlusion, intraocular surgery, uveitis, pigmentary degeneration, and/or vitreoretinal traction syndrome. The pathogenesis of ME involves the interplay of several affected factors, including the breakdown of the inner and outer blood retinal barriers, release of biochemical messengers, tissue hypoxia, retinal circulatory changes, and vitreous traction. Although medications and some other therapeutic methods are effective in some cases, they cannot be the best treatment due to adverse effects or lack of durability. Thus, the role of the vitreous in the development of ME has received attention. Abnormal glycation cross-linking of vitreal collagen has been found in the vitreous of ME cases. The abnormal collagen structure can destabilize the vitreous, leading to traction on the macula [1-7], which may distort the BRB and result in ME. On the other hand, the breakdown of the blood retinal barriers can lead to a high concentration of vasopermeable and chemoattractant factors in the posterior vitreous [8]. This pool of agents can cause cell migration to the posterior hyaloid. Contraction of these cells could lead to macular traction with possible development of a shallow macular detachment and exacerbation of ME [9,10]. (Fig. 1) Thus, we discuss the possibility of surgical treatment for ME in the following.

## 2. Vitrectomy

The role of the vitreous in the formation of DME has been recognized. A few study shows that in various disorders, including aphakia, uveitis, branched vein occlusion, and diabetic retinopathy, the vitreous could remain attached to the macula with the firm vitreomacular adhesions, which could cause traction on the inner limiting membrane (ILM) of the macula and exacerbate the ME. When the vitreous was either completely liquefied (Stickler syndrome and high myopia) or the hyaloid face had completely detached from the retina, the ME could be eliminated [11-12]. This finding demonstrated that the vitreous played a role in the development of ME and suggested that complete posterior vitreous detachment had a protective effect against the development of ME. Thus, the vitreous could play a role in exacerbating the ME, and the treatment of vitrectomy with separation of the posterior hyaloid from the macula could be beneficial.

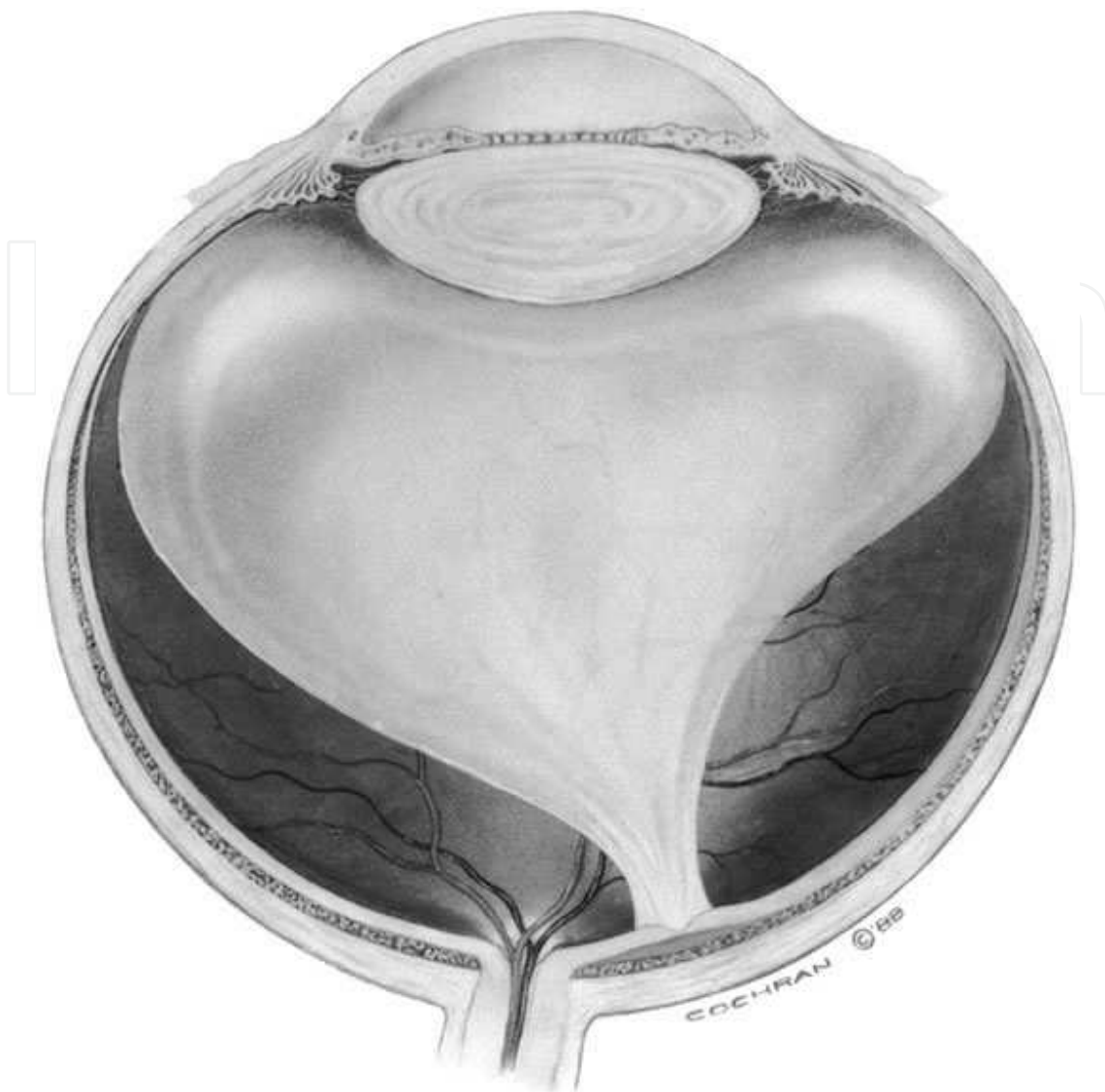


Fig. 1. Vitreomacular traction for macular edema. (From Margherio RR, Trese MT, Margherio AR et al: Surgical management of vitreomacular traction syndromes. *Ophthalmology* 1989;96:1439)

Why does vitrectomy and hyaloid removal could relieve ME? The release of vitreomacular traction is one obvious mechanism. The tractional force of the posterior hyaloid to the macula as seen in vitreomacular traction may be important in the pathogenesis of ME which has been well-demonstrated by optical coherence tomography [13]. In addition, vitrectomy appears to increase oxygenation of the macula. Kadonosho and colleagues [14] demonstrated increased perifoveal capillary blood flow after vitrectomy in their series. Stefansson and associates [15,16] reported that vitrectomy with lensectomy allows aqueous to provide increased levels of oxygen to the inner retina and that movement of oxygen transcorneally to the vitreous has been demonstrated to be more effective in vitrectomized eyes [17]. Therefore, vitrectomy has been reported to be beneficial in these situations. Some studies, however, have shown that vitrectomy is effective even when there is no evidence of macular traction [18-21]. Perhaps this is due to removal of the posterior hyaloid also removes toxic substances, such as histamine, free radical scavengers, and VEGF, which may be harbored in the preretinal space [22].

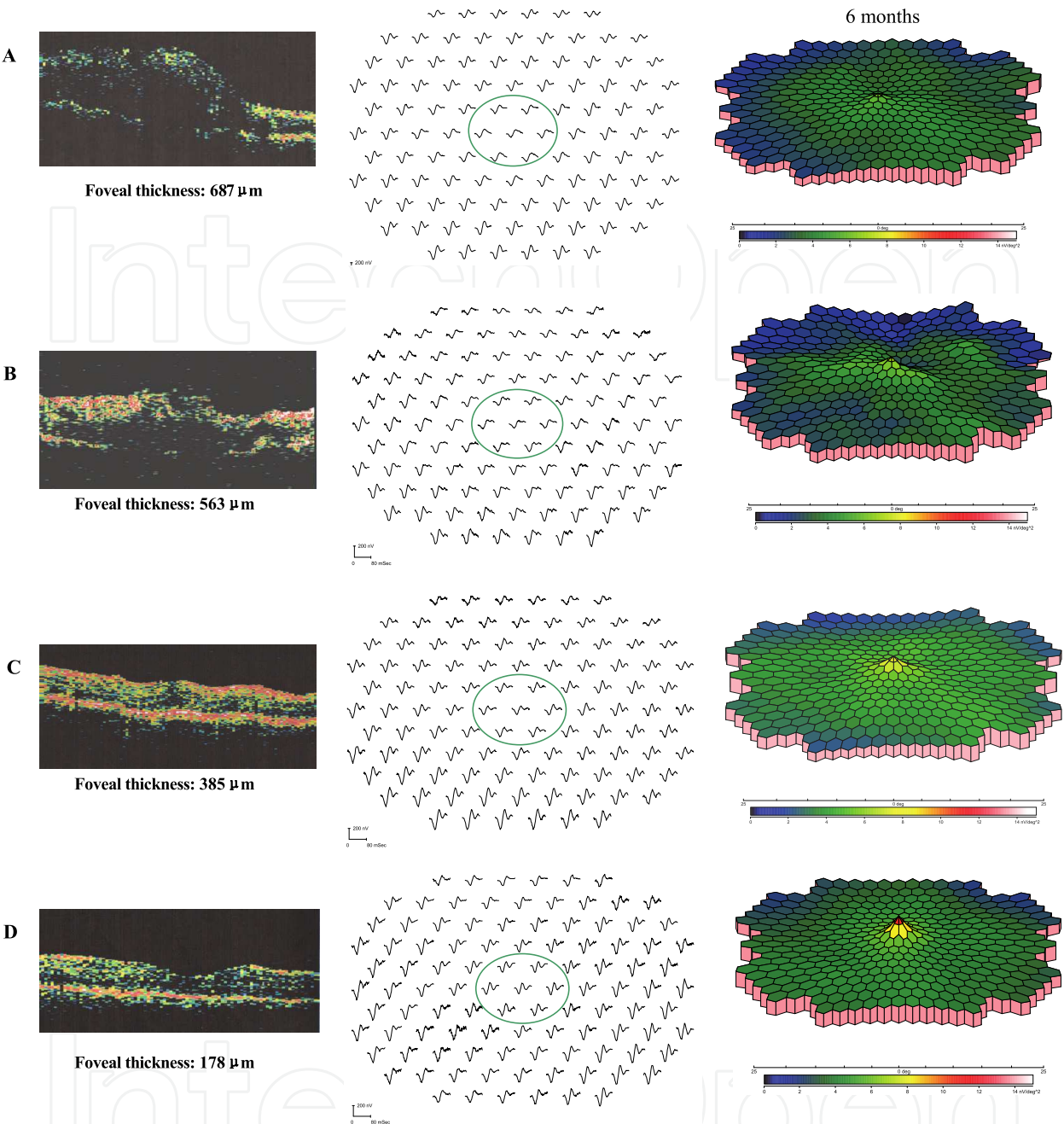
Recent advances in vitreous surgery have enabled us to treat surgically eyes with good visual acuity. The critical process in vitrectomy is making complete posterior vitreous detachment and removing the thickened and attached posterior hyaloids. We have used multifocal electroretinogram technique to investigate the effects of vitrectomy on macular visual function for diabetic ME, and prospectively evaluated the surgical outcomes in visual function. It's concluded that vitrectomy is helpful not only in reducing ME, and improving best correct visual acuity, but also in reinforcing the resume of macular and paramacular visual function [23]. (Fig. 2)

### 3. Vitrectomy with ILM peel

Recently, ILM peeling has been added to the procedure of surgical treatment for ME. Addition of ILM peel to vitrectomy expedites the resolution of the ME and prevents its recurrence, which would appear to enhance the beneficial effects of vitrectomy [24]. The mechanism for this was postulated to be the elimination of all tractional forces at the vitreoretinal interface and removal of the scaffold used by astrocytes to proliferate on the retinal surface. In addition, it was hypothesized that vitrectomy with removal of the ILM would allow the ME to decompress by facilitating the release of extracellular fluid into the vitreous, which would, in turn, restore normal retinal thickness and intraretinal tissue pressure. Challenges in surgical manipulation include poor visibility of the thin transparent membrane and the small dimensions and the sensitivity of the macular tissue. More recently, many study demonstrated that the technical difficulty of performing ILM peels can be eased with staining that specifically targets the ILM [25-29], which including indocyanine green, triamcinolone acetonide, trypan blue, whole blood, and brilliant blue G. These were shown selectively to stain the ILM and not the posterior vitreous or the underlying retinal layers. The use of indocyanine green in ILM removal has been decreased more recently for several reports of indocyanine green toxicity. Triamcinolone acetonide, trypan blue and brilliant blue G have become popularly used in ILM staining. (Fig. 3) We have treated chronic cystoid ME in branch retinal vein occlusion with 25-gauge vitrectomy and TA-assisted ILM peeling, and evaluated the efficacy. The result is that TA-assisted ILM peeling is generally effective in reducing ME and improving BCVA for CCME in BRVO for at least 7 months [30]. Certainly, the ILM can also be peeled without a visualization agent to avoid concerns of toxicity, especially if the ocular media and surgeon's view are particularly clear. This would avoid dye toxicity concerns but runs the risk of incomplete peeling. But in cases of ME, the adhesion of the ILM to the macula is stronger, and the manipulation must be more delicate. Therefore, additional repeated staining may be indicated, which decrease the risk of iatrogenic damage from surgical manipulation. Nevertheless, the value of ILM removal for treatment of ME has also been questioned recently. In a study of 135 eyes, 74 of which underwent ILM peeling, Kumagai and associates [31] found that even though ILM removal accelerated the absorption of ME, the final VA and rate of ME absorption were similar in both groups.

### 4. Vitrectomy with intravitreal pharmacologic therapies

Recently, intravitreal pharmacologic therapies (including intravitreal TA, VEGF inhibitors and protein kinase C beta-isoform inhibitors) have been demonstrated as effective in the treatment of ME when other modalities have failed, especially laser, in the setting of retinal vascular decompensation ME [32-34]. Intravitreal corticosteroids such as TA have been documented to reduce macular leakage in ME retinopathy with or without clinically



(A) before vitrectomy, the P1 value of amplitude and latency were 5.8  $\text{nv/deg}^2$  and 41.6 msec respectively; the best-corrected visual acuity was 0.04. (B) 2 months after vitrectomy, the P1 value of amplitude and latency were 6.3  $\text{nv/deg}^2$  and 40.2 msec respectively; the best-corrected visual acuity was 0.08. (C) 4 months after vitrectomy, the P1 value of amplitude and latency were 11.4  $\text{nv/deg}^2$  and 32.7 msec respectively; the best-corrected visual acuity was 0.2. (D) 6 months after vitrectomy, the P1 value of amplitude and latency were 16.9  $\text{nv/deg}^2$  and 25.3 msec respectively; the best-corrected visual acuity was 0.3. Ovals indicate central hexagons (ring1 and ring2 area). (From Ma J et al. Assessment of Macular Function by Multifocal Electroretinogram in Diabetic Macular Edema before and after Vitrectomy. Documenta Ophthalmologica. 2004;109 (2): 131-137.)

Fig. 2. The OCT image (left), trace array (Middle) and 3-D topography (right) of multifocal ERG for a same case of diabetic macular edema. With the passage of follow up, macular edema had decreased and retinal fuction had increased gradually.



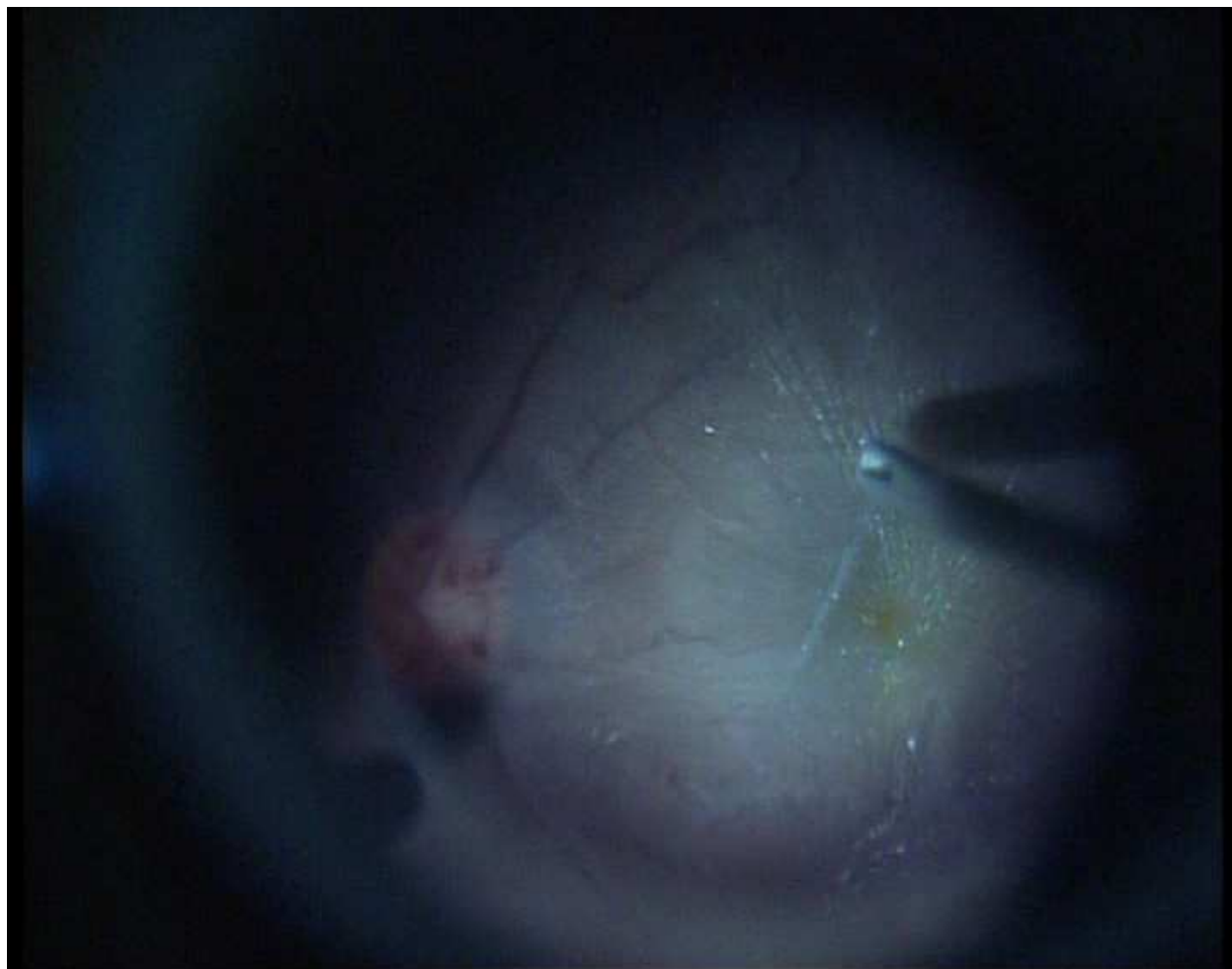


Fig. 3. Triamcinolone acetonide (TA) assisted internal limiting membrane (ILM)-peeling. The ILM is directly grasped with an intraocular forceps and peeled in a circumferential manner around the macular edema. The peeled area is clearly observed as lacking the white specks left by the TA. (Supplied by Jin Ma, MD.)

significant traction from vitreous or preretinal membranes. In this setting, corticosteroids appear to be effective by inhibiting both VEGF and macrophage-released factors on the basis of mechanisms described here. Corticosteroids may also be important in promoting overall endothelial cell repair [35]. VEGF is a peptide growth factor specific for vascular endothelial cells and increases vascular permeability and is thought to contribute to capillary wall dysfunction [36]. VEGF plays a dominant role in retinal vascular leakage and formation of ME. VEGF-A has been implicated as an important factor in the breakdown of the blood-retina barrier, with increased vascular permeability resulting in retinal edema in diabetes by affecting endothelial tight junction proteins [37]. Therefore, VEGF inhibition is another promising pharmacologic approach in the management of ME. There are several different anti-VEGF drugs which have been used in the management of ME, including pegaptanib (Macugen; Eyetech Pharmaceuticals, New York, New York, USA), bevacizumab (Avastin; Genentech Inc.), and ranibizumab (Lucentis; Genentech Inc., South San Francisco, California). Ruboxistaurin, a selective protein kinase C inhibitor, reduced retinal vascular leakage in patients with diabetic ME and reduced the rate of sustained moderate visual loss in those with moderately severe to very severe non proliferative diabetic retinopathy [32].

During the surgery, intravitreal pharmaceuticals mentioned above should be drop on the surface of fovea, after surgical removal of the posterior hyaloids with or without ILM peeling, and an air-fluid exchange carried out. Thus, vitrectomy with intravitreal pharmacologic combined therapies could provide clinicians with a set of power tools to treat ME, and may lead to a synergistic benefit that is not observed with monotherapy.

## 5. Removal of hard exudates and cysts

Further surgical procedures for ME are being attempted. Longstanding macular deposits may cause macular dysfunction and macular atrophy [38]. Direct removal of hard exudates was attempted by Takagi et al. [39] in a series of 7 eyes with massive hard exudates. They performed removal of the exudates by aspiration with a silicone-tipped extrusion needle or by direct removal with intraocular forceps. The final postoperative visual acuity was bad. In addition, intraoperative iatrogenic macular holes can be caused by the removal of neural retina surrounding the removed exudates. This complication rate mandates caution in using this technique.

Tachi et al. [40] attempted treatment of diabetic cystoid ME with cystotomy or cystectomy in addition to vitrectomy with posterior hyaloid removal. Despite resolution of cystoid ME in a few cases, there were several reported complications, including intraoperative retinal tears, and cyst reformation. The study could not demonstrate that this technique was superior to vitrectomy and posterior hyaloid removal alone.

## 6. Conclusions

Even so, laser photocoagulation remains the treatment of choice for ME associated with nondiffuse patterns of vascular leakage [41]. The action of photocoagulation is not fully known, but it is suspected that the method of treatment as described here not only cauterizes focally leaking sites, but also leads to vasoconstriction, the latter possibly by decreasing oxygen consumption in the outer retinal layers and increasing oxygen tension in the inner retinal layers [42]. Vitreous surgery is often effective in resolving ME associated with vitreoretinal or epiretinal traction and yields variable results in nontractional cases. A variety of pharmacologic agents targeting inflammatory and vasopermeability molecules have been shown to reduce diffuse ME and improve visual function over the short-term. Although treatment options continue to expand with the development of new drugs and surgical procedures, the long-term efficacy and safety of most new approaches have yet to be established in randomized, controlled clinical trials. We should be clear that this is a complicated disease which has been far than thoroughly investigated, which needs our further research on its pathogenesis thus leading to the introduction of additional pharmacological agents for the treatment and reduction of visual loss of ME. A variety of promising new medical and surgical therapies are under investigation, but additional clinical research is required to determine their role alone or in combination.


## 7. References

- [1] Enden MK, Nyengaard JR, Ostrow E, et al. Elevated glucose levels increase retinal glycolysis and sorbitol pathway metabolism. *Invest Ophthalmol Vis Sci*. 1994;53:2968-2975.
- [2] Kristinsson JK, Gottfendsdottir MS, Stefansson E. Retinal vessel dilatation and elongation precedes diabetic macular edema. *Br J Ophthalmol*. 1997;81:274-278.

- [3] Parving HH, Vibenti GC, Kern H, et al. Hemodynamic factors in the genesis of diabetic microangiopathy. *Metabolism*. 1983;32:993–999.
- [4] Abbasi M, Covantoni M, Chu L, et al. Adhesiveness of mononuclear cells to endothelium in patients with NIDDM. *Diabetes*. 1996;45(suppl):66.
- [5] Yoshida A, Feke GT, Morales-Stoppello J. et al. Retinal blood flow alterations during progression of diabetic retinopathy. *Arch Ophthalmol*. 1983;101:225–227.
- [6] Sebag J, Buckingham B, Charles MA, et al. Biochemical abnormalities in vitreous of humans with proliferative diabetic retinopathy. *Arch Ophthalmol*. 1992;110:1472–1476.
- [7] Sebag J, Boulazs EA. Pathogenesis of CME: Anatomic considerations of vitreoretinal adhesion. *Surv Ophthalmol*. 1984;29(suppl):493–498.
- [8] Sebag J. Diabetic vitreopathy. *Ophthalmology*. 1996;103:205–206.
- [9] Jumper MJ, Embabi SN, Toth CA, et al. Electron immunocytochemical analysis of protein hyaloid associated with diabetic macular edema. *Retina*. 2000;20:63–68.
- [10] Lewis H. The role of vitrectomy in the treatment of diabetic macular edema. *Am J Ophthalmol*. 2001;131:123–125.
- [11] Schepens CL, Avila MP, Jalkh AE, et al. Role of the vitreous in cystoid;macular edema. *Surv Ophthalmol*. 1984;28(suppl):499–504.
- [12] Nasrallah FP, Van de Velde F, Jalkh AE, et al. Importance of the vitreous in young diabetics with macular edema. *Ophthalmology*. 1989;96:1511–1517.
- [13] Massin P, Duguid G, Erginay A, et al. Optical coherence tomography for evaluating diabetic macular edema before and after vitrectomy. *Am J Ophthalmol*. 2003;135:169–177.
- [14] Kadonosono K, Itoh N, Ohno S. Perifoveal microcirculation before and after vitrectomy for diabetic cystoid macular edema. *Am J Ophthalmol*. 2000;130:740–744.
- [15] Stefansson E, Landers MB 3rd, Wobarsht ML. Increased retinal oxygen supply following panretinal photocoagulation and vitrectomy and lensectomy. *Trans Am Ophthalm Soc*. 1981;79:307–334.
- [16] Stefansson E. The therapeutic effects of retinal laser treatment and vitrectomy. A theory based on oxygen and vascular physiology. *Acta Ophthalmol Scand*. 2001;79:435–440.
- [17] Wilson CA, Benner JD, Berkowitz BA, et al. Transcorneal oxygenation of the preretinal vitreous. *Arch Ophthalmol*. 1994;112:839–845.
- [18] Tachi N, Ogino N. Vitrectomy for diffuse macular edema in cases of diabetic retinopathy. *Am J Ophthalmol* 1996; 122:258–260.
- [19] La Heij EC, Hendrikse F, Kessels AGH, Derhaag PJFM. Vitrectomy results in diabetic macular edema without evident vitreomacular traction. *Graefes Arch Clin Exp Ophthalmol* 2001; 239:264–270.
- [20] Yanyali A, Horozoglu F, Celik E, Nohutcu AF. Long-term outcomes of pars plana vitrectomy with internal limiting membrane removal in diabetic macular edema. *Retina* 2007; 27:557–566.
- [21] Patel JL, Hykin PG, Schadt M, et al. Pars plana vitrectomy for diabetic macular oedema: OCT and functional correlations. *Eye* 2006; 20:674–680.
- [22] Christoforidis JB, D'Amico DJ. Surgical and other treatments of diabetic macular edema: an update. *Int Ophthalmol Clin*. 2004 ;44(1):139-60.
- [23] Ma J, Yao K, Jiang J, Wu D, Gao R, Yin J, Fang X. Assessment of macular function by multifocal electroretinogram in diabetic macular edema before and after vitrectomy. *Doc Ophthalmol*. 2004;109(2):131-7.
- [24] Gandorfer A, Messmer EM, Ulbig MW, et al. Resolution of diabetic macular edema after surgical removal of the posterior hyaloid and the inner limiting membrane. *Retina*. 2000;20:126–133.



- [25] Mochizuki Y, Enaida H, Hisatomi T, Hata Y, Miura M, Arita R, Kawahara S, Kita T, Ueno A, Ishibashi T. The internal limiting membrane peeling with brilliant blue G staining for retinal detachment due to macular hole in high myopia. *Br J Ophthalmol*. 2008;92(7):1009.
- [26] Oie Y, Emi K, Takaoka G, Ikeda T. Effect of indocyanine green staining in peeling of internal limiting membrane for retinal detachment resulting from macular hole in myopic eyes. *Ophthalmology*. 2007;114(2):303-6.
- [27] Lai CC, Wu WC, Chuang LH, Yeung L, Lee JS, Chen TL. Selective staining of the internal limiting membrane using the sequential intraoperative instillation of whole blood followed by indocyanine green dye. *Am J Ophthalmol*. 2005;140(2):320-2.
- [28] Azad RV, Pal N, Vashisht N, Sharma YR, Kumar A. Efficacy of 0.15% trypan blue for staining and removal of the internal limiting membrane, epiretinal membranes, and the posterior hyaloid during pars plana vitrectomy. *Retina*. 2005;25(5):676.
- [29] Tognetto D, Zenoni S, Sanguinetti G, Haritoglou C, Ravalico G. Staining of the internal limiting membrane with intravitreal triamcinolone acetonide. *Retina*. 2005;25(4):462-7.
- [30] Ma J, Yao K, Zhang Z, Tang X. 25-gauge vitrectomy and triamcinolone acetonide-assisted internal limiting membrane peeling for chronic cystoid macular edema associated with branch retinal vein occlusion. *Retina*. 2008;28(7):947-56.
- [31] Kumagai K, Ogino N, Furukawa M, et al. Internal limiting membrane peeling in vitreous surgery for diabetic macular edema. *Nippon Ganka Gakkai Zasshi*. 2002;106:590-594.
- [32] Frank RN. Potential new medical therapies for diabetic retinopathy: Protein kinase C inhibitors. *Am J Ophthalmol*. 2002;133:693-698.
- [33] Haritoglou C, Kook D, Neubauer A, et al. Intravitreal bevacizumab (Avastin) therapy for persistent diffuse diabetic macular edema. *Retina* 2006; 26:999-1005.
- [34] Gillies MC, Sutter FK, Simpson JM, et al. Intravitreal triamcinolone for refractory diabetic macular edema: two-year results of a double-masked, placebocontrolled, randomized clinical trial. *Ophthalmology* 2006; 113:1533-1538.
- [35] Gibran SK, Khan K, Jungkim S, Cleary PE. Optical coherence tomographic pattern may predict visual outcome after intravitreal triamcinolone for diabetic macular edema. *Ophthalmology* 2007; 114:890-894.
- [36] Viores SA, Youssri AI, Luna JD, et al. Upregulation of vascular endothelial growth factor in ischemic and non-ischemic human and experimental retinal disease. *Histol Histopathol*. 1997;12:99-109.
- [37] Qaum T, Xu Q, Jousen AM, et al. VEGF-initiated blood-retinal barrier breakdown in early diabetes. *Invest Ophthalmol Vis Sci* 2001; 42:2408-2413.
- [38] Davis MD, Fisher MR, Gangnon RE, et al. Risk factors for high-risk proliferative diabetic retinopathy and severe visual loss: Early Treatment Diabetic Retinopathy Study. Report #18. *Invest Ophthalmol Vis Sci*. 1998;39:233-252.
- [39] Takagi H, Otani A, Kiryu J, et al. New surgical approach for removing massive foveal hard exudates in diabetic macular edema. *Ophthalmology*. 1999;106:249-256.
- [40] Tachi N, Hashimoto Y, Ogino N. Cystotomy for diabetic cystoid macular edema. *Doc Ophthalmol*. 1999;97(3-4):459-463.
- [41] Johnson MW. Etiology and treatment of macular edema. *Am J Ophthalmol*. 2009; 147(1):11-21.
- [42] Weiter JJ, Zuckerman R. The influence of the photoreceptor RPE complex on the inner retina. *Ophthalmology*. 1980;87:1133-1139.



## **Vitrectomy**

Edited by Dr. Zongming Song

ISBN 978-953-51-0546-6

Hard cover, 96 pages

**Publisher** InTech

**Published online** 20, April, 2012

**Published in print edition** April, 2012

This book is a comprehensive and systematic introduction to the basic theory, surgical techniques and the latest advances in vitrectomy. It focuses on vitreoretinal surgical indications and contraindications, surgical and operating techniques, surgery-related complications and their prevention, post-operation evaluation and prognosis. The book is divided into 6 chapters and has abundant content as well as a strong scientific and practical value. This book will be a valuable reference to ophthalmologists on all levels, especially vitreoretinal surgeons and researchers.

### **How to reference**

In order to correctly reference this scholarly work, feel free to copy and paste the following:

Jin Ma (2012). Macular Edema Surgical Treatment, Vitrectomy, Dr. Zongming Song (Ed.), ISBN: 978-953-51-0546-6, InTech, Available from: <http://www.intechopen.com/books/vitrectomy/macular-edema-surgery>

**INTech**  
open science | open minds

### **InTech Europe**

University Campus STeP Ri  
Slavka Krautzeka 83/A  
51000 Rijeka, Croatia  
Phone: +385 (51) 770 447  
Fax: +385 (51) 686 166  
[www.intechopen.com](http://www.intechopen.com)

### **InTech China**

Unit 405, Office Block, Hotel Equatorial Shanghai  
No.65, Yan An Road (West), Shanghai, 200040, China  
中国上海市延安西路65号上海国际贵都大饭店办公楼405单元  
Phone: +86-21-62489820  
Fax: +86-21-62489821

© 2012 The Author(s). Licensee IntechOpen. This is an open access article distributed under the terms of the [Creative Commons Attribution 3.0 License](https://creativecommons.org/licenses/by/3.0/), which permits unrestricted use, distribution, and reproduction in any medium, provided the original work is properly cited.

IntechOpen

IntechOpen