

We are IntechOpen, the world's leading publisher of Open Access books Built by scientists, for scientists

6,900

Open access books available

186,000

International authors and editors

200M

Downloads

Our authors are among the

154

Countries delivered to

TOP 1%

most cited scientists

12.2%

Contributors from top 500 universities



WEB OF SCIENCE™

Selection of our books indexed in the Book Citation Index
in Web of Science™ Core Collection (BKCI)

Interested in publishing with us?
Contact book.department@intechopen.com

Numbers displayed above are based on latest data collected.
For more information visit www.intechopen.com



Eye Movement Abnormalities in Spinocerebellar Ataxias

Roberto Rodríguez-Labrada and Luis Velázquez-Pérez
*Centre for the Research and Rehabilitation of Hereditary Ataxias, Holguín
Cuba*

1. Introduction

Spinocerebellar ataxias (SCAs) are a heterogeneous group of autosomal dominant neurodegenerative disorders characterized by a progressive cerebellar syndrome, variably associated to signs of brainstem involvement, pyramidal or extrapyramidal manifestations and cognitive dysfunctions, among other features that confer a remarkable wide range in phenotypes (Harding, 1983; Durr, 2010).

SCAs are associated with at least 31 different genetic loci, but the responsible gene is known in only 19 of them. Causative mutations include coding CAG expansions leading to a long polyglutamine (polyQ) tract in the respective proteins (SCA1, 2, 3, 6, 7 and 17), non-coding trinucleotide or pentanucleotide expansions (SCA8, 10, 12 and 31), as well as conventional mutations (SCA5, 11, 13, 14, 15/16, 20, 27 and 28) (Durr, 2010). The worldwide prevalence of SCAs is estimated near to 5-7 cases per 100 000 inhabitants but it can be higher in some regions due to foundational effects such as SCA2 in Holguín, Cuba (Velazquez-Pérez et al., 2009a) and SCA3 in Azores islands, Portugal (Vale et al., 2010).

Oculomotor disturbances are prominent features of SCA patients as result of cerebellar and brainstem neurodegeneration (Zee et al., 1976; Pula et al., 2010). The study of eye movement abnormalities give us valuable tools to search disease biomarkers because they can be easily accessible to clinical and/or electrophysiological evaluations and their dynamic properties and neurobiological basis are well known (Leigh & Kennard, 2004; Leigh & Zee, 2006; Reilly et al., 2008). The focus of this chapter is to review the state of the art of the eye movement deficits in SCAs, emphasizing in the usefulness of these features as disease biomarkers.

2. Brief overview of eye movements

Eye movements contribute to the clear vision stabilizing images on the retina, especially against movements of the head and body, capturing and keeping particular stimuli on the fovea and aligning the retinal images in the two eyes to guarantee the single vision and stereopsis. These functions can be achieved by 5 basic types of eye movements. For example, the image stabilization on the retina is promoted by the vestibulocular and optokinetic reflexes; the foveation occurs thorough the saccadic and smooth pursuit movements, whereas the binocular alignment is guaranteed by the vergence eye movements (Bruce & Friedman, 2002).

Eye movements differ in many aspects, such as their velocity, reaction time, reflexivity/volitional degree and their neurobiological substrate (Sparks, 2002). Nevertheless all have generic kinematic properties and share a common final path represented by three cranial nerve nuclei and the three pairs of eye muscles that they control (Bruce & Friedman, 2002; Leigh & Zee, 2006). Cranial nerve III (oculomotor) innervates superior, inferior and medial rectus muscles as well as the inferior oblique muscle, whereas troclear (IV) and abducens (VI) nerves innervate the superior oblique and lateral rectus respectively (Leigh & Zee, 2006).

Main features and neurophysiological bases of the 5 basic types of eye movements will be briefly addressed as follow.

2.1 Vestibulocular reflex (VOR)

The vestibulocular reflex (VOR) is elicited by the vestibular system in response to body/head rotations and consists in compensatory eye movements in opposite direction to body/head movement to guarantee the image stabilization on the retina (Aw et al., 1996). VOR depends of two neural circuits: *a)* Basic three neurons circuit and, *b)* Neural integrator circuit.

In the basic three neurons circuit, the head/body rotations are detected and transduced by vestibular ganglion neurons in the semicircular canal. Then, the transduced information is projected to neurons of the vestibular nuclei, located in the pons, and from there to oculomotor neurons (OMN) in one of the three oculomotor nuclei. Nevertheless, the three neurons circuit by itself is unable to adequately stabilize the image on the retina because it only generates phasic innervations of the oculomotor muscles, causing the return of the eye back to the central position due to the pulling of elastic forces. The neural integrator serves to exactly overcome this elastic force producing tonic innervations of oculomotor muscles. It is located in the *prepositus hypoglossi* and medial vestibular nuclei, which receive projections from the vestibular nuclei and have recurrent connections onto themselves. Some vestibular afferents go directly to the flocculus/paraflocculus cerebellar lobe, which is involved in VOR adaptation (Bruce & Friedman, 2002).

2.2 Optokinetic reflex (OKR)

When head/body rotations are very large and continued the VOR is depressed and thus it is complemented by the optokinetic reflex (OKR), in which the speed and direction of a full-field image motion is computed to develop eye movements with two phases, an slow phase that alternates with resetting quick phase (Tusa & Zee, 1989). Pathway underlying OKR includes the nucleus of the optic tract, which receives visual motion signals from the contralateral eye and striate/extrastriate cortical areas. This information is send to the vestibular nuclei and to the inferior olivary nucleus, and then to the floccular/parafloccular Purkinje cells via their climbing fibers (Bruce & Friedman, 2002).

2.3 Saccadic eye movements

Saccades are ballistic, conjugate eye movements that redirect fovea from one object of interest to another, allowing to explore accurately the visual scenes. For that, the saccadic system processes information about the distance and direction of a target image from the

current position of gaze. Saccades are the fastest eye movements, reaching up to $600^{\circ}/s$. There are close relationships between saccadic peak velocities, durations and amplitudes, which represent the saccadic main sequence (Bahill et al., 1975; Ramat et al., 2007).

Behaviourally, the saccades may be classified as reflexive guided saccades and intentional or volitional saccades. The first ones are evoked by the suddenly appearing targets, whereas the second ones, called also higher-order saccades, are made purposely, involve high cognitive processing and include voluntary, memory guided and delayed saccades as well as antisaccades (Müri & Nyffeler, 2008; Leigh & Kennard, 2004).

The neural basis of saccadic eye movements system comprises some cortico-cortical and cortico-subcortical networks (Müri & Nyffeler, 2008). Visual information processed in the primary visual cortex is sent to higher cortical areas, such as parietal eye field (PEF) and frontal eye field (FEF), which are involved in the preparation and triggering of reflexive and intentional saccades respectively (Pierrot-Deseilligny, et al., 2004). These cortical areas project their output directly or through the basal ganglia, to superior colliculus, a midbrain structure that identifies the target in retinotopic coordinates, generates trigger signal to the brainstem premotor oculomotor circuitry and encodes the magnitude and direction of the desired eye movement. This information is projected to the cerebellum, via a pontine pre-cerebellar nucleus, which guarantees the saccadic accuracy. Premotor burst neurons (PBN) for horizontal saccades lie within the paramedian pontine reticular formation (PPRF) while burst neurons for vertical and torsional saccades lie within the rostral interstitial nucleus of the medial longitudinal fasciculus. Saccade-related cerebellar areas include the oculomotor vermis (lobules VI and VII) and the caudal region of the fastigial nucleus which send saccade commands to the contralateral PBNs leading the activation of motoneurons and oculomotor muscles related with the desired saccadic movement (Leigh & Zee, 2006; Robinson & Fuchs, 2001; Prsa & Their, 2011; Voogd et al., 2011).

2.4 Smooth pursuit movements

Smooth-pursuit eye movements enable us to maintain the image of a moving object relatively stable on or near the fovea by matching eye velocity to target velocity (Leigh & Zee, 2006). Smooth pursuit performance is optimal for target speeds ranging between $15^{\circ}/s$ and $30^{\circ}/s$ but pursuit velocity can reach up to $100^{\circ}/s$ (Lencer & Trillenberg 2008; Bruce & Friedman, 2002). Smooth pursuit system is closely related to other oculomotor systems such as OKR and saccadic system. In fact, the small position errors raised when the tracking velocity is not properly matched to the target are corrected by saccadic movements named “catch up” saccades (Lencer & Trillenberg, 2007).

Neuronal pathways for smooth pursuit movements involve a complex network of cortical and subcortical structures. Extrastriate visual area V5 (divided into middle temporal visual area (MT) and the medial superior temporal visual area (MST)) play a crucial role for motion perception and smooth pursuit control. This area receives visual motion information from the primary visual cortex in a retinotopic and ipsilaterally organized fashion. The MT area encodes image motion in a retinal coordinate system whereas MST area converts the signals into a spatial coordinate system. The signals generated in the V5 area are projected to other cortical areas in the parietal and frontal lobes. Among them, the frontal eye field (FEF) is involved in the generation of oculomotor command for smooth pursuit. Both visual motion

signals and oculomotor commands are relayed to oculomotor parts of the cerebellum, through the dorsolateral and medial pontine nuclei. Smooth pursuit-related areas of the cerebellum comprise the paraflocculus, the flocculus, the oculomotor vermis and the uvula, which control the initiation and maintenance of smooth pursuit. Finally, the cerebellar output is projected, via the vestibular nuclei, to the oculomotor nuclei (Lencer & Trillenber, 2007; Mustari et al., 2009).

2.5 Vergence eye movements

Vergence eye movements are disjunctive movements that provide the binocular alignment in response to changing fixation target distances, requiring that both eyes point in contrary directions (Zee & Levi, 1989). Vergence movements are elicited by retinal disparity (when a fixation target is not on both foveae) and retinal blur (when a target is not in focus) and are closely related to the lens accommodation and pupillary reflexes. Although the neural basis of vergence eye movements are not well understood, it is known that both the retinal disparity and the retinal blur signals are processed by cortical visual areas such as primary visual cortex (V1) and an anterior region of the FEF. Additionally, it is presumed an important role of the oculomotor nucleus (III) for vergence movements, due to its known relation to lens accommodation and pupillary reflexes (Vilis, 1997; Bruce & Friedman, 2002). The cerebellum is involved in the processing of dynamic vergence eye movements (Sander et al., 2009). Cerebellar regions related with these disconjugate eye movements lie on the dorsal paraflocculus, and the floccular lobe, which project to the lateral portion of the posterior interposed nucleus (Voogd et al., 2011).

2.6 Oculomotor disturbances

Oculomotor disturbances can be topographically classified as peripheral or central disturbances. Peripheral abnormalities result from lesions in the oculomotor muscles or nerves, whereas the central disturbances are caused by lesions in the brainstem, cerebellum or other higher-level centers (Karatas, 2009). Oculomotor signs of cerebellar impairment include pathological nystagmus such as downbeat, rebound and periodic alternating nystagmus, as well as abnormal pursuit, VOR/OKR abnormalities and saccadic dysmetria (Robinson & Fuchs, 2001; Strupp et al., 2011). Whereas, brainstem involvement produces slowed vertical, torsional or horizontal saccades, ophthalmoplegia, VOR/OKR impairments and gaze-evoked nystagmus (Rüb et al., 2008; Strupp et al., 2011). Affections in the basal ganglia can lead to reduced ability to initiate voluntary eye movements and to suppress unwanted saccades, in addition to deficits in memory-guided saccades, eye-head coordination and eye-hand coordination (Hikosaka et al., 2000; Shires et al., 2010). Frontal cortex lesions produce prolongation of saccadic latency, impaired ability to make saccades to remembered target locations and errors on the antisaccade task, as well as delayed initiation of smooth pursuit and increase of catch up saccades (Pierrot-Deseilligny et al., 2004; Thurtell et al., 2007; Karatas, 2009).

3. Oculomotor findings of spinocerebellar ataxias

3.1 Spinocerebellar ataxia type 1 (SCA1)

The main eye movement abnormalities of SCA1 patients include saccadic dysmetria, gaze evoked nystagmus and depressed smooth pursuit (Matilla-Dueñas et al., 2008). Saccadic

hypermetria is observed in majority of the cases, appears at an early stage of the disease and progresses quickly (Klostermann et al., 1997; Rivaud-Pechoux et al., 1998; Buttner et al., 1998). The overshoot of saccades may reach values greater than 30% in comparison with normal subjects (Buttner et al., 1998).

Brainstem oculomotor signs such as saccadic slowing or ophthalmoparesis are observed in 74% (Schmitz-Hübsch, et al., 2008). Reduction of saccade velocity can be detected in mildly affected patients and it is accentuated with the disease duration. Advanced patients may show ophthalmoparesis or severe saccadic slowing, so that saccadic hypermetria is less noticeable in comparison to early stages (Klostermann et al., 1997). Abnormal prolongation of saccadic latency occurs in 67% of cases (Buttner et al., 1998), whereas the execution of the antisaccadic task shows increased error rates, suggesting the presence of neurodegenerative changes in the frontal cortex (Rivaud-Pechoux et al., 1998).

Reduced gain of smooth pursuit and OKN is noticed in 92% of SCA1 cases with the lowest smooth pursuit gains in comparison to SCA2 and SCA3 patients and comparable values of OKN gains to SCA2 (Burk et al., 1998). The progressive saccadic slowing causes the diminution of catch up saccades during visual tracking, leading to decrease of the smooth pursuit amplitudes on advanced disease (Buttner et al., 1998, Klostermann et al., 1997). Regarding vestibular functions, SCA1 patients are usually characterized by reduced VOR gains, which distinguish this SCA subtype from SCA2 but neither from SCA3 nor SCA6 (Burk et al., 1998; Buttner et al., 1998).

No oculomotor abnormalities of SCA1 patients correlate with the number of CAG repeats (Burk et al., 1999; Rivaud-Pechoux et al., 1998), suggesting that they are not under significant genetic control but are more dependent on disease duration.

3.2 Spinocerebellar ataxia type 2 (SCA2)

The most common oculomotor sign in patients with SCA2 is a significant reduction in horizontal saccadic eye velocity owing to brainstem involvement. This feature called attention to Wadia and Swami when made the first report of SCA2 in 1971, so that they described the disease as *“a new form of heredofamilial spinocerebellar degeneration with slow eye movements”* (Wadia & Swami, 1971). Several clinical and epidemiological studies have confirmed the high frequency of this saccadic alteration in more than 80% of cases (Velazquez-Pérez et al., 2009a; Orozco et al., 1989; Cancel et al., 1997, Wadia et al., 1998; Schmitz-Hübsch, et al., 2008).

The first electronystagmographical evaluation of SCA2 patients was conducted by Kulkarni & Wadia in 1975 who found a relative decrease of saccadic velocity up to 25% in comparison with controls (Kulkarni & Wadia, 1975). Furthermore, comparative studies of oculomotor phenotypes among patients with cerebellar ataxias demonstrated that saccadic slowing is more prominent in SCA2 patients in comparison with SCA1, SCA3, SCA6 (Burk, et al; 1999; Buttner et al., 1998; Rivaud-Pechoux et al., 1998) and late onset cerebellar ataxia (Rufa & Federighi, 2011) giving an important diagnostic value to this oculomotor feature for SCA2.

A comprehensive electronystagmographical study developed in 82 SCA2 Cuban patients showed little overlap between maximal saccadic velocity (MSV) values of SCA2 patients and controls. This study demonstrated a high sensitivity for SCA2 diagnosis assessed by a

receiver operating characteristic (ROC) yielding an area under the curve of 0.99. The most important finding of this work was the significant influence of the number of CAG repeats, but not of disease duration, on saccadic velocity (Figure 1). According to this relationship, patients with larger expansions showed more saccadic slowing, identifying the saccadic velocity as the main variable endophenotype of the SCA2, which is under strong genetic control and therefore it may be considered as a sensitive biomarker for the study of polyglutamine toxicity. Also, MSV was negatively correlated with the total score of a cerebellar ataxia scale suggesting its association with the severity of the cerebellar syndrome (Velázquez et al., 2004). Other study performed in Cuban SCA2 patients revealed a closer relationship between the saccadic velocity and the visuomotor learning capabilities assessed by a prism adaptation task (Fernandez-Ruiz, et al., 2007).

A preliminary follow-up evaluation of saccadic slowing after one year in 30 SCA2 patients revealed no significant changes of MSV (Seifried et al., 2004). Nevertheless, other follow-up study during a larger period time it is being conducted in a large Cuban SCA2 cohort.

The saccadic slowing appears during the presymptomatic stage of the disease only for 60° target amplitude, but asymptomatic subjects carrying full-penetrant CAG expansions (≥ 36) show reduced MSV values even for 30°. In fact, the MSV reduction is stronger in carriers of large expansions. This preclinical feature progresses insidiously and it correlates with predicted time to clinical manifestation, which classifies this variable as a preclinical biomarker of high values for diagnosis and prognosis of the disease (Velázquez-Pérez et al., 2009b).

The neuroanatomical basis of this disorder has been elucidated by post-mortem studies that demonstrated the marked loss of excitatory PBN in the PPRF (Buttner-Ennever, et al., 1985; Geiner et al., 2008), the structure that coordinates the horizontal saccades (Leigh & Zee, 2006). Early, Gierga et al, 2005 had reported a significant neuronal death in the abducens (cranial nerve VI) and oculomotor nucleus (cranial nerve III), which innervate the oculomotor muscles responsible for eye movements in the horizontal plane (Leigh & Zee, 2006).

Hypometric saccades to extreme gaze positions are usual in SCA2 patients (Velázquez, 2008), nevertheless for short target amplitudes the saccade accuracy is maintained, although some patients can make hypermetric saccades. It has been suggested that as SCA2 patients having slow saccades that are no longer ballistic, visual feedback might be continuously available during the movement execution to guide the eye to its target rendering accurate short saccades (Federighi et al., 2011).

A recent electronystagmographical study in 110 SCA2 patients demonstrated the significant prolongation of saccadic latency in 46% of SCA2 patients. This variable was neither influenced by the CAG repeats, disease duration nor ataxia score, but it was close related with the neuropsychological performance of frontal-executive tasks, which highlights the saccadic latency as sensitive biomarker of cognitive disorders in SCA2 (Rodríguez-Labrada, et al., 2011a). Additionally, SCA2 patients show increased antisaccadic error rate (Rivaud-Pechoux et al., 1998). The delayed saccade onset and antisaccadic deficits could be explained by the severe gyral atrophy and neuronal loss in the frontal lobes and neurodegenerative changes in caudate nucleus and substantia nigra (Orozco et al., 1989; Durr et al., 1995; Estrada et al., 1999; Gierga et al., 2005), as well as deficits in the processing

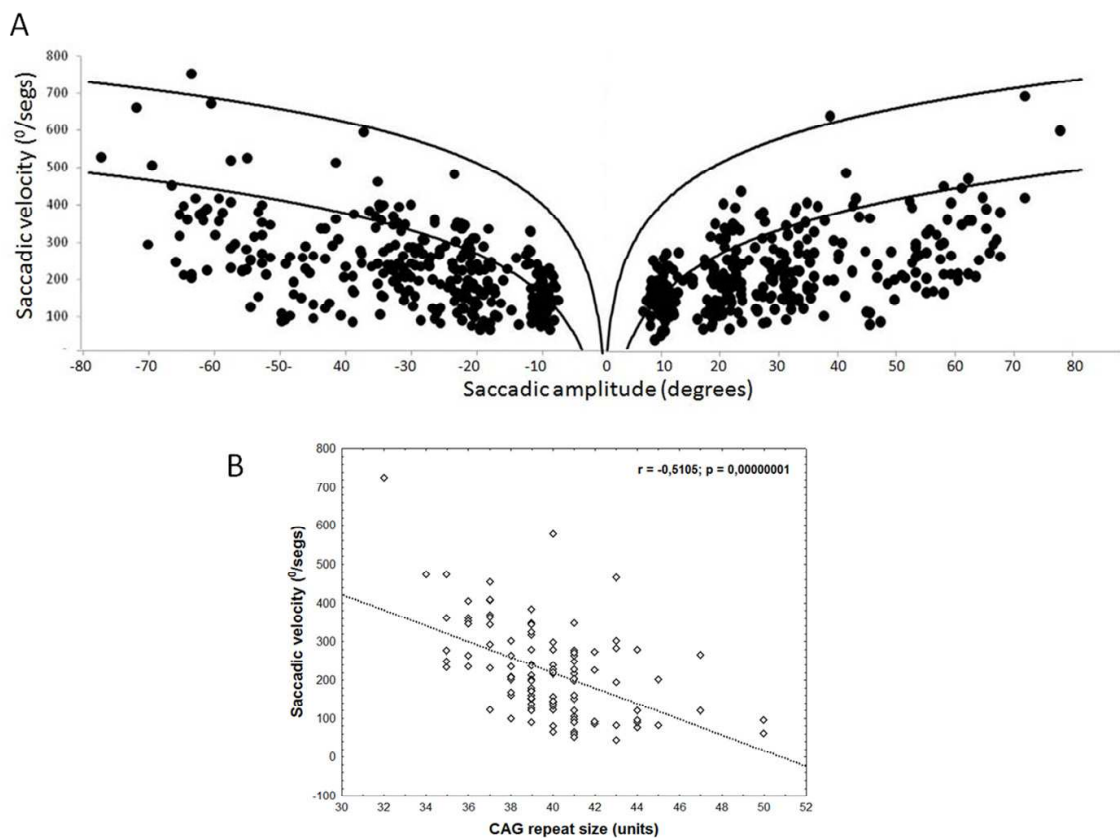


Fig. 1. Saccadic slowing in SCA2. A) Relationship of saccadic velocity and amplitudes in SCA2 patients. Show the significant reduction of saccadic velocity in almost all subjects. Dark lines represent the saccadic velocity ± 2 SD of controls. B) Influence of CAG repeat size on the saccadic velocity.

of visual information (Kremlacek et al., 2011) or in the visual-spatial attention (Le Pira et al., 2002).

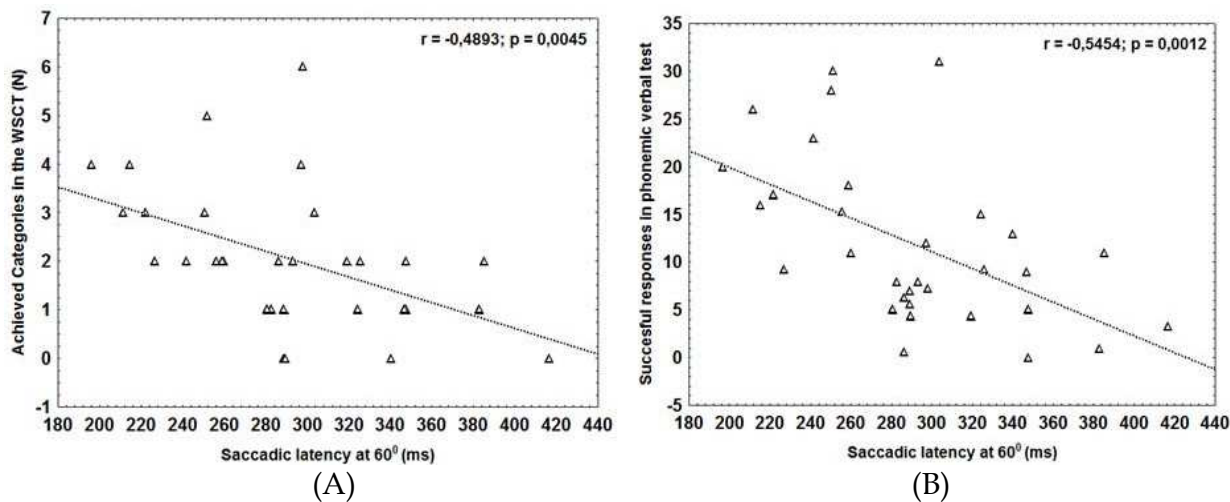


Fig. 2. Saccadic latency correlates with frontal-executive dysfunctions in SCA2 patients. Correlation analyses of saccadic latency with achieved categories in the Wisconsin sort card test (WSCT) and the number of correct responses in the phonemic verbal test.

Other oculomotor alterations include ophthalmoplegia, which usually appears at advanced disease in the 45% of the cases, although the severe saccadic slowing might overlook the frequency of ophthalmoplegia in SCA2. These patients have mild reduction of smooth pursuit gain in correspondence with the atrophy of cerebellar flocculus (Ying et al., 2006) and the decrease of catch up saccades. The physiological and pathological nystagmus are very rare in SCA2 due to impaired ability to produce saccadic corrective phases. Some SCA2 patients have VOR responses with reduced gain (Burk et al., 1999; Rivaud-Pechoux et al., 1998; Buttner et al., 1998).

Saccadic eye movements have also been used to evaluate the efficacy of therapeutical alternatives in Cuban SCA2 patients, such as neurorehabilitation (Rodríguez et al., 2008) and oral supplementation with zinc-sulphate (Velázquez-Pérez et al., 2011a). In both cases the saccadic latency decreased significantly after the therapies, but saccadic velocity and dysmetria were unchanged.

For SCA2, the oculomotor function has not only evaluated in wake state, since the density of rapid eye movements (saccadic) during REM sleep was recently assessed. Both symptomatic and presymptomatic subjects show a marked decrease in this parameter, which is negatively correlated with the ataxia score in the patients (Velázquez-Pérez, et al., 2011b; Rodríguez-Labrada et al., 2011b). These findings suggest the usefulness of saccadic density during REM sleep as progression marker of the disease and reflect the extension of the oculomotor brainstem involvement to the sleep.

3.3 Spinocerebellar ataxia type 3 (SCA3)

Pathological nystagmus are prominent oculomotor signs of SCA3 patients. The frequency of gaze evoked and rebound nystagmus is approximately 90% (Jardim et al., 2001) being higher than those in SCA1, SCA2 and SCA6. Square wave jerks are usually reported in SCA3 subjects, unlike SCA1 and SCA2 individuals (Buttner et al., 1998; Burk et al., 1998). This oculomotor sign results from cerebellar disease and consists in small, horizontal, saccade-like movements that lead the eye away from the target trajectory and, after a delay, bring it back onto the target (Leigh & Zee, 2006).

Decreased VOR gain can be detected in majority of SCA3 patients and correlates with the CAG repeats, suggesting the pathologic involvement of the vestibular nuclei in the lateral brainstem. Furthermore, these patients show reduction of smooth pursuit and OKR gains with a presentation frequency above 70% in both cases (Buttner et al., 1998; Burk et al., 1998).

Upon saccades, the main abnormality is saccadic dysmetria. Nevertheless, there are apparently conflicting data regarding the predominant type of dysmetria. Buttner et al., 1998 reported hypermetric saccades in 86% of the cases, while Rivaud-Pechoux et al., 1998, observed a predominance of hypometric (56%) over hypermetric saccades (18%). The disagreement can be explained by differences in the clinical stage of studied patients. In fact, the 81% of the patients recruited by Rivaud-Pechoux and colleagues had a moderate to severe motor disability, which could explain the higher prevalence of saccadic hypometria.

Different to SCA2 and SCA1, decreased saccadic velocity is not a common feature of SCA3 patients (Burk et al., 1999; Rivaud-Pechoux et al., 1998; Buttner et al., 1998). This oculomotor feature appears in advanced disease, perhaps in correspondence with the degenerative

changes seen in the raphe interpositus nucleus (Rub et al., 2003), a key structure of the brainstem premotor network that contains the omnipause neurons, a group of cells that play an important role in determining the size of the velocity command for saccades, beside their well-known role as gating saccades (Miura & Optican, 2006). Also, internuclear and nuclear ophthalmoplegia is observed in 53% and 10% of the cases respectively. The latter is associated with a more severe disease course (Jardim et al., 2001).

Finally, the prolongation of saccadic latency occurs late in few cases (14%) (Buttner et al., 1998) and the performance in the antisaccadic paradigm shows an increase in the number of errors (Rivaud-Pechoux et al., 1998).

3.4 Spinocerebellar ataxia type 6 (SCA6)

Oculomotor function of SCA6 patients is characterized by signs of cerebellar and vestibular impairments such as horizontal and vertical nystagmus, abnormal smooth pursuit, saccadic dysmetria and abnormal VOR (Buttner et al., 1998; Christova et al., 2008; Bour et al., 2008). In comparison with other SCAs, the spontaneous downbeat nystagmus and square-wave jerks have the higher incidence in SCA6 subjects, whereas gaze-evoked nystagmus, rebound nystagmus and periodic alternating nystagmus are common features too (Buttner et al., 1998; Colen et al., 2008; Kim et al., 2010).

Patients with SCA6 have the more severe pursuit, OKN and VOR-fixed deficits among other polyglutamine SCAs but these oculomotor signs are not directly associated to CAG repeats or disease duration (Buttner et al., 1998). Vertical pursuit is impaired more than horizontal whereas downward pursuit more than upward (Bour et al., 2008).

The pattern of saccadic dysmetria in SCA6 is variable since these patients can show both hypometric and hypermetric saccades (Buttner et al., 1998; Bour et al., 2008). Although the decrease of saccadic velocity is not a prominent sign in these patients, it has been reported a mild saccadic slowing in some subjects both for the horizontal and vertical planes (Bour et al., 2008). These findings suggest functional extracerebellar impairment in the saccadic system and therefore are opposed to the paradigm of SCA6 as a "pure cerebellar syndrome." In fact, the screening of non-ataxia signs reveals a 25% of brainstem oculomotor signs (Schmitz-Hübsch, et al., 2008). In these patients the saccadic latency is normal (Buttner et al., 1998).

In 2009, Christova and co-workers studied the eye movement's abnormalities in both symptomatic and asymptomatic SCA6 cohorts and noticed that square-wave jerks, saccadic abnormalities and depressed smooth pursuit can be detected even before the disease onset. Among them, the square-wave jerks were the most prominent with an apparition frequency of 80% (Christova et al., 2008).

3.5 Spinocerebellar ataxia type 7 (SCA7)

The major saccadic alteration in this SCA is the slowing of saccades, together with saccadic dysmetria (Miller et al., 2009; Manrique et al., 2009). The decrease in saccadic velocity in SCA7 is associated with marked pontine atrophy that characterizes these patients from early stages of the disease and progresses to produce significant external ophthalmoplegia in patients with longer disease history (Bang et al., 2004; Martin et al., 1999). These alterations

may precede cerebellar and retinal manifestations and are among the earliest signs of the disease (Oh et al., 2001). In addition, some cases have difficulties to initiate the saccadic eye movements and may develop gaze evoked nystagmus (Miller et al., 2009; Manrique et al., 2009).

3.6 Spinocerebellar ataxia type 17 (SCA17)

The patients with SCA17 show hypometric saccades in correspondence with the marked reduction of Purkinje cells in the cerebellum (Hubner et al., 2007). The saccadic hypometria is increased with disease duration but neither with ataxia score nor the number of CAG repeats. In 26% of cases, there are transient saccadic decelerations and accelerations causing hypometric saccades with multiple steps. Clinical assessments have reported normal (Nakamura, 2001) or slowed saccades (Rolfs et al., 2003), although the hypometria or prematurely terminated saccades may conduce to the erroneous classification of slowed saccades. In these patients, the saccadic latency is normal, while antisaccades have a significant increase in the error rate (Hubner et al., 2007).

Smooth pursuit abnormalities in SCA17 patients include decrease of initial eye acceleration, which appears even in the asymptomatic and mildly affected SCA17 mutation carriers, reduced steady state velocity and prolongation of smooth pursuit latency. Smooth pursuit gain decreases with the disease duration and ataxia score, whereas the latency prolongation correlates positively with the ataxia score. Gaze-evoked nystagmus is not a prominent feature in SCA17 patients (Hubner et al., 2007).

3.7 Other spinocerebellar ataxias

With the exception of polyglutamine expansions SCAs, the oculomotor function of remaining SCAs has not been systematically studied while most of data result for clinical assessment. SCA5 is characterized by eye abnormalities owing to cerebellar impairments such as downbeat nystagmus and impaired smooth pursuit movements (Ranum et al., 1994; Ikeda et al., 2002). Similar features occur in SCA8, in addition to saccadic dysmetria (Day et al., 2000; Koob et al., 1999), and SCA10 (Zu et al., 2000; Grewal et al., 2002; Lin & Ashizawa, 2005). SCA11 is associated with horizontal and vertical nystagmus as well as jerky pursuit (Worth et al., 1999), while approximately one third of SCA12 patients can develop saccadic slowing, abnormal smooth pursuits or pathological nystagmus (Worth et al., 1999; Fujigasaki et al., 2001). Besides, in subjects affected with SCA13 is usual to observe horizontal nystagmus (Stevanin et al., 2005; Waters & Pulst, 2008).

Regarding SCA14, the main oculomotor disturbance is the hypermetria of downgaze and horizontal saccades, even from the early stages of the disease. Additionally, upwards gaze evoked nystagmus are common in patients with longer disease duration. Smooth pursuit movements and VOR are also impaired (Yamashita et al., 2000; Brkanac et al., 2002a; Fahey et al., 2005). Eye movement abnormalities of SCA15/16 and SCA18 include nystagmus for all these SCA subtypes associated to saccadic dysmetria in the first one (Miyoshi et al., 2001; Brkanac et al., 2002b; Gardner et al., 2005). In addition, hypermetric saccades into downgaze and lateral gaze are detected in some patients with SCA20 (Knight et al., 2004).

SCA22 patients show nystagmus and impaired smooth pursuit with intermittent corrective saccadic (Chung et al., 2003), while in SCA23 the ocular dysmetria and slowed saccades can

be noted (Verbeek et al., 2004; Verbeek, 2009). SCA25, SCA26 and SCA27 are characterized by pathological nystagmus in some patients, associated with slow eye movements in SCA25, abnormal pursuit in SCA26 and saccadic dysmetria in SCA27 (van Swieten, et al., 2003; Stevanin et al. 2004; Yu et al., 2005). SCA28 patients develop gaze-evoked nystagmus at early disease, while subjects with advanced disease have slowed saccades and ophthalmoparesis with frequency estimates of 60% and 80% respectively (Cagnoli et al., 2006). SCA29, which overlap with SCA15, is characterized by bilateral horizontal nystagmus (Dudding et al., 2004). In the case of SCA30, hypermetric saccades and gaze evoked nystagmus can be detected (Storey et al., 2009), as well as abnormal pursuit in SCA31 (Ishikawa et al., 2004). Finally, in a new SCA subtype recently identified by Wang et al., 2010 in two Chinese families, it was observed ocular dysmetria as main oculomotor sign.

4. Conclusions

Eye movement abnormalities are among the most common phenotypic manifestations of patients with SCAs. The most prominent oculomotor feature is the presence of pathological nystagmus in almost all subtypes, which is generally associated to abnormal smooth pursuit, saccadic dysmetria, impaired VOR/OKR, saccadic slowing and ophthalmoplegia. These oculomotor phenotypes are useful, but not determinant, for the differential diagnosis of SCAs. For example, the early and severe saccadic slowing with rare pathological nystagmus distinguishes SCA2 from SCA1, SCA3, SCA6, SCA17 and other SCA subtypes, whereas the marked abnormalities of smooth pursuit, VOR and OKR; in association with pathological nystagmus and rare saccadic slowing may help to define a SCA6 phenotype. Nevertheless, the notable overlapping of oculomotor features between SCA subtypes implies the requirement of other clinical criteria or the genetic testing for sensitively discriminating among these diseases.

The study of eye movement abnormalities allows the identification of several biomarkers useful in the clinical and research practice of SCAs. Some of the oculomotor disturbances precede the ataxia onset, being important preclinical markers to detect the early stages of the neurodegenerative process, to evaluate the genetic susceptibility of the asymptomatic relatives and to identify individuals close to ataxia onset for enrollment in preventive clinical trials and as potential outcome variables in these same trials. As most of the oculomotor abnormalities of SCAs are significantly accentuated with the advance of the disease, these can be used in monitoring clinical progression and therefore to assess the response to symptomatic treatments at short, medium or long term. The number of CAG repeats influences significantly on the saccadic slowing in SCA2 and the reduced VOR gain in SCA3 classifying these oculomotor features as sensitive biomarker of genetic damage, useful to evaluate the effect of modifying factors and therapeutic alternatives on the polyglutamine toxicity.

Despite the above, still is necessary to deep more into the study of oculomotor function in SCAs. For example, vergence movements have not been studied, in spite of the known role of the cerebellum in these eye movements (Robinson & Fuchs, 2001) and the correspondent vergence deficits in patients with circumscribed cerebellar lesions (Sender et al., 2009). Moreover, further neuropathological, imaging and transcranial magnetic stimulation studies are required to focus the oculomotor system in order to provide more

insight on eye movement abnormalities and its potential role as therapeutic biomarkers in SCAs.

5. Acknowledgements

We are very indebted to Cuban Ministry of Public Health and to the Iberoamerican Multidisciplinary Network for the Movement Disorders Study: Parkinson disease and Spinocerebellar Ataxias. (RIBERMOV, abbreviation in Spanish).

6. References

- Aw ST, Haslwanter T, Halmagyi GM, Curthoys IS, Yavor RA & Todd MJ. (1996). Three-dimensional vector analysis of the human vestibuloocular reflex in response to high-acceleration head rotations. I. Responses in normal subjects. *Journal of Neurophysiology*, Vol.76, pp. 4009-20, ISSN 1522-1598.
- Bahill AT, Clark MR & Stark L. (1975) The main sequence, a tool for studying human eye movements. *Mathematical Biosciences*, Vol.24, pp. 191-204, ISSN 0025-5564.
- Bang OY, Lee PH, Kim SY, Kim HJ & Huh K. (2004). Pontine atrophy precedes cerebellar degeneration in spinocerebellar ataxia 7: MRI-based volumetric analysis. *Journal of Neurology Neurosurgery and Psychiatry*, Vol.75, No.10, pp. 1452-6, ISSN 1468-330X.
- Bour LJ, van Rootselaar AF, Koelman JH & Tijssen MA. (2008). Oculomotor abnormalities in myoclonic tremor: a comparison with spinocerebellar ataxia type 6. *Brain*, Vol.131, pp. 2295-303, ISSN 1460-2156.
- Brkanac Z, Bylenok L, Fernandez M, Matsushita M, Lipe H, Wolff J, et al. (2002a). A new dominant spinocerebellar ataxia linked to chromosome 19q13.4-qter. *Archives of Neurology*, Vol.59, No.8, pp. 1291-95, ISSN 1538-3687.
- Brkanac Z, Fernandez M, Matsushita M, Lipe H, Wolff J, Bird TD & Raskind WH. (2002b). Autosomal dominant sensory/motor neuropathy with Ataxia (SMNA): Linkage to chromosome 7q22-q32. *American Journal of Medical Genetics*, Vol.114, No.4, pp. 450-57, ISSN 0148-7299.
- Bruce CH & Friedman HR. (2002). Eye Movements. *Encyclopedia of the Human Brain*, Vol. 2, pp. 269-97.
- Burk K, Fetter M, Abele M, Laccone F, Brice A, Dichgans J, et al. (1999). Autosomal dominant cerebellar ataxia type I: oculomotor abnormalities in families with SCA1, SCA2, and SCA3. *Journal of Neurology*, Vol.246, No.9, pp. 789-97, ISSN 0340-5354.
- Buttner JA, Geschwind D, Jen JC, Perlman S, Pulst SM & Baloh RW.(1998). Oculomotor phenotypes in autosomal dominant ataxias. *Archives of Neurology*, Vol.55, No.10, pp. 1353-7, ISSN 1538-3687.
- Buttner-Ennever JA, Wadia NH, Sakai H & Schwendeman G. (1985) Neuroanatomy of oculomotor structures in olivopontocerebellar atrophy (OPCA) patient with slow saccades. *Journal of Neurology*, Vol.232, Suppl 285, ISSN 0340-5354
- Cancel G, Durr A, Didierjean O, Imbert G, Burk K, Lezin A, et al. (1997). Molecular and clinical correlations in spinocerebellar ataxia 2: a study of 32 families. *Human Molecular Genetics*, Vol.6, No.5, pp. 709-15, ISSN 1460-2083.
- Cagnoli C, Mariotti C, Taroni F, Seri M, Brussino A, Michielotto C, et al. (2006). SCA28, a novel form of autosomal dominant cerebellar ataxia on chromosome 18p11.22-q11.2. *Brain*. Vol.129, pp. 235-42, ISSN 1460-2156.

- Carlson KM, Andresen JM & Orr HT. (2009). Emerging pathogenic pathways in the spinocerebellar ataxias. *Current Opinion in Genetics & Development*, Vol.19, No.3, pp. 247-53, ISSN 1879-0380.
- Christova P, Anderson JH & Gomez C. (2008). Impaired Eye Movements in Presymptomatic Spinocerebellar Ataxia Type 6. *Archives of Neurology*, Vol.65, No.4, pp. 530-6, ISSN 1538-3687.
- Chung MY, Lu YC, Cheng NC & Soong BW. (2003). A novel autosomal dominant spinocerebellar ataxia (SCA22) linked to chromosome 1p21-q23. *Brain*, Vol.126, Pp. 1293-1299, ISSN 0006-8950.
- Colen C, Ketko A, George E & Van Stavern G. (2008). Periodic alternating nystagmus and periodic alternating skew deviation in spinocerebellar ataxia type 6. *Journal of Neuro-Ophthalmology*, Vol.28, pp. 287-88, ISSN 1536-5166.
- Day JW, Schut LJ, Moseley ML, Durand AC & Ranum LP. (2000). Spinocerebellar ataxia type 8: clinical features in a large family. *Neurology*, Vol.55, No.5, pp.649-57, ISSN 1474-547X.
- Dudding TE, Friend K, Schofield PW, Lee S, Wilkinson IA & Richards RI. 2004. Autosomal dominant congenital non-progressive ataxia overlaps with the SCA15 locus. *Neurology*, Vol. 63, pp. 2288-2292, ISSN 0028-3878.
- Durr A, Smadja D, Cancel G, Lezin A, Stevanin G, Mikol J, et al. (1995). Autosomal dominant cerebellar ataxia type I in Martinique (French West Indies). Clinical and neuropathological analysis of 53 patients from three unrelated SCA2 families. *Brain*, Vol.118, pp.1573-81, ISSN 1460-2156.
- Durr A. (2010). Autosomal dominant cerebellar ataxias: polyglutamine expansions and beyond. *Lancet Neurology*, Vol.9, pp. 885-94, ISSN 1474-4422.
- Estrada R, Galarraga J, Orozco G, Nodarse A & Auburger G. (1999). Spinocerebellar ataxia 2 (SCA2): morphometric analyses in 11 autopsies. *Acta Neuropathologica*, Vol.97, No.3, pp. 306-10, ISSN 1432-0533.
- Fahey MC, Knight MA, Shaw JH, McK Gardner RJ, du Sart D, Lockhart PJ, et al. (2005). Spinocerebellar ataxia type 14: study of a family with an exon 5 mutation in the PRKCG gene. *Journal of Neurology, Neurosurgery and Psychiatry*, Vol.76, pp. 1720-22, ISSN 1468-330X.
- Federighi P, Cevenini G, Dotti MT, Rosini F, Pretelegiani E, Federico A, et al. (2011). Differences in saccade dynamics between spinocerebellar ataxia 2 and late-onset cerebellar ataxias. *Brain*, Vol.134, pp. 879-91, ISSN 1460-2156.
- Fernández-Ruiz J, Velásquez-Pérez L, Díaz R, Drucker-Colín R, Pérez-González R, et al. (2007). Prism adaptation in spinocerebellar ataxia type 2. *Neuropsychologia*, Vol.45, pp. 2692-98, ISSN 0028-3932.
- Fujigasaki H, Verma IC, Camuzat A, Margolis RL, Zander C, Lebre AS, et al. (2001). SCA12 is a rare locus for autosomal dominant cerebellar ataxia: a study of an Indian family. *Annals of Neurology*, Vol.49, pp.117-21, ISSN 0364-5134.
- Gardner RJ, Knight MA, Hara K, Tsuji S, Forrest SM & Storey E. (2005). Spinocerebellar ataxia type 15. *The Cerebellum*, Vol.4, No.1, pp. 47-50, ISSN 1473-4230.
- Geiner S, Horn AK, Wadia NH, Sakai H & Buttner-Ennever JA. (2008). The neuroanatomical basis of slow saccades in spinocerebellar ataxia type 2 (Wadia-subtype). *Progress in Brain Research*, Vol.171, pp. 575-81. ISSN 1875-7855.
- Gierga K, Burk K, Bauer M, Orozco G, Auburger G, Schultz C, et al. (2005). Involvement of the cranial nerves and their nuclei in spinocerebellar ataxia type 2 (SCA2). *Acta Neuropathologica*, Vol.109, pp. 617-31, ISSN 1432-0533.

- Grewal RP, Achari M, Matsuura T, et al. (2002). Clinical features and ATTCT repeat expansion in spinocerebellar ataxia type 10. *Archives of Neurology*, Vol.59, pp. 1285–90, ISSN 1538-3687.
- Harding AE. (1983). Classification of the hereditary ataxias and paraplegias. *The Lancet*, Vol.1, pp. 1151–55, ISSN 1474-547X.
- Hikosaka O, Takikawa Y & Kawagoe R. (2000). Role of the basal ganglia in the control of purposive saccadic eye movements. *Physiological Reviews*, Vol.80, No.3, pp. 953-78, ISSN 0031-9333.
- Holmes SE, O'Hearn EE, McInnis MG, Gorelick-Feldman DA, Kleiderlein JJ, Callahan C, et al. (1999). Expansion of a novel CAG trinucleotide repeat in the 5' region of PPP2R2B is associated with SCA12. *Nature Genetics*, Vol.23, pp.391-92, ISSN 1061-4036.
- Hubner J, Sprenger A, Klein C, Hagenah J, Rambold H, Zuhlke C, et al. (2007). Eye movement abnormalities in spinocerebellar ataxia type 17 (SCA17). *Neurology*, Vol.69, No.11, pp. 1160-8, ISSN 0028-3878.
- Ikeda Y, Dick KA, Weatherspoon MR, Gincel D, Armbrust KR, Dalton JC et al. (2006). Spectrin mutations cause spinocerebellar ataxia type 5. *Nature Genetics*, Vol.38, pp. 184–90, ISSN 1061-4036.
- Ishikawa K, Toru S, Tsunemi T, Li M, Kobayashi K, Yokota T, et al. (2005). An autosomal dominant cerebellar ataxia linked to chromosome 16q22.1 is associated with a single-nucleotide substitution in the 5' untranslated region of the gene encoding a protein with spectrin repeat and Rho guanine-nucleotide exchange-factor domains. *American Journal of Human Genetics*, Vol.77, No.2, pp. 280-96, ISSN 0002-9297.
- Jardim LB, Pereira ML, Silveira I, Ferro A, Sequeiros J & Giugliani R. (2001). Neurologic findings in Machado-Joseph disease: relation with disease duration, subtypes, and (CAG)n. *Archives of Neurology*, Vol.58, No.6, pp. 899-904, ISSN 1538-3687.
- Karatas M. (2009). Internuclear and supranuclear disorders of eye movements: clinical features and causes. *European Journal of Neurology*, Vol.16, pp.1265–77, ISSN 1468-1331.
- Kim JM, Lee JY, Kim HJ, Kim JS, Kim YK, Park SS, et al. (2010). The wide clinical spectrum and nigrostriatal dopaminergic damage in spinocerebellar ataxia type 6. *Journal of Neurology, Neurosurgery and Psychiatry*, Vol.81, pp. 529–32, ISSN 1468-330X.
- Klostermann W, Zuhlke C, Heide W, Kompf D & Wessel K. (1997). Slow saccades and other eye movement disorders in spinocerebellar atrophy type 1. *Journal of Neurology*, Vol.244, No.2, pp.105-11, ISSN 0340-5354.
- Knight MA, Gardner RJ, Bahlo M, Matsuura T, Dixon JA, Forrest SM, et al. (2004). Dominantly inherited ataxia and dysphonia with dentate calcification: spinocerebellar ataxia type 20. *Brain*, Vol.127, No. 5, pp. 1172–81, ISSN 1460-2156.
- Koob MD, Moseley ML, Schut LJ, Benzow KA, Bird TD, Day JW, et al. (1999). An untranslated CTG expansion causes a novel form of spinocerebellar ataxia (SCA8). *Nature Genetics*, Vol.21, pp. 379–84, ISSN 1061-4036.
- Kremlacek J, Valis M, Masopust J, Talab R, Kuba M, Kobova Z, et al. (2011). An Electrophysiological Study of Visual Processing in Spinocerebellar Ataxia Type 2 (SCA2). *The Cerebellum*, Vol.10, pp. 32–42, ISSN 1473-4230.
- Kulkarni SA & Wadia NH. (1975) Model of an oculomotor subsystem. *International Journal of Biomedical Computation*, Vol6, pp. 1-21, ISSN 0020-7101.
- Le Pira F, Zappala G, Saponara R, Domina E, Restivo DA, Regio E, et al. (2002). Cognitive findings in spinocerebellar ataxia type 2: Relationship to genetic and clinical variables *Journal of the Neurological Sciences*, Vol.201, pp. 53–7, ISSN 0022-510X.

- Leigh RJ & Kennard C. (2004). Using saccades as a research tool in the clinical neurosciences. *Brain*, Vol.127, pp. 460-77, ISSN 1460-2156.
- Leigh RJ & Zee DS. (2006). *The neurology of eye movements* (4th Ed), Oxford University Press, New York, USA.
- Lencer R & Trillenberg P. (2008). Neurophysiology and neuroanatomy of smooth pursuit in humans. *Brain and Cognition*, Vol.68, pp. 219-28, ISSN 1090-2147.
- Lin X & Ashizawa T. (2005). Recent progress in spinocerebellar ataxia type-10 (SCA10). *The Cerebellum*, Vol. 4, pp. 37-42, ISSN 1473-4230.
- Matilla-Dueñas A, Goold R & Giunti P. (2008) Clinical, genetic, molecular, and pathophysiological insights into spinocerebellar ataxia type 1. *The Cerebellum*, Vol. 7 pp. 106-114, ISSN 1473-4222.
- Manrique RK, Noval S, Aguilar-Amat MJ, Arpa J, Rosa I & Contreras I. (2009). Ophthalmic Features of Spinocerebellar Ataxia Type 7. *Journal of Neuro-Ophthalmology*, Vol.29, pp. 174-9, ISSN 1536-5166.
- Martin J, Van Regemorter N, Del-Favero J, Lofgren A & Van Broeckhoven C. (1999). Spinocerebellar ataxia type 7 (SCA7) - correlations between phenotype and genotype in one large Belgian family. *Journal of the Neurological Sciences*, Vol.168, No.1, pp. 37-46, ISSN 0022-510X.
- Miller R, Tewari A, Miller J, Garbern J & Van Stavern GP. (2009). Neuro-ophthalmologic features of spinocerebellar ataxia type 7. *Journal of Neuro-Ophthalmol*, Vol.29, pp. 180-86, ISSN 1536-5166.
- Miura K & Optican LM. (2006). Membrane channel properties of premotor excitatory burst neurons may underlie saccade slowing after lesions of omnipause neurons. *Journal of Computational Neuroscience*, Vol.20, pp.25-41, ISSN 1573-6873.
- Miyoshi Y, Yamada T, Tanimura M, Taniwaki T, Arakawa K, Ohyagi Y, et al. (2001). A novel autosomal dominant spinocerebellar ataxia (SCA16) linked to chromosome 8q22.1-24.1. *Neurology*, Vol.57, No.1, pp. 96-100, ISSN 1526-632X.
- Müri RM & Nyffeler T. (2008) Neurophysiology and neuroanatomy of reflexive and volitional saccades as revealed by lesion studies with neurological patients and transcranial magnetic stimulation (TMS). *Brain and Cognition*, Vol.68, pp. 284-292, ISSN 1090-2147.
- Mustari MJ, Ono S & Das VE. (2009) Signal Processing and Distribution in Cortical-Brainstem Pathways for Smooth Pursuit Eye Movements. *Annals of New York Academy of Sciences*, Vol.1164, pp. 147-154, ISSN 0077-8923.
- Nakamura K. (2001). SCA17, a novel polyglutamine disease caused by the expansion of polyglutamine tracts in TATA-binding protein. *Rinsho Shinkeigaku*, Vol.41, pp. 1123-25.
- Oh AK, Jacobson KM, Jen JC & Baloh RW. (2001). Slowing of voluntary and involuntary saccades: an early sign in spinocerebellar ataxia type 7. *Annals of Neurology*, Vol.49, No.6, pp. 801-4, ISSN 1531-8249.
- Orozco DG, Estrada R, Perry T, Araña J & Fernández R. (1989). Dominantly inherited olivopontocerebellar atrophy from eastern Cuba. Clinical, neuropathological and biochemical findings. *Journal of the Neurological Sciences*, Vol.93, pp. 37-50, ISSN 0022-510X.
- Pierrot-Deseilligny C, Mileab D & Müri RM. (2004). Eye movement control by the cerebral cortex. *Current opinion in neurology*, Vol.17, pp. 17-25, ISSN 1350-7540.
- Prsa M. & Their P. (2011) The role of the cerebellum in saccadic adaptation as a window into neural mechanisms of motor learning. *European Journal of Neuroscience*, Vol.33, pp. 2114-2128, ISSN 0953-816X.

- Pula JH, Gomez CM & Kattah JC. (2010). Ophthalmologic features of the common spinocerebellar ataxias. *Current Opinion in Ophthalmology*, Vol.21, No.6, pp. 447-53, ISSN 1531-7021.
- Ramat S, Leigh RJ, Zee DS & Optican LM. (2007). What clinical disorders tell us about the neural control of saccadic eye movements. *Brain*, Vol.130, pp. 10-35, ISSN 1460-2156.
- Ranum LP, Schut LJ, Lundgren JK, Orr HT & Livingston DM. (1994). Spinocerebellar ataxia type 5 in a family descended from the grandparents of President Lincoln maps to chromosome 11. *Nature Genetics*, Vol. 8, pp. 280-84, ISSN 1061-4036.
- Reilly JL, Lencer R, Bishop JR, Keedy S & Sweeney JA. (2008). Pharmacological treatment effects on eye movement control. *Brain and Cognition*, Vol.68, pp. 415-35, ISSN 1090-2147.
- Rivaud-Pechoux S, Durr A, Gaymard B, Cancel G, Ploner CJ, Agid Y, et al. (1998). Eye movement abnormalities correlate with genotype in autosomal dominant cerebellar ataxia type I. *Annals of Neurology*, Vol.43, pp. 297-302, ISSN 1531-8249.
- Robinson FR & Fuchs AF. (2001). The role of the cerebellum in voluntary eye movements. *Annual Review of Neuroscience*, Vol.24, pp. 981-1004, ISSN 1545-4126.
- Rodríguez Díaz JC, Velázquez-Pérez L, Sanchez Cruz G, Almaguer Gotay D, Rodríguez Labrada R, Aguilera Rodríguez R, et al. (2008). Evaluation of Neurological Restoration in patients with Spinocerebellar Ataxia type 2. *Plasticidad & Restauración Neurológica*, Vol.7, pp. 13-8.
- Rodríguez-Labrada R; Velázquez-Pérez L; Seigfried C; Canales-Ochoa N; Auburger G; Medrano-Montero J; et al. (2011a). Saccadic latency is prolonged in Spinocerebellar Ataxia type 2 and correlates with the frontal-executive dysfunctions. *Journal of the Neurological Sciences*, Vol.306, pp. 103-07, ISSN 0022-510X.
- Rodríguez-Labrada R, Velázquez-Pérez L, Canales Ochoa N, et al. (2011b). Subtle Rapid Eye Movement sleep abnormalities in presymptomatic Spinocerebellar Ataxia type 2 gene carriers. *Movement Disorders*, Vol.26, pp. 347-50, ISSN 1531-8257.
- Rolfs A, Koeppen AH, Bauer I, Bauer P, Buhlmann S, Topka H, et al. (2003). Clinical features and neuropathology of autosomal dominant spinocerebellar ataxia (SCA17). *Annals of Neurology*, Vol.54, pp. 367-75, ISSN 1531-8249.
- Rüb U, Brunt ER, Gierga K, Schultz C, Paulson H, de Vos RA, et al. (2003). The nucleus raphe interpositus in spinocerebellar ataxia type 3 (Machado-Joseph disease). *Journal of Chemical Neuroanatomy*, Vol.25, No.2, pp.115-27, ISSN 0891-0618.
- Rüb U, Jen JC, Braak H & Deller T. (2008). Functional neuroanatomy of the human premotor oculomotor brainstem nuclei: insights from postmortem and advanced in vivo imaging studies. *Experimental Brain Research*, Vol.187, pp. 167-80, ISSN 0014-4819.
- Rufa & Federigh. (2011) Fast versus slow: different saccadic behaviour in cerebellar ataxias. In Basic and Clinical Ocular Motor and Vestibular Research. Rucker J & Zee DS, Eds. *Annals of the New York Academy of Sciences*, Vol.1233, pp. 148-154. ISSN 0077-8923.
- Sander T, Sprenger A, Neumann G, Machner B, Gottschalk S, Rambold H, et al. (2009). Vergence deficits in patients with cerebellar lesions. *Brain*, Vol.132, pp. 103-15, ISSN 1460-2156.
- Schmitz-Hübsch T, Coudert M, Bauer P, Giunti P, Globas C, Baliko L, et al. (2008). Spinocerebellar ataxia types 1, 2, 3, and 6: disease severity and nonataxia symptoms. *Neurology*, Vol.71, pp. 982-989, ISSN 1526-632X.

- Seifried C, Velazquez-Perez L, Santos-Falcon N, Abele M, Ziemann U, Almaguer LE, et al. (2005). Saccade velocity as a surrogate disease marker in spinocerebellar ataxia type 2. *Annals of New York Academy of Sciences*, Vol.1039, pp. 524-7, ISSN 0077-8923.
- Shires J, Joshi S & Basso MA. (2010). Shedding new light on the role of the basal ganglia-superior colliculus pathway in eye movements. *Current Opinion in Neurobiology*, Vol.20, pp. 1-9, ISSN 0959-4388.
- Soong BW & Paulson HL. (2007). Spinocerebellar ataxias: an update. *Current Opinion in Neurology*, Vol.20, No.4, pp. 438-46, ISSN 1350-7540.
- Sparks DL. (2002). The brainstem control of saccadic eye movements. *Nature Reviews Neuroscience*, Vol.3, No.12, pp. 952-64, ISSN 1471-0048.
- Stevanin G, Bouslam N, Thobois S, Azzedine H, Ravaux L, Boland A, et al. (2004). Spinocerebellar ataxia with sensory neuropathy (SCA25) maps to chromosome 2p. *Annals of Neurology*, vol.55, No.1, pp. 97-104, ISSN 0364-5134.
- Stevanin G, Durr A, Benammar N & Brice A. (2005). Spinocerebellar ataxia with mental retardation (SCA13). *The Cerebellum*, Vol.4, No.1, pp. 43-46, ISSN 1473-4222.
- Storey E, Bahlo M, Fahey M, Sisson O, Lueck CJ & Gardner RJ. (2009). A new dominantly inherited pure cerebellar ataxia, SCA 30. *Journal of Neurology Neurosurgery and Psychiatry*, Vol.80, pp. 408-11, ISSN 1468-330X.
- Strupp M, Hübner K, Sandmann R, Zwergal A, Dieterich M, Jahn K, et al. (2011). Central Oculomotor Disturbances and Nystagmus. A Window Into the Brainstem and Cerebellum. *Deutsches Ärzteblatt International*, Vol.108, No.12, pp. 197-204.
- Thurtell MJ, Tomsak RL & Leigh RJ. (2007). Disorders of saccades. *Current neurology and neuroscience reports*, Vol.7, No.5, pp. 407-16, ISSN 1528-4042.
- Tusa R. & D. Zee. (1989). Cerebral control of smooth pursuit and optokinetic nystagmus. *Current Opinion in Ophthalmology*. Vol.2, pp. 115-146, ISSN 1531-7021.
- Vale J, Bugalho P, Silveira I, Sequeiros J, Guimaraes J & Coutinho P. (2010). Autosomal dominant cerebellar ataxia: frequency analysis and clinical characterization of 45 families from Portugal. *European Journal of Neurology*, Vol.17 pp. 124-28, ISSN 1468-1331.
- van Swieten JC, Brusse E, de Graaf BM, Krieger E, van de Graaf R, de Koning I, et al. (2003). A mutation in the fibroblast growth factor 14 gene is associated with autosomal dominant cerebellar ataxia [corrected]. *American Journal of Human Genetics*, Vol.72, No.1, pp. 191-99, ISSN 0002-9297.
- Velázquez L (2008). *Ataxia Espinocerebelosa tipo 2. Principales aspectos neurofisiológicos para el diagnóstico y pronóstico de la Enfermedad*, (2nd Ed), Ediciones Holguín, ISBN 959-221-202-3, Holguín, Cuba.
- Velazquez Perez L, Cruz GS, Santos Falcon N, Enrique Almaguer Mederos L, Escalona Batallan K, Rodríguez Labrada R, et al. (2009a). Molecular epidemiology of spinocerebellar ataxias in Cuba: insights into SCA2 founder effect in Holguin. *Neuroscience Letters*, Vol.454, No.2, pp. 157-60, ISSN 0304-3940.
- Velazquez-Perez L, Seifried C, Abele M, Wirjatijasa F, Rodriguez-Labrada R, Santos-Falcon N, et al. (2009b). Saccade velocity is reduced in presymptomatic spinocerebellar ataxia type 2. *Clinical Neurophysiology*, Vol.120, No.3, pp. 632-35, ISSN 1388-2457.
- Velazquez-Perez L, Seifried C, Santos-Falcon N, Abele M, Ziemann U, Almaguer LE, et al. (2004). Saccade velocity is controlled by polyglutamine size in spinocerebellar ataxia 2. *Annals of Neurology*, Vol.56, No.3, pp. 444-47, ISSN 1531-8249.
- Velázquez-Pérez L, Rodríguez-Chanfrau J, García-Rodríguez JC, Sánchez-Cruz G, Aguilera-Rodríguez R, et al. (2011a). Oral Zinc Sulphate Supplementation for Six Months in

- SCA2 Patients: A Randomized, Double-Blind, Placebo-Controlled Trial. *Neurochemical Research*, In press, ISSN 1573-6903.
- Velázquez-Pérez L, Voss U, Rodríguez-Labrada R, Auburger G, Canales Ochoa N, Sánchez Cruz G, Galicia Polo L, et al. (2011b). Sleep Disorders in Spinocerebellar Ataxia Type 2 Patients. *Neurodegenerative Diseases*, Vol.8; pp. 447-454, ISSN 1660-2862.
- Verbeek DS, van de Warrenburg BP, Wesseling P, Pearson PL, Kremer HP & Sinke RJ. (2004). Mapping of the SCA23 locus involved in autosomal dominant cerebellar ataxia to chromosome region 20p13-12.3. *Brain*, Vol.127, pp. 2551-57, ISSN 1460-2156.
- Verbeek DS. (2009). Spinocerebellar ataxia type 23: a genetic update. *The Cerebellum*, Vol.8, No.2, pp. 104-07, ISSN 1473-4222.
- Vilis, T. (1997). Physiology of three-dimensional eye movements: saccades and vergence. In *Three-Dimensional Kinematics of Eye, Head, and Limb Movements* (M. Fetter, T. Haslwanter, H. Misslisch, and D. Tweed, Eds.), pp. 57-72. Harwood Academic Publishing, Amsterdam.
- Voogd J, Schraa-Tam CKL, van der Geest JN & De Zeeuw CI. (2011) Visuomotor Cerebellum in Human and Nonhuman Primates. *The Cerebellum*, In press, ISSN 1473-4222.
- Wadia NH & Swami RK. (1971) A new form of heredo-familial spinocerebellar degeneration with slow eye movements (nine families). *Brain*, Vol.94, pp. 359-374, ISSN 1460-2156.
- Wadia N, Pang J, Desai J, Mankodi A, Desai M & Chamberlain S. (1998). A clinicogenetic analysis of six Indian spinocerebellar ataxia (SCA2) pedigrees. The significance of slow saccades in diagnosis. *Brain*, Vol.121, pp. 2341-55, ISSN 1460-2156.
- Wang JL, Yang X, Xia K, Hu ZM, Weng L, Jin X, et al. (2010). TGM6 identified as a novel causative gene of spinocerebellar ataxias using exome sequencing. *Brain*, Vol.133, pp. 3510-18, ISSN 1460-2156.
- Waters MF & Pulst SM. (2008). Sca13. *The Cerebellum*, Vol.7, No.2, pp. 165-169, ISSN 1473-4222.
- Worth PF, Giunti P, Gardner-Thorpe C, et al. (1999). Autosomal dominant cerebellar ataxia type III: linkage in a large British family to a 7.6-cM region on chromosome 15q14-21.3. *American Journal of Human Genetics*, Vol.65, No.2, pp. 420-26, ISSN 0002-9297.
- Yamashita I, Sasaki H, Yabe I, Fukazawa T, Nogoshi S, Komeichi K, et al. (2000). A novel locus for dominant cerebellar ataxia (SCA14) maps to a 10.2-cM interval flanked by D19S206 and D19S605 on chromosome 19q13.4-qter. *Annals of Neurology*, Vol.48, No.2, pp. 156-163, ISSN 0364-5134.
- Ying SH, Choi SI, Perlman SL, Baloh RW, Zee DS & Toga AW. (2006). Pontine and cerebellar atrophy correlate with clinical disability in SCA2. *Neurology*, Vol.66, No.3, pp. 424-426, ISSN 1526-632X.
- Yu GY, Howell MJ, Roller MJ, Xie TD & Gomez CM. (2005). Spinocerebellar ataxia type 26 maps to chromosome 19p13.3 adjacent to SCA6. *Annals of Neurology*, Vol.57, No.3, pp. 349-54, ISSN 0364-5134.
- Zee DS, Yee RD, Cogan DG, Robinson DA & Engel WK. (1976). Ocular motor abnormalities in hereditary cerebellar ataxia. *Brain*, Vol.99, pp. 207-234, ISSN 1460-2156.
- Zee DS & Levi L. (1989) Neurological aspects of vergence eye movements. *Revista de Neurologia (Paris)*, Vol.145, No.8-9, pp. 613-2.
- Zu L, Figueroa KP, Grewal R & Pulst SM. (1999). Mapping of a new autosomal dominant spinocerebellar ataxia to chromosome 22. *American Journal of Human Genetics*, Vol.64, pp. 594-599, ISSN 0002-9297.



Spinocerebellar Ataxia

Edited by Dr. José Gazulla

ISBN 978-953-51-0542-8

Hard cover, 198 pages

Publisher InTech

Published online 18, April, 2012

Published in print edition April, 2012

The purpose of this book has been to depict as many biochemical, genetic and molecular advances as possible, in the vast field of the spinocerebellar ataxias.

How to reference

In order to correctly reference this scholarly work, feel free to copy and paste the following:

Roberto Rodríguez-Labrada and Luis Velázquez-Pérez (2012). Eye Movement Abnormalities in Spinocerebellar Ataxias, Spinocerebellar Ataxia, Dr. José Gazulla (Ed.), ISBN: 978-953-51-0542-8, InTech, Available from: <http://www.intechopen.com/books/spinocerebellar-ataxia/eye-movement-abnormalities-in-spinocerebellar-ataxias>

INTECH
open science | open minds

InTech Europe

University Campus STeP Ri
Slavka Krautzeka 83/A
51000 Rijeka, Croatia
Phone: +385 (51) 770 447
Fax: +385 (51) 686 166
www.intechopen.com

InTech China

Unit 405, Office Block, Hotel Equatorial Shanghai
No.65, Yan An Road (West), Shanghai, 200040, China
中国上海市延安西路65号上海国际贵都大饭店办公楼405单元
Phone: +86-21-62489820
Fax: +86-21-62489821

© 2012 The Author(s). Licensee IntechOpen. This is an open access article distributed under the terms of the [Creative Commons Attribution 3.0 License](https://creativecommons.org/licenses/by/3.0/), which permits unrestricted use, distribution, and reproduction in any medium, provided the original work is properly cited.

IntechOpen

IntechOpen