

# We are IntechOpen, the world's leading publisher of Open Access books Built by scientists, for scientists

6,900

Open access books available

186,000

International authors and editors

200M

Downloads

Our authors are among the

154

Countries delivered to

TOP 1%

most cited scientists

12.2%

Contributors from top 500 universities



WEB OF SCIENCE™

Selection of our books indexed in the Book Citation Index  
in Web of Science™ Core Collection (BKCI)

Interested in publishing with us?  
Contact [book.department@intechopen.com](mailto:book.department@intechopen.com)

Numbers displayed above are based on latest data collected.  
For more information visit [www.intechopen.com](http://www.intechopen.com)



# Superior Mesenteric Artery Syndrome

Rani Sophia and Waseem Ahmad Bashir  
*Yeovil Hospital NHS Foundation Trust, Yeovil, Somerset  
 United Kingdom*

## 1. Introduction

Superior mesenteric artery syndrome (SMAS) mostly occurs in adolescent or young adults and is a rare disorder. The syndrome was first described by the Von Rokitansky in 1842 and since then about 400 cases has been reported in literature but SMAS is not well recognised and often diagnosed late till the patients are far advanced with their symptoms (Geer 1990, Raissi et al 1996). In general population the incidence with the help of upper gastrointestinal barium studies were reported to be around 0.013-0.3 % (Ylinen et al 1989). However after the scoliosis surgery the prevalence was reported to be in range of 0.5-4.7 % (Tsirikos, Jeans 2005). Geer (1990) reported that 75% of the cases occurred in patients aged between 10-30 years. In a large series of 75 patients it was reported that two third of the cases were women and one third men and the average age was around 40 years (Wilkie 1927). The morbidity caused by this syndrome and the difficulty in diagnosing it prompted this review, and at the same time it will also act as a fresh reminder for the clinicians.

## 2. Anatomy and pathology

The superior mesenteric artery (SMA) originates behind the neck of the pancreas at the level of the first lumbar vertebra and leaves the aorta at an acute angle. It forms an angle of approximately 45° with the abdominal aorta. The third part duodenum crosses caudal to the origin of superior mesenteric artery (SMA), coursing between SMA and aorta just inferior to the left renal vein from right to left (Fig 1). Any factor that sharply narrows the aortomesenteric angle from approximately 45° (range between 38-56°) to 6-25° will thus reduce the aortomesenteric distance to about 2-8mm (Hines et al 1984, Neri et al 2005). The mean radiographic aortomesenteric distance is 10-28 mm (Neri et al 2005). This can cause entrapment and compression of the third part of duodenum. Thus conditions such as loss of mesenteric and retroperitoneal fat and subsequent decrease of the aortomesenteric distance can cause SMAS.

## 3. Causes

- In elderly patients heavily calcified or tortuous aorta can cause SMAS.
- Other causes reducing the aortomesenteric angle are:
- Severe cachexia or catabolic states such as weight loss due to neoplasia, anorexia nervosa
- Severe head injuries or prolonged bed rest or severe burns
- Bariatric surgery or Nissan fundoplication, spinal scoliosis surgery
- Spinal deformities or trauma

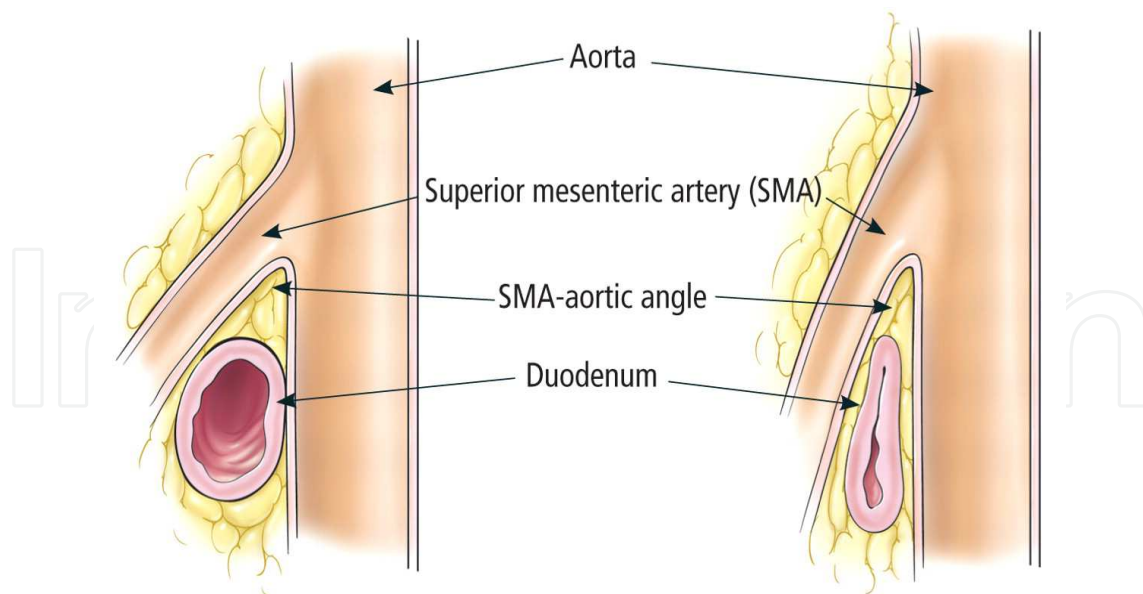


Fig. 1. Left, the normal angle between the superior mesenteric artery (SMA) and the aorta is 25 to 60 degrees. Right, in SMA syndrome, the SMA-aortic angle is more acute, and the duodenum is compressed between the aorta and the SMA (Reproduced with permission from Pasumarthy et al (2010) *Cleveland Clinic Journal of Medicine*. 77:45-50)

- Anatomic or congenital anomalies as high insertion of the ligament of Treitz, Intestinal malrotation, peritoneal adhesions and low origin of the superior mesenteric artery

#### 4. Symptoms and signs

The most common symptom in these patients is intermittent abdominal pain and copious vomiting. The abdominal pain can be postprandial and the nausea, vomiting can lead to anorexia and weight loss. Early satiety, eructations, and at times sub-acute small bowel obstruction can develop. The symptoms are relieved when patient lies in left lateral decubitus, prone or knee-to-chest position (Geer 1990, Wilkie 1927, Raissi et al 1996). They are often aggravated by in an asthenic patient in supine position. Examination of the abdomen may reveal a succussion splash. Peptic ulcer disease is found in 25-45% of the patients and hyperchlohydria in 50 % ( Geer 1990, Ylinen et al 1989). Dilated duodenum and stomach could predispose a patient to aspiration pneumonia and acute gastric rupture.

#### 5. Diagnosis

To diagnose a patient with SMAS traditionally barium meal studies with hypotonic duodenography is being used. A positive diagnosis will include duodenal dilatation, retention of barium within duodenum, the classical vertical linear impression caused by extrinsic pressure in the third part of duodenum and frequent relief of obstruction in left lateral or decubitus position (Tsirikos , Jeans 2005, Raissi et al 1996). In the past angiographic measurement of the aortomesenteric angle was thought to be a gold standard. An aortomesenteric angle of  $< 22-25^\circ$  and a distance of  $< 8$  mm correlated well with symptoms of SMAS (Hines et al 1984). Because of its invasive nature, Computed tomography (CT) scan or CT angiogram/MR angiogram have taken over as a gold standard (Tsirikos , Jeans 2005,

Lee, Mangla 1978). CT or CT angiogram is also superior to ultrasound because it can measure the reduced aortomesenteric angle and show the gastric and duodenal dilatation at the same time. CT scan will also be helpful in finding the cause of SMAS e.g high insertion of ligament of Trietz or a neoplasia in that region. Upper gastrointestinal endoscopy is essential to rule out mechanical outlet obstruction of stomach or an ulcer (Ylinen et al 1989, Raissi et al 1996).

## 6. Treatment

If there is a neoplasm causing SMAS, anatomic or congenital abnormality then the treatment is surgical, otherwise this condition is treated conservatively. Patients are fed frequent small meals orally or if it is not possible then through enteral jejunal tube. After feeding the patient, he/she should be placed in either prone or lateral decubitus position. If patient cannot tolerate tube feeding because of excessive vomiting then he/she needs to be fed parentally. Both ways of feeding have shown to be effective (Barnes, Lee 1996). This conservative treatment should aim to correct the fluid and electrolyte balance and increase the body weight in an attempt to increase the retroperitoneal fat so that the aortomesenteric angle is corrected.

Surgical treatment is indicated if conservative treatment fails or if there is severe progressive weight loss, pronounced duodenal dilatation with stasis and complicating peptic ulcer disease. Several surgical procedures have been tried and tested in the management of SMAS. Gastrojejunostomy, duodenojejunostomy, Strong's operation (duodenal mobilisation for lowering the duodenojejunal flexure) have been performed to treat this condition. Gastrojejunostomy and lysis of the ligament of Treitz provided adequate decompression of the stomach but was not helpful in overcoming the duodenal obstruction and at times leading to blind loop syndrome with reflux of bile necessitating duodenojejunostomy (Lee, Mangla 1978). A review of 146 cases showed that duodenojejunostomy was the treatment of the choice (Lee, Mangla 1978) and success rate was 90 % (Raissi et al 1996). Recently laparoscopic duodenojejunostomy has become treatment of choice. Massoud (1995) reported his experience of laparoscopic division of the ligament of Treitz in 4 cases. It was successful in 3 cases. Gerson and Heniford (1998) reported first laparoscopic duodenojejunostomy and then further cases were reported in the literature (Richardson, Surowiec 2001). Minimally invasive surgery with less operative time, quick post operative recovery and relief of the symptoms were the advantages over traditional duodenojejunostomy.

## 7. Conclusion


SMAS is a rare disorder and is under-diagnosed in our practice of medicine. It should be ruled out in the patients with postprandial abdominal pain, vomiting and weight loss. It is caused by compression of the third part of duodenum by the narrowed aortomesenteric angle. There are different predisposing factors but severe weight loss and cachexia, spinal deformities and congenital anomalies are some of them. SMAS is treated initially conservatively but laparoscopic duodenojejunostomy has high success rate as well.

## 8. References

Barnes JB, Lee M (1996) Superior mesenteric artery syndrome in an intravenous drug abuser after rapid weight loss. *South Med J*. 89: 331-334.

- Geer D (1990) Superior mesenteric artery syndrome. *Mil Med.* 155:321-3
- Gersin KS, Heniford BT (1998) Laparoscopic duodenojejunostomy for treatment of superior mesenteric artery syndrome. *JSLs.* 2: 281-284.
- Hines JR, Gore RM, Ballantyne GH (1984) Superior mesenteric artery syndrome. Diagnostic criteria and therapeutic approaches. *Am J Surg.* 148: 630-632.
- Lee CS, Mangla JC (1978) Superior mesenteric artery compression syndrome. *Am J Gastroenterol.* 70: 141-150.
- Massoud WZ (1995) Laparoscopic management of superior mesenteric artery syndrome. *Int Surg.* 80: 322- 27.
- Neri S, Signorelli SS, Mondati E, Pulvirenti D, Campanile E, Di Pino L, Scuderi M, Giustolisi N, Di Prima P, Mauceri B, Abate G, Cilio D, Misseri M, Scuderi R: (2005) Ultrasound imaging in diagnosis of superior mesenteric artery syndrome. *J intern Med.* 257: 346-351.
- Raissi B, Taylor B, Traves D (1996) Recurrent mesenteric artery (Wilkie's) syndrome: a case report. *Can J Surg.* 39: 410-6.
- Richardson WS, Surowiec WJ (2001) Laparoscopic repair of superior mesenteric artery syndrome. *Am J Surg.* 181: 377-78.
- Tsirikos AL, Jeans LA (2005) Superior mesenteric artery syndrome in children and adolescents with spine deformities undergoing corrective surgery. *J Spinal Disord Tec.* 18:263-271.
- Wilkie DPD (1927) Chronic duodenal ileus. *Am J Med Sci.* 173: 643-9
- Ylinen P, Kinnunen J, Hockerstedt K (1989) Superior mesenteric artery syndrome. *J Clin Gastroenterol.* 11: 386-91

IntechOpen



### **New Advances in the Basic and Clinical Gastroenterology**

Edited by Prof. Tomasz Brzozowski

ISBN 978-953-51-0521-3

Hard cover, 546 pages

**Publisher** InTech

**Published online** 18, April, 2012

**Published in print edition** April, 2012

The purpose of this book was to present the integrative, basic and clinical approaches based on recent developments in the field of gastroenterology. The most important advances in the pathophysiology and treatment of gastrointestinal disorders are discussed including; gastroesophageal reflux disease (GERD), peptic ulcer disease, irritable bowel disease (IBD), NSAIDs-induced gastroenteropathy and pancreatitis. Special focus was addressed to microbial aspects in the gut including recent achievements in the understanding of function of probiotic bacteria, their interaction with gastrointestinal epithelium and usefulness in the treatment of human disorders. We hope that this book will provide relevant new information useful to clinicians and basic scientists as well as to medical students, all looking for new advancements in the field of gastroenterology.

#### **How to reference**

In order to correctly reference this scholarly work, feel free to copy and paste the following:

Rani Sophia and Waseem Ahmad Bashir (2012). Superior Mesenteric Artery Syndrome, New Advances in the Basic and Clinical Gastroenterology, Prof. Tomasz Brzozowski (Ed.), ISBN: 978-953-51-0521-3, InTech, Available from: <http://www.intechopen.com/books/new-advances-in-the-basic-and-clinical-gastroenterology/superior-mesenteric-artery-syndrome>

**INTECH**  
open science | open minds

#### **InTech Europe**

University Campus STeP Ri  
Slavka Krautzeka 83/A  
51000 Rijeka, Croatia  
Phone: +385 (51) 770 447  
Fax: +385 (51) 686 166  
[www.intechopen.com](http://www.intechopen.com)

#### **InTech China**

Unit 405, Office Block, Hotel Equatorial Shanghai  
No.65, Yan An Road (West), Shanghai, 200040, China  
中国上海市延安西路65号上海国际贵都大饭店办公楼405单元  
Phone: +86-21-62489820  
Fax: +86-21-62489821

© 2012 The Author(s). Licensee IntechOpen. This is an open access article distributed under the terms of the [Creative Commons Attribution 3.0 License](https://creativecommons.org/licenses/by/3.0/), which permits unrestricted use, distribution, and reproduction in any medium, provided the original work is properly cited.

IntechOpen

IntechOpen