

We are IntechOpen, the world's leading publisher of Open Access books Built by scientists, for scientists

6,900

Open access books available

186,000

International authors and editors

200M

Downloads

Our authors are among the

154

Countries delivered to

TOP 1%

most cited scientists

12.2%

Contributors from top 500 universities



WEB OF SCIENCE™

Selection of our books indexed in the Book Citation Index
in Web of Science™ Core Collection (BKCI)

Interested in publishing with us?
Contact book.department@intechopen.com

Numbers displayed above are based on latest data collected.
For more information visit www.intechopen.com



The LNG-IUS: The First Choice Alternative to Hysterectomy?

Intrauterine Levonorgestrel-Releasing Systems for Effective Treatment and Contraception

D. Wildemeersch

Outpatient Gynaecological Clinic and IUD Training Center, Ghent, Belgium

1. Introduction

Hysterectomy (from Greek ὑστέρα *hystera* "womb" and εκτομία *ektomia* "a cutting out of") is the surgical removal of the uterus. Hysterectomy may be total (removing the body, fundus, and cervix of the uterus; often called "complete") or partial (removal of the uterine body while leaving the cervix intact; also called "supracervical"). It is the most commonly performed gynaecological surgical procedure although the incidence of hysterectomy varies widely across the world.¹ This is the case even when one considers only developed countries with comparable resources. In 2003, over 600,000 hysterectomies were performed in the United States alone, of which over 90% were performed for benign conditions.² In the USA a woman's life-time risk of hysterectomy is 25%, which compares to a much lower risk of 10.4% in Denmark.³ In England and Wales the hysterectomy rate in NHS hospitals is estimated at 28 per 10,000 women per annum.⁴ Even within each country, there are large regional variations.⁵ Such rates being highest in the industrialized world has led to the major controversy that hysterectomies are being largely performed for unwarranted and unnecessary reasons.

Oophorectomy is frequently done together with hysterectomy to decrease the risk of ovarian cancer. However, recent studies have shown that prophylactic oophorectomy without an urgent medical indication has serious consequences.⁶ Apart from the current occurrence of estrogen deficiency symptoms, women who are oophorectomized, particularly at an early age experience an increased risk of ischaemic heart disease as well as death from cardiovascular disease. Oophorectomy also leads to early loss of bone and an increased risk of osteoporotic fracture and may also be linked to impaired cognitive function. The impact on psychological health could also be substantial leading to long lasting anxiety, depression, loss of self-esteem and well-being and may also indirectly or directly give rise to problems of sexual function. This effect is not limited to pre-menopausal women; even women who have already entered menopause were shown to have experienced a decrease in long-term survivability post-oophorectomy.⁷

Hysterectomy and bilateral oophorectomy has surgical risks as well as long-term effects. So the surgery should normally be recommended only when other treatment options are not

available. However, it is expected that the frequency of hysterectomies for non-malignant indications will fall as there are good alternatives in many cases.⁸ As most of the hysterectomies are conducted for benign conditions, including fibroid disease, dysfunctional uterine bleeding, endometriosis, benign adnexal mass, pelvic relaxation/prolapse and chronic pelvic pain, many of these conditions can be effectively treated with alternative treatment modalities of which the LNG-IUS is probably the easiest, safest, most effective and most economical of the conservative alternatives of hysterectomy. In this chapter, a short review is given about these alternative treatments with special focus on current and future LNG-releasing systems.

2. Morbidity and mortality of hysterectomy

A multicenter study conducted in 102 hospitals in Canada evaluated the morbidity and mortality rates of laparoscopic, abdominal, and vaginal hysterectomy.⁹ One thousand seven hundred ninety-two women underwent hysterectomy for benign, nonobstetric indications. The overall hysterectomy-related morbidity rate was 6.1%. The rate of morbidity was higher in the laparoscopic supracervical hysterectomy (LASH) group (9.4%) than in the abdominal hysterectomy (AH) group (5.2%, $p < 0.01$), but no significant difference was noted between AH and vaginal hysterectomy (VH) (8.6%). The incidence of intraoperative bowel injury was 0.4% in the LASH group (a trocar injury in a patient) and 0.3% in the AH group. Bladder injury was encountered in two patients in the LASH group (0.9%) and in another two in the AH group (0.1%). Ureteral injury occurred in a patient in the AH group (0.07%). There were no cases of intraoperative vascular injury. Vaginal hysterectomy was associated with more urinary retention and hematoma formation than the other two groups. Discordant diagnosis was noted in four cases (two missed endometrial cancer, atonic and distended bladder mistaken for an ovarian cyst, and pelvic tuberculosis). The conversion rate to laparotomy was 1.7% in the LASH group and 0.4% in the VH group, and the incidence of reoperation was 0.4% in the AH group. It was concluded that besides the overall hysterectomy-related morbidity rate of 6.1%, compared with other types of hysterectomy, more urinary retention and hematoma formation occur after VH. LASH is associated with a higher morbidity rate than AH; mainly because of conversion to laparotomy and blood transfusion.

A review by Banu et al¹⁰ on the health outcomes following hysterectomy reports that hysterectomy is highly effective, resulting in high satisfaction rates^{11,12}, improvements in health-related quality-of-life measures^{13,14} and sexual functioning¹⁵, and of course a complete resolution of the menstrual disturbance without the possibility of recurrence. However, hysterectomy is a major operation which causes discomfort and considerable disability in the weeks following surgery¹⁶, has mortality rates in the range 0.38–1 per 1000^{17,18}, severe complications in 3% of women⁹, and minor morbidity (mainly fever and infection) in up to 30% women.

Hysterectomy is also thought to be associated with urinary incontinence many years after the operation¹⁹, and may cause early ovarian failure (and the consequences thereof).²⁰

These issues, including the high surgery and hospital cost implications²¹, have resulted in the search for effective alternatives.

3. Alternatives to hysterectomy in women with bleeding disorders and other gynaecological conditions

A Non-steroidal anti-inflammatory drugs

Mefenamic acid, and the antifibrinolytic agent tranexamic acid are effective treatments and are considered first-line treatment for menorrhagia.²² The efficacy of these treatments has been demonstrated in several randomized trials and reported in systematic reviews.^{23,24} Tranexamic acid reduces menstrual loss by about 50% and mefenamic acid by a third. Both drugs also relieve menstrual cramps.

B Systemically administered hormones

Cyclical progestogens given during the luteal phase of the cycle are ineffective, but are effective when given continuously for 21 days.²⁵ Side effects such as breakthrough bleeding, breast tenderness, weight gain, alteration in libido and depression reduce compliance. The additional contraceptive effect limits their use in women who wish to conceive. Where contraception is desired, the combined oral contraceptive pill appears to be a better choice for the treatment of menorrhagia. The hormones work by inhibiting the growth and development of the endometrium, thus significantly reducing blood loss.

C Locally administered hormones

The main focus of this section will be on the local administration of levonorgestrel (LNG) using an intrauterine drug delivery system (IUS) as LNG is a potent progestogen with many advantages.²⁶ The progesterone-releasing intrauterine device (IUD) will not be discussed as the Progestasert® IUD is not commercialized anymore. The natural hormone is much weaker than LNG and, therefore, less suitable for the treatment purposes described in this paper.

Our research group has been involved in the clinical development of frameless and framed LNG-releasing intrauterine systems since 1997. Another chapter in this book focuses on the effect of these systems on menstrual blood loss in women with and without heavy menstrual bleeding or menorrhagia. This section will mainly focus on the differences between these novel devices compared to the Mirena® LNG-IUS (BayerSchering AG, Berlin, Germany). In addition, the use of the LNG-IUS will be discussed for the treatment of precancerous lesions of the endometrium, including early endometrial cancer of the endometrium, conditions that usually are treated by hysterectomy.

In order to be successful as a method for intrauterine treatment, the prerequisite is that the following conditions are met. The method should:

1. be easy and safe to apply
2. be well-tolerated and fit in cavities of every size and shape
3. be well retained
4. release a sufficient amount of active substance per day
5. preferably release a high dosage during the first few weeks to establish fast and profound suppression of the endometrium
6. be long-acting
7. have few side effects and
8. be easy to remove

a. Comparison between Femilis® LNG-IUS and Mirena® LNG-IUS

Figure 1 depicts both intrauterine systems. The design of Femilis® is slimmer with shorter crossarms and thinner stem than Mirena®. Both release a similar amount of LNG (20 µg/day) except for the first weeks whereby comparative in vitro release studies showed that the release rate of Femilis® is approximately 2 to 3 times higher. Femilis® and Mirena® have a duration of action of at least 5 years.




Fig. 1. Femilis® LNG-IUS.

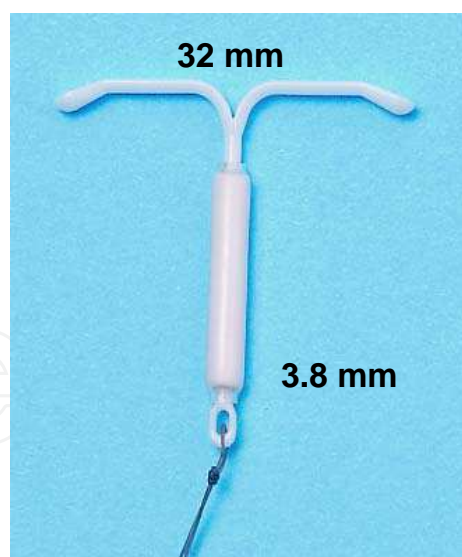


Fig. 2. Mirena® LNG-IUS

The difference in design is important as it has a bearing on the easiness and safety of the insertion procedure as well as on the acceptability and retention of the LNG-IUS.

As Femilis® is significantly smaller than Mirena®, it is suitable for parous as well as nulliparous women. Women with narrow, but not too narrow, uterine cavities tolerate the LNG-IUS. Figure 3 shows the blister package of Femilis® with uterine sound.



Fig. 3. Blister package with Femilis® inserter and uterine sound.

Figure 4 illustrates the insertion procedure of the Femilis® IUS and Figure 5 the insertion procedure of the Mirena® LNG-IUS.

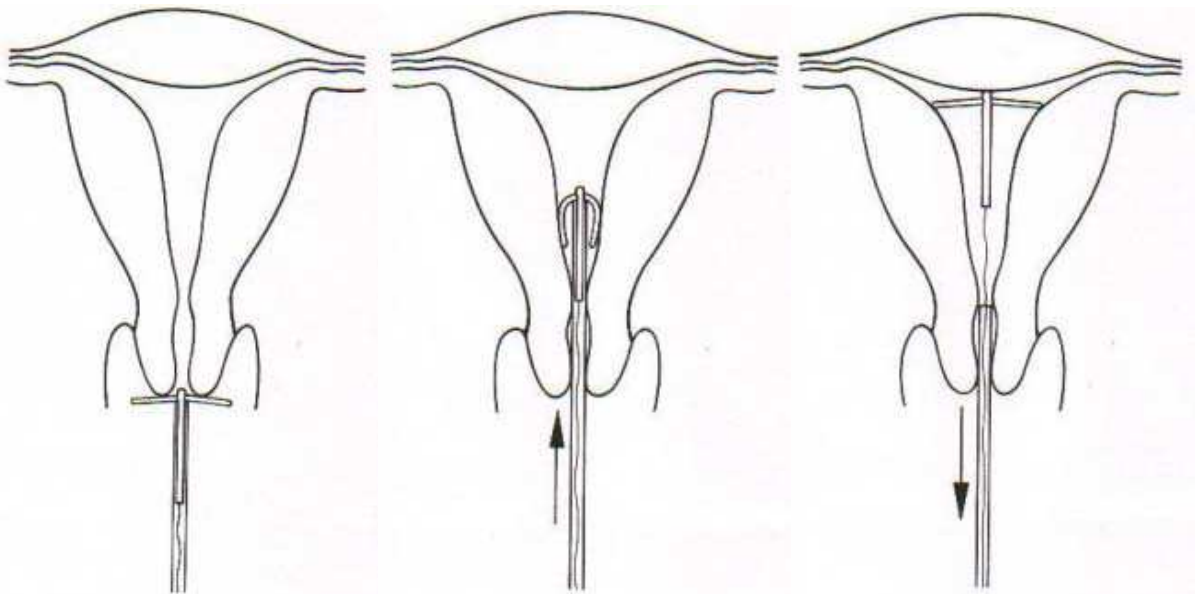


Fig. 4. Insertion of Femilis®. The applicator is positioned against the cervix (left) and pushed into the uterine cavity (middle) until its front end reaches the fundus (right). The inserter tube is then removed and the thread is trimmed at 2 cm from the cervix. Note: During insertion the sidearms unfold protecting against perforation.

Uterine cavities differ considerably in size and shape, and the uterus is subject to changes in size and volume during the menstrual cycle.^{27,28} These changes are most pronounced at the time of menses. These individual variations in size and shape of the human uterus are probably greater than variations of the human foot (H.M. Hasson). Research has shown that if the width of the uterine cavity is too small, side effects and complications are likely to occur. The crossarms of standard T-shaped IUDs are frequently too long for a large number of uterine cavities, as the average transverse diameter of the uterine cavity in the majority of women is smaller than the span of the crossarms of the IUD. The average transverse

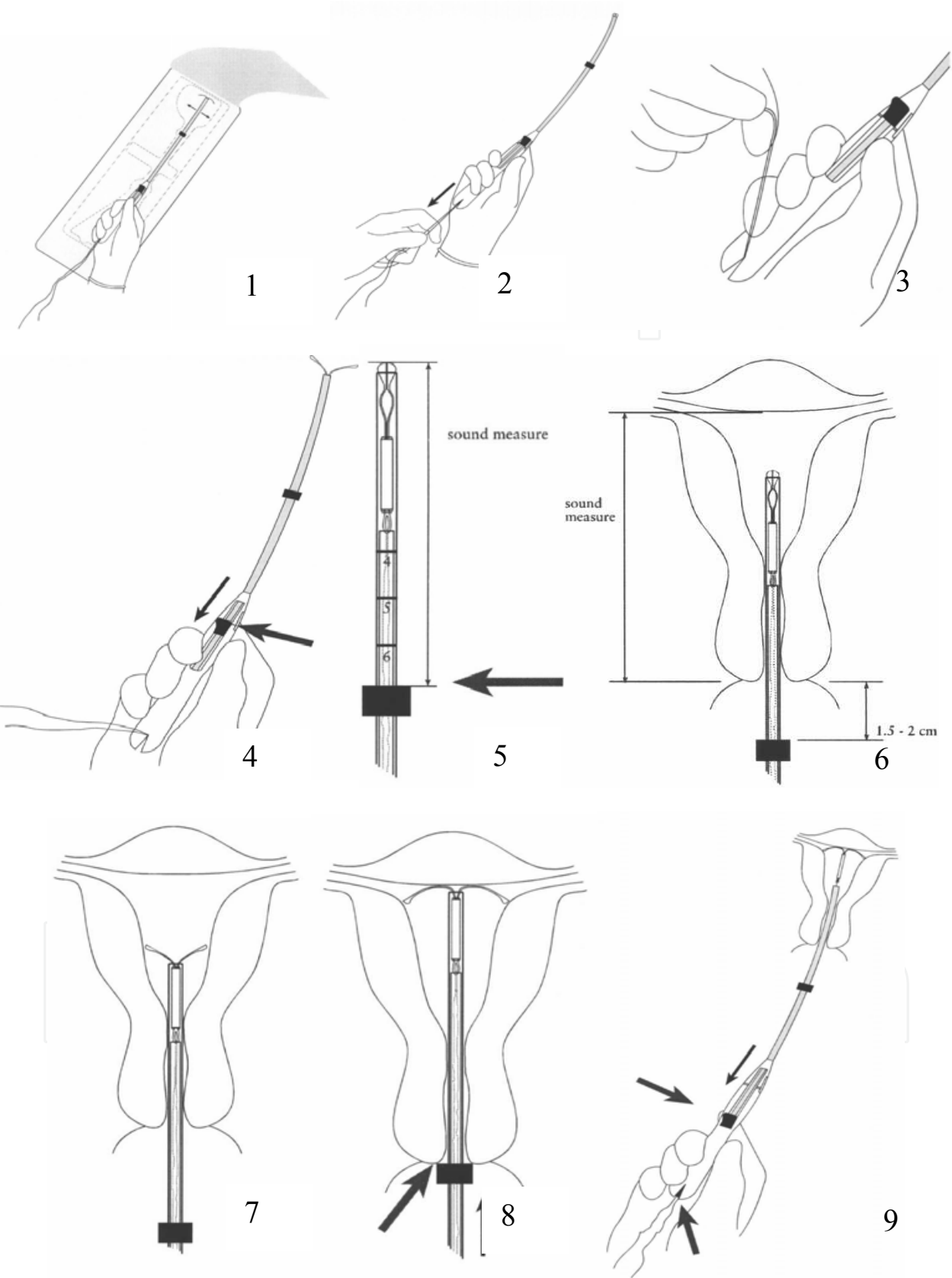


Fig. 5. Insertion of Mirena®: **1)** The package is opened and the shaft of the insertion instrument is grasped as shown. The arms of the IUS should be in horizontal position

(adjustment can be done on the sterile inner surface of the peel pack). **2)** The threads are now pulled until both knobs close the open end of the front end of the inserter. **3)** The thread is then fixed in the cleft at the end of the inserter. **4)** The sidearms of the IUS should be in the correct position as they should fold out horizontally. If not, open the arms by pulling the slider back to the raised mark on the shaft. Align the open arms on the sterile surface of the package and return the slider to its previous position. Check that the threads are still tight and that the arms have moved back into the inserter. **5)** Set the flange at a distance from the knobs corresponding to the uterine sound measure by using the scale marked on the insertion tube. Note that this measurement is from the end of the inserter to the top edge of the flange. **6)** Mirena® is now ready to be inserted. Hold the slider with the forefinger or thumb firmly in the most distal position. Move the inserter carefully through the cervical canal into the uterus until the flange is situated at a distance of about 1.5 – 2 cm from the cervix to give sufficient space for the arms to open. Do not force the inserter. **7)** While holding the inserter steady, release the arms of the IUS by pulling the slider back until it reaches the raised mark on the shaft. **8)** Holding the slider firmly, push the inserter gently inward until the flange touches the cervix. The IUS should now be at the fundus. **9)** Holding the inserter firmly in position, release the IUS by pulling the slider all the way back. Remove the inserter and cut the strings at 2 cm from the cervix.

diameter of the uterine cavity at the fundal level in nulliparous women between 15 and 34 years of age, as well as in many parous women, is much smaller than the length of the crossarms of most currently used T-shaped IUDs resulting in dimensional problems. The length of the crossarms of the Mirena® LNG-IUS is 32 mm. The average fundal transverse dimension in nulliparous as well as parous women is only around 25 to 27 mm. Recent 3-D sonography studies compared women with abnormally and those with normally located IUDs with respect to their indication for sonography and found that the proportion of patients whose principal indication for sonography was bleeding, pain or bleeding and pain were significantly greater in those with an abnormally located IUD, including imbedded IUDs, compared with those whose IUD was not located abnormally on 3-D sonography.^{29,30} It should be noted that standard 2-D sonography is not able to detect many abnormally located IUDs particularly with regard to abnormal location of the sidearms of the IUD. Accurate location of the sidearms is only possible by hysteroscopy and with 3-D coronal sonography, as shown in Figure 6. Due to the shorter crossarms of the Femilis® LNG-IUS it has been demonstrated in clinical trials that the IUS fits better in uterine cavities with small transverse dimensions. This indicates that side effects (e.g., pain, bleeding and expulsion) due to incompatibility can be avoided by reducing the length of the crossarms. IUDs that do not fit well contribute to early discontinuation.³¹ In addition, insertion of the Femilis® IUS is straightforward. Following uterine sounding, the IUS is simply pushed in the uterine cavity, up to the fundal wall. The ease and safety of this insertion technique was demonstrated in a multicenter clinical trial.^{32,33}

b. Use of the LNG-IUS in women with precancerous or early cancer of the endometrium

The use of the LNG-IUS as an alternative to hysterectomy for treatment of heavy menstrual bleeding was covered in another chapter in this book. Other uterine pathologies such as precancerous changes of the endometrium and even early endometrial cancer of the uterus can effectively be treated by the LNG-IUS. Our group evaluated the effect on endometrial

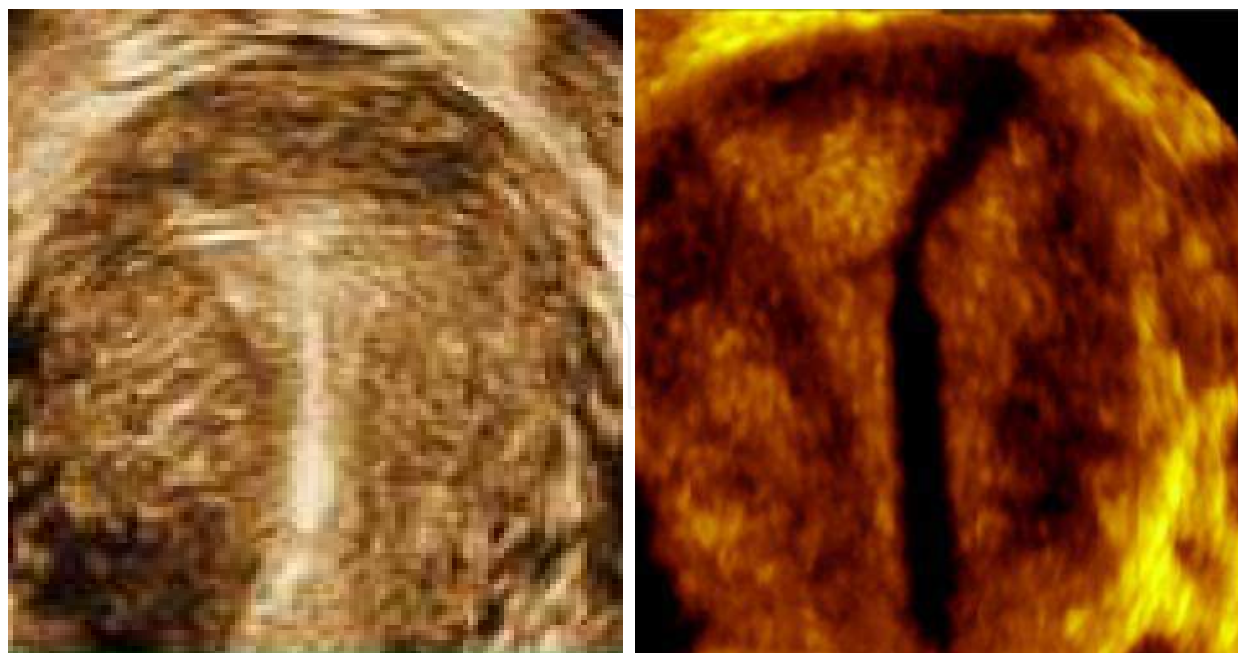


Fig. 6. Left: Femilis® fitting snugly in a small uterine cavity. Right: Mirena® showing unfolded and embedded crossarm due to incompatibility with the narrow uterine cavity.

non-atypical and atypical hyperplasia in 20 women. The aim of the study was to evaluate the long-term cure (remission) rate. All women in this small series developed a normal endometrium, except one asymptomatic woman with atypical hyperplasia who still had focal residual non-atypical hyperplasia at 3 years follow-up in the presence of a thin (<4 mm) endometrium. This patient is being followed-up on a regular basis. It was concluded that continuous intrauterine delivery of LNG appears to be a promising alternative to hysterectomy for the treatment of endometrial hyperplasia and could enhance the success rate when compared with other routes of progestogen administration as well as intrauterine progesterone delivery.³⁴ As many women with atypical hyperplasia harbour cancer cell, patients should be followed-up long-term and the endometrium should continuously kept suppressed with a LNG-IUS.

Two cases of early, respectively well- and moderately differentiated endometrial carcinoma were also effectively treated with the LNG-IUS. Below is the summarized report of one of these patients. The patient presented with minimal postmenopausal bleeding. An outpatient endometrial pipelle biopsy was performed which revealed a moderately differentiated adenocarcinoma (Figure 7) with minimal myometrial invasion (Clinical FIGO stage I).³⁵ An LNG-IUS (Femilis®) was inserted and advice was given to conduct a repeat biopsy within the next 3 to 6 months. Spotting continued for several weeks and then stopped. As the patient was completely free of symptoms 6 months after insertion of the LNG-IUS, a pelvic transvaginal ultrasound was performed, including a 3-D ultrasound. The uterus appeared completely normal, and there was no evidence of any pathology. The endometrium showed normal thickness, and there was no evidence of any endometrial abnormality or myometrial invasion. The LNG-IUS was identified in situ, as expected. Six months later, in order to ascertain complete remission, it was decided to remove the LNG-IUS and to perform a full D&C. The uterine sound length was 6 cm. The whole cavity was explored, and very scant tissue was removed. Histological examination of the specimen revealed a secretory

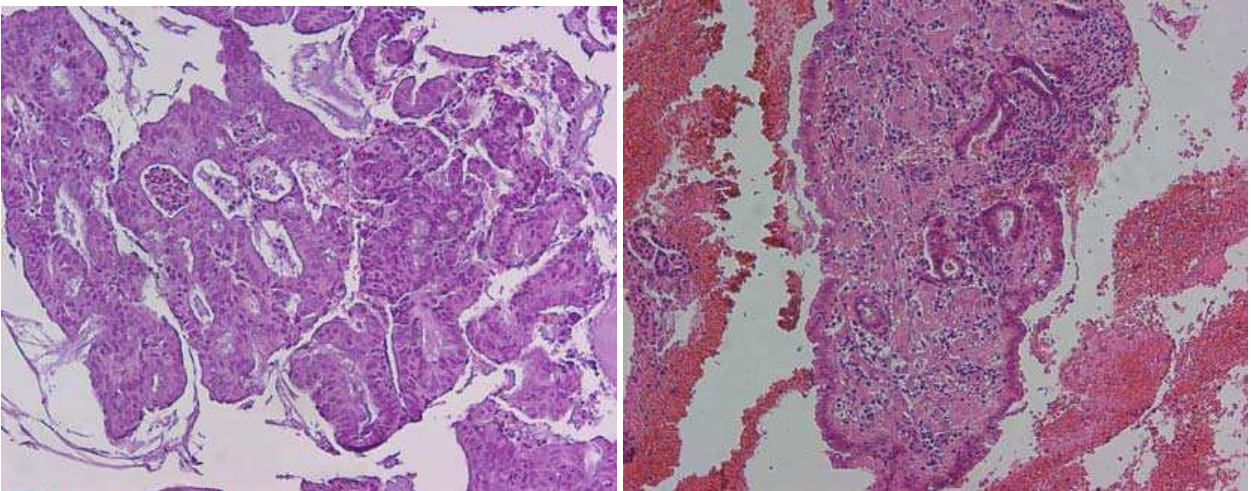


Fig. 7. Left: Endometrial curetting prior to therapy, irregular cribriform glands, and mild atypia: moderately-differentiated endometrioid carcinoma (H&E 100x). Right: Endometrial curetting post-therapy, small regular glands with tubal metaplasia, surrounded by decidualised stroma (H&E 100x).

endometrium without signs of hyperplasia or atypia (Figure 7). A new LNG-IUS was inserted as a precaution. The patient was again examined two years following initial treatment. She had no symptoms, and vaginal ultrasound showed a very thin endometrium and normal position of the LNG-IUS in the uterine cavity.

- c. Use of the LNG-IUS in women with primary or secondary dysmenorrhea, endometriosis/adenomyosis and chronic pelvic pain

Our group evaluated the effect of a frameless LNG-IUS releasing 14 µg of LNG/d (Figure 8) on menstrual pain in women with primary and secondary dysmenorrhea.

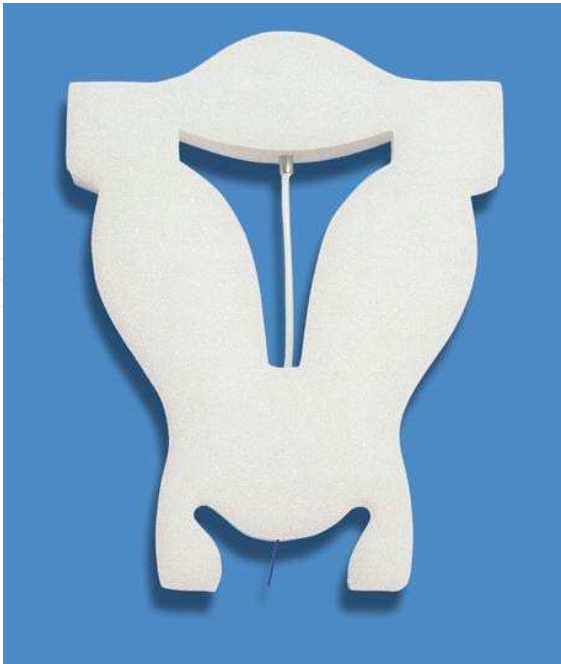

Fig. 8. The frameless FibroPlant® LNG-IUS

Eighteen insertions were performed in women between 16 and 52 years of age. Eight women were categorized as having primary and 10 having secondary dysmenorrhea. Twelve women complained of heavy bleeding. Two women had significant fibroids and three were suspected to have adenomyosis. All women, except one with significant fibroids, reported much reduced pain, no pain at all, or strongly reduced bleeding, which started as soon as one month after insertion of the frameless LNG-IUS. The results of this small study suggest that the LNG-IUS could be an effective method in women with primary or secondary dysmenorrhea, associated or not with excessive menstrual bleeding, and avoid surgery in many of them as both bleeding and pain are effectively treated with the LNG-IUS. An additional advantage is that the LNG-IUS is a potent contraceptive as well. The absence of a frame is particularly advantageous in these cases as it does not elicit uterine contractions.

Endometriosis affects almost 10–20% of women of reproductive age, while 70–90% of women with chronic pelvic pain (CPP), dysmenorrhea, dyspareunia, infertility and menstrual disturbances also have endometriosis, a disease that impairs patients' quality of life.³⁶ Many therapies are proposed. These include nonsteroidal anti-inflammatory drugs, antiestrogens, progestogens such as depot medroxyprogesterone acetate (DMPA), GnRH analogues to induce pseudo-menopause, androgen derivatives (danazol) and continuous combined oral contraceptives (COC) to induce pseudo-pregnancy. Medical treatments are based on the reduction of lesions or on ovarian estrogen suppression; however, adherence and long-term therapy continue to represent a challenge in the management of endometriosis. Because of the profound hypoestrogenism provoked by some of these drugs, bone mineral density is the principal concern that limits their use to 6 months, although longer treatment with add-back hormone therapy is possible. GnRH-a is also expensive and not readily available to women worldwide, especially in developing countries.

One of the options to treat these conditions, and alleviate the pain complaints, is the levonorgestrel-releasing intrauterine system. Bahamondes et al. recently reviewed the literature regarding the use of LNG-IUS (Mirena®) in women with endometriosis, adenomyosis, cyclic pelvic pain and dysmenorrhea.³⁷ They found that all studies reported an improvement in pelvic pain and dysmenorrhea, and a reduction in menstrual bleeding. One study found an improvement in the staging of the disease at 6 months of use, and the studies that evaluated the use of LNG-IUS in women with adenomyosis reported a reduction in uterine volume. Furthermore, the only study in which women were followed up for 3 years after insertion found improvement in pelvic pain at 12 months of use, but no improvement after that period. They concluded that the use of LNG-IUS is an alternative for the medical treatment of women suffering from endometriosis, adenomyosis, chronic pelvic pain or dysmenorrhea, but that experience is limited and long-term studies are necessary to reach definitive conclusions. Other authors came to the same conclusion.³⁸ However, for women who do not wish to become pregnant, this device offers the possibility of at least 5 years of treatment following one single intervention. It is to be expected that many of these women, without further fertility, could avoid surgical treatment which would be viewed as an enormous benefit for those concerned.

Given the above scientific evidence, it should be concluded that the LNG-IUS is effective for the treatment of the most frequently occurring gynaecological conditions for which gynaecologists are consulted. The use of local medical treatment has many advantages and should, therefore, be considered as the first line treatment before a surgical intervention.^{39,40} In a randomized trial comparing the LNG-IUS with hysterectomy, 42% in the LNG-IUS group subsequently underwent hysterectomy, and, thus, surgery and the associated risks

with surgery were avoided in 58% of the women. The number of hysterectomies for menorrhagia in England has fallen substantially to just over one third (36%) of the number of a decade ago (Figure 9).⁴¹ This trend can be explained by an increase in medical treatment as well as by the more widespread use of endometrial resection or ablation.

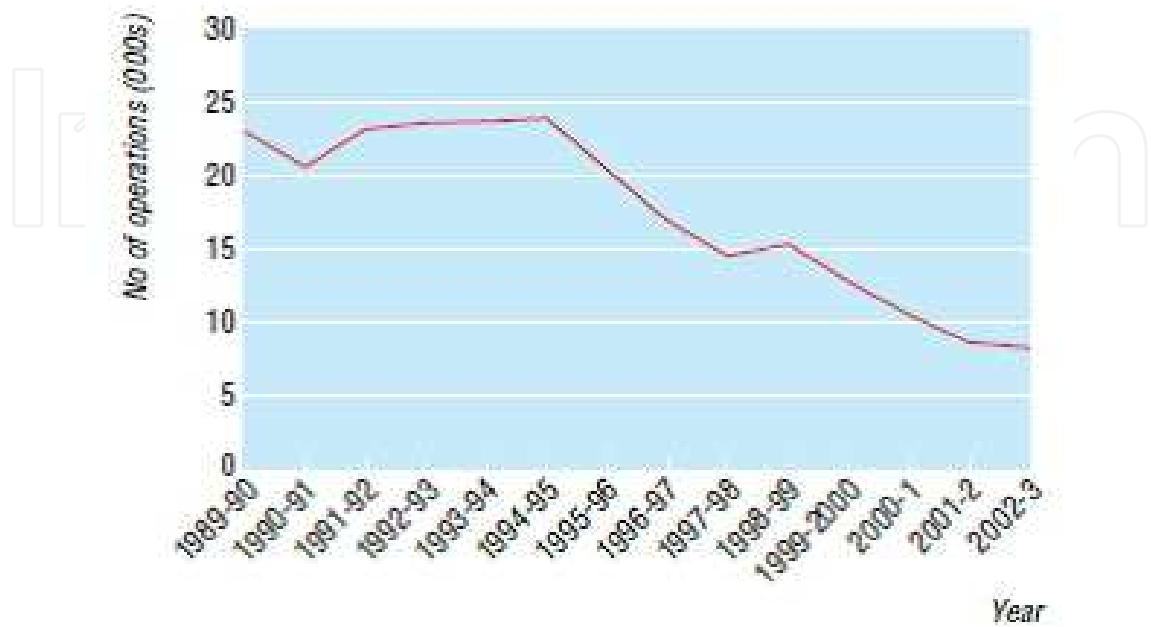


Fig. 9. Number of hysterectomies for menorrhagia from 1989-90 to 2002-3 in NHS trusts in England

Active education of good management of menorrhagia and promotion of effective medical management in primary care halves the number of referrals to secondary care. However, despite the strong evidence that medical treatments, in particular the LNG-IUS, are effective, many hysterectomies and endometrial ablations/resections are still performed annually without first evaluating medical treatment.³⁷

d. Health-related quality of life and cost of the LNG-IUS vs. hysterectomy

Hurskainen et al. (Finland) compared outcomes, quality-of-life issues, and costs of the LNG-IUS vs. hysterectomy in the treatment of menorrhagia.⁴² After 5 years of follow-up, 232 women (99%) were analyzed for the primary outcomes. The 2 groups did not differ substantially in terms of health-related quality of life (HRQL) or psychosocial well-being. Although 50 (42%) of the women assigned to the LNG-IUS group eventually underwent hysterectomy, the discounted direct and indirect costs in the LNG-IUS group (\$2817 [95% confidence interval, \$2222-\$3530] per participant) remained substantially lower than in the hysterectomy group (\$4660 [95% confidence interval, \$4014-\$5180]). Satisfaction with treatment was similar in both groups. Compared to other medications the LNG-IUS is much cheaper per menstrual cycle unless it is removed before 5 years. Long-term acceptability is therefore essential.⁴³

D Endometrial ablative techniques

In recent years various surgical techniques have been developed to ablate the endometrium. An excellent review on these techniques was recently published.¹⁰ The reader is therefore referred to this paper. It suffices to make some observations and conclusions.

The endometrial ablative techniques can be divided into two broad groups: the first-generation hysteroscopic endometrial ablation (HEA) procedures performed under direct vision, and the second-generation non-hysteroscopic endometrial ablation (NHEA) procedures which are largely ‘blind’. These techniques are mainly used to treat women with excessive menstrual bleeding. They are summarized in Table 1.

TECHNIQUE	ADVANTAGES	DISADVANTAGES
Hysteroscopic endometrial ablation (first generation)		
<u>Transcervical resection</u> of the endometrium (TCRE) utilizes an electrosurgical cutting loop	TCRE results in satisfactory reduction of menstrual loss in up to 90% of cases	These first-generation techniques require a general or regional anaesthetic, specialized surgical skill and often carry a small risk of perforation at the thin cornua, haemorrhage, fluid overload and infection Recurrence of menorrhagia or dysmenorrhoea and pelvic pain are principal reasons for further surgery The cost of the laser-photo-vaporization machine as well as the single-use laser fibre limits its more general application
<u>Transcervical rollerball</u> uses an electrosurgical rollerball to coagulate the tissues	The technique is significantly safer than hysterectomy	
<u>Laser photo-vaporization</u> uses a high-energy beam to destroy endometrial tissues	Rollerball endometrial ablation is the easiest technique to master and generally the quickest to perform. The risk of perforation is greatly diminished	
Non-hysteroscopic endometrial ablation (NHEA) (second generation)		
Cavatherm device Hydrothermablation ThermaChoice MenoTreat System VestaBlate HydroThermAblator NovaSure GyneLase MEA	These second-generation ‘less invasive’ techniques are designed to ablate the full thickness of the endometrium by the controlled application of heat, cold, microwave or other forms of energy The techniques are simpler and quicker to perform than hysteroscopic methods, while satisfaction rates and reduction in menstrual blood loss are high (up to 90%)	Women choosing one of these options need to be aware that they are likely to continue to experience some degree of menstrual bleeding and that further surgery may be necessary for persistent heavy bleeding The data on the safety of all the second generation techniques are as yet incomplete, but all systems appear to be associated with minimal complication rates

Table 1. Endometrial ablative techniques.

Myomectomy (laparoscopic, robotic assisted laparoscopic, vaginal, laparoscopic assisted vaginal, laparotomy)	
Advantages	Disadvantages
<ul style="list-style-type: none">-Overall results are 81% resolution of menorrhagia symptoms, with similar results for pelvic pressure symptoms-Laparoscopic approach to myomectomy is associated with a shorter postoperative recovery period, shorter hospital stay and cost-saving benefits-Robotic-assisted laparoscopic myomectomy could considerably reduce learning curve (Nisolle et al. 2011)-Vaginal myomectomy is only possible in selected cases-Combined approach renders haemostasis and uterine repair easier than by the laparoscopic approach alone	<ul style="list-style-type: none">-Only a limited range of fibroids is amenable to the laparoscopic approach-Risk of conversion to open myomectomy is 2-8%-Rupture of the pregnant uterus has been reported after laparoscopic myomectomy-Myomectomy performed via a laparotomy is associated with increased blood loss, operating time, pain, postoperative morbidity and longer hospital stay than hysterectomy, while an additional procedure (such as repeat myomectomy or hysterectomy) is necessary in 20–25% of women-Recurrence of fibroids following myomectomy occurs in up to 50%-Myomectomy carries a risk of postoperative pelvic adhesions
GnRH analogues in the management of uterine fibroids	
Advantages	Disadvantages
<ul style="list-style-type: none">-GnRH analogues prior to either hysterectomy or myomectomy has shown that uterine volume and size, as well as fibroid volume, were all reduced, as were pelvic symptoms-Hysterectomy is rendered easier, with reduced operating time, and a greater proportion of hysterectomy patients were able to have a vaginal rather than an abdominal procedure-Blood loss and rate of vertical incision were reduced for both myomectomy and hysterectomy-Duration of hospital stay was reduced	<ul style="list-style-type: none">-Disadvantages of GnRH analogues include cost, menopausal symptoms (but can be prevented by ‘add-back’ HRT) and, with prolonged therapy, bone demineralization-Some believe that benefits do not justify the costs-GnRH analogues render surgical planes less distinct, perhaps due to softening of the fibroids, which makes enucleation more difficult-Their use as primary therapy in younger women is questionable as fibroids re-grow to their original size within a few months of discontinuation of treatment

Uterine artery embolization (UAE)	
Advantages	Disadvantages
<ul style="list-style-type: none">-Clinical success rates are good with good fibroid shrinkage rates (10-70%) and symptom improvement (70-94%)-UAE is now widely practiced in Western Europe and North America, and the National Institute for Clinical Excellence (NICE) in the UK has decreed that it can be routinely offered as a primary treatment for uterine fibroids, although it is recommended that all procedures are registered-However, the fact remains that UAE has never been compared with conventional treatments in a prospective randomized controlled trial (RCT), as either a pilot or a full study-There is also a lack of long-term data	<ul style="list-style-type: none">-Complications secondary to arterial puncture, contrast injection, arterial catheterization and non-target-organ embolization are intrinsic to all embolization procedures, but are uncommon, and further minimized by operator experience and good technique-Chronic discharge is a frequent complication, affecting up to 7% of patients-Infections are also more common with larger fibroids-Fibroid extrusion occurs in about 10% of cases. Larger ones may necessitate a surgical procedure for removal, especially if impacted at the cervix-Clinical features of the so-called post-embolization syndrome include a flu-like illness, high temperature, high white cell count and a feeling of malaise, and may be due to release of cytokines and toxins from the ischaemic tissue. This might be difficult to differentiate from sepsis

Table 2. Summarizes these new approaches, their advantages and disadvantages (adapted from Banu et al.¹⁰).

A Cochrane review concluded that while short-term follow-up studies might indicate an advantage for endometrial ablation, longer-term studies show a narrowing of the gap, and hysterectomy appears to have consistently higher rates of satisfaction and better health-related quality-of-life outcomes.⁴⁴ A study conducted by Maia et al. is also worth mentioning in this respect.⁴⁵ They investigated 106 women with HMB. After endometrial resection, the women were randomized into two groups, 53 women in each. Women in the treatment group were fitted with Mirena®. In this group, amenorrhoea was achieved in 72% of cases after 3 months, in 89% after 6 months and in 100% after 1 year. In the resection-only group, the corresponding numbers were 19%, 17% and 9%, and in this group, 19% of the women underwent a second resection.

A second study by Maia et al. (CEPARH, Brazil) was recently reported at the World Congress on the Menopause (Abstract Book p. 74). Ninety-two perimenopausal women with menorrhagia, dysmenorrhea and premenstrual syndrome (PMS) were enrolled in this study. Sixty-two patients had adenomyosis and the remaining 30 had submucous and intramural myomas. The use of the LNG-IUS (Mirena®) following endometrial resection significantly increased amenorrhoea rates. The rate was 98% in the fifth year. Complete resolution of dysmenorrhea and PMS was reported by over 90% of patients. In historical controls submitted to endometrial resection, the amenorrhoea rate was only 20% with a failure rate of 40%. This study also showed an inhibition of the expression of aromatase in the ectopic glands in the myometrium of patients with adenomyosis, thereby contributing towards

interrupting the progression of the disease. This may explain why the rates of amenorrhoea are far superior to those achieved with endometrial resection alone. It was concluded that endometrial resection with LNG-IUS is a viable alternative to hysterectomy in perimenopausal women.

E. Alternative therapies for the management of fibromyomas

Uterine myoma (leiomyoma, fibromyoma, fibroid) is a very common disease. They are more common in certain ethnic populations, especially the Afro-Caribbean.⁴⁶ Leiomyomas occur with an incidence of up to 77%.⁴⁷ Fibroids can cause menorrhagia, pelvic pain/discomfort, and bladder and bowel compression symptoms. They are often asymptomatic but some 25-50% of women will experience symptoms such as menorrhagia and pelvic discomfort. About 5% of the fibroids are intracavitary and submucosal and are most difficult to treat.^{48,49} Hysterectomy is still the most commonly used procedure although medical treatments are preferable.^{50,51} Uterine fibroids are responsible for 30% of hysterectomies. Notwithstanding the success of radical surgery, it is not always desirable particularly in the younger woman desiring fertility. Also psychological factors play a role as the uterus has been regarded as a sexual organ, a source of energy and vitality, and a maintainer of youth and attractiveness. Many women, therefore, might wish to avoid a hysterectomy, even when their families are complete.

Recently, new conservative treatment options have been developed such as the treatment with GnRH analogs and the levonorgestrel-releasing intrauterine system (LNG-IUS).^{52,53} GnRH analogs, however, are only temporarily indicated before surgical intervention.

4. Conclusion

Because of its multiple health benefits, the LNG-IUS is likely to continue to conquer the worldwide markets to treat frequent gynaecological conditions and simultaneously provide contraception when needed. In addition, The LNG-IUS may also offer major benefits for the prevention of uterine pathologies and conditions, including endometrial polyps, endometrial hyperplasia, endometrial carcinoma in association or not with tamoxifen treatment of breast cancer, peri-menopausal menstrual disturbances, post-menopausal endometrial hyperplasia with hormone replacement therapy, endometrial hyperplasia and uterine myomas, endometriosis, adenomyosis, acute pelvic inflammatory disease and infertility.²⁷ Just as we are very conscious about the health benefits of estrogens in the prevention of osteoporotic fractures, the LNG-IUS and other hormone-releasing systems will be used mostly for the prevention of benign diseases in gynaecology. However, successful treatment of precancerous lesions and early cancer of the endometrium are within reach of the LNG-IUS.

The challenge also remains to promote novel LNG-IUSs who are easy to apply and are designed to fit in uterine cavities with different size and shape to improve tolerance and maximize continued use. Furthermore, new conservative approaches and minimally invasive techniques should be explored. Progesterone antagonists and progesterone receptor modulators may have a major role in the future to treat conditions such as fibroids and endometriosis conservatively. Endometriosis accounts for approximately 20% of the hysterectomies currently performed. There is no doubt that these new approaches will help reduce the number of hysterectomies further. However, hysterectomy will always remain the first choice for infiltrative cancer of the uterus and for most forms of pelvic relaxation although vaginal pessaries are increasingly used in older women. Currently, utero-vaginal prolapse is the indication for 15% of hysterectomies.

5. Conflict of interest

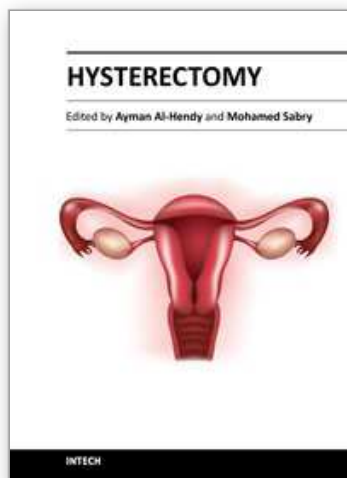
Dirk Wildemeersch, MD, PhD, is a Belgian gynaecologist and Medical Director of Contrel Drug Delivery Research, an organization which was established to manage clinical research and to develop and study innovative drug delivery technologies, aimed at finding improved methods for prevention and treatment of gynaecological conditions, improvements to birth control methods, and higher levels of safety, user acceptability, compliance and quality of life for women. Contrel is the manufacturer of GyneFix®, FibroPlant® and Femilis®. The research organization also provides insertion training for doctors. The funds generated are used for conducting further research and to participate in humanitarian projects.

6. References

- [1] Vessey MP, Villard-Mackintosh L, McPherson K, Coulter A, Yeates D. The epidemiology of hysterectomy: findings in a large cohort study. *Br J Obstet Gynaecol* 1992;99:402-7.
- [2] Wu JM, Wechter ME, Geller, EJ; Nguyen TV, Visco AG. Hysterectomy rates in the United States, 2003. *Obstet Gynecol* 2007;110:1091-5.
- [3] Settnes A, Jorgensen T. Hysterectomy in a Danish Cohort. Prevalence, incidence and sociodemographic characteristics. *Acta Obstetricia et Gynecologica Scandinavica* 1996;75:274-80.
- [4] Coulter A, McPherson K, Vessey M. Do British women undergo too many or too few hysterectomies? *Soc Sci Med* 1988;27:987-94.
- [5] Bernstein SJ, McGlynn EA, Siu AL, Roth CP, Sherwood MJ, Keesey JW, Kosecoff J, Hicks NR, Brook RH. The appropriateness of hysterectomy: a comparison of care in seven health plans. *JAMA* 1993; 269: 2398-402.
- [6] Shuster LT, Gostout BS, Grossardt BR, Rocca WA. Prophylactic oophorectomy in premenopausal women and long-term health. *Menopause International* 2008;14:111-6.
- [7] Shoupe D, Parker WH, Broder MS, Liu Z, Farquhar C, Berek JS. Elective oophorectomy for benign gynecological disorders. *Menopause* 2007;14(Suppl. 1): 580-5.
- [8] Bahamondes L, Bahamondes MV, Monteiro I. "Levonorgestrel-releasing intrauterine system: uses and controversies". *Expert Review of Medical Devices* 2008;5:437-45.
- [9] Boyd ME, Groome PA. The morbidity of abdominal hysterectomy. *Can J Surg.* 1993;36:155-9.
- [10] Banu NS, Manyonda IT. Alternative medical and surgical options to hysterectomy. *Best Practice & Rese Clin Obstet Gynaecol.* 2005;19:431-49.
- [11] Dwyer N, Hutton J & Stirrat GM. Randomised controlled trial comparing endometrial resection with abdominal hysterectomy for the surgical treatment of menorrhagia. *Br J Obstet Gynaecol* 1993;100:237-43.
- [12] Weber AM, Walters MD, Schover LR, Church JM, Piedmonte MR. Functional outcomes and satisfaction after abdominal hysterectomy. *Am J Obstet Gynecol* 1999;181:530-5.
- [13] Thakar R, Ayers S, Georgakapolou A, Clarkson P, Stanton S, Manyonda I. Hysterectomy improves quality of life and decreases psychiatric symptoms: a prospective and randomised comparison of total versus subtotal hysterectomy. *BJOG* 2004;111:1115-20.
- [14] Rannestad T, Eikeland O, Helland H & Quarnstrom U. The quality of life in women suffering from gynaecological disorders is improved by means of hysterectomy. *Acta Obstet Gynecol Scand* 2001;80:46-51.
- [15] Rhodes JC, Kjerulff KH, Langenberg PW & Guzinski GM. Hysterectomy and sexual functioning. *JAMA* 1999;282:1934-41.
- [16] Dicker RC, Greenspan JR, Strauss LT, Cowart MR, Scally MJ, Peterson HB, DeStefano F, Rubin GL, Ory HW. Complications of abdominal and vaginal hysterectomy among

- women of reproductive age in the United States: the collaborative review of sterilization. *Am J Obstet Gynecol* 1982;144:841-8.
- [17] McPherson K, Metcalfe MA, Herbert A, Maresh M, Casbard A, Hargreaves J, Bridgman S, Clarke A. Severe complications of hysterectomy: the value study. *BJOG* 2004;11:688-94.
- [18] Wingo PA, Huezo CM, Rubin GL, Ory HW, Peterson HB. The mortality risk associated with hysterectomy. *Am J Obstet Gynecol* 1985;152:803-8.
- [19] van der Vaart CH, van der Bom JG, de Leeuw JR, Roovers JP, Heintz AP. The contribution of hysterectomy to the occurrence of urge and stress urinary incontinence symptoms. *BJOG* 2002;109:149-54.
- [20] Riedel HH, Lehmann-Willenbrock E & Semm K. Ovarian failure phenomena after hysterectomy. *J Reprod Med* 1986;31:597-600.
- [21] Carlson KJ, Miller BA & Fowler FJ. The Maine Women's Health Study: I. Outcomes of hysterectomy. *Obstet Gynecol* 1994;83:556-65.
- [22] National Evidence-Based Clinical Guidelines. The Management of Menorrhagia in Secondary Care. Royal College of Obstetricians and Gynaecologists, London.
- [23] Lethaby A., Augood C, Duckitt K. Nonsteroidal anti-inflammatory drugs for heavy menstrual bleeding. In: Cochrane Collaboration, ed. Cochrane Library, Issue 1. Update Software, Oxford; 1999.
- [24] Cooke I, Lethaby A, Farquhar, C. Antifibrinolytics for heavy menstrual bleeding. Antifibrinolytics for heavy menstrual bleeding. In: Cochrane Collaboration, ed. Cochrane Library, Issue 1; 1999.
- [25] Lethaby A, Irvine G, Cameron, I. Cyclical progestagens for heavy menstrual bleeding. In: Cochrane Collaboration, ed. Cochrane Library, Issue 1. Update Software. Oxford; 1999.
- [26] Fraser IS. Non-contraceptive health benefits of intrauterine hormonal systems. *Contraception* 2010;82:396-403.
- [27] Hasson HM. Clinical studies of the Wing Sound II metrology device. In: Zatuchni GI, Goldsmith A, Sciarra JJ (eds). *Intrauterine Contraception: Advances and Future Prospects*. Harper & Row, Philadelphia, 1984; 126-41.
- [28] Kurz KH. Cavimeter uterine measurements and IUD clinical correlation. In: Zatuchni GI, Goldsmith A, Sciarra JJ (eds). *Intrauterine Contraception: Advances and Future Prospects*. Harper & Row, Philadelphia, 1984; 142-62.
- [29] Benacerraf BR, Shipp TD, Bromly B. Three-dimensional ultrasound detection of abnormally located intrauterine contraceptive devices which are the source of pelvic pain and abnormal bleeding. *Ultrasound Obstet Gynecol* 2009;34:110-5.
- [30] Shipp TD, Bromly B, Benacerraf BR. The width of the uterine cavity is narrower in patients with an embedded intrauterine device (IUD) compared to a normally positioned IUD. *J Ultrasound Med* 2010; 29: 1453-6.
- [31] Wildemeersch D. Commentary. Intrauterine contraceptives that do not fit well contribute to early discontinuation. *Eur J Contracept Reprod Health Care* 2011;16:1-7.
- [32] Wildemeersch D, Janssens D, Weyers S. Ease of insertion, contraceptive efficacy and safety of new T-shaped levonorgestrel-releasing intrauterine systems. *Contraception* 2005; 6:465-9.
- [33] Wildemeersch D, Janssens D, Andrade A. The Femilis® LNG-IUS: Contraceptive performance- an interim analysis. *Eur J Contracept Reprod Health Care* 2009;14:1-8.
- [34] Wildemeersch D, Pylyser K, De Wever N, Dhont M. Treatment of non-atypical and atypical endometrial hyperplasia with a levonorgestrel-releasing intrauterine system: longterm follow-up. *Maturitas* 2007;57:210-3.
- [35] Wildemeersch D, Anderson E, Lambein K, Pauwels P, Dhont M. Successful Treatment of Early Endometrial Carcinoma by Local Delivery of Levonorgestrel: A Case

- Report. Obstetrics and Gynecology International 2010, Article ID 431950, doi:10.1155/2010/431950.
- [36] Marques AA, Bahamondes L, Aldrighi JM, Petta CA. Quality of life in Brazilian women with endometriosis assessed through a medical outcome questionnaire. *J Reprod Med* 2004;49:115-20.
 - [37] Bahamondes L, Petta CA, Fernandes A, Monteiro I. Use of the levonorgestrel-releasing intrauterine system in women with endometriosis, chronic pelvic pain and dysmenorrhea. *Contraception* 2007;75:S134-S9.
 - [38] Anpalagan A, Condous G. Is There a Role for Use of Levonorgestrel Intrauterine System in Women with Chronic Pelvic Pain? A review. *J Minimally Invasive Gynecol* 2008;15:663-6.
 - [39] Milsom I. The levonorgestrel-releasing intrauterine system as an alternative to hysterectomy in peri-menopausal women. *Contraception* 2007;75:S152-S4.
 - [40] Lähteenmäki P, Haukkamaa M, Puolakka J, Riikonen U, Sainio S, Suvisaari J, Nilsson CG. Open randomised study of use of levonorgestrel releasing intrauterine system as alternative to hysterectomy. *BMJ* 1998;316:1122-6.
 - [41] Reid PC, Mukri F. Trends in number of hysterectomies performed in England for menorrhagia: examination of health episode statistics, 1989 to 2002-3. *BMJ* 2005;330:938-9.
 - [42] Ritva Hurskainen R, Teper J, Rissanen P, Aalto AM, Grenman S, Kivela A, Kujansuu E, Vuorma S, Yliskoski M, Paavonen J. Outcomes and Costs With the Levonorgestrel-Releasing Intrauterine System or Hysterectomy for Treatment of Menorrhagia. Randomized Trial 5-Year Follow-up. *JAMA* 2004;291:1456-63.
 - [43] Lethaby AE, Cooke I & Rees M. Progesterone /progestagen releasing intrauterine system versus either placebo or any other medication for heavy menstrual bleeding. *Cochrane Database Syst Rev* 2000:CD002126.
 - [44] Marjoribanks J, Lethaby A & Farquhar C. Surgery versus medical therapy for heavy menstrual bleeding. *Cochrane Database Syst Rev* 2003:CD00385.
 - [45] Maia H Jr, Maltez A, Coelho G, Athayde C, Coutinho EM. Insertion of mirena after endometrial resection in patients with adenomyosis. *J Am Assoc Gynecol Laparosc.* 2003;10:512-6.
 - [46] Kjerulff K, Guzinski G & Langenberg P. Hysterectomy and race. *Obstet Gynaecol* 1993;82:757-64.
 - [47] Cramer SF, Patel A. The frequency of uterine leiomyomas. *Am J Clin Pathol* 1990;94:435-8.
 - [48] Buttram VC, Reiter RC. Uterine leiomyomas: etiology, symptomatology and management. *Fert Steril* 1981;36:433-45.
 - [49] Donnez J, Schindler AE, Wall weiner D, Audebert A. Fibroids: management and treatment. In: Lunenfeld B, Insler V, eds. *GnRH analogues: The State of the Art* 1996. Carnforth, UK: Parthenon Publishing, 1996:71-82.
 - [50] Vollenhoven BL, Lawrance AS, Healy DL. Uterine Fibroids: a clinical review. *Br J Obstet Gynaecol* 1990;97:285-98.
 - [51] Cramer SF, Hoisznny JA, Leppert P. Epidemiology of uterine leiomyomas. With an etiologic hypothesis. *J Reprod Med* 1995;40:595-600.
 - [52] Nisolle M and Donnez J. Medical management of uterine fibroids: short-term therapy with GnRH agonists. In: Brosens I, Lunenfeld B, Donnez J, eds. *Pathogenesis and medical management of uterine fibroids*. Carnforth, UK: Parthenon Publishing, 1999:113-119.
 - [53] Donnez J, Gillerot S, Squifflet J and Nisolle M. Progestogens and antiprogestogens. In: Brosens I, Lunenfeld B, Donnez J, eds. *Pathogenesis and medical management of uterine fibroids*. Carnforth, UK: Parthenon Publishing, 1999:121-128.



Hysterectomy

Edited by Dr. Ayman Al-Hendy

ISBN 978-953-51-0434-6

Hard cover, 426 pages

Publisher InTech

Published online 20, April, 2012

Published in print edition April, 2012

This book is intended for the general and family practitioners, as well as for gynecologists, specialists in gynecological surgery, general surgeons, urologists and all other surgical specialists that perform procedures in or around the female pelvis, in addition to intensives and all other specialties and health care professionals who care for women before, during or after hysterectomy. The aim of this book is to review the recent achievements of the research community regarding the field of gynecologic surgery and hysterectomy as well as highlight future directions and where this field is heading. While no single volume can adequately cover the diversity of issues and facets in relation to such a common and important procedure such as hysterectomy, this book will attempt to address the pivotal topics especially in regards to safety, risk management as well as pre- and post-operative care.

How to reference

In order to correctly reference this scholarly work, feel free to copy and paste the following:

D. Wildemeersch (2012). The LNG-IUS: The First Choice Alternative to Hysterectomy? Intrauterine Levonorgestrel-Releasing Systems for Effective Treatment and Contraception, Hysterectomy, Dr. Ayman Al-Hendy (Ed.), ISBN: 978-953-51-0434-6, InTech, Available from:
<http://www.intechopen.com/books/hysterectomy/the-lng-ius-the-first-choice-alternative-to-hysterectomy->

INTECH
open science | open minds

InTech Europe

University Campus STeP Ri
Slavka Krautzeka 83/A
51000 Rijeka, Croatia
Phone: +385 (51) 770 447
Fax: +385 (51) 686 166
www.intechopen.com

InTech China

Unit 405, Office Block, Hotel Equatorial Shanghai
No.65, Yan An Road (West), Shanghai, 200040, China
中国上海市延安西路65号上海国际贵都大饭店办公楼405单元
Phone: +86-21-62489820
Fax: +86-21-62489821

© 2012 The Author(s). Licensee IntechOpen. This is an open access article distributed under the terms of the [Creative Commons Attribution 3.0 License](https://creativecommons.org/licenses/by/3.0/), which permits unrestricted use, distribution, and reproduction in any medium, provided the original work is properly cited.

IntechOpen

IntechOpen