

We are IntechOpen, the world's leading publisher of Open Access books Built by scientists, for scientists

6,900

Open access books available

186,000

International authors and editors

200M

Downloads

Our authors are among the

154

Countries delivered to

TOP 1%

most cited scientists

12.2%

Contributors from top 500 universities



WEB OF SCIENCE™

Selection of our books indexed in the Book Citation Index
in Web of Science™ Core Collection (BKCI)

Interested in publishing with us?
Contact book.department@intechopen.com

Numbers displayed above are based on latest data collected.
For more information visit www.intechopen.com



Peripartum Hysterectomy Versus Non Obstetrical Hysterectomy

S. Masheer and N. Najmi
Aga Khan University Hospital, Karachi,
Pakistan

1. Introduction

Hysterectomy is the surgical removal of the uterus. It is one of the commonest gynecological procedures performed all over the world. Most of the time it is done electively for common gynecological conditions like abnormal uterine bleeding, fibroid uterus, endometriosis, chronic pelvic pain and cervical dysplasia. In majority of these conditions, woman is peri menopausal or has already completed her family.

Cesarean hysterectomy is a unique entity where surgical removal of uterus is performed in order to save the patient's life. Although the basic steps of different types of hysterectomy are similar, yet according to their indications and pelvic anatomy, the technique can become more challenging leading to various outcomes in the post operative period.

2. Types of hysterectomy

Depending on the reason for doing hysterectomy, different types of hysterectomies are performed. These include:

1. Total abdominal hysterectomy
2. Supra cervical hysterectomy
3. Radical /Wertheim's Hysterectomy
4. Vaginal Hysterectomy
5. Laparoscopic assisted vaginal hysterectomy
6. Obstetric/Cesarean Hysterectomy

2.1 Total abdominal hysterectomy

This is, by far, one of the commonest gynaecological major operations. Abdominal hysterectomies are usually performed for large uterine fibroids, endometriosis and dysfunctional uterine bleeding etc. A further extension to total abdominal hysterectomy is the Radical hysterectomy which is reserved for carcinoma of the cervix or uterus.

For total abdominal hysterectomy, the patient is placed in dorsal position. Incision to the abdomen is made vertically or transversely according to the indication and size of the uterus. After opening the peritoneal cavity, abdominal sponges are used to pack the bowel

and Balfour retractor is applied to have good access of the operating field. Uterus is grasped with medium sized clamps and pulled out of the incision to expose the anterior surface of the uterus.

The round ligament on each side is identified and clamped using firm grasping clamps like Kocher or Spencerville. Anterior fold of broad ligament is opened starting from the round ligament. After cutting and ligating the round ligament on each side, a window is created where peritoneum is thin with the index finger to clamp the infundibulo pelvic ligament which is then cut and transfixed. Urinary bladder is pushed down after opening the utero vesical fold completely. It is important to carefully identify the correct plane and reflect the bladder from the centre of the cervix as lateral reflection could lead to inadvertent bleeding. Next step is to clamp the uterine arteries at the level of internal cervical os with heavy clamps like Roberts or Mangots hugging on to the cervix and ligating them carefully. Then the cardinal ligament are clamped, cut and ligated, going medially towards the cervix to avoid injury to the ureters till the vagina is reached. The uterus is removed and the anterior and posterior walls of the cut vagina are grasped by Volsellum forceps. The vagina is closed with either figure of eight sutures or in button hole fashion in which vagina is left open.

2.2 Supra cervical hysterectomy

One of the commonest indications for performing supra cervical hysterectomy is Endometriosis where there is frozen pelvis and difficulty in accessing the area below the level of uterine arteries.

In supra cervical or subtotal hysterectomy, body of the uterus is removed in exactly the same fashion as the total abdominal hysterectomy until the level of ligation of uterine arteries. After this level, the uterine body is cut from the cervix and haemostatic sutures are taken on the cut edge of the left over cervix. Some surgeons also prefer to perform the conization of the endo cervix in order to reduce the chances of cervical cancer. Women undergoing supra cervical hysterectomy are advised to follow up with their Pap smear in the similar fashion as before the surgery.

2.3 Laparoscopic hysterectomy

Laparoscopic hysterectomies were introduced as a replacement of abdominal hysterectomy with the benefit of avoiding incision of the abdomen.

Patient should be placed in dorsal lithotomy position. Uterine manipulator is inserted according to the size of introitus and parity of the patient. Dilatation of cervix is rarely required to place the uterine manipulator. Foley catheter is inserted into the urinary bladder.

The best way to minimize laproscopic injuries is to insert primary Trocars with maximum care.

Most of the gynecologists prefer closed entry technique in which carbon dioxide is insufflated via Verses needle into the peritoneal cavity. Other method is open technique in which a small incision is made into the rectus sheath and has direct access to peritoneal cavity.

The incision for laparoscopy should be vertical from the base of the umbilicus as it is the thinnest part of the abdominal wall. The Veress needle should be sharp and its spring mechanism should be properly working. Lower abdominal wall should be stabilized by grasping and holding it upwards with one hand so that veress is inserted perpendicular to the skin with the other hand. Two audible clicks are usually heard when veress pierces the fascia and the peritoneum respectively. In case of difficult or failed attempts either the open method or the palmers point entry should be approached. For primary trocar insertion intra-abdominal gas pressure should be 20-25 mmHg which is later reduced to 12-15 mmHg for surgery.

The infundibulo pelvic ligament is desiccated with bipolar grasper. It is very important to stay close to the ovaries and transect them using Harmonic scalpel. During this step uterine manipulator should be pushed upwards and on opposite side to provide maximum visualization and good working space.

After this step, round ligament is transected in order to separate the leaves of broad ligament with Harmonic scalpel. This step differs from abdominal hysterectomy where round ligaments are transected as the first step of surgery. Identification of correct plane is vital, i.e. where peritoneum is loose and easily separable, uterovesical fold is opened anteriorly to mobilize the bladder down. It should be carefully done in patients with previous cesarean sections and uterine surgeries. Once the bladder is down, ureters are retracted laterally, so the uterine arteries can be desiccated with bipolar grasper and transected with harmonic scalpel. Two small incisions are made with Harmonic scalpel medial to uterine vessels so as to free the cervix from the transcervical ligaments. Vaginal fornices can be identified by pushing in upward direction with the uterine manipulator and Harmonic scalpel is used to cut the cervix from the vagina. Uterus is then removed and a glove with sponges is placed into the vagina to maintain pneumoperitoneum.

Vaginal cuff is closed in a running fashion, with almost one centimeter thickness including vaginal mucosa and pubocervical and rectovaginal fascia.

It is recommended to suture the rectus sheath of all non-midline port over 7mm and midline port greater than 10mm to avoid hernia formation.

2.4 Total vaginal hysterectomy

Patient is placed in dorsal lithotomy position with buttocks at the end of table. Two Jacobs's tenacula are used to grasp the anterior and posterior lip of cervix. Simple saline solution or adrenaline with the dilution of 1:100000 is injected into the vaginal mucosa at its junction with the cervix. After injecting the solution the Mucosa is incised with scalpel around the entire cervix.

Index finger is used to dissect the bladder up to the peritoneal vesico uterine fold. Alternatively, sharp dissection can also be done for this step. A right angle retractor is placed under the vaginal mucosa and bladder to elevate them and the peritoneal fold is incised with Mayo's scissors. Cervix is lifted up with Jacobs's tenacula and peritoneum of cul-de-sac is incised.

A curved Heaney clamp is placed in posterior cul de sac. The clamp is applied next to cervix and uterosacral ligaments are cut with mayo's scissors and ligated. This suture not only ligates the uterosacral ligament but plicates the pedicle to vaginal cuff.

The cardinal ligament is clamped adjacent to lower uterine segment and ligated. The uterine arteries are clamped, cut and ligated in the similar fashion close to the junction of lower uterine segment with internal cervical os. Uptil this step ligating and securing the pedicles is relatively easy as they are easily approachable surgically. The next step is clamping and ligating the tubo- ovarian ligaments. This step can be difficult sometimes especially if the uterus is enlarged. In such circumstances, either the fundus of the uterus can be delivered outside or uterus can be bisected longitudinally in the midline and each pedicle can then be secured separately.

Heaney clamps are applied to tubo- ovarian round ligament either directly or by following any of the above methods and uterus is then removed through the vagina.

Re-peritonealization is carried out with purse string sutures starting from anterior peritoneal edge and continued down through the uterosacral cardinal ligament pedicles and the vaginal mucosa.

Vaginal cuff is sutured with running locking stitch and is left open.

2.5 Radical hysterectomy

Patient selection is critical for radical hysterectomy. Young, thin patients with early stage carcinoma of cervix are usually the best candidates. Obesity is at times associated with carcinoma of the endometrium and is a relative contraindication. Preoperative preparation and informed consent are the prerequisite as in any other surgery.

Patient is placed in dorsal position. Abdominal incision is midline as it gives excellent access to pelvis and Para aortic lymph nodes are easily approachable when required. After opening the peritoneal cavity, peritoneal cytology is taken. Large sponges are used to pack the bowel and Balfour retractor is applied to have good view of the pelvis. If the patient is obese Book Walter retractor provides excellent access to the pelvis.

In radical hysterectomy round ligament is clamped on each side closed to the pelvic side wall and broad ligament is opened superiorly up to the paracolic gutter and the incision is extended inferiorly and medially to open the Utero-vesical fold. Laterally non toothed forceps can be used to freed the peritoneum from the adjacent soft tissue and reaches to the triangle bounded by urinary bladder medially, iliac vessels laterally and the pelvis inferiorly. If the ovaries are to be conserved the index finger is placed on the medial side of the ovary and then pierces the peritoneum through the thinnest part and clamp is applied and infundibulopelvic ligament is then cut. The same steps are repeated on the other side.

Uterine artery needs to be skeletonized so that it is completely separated from the ureters and obliterated hypogastric artery should be identified at this point. The uterine vessel should be accurately clamped with Meig's forceps close to its origin at the internal iliac artery. Now make sure that bladder is separated from the cervix. This can be easily done by pushing down the utero vesical fold with swab folded on the index finger.

Next important step is the identification and division of the roof of the ureters tunnel. Usually tissue forceps are placed medially to uterine arteries and canal roof is clamped and cut, exposing the ureters and this pedicle is tied. Next step is separation of ureters laterally

from the upper vagina, this will expose cardinal ligament. Posteriorly peritoneum is opened just below the cervix, revealing soft tissue between vagina and the rectum. It is important to work under direct vision keeping an eye on the ureter. Make sure that uterosacral ligaments are free and away from the ureters and Zippelin forceps are applied and uterosacrals are cut. Another Zippelin clamp is applied on the cardinal ligament, it is cut and ligated and uterus is removed. Vault is closed with running suture or button hole fashion but caution must be applied on reviewing the ureters.

Radical hysterectomy is usually accompanied by dissection of pelvic lymph nodes. Some authorities prefer to do it before performing radical hysterectomy and some do it afterwards.

2.6 Obstetric/ peri partum hysterectomy

Obstetric hemorrhage is one of the leading causes of maternal mortality. The rise in mortality rate has been attributed to a number of factors, including increasing age at childbirth, increased numbers of multiple pregnancies and the rising caesarean section rate. Postpartum hemorrhage is one of the leading causes of maternal deaths and at times hysterectomy remains the life saving procedure in such cases. Almost all the literature on peri partum hysterectomy consists of analysis of retrospective cases in different hospitals all over the world.

2.6.1 Risk factors for obstetrics hysterectomy

Incidence of Peri partum hysterectomy in modern obstetrics is rising due to increase in rate of Cesarean section all over the world, leading to morbidly adherent placenta. Other reasons for peri partum hysterectomy are grand multi parity which can lead to uterine atony, uterine rupture and coagulopathy, presence of large leiomyomas, or bleeding from lacerated uterine vessel which is not treatable by more conservative measures. Hysterectomy also may be appropriate for women with postpartum uterine infection unresponsive to antibiotic therapy. In majority of the cases, peri partum hysterectomy is performed as an emergency procedure which leads to further morbidity to the patient.

Planned hysterectomy at the time of delivery is controversial because of increased morbidity related to surgery on the highly vascular pelvic organs. However, there are certain elective indications for peri partum hysterectomy. These include large or symptomatic leiomyomas and severe cervical dysplasia or carcinoma in situ.

2.6.2 Preparation

Most of the times, the obstetrician can anticipate the possible need for peri partum hysterectomy which helps in better preoperative preparation and management. Many of the litigations can be prevented by taking and documenting an informed consent for the procedure including the chances of all possible complications. This may not always be possible when one is dealing with acute emergency but it can be done electively prior to labor and delivery when there are risk factors present in the patient such as suspicion of morbidly adherent placenta.

Risk assessment of the pregnant woman should be routinely carried out at her first antenatal visit and then at 20 weeks of gestation when anomalies scan can comment on placental localization. Follow-up imaging is required if the placenta covers or overlaps the cervical os at 20 weeks of gestation especially for women with previous cesarean scars where chances of accreta are higher. Antenatal sonographic imaging can be complemented by magnetic resonance imaging in equivocal cases to distinguish those women at special risk of placenta accreta.

Patients with high parity, major placenta previa and previous cesarean section should be vigilantly followed and delivered in well resourced settings where facilities of blood bank and multidisciplinary antenatal, intra partum and post operative care can be provided.

The National Patient Safety Agency (NPSA) in collaboration with the Royal College of Obstetricians and Gynaecologists (RCOG) and the Royal College of Midwives (RCM) developed a Care Bundle for placenta previa accreta. This Care Bundle has six elements of good care as follows:

- Consultant obstetrician planned and directly supervising delivery
- Consultant anaesthetist planned and directly supervising anaesthetic at delivery
- Blood and blood products available
- Multidisciplinary involvement in pre-op planning
- Discussion and consent includes possible interventions (such as hysterectomy, leaving the placenta in place, cell salvage and intervention radiology)
- Local availability of a level 2 critical care bed. Level 2 critical care bed are the high dependency area capable of providing service to meet the needs of patients who require more detailed observation or intervention ,short-term non-invasive ventilation and post- operative care.

The morbidities associated with placenta accreta/percreta can be reduced by following these six points of Care Bundle.

2.6.3 Technique

Women with placenta previa in the third trimester should be counselled about the risks of preterm delivery and obstetric haemorrhage, and their care should be tailored to their individual needs. This care plan should be documented in the antenatal folder so that if patient presents in an emergency situation, the procedures/prerequisites to follow are already present. Good communication among the team members is essential for successful outcome.

Prophylactic antibiotic is mandatory for such patients and majority of the times this is converted into therapeutic antibiotics depending upon the extent and nature of surgery. Similarly, thromboembolism prevention such as by using preoperative anti-embolism compression stockings and post operative physiotherapy are some universal steps which can lead to a better outcome.

Adequate exposure is important. Although Pfannenstiel incisions are mostly given in unanticipated cases, but midline skin incision can be considered if the morbidly adherent placenta is diagnosed or suspected. It will not only help in selection of uterine incision

which may be classical but also will be valuable if proceeding for hysterectomy. In case of Pfannenstiel approach, incision can be extended in order to have good exposure of the surgical field. Semi Trendelenburg position of the patient and abdominal packing with large swabs will help in better exposure. Anterior abdominal wall retraction with Deaver is usually enough most of the time, Balfour retractor is not always necessary. As peripartum hysterectomy is associated with massive hemorrhage most of the time, therefore time constraints should be kept in mind. Both sided round ligament should be clamped with straight Heaney close to the uterus and double ligated with vicryl zero or one. Utero-vesical fold is already opened if proceeding to hysterectomy after the cesarean section. Otherwise this fold needs to be opened and bladder should be reflected down so that ureters move away from the infundibulo-pelvic ligament and uterine arteries. Posterior leaf of broad ligament is opened by blunt dissection with the help of index finger from posterior to anterior and with curved Heaney the utero-ovarian ligament and fallopian tube is clamped and transfixed with vicryl one. Ovaries are conserved in cases of peripartum hysterectomy. On the other hand, Round and infundibulo-pelvic ligaments can be taken together close to the fundus of the uterus in order to save time. Bladder should again be carefully reflected down further, both sided uterine arteries and veins are identified, clamped with curved Heaney, and ligated with vicryl one. By this point bleeding is usually controlled and body of uterus should be removed just below the ligation of uterine arteries and cervical stump can be closed with vicryl one. This subtotal hysterectomy is often the procedure of choice in obstetric hemorrhage.

If the bleeding is not controlled or morbidly adherent placenta is involving the lower uterine segment, then total hysterectomy should be performed which at times can be difficult. Lower margins of cervix can be felt with fingers when the scar is opened, it will roughly give an idea of cervical length and clamps should be applied medially to the secured uterine arteries close to the uterus. Once again bladder should be reflected down further before applying clamps. If uterus is not opened, clamps are applied in a similar way to the cardinal ligament, and the pedicle is ligated and transfixed. These steps are repeated till lateral vaginal fornix is reached. Just below the cervix curved clamps like Roberts are applied medially on both sides and uterus with cervix is removed. Cervix should be inspected for its complete removal. Both sided vaginal angle should be secured with figure of eight sutures. Vaginal vault can be closed with interrupted sutures using vicryl zero or one or can be left open with button hole sutures.

3. Complications of Peri partum hysterectomy Vs gynecological hysterectomy

The outcome of Peri partum hysterectomy depends upon its indication. In most cases, this is performed as an emergency procedure, thus the complications associated with it are definitely higher than non obstetrics hysterectomy. One of the most common complications encountered in Peri partum hysterectomies is the risk of hemorrhage. Massive post partum hemorrhage is encountered in almost all cases of peri partum hysterectomies. According to one study, the estimated blood loss ranged from 1-6 liters, leading to blood transfusion in 92% of patients, 20 % of whom also developed coagulopathy. Because of massive hemorrhage, hemostasis can be a challenging task and such patient may end up in having a repeat laparotomy for this reason. The percentage of patients undergoing repeat laparotomy

could be as high as 16%. When compared with non obstetric hysterectomy, women who underwent a peri partum procedure are nearly eight times more likely to require surgical re-exploration and almost three times as likely to develop a wound complication.

Another complication commonly encountered is the risk of infection. It is one of the commonest reasons for prolonged hospital stay. Wound infections and puerperal sepsis can occur in up to 14-19% of cases.

Organ injury is more likely to occur in Peri partum hysterectomies especially those done for morbidly adherent placenta where bladder is injured. Similarly, ureters can also be injured in such emergency cases. Other organs like bowel are less commonly injured. According to one survey in UK, bladder damage was more likely to occur in cases of morbidly adherent placenta (23%) compared to uterine atony (8%, OR 3.41, 95% CI 1.55–7.48). Ureteric injury was similar in both cases (6% vs 4%). The percentage of organ injury is much higher when compared to prevalence of organ injuries in other benign gynecological reasons for hysterectomy (0.4%-2.5%).

When comparing peri partum hysterectomy to non obstetric benign hysterectomy, rates of postoperative hemorrhage (5% compared with 2%), wound complications (10% compared with 3%), and venous thromboembolism (1% compared with 0.7%) are all quoted to be higher in women who underwent peri partum hysterectomy. Similarly, peri operative cardiovascular, pulmonary, gastrointestinal, renal, and infections morbidities are all higher for Peri partum hysterectomy.

Because of the challenging nature of the surgery and the associated complications, the post operative stay in hospital, including the ICU stay, of such patients is much higher than those undergoing non obstetric hysterectomy. For the similar reasons, the chances of mortality of such patients are also higher compared to the other group. According to Wright et al, the mean length of stay for women who underwent peri partum hysterectomy was 8.7 days compared with 2.9 days for non obstetric hysterectomy. The peri operative mortality for peri partum hysterectomy was 1% compared with 0.04% for non obstetric hysterectomy. This study showed that the mortality in cases of peri partum hysterectomy was 14 times higher when compared to non obstetric hysterectomy.

4. Conclusion

Timely expert management in a well resourced centre is advocated. Hemorrhage is predictable in some situations when risk factors are present but severe uncontrollable hemorrhage can occur unexpectedly. It is in these situations that early decision making and the provision of adequate supplies of blood and blood products become extremely important. All obstetricians should be adequately trained in the performance of the B-lynch procedure, emergency hysterectomy and other complicated procedures such as ligation of the internal iliac arteries to control uterine hemorrhage. It is advisable that senior obstetrician must be involved in care of such patients. There must be national and local clear protocols and drills on the management of peri partum hemorrhage which may help reduce the incidence of peri partum hysterectomy.

All essential drugs for managing post partum hemorrhage should be available in the delivery unit all the time. Vigilant monitoring of laboring patients with previous scar can lead to timely decision of cesarean delivery which in turn leads to reduced chances of

uterine rupture. On the other hand, increasing cesarean section rates leads to increased chances of morbidly adherent placenta which in turn leads to increased chances of peripartum hysterectomy. Therefore it is recommended that such cases should always be dealt in tertiary care with multi disciplinary team approach involving urologists, hematologist and intensive care experts. Despite advances in clinical practice, it is likely that peripartum hysterectomy will be more challenging for obstetricians in the future and therefore regular drills of these protocols can help reduce morbidity associated with it.

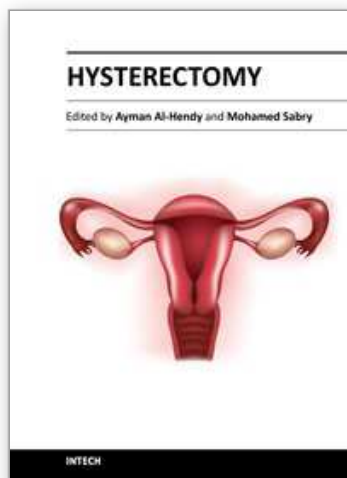
5. References

- Cunningham FG, Leveno KJ, Bloom SL, Hauth JC, Rouse DJ, Spong CY. *Williams Obstetrics*, 23rd edition Section IV. Labor and Delivery Chapter 25. Cesarean Delivery and Peripartum Hysterectomy. The McGraw-Hill Companies.
- Clifford R Wheel less, Marcelle L Roenneburg. Atlas of pelvic surgery, on line edition, October 2011.
<http://www.atlasofpelvicsurgery.com/5Uterus/9TotalVaginalHysterectomy/chap5sec9.html>
- Drake MJ, Noble JG. Ureteric trauma in gynecologic surgery. *Int Urogynecol J Pelvic Floor Dysfunct*. 1998;9(2):108-17.
- Jon I Einarasson, 2009. Total laproscopic Hystrectomy: 10 steps toward a successful procedure, *Rev Obstet Gynaecol*. 2(1): 57-64
- Jacobs Allon. Peripartum hysterectomy. *UptoDate*: September 2010.
- Jason D. Wright JD, Devine P, Shah M, et al. Morbidity and Mortality of Peripartum Hysterectomy. *Obstet Gynecol* 2010; 115:1187-93
- K A Rabi, F M Akinlusi and A A Adewunmi. Emergency peripartum hysterectomy in a tertiary hospital in Lagos, Nigeria: a five-year review. *Trop Doct* 2010; 40:1-4.
- Knight M on behalf of UKOSS. Peripartum hysterectomy in the UK: management and outcomes of the associated haemorrhage. *BJOG* 2007;114:1380-1387.
- Michael J. Turner; Peripartum hysterectomy: An evolving picture. *International Journal of Gynecology & Obstetrics* Vol 109, Issue 1, Pages 9-11, April 2010
- RA Kwame-Aryee, AK Kwakye, and JD Seffah. Peripartum hysterectomies at the korle-bu teaching hospital: a review of 182 consecutive cases. *Ghana Med J*. 2007 September; 41(3): 133-138.
- Paterson-Brown S, Singh C. Developing a care bundle for the management of suspected placenta accreta. *The Obstetrician & Gynaecologist* 2010;12:21-7.
- RCOG Green-top Guideline No. 27. Placenta praevia, placenta praevia accreta and vasa praevia: diagnosis and management, January 2011
- RCOG Green -top Guideline No. 49. Preventing Entry related Gynaecological Laproscopic injuries, May 2008
- Tito Lopes et al 2010. Operations on the uterus, In: *Bonney's Gynaecological Surgery*, 105-120 Wiley- Blackwell, ISBN 9781405195652, UK
- Tallab F, Helewa M. Peripartum hysterectomy: 10 years experience in two Manitoba tertiary centers. *Ann Saudi Med* 1998; 18 (5): 398-400.
- William J Mann. Radical Hystrectomy, *Upto Date*, March 2011.

Yalinkaya A, Güzel A I, Kangal K. Emergency Peripartum Hysterectomy: A 16 years experience of a Medical Hospital. *J Chin Med Assoc* 2010;73(7):360-363.

IntechOpen

IntechOpen



Hysterectomy

Edited by Dr. Ayman Al-Hendy

ISBN 978-953-51-0434-6

Hard cover, 426 pages

Publisher InTech

Published online 20, April, 2012

Published in print edition April, 2012

This book is intended for the general and family practitioners, as well as for gynecologists, specialists in gynecological surgery, general surgeons, urologists and all other surgical specialists that perform procedures in or around the female pelvis, in addition to intensives and all other specialties and health care professionals who care for women before, during or after hysterectomy. The aim of this book is to review the recent achievements of the research community regarding the field of gynecologic surgery and hysterectomy as well as highlight future directions and where this field is heading. While no single volume can adequately cover the diversity of issues and facets in relation to such a common and important procedure such as hysterectomy, this book will attempt to address the pivotal topics especially in regards to safety, risk management as well as pre- and post-operative care.

How to reference

In order to correctly reference this scholarly work, feel free to copy and paste the following:

S. Masheer and N. Najmi (2012). Peripartum Hysterectomy Versus Non Obstetrical Hysterectomy, Hysterectomy, Dr. Ayman Al-Hendy (Ed.), ISBN: 978-953-51-0434-6, InTech, Available from: <http://www.intechopen.com/books/hysterectomy/peripartum-hystrectomy-versus-non-obstetrical-hystrectomy>

INTECH
open science | open minds

InTech Europe

University Campus STeP Ri
Slavka Krautzeka 83/A
51000 Rijeka, Croatia
Phone: +385 (51) 770 447
Fax: +385 (51) 686 166
www.intechopen.com

InTech China

Unit 405, Office Block, Hotel Equatorial Shanghai
No.65, Yan An Road (West), Shanghai, 200040, China
中国上海市延安西路65号上海国际贵都大饭店办公楼405单元
Phone: +86-21-62489820
Fax: +86-21-62489821

© 2012 The Author(s). Licensee IntechOpen. This is an open access article distributed under the terms of the [Creative Commons Attribution 3.0 License](https://creativecommons.org/licenses/by/3.0/), which permits unrestricted use, distribution, and reproduction in any medium, provided the original work is properly cited.

IntechOpen

IntechOpen