

We are IntechOpen, the world's leading publisher of Open Access books Built by scientists, for scientists

6,900

Open access books available

186,000

International authors and editors

200M

Downloads

Our authors are among the

154

Countries delivered to

TOP 1%

most cited scientists

12.2%

Contributors from top 500 universities



WEB OF SCIENCE™

Selection of our books indexed in the Book Citation Index
in Web of Science™ Core Collection (BKCI)

Interested in publishing with us?
Contact book.department@intechopen.com

Numbers displayed above are based on latest data collected.
For more information visit www.intechopen.com



Le Fort I Osteotomy for Maxillary Repositioning and Distraction Techniques

Antonio Cortese
University of Salerno
Italy

1. Introduction

Despite the widespread acceptance of various classifications for midface fractures, the most commonly used for describing these fractures remains the classical one described by the French physician Rene Le Fort in 1901 (Le Fort, 1900, 1901).

The technique for maxillary osteotomy type Le Fort I was performed for the first time by Cheever in 1864 for rinofaringeal tumor resection (Halvorson & Mulliken, 2008).

In 1921 Herman Wassmund performed a Le Fort I osteotomy for dentofacial deformity correction without intraoperative mobilization, which was achieved by orthopedic traction in the post operative time (Wassmund, 1927, 1935).

In 1934 Auxhausen performed a Le Fort I osteotomy mobilization for open bite correction (Axhausen, 1934), but only in 1952, in the USA, Converse described his cases operated by maxillary osteotomy and large vestibular and palatal elevation for Le Fort I osteotomy combined with midpalatal osteotomy (Converse, 1952).

After this report some other surgeons performed maxillary osteotomies for open bite correction, but results were not stable (Steinhausen, 1996). Only in 1974 Stoker and in 1975 Epker, reported encouraging results in dentofacial deformity correction using down fracture technique for complete maxillary mobilization by Le Fort I osteotomy (Stoker, 1974; Epker, 1975).

After encouraging reports by some American surgeons (Converse, 1969) who published several methods for correction of jaw deformities and stressed the importance of close collaboration between surgeon and orthodontist, other surgeons (Obwegeser, Wilmar, Bell) started to widely adopt maxillary osteotomies for dentofacial deformity correction (Obwegeser, 1969; Bell, 1975, Hogeman & Wilmar, 1967).

An important contribution to orthognatic surgery came from Obwegeser's unit in Zurich (Switzerland) and from many excellent textbooks on orthognatic surgery published in the 80s by different American surgeons (Bell, 1980; Bell, 1985, Epker and Fish, 1986; Profitt and White, 1991).

Before 1965 this kind of deformities were commonly treated only by mandibular osteotomies even if skeletal problems were present in maxillary bones, but final results were not aesthetically satisfactory. An important progress in orthognatic surgery was the 'two-

jaws surgery' with the simultaneous mobilization of the total maxilla and mandible. Köle introduced bimaxillary alveolar surgery in 1959, but Obwegeser published his experience in 1970 as the first surgeon who had performed total mandibular and maxillary osteotomies (Obwegeser, 1970). Nowadays the Le Fort I osteotomies are widely employed in dentofacial deformities correction in consideration of the new aesthetic concept of facial beauty.

2. Le Fort I osteotomy and facial aesthetic evolution

The first parameter for facial beauty is symmetry, which is probably related to the expression of a correct genetic asset of each individual. In a study by Little (Little et al., 2001), different images (symmetric and asymmetric) of the same subject were shown to a group of young females and the concept of beauty was identified in symmetric images (Perrett et al., 1999). Secondly the concept of beauty has been modifying towards bi-protrusive cephalometric type as shown by most contemporary actors' faces; probably because maxillary bi-protrusion strongly suggests a complete genetic growth expression (Arnett & Gunson, 2010). The third point for a modern concept of beauty of the face is a wide smile without black corridors in the lateral area of the mouth; also a gingival exposure of the upper dental arch is commonly accepted for a durable beauty of the face and young appearance in consideration of the natural drop of the smile height in older age (Arnett & Gunson, 2004).

The fourth point is the association of malar bones and mandibular lower border evidence, resulting in good face skin tension with cheek concavity, without any sub-mental and cheek folds (Naini et al., 2006).

This new concept of beauty largely influences the planning of dentofacial deformity correction with an indication to increase facial skeleton dimension either by Le Fort I osteotomies alone or in association with mandibular surgery.

Because the patient's main request in dentofacial deformity treatment is a new aesthetical balance of the face (see fig.1) involving good occlusion, good masticatory function, aesthetic of the smile, aesthetic of the facial skeleton contour (zygomatic and mandibular border evidence) and high ratio between facial skeleton and skin amount for good skin tension and juvenile looking; a new kind of operation and surgical planning has been developed in maxillofacial surgery (Merli et al., 2007; Triaca et al., 2004, 2009, 2010).

Many of these procedures involve the Le Fort I osteotomies with new variations and techniques like osteodistraction and bone augmentation and a skill team working with intense cooperation between Maxillofacial surgeons, orthodontists, dentists and anesthesiologists (Cortese et al., 2003, 2009, 2010, 2011).

3. Le Fort I type osteotomy: Classic surgical technique

Bleeding control and vascular preservation after complete mobilization of the maxillary segments in order to avoid vascular necrosis were the main problems that maxillofacial surgeons had to face at the beginning of the Le Fort I type osteotomy surgery.

For these reasons vascular studies were performed by Turvey and Fonseca on maxillary artery anatomy (Turvey & Fonseca, 1980) and the importance of accurate surgery technique in the posterior maxilla area to preserve the integrity of the maxillary artery. The importance of soft

posterior tissue pedicles for maxillary blood supply was investigated by Bell (Bell, 1973), Justus by a laser Doppler analysis and Jones, who suggested attention to vascular risk, particularly in patients using orthodontic appliances or post-surgical splints (Justus et al., 2001; Jones, 2001). Teeth modification with narrowing of the pulp canals after Le Fort I osteotomy was investigated also by Ellingsen and Artun (Ellingsen & Artun, 1993) but the conclusion over 30 years of Le Fort I osteotomy is that no major problems are usually reported after maxillary osteotomies following recommended techniques (Panula et al., 2001); life-threatening complications are very rare (Van de Perre et al., 1996; Acebal-Bianco et al., 2000).




Fig. 1. Classic versus modern concepts of beauty face

Avascular necrosis related to lack in blood supply is one of the main complications after Le Fort I osteotomy and has been reported by some studies (Parnes & Becker, 1972; Lanigan, 1993) with an occurrence fewer than 1% after this kind of surgery.

The main problems related to vascular compromise after maxillary mobilization are rupture of the descending palatal artery, post-operative thrombosis, perforation of the palatal mucosa in segmented maxillary surgery and partial stripping or excessive tension of the palatal fibromucosa in maxillary expansion (Lanigan et al., 1990). Anatomic irregularities such as craniofacial dysplasias, orofacial clefts, or vascular anomalies increase the risks of vascular problems following maxillary osteotomy surgery (Kramer et al., 2004). Especially in the segmented Le Fort I, palatal fibromucosa preservation is an important factor to avoid partial necrosis and malunion of the maxillary bone fragments particularly in patients with orthodontic appliances or palatal splint causing pressure on the palatal mucosa.

External reference landmarks are established at the nasofrontal area by inserting a pin into bone after a stab incision, in order to record the vertical measurement from the pin to the incisal edge of the maxillary incisors for proper vertical positioning of the maxilla after osteotomies. In the Author experience external reference is more reliable than reference mark on the maxilla, but multiple control references are advised because correct maxillary repositioning is fundamental for postoperative final symmetry of the face. For these reasons, direct control of the bipupillar line and occlusal planes symmetry and the midline alignment of the frontonasal (Nasion), interincisal and Pogonion points must be checked before final fixation of the maxilla.

Also intermediate maxillary splint for maxilla repositioning is not completely reliable because mandibular condyles may be displaced from the glenoid fossae during repositioning and fixation procedures.

3.1 Soft tissue incision

Before proceeding to the surgical incision a solution of local anaesthetic with epinephrine (2% lidocaine with 1:100000 epinephrine) is infiltrated into the buccal mucosa along the entire surface of the maxilla in order to minimize bleeding and increase anaesthesia during surgical procedure. Because palatal soft tissue is an important vascular pedicle for the maxilla after complete LeFort I osteotomy, no injection is performed in the palatal region.

Total blood loss is significantly reduced during surgery also elevating of 15 degrees patient's head and by systolic blood pressure control (about 90 mmHg) with hypotensive anaesthesia (Shepherd, 2004).

Soft tissues incision is performed bilaterally from the midline of the fornix above the central incisors to first molar region, involving mucosa, muscle and periosteum; after the incision, blood supply of the maxilla is guaranteed by a wide pedicle of buccal tissue over the teeth. A subperiosteal dissection made with a periosteal elevator exposes the lateral wall of the maxilla, from the pterygomaxillary junction to the anterior nasal spine. At this point it is important to identify and protect the infraorbital neurovascular bundle; dissection should not be extended to tissues set behind the incision, in order to preserve an optimal perfusion of the maxilla (see fig. 2 and fig. 3).

The dissection continues toward the maxillary tuberosity and pterygoid plate, with an inferior angled fold behind the zygomatic buttress. In this area it is recommended to achieve a mucosal tunnelling under direct vision, to preserve a wide-based, intact part of buccal soft tissues. During this procedure the buccal fat pad can be exposed, covering the surgical field: using a retractor the fat pad can be displaced laterally, after covering it with a moistened gauze.

The piriform aperture is exposed, and the mucoperiosteum is elevated along the piriform rim, the nasal floor and the lateral wall under the inferior turbinate, then reflected with a periosteal elevator to expose the anterior floor of the nose. The septopremaxillary ligament is transected as well as the transverse nasalis muscle to completely free the anterior nasal spine. Obviously a careful management of the nasal mucosa, without perforations and cuts, minimizes blood loss and reduces postoperative discomfort.

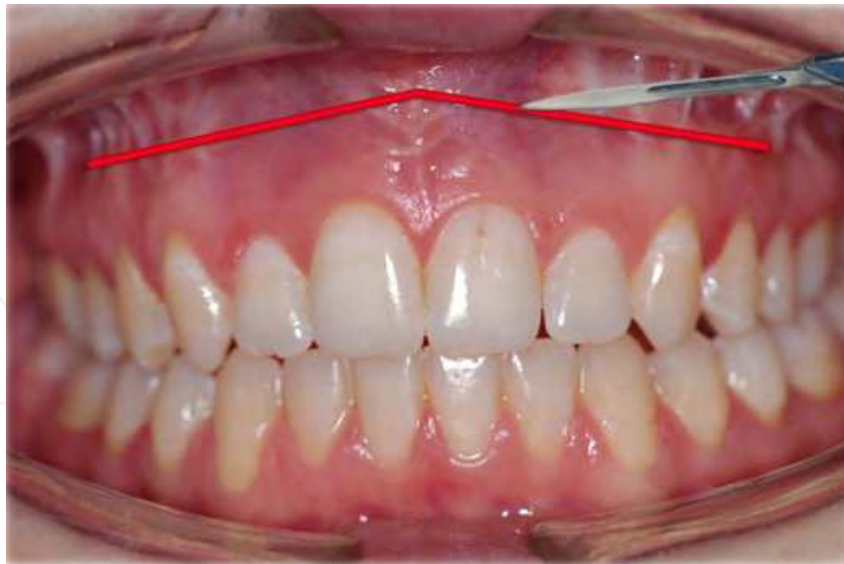

Fig. 2. Buccal mucosa incision starts from the zygomatic buttress 5 mm over the dental roots apices and proceeds across the median region up to the opposite site, from 1.6 to 2.6.

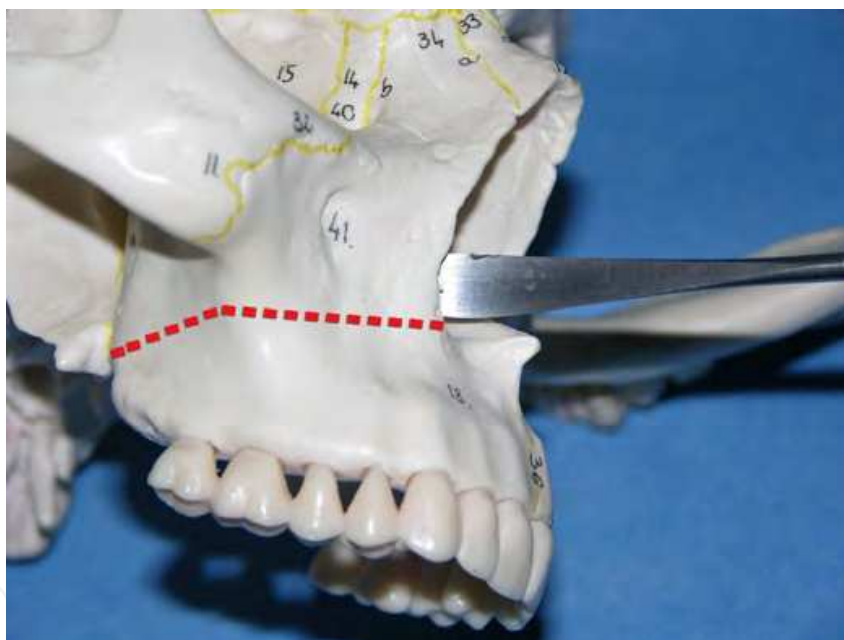


Fig. 3. Periosteum elevation both on buccal and nasal side of the maxilla.

3.2 Osteotomy techniques

Once the dissection is completed, reference points are established before performing osteotomy. Vertical reference landmarks are scratched with a bur at the piriform aperture region and at the zygomatico-maxillary region; the couples of holes in cortical bone stand 5 millimetres above and 5 millimetres beneath the imaginary line of planned osteotomy (see fig. 4); if a maxillary impaction is planned this distance has to be increased, depending on the amount of the impaction. Using the callipers, two holes 4 mm above the apices of the canine and the first molar are marked to help positioning of the first osteotomy line. Together with the external landmarks described before, these intraoral points allow vertical

and horizontal positioning of the maxilla after the mobilization is made; also the occlusal splint will help the proper fixation of the maxilla in the sagittal and vertical planes.

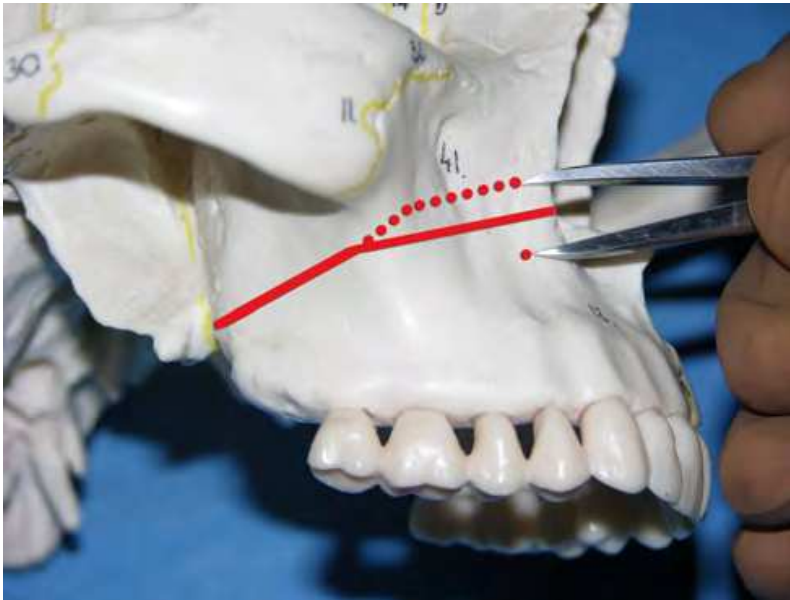


Fig. 4. Amount of bone removal measured by caliper at the osteotomy site.

The osteotomy begins placing a bur or a surgical saw posteriorly at the zygomatic buttress, about 35 mm above the occlusal plane, and advances through lateral maxillary wall to the piriform rim. Before performing the osteotomy of the lateral wall of the nose, a periosteal elevator is inserted subperiosteal under the inferior turbinate, at the piriform aperture for 2 cm approximately, to protect the nasal mucosa (see fig. 5).

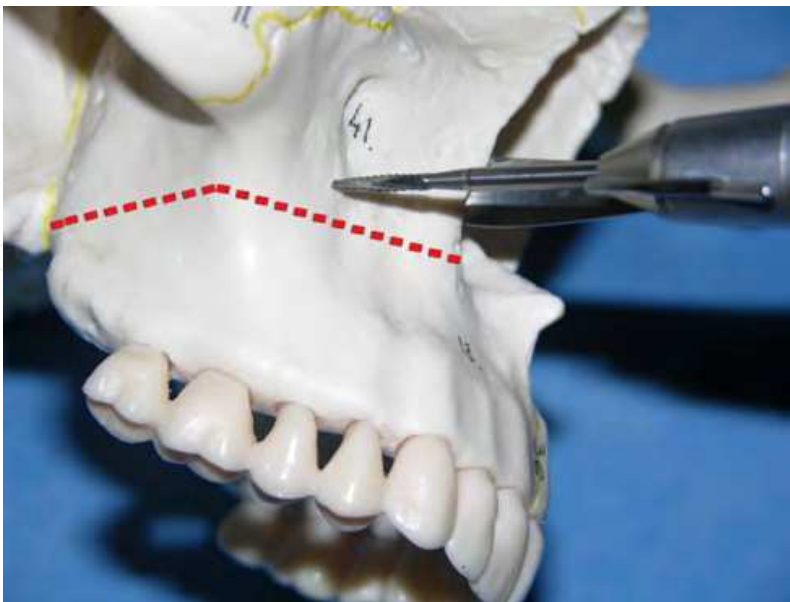


Fig. 5. Maxilla bone cut from the piriform fossae up to the tuber maxillae.

To complete the section of the lateral posterior wall of the maxilla, a flexible retractor must be placed under the periostium at the junction of the maxillary tuberosity with the

pterygoid plates, to avoid the risk of damaging the maxillary artery or one of its branches

In this area the osteotomy is directed inferiorly and posteriorly, under direct vision with high carefulness. Once the section of the lateral maxillary wall is completed, the direction of the saw is reversed so that the blade cuts laterally from the sinus to the outside: this shift allows an easy sectioning of the posterior maxillary wall.

Referring to the amount of maxillary impaction planned before surgery, adequate amount of bone will be removed by the saw or bur from the lateral piriform rim to the posterolateral sinus wall. In this posterior aspect, amount of bone removal will be less than planned for impaction, because of the bone thinness and telescopic movements frequently seen in this area.

The osteotomy line should always run at least 5 mm above the second molar roots to reduce the risk of devitalizing teeth. If an impacted molar is placed over the line, the osteotomy design must not be modified: it will be removed at the end of the procedure, after downfracture. The same procedure is repeated on the opposite side and wet gauzes are introduced in the posterior aspect of the wound to minimize blood loss.

At this point osteotomy of the septum and the lateral nasal wall are performed. A septal osteotome is carefully inserted along the septal crest of the maxilla under the intact nasal mucosa, in order to separate the cartilaginous and bony septum from the septal crest of the maxilla (see fig. 6).

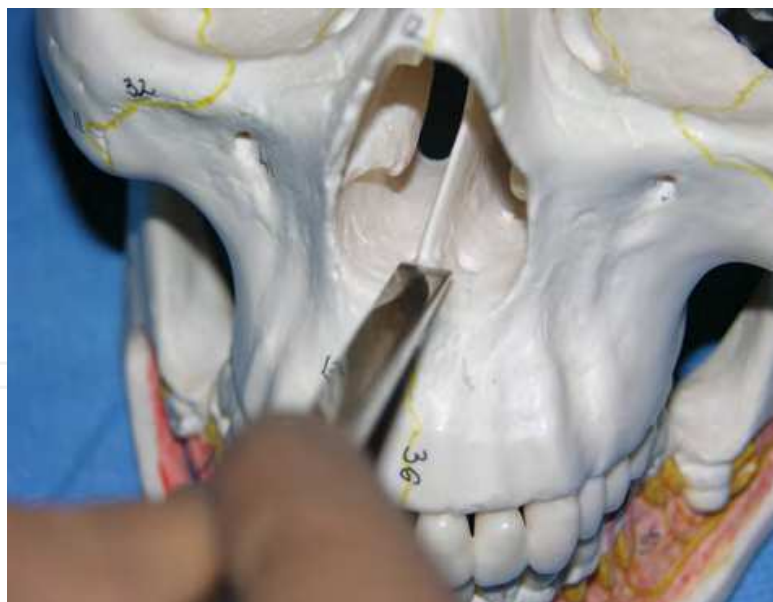

Fig. 6. Nasal septum disarticulation from anterior nasal spine and septal crest of the maxilla.

An elevator protect the nasal mucosa when the nasal lateral wall is sectioned by an osteotome directed posteriorly and inferiorly toward the perpendicular plate of the palatine bone. Particular care must be paid to this step of the procedure: bone of the lateral wall of the nose is thin with few resistance to the chisel; when the vertical pillar of the palatine bone is reached, resistance will increase with detectable change in sound when malleting the chisel (see fig. 7).

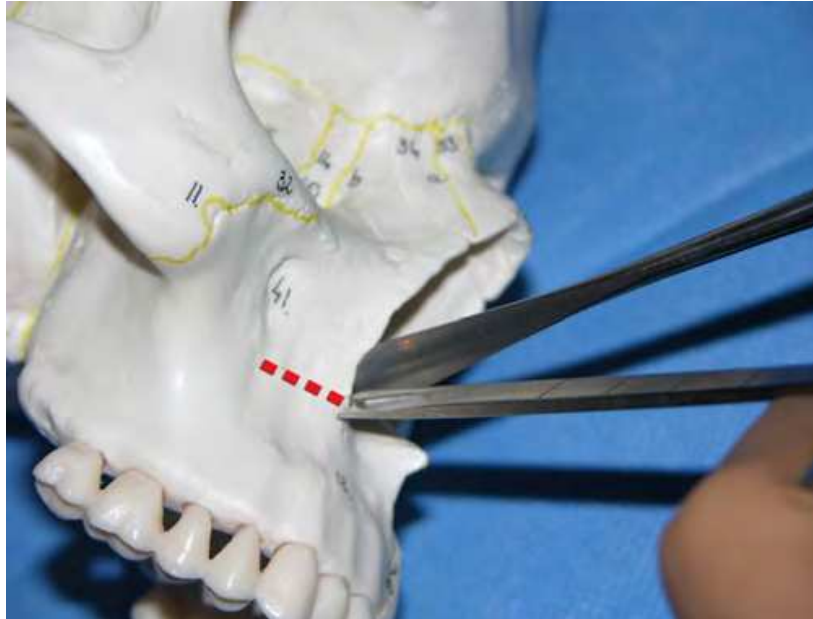


Fig. 7. Nasal wall osteotomy protecting nasal mucosa by elevator (dotted line for osteotomy inside the nasal cavity).

Partial section of the perpendicular plate of the palatine bone must be performed in order to avoid bad-fracture at the downfracture step resulting in an higher fracturing line than the nasal floor plane. This surgical event could lead to disruption of the orbit or even of the cranial base. If the osteotomy is carried out too deeply in the vertical plate of the palatine bone it could result in injury of the descending palatine vessels with a bleeding difficult to control before performing the downfracture. The opposite lateral nasal wall will be sectioned following the same procedure and the osteotomy of the nasal septum will be carried out. If the maxilla remains firmly attached to its bony base posteriorly after complete section of the buccal cortical plane, of the lateral walls of the nasal cavity and septum foot, osteotomy of the pterigomaxillary junction will be performed.

After removing gauze sponges previously placed, a retractor is inserted subperiosteally in order to place a curved osteotome at the junction of the maxilla and pterygoid plate. An index finger is placed on the palate at the amular notch region in order to feel the tip of the osteotome when malleting (see fig. 8). The same procedure will be performed on the other side and downfracture is performed using finger pressure on the anterior aspect of the maxilla or by Rowe forceps. During this procedure nasal mucosa partially attached is carefully elevated from the nasal floor.

Particularity when impaction of the maxilla is planned remaining vomer, septum, septal crest and lateral nasal walls are reduced by rongeur or bur, to accomplish any superior setting. After downfracture, mobilized maxilla freely move in all of the three planes. Usually the neurovascular bundle of the descending palatine vessels are commonly preserved and bone should be removed carefully from the posterior maxilla. If this bundle is injured bleeding can be controlled by packing, cautery or vascular clamps; sensibility in the maxillary area is usually preserved even performing these manoeuvres (Bouloux & Bays, 2000).

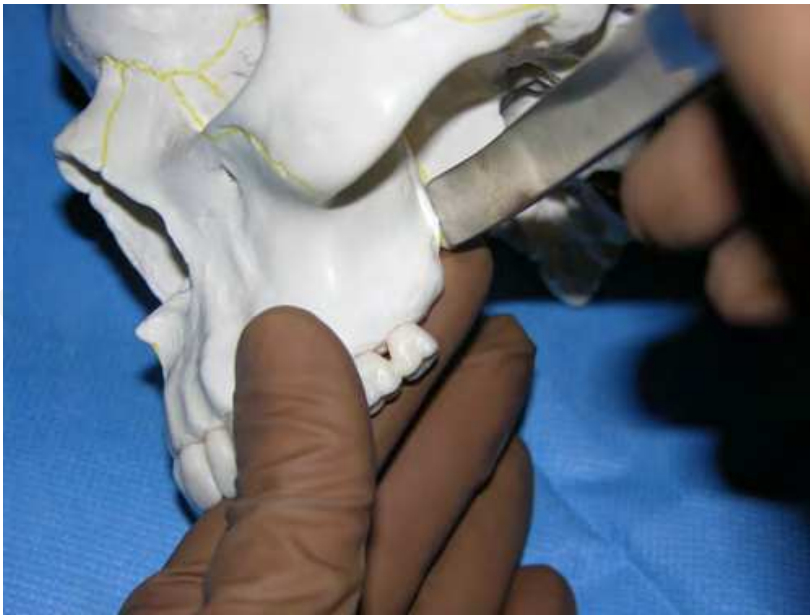

Fig. 8. Section of the pterygo-maxillary junction by curved chisel under finger control on the palatal side.

Also removing bone from the pterygoid plates can cause bleeding from the pterygoid muscles, usually controlled by packing or injecting dilute epinephrine solution. Bone interferences are common in this area and must be carefully eliminated for proper maxillary repositioning even if it's a time-consuming procedure. At this time an occlusal wafer splint is inserted and maxilla and mandible are fixed together by 25-Gauge wire for maxillomandibular fixation. Then the maxillomandibular complex with the inserted splint will be turned up to the proper position, detecting bone premature contacts and taking care not to dislocate condyles from glenoid fossae (see fig. 9). Measurement of the distance

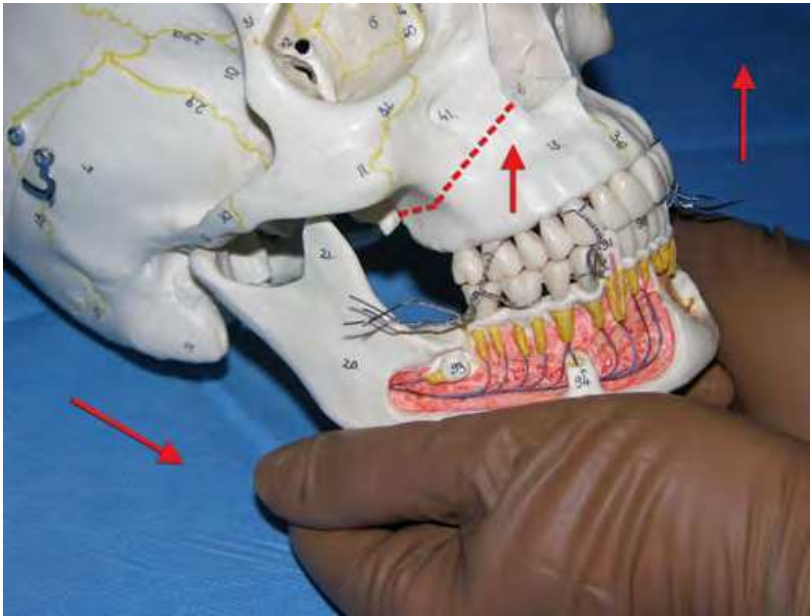


Fig. 9. Maxillary fixation after maxillo-mandibular block checking centric condilar position in the glenoid fossae.

between intraoral and extraoral reference points is performed to ascertain that proper maxilla repositioning has been achieved. Attention must be paid to bone precontacts causing mandibular condyle dislocation and septum deviation with nasal airflow obstruction. If more than 5 millimetres maxillary impaction is planned, also trimming of the inferior turbinates is suggested. Gross tears and nasal mucosa holes must be repaired by 4-0 Vicryl suture to minimize nasal bleeding.

3.3 Maxillary segmentation

If a segmented Le Fort I is planned for maxillary expansion, or for occlusal plane levelling for open or deep bite correction, or for space closure after dental extraction in Class II correction, the segmentation should be performed before the downfracture for better handling of the bone fragments. In the two pieces maxillary segmentation interdental osteotomy is performed between the central incisors roots, under finger control by the palatal side (see fig. 10).

For maintaining vascular supply of the maxillary bones, no more than three or at least four pieces segmentation must be performed, because risks of necrosis increase with multiple segmentation. Also the integrity of the palatal mucosa is mandatory to avoid necrosis problems of the anterior maxilla and teeth. For these reasons sagittal segmentation is usually performed in para-median sites, where bone is thin and palatal mucosa is thicker than the midline, avoiding risks of palatal mucosa perforation (see fig. 11). In the three pieces maxillary segmentation, interdental osteotomy sites are usually located between canine and bicuspidate roots, where a 3 millimetres space must be created with orthodontic treatment for parodontal safety (Dorfman & Turvey, 1979) (see fig. 11 and fig. 12). In this three pieces maxilla segmentation is performed placing the osteotomy sites in a bilateral position between the roots of canine and first bicuspids, lateral sites of the palate, and a transversal osteotomy of conjunction (see fig. 13).

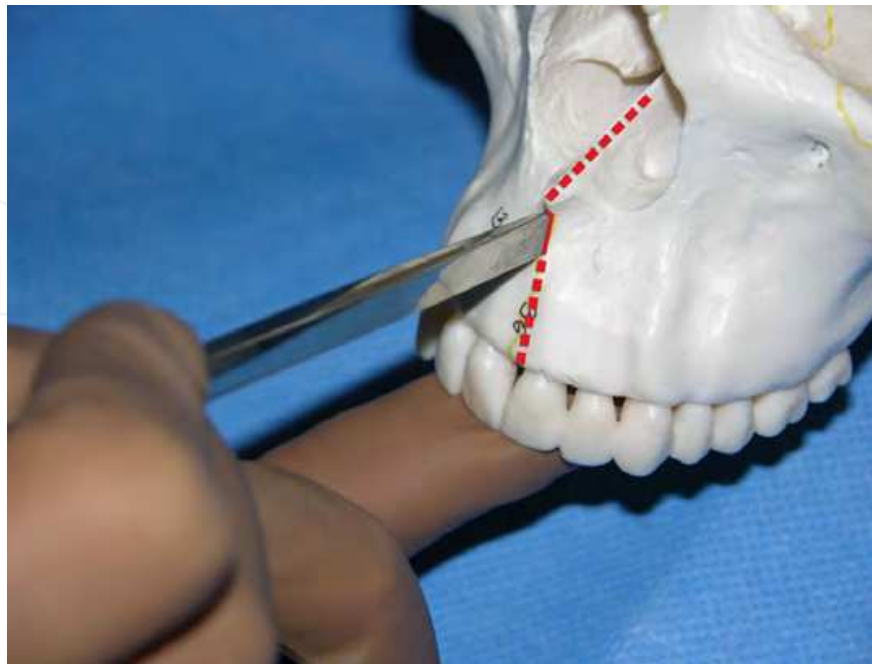


Fig. 10. Interdental midline osteotomy under finger control by the palatal side.

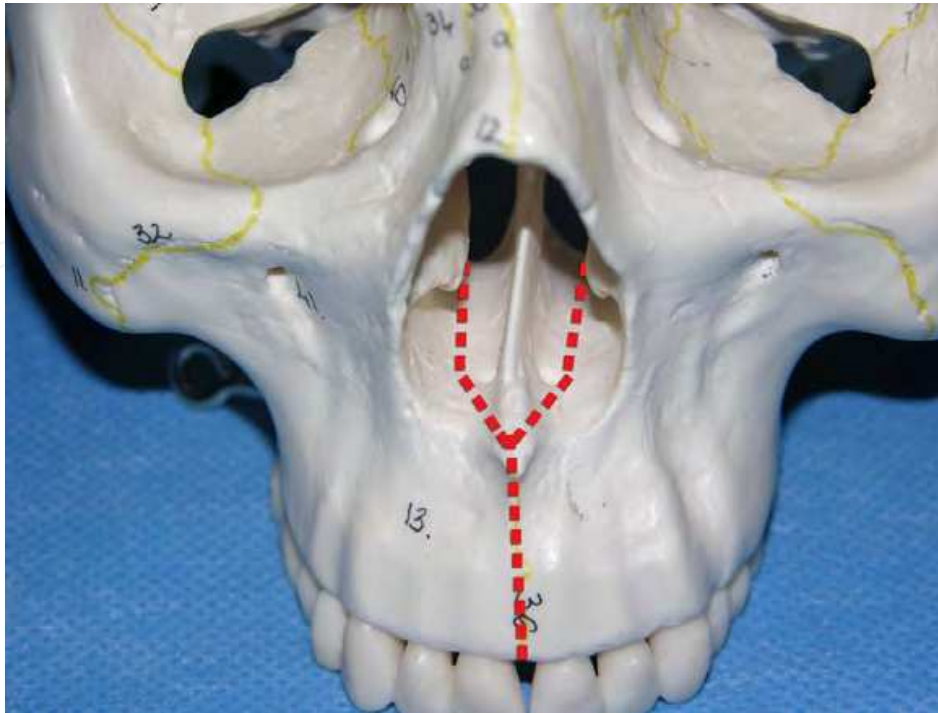


Fig. 11. Midline interdental and palatal para-median osteotomy for the two pieces maxilla segmentation.

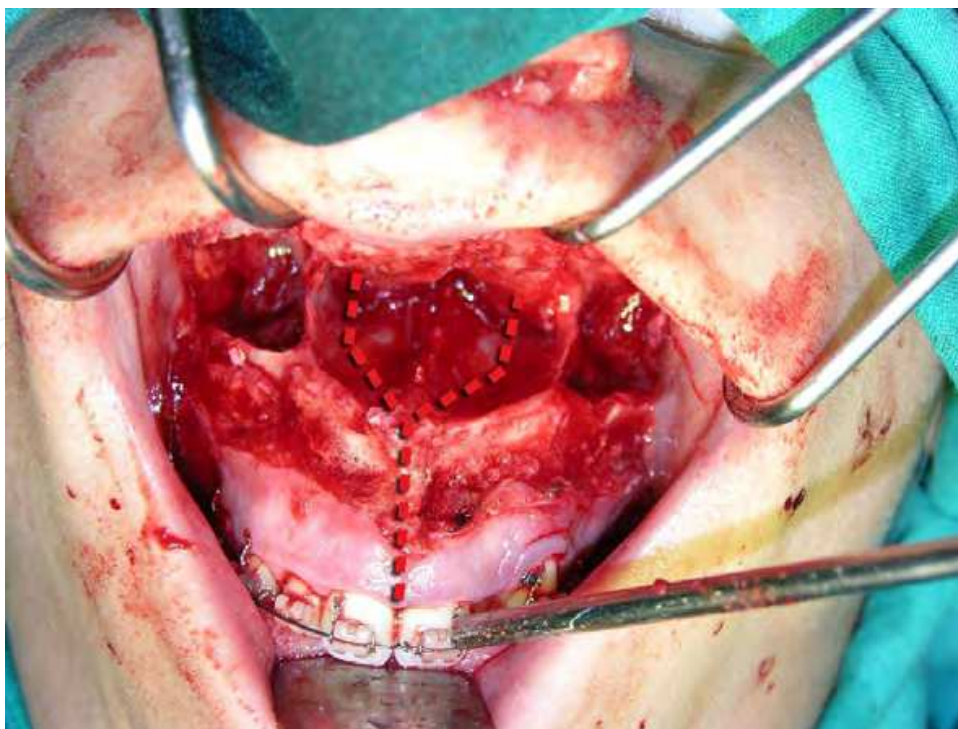


Fig. 12. Down fracture in Le Fort I osteotomy with possibility to perform maxillary segmentation.

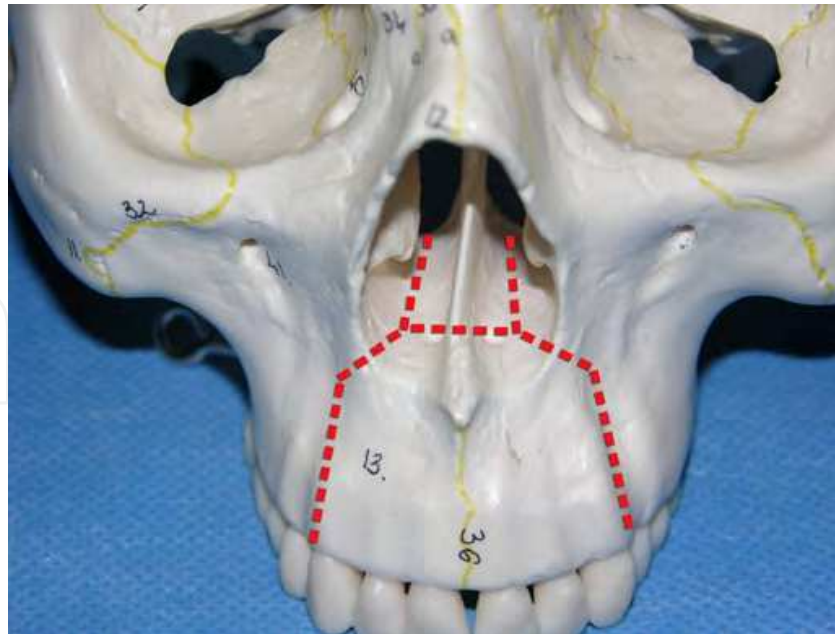


Fig. 13. Interdental and palatal lateral osteotomy plus transversal palatal osteotomy for the three pieces maxilla segmentation.

Even if this kind of segmentation is commonly performed in the Le Fort I osteotomy with down fracture, expansion and three dimensional repositioning (LFI-E), nowadays segmented Le Fort I is frequently associated with other techniques like surgical assisted rapid palatal expansion (SARPE), tooth-borne or bone-borne distraction for specific consideration about related problems, complications and indication:

1. In maxillary two pieces sagittal segmentation for palatal expansion, relapse is a frequent problem, in association with heavy limits to palatal expansion for fibro-mucosa inextensibility and related risks of aseptic necrosis for excessive tension of the fibro-mucosa (Cortese et al., 2010; Haas, 1980; Wertz, 1970).
2. Even if in maxillary three or four pieces segmentation for palatal expansion and occlusal plane levelling, fibro-mucosa tension is distributed in multiple sites, the aforementioned problems and complication occur any way for the extensive dissection need of the palatal fibro-mucosa ; moreover multiple segment management during operation is difficult.
3. About the maxillary segmentation technique for space closure after bicuspidate extraction for Class II correction (Wassmund), it is nowadays frequently avoided in favour of mandibular advancement alone or in combination with maxillary expansion for correct interdental arches relations after mandibular advancement .

For more extensive information about bone-born maxillary expansion techniques, refer to the specific paragraph of this chapter (Palatal expansion: bone born techniques).

3.4 Fixation

Before proceeding with fixation, it is advisable to expose the nasal floor and the posterior maxillary area and wash with saline solution to remove blood clots. Maxillary fixation requires occlusal splint insertion to achieve the correct maxillary position. In the classic

technique occlusal splint are taken in place by four transosseous wire sutures (26-Gauge) passing through holes in the piriform area and zygomatic buttress; in this areas the thickness of the bone ensures good retention. To reinforce stability an additional suspension wire (24-Gauge) is placed through a hole in the piriform region, left exposed in the buccal fold with a loop, connected subsequently to the mandibular arch wire to reduce the maxillo-mandibular shift.

In our experience occlusal splint is kept in place by interdental arch wire fixation (26-Gauge), placed on orthodontic arch wire or on dental brackets; maxillomandibular complex is turned upward in position, checking for bone interference that have to be accurately eliminated to avoid dislocation of the condyles resulting in final maxillary malpositioning. For this reason also occlusal splint retainment and maxillary positioning by transosseous wire sutures in the piriform area are avoided, preferring manual positioning of the maxillomandibular complex after studying occlusion at this step on articulator, paying attention not to displace condyles from the centric position in the glenoid fossae. For this purpose maxillomandibular complex must be positioned applying manual pressure on the inferior border of the mandible, particularly in the Gonion area, avoiding excessive pressure on the symphysis.

Nowadays the most common way to achieve maxillary fixation is by rigid osteosynthesis with four miniplates and screws; in this procedure maxilla is placed in the new position, then two bone plates (usually small, semirigide, metal or biodegradable) for each side are set to the piriform rim and to zygomatic buttress. The shape of the plates should be similar to the edge of the maxillary walls, to avoid displacement of the bone and unexpected malocclusion. Although stabilization could be reached with one screw holding any repositioned segment, it is recommended to place two screws on each side of the osteotomy line (four screws for each plate). Three or four maxillary segments could not require additional plates, because the fragments are held in the occlusal splint.

After rigid fixation, maxillomandibular stabilization devices are removed and the occlusion must be checked into the splint. With a gentle movement of the fingers posed on the inferior border, the mandible is rotated to the final position with teeth firmly locked into the splint. In case of interferences (deviations or open-bite) maxillary position is evaluated and eventually corrected in order to obtain proper maxillary position with mandibular condyles in centric position in the glenoid fossae. Usually the bone interference is placed posteriorly and medially: once removed, wires on one of the sides of osteotomy are replaced and re-established the maxillomandibular fixation, the entire bony complex is rotated into correct position and the occlusion checked again as before. This procedure is repeated until the surgeon can achieve the expected occlusion, with the mandible placed passively into the splint. If an early jaw function will follow the surgery, all interferences should be removed from the surface of the splint.

4. Bone grafts

After osteotomy and repositioning of the maxilla, an incomplete contact between the lateral bony walls can occur because of their thinness. The bone in the premolar zone can heal with development of fibrous tissue, but this event does not injure maxillary stability or the sinus health. Crucial regions for a good healing are the piriform rim and the zygomatic buttress:

when these areas are in contact a proper osseous union is expected. Otherwise, significant vertical defects (>3 mm) must be filled with bone grafts. Bone grafting helps the stabilization of the new maxillary position and allows faster healing of the bone; sometimes these grafts come from bone removed during surgery and saved sequentially.

Bone scraps can be forced and locked between bone segments, or supported with fixation devices.

Particularly in cases of vertical dimension increase of the maxillary bones with gaps > 3 -4 mm rigid fixation by miniplates alone cannot support bone healing, resulting in final compromising of the maxilla stability. In these cases bone grafts are recommended from iliac crests (first choice) or from mandible or calvaria.

The bone grafts can be fixed in the proper position to fit the bone gaps by wire or screw fixation, or by the bone plates used for maxillary fixation across the defects. Additional bone can be placed over the remaining defects of the lateral maxillary walls, but they have to be stabilized primarily by fitting into the defects or by rigid membranes, because displaced bone grafts in the sinus cavities can result in bony sequestration with complain of nasal bad smelling secretions. In these cases if symptomatology doesn't resolve within 15 days, the bone sequestration has to be removed by lateral sinus wall approach; if the infection will interfere with osteotomy bone healing, the final stability might be compromised.

Allogeneic bone grafts from bank bone have also been employed with similar results to autogenous bone grafts and the advantage of avoiding the necessity of a donor surgical site, but the vascularization and healing are delayed when allogenic bone is used.

Also alloplastic material like hydroxyapatite have also been used into maxillary osteotomy defects, with good properties for stabilizing the bone defects, but the material is not replaced by bone; for this considerations, autogenic bone grafts is still the first choice for maxillary grafting.

5. Soft tissue closure

Maxillary advancement is classically associated with lip shortening; some Authors suggest that this problem is related to excessive tissue compression when suturing with large amount of tissue capturing when stitching. Others suggest that scar retraction or failure to suture the transacted mimic facial muscles are the reason for lip shortening and alar base widening; but probably the main factor is the increase of soft tissue tension after maxillary advancement.

To avoid this problem, two different techniques, alar cinching and double V-Y suture, are commonly performed in soft tissue closure (Howley et al., 2011).

The alar cinching technique is usually performed by a 3-0 Vicryl suture passed through the alar bases of the nose, from lateral to medial on one side, and from medial to lateral on the opposite site; the median region is included in the stitch passing the suture in a little hole of the bone at the anterior nasal spine site. The stitch is tightened until the alar base width will be identical to that dimension measured by a calliper before the surgery.

The muscle suturing technique is performed with four mucoperiosteal stitches, two for each side, passed for the nose alar base and the inferior mucosa at the paramedian region with an

anterior direction, in order to pull the lip and the alar base medially when tightened. The posterior suture begins at the first molar region on the superior border of the wound and is passed in a more medial direction at the canine or premolar region of the lower side of the wound. In this way the wound includes periosteum and muscle layer when the needle is inserted. When tightening this sutures, pressure on cheek skin has to be performed in order to allow skin repositioning in a more anterior fashion.

The V-Y mucosal closure with 4-0 Vicryl is performed in a double lateral position in order to avoid excessive bulging in the midline of the upper lip. Placing the V-Y suture in the canine region upper lip advancement and vermillion exposition is uniformly placed on the entire upper lip, minimizing any vermillion surface deficiency on the anterior aspect. Also the bulk from the advancement technique is not concentrated in the midline area.

At the end of the operation a nasogastric tube is placed in order to prevent blood collecting in the gastrointestinal tract, from nasal or paranasal mucosal bleeding immediately after surgery.

6. Problems and complications

Nasal airway obstruction frequently happens in the immediate post operative period; for this reason good care must be taken to keep nasal airways clean from blood crusting and secretions by suction and by wet gauze cleaning, particularly in cases of intermaxillary fixation.

Conspicuous facial oedema frequently may appear immediately after surgery, maximum degree is reached in two or three days and it progressively decrease in two weeks; useful method to decrease the oedema are corticosteroid therapy one day before and two or three days after surgery, upward head position during day and night and cold package by ice for one day after surgery

Also residual bleeding is one of the most common problems in the immediate post operative phase; lack of sensibility for infra orbital or alveolar nerve are the most common complications that usually resolves in at least 6-12 months.

With rigid fixation with miniplates and screws, intermaxillary fixation is not anymore necessary; in case of inter-maxillary fixation necessity for multiple days, extrusion of the frontal teeth frequently happens, for these reason intermaxillary fixation by bone anchorage is recommended.

The most dangerous problem in immediate post operative time after maxillary surgery is partial or total maxillary bone necrosis for vascular supply failure.

Maxillary aseptic necrosis is usually related to the degree of vascular compromise and is a very rare complication occurring in less than 1% of cases after complete Le Fort I osteotomy (Lanigan et al., 1990, 1997; Kramer et al., 2004; Parnes & Becker, 1972).

Failure of the blood supply to the maxilla after the down fracture is usually related to lesion of the descending palatine artery during the osteotomy, perforation of the palatal mucosa when cutting the maxilla in two segments particularly in the median aspect where the palatal fibromucosa is thinner, and excessive tension or stripping of the palatal mucosa when expending the transversal dimension of the maxillary arch. Palatal devices may also cause vascular defeat by pressure on the soft tissue of the palate, particularly in segmented Le Fort I osteotomy. Problems related to a vascular necrosis of the maxillary bones may

include loss of tooth vitality, periodontal defects, tooth loss and a major or minor part loss of the alveolar bone up to necrosis of the entire maxilla (Bell et al., 1995).

Risks and complications related to aseptic necrosis of the maxilla after major maxillary surgery is also related with vascular anomalies, craniofacial dysplasia and orofacial clefts probably related to scar fibrosis after prior surgery. Aseptic necrosis of the maxilla should be treated by careful hygiene of the mouth with curettage and cleansing of the necrotic tissue, antibiotic therapy, heparinization and hyperbaric therapy (Nilsson et al., 1987; Singh et al., 2008).

Important complications during major maxillary surgery are bad fracture of the maxillary bones particularly at the down fracture surgical time. At this surgical step much attention must be paid to avoid pterygoid plate fracture, usually at a low level of the plates; in a few cases pterygoid plate fracture can cause trauma to the base of the skull with vascular and ophthalmic complications (Kumar et al., 2007; Silverstein, 1992).

Complications in the immediate post operative time are related to malpositions of the nasal septum in relation with nasal floor and mandibular condyle dislocation in the glenoid fossae. In case of major dislocations reoperation is recommended.

Late complications may include major periodontal defects or loss of the vascular supply to the teeth adjacent to the sectorial osteotomy site in segmented Le Fort I operations.

7. Consideration on nasal airway and sinus cavities

Superior repositioning of the maxilla is a procedure commonly used for the correction of vertical maxillary excess: concern for the effect of this procedure on nasal respiration may be appropriate, since superior repositioning of the maxilla may decrease the volume of the nasal cavity, particularly if the septum is not shortened and out of the proper mid-position.

Following results may apparently be in contradiction with the assumption that nasal air flow space is decreased when the palate is impacted in maxillary surgery; but an explanation can be found in the support gain for nostrils when the maxilla is advanced or superiorly repositioned. Scientific studies have been performed evaluating pre- and postoperative nasal-resistance in patients who underwent superior repositioning of the maxilla by the Le Fort I down-fracture procedure. In case of superior repositioning of the maxilla nasal respiratory function was not usually reduced; these findings indicate that superior repositioning of the maxilla, with or without involvement of the nasal floor by osteotomies, usually results in decreased nasal resistance (Turvey et al., 1984; Walker et al., 1998).

Support gain will determinate nostril angle and nasal valve widening resulting in final decrease for nasal airflow resistances.

When analyzing patients who underwent a one-piece Le Fort I-osteotomy with anterior and superior repositioning of the maxilla, using cephalograms, rhinological inspection, anterior rhinomanometry and acoustic rhinometry, results show a significant increase in interalar width and in cross-sectional diameter at the nasal valve too. The mean total nasal airflow is unchanged, indicating no increase in resistance despite decreased intranasal dimensions (Erbe et al., 2001).

These findings show that surgical maxillary impaction rarely compromise nasal breathing; conversely, an increase in nasal patency is usually observed in most of the patients undergoing orthognathic surgery with maxillary expansion or advancement: a deformation of the nasal valve from a teardrop-shape to a postoperatively more rounded fashion was claimed to be responsible for this change (De Mol Van Otterloo et al., 1990).

Maxillary advancement also involves the aesthetic of face and profile, with significant increasing of the nasolabial angle, nasal tip angle, nasal tip inclination, alar base width and columellar angle; also the columellar length and nostril axis angle usually decrease, while the nostril area doesn't show any significant change. In a recent study analyzing nasal tip and alar base width changes using Cone-Beam Computer Tomography (CBCT) in adults with skeletal class III deformities who underwent Le Fort I advancement and impaction osteotomy associated with mandibular setback, an anterosuperior shift of the nasal tip and widen of the alar base width and nostril was reported (Park et al., 2011). CBCT analysis can be an available tool for measurement of both skeletal and soft-tissue changes enabling, moreover, 3D assessment of nasal morphologic changes.

Also in other studies, an increase in nasal airflow and a decrease in nasal resistance are usually observed in the maxillary impaction and advancement.). After bimaxillary surgery consisting of a 1-piece Le Fort I osteotomy advancement combined with a bilateral sagittal split osteotomy, active anterior rhinomanometry show an increase of mean and median total nasal airflow and of nasal resistance (Ghoreishian & Gheisari, 2009).

Bimaxillary surgery (maxillary advancement and mandibular setback) for treatment of Class III malocclusion, appears to be more effective than mandibular setback alone into keeping patency of the upper airway space. A computed tomography study was performed to evaluate the morphologic changes at the level of soft palate and base of tongue in patients treated with these two different types of surgery. Results show a significantly less reduction in anteroposterior dimensions of the airway in cases treated with bimaxillary surgery, at least not statistically significant; while in the mandibular setback surgery group, the cross-sectional area of the airway decreased significantly (Degerliyurt et al., 2008).

Even if nasal breathing actually increase after maxillary advancement and impaction, in cases where a considerable amount of superior repositioning is planned, much attention must be paid in septum repositioning without deviations or bulking by proper remodeling or reductions of the osteo-cartilaginous portions, septal crest of the maxilla and lower turbinate (Haarmann et al., 2009; Posnick et al., 2007).

Because aesthetic is the main motivation for most of the patients who undergo this kind of surgery and alar flaring of the nasal base is often an unaesthetic modification, the resuturing of the transverse nasals muscle or the alar base cinch suture must be performed to avoid excessive widening of the alar base. Techniques are described in the related paragraph (Soft tissue closure) of this chapter.

8. Classic maxillary segmentation techniques: Anterior sub-apical osteotomies

Segmented maxillary osteotomy surgery was usually performed in the decade of the sixty years to achieve correction of class II malocclusions by frontal teeth set back following the

techniques of Wassmund and Wunderer. With the evolution of the Le Fort I osteotomy techniques this anterior subapical osteotomy for pre-maxilla set back was relegated for few particular cases because new concepts about beauty of the face and cephalometric and photometric analysis suggest that maxillary and upper frontal teeth are usually in good position for most of the patients with class II malocclusions. (Arnett & Gunson, 2010)

Also in that few cases where upper frontal teeth are in a protruded position these condition is frequently associated with a narrowed palate : by transversal palatal expansion a consequent set back of the upper teeth is achieved by an orthodontic dentoalveolar movement related to basal bone and dentoalveolar enlargement in the transversal dimension.

For these reasons isolated anterior subapical osteotomy of the maxilla following the classic Wassmund technique is nowadays rarely performed, relegated to particular indications: cases of anteriorly positioned maxilla with normal transversal palatal dimension.

8.1 Surgical technique

The classic Wassmund technique with ostectomy of the palatal premolar segment after extractions is performed on a subperiosteal plane leaving extensive palatal and buccal soft tissue pedicles in order to preserve premaxilla blood supply.

Under general anaesthesia, after infiltrating the buccal mucosa in the canine-bicuspid region, a vertical incision is performed bilaterally between canine and bicuspid (see fig. 14); no solution injection should be performed in the palatal site in order to preserve palatal vascular supply.

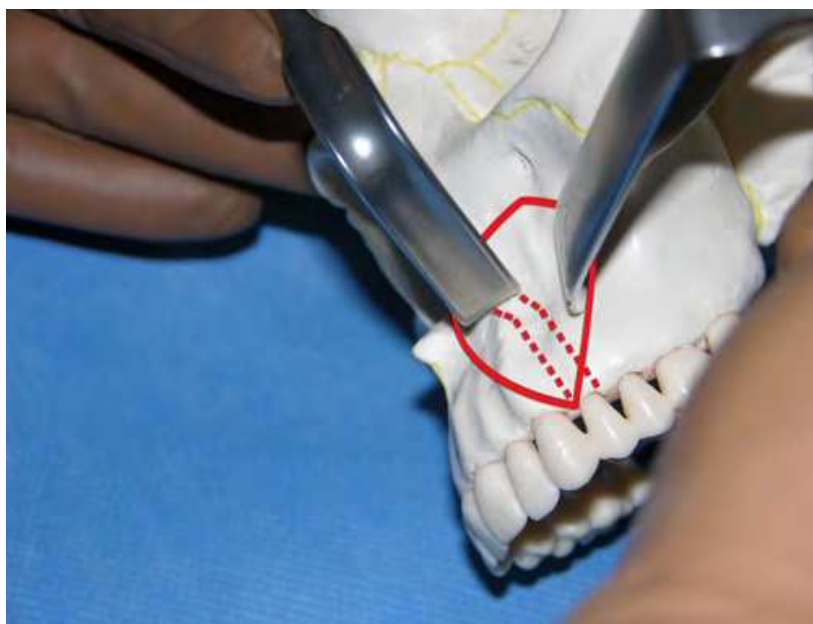


Fig. 14. Buccal mucosa incision at the premolar site with mucoperiosteal flap elevation (continuous line) and osteotomy (dotted line).

Leaving the canine distal papilla intact and in bone contact, a mucoperiosteal flap is elevated from the premolar and tunnelized up to the piriforme aperture. Also nasal mucosa

should be carefully elevated from nasal floor together with the palatal mucosa in order to consent palatal bone segment ostectomy (see fig. 15).

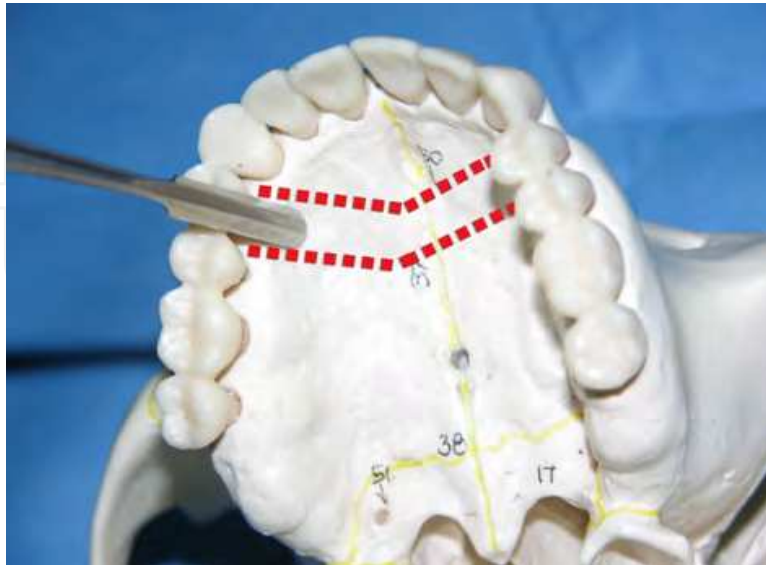


Fig. 15. Palatal mucosa elevation for bone removal.

Before this time, first bicuspid must be extracted if planned, otherwise sufficient space between cuspid and first bicuspid roots should be orthodontically created for planned bone segment removal.

Ostectomy may be performed by bur or in combination with oscillating saw and chisel, starting from the lateral aspect of the maxilla and extending the bone cuts to the lateral wall of the nose and the palate. Amount of bone removal must be carefully evaluated and no more than the planned amount must be performed leaving 2 mm of bone over the adjacent teeth roots (see fig. 16). Then the nasal septum will be disarticulated from the nasal floor by an osteotome and the mobilized premaxilla will be properly repositioned by an occlusal splint.

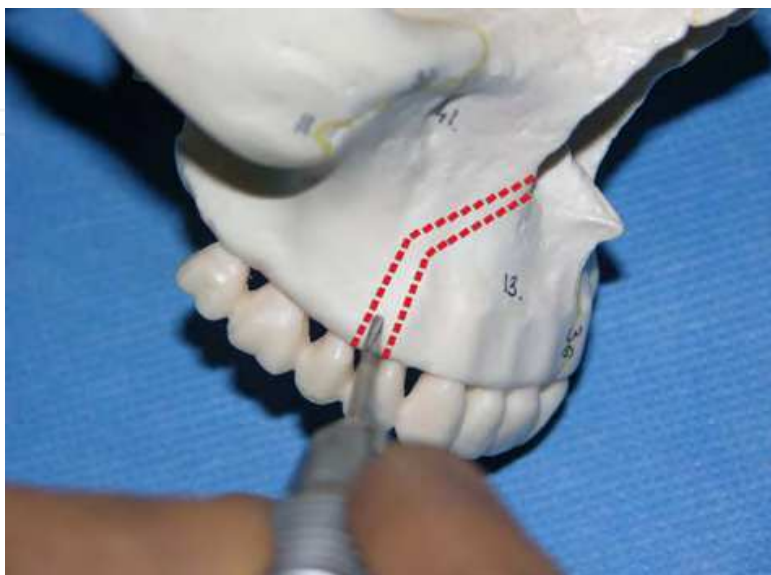


Fig. 16. Buccal bone removal at the inter-bicuspid site or after bicuspid removal.

The anterior fragment can still be splinted in the midline after mucosa incision in the interincisive site; fixation will be performed by miniplates and screws on the facial aspect of the osteotomy at the piriform rim and on auxiliary orthodontic arch wire previously prepared after maxillomandibular fixation on the occlusal splint.

Wound closure will be performed by continuous suture in the buccal aspects and single suture in case of palatal wound to preserve palatal vascular supply.

In most of the cases fixation stability is firm and no additional maxillomandibular fixation is required in the post-operative time.

9. Classic maxillary segmentation technique: Lateral sub-apical osteotomy

Isolated posterior subapical osteotomy is a segmental technique that can be performed in particular cases; following Schuchardt techniques lateral sub apical osteotomies can be performed in case of anterior open bite, unilateral cross-bite or in case of molar intrusion planning, particularly in pre-prosthetic surgery for dentoalveolar segment repositioning when upper molar extrusion occur after lower molar extraction (Ermel et al., 1999).

9.1 Surgical technique

This technique can be performed under general anaesthesia or lower anaesthesia or conscious sedation; surgical treatment must be planned in conjunction with orthodontist to align teeth and create sufficient space between the teeth roots (3mm) for bone osteotomy. Also in preprosthetic surgery osteotomy must be planned in cooperation with the prosthodontist to facilitate replacement of the teeth.

After infiltrating with an anaesthetic-vasoconstrictor solution (2% lidocaine 1:100,000 epinephrine) in the buccal mucosa a mucoperiosteal incision is made from the upper canine to the tuberosity; a mucoperiosteum flap is elevated superiorly leaving the mucoperiosteum inferior to the incision attached to the bone to preserve proper vascular nutrition to the posterior maxilla bone fragment. Also in the area of the bone vertical cut distal to canine periosteum is carefully elevated tunnelling the mucosa; in the palatal region usually no incision are necessary for bone cut, only in cases of medial repositioning necessity, bone removal is required and a paramedian palatal mucosa cut is necessary. No vasoconstrictor infiltration is performed in the palatal mucosa to preserve vascular supply. Bone cuts are performed by bur in the buccal aspect and by a curved chisel for the palatal cuts through the sinus cavity. Only in cases where bone removal is required from the palatal bone, a cylindrical bur is used through the palatal mucosa incision. At this time the maxillary tuberosity is separated from the pterygoid plates using a curved osteotomy. Performing bone cuts particular attention must be paid to preserve vascular supply of the bone fragment from facial and palatal mucosa pedicles. After appropriate bone removal the posterior dentoalveolar segment of the maxilla is repositioned by a previously prepared occlusal splint.

Fixation of the fragment is performed combining rigid fixation by mini plates and screws in the buccal aspect with auxiliary orthodontics arch wire and occlusal splint.

When lateral repositioning of the dento alveolar fragment is required amount of palatal mucosa may be insufficient for closure; and incision on the contralateral palate mucosa may be required to mobilize a flap over the palatal osteotomy to allow bone closure without

tension. Usually maxillomandibular fixation is not required for the post operative days; occlusion splint fixation for the maxilla can keep dento-alveolar fragment fixed for clinical healing.

9.2 Problems and complications

Facial oedema after sectorial maxillary surgery may be conspicuous and not be strictly correlated to the trauma of the procedure; maximum degree is reached in two or three days and progressively decrease in two weeks.

Useful method to decrease the oedema are corticosteroid therapy one day before and two or three days after surgery, upward head position during day and night and cold package by ice for one day after surgery.

Sensory supply to the mucosa and teeth may be altered for four months to one year; in some cases teeth may maintain vascular supply even if the response to the cold is negative. Also upper lip and paranasal area sensibility may be altered in an immediate short time after surgery.

Forty day after surgery are usually sufficient to remove splint and auxiliary arch wire when the dento-alveolar segment is clinically firm.

Complication in segmental maxillary osteotomy are quite rare and are usually related to periodontal defect in osteotomy sites and failure of the vascular supply to the adjacent teeth: to avoid this complications attention must be paid in leaving 3 mm of bone coverage on adjacent teeth to the osteotomy site.

Also failure to entire dento-alveolar bone segment may happen particularly when the bone segment is not totally firm: in this case the entire dento-alveolar segment can be lost and the repair may be attempted by prosthetic technique or reconstructive surgery.

10. Palatal expansion: Bone born distraction techniques

Transversal maxillary hypoplasia in adolescents and adults is a frequently seen pathology with substantial effects on occlusion with cross-bite malocclusions and dental crowding, on breathing with nasal airflow limitations, on smile aesthetic with buccal corridors evidence when smiling and on TMJ dysfunctions.

Treatment of these dysmorphisms is maxillary expansion which is commonly performed during the growing age by orthodontic appliances (Hyrax and Haas), promoting growth at the suture through the deposition of new bone at the sutural margin by the adjacent cellular layer (Gautam et al., 2009). After maxillary skeletal maturity has been reached, orthodontic treatment can't provide a stable widening of the constricted maxilla. Even if the available literature is inconclusive and in conflict regarding time of closure of the palatal suture ranging from the possibility to easily separate the intermaxillary and palatine sutures at as late an age as 35 years to data expressed (Koudstaal et al., 2008), in clinical practice skeletal correction via orthopaedics appliances is considered successful until the age of skeletal maturation (14-15 years). After this age a combination of surgery and orthodontic treatment is suggested for widening of the maxilla in skeletally matured patients.

Up to two years ago there were three kinds of different techniques for maxillary correction in adult patients after maturation of the facial skeleton has occurred:

1. the segmental Le Fort I osteotomy (LFI-E) (Charezinski et al., 2009; Bailey et al., 1997; Morgan & Kirk, 2001; Phillips et al., 1992; Reinkingh & Rosenberg, 1996);
2. the surgically assisted rapid maxillary expansion (SARME-dental) by a tooth borne devices (Hyrax),
3. the surgically assisted rapid maxillary expansion by bone borne devices (SARME-bone) (Mommaerts, 1999; Pinto et al., 2001; Ramieri et al., 2005);

The first technique allows a simultaneous correction in the three planes of the space in one surgical operation, but it is considered one of the least stable orthognatic procedure (Phillips et al., 1992; Pinto, 2009).

Other negative aspects of this technique are the difficulties found in obtaining large amount of expansion because of the palatal fibromucosa traction, bone fragment tipping, root damage risks in the three peaces segmentation, vascular risks of bone necrosis for premaxilla fragment after wide deperiostation of the palatal bone for allowing segmental movements and difficulties in bone fragment managing at the fixation time during surgery (Pinto, 2009; Quejada et al., 1986; Lanigan et al., 1990).

Other unfavourable occurrences associated with the LFI-E are severe intra and post operative haemorrhage after transectioning of the descending palatine or other large blood vessels, oroantral or oronasal fistulas, permanent mobility the maxillary fragments and loss of gingival papillae after large immediate widening of the bone fragments (Pinto, 2009).

The second technique SARME-dental requires a two steps surgery with second operation for maxillary advancement, rotation or occlusal plane variation accomplished by a complete Le Fort I osteotomy.

Advantages in this technique consist of new bone formation achieved by osteodistraction and new soft tissue gain achieved by distraction histogenesis particularly useful at the palatal fibromucosa site for avoiding resistance in the expansion movement.

Disadvantages of this technique are related to the tooth borne forces (cortical fenestration with parodontal defects, dental root reabsorption, dental tipping and relapse (Koudstaal, 2009).

Also the third technique SARME-bone requires a two steps surgery for expansion and tridimensional maxillary position correction. This technique avoids teeth related disadvantages of the aforementioned SARME-dental related to the use of a tooth borne appliance because of the employment of the bone borne devices (Cortese et al., 2004, 2010; Matteini & Mommaerts, 2001; Marchetti et al., 2009).

Several bone borne distractor devices have been projected and used in this kind of surgery in the last few years; the most widely used are the TPD device by Mommaerts and the Rotterdam Distractor.

The transpalatal distractor (TPD) (CE 9001, Surgi-tec, Bruges, Belgium) was developed in 1999. The module consists of a two-cylinder screw attached to abutment plates fixed to the palate with screws. The Rotterdam palatal distractor (CE-0297, KLS Martin, Postfach 60, D-78501 Tuttlingen, Germany) is a bone-borne distractor made of titanium grade II based on

the mechanical design of a car jack. The two abutment plates (5 x 12 mm) contain 6 nails, each 2 mm long. The activation part consists of a small exagonal activation rod, positioned directly behind the maxillary central incisors. By activating the distractor, the nails of the two abutment plates penetrate the bone and the device is stabilized automatically and no screws are necessary to fix the distractor to the bone.

Major advantages of the bone borne devices are that the forces are directly applied to the bone nearly to the centre of resistance of the maxillary bone avoiding dental tipping and maintaining segmental bone tipping to a minimum level. Relapse of maxillary expansion after distraction or segmented Le Fort I is a widely recognised risk (Chamberland & Proffit, 2008).

Problems concerning the use of the aforementioned two types of palatal distractors are related to the poor stability of the appliances concerning the poor retention on the palatal site and the poor rigidity of the devices. In the authors' experiences with these appliances, problems are related to the absence of fixation screws on the palatal vault and to the possibility of movement of the expansion module with the plates connected to the palatal vault.

According to the Paley classification, these can cause two kinds of complications: detachment of the appliances from the palatal vault with swallowing risks; loose of control of the distraction vector during the expansion phase with asymmetric expansion (Koudstaal, 2009) and three-dimensional malposition of the two maxillary fragments at the end of the distraction. To overtake these limits a new device was developed and used by the Author (Cortese, 2003, 2010) named Palatal Distractor Device (PDD) (see fig. 17).

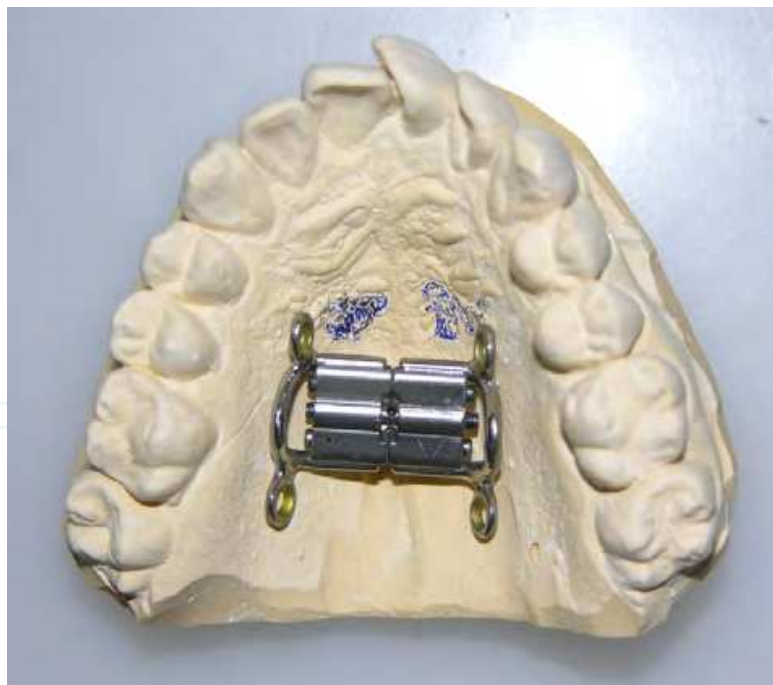

Fig. 17. Rigid bone borne palatal distractor device.

10.1 Appliance design

The functional components of the PDD are a Rematitan titanium expansion jackscrew (Dentaurum, Pforzheim, Germany) welded with 2 titanium miniplates (Stryker Leibinger,

Leibinger, Germany). These components are intended to combine a simple expansion system (titanium expansion screw) with a well-tested fixation system (miniplates and screws). A triangular bar is welded to the miniplates to allow proper expansion of the alveolar bone. The PDD is cast on patient models, and activation is performed transorally at its medial part, using a common key for the expansion screw. One full turn is equivalent to an expansion of 0.8 mm; the full expansion is 10 mm. The rationale for using a jackscrew for the activation system is to obtain a transversal activation system on a horizontal stable plane, to avoid inclination of the 2 maxillary bones during activation. With the PDD, it is possible to ensure stability of the 2 maxillary bones in the sagittal and horizontal planes during activation, with palatal distraction in association with an incomplete Le Fort I osteotomy. Advantages of this distractor in comparison to the 2 other palatal distractors (TPD by Mommaerts and Rotterdam palatal distractor) and other most common palatal distractors consists in its intrinsic stability in the three plane of the space because of the jack screw expansion system and the three points of anchorage for each maxillary halves (two screws and one triangular bar for each side).

Because of this characteristics a segmental bodily movement is obtained with full control in the three planes of the space in the cases treated by Le Fort I osteotomy, midline segmentation and maxillary distraction by PDD (See fig. 18). On the other hand the other types of palatal distractors can't assure this stability because they haven't any intrinsic rigidity and have only one point of force application.

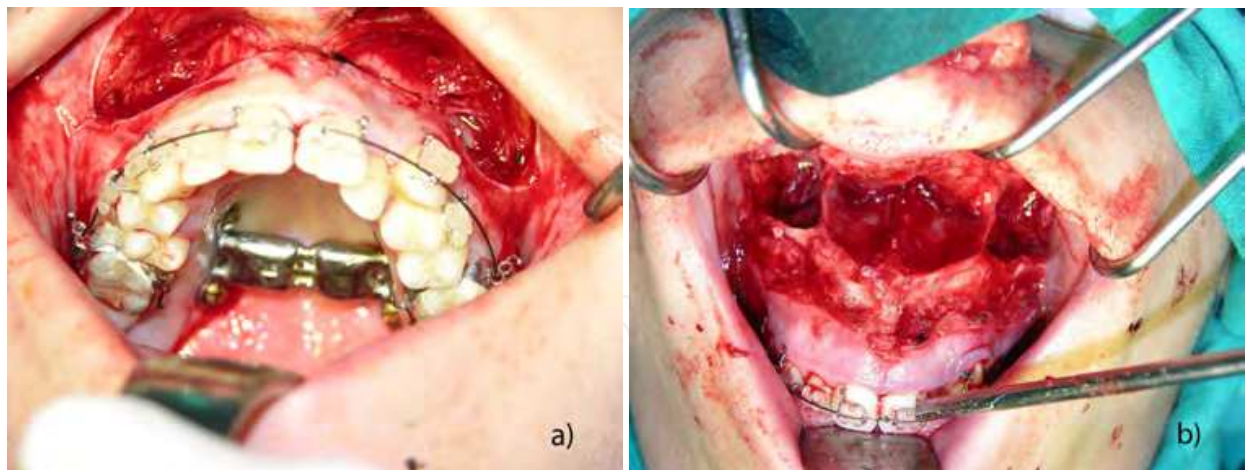


Fig. 18. (A). Palatal distractor fixation by four screws. (B). Downfracture after two pieces Le Fort I osteotomy and palatal distractor fixation by four screws.

This is particularly important in surgically assisted rapid maxillary expansion (SARME) when no fixations systems are applied on the maxilla because only an incomplete Le Fort I is performed (see fig. 19, Case 1).

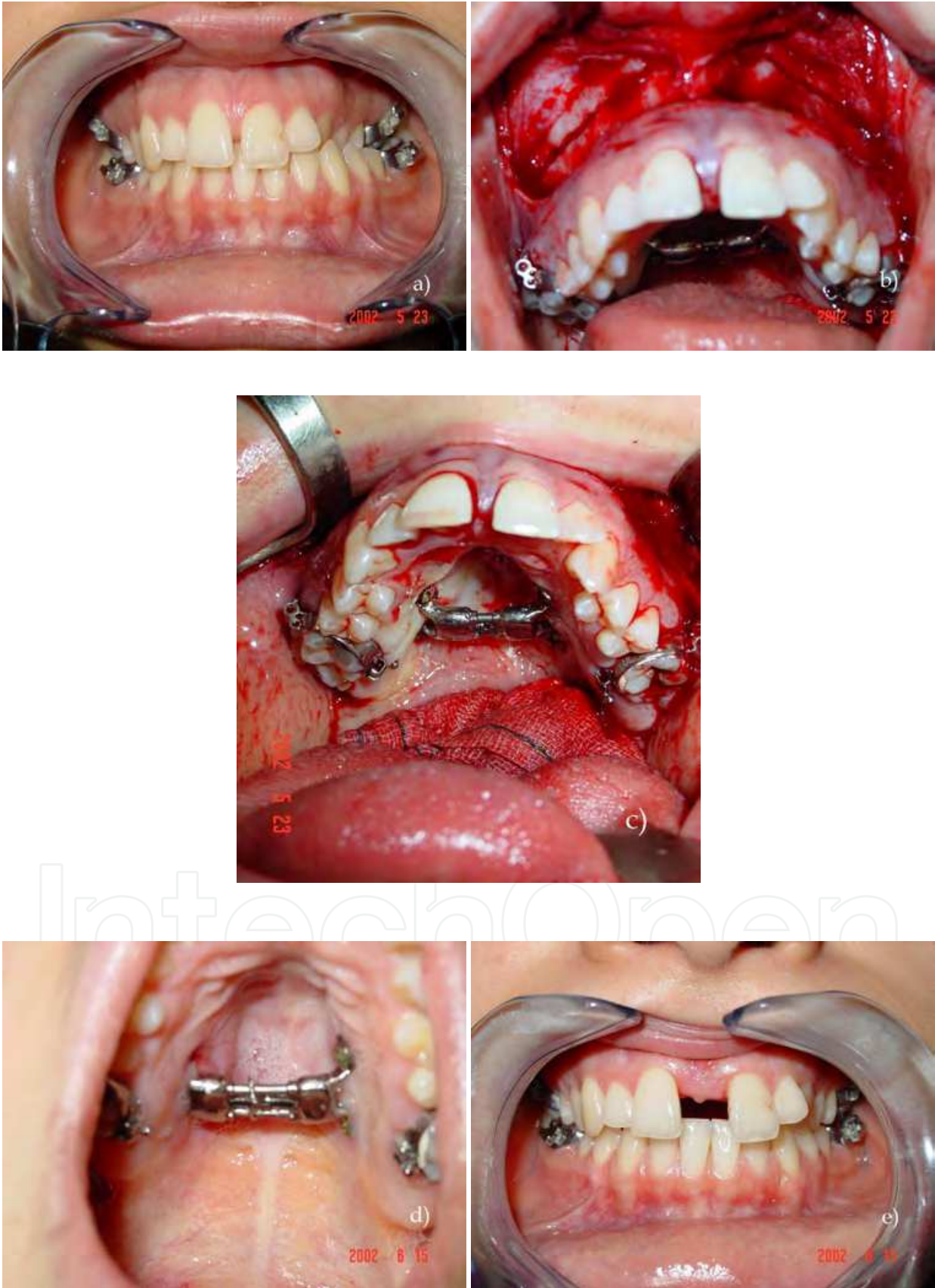

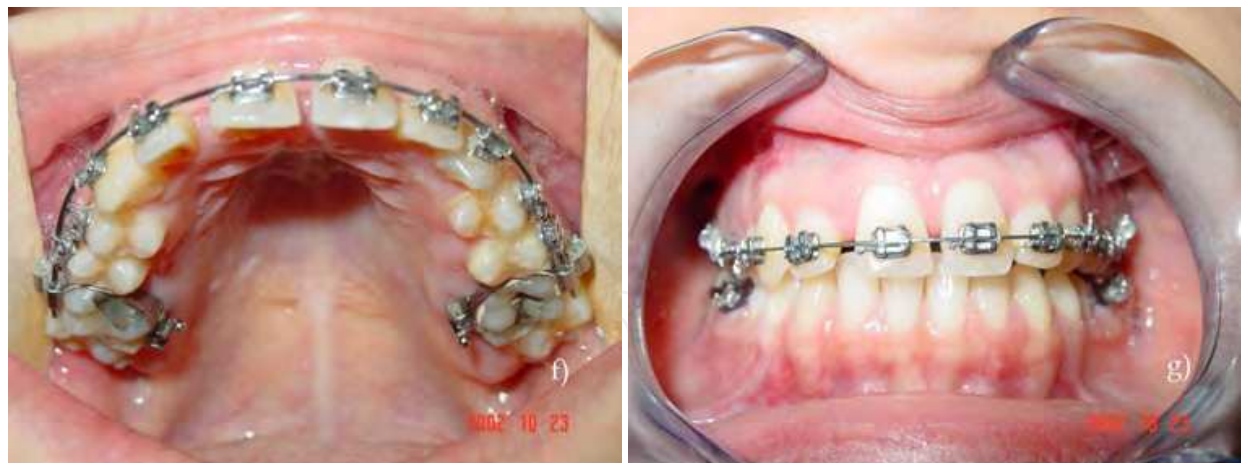


Fig. 19. (Case 1). Patient with maxillary constriction who underwent surgery for maxillary distraction by bone-borne device (SARME-bone). A) Occlusion, pre-operative view. B) Le Fort I and midline osteotomy for maxillary bipartition with palatal distractor in place. C) Palatal distractor fixed at the palatine vault, intra-operative view. D) Post operative palatal mucosa healing after distractor placement. E) Dental occlusion after distraction phase. F) Palatal mucosa healing after palatal distractor removal. G) Dental occlusion after palatal distractor removal.

11. Palatal distraction and maxillary tridimensional repositioning in one stage

One disadvantage of the two techniques for maxillary repositioning (SARME-d with tooth borne device and SARME-b with bone borne device) is the necessity of a second surgery step for three-dimensional maxillary repositioning by a complete Le Fort I osteotomy.

To overtake this problems and combine the best features of the two techniques (stability for osteodistraction osteogenesis and histogenesis in the maxillary distraction by bone borne appliance and one stage expansion and maxillary repositioning by a the LFI-E) a new technique was developed by the Author: a Le Fort I Osteotomy for Maxillary Advancement and Palatal Distraction in 1 Stage (Pinto, 2009; Cortese et al., 2009).

The goal of this technique (LFI-do-bone) was to obtain a good stability in the three-dimensional planes without limiting transversal distraction by PDD.

11.1 Surgical techniques

Under general anaesthesia administered through nasoendotracheal intubation, a Le Fort I osteotomy with down-fracture was performed in combination with a midpalatal osteotomy and palatal distractor setting (LFI-do-bone) (see fig. 20 Case 2).

For this operation, the Le Fort I osteotomy was conducted in the usual manner; however, before the down-fracture was performed, a midline osteotomy was created between the 2 central incisors root up to the posterior nasal spine using a small osteotome. The PDD is typically applied with an epimucosal fixation by four 8-mm screws after predrilling through the holes of the plates and the palatal mucosa. (We prefer using four 8-mm screws after drilling the bone with a bur angled in a vertical direction to avoid the dental roots and any risk of screw release and swallowing). The proper screw position is over the root apex between the first and second bicuspid and between the first and second molars (see fig. 21).

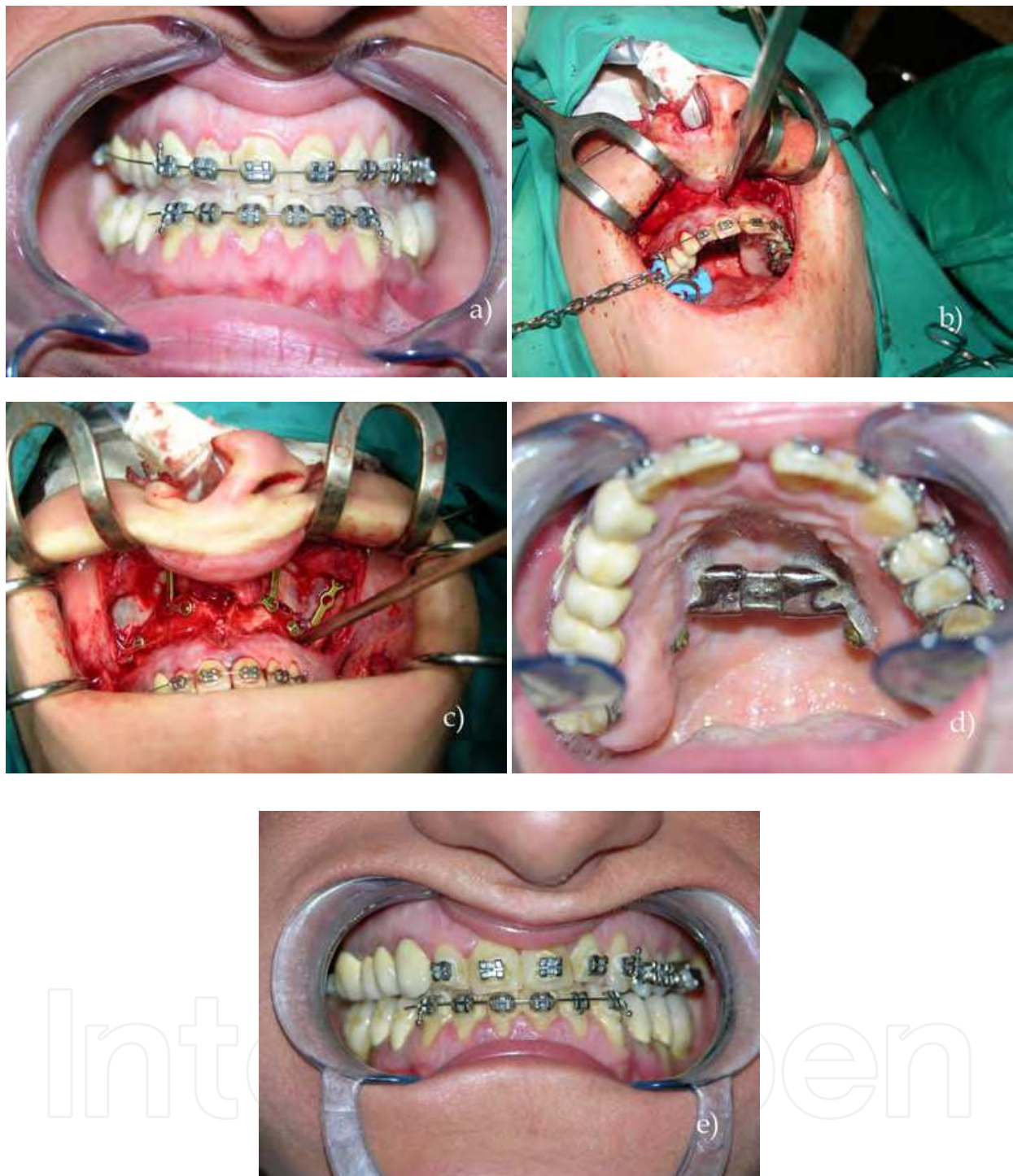

Fig. 20. (Case 2). Patient with class III malocclusion and maxillary constriction who underwent surgery for Le Fort I osteotomy with down fracture, three dimensional maxillary repositioning and distraction with rigid bone borne device in one surgical step (LFI-DO-bone-borne) A) Occlusion, pre-operative view. B) Le Fort I and midline osteotomy for maxillary bipartition with palatal distractor in place. C) Maxillary fixation after down-fracture and maxillary three-dimensional repositioning by four mini-plates and only two screw for each plate to allow maxillary distraction. D) Palatal distractor fixed at the palatine vault, post- distraction view. E) Dental occlusion after palatal distractor removal.

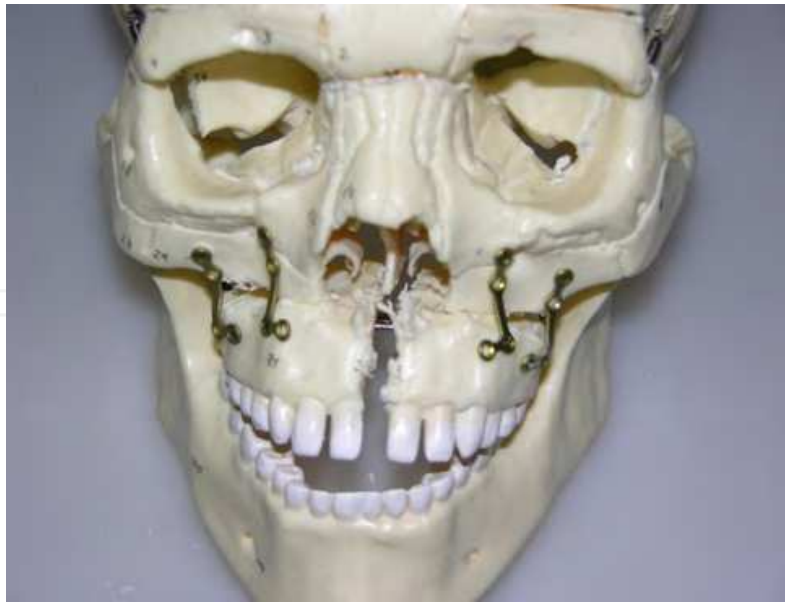

Fig. 21. Complete Le Fort I osteotomy for palatal distraction and maxilla repositioning and semi-rigid fixation by four mini-plate and only 8 screws.

The PDD gives good stability on the horizontal plane, allowing easy management of the 2 fragments of the maxillary bones during the down-fracture procedure. It also facilitates fixation of the maxillary bones in a more advanced position to correct Class III malocclusion or maxillary malposition after down fracture. To allow maxillary expansion when activating the PDD, we perform fixation with 4 miniplates and only 8 or 12 screws (2 or 3 screws for each miniplate) leaving one hole free of the upper part of the miniplate. The miniplates are torqued in the vestibular direction to allow maxillary expansion. The screws are inserted in a very high position in the upper part of the maxillary sinus walls. The goal of this technique is to achieve good stability in the vertical and anteroposterior directions without limiting transversal distraction.

After 7 days of healing, the device is activated in 0.20-mm increments 4 times a day until adequate expansion is achieved. Overexpansion is avoided, because we expect an almost pure skeletal movement without dental share.

Once proper maxillary expansion is obtained, the expansion screw of the device is blocked for 4 months, after which the device is removed under local anaesthesia.

Also when a complete Le Fort I osteotomy is performed in association with a mid palatal distraction, the intrinsic stability of the system is important because in this way it is possible to put 4 mini plates for maxillary fixation taking under proper control the occlusal plane stability particularly in the posterior aspect of the maxilla.

During the post operative time, an inferior molar vestibular torque frequently occurs for decompensation of the lingual inclination of the lower molars. This movement frequently happens because of the new pattern of the bite forces on buccal cuspids of lower molars after crossbite resolution and for the orthodontic appliances effects.

When this situation occurs a little widening of the inferior arch appears with the consequent necessity of further maxillary expansion: in the cases treated with a segmented LFI-e, a new

operation is necessary to obtain further maxillary expansion; also in cases treated with SARME-d technique in association with Hyrax or other tooth borne appliances a restart of the expansion system is at risk for tooth borne problems, in relation to the application of the expansion forces on teeth against an increased resistance because of the initial consolidation of the osteotomies.

On the contrary in the cases treated with the PDD, tooth borne risks are avoided and resistance forces may be easily over passed because of the bone borne and rigidity device characteristics which also assure a bodily bone fragment movement with full control in the three planes of the space.

11.2 Considerations about different (tooth born and bone born) palatal expansion techniques

Transverse maxillary deficiency is a common pathology among adults in treatment by orthodontic therapies; this deficiency can be treated with several different surgical therapies but relapse is one of the main problem in maxillary expansion technique.

There is no consensus in the literature regarding the cause and amount of relapse and whether or not over-correction during the distraction phase is necessary.

A consolidation period of 3 months is generally accepted to be sufficient to avoid most of the relapse due to bone incomplete consolidation. A factor to consider in relapse is the mode of distraction.

It is suggested that relapse increases when a tooth-borne rather than a bone-borne distractor is used. An explanation for this might be the tipping of the elements due to the tooth-borne fixation of the expander. Another factor might be the tipping of the maxillary segments instead of parallel expansion due to the different position of the tooth-borne and bone-borne distractors relative to the 'centre of resistance' (Matteini & Mommaerts, 2001).

This 'centre of resistance' is a combination of the area where the maxillary halves are still connected to the skull after the maxillary corticotomy: they are the pterygoid region (in case of SARME without pterygo-maxillary disjunction), the resistance of the surrounding soft tissues and, above of all, the vertical plates of the palatine bones. This latter strong bone structure acts like a pivot during the maxillary expansion: evidence of this is the commonly accepted concept that the resistance centre of the maxillary bones during expansion is located upward and backward, exactly in the position of the vertical plates of the palatine bones (see fig. 22). For this reason maxillary expansion commonly happens with a v-shaped movement, which is of major amount at the frontal teeth level and minor at the molar area. To avoid this v-shaped movement and related orthodontic problems with difficulties in space closure of the frontal teeth and relapse of cross-bite for molar teeth, it's important to adopt a palatal distractor device with intrinsic rigidity and four anchorage point on the horizontal plane.

Also in surgical assisted expansion with three-dimensional maxillary repositioning after down-fracture, a v-shaped expansion may occur probably for bone contacts at the fractured palatine vertical plates; for this reason a rigid palatal distractor device is recommended.

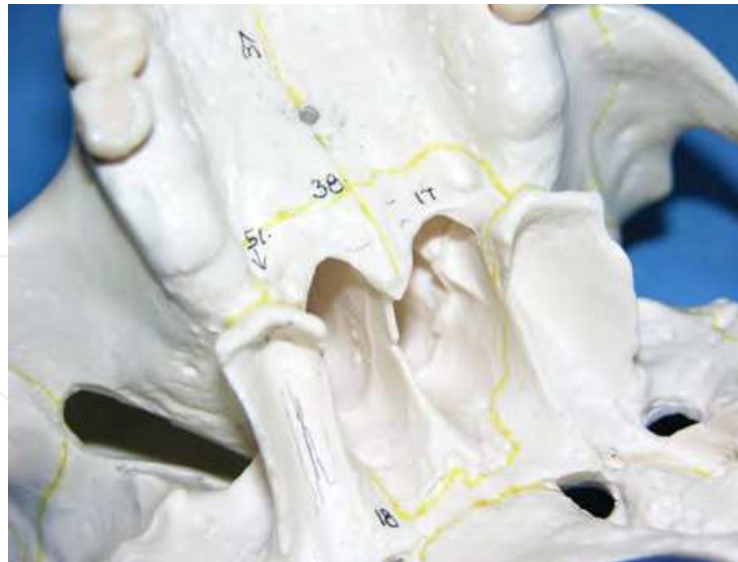

Fig. 22. Horizontal and vertical plates of the palatine bone (n. 17).

Surgical maxillary expansion can be accomplished by several different techniques which can be classified in:

- Segmented Le Fort I with down fracture with expansion and three-dimensional maxillary repositioning (LFI-E)
- Surgical Assisted Rapid Maxillary Expansion by incomplete Le Fort I osteotomy with dental borne devices Hyrax (SARME-dental)
- Surgical Assisted Rapid Maxillary Expansion by incomplete Le Fort I osteotomy with bone borne devices (SARME-bone)
- Le Fort I osteotomy with down fracture, three-dimensional maxillary repositioning and distraction osteogenesis with dental borne device (LFI-DO-dental)
- Le Fort I osteotomy with down fracture, three-dimensional maxillary repositioning and distraction osteogenesis with bone borne devices (LFI-DO-bone)
- Le Fort I osteotomy with down fracture, three-dimensional maxillary repositioning and distraction osteogenesis with rigid bone borne devices (LFI-DO-bone-rigid) (Charezinsky et al., 2009; Cortese, 2009, 2010, 2011; Pinto et al., 2009).

Because of frequent association between maxillary anterior-posterior and vertical deformities with transversal discrepancies, a subsequent orthognatic surgery is necessary in all SARME procedures with consequent costs and risks of an additional procedure under general anaesthesia. In contrast with LFI-E it's possible to obtain palatal expansion and desired three-dimensional movements, but it's considered one of the less stable orthognatic procedure. With the LFI-DO it's possible to combine the advantages of the aforementioned techniques limiting the relative disadvantages. Also in surgical assisted expansion with three-dimensional maxillary repositioning after down-fracture, a v-shaped expansion occur probably because of bone contacts at the fractured palatine vertical plates: for this reason a rigid palatal distractor device is recommended (Pinto et al., 2009).

11.3 Problems and complications

Even if surgical complications are infrequent, in LFI-E severe intra or postoperative haemorrhage, difficulties in positioning and stabilizing the bone segments, oro-antral or oro-

nasal fistulas, permanent mobility of maxillary segments, and loss of gingival papillae for underlying periodontal defects have been reported (Quejada et al., 1986; Lanigan et al., 1990).

With SARME-dental most of the aforementioned problems related with LFI-E are avoided but teeth borne related problems (periodontal defects bone and root reabsorption) may occur and a double stage surgery is necessary when a three-dimensional maxillary repositioning is required.

With SARME-bone related tooth borne problems are avoided but a double stage surgery is necessary if required for a three-dimensional maxillary malposition correction.

With a complete Le Fort I osteotomy with down fracture, associated with distraction osteogenesis by tooth borne devices (LFI-DO dental), it's possible to associate the advantages of the one step surgery by LFI-E with the advantages of the SARME-dental, avoiding the surgical related problems of LFI-E.

By a LFI-DO-bone, using a bone-borne distractor device it's possible to avoid the teeth related problems of a tooth borne device of the aforementioned technique.

By LFI-DO-bone rigid PDD, using a bone-borne distractor devices, it's possible to avoid the problems related to the use of a non-rigid device like asymmetric maxillary expansion (Koudstaal, 2009, 2010, 2011), device components detachment with swallowing risks (Neyt et al., 2002).

As the rigid palatal distractor device (PDD) held the maxillary segments rigidly like a single unit, advantages of using a rigid tooth borne device are the related facilities in positioning and stabilizing the bone segments at the maxillary fixation time during surgery and possibility to start again with palatal expansion when required if occlusal changes in the lower dental arch occurs.

In the Le Fort I with down fracture and maxillary repositioning associated with the technique of palatal distraction by the use of a rigid tooth borne palatal distractor and semi-rigid contention system (four mini-plates with only two or three screws for each miniplate) it's possible to obtain a variation of the occlusal plane particularly useful when an improvement of the posterior maxillary height is required.

With this technique stability of the maxillary bones is good and to perform osteotomy for mandibular repositioning in the same surgical stage is suitable.

In all of the aforementioned surgical procedures close cooperation between orthodontist, dental prosthetist and maxillofacial surgeon is fundamental: to succeed in creating this kind of cooperation partial overlapping of competence between the different disciplines involved in the treatment of this patients is needed.

12. References

- Acebal-Bianco, F. Vuylsteke, PL. Mommaerts, MY. et al. (2000). Perioperative complications in corrective facial orthopedic surgery: A 5-year retrospective study. *J Oral Maxillofac Surg* Vol. 58, No. 7, (Jul 2000), pp. 754-60.
- Arnett, GW. Gunson, MJ. (2004). Facial planning for orthodontists and oral surgeons. *Am J Orthod Dentofacial Orthop*, Vol. 126, No. 3, (Sep 2004), pp. 290-295.

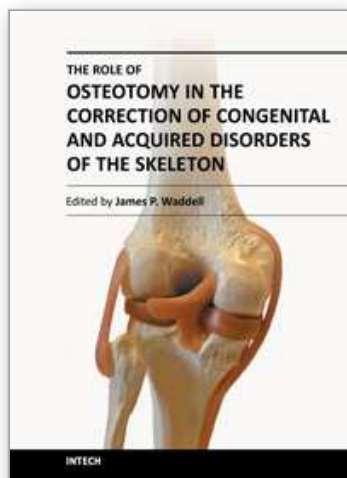
- Arnett, GW. Gunson, MJ. (2010) Esthetic treatment planning for orthognathic surgery. *J Clin Orthod*, Vol. 44, No. 3, (Mar 2010), pp. 196-200.
- Axhausen, G. (1934). Zur Behandlung veralteter disloziert geheilter Oberkieferbrache. *Dtsch Zahn-Mund-Kieferheilk* 6 (1934) 582
- Bailey, LJ. White, RP. Proffit, WR. Turvey, TA. (1997). Segmental LeFort I osteotomy for management of transverse maxillary deficiency. *J Oral Maxillofac Surg*, Vol. 55, No.7, (Jul 1997), pp. 728-731.
- Bell, WH. (1973). Biologic basis for maxillary osteotomies. *Am J Phys Anthropol* Vol. 38, No. 2, (Mar 1973), pp. 279-89.
- Bell, WH. (1975). Le Fort I osteotomy for correction of maxillary deformities. *J Oral Surg*. Vol. 33, No. 6, (Jun 1975), pp. 412-26.
- Bell, WH. (1980-1985). *Surgical correction of Dentofacial Deformities*. W.B. Saunders, Philadelphia, USA.
- Bell, WH. You, ZH. Finn, RA, et al. (1995). Wound healing after multi- segmental Le Fort I osteotomy and transection of the descending palatine vessels. *J Oral Maxillofac Surg*. Vol. 53, No. 12, (Dec 1995), pp. 1425-33; discussion 1433-4.
- Bouloux, GF. Bays, RA. (2000). Neurosensory recovery after ligation of the descending palatine neurovascular bundle during Le Fort I osteotomy. *J Oral Maxillofac Surg*. Vol. 58, No. 8, (Aug 2000), pp. 841-5; discussion 846.
- Chamberland, S. Proffit, WR. (2008). Closer look at the stability of surgically assisted rapid palatal expansion. *J Oral Maxillofac Surg*, Vol. 66, No.9, (Sep 2008), pp. 1895-900.
- Charezinski, M. Balon-Perin, A. Deroux, E. De Maertelaer, V. Glineur, R. (2009). Transverse maxillary stability assisted by a transpalatal device: a retrospective pilot study of 9 cases. *Int J Oral Maxillofac Surg*, Vol. 38, No.9, (Sep 2009), pp. 937-41.
- Converse, JM. Shapiro, HH. (1952). Treatment of developmental malformations of the jaws. *Plast. Surg*. Vol. 10, No. 473, (1952).
- Converse, JM. Horowitz, SL. (1969): The surgical orthodontic approach to the treatment of dentofacial deformities. *Am. J. Orthodont*. Vol. 55, (1969), p. 217
- Cortese, A. Savastano, G. Saturno, G. & Albano, F. (2003). Tridimensional Intraoral Distractor Device in Adult Severe Mandibular Retrognathia: Management Consideration. *From 7th European Craniofacial Congress*, Bologna (Italy), November 20-22, 2003. Medimond International Proceedings. Volume ISBN 88-7587-031-4 pp. 69-74
- Cortese, A. De Cristofaro, M. Papa, F. Savastano, G. (2004). A new transpalatal distractor device. Report of 3 cases with surgical and occlusal evaluations. *Rivista Italiana di Chirurgia Maxillo-Facciale*, Vol. 14, No.1, (Apr 2004), pp. 23-29.
- Cortese, A. Savastano, G. Savastano, M. Spagnuolo, G. Papa, F. (2009). New technique: Le Fort I osteotomy for maxillary advancement and palatal distraction in 1 stage. *J Oral Maxillofac Surg*, Vol. 67, No. 1, (Jan 2009), pp. 223-8.
- Cortese, A. Savastano, M. Savastano, G. Papa, F. Howard, CM & Claudio, PP. (2010). Maxillary constriction treated by a new palatal distractor device: surgical and occlusal evaluations of 10 patients. *J Craniofac Surg*, Vol. 21, No. 2, (Mar 2010), pp. 339-43.
- Cortese, A. Savastano, M. Savastano, G. Claudio, PP. (2011). One-Step Transversal Palatal Distraction and Maxillary Repositioning: Technical Considerations, Advantages,

- and Long-Term Stability. *The Journal of Craniofacial Surgery*. Vol. 22, No. 5, (Sept 2011), pp. 1714-9.
- de Mol van Otterloo, JJ. Leezenberg, JA. Tuinzing, DB. van der Kwast, WA. (1990). The influence of the Le Fort I osteotomy on nasal airway resistance. *Rhinology* Vol. 28, No. 2, (Jun 1990), pp. 107-12.
- Degerliyurt, K. Ueki, K. Hashiba, Y. Marukawa, K. Nakagawa, K. Yamamoto, E. (2008). A comparative CT evaluation of pharyngeal airway changes in class III patients receiving bimaxillary surgery or mandibular setback surgery. *Oral Surg Oral Med Oral Pathol Oral Radiol Endod* Vol. 105, No. 4, (Apr 2008), pp. 495-502.
- Dorfman, HS. Turvey, TA. (1979). Alterations in osseous crestal height following interdental osteotomies. *Oral Surg Oral Med Oral Pathol*. Vol. 48, No. 2, (Aug 1979), pp. 120-5.
- Ellingsen, RH. Artun, J. (1993). Pulpal response to orthognathic surgery: a long-term radiographic study. *Am J Orthod Dentofacial Orthop* Vol. 103, No. 4, (Apr 1993), pp. 338-43.
- Epker, BN. Wolford, LM. (1975). Middle third face osteotomies; their use in the correction of acquired and developmental dentofacial and craniofacial deformities. *J. Oral Surg*. Vol. 3, (1975), pp. 491-514.
- Epker, BN. Fish, LC. (1986). *Dentofacial Deformities*. Mosby, St. Louis, USA.
- Erbe, M. Lehotay, M. Göde, U. Wigand, ME. Neukam, FW. (2001). Nasal airway changes after Le Fort I--impaction and advancement: anatomical and functional findings. *Int J Oral Maxillofac Surg*. Vol. 30, No. 2, (Apr 2001), pp. 123-9.
- Ermel, T. Hoffmann, J. Alfter, G. Göz, G. (1999). Long-term stability of treatment results after upper jaw segmented osteotomy according to Schuchardt for correction of anterior open bite. *J Orofac Orthop*. Vol. 60, No. 4, (1999), pp. 236-45.
- Gautam, P. Valiathan, A. Adhikari, R. (2009). Maxillary protraction with and without maxillary expansion: a finite element analysis of sutural stresses. *Am J Orthod entofacial Orthop*. Vol. 136, No.3, (Sep 2009), pp. 361-6.
- Ghoreishian, M. Gheisari, R. (2009). The effect of maxillary multidirectional movement on nasal respiration. *J Oral Maxillofac Surg* Vol. 67, No. 10, (Oct 2009), pp. 2283-6.
- Haarmann, A. Budihardja, AS. Wolff, KD. Wangerin, K. (2009). Changes in acoustic airway profiles and nasal airway resistance after Le Fort I osteotomy and functional rhinosurgery: a prospective study. *Int J Oral Maxillofac Surg* Vol. 38, No. 4, (Feb 2009), pp. 321-25.
- Haas, AJ. (1980). Long-term posttreatment evaluation of rapid palatal expansion. *Angle Orthod*, Vol. 50, (Jul 1980), No. 3, pp. 189-217.
- Halvorson, EG. Mulliken, JB. (2008). Cheever's double operation: the first Le Fort I osteotomy. *Plast Reconstr Surg* Vol. 121, No. 4, (Apr 2008), pp. 1375-81.
- Hogeman, KE. Wilmar K. (1967). Die Vorverlagerung des Oberkiefers zur Korrektur von Gebiganomalien. *Fortschr. Kiefer Gesichtschir*. Bd 12, Stuttgart; Thieme, 1967
- Howley, C. Ali, N. Lee, R. Cox, S. (2011). Use of the alar base cinch suture in Le Fort I osteotomy: is it effective? *Br J Oral Maxillofac Surg*. Vol. 49, No. 2, (Mar 2011), pp. 127-30.
- Jones, M. (2001) Human gingival and pulpal blood flow during healing after Le Fort I osteotomy. *J Oral Maxillofac Surg*. Vol. 59, No. 1, (Jan 2001), pp. 2-7, discussion 7-8.

- Justus, T. Chang, BL. Bloomquist, D. Ramsay, DS. (2001) Human gingival and pulpal blood flow during healing after Le Fort I osteotomy. *J Oral Maxillofac Surg*. Vol. 59, No. 1, (Jan 2001), pp. 2-7, discussion 7-8.
- Köle, H. (1959). Surgical operations on the alveolar ridge to correct occlusal abnormalities. *Oral Surg. Oral Med. Oral Path*, Vol. 12, (1959), p. 277.
- Koudstaal, MJ. Wolvius, EB. Ongkosuwito, EM. van der Wal, KG. (2008). Surgically assisted rapid maxillary expansion in two cases of osteopathia striata with cranial sclerosis.. *Cleft Palate Craniofac, J* Vol. 45, No.3, (May 2008), pp. 337-42.
- Koudstaal, MJ. Wolvius, EB. Schulten, AJ. Hop, WC. van der Wal, KG. (2009). Stability, tipping and relapse of bone-born versus tooth-borne surgically assisted rapid maxillary expansion; a prospective randomized patient trial. *Int J Oral Maxillofac Surgery*, Vol. 38, No.4, (Apr 2009), pp. 308-15.
- Kramer, FJ. Baethge, C. Swennen, G. Teltzrow, T. Schulze, A. Berten, J. Brachvogel, P. (2004). Intra- and perioperative complications of the LeFort I osteotomy: a prospective evaluation of 1000 patients. *J Craniofac Surg* Vol. 15, No. 6, (Nov 2004), pp. 971-7; discussion 978-9.
- Kumar, V. Pass, B. Guttenberg, SA. et al. (2007). Bisphosphonate-related osteonecrosis of the jaws: A report of three cases demonstrating variability in outcomes and morbidity. *J Am Dent Assoc* Vol. 138, No. 5, (May 2007), pp. 602-9.
- Lanigan, DT. Hey, JH. West, RA. (1990). Aseptic necrosis following maxillary osteotomies: Report of 36 cases. *J Oral Maxillofac Surg* Vol. 48, No. 2, (Feb 1990), pp. 142-56.
- Lanigan, DT. (1997). Ligation of the descending palatine artery: Pro and con. *J Oral Maxillofac Surg* Vol. 55, No. 12, (Dec 1997), pp. 1502-4.
- Le Fort, R. (1900). Fractures de la machoire supérieure. *Cong intenat. De mèd C-r, Sect. de chir. Gèr.* pp. 275-278.
- Le Fort, R. (1901). Etude experimentale sur les fractures de la machoire superieure. *Rev Chir*, Vol. 23, pp. 479-507.
- Little, AC. Burt, DM. Penton-Voak, IS. Perrett, DI. (2001). Self-perceived attractiveness influences human female preferences for sexual dimorphism and symmetry in male faces. *Proc Biol Sci*, Vol. 268, No. 1462, (Jan 2001), pp. 39-44.
- Marchetti, C. Pironi, M. Bianchi, A. Musci, A. (2009). Surgically assisted rapid palatal expansion vs. segmental Le Fort I osteotomy: transverse stability over a 2-year period. *J Craniomaxillofac Surg*, Vol. 37, No.2, (Mar 2009), pp. 74-78.
- Matteini, C. Mommaerts, MY. (2001). Posterior transpalatal distraction with pterygoid disjunction: a short-term model study. *Am J Orthod Dentofacial Orthop*, Vol. 120, No.5, (Nov 2001), pp. 498-502
- Merli, M. Merli, M. Triaca, A. Esposito, M. (2007). Segmental distraction osteogenesis of the anterior mandible for improving facial esthetics. Preliminary results. *World J Orthod*, Vol. 8, No. 1, (Spring 2007), pp. 19-29.
- Mommaerts, MY. (1999). Transpalatal distraction as a method of maxillary expansion. *Br J Oral maxillofac Surg*, Vol. 37, No.4, (Aug 1999), pp. 268-72.
- Morgan, TA. Kirk, LF. (2001). Effects of the multiple-piece maxillary osteotomy on the periodontium. *Int I Adult Orthod Orthognath Surg*, Vol. 16, No.4, (Winter 2001), pp. 255-265.

- Naini, FB. Moss, JP. Gill, DS. (2006). The enigma of facial beauty: esthetics, proportions, deformity, and controversy. *Am J Orthod Dentofacial Orthop*, Vol. 130, No. 3, (Sep 2006), pp. 277-82.
- Neyt, NM. Mommaerts, MY. Abeloos, JV. De Clercq, CA. Neyt, LF. (2002). Problems, obstacles and complications with transpalatal distraction in non-congenital deformities. *J Craniomaxillofac Surg*, Vol. 30, No.3, (Jun 2002), pp. 139-43.
- Nilsson, LP. Granström, G. Röckert, HOE. (1987). Effects of dextrans, heparin and hyperbaric oxygen on mandibular tissue damage after osteotomy in a experimental system. *Int J Oral Maxillofac Surg* Vol. 16, No. 1, (Feb 1987), pp. 77-89.
- Obwegeser, H. (1969). Surgical correction of small or retrodisplaced maxillae. *J. Plast. Reconstr. Surg*, Vol. 43, (1969), p. 351
- Obwegeser, H. (1970). The one time forward movement of the maxilla and backward movement of the mandible for the correction of extreme prognathism. *SSO Schweiz Monatsschr Zahnheilkd*, Vol. 80, No. 5, (May 1970), pp.547-56.
- Panula, K. Finne, K. Oikarinen, K. (2001). Incidence of complications and problems related to orthognathic surgery: A review of 665 patients. *J Oral Maxillofac Surg* Vol. 59, No. 10, (Oct 2001), pp. 1128-1136.
- Parnes, EI. Becker, ML. (1972). Necrosis of the anterior maxilla following osteotomy: Report of a case. *J Oral Surg* Vol. 33, No. 3, (Mar 1972), pp. 326-330
- Park, SB. Yoon, JK. Kim, YI. Hwang, DS. Cho, BH. Son, WS. (2011). The evaluation of the nasal morphologic changes after bimaxillary surgery in skeletal class III malocclusion by using the superimposition of cone-beam computed tomography (CBCT) volumes. *J Craniomaxillofac Surg*. 2011 Jul 2. (Epub ahead of print).
- Perrett, DI. Michael BD. Penton-Voak, IS. Lee, KJ. Rowland, DA. Edwards, R. (1999). Symmetry and Human Facial Attractiveness. *Evolution and Human Behavior*, Vol. 20, No. 5, (Sept 1999), pp. 295-307.
- Phillips, C. Medland, WH. Fields, HW. Proffit, WR. White, RP. (1992). Stability of surgical maxillary expansion. *Int J Adult Orthod Orthognath Surg*, Vol. 7, No.3, (1992), pp. 139-46.
- Pinto, PX. Mommaerts, MY. Wreakes, G. Jacobs, W. (2001). Immediate post expansion changes following the use of the transpalatal distractor. *J Oral Maxillofac Surg*, Vol. 59, No.9, (Sep 2001), pp. 994-1000, discussion 1001.
- Pinto, LP. Bell, WH. Chu, S. Buschang, PH. (2009). Simultaneous 3-dimensional Le Fort I/distractor osteogenesis technique: positional changes. *J Oral Maxillofac Surg*, Vol. 67, No.1, (Jan 2009), pp. 32-9.
- Posnick, JC. Fantuzzo, JJ. Troost, T.(2007). Simultaneous intranasal procedures to improve chronic obstructive nasal breathing in patients undergoing maxillary (le fort I) osteotomy. *J Oral Maxillofac Surg* Vol. 65, No. 11, (Nov 2007), pp. 2273-81.
- Proffit, WR. White, RP. (1991). Surgical Orthodontic Treatment. Mosby-Year Book, St. Louis, USA.
- Quejada, JG. Kawamura, H. Finn, RA. Bell, WH. (1986). Wound healing associated with segmental total maxillary osteotomy. *J Oral Maxillofac Surg*, Vol. 44, No.5, (May 1986), pp. 366-77.
- Ramieri, GA. Spada, MC. Austa, M. Bianchi, SD. Berrone, S. (2005). Transverse maxillary distraction with a bone anchored appliance: dento-periodontal effects and clinical

- and radiological results. *Int J Oral Maxillofac Surg*, Vol. 34, No.4, (Jun 2005), pp. 357-63, discussion 1001.
- Reinkingh, MR. Rosenberg, A. (1996). Palatal surgical splint for transverse stability of LeFort I osteotomies: a technical note. *Int J Oral Maxillofac Surg*, Vol. 25, No.2, (Apr 1996), pp. 105-6.
- Shepherd, J. (2004). Hypotensive anaesthesia and blood loss in orthognathic surgery. *Evid Based Dent*, Vol. 5, No. 1, (2004), p. 16.
- Silverstein, P. (1992). Smoking and wound healing. *Am J Med*, Vol. 15, No. 93, (Jul 1992), pp. 22S-24S..
- Singh, J. Doddridge, M. Broughton, A. et al. (2008). Reconstruction of post-orthognathic aseptic necrosis of the maxilla. *Br J Oral Maxillofac Surg*, Vol. 46, No. 5, (Jul 2008), pp. 408-10.
- Steinhäuser, EW. (1996). Historical development of orthognathic surgery. *J Craniomaxillofac Surg*, Vol. 24, No. 4, (Aug 1996), pp. (195-204).
- Stoker, NG. Epker, BN. (1974). The posterior maxillary ostectomy: a retrospective study of treatment results. *International Journal of Oral Surgery*, Vol. 3, No. 4, (Feb 1974), pp. 153-157.
- Triaca, A. Minoretti, R. Merz B. (2004). Treatment of mandibular retrusion by distraction osteogenesis: a new technique. *Br J Oral Maxillofac Surg*, Vol. 42, No. 2, (Apr 2004), pp. 89-95.
- Triaca, A. Furrer, T. Minoretti, R. (2009). Chin shield osteotomy – A new genioplasty technique avoiding a deep mento-labial fold in order to increase the labial competence. *Int J Oral Maxillofac Surg*, Vol. 38, No. 11, (Nov 2009), pp. 1201-05.
- Triaca, A. Minoretti, R. Saulacic, N. (2010). Mandibula wing osteotomy for correction of the mandibular plane: A case report. *Br J Oral Maxillofac Surg*, Vol. 48, No. 3, (Jul 2010), pp. 182-4.
- Turvey, TA. & Fonseca, RJ. (1980). The anatomy of the internal maxillary artery in the pterygopalatine fossa: its relationship to maxillary surgery. *J Oral Surg* Vol. 38, No. 2, (Feb 1980), pp. 92-95.
- Turvey, TA. Hall, DJ. Warren, DW. (1984). Alterations in nasal airway resistance following superior repositioning of the maxilla. *Am J Orthod* Vol. 85, No. 2, (Feb 1984), pp. 109-14.
- Van de Perre, JP. Stoelinga, PJ. Blijdorp, PA et al. (1996). Perioperative morbidity in maxillofacial orthopaedic surgery: A retrospective study. *J Craniomaxillofac Surg* Vol. 24, No. 5, (Oct 1996), pp. 263-70.
- Walker, DA. Turvey, TA. Warren, DW. (1988). Alterations in nasal respiration and nasal airway size following superior repositioning of the maxilla. *J Oral Maxillofac Surg* Vol. 46, No. 4, (Apr 1988), pp. 276-81.
- Wassmund, M. (1927). *Frakturen und Luxationen des Gesichtsschgdels*, Meusser, Leipzig, Germany.
- Wassmund, M. (1935). *Lehrbuch der praktischen Chirurgie des Mundes und der Kiefer*. Meusser, Bd. I., Leipzig, Germany.
- Wertz, RA. (1970). Skeletal and dental changes accompanying rapid midpalatal suture opening. *Am J Orthod*, Vol. 58, (Jul 1970), No. 1, pp. 41-66.



The Role of Osteotomy in the Correction of Congenital and Acquired Disorders of the Skeleton

Edited by Prof. James Waddell

ISBN 978-953-51-0495-7

Hard cover, 294 pages

Publisher InTech

Published online 11, April, 2012

Published in print edition April, 2012

This book demonstrates specific osteotomy techniques from the skull to the hallux. The role of osteotomy in the correction of deformity is under appreciated in part because of the ubiquitous nature of joint replacement surgery. It should be remembered, however, that osteotomy has a role to play in the correction of deformity in the growing child, the active young adult, and patients of any age with post-traumatic deformity limiting function and enjoyment of life. In this text we bring you a number of papers defining specific problems for which osteotomy is found to be an effective and lasting solution. I hope you find it useful.

How to reference

In order to correctly reference this scholarly work, feel free to copy and paste the following:

Antonio Cortese (2012). Le Fort I Osteotomy for Maxillary Repositioning and Distraction Techniques, The Role of Osteotomy in the Correction of Congenital and Acquired Disorders of the Skeleton, Prof. James Waddell (Ed.), ISBN: 978-953-51-0495-7, InTech, Available from: <http://www.intechopen.com/books/the-role-of-osteotomy-in-the-correction-of-congenital-and-acquired-disorders-of-the-skeleton/le-fort-i-osteotomy-for-maxillary-repositioning-and-distraction>

INTECH
open science | open minds

InTech Europe

University Campus STeP Ri
Slavka Krautzeka 83/A
51000 Rijeka, Croatia
Phone: +385 (51) 770 447
Fax: +385 (51) 686 166
www.intechopen.com

InTech China

Unit 405, Office Block, Hotel Equatorial Shanghai
No.65, Yan An Road (West), Shanghai, 200040, China
中国上海市延安西路65号上海国际贵都大饭店办公楼405单元
Phone: +86-21-62489820
Fax: +86-21-62489821

© 2012 The Author(s). Licensee IntechOpen. This is an open access article distributed under the terms of the [Creative Commons Attribution 3.0 License](https://creativecommons.org/licenses/by/3.0/), which permits unrestricted use, distribution, and reproduction in any medium, provided the original work is properly cited.

IntechOpen

IntechOpen