

We are IntechOpen, the world's leading publisher of Open Access books Built by scientists, for scientists

6,900

Open access books available

186,000

International authors and editors

200M

Downloads

Our authors are among the

154

Countries delivered to

TOP 1%

most cited scientists

12.2%

Contributors from top 500 universities



WEB OF SCIENCE™

Selection of our books indexed in the Book Citation Index
in Web of Science™ Core Collection (BKCI)

Interested in publishing with us?
Contact book.department@intechopen.com

Numbers displayed above are based on latest data collected.
For more information visit www.intechopen.com



Misdiagnosis and Mistreatment for Osteosarcoma: Analysis of Cause and Its Strategy

Yao Yang and Lin Feng

Department of Medical Oncology,

*Sixth People's Hospital of Shanghai Jiaotong University, Shanghai
China*

1. Introduction

Objective To investigate various kinds of causes and consequences for misdiagnosis and mistreatment of osteosarcoma (OS). **Methods** The data from 94 patients with osteosarcoma undergoing misdiagnosis and mistreatment were collected and their clinical causes and consequences were analyzed retrospectively. **Results** The causes contributing to the misdiagnosis among 94 patients, including that patients delayed to consult physician (36 cases, 38.3%), patients underwent medical misdiagnosis (34 cases, 36.17%) and both of components occurred simultaneously (24 cases, 25.53%). The average duration of misdiagnosis was 72.15 d, 7.34 d and 100.68 d, respectively. 28 cases (29.79%) accepted traditional Chinese medicine therapy, 22 (23.40%) cases were treated by incorrect operation. Perhaps there were 56 patients (59.57%) losing limb-salvage procedure opportunity, 16 patients (17.02%) had recurrence after limb-salvage operation, 40 patients (42.55%) underwent metastasis induced by misdiagnosis and mistreatment. **Conclusion** the main cause of misdiagnosis and mistreatment of OS is that doctors, patients and their parents have deficient professional knowledge of OS. CT and MRI examinations are the effective to prevent the misdiagnosis of early OS. The probability of all kinds of diagnoses should be estimated sufficient, the therapeutic protocol should be made consummately and any other treatment procedures should not be taken blindly for atypical cases before question or biopsy.

Osteosarcoma is the most common bone cancer occurred by teenage, and its onset is more occult, higher malignant, and rapid progress, and even early stage lung metastases may occur. In recent years, the integrated treatment including chemotherapy, limb-salvage and technology-based reconstruction is developed rapidly, which is not only improving the survival of patients, but also the quality of life. However its efficacy, quality of life and survival mainly depend on the treatment of clinical stage. But it is found practically that various kinds of causes and consequences for misdiagnosis and mistreatment of osteosarcoma, which lead some patients to amputate and even metastasis of lung and other organ. Therefore, here are the analysis and treatment strategies for the 94 patients with osteosarcoma undergoing misdiagnosis and mistreatment.

2. Materials and methods

2.1 Case choice

The data from 94 patients with pathological diagnosis, osteosarcoma undergoing misdiagnosis and mistreatment from department of Medical Oncology, Sixth People’s Hospital of Shanghai Jiaotong University from Janrary, 2002 to December, 2004 were collected and their clinical causes and consequences were analyzed retrospectively. Among these 94 patients, the youngest is 5 years old, the eldest is 54 years old and the average is 21.48 years old; male is 62 cases and female is 32 cases; primary lesions in the distal femur is 40 cases (42.6%), proximal tibia is 28 cases (29.8%), proximal humerus is 10 cases (10.6%), proximal femur is 6 cases (6.4%) and distal humerus, distal ulna, calcaneus, iliac crest and maxilla is 2 cases respectively, 10 cases totally; according to Enneking & Wolf (1996), stage IIB below is 20 cases (21.3%), stage IIB is 36 cases (38.3%), stage IIB above is 18 cases (19.1) and unknown stage is 20 cases (21.3%).

2.2 Measure of remedial treatment

Most patients had received confirmation of Pathology again in our hospital and meantime accepted MRI for localized lesions, CT for chest, bone scan for whole body, B-mode ultrasound for abdominal and pelvic and serum LDH and AKP check. Chemotherapy before operation was 56 cases, who accepted HD-MTX-CFR,IFO,E-ADM,DDP intravenous chemotherapy 3 times and limb-salvage patients should add E-ADM+DDP intravenous chemotherapy. Chemotherapy after operation was 92 cases (2 case has given up chemotherapy). Among these 90 cases, there were 88 patients operated in our hospital, including 34 cases limb-salvage (40.5%) with 20 cases allograft (23.8%), 4 cases autologous bone graft (4.8%) and 10 cases artificial joint replacement(11.9%), 54 cases amputation (61.1.%) in our hospital and 2 case amputation outside.

3. Result

3.1 Causes of misdiagnosis

Table 1 shows the causes of misdiagnosis for these 94 cases. The factor contribute to misdiagnosis of patients was mainly due to the mild and not typical character of the early clinical symptoms of osteosarcoma. Patients delayed to consult physician because of the

Reasons of misdiagnosis	Cases	Male	Female
Patients	36(28.30)	26(27.66)	10(10.64)
Motion injury	16(17.02)	12(12.77)	4(4.25)
Individual delay	20(21.28)	14(14.89)	6(6.39)
Doctors	34(36.17)	24(25.53)	10(10.64)
Individual delay	18(19.15)	12(12.77)	6(6.38)
Misdiagnosis by X-ray	12(12.77)	10(10.64)	10(2.13)
Misdiagnosis by pathology	4(4.25)	2(2.13)	2(2.13)
Both	24(25.53)	12(12.77)	12(12.77)

Table 1. The analysis of the reasons of misdiagnosis in 47 cases of osteosarcoma [n(%)]

intense of study and work which is 21.28%, and the other reason is about 12.77% because of the misunderstanding of the motion injuries particularly men’s. The factor contribute to patients underwent medical misdiagnosis is 36.17% including the misdiagnosis of motion injuries or arthritis particularly men’s. The factor contribute to the physicians’ delay is 19.15% including the delay of the X-ray examination for patients in time. The misdiagnosis of the X-ray examination is 12.77% for the X-ray examination is lack of the typical X-ray for osteosarcoma at the same time CT and MRI examination haven’t been taken. Among these 47 patients, the misdiagnosis contribute to both patients and physicians is 24 cases (25.53%) and the average misdiagnosis time reached to 100.68 d, and significantly higher than the patients or physician individually.

3.2 Consequent analysis and mistreatment

Table 2 analyzed amputation, local recurrence and distant metastasis contribute to misdiagnosis and mistreatment. Among these 94 patients, the ratio of amputation was 56 cases (59.57%) including 44 local amputated cases at a late stage of disease; the ratio of distant metastasis was 40 cases (42.55%) including 30 distant metastasis cases before treatment and 10 cases after operation, and 8 cases reached CR after chemotherapy; the ration of recurrence after operation is 16 cases(17.02%) including 6 re-amputated cases after bone graft and 4 amputated cases because of local recurrence. 28 cases (29.79%) of misdiagnosis treated as massage, TCM herbs cupping and other traditional Chinese medicine treatment. 22 cases (23.40%) took incorrect surgical procedure, and 4 cases (14.25%) took intra-articular infection with antibiotic up to 3 weeks.

Consequences of misdiagnosis or mistreatment	case	misdiagnosis			Mistreatment with misdiagnosis		
		Factor of patient	Factor of doctor	Bilateral factors	Traditional medicine therapy	Incorrect surgery	Others
Amputation	56(59.57)	24(25.53)	20(21.28)	12(12.76)	18(19.15)	12(12.77)	2(2.13)
Distant metastasis	40(42.55)	16(17.02)	14(14.89)	10(10.64)	10(10.64)	4(4.25)	2(2.13)
Recurrence after operation	16(17.02)	8(8.51)	6(6.38)	6(6.38)	0	6(6.38)	0

Table 2. The analysis of consequences of misdiagnosis or mistreatment in 94 cases of osteosarcoma [n (%)]

4. Discussion

Osteosarcoma at the early stage has no typical clinical symptom and the most common symptom is the local pain, redness and/or mild dysfunction similar to injury. As osteosarcoma occurs in younger’s metaphysis with joint particularly in lower limb joints. Those male adolescents who like sports and their parents are likely to mistake the osteosarcoma as motion injuries. In addition, most of young patients had heavy burdern of learning and lack of the medical knowledge of this disease was the main cause of misdiagnosis. Our study showed that the misdiagnosis due to the patients is 38.30% especially the misdiagnosis of the male adolescents is 27.06%, and the average misdiagnosis

time is 72.15 days. Author thought that it was important to enhance the osteosarcoma knowledge disseminate, and if the pain and red around joints has occurred for one week particular at night whatever with or without motion and injured history, X-ray should be taken timely in the hospital that has the diagnosis conditions for osteosarcoma. If there is any doubt, CT or MRI examinations should be taken in time.

The misdiagnosis due to the doctors is 36.17%, and the average misdiagnosis day is 57.34 d. Most of the doctors especially the doctors from primary hospitals should pay more attention to the clinical symptom of osteosarcoma. When some patients had the typical clinical symptom as treatment, doctors should not be still subjective to misdiagnose as injury or other benign tumors without any imaging. Reviewing 12 osteosarcoma patients with X-ray as treatment, author found that almost cases were lack of the typical osteosarcoma's features for the most X-ray with only small range of bone destruction or Codman triangle. Daylight occurred rarely and another misdiagnosis of x-ray contributed to poor X-ray rates, poor light conditions, incorrect camera position and perspective and other technical factors in the primary hospital. Analyzing 4 cases of pathological misdiagnosis, the main factor was less needle biopsy material or the material from tumor necrosis zone without tumor cells. In addition to educate the knowledge of osteosarcoma to all level of physicians, the combination among clinic, imaging and pathology should be emphasized. Although X-ray clearly shows the size of the tumor lesions and bone destruction and periosteal reaction, it is short of sensitivity and only up to 30% of bone destruction can be detected. So X-ray examination cannot check osteosarcoma at the early stage. CT and MRI examinations have more resolution than X-ray, and they are the prior methods to exam osteosarcoma. They can show the tumor size, location and the relationship to normal tissue more clearly. Furthermore they provide the most important evidence to osteosarcoma clinical stage, surgical approach^{2,3}. Author thought those osteosarcoma suspected in clinic should be checked routine lateral X-ray compared with the healthy side. If necessary, an experienced physician should be asked to observe the focus repeatedly under the lesion site. The suspicious cases should be taken CT or MRI examination and that is the most effective method to prevent misdiagnosis. It is worth mentioned that the biopsy-negative patients who are diagnosed as osteosarcoma probable by clinic and imaging should not be biopsied repeatedly, to avoid artificial compartment open, clinical stage from stage IIA to IIB and cutting tumor cells metastasis. Those cases that are difficult to diagnose should be frozen biopsy before surgery by experienced physicians. Mistreatment is in the premise of misdiagnosis.

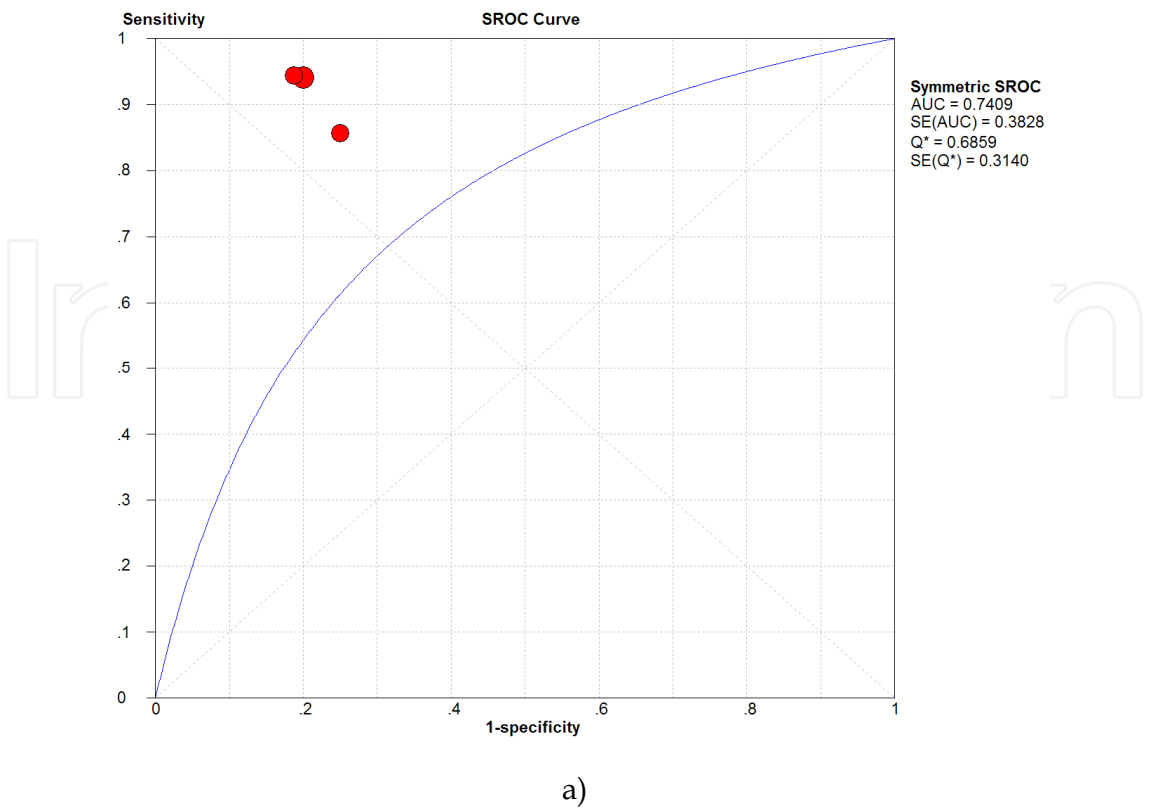
The misdiagnosis and mistreatment of osteosarcoma at the early stage commonly occur in China. Misdiagnosis is relative to patients, relatives and doctors and mistreatment is the responsibility of the doctors'. Among 94 cases, 28 patients had massage, TCM herbs cupping and other traditional Chinese medicine treatments before diagnosing osteosarcoma; 18 patients should be operated as local tumor has violated the outdoor and soft tissue; 10 patients had distant metastasis; 22 patients (23.40%) has taken surgery in local as benign tumors or injury; 2 patient has the indications for limb salvage of the proximal humerus osteosarcoma as stage IIB, who has freed the line shoulder surgery; 4 patients has been treated with antibiotics for arthritic.

Overtreatment is another question. Neoadjuvant chemotherapy increased survival in patients without metastasis, however, the patient who benefit from neoadjuvant

chemotherapy are those had good histopathological response to chemotherapy ¹⁻⁵. Therefore, it's important to develop an effective method to evaluate tumor response to chemotherapy, so that we can choose right patient to surgery and avoid overtreatment. Fluorine-18-fluorodeoxyglucose positron emission tomography with computed tomography (PET-CT) is now widely used with promising results in the initial diagnosis, staging, and detection of recurrence in many kinds of cancer ⁶. Furthermore, some studies revealed that the change of 18F-FDG uptake after chemotherapy is associated with pathological response, providing a good option to noninvasively monitor effectiveness of treatment ⁷⁻¹⁸. We meta-analyzed eleven studies comprising 233 patients. By analyzing two parameters of PET: SUV (standardized uptake value) or TBR (tumor to background ratios), we found that the ratio of TBR after treatment (TBR2) to TBR before treatment (TBR1) (TBR2/1), the SUV after therapy (SUV2) and the ratio of SUV after treatment (SUV2) to SUV before treatment (SUV1)(SUV2/1) have relatively good predicting performance(Table 3, Figure 1a,b,c, unpublished data). Therefore, if we want to make decision that when the patient should undergo surgical treatment after chemotherapy to avoid overtreatment, the PET-CT scan might be the choice.

Studies	N	Positive LR(95% CI)	Q	Negative LR(95% CI)	Q
TBR2:1	57	4.26(2.01-9.04)	0.2	0.11 (0.03-0.36)	0.63
SUV2	138	3.56(1.80-7.0)	1.37	0.56(0.39-0.80)	5.72
SUV2:1	233	1.90(1.27-2.85)	15.13	0.47(0.34-0.66)	7.54

Table 3. Likelihood ratios for the association between PET and histological response to chemotherapy (unpublished).



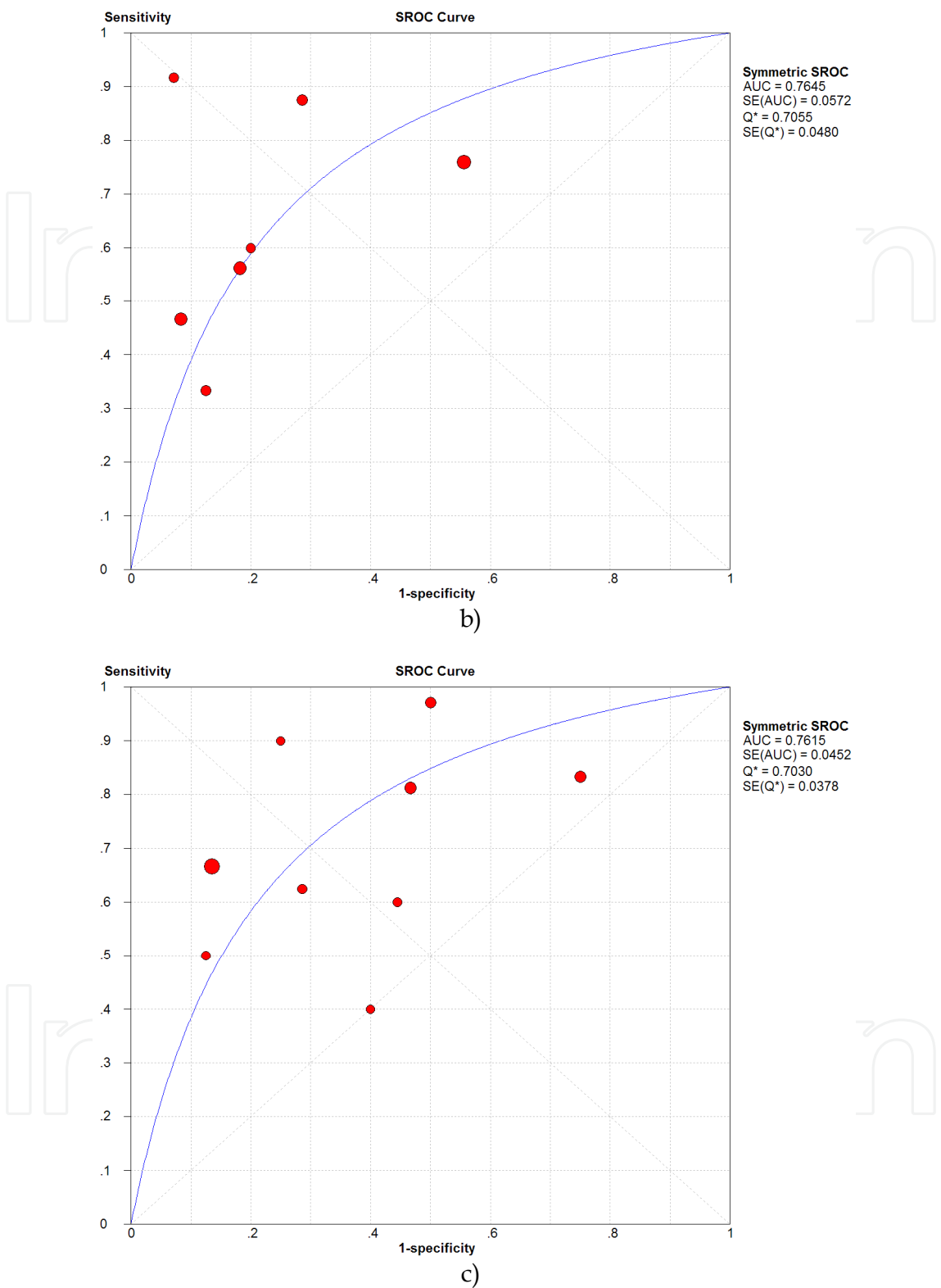


Fig. 1. The summary receiver operating characteristic (SROC) curves for TBR2:1(a), SUV2 (b) and SUV2:1(c) on a per-patient basis. Each solid circle represents each study in the meta-analysis. The size of the circle indicates the study size. The *Q indexes estimate for TBR2:1, SUV2 and SUV2:1 were 0.6859, 0.7055 and 0.7030 respectively. AUC: area under the curve; SE, standard error. (unpublished).


It is analyzed retrospectively that all misdiagnosed patients have the limb-salvage instructions by X-ray film before treatment. Lung was the distant metastasis location for 40 case and almost cases hadn't taken Chest CT as treatment. Data of our study shows mistreatment not only delay the best time of treatment, but also stimulate the growth of tumor cell directly and leading to osteosarcoma cells partial or/and distant metastasis. Reviewing previous data, it is commonly misdiagnosed malignancy as carcinoid or inflammatory disease with Chinese medical treatment or surgical debridement and bone graft, and the main reason of misdiagnosis is the lack of clinical knowledge by physicians. Our study indicates the diagnosis of osteosarcoma should combine clinic, imaging and pathology as practice. For those atypical clinical manifestations or bone destruction of X-ray not clearly for early diagnosis, clinical physicians should read X-ray film carefully and even enhance the relationship with radiated and pathological doctor. Before treatment or surgery, clinical physicians should estimate all kinds of diagnosis and develop comprehensive treatment program, and Chinese medicine treatment can be considered after completely getting rid of bone cancer. If the diagnosis of osteosarcoma has been clearly, chest CT should be taken to avoid distant metastasis and develop treatment program before surgery. In addition, those patients of extremity osteosarcoma that has the indication for limb salvage as stage IIA, in the premise of preoperative chemotherapy, direct surgery may affect life quality of patients and the long-term survival may not be improved further.

5. References

- [1] Picci, P., et al. Relationship of chemotherapy-induced necrosis and surgical margins to local recurrence in osteosarcoma. *Journal of clinical oncology : official journal of the American Society of Clinical Oncology*. 1994; 12:12: 2699-705.
- [2] Bielack, S.S., et al. Prognostic factors in high-grade osteosarcoma of the extremities or trunk: an analysis of 1,702 patients treated on neoadjuvant cooperative osteosarcoma study group protocols. *Journal of clinical oncology : official journal of the American Society of Clinical Oncology*. 2002; 20:3: 776-90.
- [3] Rosen, G., et al. Primary osteogenic sarcoma of the femur: a model for the use of preoperative chemotherapy in high risk malignant tumors. *Cancer Invest.* 1984; 2:3: 181-92.
- [4] Picci, P., et al. Prognostic significance of histopathologic response to chemotherapy in nonmetastatic Ewing's sarcoma of the extremities. *Journal of clinical oncology : official journal of the American Society of Clinical Oncology*. 1993; 11:9: 1763-9.
- [5] Rosen, G., et al. Proceedings: Disease-free survival in children with Ewing's sarcoma treated with radiation therapy and adjuvant four-drug sequential chemotherapy. *Cancer*. 1974; 33:2: 384-93.
- [6] Quarles van Ufford, H.M., et al. Added value of baseline 18F-FDG uptake in serial 18F-FDG PET for evaluation of response of solid extracerebral tumors to systemic cytotoxic neoadjuvant treatment: a meta-analysis. *Journal of nuclear medicine : official publication, Society of Nuclear Medicine*. 2010; 51:10: 1507-16.
- [7] Gaston, L.L., et al. (18)F-FDG PET response to neoadjuvant chemotherapy for Ewing sarcoma and osteosarcoma are different. *Skeletal radiology*. 2011.
- [8] Hawkins, D.S., et al. Evaluation of chemotherapy response in pediatric bone sarcomas by [F-18]-fluorodeoxy-D-glucose positron emission tomography. *Cancer*. 2002; 94:12: 3277-84.

- [9] Hawkins, D.S., et al. [18F]Fluorodeoxyglucose positron emission tomography predicts outcome for Ewing sarcoma family of tumors. *Journal of clinical oncology : official journal of the American Society of Clinical Oncology*. 2005; 23:34: 8828-34.
- [10] Denecke, T., et al. Assessment of histological response of paediatric bone sarcomas using FDG PET in comparison to morphological volume measurement and standardized MRI parameters. *European journal of nuclear medicine and molecular imaging*. 2010; 37:10: 1842-53.
- [11] Costelloe, C.M., et al. 18F-FDG PET/CT as an indicator of progression-free and overall survival in osteosarcoma. *Journal of nuclear medicine : official publication, Society of Nuclear Medicine*. 2009; 50:3: 340-7.
- [12] Nair, N., et al. Response of Osteosarcoma to Chemotherapy. Evaluation with F-18 FDG-PET Scans. *Clinical positron imaging : official journal of the Institute for Clinical P.E.T.* 2000; 3:2: 79-83.
- [13] Franzius, C., et al. Prognostic significance of (18)F-FDG and (99m)Tc-methylene diphosphonate uptake in primary osteosarcoma. *Journal of nuclear medicine : official publication, Society of Nuclear Medicine*. 2002; 43:8: 1012-7.
- [14] Schulte, M., et al. Evaluation of neoadjuvant therapy response of osteogenic sarcoma using FDG PET. *Journal of nuclear medicine : official publication, Society of Nuclear Medicine*. 1999; 40:10: 1637-43.
- [15] Franzius, C., et al. Evaluation of chemotherapy response in primary bone tumors with F-18 FDG positron emission tomography compared with histologically assessed tumor necrosis. *Clinical nuclear medicine*. 2000; 25:11: 874-81.
- [16] Ye, Z., et al. Response of osteogenic sarcoma to neoadjuvant therapy: evaluated by 18F-FDG-PET. *Annals of nuclear medicine*. 2008; 22:6: 475-80.
- [17] Iagaru, A., et al. F-18 FDG PET and PET/CT evaluation of response to chemotherapy in bone and soft tissue sarcomas. *Clinical nuclear medicine*. 2008; 33:1: 8-13.
- [18] Huang, T.L., et al. Comparison between F-18-FDG positron emission tomography and histology for the assessment of tumor necrosis rates in primary osteosarcoma. *Journal of the Chinese Medical Association : JCMA*. 2006; 69:8: 372-6.

IntechOpen



Osteosarcoma

Edited by Dr. Manish Agarwal

ISBN 978-953-51-0506-0

Hard cover, 174 pages

Publisher InTech

Published online 11, April, 2012

Published in print edition April, 2012

This book is aimed at quickly updating the reader on osteosarcoma, a dreaded primary bone cancer. Progress in management of osteosarcoma has been slow after the evolution of chemotherapy and limb salvage surgery. Research is now directed towards identifying molecular targets for systemic therapy. Availability of chemotherapy drugs and low cost implants in developing world have allowed limb salvage surgery to develop. This book looks at current basic knowledge on osteosarcoma and some of the developments in research which have the potential to change the prognosis.

How to reference

In order to correctly reference this scholarly work, feel free to copy and paste the following:

Yao Yang and Lin Feng (2012). Misdiagnosis and Mistreatment for Osteosarcoma: Analysis of Cause and Its Strategy, Osteosarcoma, Dr. Manish Agarwal (Ed.), ISBN: 978-953-51-0506-0, InTech, Available from: <http://www.intechopen.com/books/osteosarcoma/misdiagnosis-and-mistreatment-of-osteosarcoma-analysis-of-the-causes-and-the-solutions->

INTECH
open science | open minds

InTech Europe

University Campus STeP Ri
Slavka Krautzeka 83/A
51000 Rijeka, Croatia
Phone: +385 (51) 770 447
Fax: +385 (51) 686 166
www.intechopen.com

InTech China

Unit 405, Office Block, Hotel Equatorial Shanghai
No.65, Yan An Road (West), Shanghai, 200040, China
中国上海市延安西路65号上海国际贵都大饭店办公楼405单元
Phone: +86-21-62489820
Fax: +86-21-62489821

© 2012 The Author(s). Licensee IntechOpen. This is an open access article distributed under the terms of the [Creative Commons Attribution 3.0 License](https://creativecommons.org/licenses/by/3.0/), which permits unrestricted use, distribution, and reproduction in any medium, provided the original work is properly cited.

IntechOpen

IntechOpen